

See discussions, stats, and author profiles for this publication at: <https://www.researchgate.net/publication/328239233>

Pure non- gestational ovarian choriocarcinoma

Article in *Journal of Pediatric Surgery Case Reports* · October 2018

DOI: 10.1016/j.epsc.2018.10.005

CITATIONS

0

READS

12

11 authors, including:



Irene Mutua

University of Nairobi

4 PUBLICATIONS 1 CITATION

[SEE PROFILE](#)



Denver Mariga

2 PUBLICATIONS 0 CITATIONS

[SEE PROFILE](#)



Wairimu Waweru

University of Nairobi

10 PUBLICATIONS 39 CITATIONS

[SEE PROFILE](#)

Some of the authors of this publication are also working on these related projects:



Brachial plexus [View project](#)



UTILITY OF BRUSH CYTOLOGY IN EVALUATION OF ORAL MUCOSAL LESIONS AMONG PATIENTS ATTENDING DENTAL CLINIC AT KENYATTA NATIONAL HOSPITAL [View project](#)



Pure non-gestational ovarian choriocarcinoma

Mutua Irene^{a,*}, Moses Njoroge^b, Dennis Inyangala^c, Mwende Caroline^c, Denver Mariga^a, Wairimu Waweru^d, Swaleh Shahbal^e, Peter Mwika^e, Kihiko Kuria^e, Francis Osawa^e, Joel Lessan^f

^a Kampala International University, Uganda

^b Moi University, Kenya

^c University of Nairobi, Kenya

^d Department of Human Pathology, University of Nairobi, Kenya

^e Department of Surgery, College of Health Sciences, University of Nairobi, Kenya

^f Kenyatta National Hospital, Kenya

ARTICLE INFO

Keywords:

Pure non-gestational ovarian choriocarcinoma
Germ cell tumor
Chemotherapy

ABSTRACT

We present a case of a 9-year-old female child who we are managing for pure non-gestational ovarian choriocarcinoma at Kenyatta National Hospital. It is an extremely rare germ cell tumor and quite aggressive. Sub-total hysterectomy, bilateral salpingo-oophorectomy, partial omentectomy and appendectomy was done. The child is currently undergoing adjuvant chemotherapy. Prognosis is however reported to be dismal.

1. Introduction

Ovarian Choriocarcinoma can arise in one of three ways: as a primary choriocarcinoma associated with ovarian pregnancy; as a metastatic choriocarcinoma from a primary gestational choriocarcinoma arising in other parts of the genital tract, mainly the uterus; and as a germ cell tumor differentiating in the direction of trophoblastic structures and admixed with other neoplastic germ cell elements [1]. A tumor arising in the latter way is classified as a non-gestational choriocarcinoma, and when the tumor has only trophoblastic elements, then it is a pure non-gestational choriocarcinoma as in our patient.

2. Case presentation

We present a case of a 9yr old female child who presented to Kenyatta National hospital with a 3/12 history of abdominal swelling. It was initially in the suprapubic region and gradually increased in size up to the epigastric region. The mass was constantly painful. The child also had nausea and vomiting, mostly in the mornings, loss of appetite and there was history of weight loss. She did not have fevers. She had per vaginal bleeding 2/12 prior to admission. Her pubic hair and breasts also started to form within the 3 months of symptoms (Fig. 1).

On examination, she was alert though lethargic, pale and wasted. On abdominal exam, there was a palpable mass with a fundal height of 30/40, tender, firm, immobile, with smooth surface and no skin changes. Digital rectal exam revealed an anterior firm mass which was

tender and adherent to the rectal mucosa.

2.1. Other systemic examination was normal

Laboratory investigations; Full blood count showed decreased haemoglobin levels of 6.8 g/dl and the other parameters were within the normal limits. Serum tumor markers showed an elevated B- HCG levels of 444,900 mIU/ml (0–4), CEA of 1.53 ng/ml (0–5), CA 125 of 48.32U/ml (0–35) and AFP of 0.70 IU/ml (0–5).

A diagnosis of germ cell tumor was made based on the elevated B-HCG and normal AFP serum levels.

A pelvic ultrasound scan showed a large complex heterogenous pelvic mass with extension to abdomen and with cystic degenerations within it. MRI abdominopelvic (Fig. 2) showed a complex mass arising from the pelvis with enhancing septations measuring 17 × 14 × 8 cm. The ovaries were not clearly delineated from the mass. A chest x-ray showed clear lung fields.

We transfused the child and an informed consent was given for a laparotomy. Intraoperatively, we found minimal ascites and an abdominopelvic mass. It was arising from the left ovary. It had an omental cover and adherent to the gut at the ascending, transverse, descending and sigmoid colon. The appendix and rectum were also adherent to the tumor. (Fig. 3). The mass was infiltrating the uterus, fallopian tubes and the right ovary. The liver was grossly free of the tumor.

Adhesiolysis, excision of the mass, sub-total hysterectomy, bilateral salpingo-oophorectomy and appendectomy was done. However,

* Corresponding author. University of Nairobi, P.O Box 19676- 00202, Nairobi, Kenya.

E-mail address: immutua@yahoo.com (M. Irene).

<https://doi.org/10.1016/j.epsc.2018.10.005>

Received 29 September 2018; Accepted 10 October 2018

Available online 11 October 2018

2213-5766/ © 2018 The Authors. Published by Elsevier Inc. This is an open access article under the CC BY-NC-ND license (<http://creativecommons.org/licenses/by-nc-nd/4.0/>).

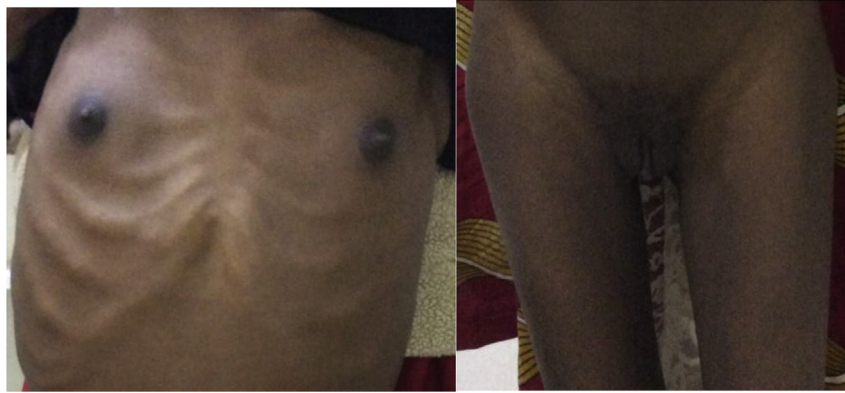

Fig. 1. Wasting and precocious puberty in the patient. Tanner stage III of breast and pubic hair development.

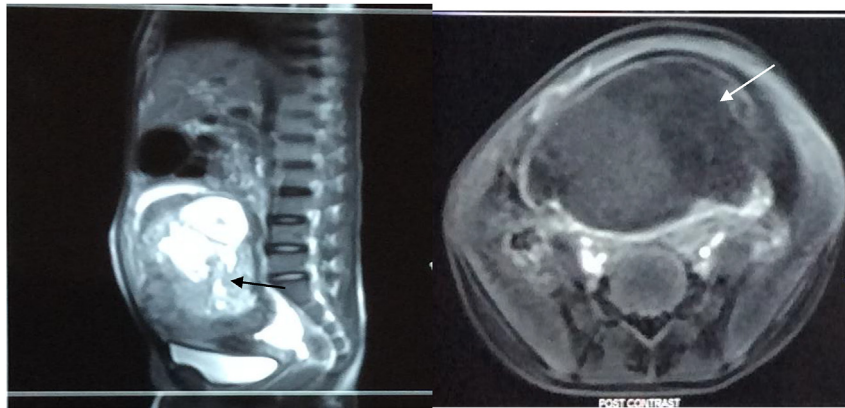


Fig. 2. MRI abdominopelvic showing the mass of pelvic origin with both cystic and solid components (black arrow on the left and white arrow on the right).



Fig. 3. Omentum and the transverse colon adherent to the mass as shown by black arrow. White arrow shows a hemorrhagic portion of the tumor.

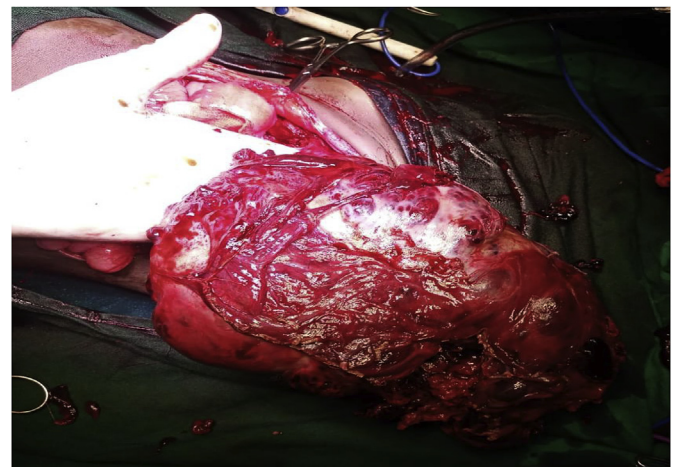


Fig. 4. Tumor following excision.

remnants of the tumor adherent to the rectum were left and there was peritoneal spillage during excision of the tumor. An implantable subcutaneous venous access port was also inserted for administration of adjuvant chemotherapy (see Figs. 4–7).

Prominent lymphovascular invasion and necrosis was seen (Fig. 8).

Histology of the appendix showed tumor infiltrating the serosal surface towards the lumen (Fig. 9).

3. Discussion

Choriocarcinoma are the most aggressive form of gestational trophoblastic diseases owing to their rapid growth and metastatic potential. Choriocarcinoma of the ovary can be either gestational or non-gestational type. The presence of corpus luteum of pregnancy adjacent to the tumor indicates the gestational type while a search for paternal DNA allows a definite distinction between the two types with gestational having paternal genomic structure while non-gestational having genomes of only maternal origin [2]. DNA polymorphism is however not readily available in our laboratory setup and was thus not done. Goswami et al. however suggested that a diagnosis of non-gestational

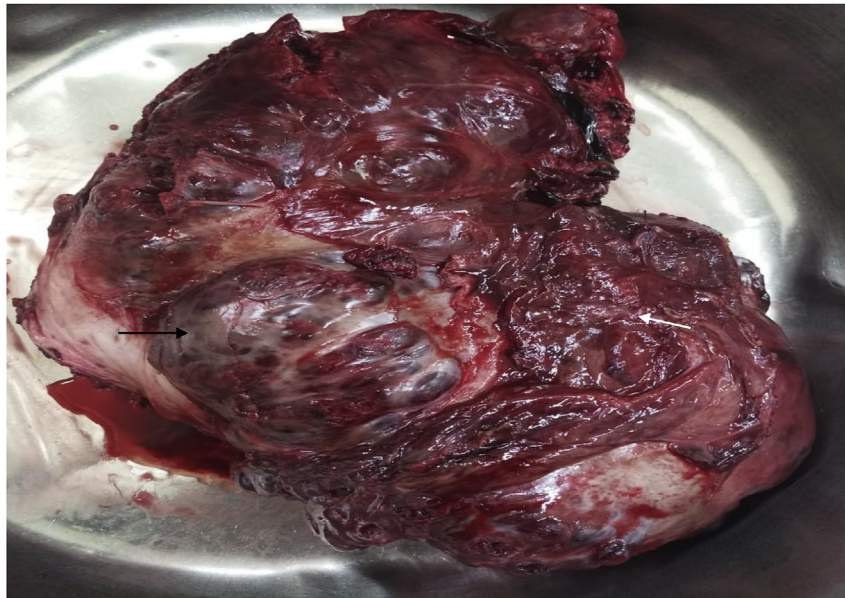

Fig. 5. Cystic (black arrow), hemorrhagic and necrotic (white arrow) components of the tumor which measured 220 × 170 × 60 mm.

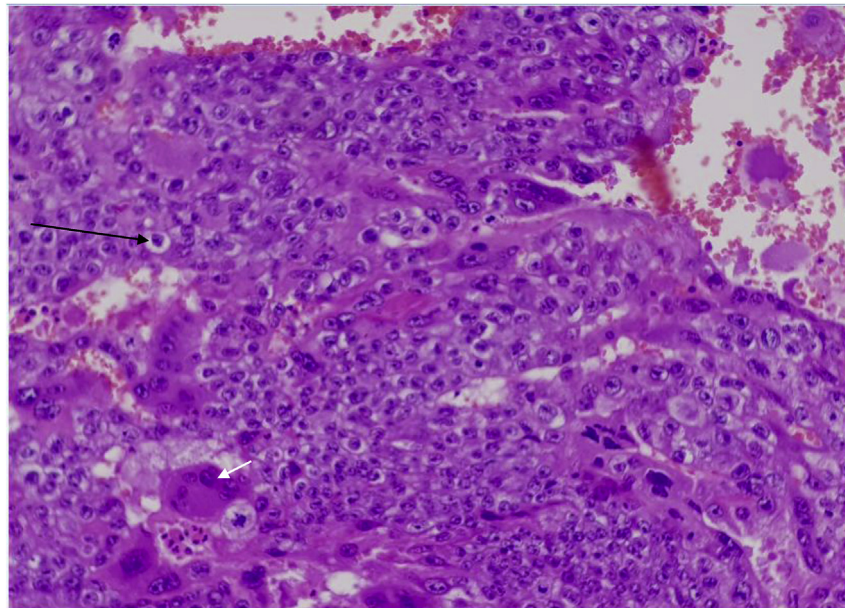


Fig. 6. Showing the tumor composed of cytotrophoblasts (black arrow), intermediate trophoblasts & syncytiotrophoblasts (white arrow). There was brisk mitosis of > 20/HPF.

choriocarcinoma be reserved for pre-menarchial girls [4]. Our patient was 9 years old and may have just begun to experience her menses as there was an episode of per vaginal bleeding two months prior to presentation.

Non-gestational ovarian choriocarcinoma (NGCC) is exceedingly rare and accounts for only 0.6% of all ovarian malignancy with a mean age of 13.6 ± 6.9 years old [3,4].

NGCC is usually of mixed type associated with other germ cell tumours such as immature teratoma, endodermal sinus tumor, embryonal carcinoma and dysgerminoma [4]. The tumor has a marked tendency to metastasize early by blood-borne dissemination, to the lungs (80%), pelvis (20%), vagina (30%), liver (10%) and other rare sites including gastrointestinal tract, spleen and kidney. The central nervous system is seldom involved in the absence of pulmonary metastases [5]. Brain metastasis have been associated with the worst prognosis as they are often associated with haemorrhage due to the syncytiotrophoblasts

propensity to infiltrate vessel walls. Our patient had extensive local metastasis of the tumor which had infiltrated the uterus, both fallopian tubes and the contralateral ovary. There was GIT involvement as the tumor had also infiltrated rectum and appendix. Histological examination of the appendix showed tumor infiltrating the serosa surface towards the lumen and there was prominent lymphovascular invasion by tumor cells. She was classified as stage IIIC as per International Federation of Gynecology and Obstetrics (FIGO) guidelines [6]. There was no evidence at the time of presentation of pulmonary metastasis. However proper follow up during treatment and even beyond is required as non-gestational choriocarcinoma has been shown in a case study to have late metastasis presenting up to two years later to the brain despite appropriate chemotherapy [7]. There is no clear consensus on the right chemotherapy regimen to be used with majority of patients being put on methotrexate based regimens for both gestational Choriocarcinoma and non-gestational choriocarcinoma. On direct

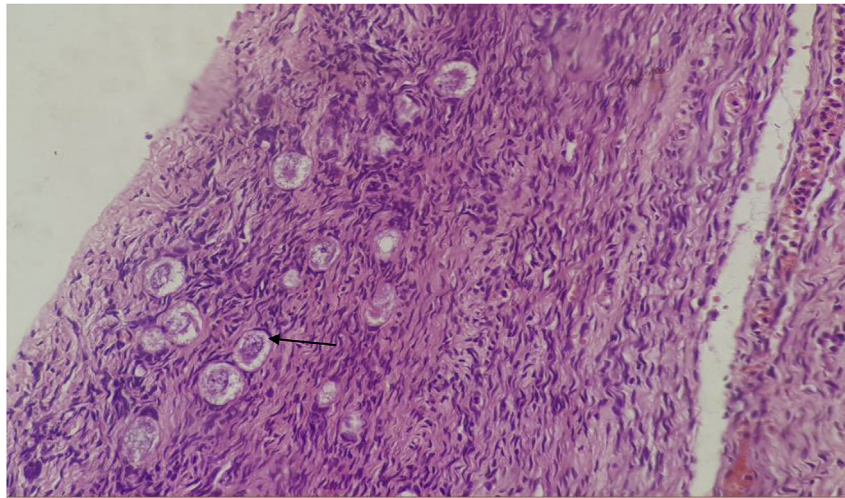


Fig. 7. Primordial follicle of the ovary (black arrow).

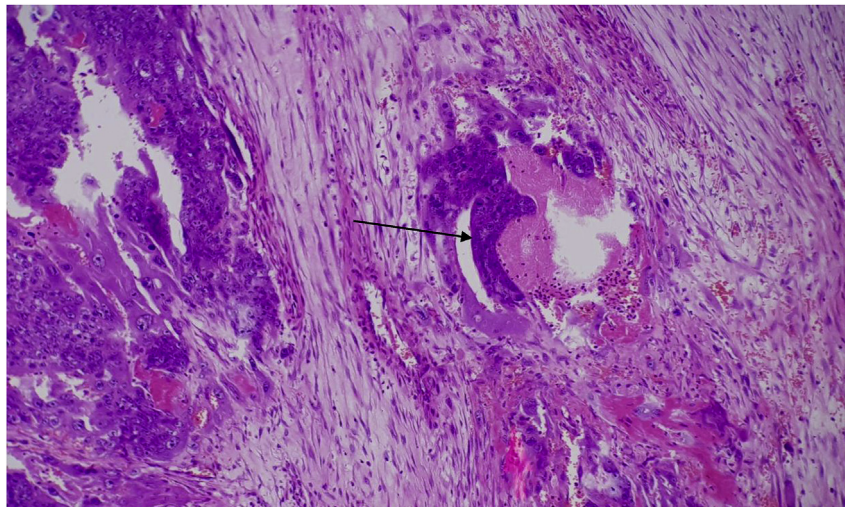


Fig. 8. Blood vessel infiltration by tumor.

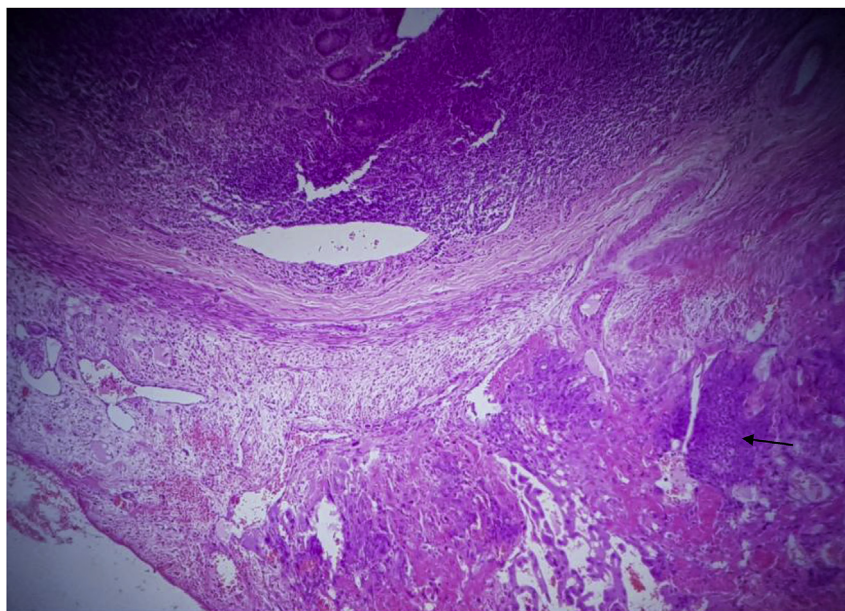


Fig. 9. Appendix infiltrated by tumor as indicated by black arrow.

assessment by Lin et al., there was no major difference between patients on germ cell tumor regimens (bleomycin, etoposide, cisplatin) versus methotrexate based regimens [8]. Our patient is on a methotrexate based multi agent regimen: etoposide, methotrexate, actinomycin- D, cyclophosphamide and vincristine and we await to see her response to the regimen.

4. Conclusion

Despite the extremely low incidence of pure non-gestational choriocarcinoma, there is sufficient evidence in literature that cytoreductive surgery in combination with post-operative chemotherapy may be an effective therapeutic strategy for pure ovarian choriocarcinomas. Though non-gestational choriocarcinoma has been shown to have a worse prognosis, there are also numerous cases of complete resolution of symptoms. We envision that as we follow up our patient she will be among the successful cases.

Patient consent

Consent to publish the case was not obtained. This report does not contain any personal information that could lead to the identification of the patient.

Funding

No funding or grant support.

Authorship

All authors attest that they meet the current ICMJE criteria for Authorship.

Conflict of interest

The following authors have no financial disclosures: (MI, MN, DI, MC, DM, WW, SS, PM, KK, FO, JL).

References

- [1] Hye P, Ami P, Joo Y, Kim, et al. A case of non- gestational choriocarcinoma arising in the ovary of a postmenopausal woman. *J Gynecol Oncol* 2009;20(3):192–4. Sep.
- [2] Narges IM, Nasrin S, Parvaneh RM, et al. Pure ovarian choriocarcinoma: report of two cases. *J Res Med Sci* 2009;14(5):327–30.
- [3] Yamamoto E. Ovary: choriocarcinoma: atlas of genetics and cytogenetics in oncology and haematology. 2009.
- [4] Goswami D, Sharma K, Zutshi V, et al. Non- gestational pure ovarian chor- iocarcinoma with contralateral teratoma. *Gynecol Oncol* 2001;80:262–6. [PubMed].
- [5] Kidd D, Plant GT, Scaravilli F, McCartney ACE, Stanford M, Graham EM. Metastatic choriocarcinoma presenting as multiple intracerebral haemorrhages: the role of imaging in the elucidation of the pathology. *J Neurol Neurosurg Psychiatry* 1998;65:939–41.
- [6] Prat J. FIGO Committee on Gynaecologic Oncology: FIGO Guidelines. Staging clas- sification for cancer of the ovary, fallopian tube and peritoneum. *Int J Gynaecol Obstetrics* 2014 Jan;124(1):1–5.
- [7] Rao KVLN, Subhas K, Jagathlal G, et al. A pure non-gestational ovarian chor- iocarcinoma with delayed solitary brain metastases: case report and review of the literature. *J Neurosci Rural Pract* 2015;6(4):578–81.
- [8] Lin L, Kaixuan Y, Hai W, et al. Pure choriocarcinoma of the ovary: a case report. *J Gynecol Oncol* 2011;22(2):135–9.