

**A FIVE YEAR REVIEW OF THE CLINICAL PRESENTATION AND
MANAGEMENT OF PRESEPTAL AND ORBITAL CELLULITIS IN IN-PATIENTS
AT KENYATTA NATIONAL HOSPITAL.**

DR. KAGENDO KAHUNYO

H58/81172/2015

**DEPARTMENT OF OPHTHALMOLOGY
UNIVERSITY OF NAIROBI**

**A DISSERTATION SUBMITTED IN PARTIAL FULFILMENT FOR THE AWARD
OF DEGREE OF MASTER OF MEDICINE IN OPHTHALMOLOGY**

DECLARATION

I declare that this dissertation is my original work and has not been presented for the award of a degree in any other university.

PRINCIPAL INVESTIGATOR:

Dr. Kagendo Kahunyo

MBChB(UoN).

Signed: _____ Date: _____

SUPERVISORS

Dr. Margaret W Njuguna

Senior Lecturer, Department of Ophthalmology, University of Nairobi.

MBChB(UoN), MMed(Ophth), FEACO, Paediatric Ophthalmologist.

Signed: _____ Date: _____

Dr. Muindi Nyenze

Lecturer, Department of Ophthalmology, University of Nairobi.

MBChB(Moi), MMed(Ophth), FEACO, Oculoplastics.

Signed: _____ Date: _____

ACKNOWLEDGEMENT

I would like to appreciate my supervisors Dr. M. Njuguna and Dr. E. Nyenze for their patience and valuable input while guiding me through this work.

Special thanks to my friend and colleague Dr. Judy K. for nudging me forward when it was needed, and last but not least my family for their support through the journey of postgraduate training.

LIST OF ABBREVIATIONS

1. CT scan	-	Computerized tomography scan
2. CNS	-	Central nervous system
3. CST	-	Cavernous sinus thrombosis
4. FESS	-	Functional endoscopic sinus surgery
5. KNH	-	Kenyatta National Hospital
6. MRI	-	Magnetic resonance imaging
7. OC	-	Orbital cellulitis
8. PC	-	Preseptal cellulitis
9. RAPD	-	Relative afferent pupillary defect
10. SPA	-	Subperiosteal abscess
11. URTI	-	Upper respiratory tract infection
12. VA	-	Visual acuity

TABLE OF CONTENTS

DECLARATION.....	ii
LIST OF ABBREVIATIONS	iv
LIST OF FIGURES	vii
LIST OF TABLES	viii
ABSTRACT.....	ix
CHAPTER 1. INTRODUCTION AND LITERAURE REVIEW.....	10
1.1 INTRODUCTION.....	10
1.1.1 Preseptal cellulitis	10
1.1.2 Orbital cellulitis	10
1.2 LITERATURE REVIEW	11
1.2.1 Epidemiology.....	11
1.2.2 Predisposing factors.....	11
1.2.3 Presentation.....	12
1.2.4 Complications.....	14
1.2.5 Investigations.....	15
1.2.6 Management.....	17
CHAPTER 2: JUSTIFICATION	19
2.1 Study rationale	19
2.2 Research question	19
2.3 Objectives	19
2.3.1 Broad Objective	19
2.3.2 Specific Objectives	19
CHAPTER 3: MATERIALS AND METHODOLOGY.....	20
3.1 Study design.....	20
3.2 Study setting.....	20

3.3	Study Population.....	20
3.4	Inclusion criteria	20
3.5	Exclusion criteria	20
3.6	Sample Size.....	20
3.7	Data collection procedure.....	22
3.8	Data management and analysis	22
3.9	Ethical Considerations	22
	CHAPTER 4: RESULTS	24
4.1	Patients’ demographic characteristics	25
4.2	Presenting signs and symptoms	27
4.3	Known Predisposing Factors	28
4.4	Investigation findings:	28
4.5	Treatment	30
4.6	Outcome of treatment	32
	CHAPTER 5: DISCUSSION	33
5.1	Limitations	37
5.2	Conclusions.....	37
5.3	Recommendations.....	37
	REFERENCES.....	38
	APPENDICES.....	43
	Appendix 1: Study tool	43
	Appendix 2: ICD-10 CM Codes	47
	Appendix 3: Budget	48
	Appendix 4. KNH- UoN Ethics and Research Committee Approval.....	49

LIST OF FIGURES

Figure 1. Distribution by sex of 67 patients with preseptal and orbital cellulitis.	25
Figure 2. Distribution by age of patients with preseptal and orbital cellulitis.	26

LIST OF TABLES

Table 1. Distribution of patients by Chandler’s staging	26
Table 2. Presenting signs and symptoms in 67 patients with preseptal and orbital cellulitis..	27
Table 3. Presenting signs in patients with preseptal and orbital cellulitis	27
Table 4. Known predisposing factors found in patients with preseptal and orbital cellulitis.	28
Table 5. Duration of pre-admission treatment	28
Table 6. Full haemogram results in patients with preseptal and orbital cellulitis.....	28
Table 7. Microbiology findings in patients with preseptal and orbital cellulitis.	29
Table 8. CT scan findings in preseptal and orbital cellulitis.....	29
Table 9. Sinus involvement and subperiosteal abscess location.....	30
Table 10. Empiric treatment prescribed at admission in 67 patients.	30
Table 11. Surgical procedures performed in patients with preseptal and orbital cellulitis.....	31
Table 12. Duration of treatment at KNH in days.....	31
Table 13. Visual acuity in 47 patients with orbital cellulitis	32
Table 14. Complications of preseptal and orbital cellulitis.	32

ABSTRACT

Background: Preseptal cellulitis is a common eye condition especially in children and generally responds well to treatment. Orbital cellulitis is a more severe infection and has the potential risk of loss of sight and life. Prompt identification and treatment is necessary to minimize complications. The aim of the study is to assess local presenting features and outcomes of treatment, in order to improve care for these patients and optimize their outcomes.

Study Objectives: To determine the demographic and clinical characteristics, treatment and outcomes of in-patients with preseptal and orbital cellulitis at Kenyatta national hospital from 1st January 2013- 31st December 2017.

Methodology: Medical records of all patients admitted with a diagnosis of preseptal cellulitis, orbital cellulitis or lid abscess between 1st January 2013 and 31st December 2017 were retrospectively reviewed. Data collected was filled into a predesigned tool and analyzed using descriptive statistics.

Results: Out of records of 67 patients, 20 had preseptal and 47 had orbital cellulitis. The male: female ratio was 7:3 in preseptal, and 2.1:1 in orbital cellulitis. Eighty percent of preseptal cellulitis patients were below 9 years while 45% of orbital cellulitis patients were in their second decade. Sinusitis was the commonest predisposing factor for orbital cellulitis, while upper respiratory tract infections were more common in preseptal cellulitis. Leucocytosis was found in 33% versus 44% of patients with preseptal and orbital cellulitis respectively. Microbiological yield was low as 58% cultured no growth. Overall, 54% required surgical intervention in addition to medical treatment due to abscess formation. Though vision improved for many, blindness (vision <3/60) was found in 11%.

Conclusion: Preseptal and orbital cellulitis mostly affect children. Sinusitis being a common predisposing factor for both should be treated adequately to prevent complications. More microbiological investigations are required in these patients to better identify the local aetiological factors. Complications are not uncommon and include abscess formation, which often requires surgery. Patients with orbital cellulitis are at risk of visual loss and prompt treatment is required to avoid this.

CHAPTER 1. INTRODUCTION AND LITERATURE REVIEW

1.1 INTRODUCTION

1.1.1 Preseptal cellulitis

Inflammation or infection involving the tissues anterior to the orbital septum is referred to as preseptal cellulitis. This includes the eyelid skin, subcutaneous tissue and orbicularis muscle. Tissues in the preseptal area are loosely attached creating potential spaces for fluid accumulation. Infections can arise from spread from adjacent areas of the face including sinuses or directly on the eyelid skin.(1) The presenting features of preseptal cellulitis include swelling, erythema, warmth and tenderness of the eyelid. Discharge from the conjunctiva may be present, but the eye itself is not involved.(2) Treatment is usually with oral antibiotics and response is good, but it rarely spreads to the orbit. Complications include abscess formation on the eyelids or periorbital region, and progression to orbital cellulitis. Incision and drainage is necessary when the infection becomes suppurative.(3)

1.1.2 Orbital cellulitis

Orbital cellulitis refers to soft tissue infection in the orbit, posterior to the orbital septum. It can result in visual impairment and even loss of life if untreated, therefore appropriate and prompt treatment should be instituted in order to minimize complications.(4) It commonly presents with pain, proptosis and limitation of extraocular motility. In addition, patients may report reduced vision, periocular swelling and fever. (5) Common complications include formation of eyelid and/or subperiosteal and orbital abscesses which require surgical drainage in most cases.(3) Infection may spread through the venous drainage system into the brain and cavernous sinus. These are serious complications and are considered life threatening. Treatment is by use of antibiotics and surgical intervention is required in many cases. Preseptal and orbital cellulitis present part of a continuum that may result in more severe complications as described by Chandler et al(6) as follows:

Stage I: Preseptal cellulitis; this condition is not regarded as true orbital cellulitis. It rarely extends to become true postseptal orbital cellulitis.

Stage II: Orbital cellulitis - Also known as postseptal cellulitis or true orbital cellulitis refers to orbital inflammation without suppuration.

Stage III: Subperiosteal abscess- Pus collects between the periorbita and orbital wall. The periorbita has a protective role in that it bars infection from spreading into the orbital cavity per se.

Stage IV: Orbital abscess- may result from purulent collection in association with orbital cellulitis or rupture of subperiosteal abscess.

Stage V: Cavernous sinus thrombosis- this is whereby infection spreads to the cavernous sinus usually through venous channels. It is signified by the patient becoming septic, involvement of the 3rd, 4th, 6th cranial nerves bilaterally, signs of meningism, and altered state of consciousness. It carries a high risk of mortality.

With advancing stage comes the risk of long-term complications such as blindness and death, hence orbital cellulitis is a medical emergency and requires in-patient management.

1.2 LITERATURE REVIEW

1.2.1 Epidemiology

Orbital cellulitis (OC) can affect both adults and children but occurs more in children and adolescents, most often as a complication of sinusitis. A previous study done in KNH found that orbital cellulitis was most common in children below 10 years(43%)(7). In one study done in South Africa, the mean age of 59 in patients with OC was 13 years (8), while another in Nigeria by Nwaorgu *et al*(9) found that 84% of inpatients reviewed were below the age of twenty. This has been attributed to the immature immune systems in children, who develop colds and sinusitis more frequently than adults.(10) Orbital cellulitis occurs less frequently than preseptal cellulitis. In Taiwan (5) and the United States(3) two hospital based studies found the rates of occurrence of orbital cellulitis was 71% and 29% respectively.

Many studies have found that the left side was more often involved than the right, although the reason behind it is not known(11) and that it occurred more in males than females at ratios ranging from 2:1 upto 7:1(8,9). Majority of cases are unilateral although rarely, bilateral involvement has been described. Liu *et al* in Vietnam found 2/67 patients with preseptal cellulitis had bilateral disease while there were none with bilateral infection among those with orbital cellulitis(5). Prior to the age of antibiotic use, the rate of complications arising from sinusitis were fairly high. Morbidity of about 20% and mortality of 17% have been reported in previous studies(12). Since the introduction of antimicrobials and the advent of more advanced surgical methods, morbidity and mortality rates have reduced markedly to 3–11% and 0–2.5%, respectively(13,14).

1.2.2 Predisposing factors

Orbital and preseptal cellulitis have similar underlying causes. The commonest underlying factor in preseptal and orbital cellulitis in children is sinusitis, with Ferguson and McNab in

Australia reporting it as the main predisposing factor in 91% of orbital cellulitis patients(15). They found that ethmoid and maxillary sinusitis was a common finding in children. It was also not unusual to find that they had had an upper respiratory infection shortly before presenting. Less common causes of preseptal cellulitis include trauma to the eyelid, insect bite, blepharitis or chalazion(15,16).

In adults, the leading cause of preseptal cellulitis was found to be dacryocystitis by Chaudhry et al who studied in-patients with PC in Riyadh, Saudi Arabia, followed by sinusitis and penetrating cutaneous trauma.(16) Orbital cellulitis from sinusitis usually involves mixed sinus pathology, in contrast to children where usually one sinus is involved(17). Infections of dental origin can result in sinusitis and orbital infections which may not respond to medical treatment alone due to the virulence of the organisms(18,19). Orbital fractures and any ocular or orbital surgery can also predispose one to orbital cellulitis. Examples include squint surgery(20) and scleral buckle insertion(21), though this rarely happens.

Endogenous causes of orbital cellulitis include bacterial endocarditis which can predispose to (1)orbital cellulitis and septic emboli in the brain(19,22). Endophthalmitis/ panophthalmitis also rarely can lead to orbital cellulitis(23).

Immunosuppressive states such as in corticosteroid use, substance abuse, myelodysplastic syndromes and diabetes mellitus have been found to predispose one to fungal orbital cellulitis. Mucormycosis is the commonest fungal infection encountered under these conditions. The other common fungal infection is aspergillosis, which does not have classic underlying associations(15,24).

1.2.3 Presentation

1.2.3.1 Preseptal cellulitis

Preseptal cellulitis presents with inflammation and swelling of the eyelids, with or without tenderness, and oedema of the contralateral eyelids may appear. Patients present with pain, tearing and blurred vision. Where there is a history of trauma, a foreign body might be present so it must be considered and investigated. There may be sinus tenderness, rhinorrhoea, cervical, submandibular or preauricular lymphadenopathy and other signs that suggest upper respiratory tract infection(16,25). In preseptal cellulitis, ocular motility is not limited and proptosis and pain on eye movement are absent which helps to differentiate it from orbital cellulitis(1). In addition, chemosis may be present although it is commoner in

orbital cellulitis(3,5). One author classified preseptal cellulitis with chemosis as a separate entity, intermediate in severity between preseptal and orbital cellulitis(11). In the paediatric group, fever and leucocytosis feature prominently.

1.2.3.2 Orbital cellulitis

The features that most define orbital cellulitis are proptosis and/or limited ocular motility.(5) Various series in the USA, Australia, Taiwan report their presence in about 71-100% of cases(5,15,26). Other features include orbital pain, chemosis and reduced vision. Patients may also have a history of headache, fever, malaise, upper respiratory tract infection, toothache/ dental carries or trauma to the face or orbit itself.

When the optic nerve is affected this presents as reduced vision and abnormal pupillary reactions (relative afferent pupillary defect). The signs include disc oedema or neuritis which could progress to optic atrophy and hence blindness. Optic atrophy is determined by factors such as mechanical pressure on the nerve and compression of the blood vessels that supply it(27). Also, orbital cellulitis may spread directly to the optic nerve. Additionally, infarction of the sclera, choroid, and the retina may occur. Spread to the globe may also occur leading to an infectious uveitis or a panophthalmitis(28).

The prevalence of subperiosteal and orbital abscess occurring as a complication of orbital cellulitis varies widely. While Nwaorgu et al in Nigeria reported (4/31)13%, Elshafei et al in Egypt reported 15.6% while a series in Saudi Arabia by Elsharidi et al reported a higher rate of 53%(9,29–31). Most series have found that the location of subperiosteal abscess is usually medial. This has been attributed to the close proximity with the ethmoid sinus with its thin bony wall and looser attachment of the periorbita anteriorly than posteriorly(30). However, one series in upper Egypt found superior subperiosteal abscess was more common(29).

Intracranial complications may arise and lead to involvement of the other eye. Signs such as periorbital swelling and ophthalmoplegia of the other eye may occur in cavernous sinus thrombosis (CST). Other signs include fever, ptosis, dilated pupils (if parasympathetic nerves are involved), headache and disc oedema. A patient with cavernous sinus thrombosis is a very sick patient and the risk of death is high. Before antimicrobial agents were available, mortality from CST was almost 100%. Since their introduction though, this has notably reduced to approximately 20% to 30%(32).

Other intracranial complications include meningitis, encephalitis, subdural empyema, epidural empyema, intracerebral abscess. The presenting features include reduced

consciousness, headache, vomiting, convulsions and neck stiffness(33). Many of these will need neurosurgical intervention for the drainage of brain abscess. Preseptal and orbital cellulitis are usually more severe and more rapidly progressive in children than in adults(34).

1.2.4 Complications.

Acute complications of preseptal cellulitis include fever, progression to orbital cellulitis, lid abscess formation, transient decrease in vision due to drooping of the eyelid in the affected eye(5,9). Infection may even spread to cause meningitis as reported in one 10 month old child(2).

Similarly, orbital cellulitis can complicate with lid abscess, meningitis, brain abscess and even cavernous sinus thrombosis(9). Patients may have loss of vision due to exposure keratopathy or optic nerve involvement and this may be transient or permanent depending on severity. Diplopia may arise due to dystopia which causes difficulty in fusion of images as the image falls on a non-foveal location in the displaced eye(31). Furthermore, the ptosis and proptosis often present are cosmetically disfiguring, though they often resolve with treatment.

The incidence of major complications (CST, empyema) from ethmoid and frontal sinusitis is low. However, when they arise they are associated with considerable long-term sequelae. Before the antibiotic age, mortality in orbital cellulitis due to meningitis was reported in about 17%. Similarly, blindness was reported in about 20% of cases(35). More recent studies show that of patients who present with reduced vision, visual outcomes range from no permanent visual impairment reported in some series(5,15) to varying degrees of vision loss from various causes. Some of these causes include corneal scarring, optic atrophy and phthisis bulbi. Patients may end up requiring further surgeries such as evisceration or enucleation, to remove the focus of infection for example in endophthalmitis and panophthalmitis.(36) Blindness has been reported in about 0-5% of cases(13,31). Reports of death secondary to orbital cellulitis are rare, although the mortality rate may be as high as about 80% in fungal infections in immunocompromised individuals(37).

Recurrence is another possible complication seen in both preseptal and orbital cellulitis. Liu et al reported four cases with preseptal and one with OC had recurrence, although all had good recovery(5).

Other long-term complications include ptosis, ophthalmoplegia(3), diplopia(3,38), strabismus(31), and corneal opacification from exposure keratopathy(9).

1.2.5 Investigations

1.2.5.1 Imaging

Imaging is particularly useful in orbital cellulitis. Computerized tomography (CT) scan is used to aid diagnosis in terms of localising of orbital and intracranial abscesses and evaluating the sinuses. Majority of CT scans reveal significant sinus disease noted by opacification of the sinuses or an air fluid level(39). Since there may be isolated medial, superior or inferior abscess, both axial and coronal views are recommended(30). Post contrast studies are preferred due to enhanced delineation of phlegm, and they allow evaluation of the superior ophthalmic vein and cavernous sinus(30).

When orbital cellulitis is diagnosed clinically, immediate radiographic imaging should be performed to confirm involvement of the orbit, assess for the presence of an abscess or foreign body, determine the degree of orbital involvement, and evaluate for potential sources of infection. This is especially true in cases where the examination is limited (young children, significant periorbital oedema), there is concern for CNS involvement, gross proptosis and ophthalmoplegia are present, there is no improvement or concern for progression despite appropriate treatment, and surgical intervention is being considered(4).

X-rays of the paranasal sinuses have been used in orbital cellulitis to rule out associated sinusitis in resource limited settings such as Nigeria(14) and the Philippines(40). It is however recommended that more sophisticated technology be used where possible due to the limited information obtainable from radiographs.

Orbital ultrasound has also been used where complications arising from orbital cellulitis are suspected. Schramm et al(11) and Spires et al(41) found ultrasound to be generally sensitive in detecting orbital abscesses and foreign bodies, but less sensitive than CT scan in detecting pathology at the orbital apex and posterolateral site.

Where full blood count has been done, only up to about 50% have yielded a raised leucocyte count so the test may not be very sensitive(39,42). However, one series in Taiwan found 68.7% of cases had a raised white cell count(43). Leucocytosis is more often a finding in orbital than in preseptal cellulitis(44) and is a commoner finding in children than in adults(15). Similarly, C-reactive protein was found to be elevated more in orbital than preseptal cellulitis(5).

Magnetic resonance imaging (MRI) of the orbits provides better soft tissue resolution compared to ultrasound and CT, while limiting exposure to radiation. It is valuable in detecting non-metallic foreign body and suspected intracranial involvement(31). However, the disadvantages of MRI include the longer scanning time compared to standard CT, which may require sedation and consultation with paediatric anesthesia. In addition, MRI services may not always be readily accessible.

To determine the causative organisms involved, microbiologic investigations are carried out. The investigations usually done are blood cultures and culture of specimens taken from various sites. The highest yields are obtained from pus swabs and swabs of infected sinuses(5,16,39,45,46). Blood cultures however generally have a low yield, with results ranging from no yield to about 50%(5,8,15). This has been attributed to the fact that most patients are already on antibiotics by the time these samples are taken and perhaps problems in the techniques used in sample collection and culturing.

1.2.5.2 Microbiologic findings

The most common organism obtained from cultures is *Staphylococcus aureus*. *Staphylococcus saprophyticus*, *Pseudomonas aeruginosa*, *Haemophilus influenzae* are also relatively common causes of both preseptal and orbital cellulitis(5,7).

In children, *Streptococcus* species (mostly alpha haemolytic *Streptococci*) has been the most frequent organism identified in many series(15,26). Since the introduction of the *Haemophilus influenzae* type b(Hib) vaccine in 1985, the incidence of disease due to this organism is noted to have reduced drastically at least in developed countries where there are high vaccination rates(47). In contrast to this, one prospective study in Scotland over a one-year period found *H. influenzae* was the second most frequent pathogen identified (46%) after *Streptococcus* (66%) in orbital cellulitis. However, neither the strains were known nor the immunization status of the children(45). Anaerobes including *Peptostreptococcus*, *Fusobacterium* and *Bacteroides* are also frequently isolated(41).

In adults, *Staphylococcus* and *Streptococcus* species have been identified as the most common causative organisms in both preseptal and orbital cellulitis(39). In addition, mixed organisms are also common across all age groups.

1.2.6 Management

1.2.6.1 Medical treatment

All cases of preseptal and orbital cellulitis are treated with antibiotics but some also require surgery. Various regimens have been used, including second or third generation cephalosporins, amoxicillin/clavulanate, flucloxacillin, metronidazole etc in varying combinations(14,39). Treatment regimens are typically based on empiric coverage of the common causative organisms, as no randomized, controlled studies have investigated the ideal antibiotic combination for preseptal and orbital cellulitis. Antibiotic selection may later be modified based on culture and sensitivity results. Local patterns in antimicrobial susceptibility should be considered, as flora and their resistance profiles varies between regions. In developing countries, other reasons may determine treatment given. For instance in one series in South Africa, the choice of drugs was determined by availability at that hospital(8).

For preseptal cellulitis oral medication is usually sufficient and patients are treated as outpatients. Indications for admission include age less than one year, systemic adverse effects, lack of response to oral antibiotics and lid abscess(5,36). A diagnosis of orbital cellulitis on the other hand requires urgent admission and prompt appropriate management.

The treatment of mucormycosis consists of intravenous and local amphotericin B, improving their underlying states such as metabolic acidosis and immunosuppression, and debridement of necrotic tissues. The treatment of aspergillosis is similar except usually there is no underlying illness. Lubricants are necessary for those with signs of exposure keratopathy in order to preserve the cornea.

1.2.6.2 Surgical treatment

Orbital cellulitis is generally treated with intravenous antibiotics, but some will require surgical intervention. Historically, the presence of subperiosteal and/or orbital abscess was considered an indication for urgent drainage in most instances(29). There is usually a dramatic improvement in response after drainage. However, Garcia and Harris have shown that in certain circumstances, such as medial, small, subperiosteal abscess can be treated successfully with antibiotics alone in patients less than 9 years(48).

Canthotomy and cantholysis should be performed as an emergency if orbital compartment syndrome is suspected. It may lower intraocular pressure, but drainage of subperiosteal/orbital abscess is definitive in order to decompress the optic nerve.

Patients with orbital cellulitis due to underlying sinusitis will require a multidisciplinary team approach. Some of the sinus surgeries performed by otorhinolaryngologists include external ethmoidectomy, frontal sinusotomy and antral lavage depending on the sinus responsible for the orbital infection. More recently, functional endoscopic sinus surgery (FESS) has been used in extracranial complications of acute sinusitis, and its advantages include high success rates, low morbidity and no facial distortion or scars(8). El-Silimy used nasal endoscopy successfully to drain both the affected sinus and also the adjoining subperiosteal abscess in 16 patients(49). Neurosurgeons are consulted in cases of intracranial suppurative complications as they often require drainage.

In addition, patients may require other surgeries due to the other conditions associated with orbital cellulitis. For instance where there is brain abscess, endophthalmitis, pan-ophthalmitis, ruptured globe, nasolacrimal duct obstruction and fungal infection, patients may also undergo craniotomy, evisceration, enucleation, exenteration or dacryocystorhinostomy.

CHAPTER 2: JUSTIFICATION

2.1 Study rationale

Preseptal and orbital cellulitis are conditions that need prompt assessment and management in order to avoid complications. A multidisciplinary team approach is usually necessary in treatment of orbital cellulitis.

Although studies done elsewhere have shown an improvement in outcomes in the last few decades, few such studies have been done in Africa. It is therefore important to do an audit and see whether the same is being replicated in developing countries, and in order to suggest how to improve outcomes. The results of this study will also illustrate any changing trends in orbital disease in KNH in recent years.

2.2 Research question

What are the clinical characteristics, treatment given and outcomes of in-patients treated for preseptal and orbital cellulitis at Kenyatta National Hospital?

2.3 Objectives

2.3.1 Broad Objective

To describe the clinical characteristics, treatment and outcomes of in-patients treated for preseptal and orbital cellulitis between January 2013- December 2017 at Kenyatta national hospital.

2.3.2 Specific Objectives

1. To determine the demographics and presenting signs and symptoms in the patients.
2. To determine the known predisposing factors in these patients.
3. To determine the investigations and treatment offered to these patients.
4. To determine the outcome of treatment among these patients.

CHAPTER 3: MATERIALS AND METHODOLOGY

3.1 Study design

This was a retrospective case series.

3.2 Study setting

The study was conducted at the Kenyatta national hospital, Nairobi, Kenya. This is a tertiary level hospital and a referral centre. It is also a university teaching hospital which includes an eye unit among other specialties. Patients are referred from many parts of the country for specialized services.

3.3 Study Population

All patients who were admitted with a diagnosis of preseptal and orbital cellulitis at Kenyatta national hospital between 1st January 2013- 30th December 2017.

3.4 Inclusion criteria

A patient diagnosed with preseptal cellulitis, lid abscess, orbital cellulitis, orbital abscess within the study period.

3.5 Exclusion criteria

1. Patients who were diagnosed with preseptal or orbital cellulitis but found to be having non-infectious causes of periorbital/ orbital inflammation such as neoplastic lesions, non-specific orbital inflammation, et cetera.
2. Missing patient records.

3.6 Sample Size

The following sample size determination formula for finite population correction (Wanga & Lemeshow, 1991) was used to estimate the proportion of population study size.

$$n^1 = \frac{NZ^2P(1 - P)}{d^2(N - 1) + Z^2P(1 - P)}$$

Where

n' = sample size with finite population correction;

N = size of the target population = 21 x 5 years → 105 (according to the registry book, an average of 21 patients are seen per year with a diagnosis of preseptal and orbital cellulitis at KNH. The study period will be 5 years i.e. between 2013 and 2017).

Z = the value that specifies the level of confidence you want in your confidence interval when you analyze your data. Typical levels of confidence for surveys are 95%, in which case z is set to 1.96;

$P = p$ is the estimated proportion of population value = 0.1% (Babar et al., 2009);

d = margin of error = 0.05%

$$n^1 = \frac{105 \times 3.8416 \times 0.000999}{0.00001225 + 3.8416 \times 0.000999}$$

$$n' = 105 \text{ patients}$$

Correcting for finite population is done using the following formula:

$$N = \frac{N \times X}{X + N - 1}$$

Where:

N is population size (number of patients seen with a diagnosis of preseptal and orbital cellulitis at KNH in the last 5 years = 105)

X is previous sample size calculated

$$N = \frac{105 \times 105}{105 + 105 - 1}$$

$$N = 53$$

The minimum sample size required for this study to have adequate power of 80% is calculated using this formula:

$$n' = \frac{n}{1 + \frac{n}{N}}$$

Where:

n is sample size after population correction

N is previous sample size calculated

$$n' = \frac{53}{1 + \frac{53}{105}}$$

$$n' = 35 \text{ Patients}$$

3.7 Data collection procedure

The inpatient numbers of patients who were seen with a diagnosis of preseptal cellulitis, orbital cellulitis, or eyelid abscess were obtained using ICD-10 codes H00.0 and H05.0 (Appendix 2) from the medical records department's electronic directory. This information was then used to retrieve their medical records.

All the information relevant to the study was collected and entered into the pre-designed data collection tool. The data included:

- i. Demographic details: age and sex.
- ii. Clinical Presentation: symptoms and signs reported and elicited respectively, and known predisposing factors.
- iii. Pathogens identified: from blood culture, culture of abscess material.
- iv. Investigations done and results: hematologic and imaging studies.
- v. Treatment: the antibiotics used, and surgical interventions performed
- vi. Outcomes; visual acuity and complications from the illness at discharge and at follow-up visits if any.

3.8 Data management and analysis

The data collected was entered into a Microsoft Excel sheet. Data cleaning was done and descriptive statistics used to analyze the data. We used sums and proportions as the data was categorical. Tables, charts and histograms were then extracted to display the results.

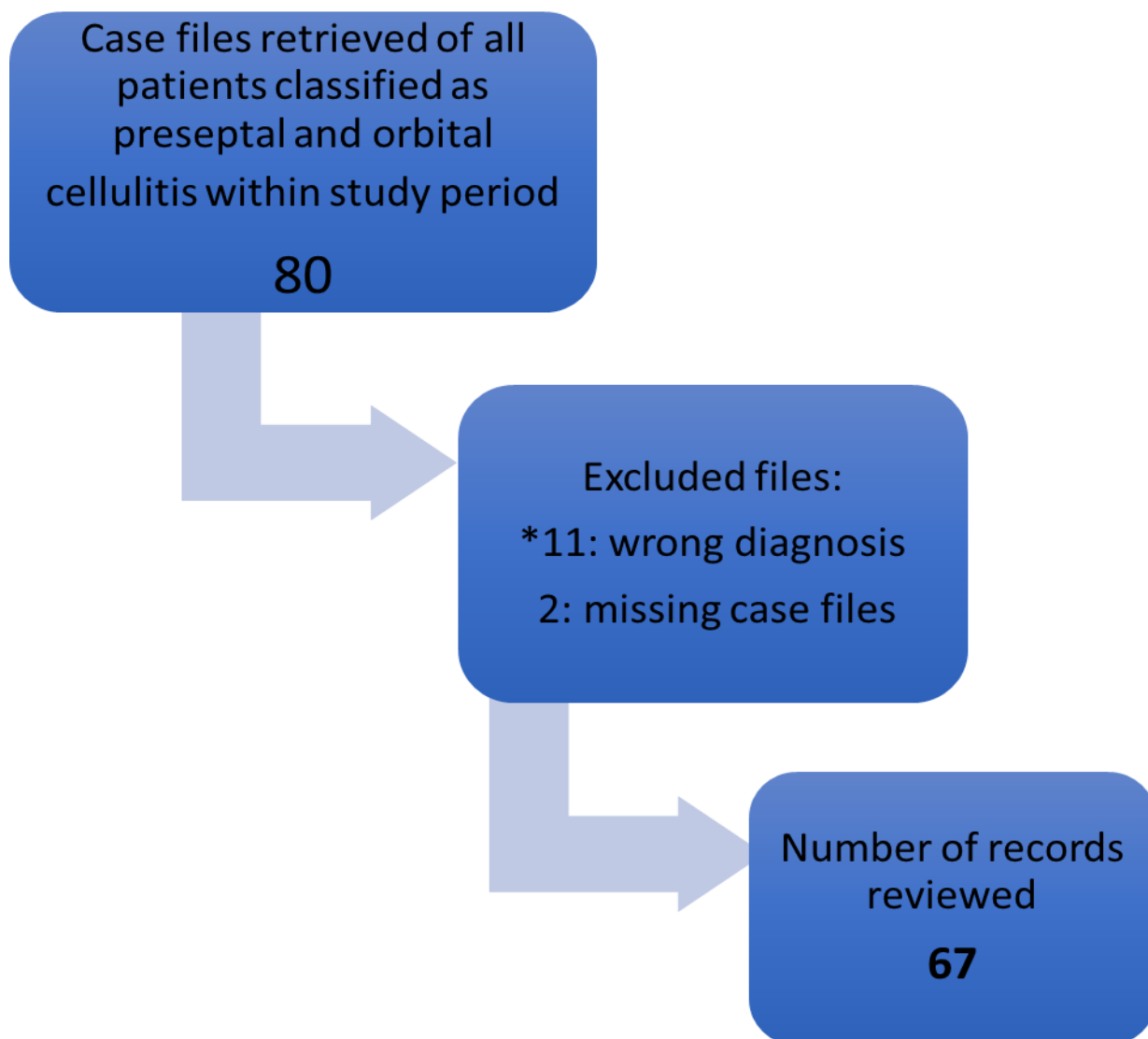
3.9 Ethical Considerations

Ethical approval was given by Kenyatta National Hospital/ University of Nairobi Ethics and Research Committee.

Patient details and identity were kept anonymous throughout with the use of serially coded questionnaires. The information on the questionnaire was accessible to the investigators and statistician.

CHAPTER 4: RESULTS

A total of 67 patients were admitted to Kenyatta national hospital with either preseptal or orbital cellulitis between 1st January 2013 and 31st December 2017.



*Patients had other orbital conditions such as thyroid orbitopathy, orbital pseudotumor, retrobulbar hemorrhage, proptosis due to systemic lupus erythematosus, orbital haemorrhage.

4.1 Patients' demographic characteristics

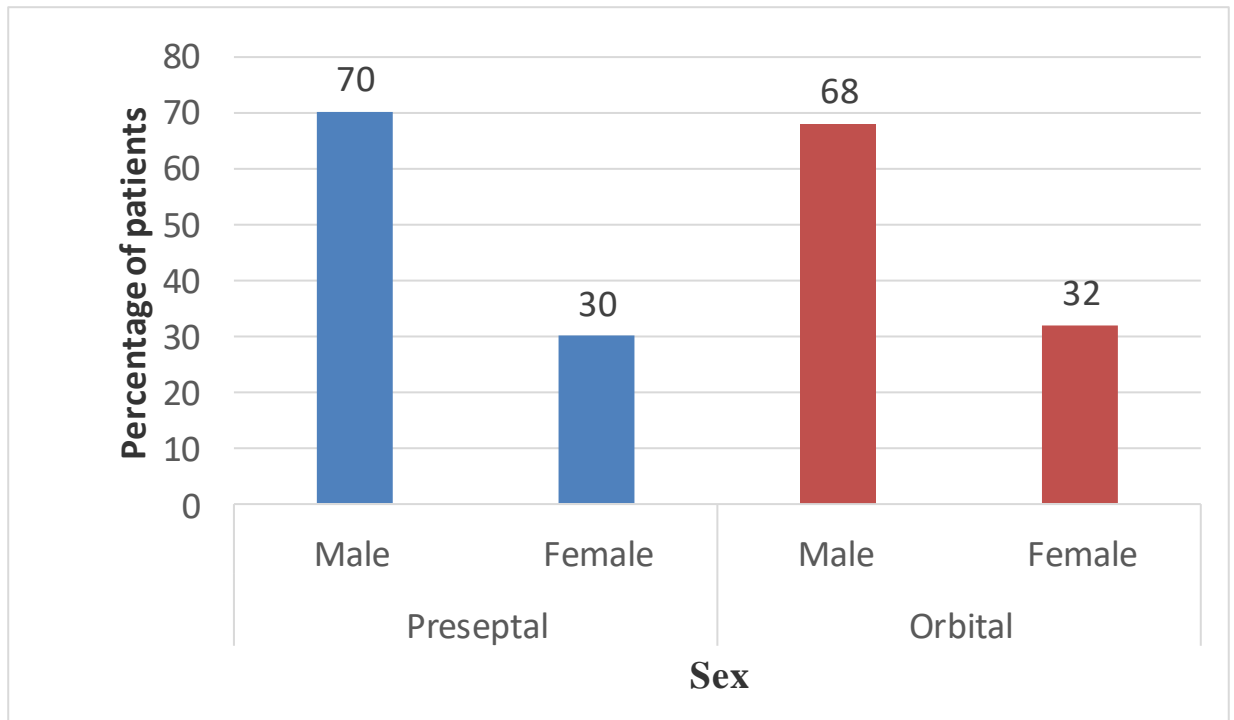


Figure 1. Distribution by sex of 67 patients with preseptal and orbital cellulitis.

There were more males than females in both the preseptal and orbital cellulitis groups.

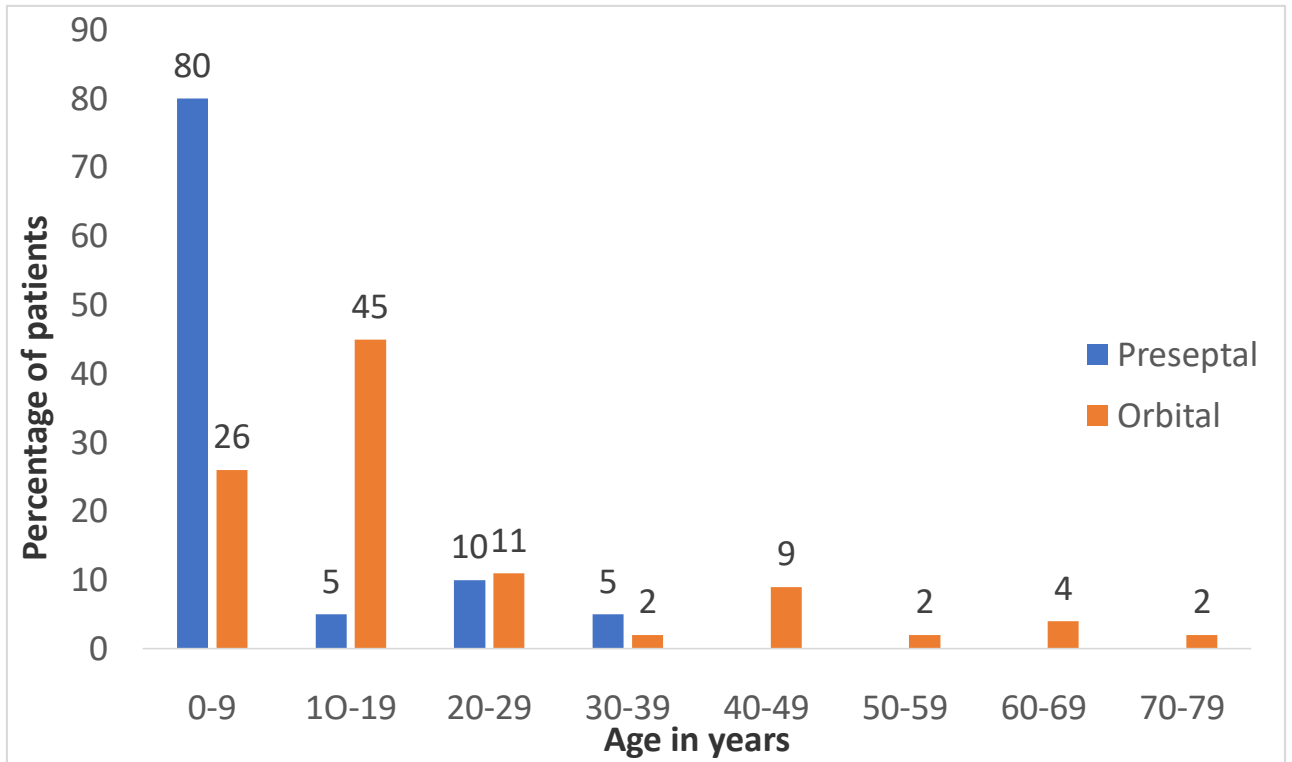


Figure 2. Distribution by age of patients with preseptal and orbital cellulitis.

Most patients with preseptal cellulitis were below 9 years (range 2 months-35years) while 45% of those with orbital cellulitis were between 10-19 years (range 1month-74years).

Table 1. Distribution of patients by Chandler’s staging of orbital cellulitis

	No. of patients (%) n=67
I (Preseptal cellulitis)	20 (30)
II (Orbital cellulitis)	17 (25)
III (Subperiosteal abscess)	17 (25)
IV (Orbital abscess)	4 (6)
V (Cavernous sinus thrombosis*)	9 (13)
Total	67 (100)

*Includes cavernous sinus thrombosis and other intracranial extension

Based on Chandler’s staging, there were more patients admitted with orbital cellulitis and its complications than preseptal cellulitis.

4.2 Presenting signs and symptoms

Table 2. Presenting symptoms in 67 patients with preseptal and orbital cellulitis.

Presenting symptoms	Preseptal n=20* (%)	Orbital n=47*(%)
Eye swelling	20 (100)	45 (96)
Eye pain	11 (55)	34 (72)
Reduced vision	1 (5)	16 (34)
URTI symptoms ¹	6 (30)	8 (17)
Headache	3 (15)	7 (15)
Diplopia	0	5 (11)
Others ²	2 (10)	4 (9)

*Patients presented with more than one symptom

¹URTI symptoms included cough, nasal discharge, nasal blockage

². Others includes irritability in the very young, and two with orbital cellulitis who had convulsions

Eye swelling and pain were the most common presenting symptoms in preseptal and orbital cellulitis.

Table 3. Presenting signs in patients with preseptal and orbital cellulitis

Presenting Sign	Preseptal n=20* (%)	Orbital n=47*(%)
Eyelid oedema/ inflammation	20 (100)	44 (94)
Proptosis	0	44 (94)
Chemosis	4 (20)	40 (85)
Ptosis	17(85)	38 (81)
Limited EOMM	0	30 (64)
Discharge	11 (55)	27 (57)
RAPD	0	18 (38)
Fever	5 (25)	13 (28)

*Patients had more than one presenting sign

Eyelid oedema/inflammation was the commonest presenting sign in both groups, and proptosis was a key feature in orbital cellulitis. Only a minority of patients had fever at admission.

4.3 Known Predisposing Factors

Table 4. Known predisposing factors found in patients with preseptal and orbital cellulitis.

	Preseptal n=20(%)	Orbital n=47(%)
Sinusitis	4 (20)	29 (62)
URTI ¹	6 (30)	1 (2)
Trauma	5 (25)	9 (19)
Dental infection	1 (5)	7 (15)
Skin infection	3 (15)	1 (2)
Nasolacrimal duct obstruction	1 (5)	0
Total	20 (100)	47 (100)

¹Includes cough, nasal discharge, nasal blockage, adenoid and adeno-tonsillar hypertrophy.

Upper respiratory tract infection was the commonest predisposing factor in preseptal cellulitis, while sinusitis was commoner in orbital cellulitis.

Table 5. Duration of pre-admission treatment

	Preseptal n=11	Orbital n=39
Mean	4.5 +/- 1.9	4.1 +/- 2.1
Range	2-7	1-9

In the preseptal group, 11/20 (55%) versus 39/47 (83%) of those with orbital cellulitis had been on treatment prior to admission, for about 4 days on average.

4.4 Investigation findings:

(i) Full haemogram

Full hemogram results were available for 59/67(88.0%) overall, 90% of the preseptal group and 89% of the orbital cellulitis group.

Table 6. Full haemogram results in patients with preseptal and orbital cellulitis.

	Preseptal n=18(%)	Orbital n=41(%)
Leucocytosis (>11.0 x 10 ⁹ /L)	6 (33)	18 (45)
No leucocytosis	12 (67)	23 (55)
Total	18 (100)	41 (100)

Out of those who had full haemogram done, leucocytosis was identified in less than half of the patients, and was more common in orbital cellulitis.

(ii) Microbiology

Samples were taken for microscopy, culture and sensitivity in 19/67 (28 %) of patients.

Table 7. Microbiology findings in patients with preseptal and orbital cellulitis.

Organism grown	No. of samples (%)	Sensitivity
No growth obtained	11 (58)	
Growth obtained	4 (21)	
Preseptal:	<i>Klebsiella spp.</i>	Moxifloxacin, levofloxacin
	<i>Proteus spp.</i>	Gentamicin, ceftriaxone, levofloxacin, ceftazidime
	<i>Streptococcus pyogenes</i>	Ampicillin, doxycycline, ceftazidime, imipenem, cefepime
Orbital:	<i>Staphylococcus aureus</i>	Gentamicin, tobramycin, erythromycin, clarithromycin, linezolid, vancomycin
	<i>Escherichia coli</i>	Ampicillin, amoxicillin-clavulanate, cefepime, cefuroxime
No results filed	4 (21)	
Total	19 (100)	

Majority (58%) did not grow any organisms on culture, a low positive culture rate. All samples were from abscess material obtained during surgery.

(iii) Imaging

Table 8. CT scan findings in preseptal and orbital cellulitis

	Preseptal n=8*(%)	Orbital n=39*(%)
Sinusitis	4 (50)	29 (74)
Orbital abscess	0	17 (44)
Brain abscess	0	8 (21)

Periorbital edema	5 (63)	4 (10)
Orbital fractures	0	2 (5)
Intraorbital foreign body	0	1 (3)

*Patients often had more than one finding.

CT scan was done in 47/67 (39%) of patients; 40% with preseptal and 83% with orbital cellulitis. Sinusitis was the most common finding reported on imaging.

Table 9. Sinus involvement and subperiosteal abscess location.

	Preseptal n=4	Orbital n=29
Sinus involved		
Ethmoid +maxillary	3	19
Ethmoid +maxillary +sphenoid	1	2
Ethmoid +maxillary +frontal	0	5
Maxillary	0	1
Ethmoid	0	1
Ethmoid + frontal	0	1
Subperiosteal abscess location n=17*		
Nasal		15 (88)
Superior		5 (29)
Lateral		3 (18)
Inferior		1 (6)

*most had abscess spanning more than one location

Ethmoid and maxillary sinusitis were the most commonly involved sinuses. Subperiosteal abscess was present in 17/47 (36%) of patients with orbital cellulitis, and most were found nasally.

4.5 Treatment

Table 10. Empiric treatment prescribed at admission in 67 patients.

	Preseptal n=20(%)	Orbital n=47(%)
Single drug		
Amoxicillin-clavulanate	6 (30)	3 (6)
Ceftriaxone	5 (25)	3 (6)
Cefuroxime	0	5 (11)

Multiple drugs		
Cefuroxime + metronidazole	3 (15)	19 (40)
Ceftriaxone + metronidazole	5 (25)	12 (26)
Amoxicillin-clavulanate + metronidazole	1 (5)	3 (6)
Ceftriaxone + metronidazole + vancomycin	0	2 (4)

Most patients with orbital cellulitis (77%) were put on combination therapy at admission, with either a 2nd or 3rd generation cephalosporin together with metronidazole. More than half (55%) of those with preseptal cellulitis were started on single drug at admission.

Table 11. Surgical procedures performed in patients with preseptal and orbital cellulitis

Procedure	Preseptal n=20*(%)	Orbital n=47*(%)
None	10 (50)	17 (36)
Lid abscess drainage	10 (50)	15 (32)
Drainage of subperiosteal/ orbital abscess	0	17 (36)
Functional endoscopic sinus surgery	0	15 (32)
Craniotomy	0	5 (11)
Others ¹	0	1 (2)

*Most patients had more than one procedure done

¹Open reduction and internal fixation of facial fractures

Surgical intervention was necessary in 40/67(60%) of patients. Lid abscess drainage was done in half the preseptal group while it was second to drainage of orbital/subperiosteal abscess in those with orbital cellulitis.

Table 12. Duration of treatment at KNH

	Number of days	
	Preseptal n=20	Orbital n=47
Mean +/- SD	7.0 +/- 3.2	11.7 +/- 4.9
Range	3-14	4-28

On average, patients with preseptal cellulitis were treated for one week with parenteral treatment while those with orbital cellulitis were treated for 11 days.

4.6 Outcome of treatment

Table 13. Visual acuity in 47 patients with orbital cellulitis

	Presenting VA n (%)	VA at discharge n (%)
6/6- 6/18 Normal vision	12 (26)	25 (53)
<6/18- 6/60 Mild visual impairment	5 (11)	1 (2)
<6/60- 3/60 Moderate visual impairment	5 (11)	0
<3/60 Blind	9 (19)	5 (11)
Fixing and following objects/light	6 (13)	8 (17)
Vision not recorded	10 (21)	8 (17)
Total	47 (100)	47 (100)

About half of patients (53%) had normal vision at discharge, while 11% went blind from orbital cellulitis.

In the preseptal cellulitis group, 4/20 (25%) had normal vision at presentation at discharge. In 10/20 (50%) vision was recorded as fixing and following objects/light and for the remaining 6/20 (30%), vision was not recorded.

Table 14. Complications of preseptal and orbital cellulitis.

	Preseptal n=20 (%)	Orbital n=47*(%)
No complications	10 (50)	19 (40)
Lid abscess	10 (50)	16 (34)
Orbital/ subperiosteal abscess	0	21 (45)
Meningitis	0	1 (0)
Brain abscess	0	8 (17)
Exposure keratopathy	0	3 (6)
Strabismus	0	3 (6)
Recurrence of orbital cellulitis	0	1 (0)

*Some patients had more than one complication

Preseptal cellulitis was complicated by lid abscess in half the patients. About 28/47 (60%) patients with orbital cellulitis had complications, with suppuration being the most common. There were no deaths reported within the study period.

CHAPTER 5: DISCUSSION

We reviewed the medical records of 67 patients (20 preseptal cellulitis and 47 orbital cellulitis). Overall there were more males than females in each group with a male: female ratio of 7:3 and 2.1:1 seen in the preseptal and orbital cellulitis respectively (Fig 1). In comparison, Liu et al found no sex predilection in preseptal cellulitis but also found a male: female ratio of 2:1 in orbital cellulitis (5). Two other studies also reported a male predilection in orbital cellulitis secondary to sinusitis, one finding a ratio as high as 7:1(9, 10). The reason for this tendency is not known.

The patients in our study were aged between one month and 74 years, with a mean of 7.9 +/- 10.2 for the preseptal group and a mean of 18.9 +/- 18.2 for the orbital group. This is in contrast to the findings of Kiumbura et al who found orbital cellulitis affected patients mainly below 10 years, but others have also found it more in the second decade of life (9,10). This has been attributed to the rapid growth phase the sinuses undergo from around six years of age. The immature immune systems of children also put them at higher risk of sinusitis and upper respiratory tract infections.

Eye swelling and pain were the most common presenting symptoms in both orbital and preseptal cellulitis (table 2). Those with preseptal cellulitis often presented with upper respiratory tract symptoms like nasal blockage and nasal discharge, and irritability in the very young. This is because as in other series, sinusitis and upper respiratory tract infections were found to be frequent causes of preseptal cellulitis(3,5). In the orbital cellulitis group, 34% complained of reduced vision, followed by upper respiratory symptoms, headache and diplopia. In a study by Chang et al, the incidence of reduced visual acuity and RAPD substantially increased at Chandler stage IV and V respectively(43). Two patients who had brain abscess at admission presented with convulsions and one had aphasia.

All patients with preseptal cellulitis had eyelid oedema/inflammation, followed by ptosis and discharge. About 20% had chemosis, a finding more commonly but not exclusively found in orbital cellulitis. Similar findings were reported by Liu et al(5) and Jackson et al(3) who found that 13.4% and 14% respectively of preseptal cellulitis patients had chemosis. In the orbital cellulitis group, 94% presented with eyelid inflammation and proptosis, followed by chemosis, ptosis and limited extraocular motility. Only 27% had fever at presentation, likely because most presented having been on antibiotics and presumably also analgesics/

antipyretics prior to admission. This is in contrast to other studies where fever was found in 68.6% of children versus 43% of adults(43) and 71% of children versus 32% of adults(15).

In preseptal cellulitis, URTI was the main predisposing factor, followed by sinusitis. The two are closely related since upper respiratory tract infections can spread to involve the paranasal sinuses. Similarly, sinusitis was the underlying risk factor in most patients with orbital cellulitis. Studies by Adeoti et al and Ferguson et al had similar findings for orbital cellulitis in particular (15,16) but on the contrary, Liu et al found skin lesions in children and dacryocystitis in adults to be more associated with preseptal cellulitis (5). The youngest patient, a month-old child, had been treated for pneumonia a week before presenting to our hospital with orbital cellulitis. Two patients developed orbital cellulitis due to intra-orbital foreign bodies that were removed surgically. One patient with orbital cellulitis secondary to trauma had panfacial fractures and after treatment underwent open reduction and internal fixation for the fractures. Other predisposing factors for both preseptal and orbital cellulitis included dental infections, skin infections of the eyelid (two with hordeolum and one with chalazion). One patient developed preseptal cellulitis secondary to nasolacrimal duct obstruction, and after resolution of the infection, underwent dacryocystorhinostomy.

Full haemogram was done in a majority of patients. Out of those that had results, leucocytosis was found in 45% of orbital cellulitis versus 33% of preseptal cellulitis patients. This is in keeping with literature where it has been found to occur more in orbital cellulitis (45). The rate of leucocytosis also varies widely between 18% and 50% for orbital cellulitis (5,16,40,43).

Imaging is not necessary in most cases of preseptal cellulitis, but is very important in orbital cellulitis. In this series, CT scan was the imaging modality of choice and was done in 8/20 (43%) and 39/47(83%) of preseptal and orbital cellulitis patients respectively. The ethmoid and maxillary sinuses were most often affected and usually multiple sinuses(pansinusitis) were involved. Similar findings have been found in other series by Nwaorgu et al, Chang et al and El-Beltagy et al (9,43,50). The scans helped identify orbital wall fractures in two patients(one of whom went ahead to have surgical reduction with plates after the cellulitis resolved), and intraorbital foreign body in another who had been injured by a graphite pencil.

Cultures were done in a minority, 19/67 (28%) of patients. All samples were taken from abscess material during surgery. The positive culture rate was low, with 58% of the patients having no growth obtained from cultures. This is possibly because a majority of patients had

already been on antibiotic treatment by the time samples were taken. In contrast, higher positive culture rates of between 35-71% have been reported in other studies, with the highest yield being from abscess material (5,8,16,17). The organisms cultured in this series were *Staphylococcus aureus*, *Streptococcus pyogenes*, *Klebsiella spp*, *Escherichia coli*, and *Proteus spp*, all of which have been isolated in other studies from patients with orbital cellulitis (8,9,16,17,27). No blood cultures were found in the records in this series, and since literature has reported low yields generally, this would likely have been of more value in the very sick patients due to septicaemia (5, 9, and 16).

On admission, all patients were started on antibiotics either a single drug or combination therapy. The latter was preferred in orbital cellulitis (76%), and either cefuroxime or ceftriaxone, then amoxicillin-clavulanate in combination with metronidazole were used empirically. This was to ensure broad spectrum coverage of organisms as gram positive, gram negative and anaerobes have been isolated from various studies. In our case, the yield was too low to generalize and give recommendations. For those with brain abscess, and/ or having poor response to medical treatment, vancomycin or meropenem was added. All patients received oral antibiotics on discharge, for varying duration, but generally to complete at least one week of treatment. While there are no randomized controlled trials on treatment of orbital cellulitis, treatment is based on empiric coverage of the common causative organisms as previously mentioned(4).

In addition to antibiotic use, majority of patients 10/20 (50%) with preseptal cellulitis and 30/47 (64%) of orbital cellulitis patients required surgery. This is in keeping with literature where 63% in Kiumbura's study, 50% in Chaudhry's and 54% in Chang et al's study needed surgery (8,17,44). Lid abscess drainage was done in half of the patients admitted with preseptal cellulitis while drainage of orbital and subperiosteal abscess followed by lid abscess were the most commonly performed in those with orbital cellulitis. These procedures were often done together with functional endoscopic sinus surgery to drain the sinuses and prevent recurrence. However, the otorhinolaryngologists at times opted to manage the patients conservatively with nasal decongestants, and it was not always clear when surgical versus conservative management of sinusitis was indicated. Patients with brain abscess were managed in consultation with neurosurgeons where 5/8(63%) required craniotomy and the rest were managed conservatively. All recovered well.

Visual acuity in preseptal cellulitis was not affected except for the transient 'loss of vision' in the acute phase due to eyelid swelling and mechanical ptosis. Four patients whose vision was recorded in the Snellen format had better than 6/18 vision both at admission and at discharge. Half of the patients had their vision recorded as fixing and following objects/ light and this is likely due to the fact that those largely affected were young children. Nine patients (45%) were below four years in the preseptal cellulitis group and this presented a challenge in assessing visual acuity. In addition, pain and tenderness of the periorbital tissues contributes to the difficulty in taking vision at presentation. Among those with orbital cellulitis, there was a significant proportion already blind at presentation, and 11% at discharge (table 13). Other studies have demonstrated a wide range from as low as 3% to 45% blindness at the end of treatment (10,15,32). The high rate of visual loss has been attributed to delayed proper diagnosis and surgical intervention in previous studies.

Complications were more common in orbital than preseptal cellulitis. Half of the patients with preseptal cellulitis and 60% of those with orbital cellulitis developed complications. Lid abscess was the only complication of preseptal cellulitis and all the patients underwent incision and drainage. Subperiosteal abscess and orbital abscess, often co-existing with lid abscess were the most common complications of orbital cellulitis. In most cases, this called for surgical intervention. This is similar to findings in literature by Nwaorgu et al and Adeoti et al (9,14) who also found abscesses were the most common complications of orbital cellulitis. About 3/47(6%) were found to have exposure keratopathy and strabismus during the admission. The exposure had healed by the time of discharge but two patients with orbital cellulitis had strabismus at discharge and were to have further assessment at their out-patient follow-up visits. In a study by Chaudry et al in Saudi Arabia, there were 6 cases of strabismus and ptosis that persisted after the orbital cellulitis had been treated and resolved (31). One patient, a 10year old boy who was treated for orbital cellulitis secondary to sinusitis was admitted three weeks later with a recurrence in the other eye. He was treated medically for two weeks and also underwent a repeat FESS and antral washout. He recovered fully with no further complications.

The rate of intracranial complications was 17% in this study. A similar rate of 20% was recorded in Nigeria by Nwaorgu et al (9). Though no deaths were reported in this series, it still rarely occurs and from advanced disease. El-Beltagy reported two deaths from cavernous sinus thrombosis (50), Chang et al reported one death due to cavernous sinus and temporal lobe invasion (43). Complications from preseptal and orbital cellulitis can be prevented by

adequate treatment of the underlying conditions in particular sinusitis, proper antibiotic coverage once diagnosis is made and being vigilant for development of complications as they are common.

5.1 Limitations

1. Lack of investigations such as microscopy, culture and sensitivity meant that the results could not be generalised as the positive cultures were too few.
2. Missing records on details found in imaging, results of investigations affect the completeness of information.

5.2 Conclusions

1. Preseptal and orbital cellulitis were commoner in young, male patients below twenty years.
2. Sinusitis and upper respiratory infections were the most common risk factor for both groups.
3. Low yield was obtained from microbiological investigations.
4. At least half of patients needed surgical intervention.
5. Eleven per cent of patients with orbital cellulitis were blind, a significant proportion.

5.3 Recommendations

1. Upper respiratory tract infections and cellulitis should be treated aggressively in order to minimize complications.
2. A multidisciplinary approach to management is necessary in sinusitis and should be sought early.
3. More microbiological investigations done early in the course of treatment would give a higher yield and inform choice of treatment
4. Imaging should be done in all patients with orbital cellulitis at presentation to identify the underlying cause and complications.
5. The empiric treatment should be based on the likely organisms in relation to the likely predisposing factor identified.

REFERENCES

1. American Academy of Ophthalmology. Pediatric ophthalmology and strabismus. 2015.
2. Smith TF, O'day D, Wright PF. Clinical implications of preseptal (periorbital) cellulitis in children. *Pediatrics*. 1978;62(1006).
3. Jackson K, Baker SR. Clinical implications of orbital cellulitis. *Laryngoscope*. 1986;96(5):568–74.
4. Lee S, Yen MT. Management of preseptal and orbital cellulitis. Vol. 25, *Saudi Journal of Ophthalmology*. 2011. p. 21–9.
5. Liu IT, Kao SC, Wang AG, Tsai CC, Liang CK, Hsu WM. Preseptal and orbital cellulitis: A 10-year review of hospitalized patients. Vol. 69, *Journal of the Chinese Medical Association*. 2006. p. 415–22.
6. ChandlerJR, LangenbrunnerDJ SE. The pathogenesis of orbital complications in acute sinusitis. *The Laryngoscope*. 80(9):1414–28.
7. Kiumbura NW. Orbital cellulitis as seen at Kenyatta national hospital. University of Nairobi; 1997.
8. Tshifularo M, Monama GM. Complications of inflammatory sinusitis in children: institutional review. *South African Family Practice*. 2006;28(10):16-16c.
9. Nwaorgu OGB, Awobem FJ, Onakoya PA, Awobem AA. Orbital cellulitis complicating sinusitis: a 15-year review. *Nigerian journal of surgical research*. 2004;6(1–2):14–6.
10. Lusk RP. Pediatric sinusitis. *Diseases of the sinuses. Diagnosis and treatment*. 1st ed. BC Decker Inc; 2001. 255–69 p.
11. Schramm VL, Curtin HD, Kennerdell JS. Evaluation of orbital cellulitis and results of treatment. *Laryngoscope*. 1982;92(7):732–8.
12. Osguthorpe JD, Hochman M. Inflammatory sinus diseases affecting the orbit. *Otolaryngol Clin North Am*. 1993;26(4):657–671.
13. Patt BS, Manning SC. Blindness Resulting from Orbital Complications of Sinusitis. *Otolaryngology-Head and Neck Surgery*. 1991;104(6):789–95.

14. Adeoti CO, Adejumo OO, Isawumi MA, Kolawole OO, Haastrup A A. Orbital cellulitis in a tertiary institution in Nigeria: Improving outcomes. *Nigerian Journal of Ophthalmology*. 2017;25:141–5.
15. Ferguson MP, McNab AA. Current treatment and outcome in orbital cellulitis. *Australian and New Zealand journal of ophthalmology*. 1999;27(6):375–379.
16. Chaudhry IA, Shamsi FA, Elzaridi E, Al-Rashed W, Al-Amri A, Arat YO. Inpatient preseptal cellulitis: Experience from a tertiary eye care centre. *British Journal of Ophthalmology*. 2008;92(10):1337–41.
17. Al-Madani MV, Khatatbeh AE, Rawashdeh RZ, Al-Khtoum NF, Shawagfeh NR. The prevalence of orbital complications among children and adults with acute rhinosinusitis. *Brazilian Journal of Otorhinolaryngology*. 2013;79(6):716–9.
18. Allan BP, Egbert MA, Myall RWT. Orbital abscess of odontogenic origin. Case report and review of the literature. *International Journal of Oral and Maxillofacial Surgery*. 1991;20(5):268–70.
19. Jain A, Rubin PAD. Orbital cellulitis in children. *international Ophthalmology clinics*. 2001;41(4):71–86.
20. Wilson ME, Paul TO. Orbital cellulitis following strabismus surgery. *Ophthalmic surgery*. 1987;18(2):92–4.
21. Schwartz SG, Kuhl DP, McPherson AR et al. Twenty year follow-up of scleral buckling procedures. *Archives of Ophthalmology* . 2002;120(3):325–9.
22. Bakshi R, Wright PD, Kinkel PR, Bates VE, Mechtler LL, Kamran S, et al. Cranial magnetic resonance imaging findings in bacterial endocarditis: The neuroimaging spectrum of septic brain embolization demonstrated in twelve patients. *Journal of Neuroimaging*. 1999;9(2):78–84.
23. Doan A, Carter KD. Pan-endophthalmitis and orbital cellulitis: 89-year-old female with a history of gradual redness and proptosis OD over 3 weeks. February 21, 2005.
24. Farooq A V, Patel RM, Lin AY, Setabutr P, Sartori J, Aakalu VK. Fungal Orbital Cellulitis: Presenting Features, Management and Outcomes at a Referral Center. *Orbit (Amsterdam, Netherlands)*. 2015;34(April):1–8.

25. Kwitko GM, Sobol AL. Preseptal cellulitis clinical presentation [Internet]. *emedicine.medscape.com*. 2017 [cited 2018 Mar 9]. Available from: <https://emedicine.medscape.com/article/1218009>
26. Nageswaran S, Woods CR, Benjamin DK, Givner LB, Shetty AK. Orbital cellulitis in children. *Vol. 25, Pediatric Infectious Disease Journal*. 2006. p. 695–9.
27. Jarrett WH, Gutman FA. Ocular Complications of Infection in the Paranasal Sinuses. *Archives of Ophthalmology*. 1969;81(5):683–8.
28. Chaudhry I, Al-Rashed W, Arat Y. The hot orbit: Orbital cellulitis. *Middle East African Journal of Ophthalmology*. 2012;19(1):34.
29. Elshafei AMK, Sayed MF, Abdallah RMA. Clinical profile and outcomes of management of orbital cellulitis in Upper Egypt. *Journal of Ophthalmic Inflammation and Infection*. 2017;7(1).
30. Mathew A V., Craig E, Al-Mahmoud R, Batty R, Raghavan A, Mordekar SR, et al. Paediatric post-septal and pre-septal cellulitis: 10 years' experience at a tertiary-level children's hospital. *British Journal of Radiology*. 2014;87(1033).
31. Chaudhry IA, Shamsi FA, Elzaridi E, Al-Rashed W, Al-Amri A, Al-Anezi F, et al. Outcome of Treated Orbital Cellulitis in a Tertiary Eye Care Center in the Middle East. *Ophthalmology*. 2007;114(2):345–54.
32. Ebricht JR, Pace MT, Niazi AF. Septic thrombosis of the cavernous sinuses. *Archives of Internal Medicine*. 2001 Dec 10;161(22):2671–6.
33. Nicoli TK, Oinas M, Niemelä M, Mäkitie AA, Atula T. Intracranial Suppurative Complications of Sinusitis. *Scandinavian Journal of Surgery*. 2016;105(4):254–62.
34. American Academy of Ophthalmology. *Ophthalmic Pathology and Intraocular Tumors*. Basic and clinical science course, section 4. 2009. 186 p.
35. Morgan PR, Morrison W V. Complications of frontal and ethmoid sinusitis. *The Laryngoscope*. 1980;90(4):661–6.
36. Pandian D, Chaitra A, Rao V, Babu R, Anjali A, Srinivasan R. Nine years' review on preseptal and orbital cellulitis and emergence of community-acquired methicillin-resistant *Staphylococcus aureus* in a tertiary hospital in India. *Indian Journal of*

- Ophthalmology. 2011;59(6):431.
37. Kronish JW, Johnson TE, Gilberg SM, Corrent GF, McLeish WM, Scott KR. Orbital infections in patients with human immunodeficiency virus infection. *Ophthalmology*. 1996;103(9):1483–92.
 38. Swift AC, Charlton G. Sinusitis and the acute orbit in children. *The Journal of Laryngology & Otology*. 1990;104(3):213–6.
 39. Robinson a, Beech T, McDermott a L, Sinha A. Investigation and management of adult periorbital and orbital cellulitis. *J Laryngol Otol*. 2007;121(6):545–7.
 40. Uy HS, Tuaño PMC. Preseptal and orbital cellulitis in a developing country. *Orbit*. 2007;26(1):33–7.
 41. Spires JR, Smith RJ. Bacterial infections of the orbital and periorbital soft-tissues in children. *Laryngoscope*. 1986;96(7):763–7.
 42. Bergin DJ, Wright JE. Orbital cellulitis. *The British journal of ophthalmology*. 1986;70(3):174–8.
 43. Chang YS, Chen PL, Hung JH, Chen HY, Lai CC, Ou CY, et al. Orbital complications of paranasal sinusitis in Taiwan, 1988 through 2015: Acute ophthalmological manifestations, diagnosis, and management. *PLoS ONE*. 2017;12(10).
 44. Weiss A, Friendly D, Eglin K, Chang M, Gold B. Bacterial Periorbital and Orbital Cellulitis in Childhood. *Ophthalmology*. 1983;90(3):195–203.
 45. Murphy C, Livingstone I, Foot B, Murgatroyd H, MacEwen CJ. Orbital cellulitis in Scotland: Current incidence, aetiology, management and outcomes. *British Journal of Ophthalmology*. 2014;98(11):1575–8.
 46. Seltz LB, Smith J, Durairaj VD, Enzenauer R, Todd J. Microbiology and Antibiotic Management of Orbital Cellulitis. *Pediatrics*. 2011 Mar 1;127(3):e566 LP-e572.
 47. Donahue SP, Schwartz G. Preseptal and orbital cellulitis in childhood. A changing microbiologic spectrum. *Ophthalmology*. 1998;105(10):1902–6.
 48. Garcia GH, Harris GJ. Criteria for nonsurgical management of subperiosteal abscess of the orbit²². *Ophthalmology*. 2018 Mar 24;107(8):1454–6.
 49. El-Silimy O. The place of endonasal endoscopy in the treatment of orbital cellulitis.

Rhinology. 1995;33(2):93–6.

50. El-Beltagy Y, Hamid Hamdy TA, Hasaballah MS. Orbital complications following sinusitis still a problem: Our experience and results. Egyptian Journal of Ear, Nose, Throat and Allied Sciences. 2014;15(3):189–95.
51. www.who.int/blindness/changeDefinitionofBlindness.pdf.

APPENDICES

Appendix 1: Study tool

Serial No..... Date of data
collection.....

A. Biodata

1. Age in years
2. Sex: Male (0)
Female (1)

B. Presenting symptoms

1. Pain (1)
2. Eye swelling (2)
3. Reduced vision (3)
4. URTI-like symptoms (4)
5. Diplopia (5)
6. Fever (6)
7. Toothache (7)
8. Other.....

C. Presenting signs

1. Vitals: Temperature.....
Pulse rate.....
2. Visual acuity..... Not assessed.....
3. Limited EOMM Yes (0) No (1) Not assessed (2)
4. RAPD Yes (0) No (1) Not assessed (2)
5. Eyelid swelling Yes (0) No (1)
6. Proptosis Yes (0) No (1)
7. Discharge Yes (0) No (1)
8. Ptosis Yes (0) No (1)
9. Chemosis Yes (0) No (1)

d. Cavernous sinus thrombosis		
e. Brain abscess		

3. Orbital ultrasound Yes (0) No(1)

Findings.....

4. Full haemogram Yes (0) No(1)

Results: White blood cells.....

Neutrophils.....

Eosinophils.....

Basophils.....

Platelets.....

5. Microbiology Yes (0) No (1)

6. Method of obtaining specimen.....

7. Gram stain Positive (0) Negative (1) Not done (2)

8. Organisms grown and sensitivity

S. aureus (0).....

S. epidermidis (1).....

Strep spp (2).....

H.influenzae (3).....

No growth obtained (4)

Others (specify).....

9. Final Diagnosis: Stage I II III IV V

F. Treatment modalities

1. Antibiotics given prior to admission.....

 Duration.....

2. Empiric antibiotics at admission

Co-amoxiclav (0).....

Ceftriaxone (1).....

Metronidazole (2).....

Others (specify).....

Duration.....

 1. Surgery done:

 Drainage of lid abscess (0)

 Drainage of subperiosteal/orbital abscess (1)

 FESS (2)

 Craniotomy (3)

 Others.....

G. Complications of preseptal and orbital cellulitis

Visual acuity at discharge..... VA at last follow-up visit.....

Lid abscess (0) Exposure keratopathy (4)

Orbital abscess (1) Panophthalmitis (5)

Cavernous sinus thrombosis (2) Ptosis (6)

Strabismus (3) Death (7)

None (8)

Other (specify).....

Appendix 2: ICD-10 CM Codes

1. H00-H59 Disorders of eyelid, lacrimal system and orbit

Disorders of eyelid, lacrimal system and orbit H00-H05 >

Type 2 Excludes:

- open wound of eyelid (S01.1-)
- superficial injury of eyelid (S00.1-, S00.2-)

Codes

- H00 Hordeolum and chalazion
- H01 Other inflammation of eyelid
- H02 Other disorders of eyelid
- H04 Disorders of lacrimal system
- H05 Disorders of orbit

Codes

- H00 Hordeolum and chalazion
 - H00.0 Hordeolum (externum) (internum) of eyelid
 - H00.01 Hordeolum externum
 - H00.02 Hordeolum internum
 - H00.03 Abscess of eyelid
 - H00.1 Chalazion
- H05 Disorders of orbit
 - H05.0 Acute inflammation of orbit
 - H05.00 Unspecified acute inflammation of orbit
 - H05.01 Cellulitis of orbit
 - H05.1 Chronic inflammatory disorders of orbit
 - H05.2 Exophthalmic conditions
 - H05.3 Deformity of orbit
 - H05.4 Enophthalmos
 - H05.5 Retained (old) foreign body following penetrating wound of orbit.

Appendix 3: Budget

Item	Quantity	Unit Cost	Total Cost
Proposal/Ethical approval			
Proposal writing and printing (35 pages)	6 copies		1,000
Binding Proposal	6 copies		150
Ethics	1		2,000
Internet			1,000
		Subtotal	4,150
Data Collection			
Printing of Questionnaires	4 pages		50
Photocopy of Questionnaires	4 pages (100 copies)		1200
Stationery –pens, rubbers etc.			500
Flash Disk 16GB Hp	1		2,000
Box files for filing questionnaires	1		200
		Subtotal	3,950
Transport			
		Subtotal	3,000
Contracted services			
Statistician	1	Subtotal	35,000
Printing costs and binding of final book			
Finished book printing (approx. 60 pages)	8 copies		2,400
Binding	8 copies		800
		Subtotal	3,600
TOTAL			49,700

Appendix 4. KNH- UON Ethics and Research Committee Approval



UNIVERSITY OF NAIROBI
COLLEGE OF HEALTH SCIENCES
P O BOX 19676 Code 00202
Telegrams: varsity
Tel:(254-020) 2726300 Ext.44355

KNH-UON ERC

Email: uonknh_erc@uonbi.ac.ke
Website: <http://www.erc.uonbi.ac.ke>
Facebook: <https://www.facebook.com/uonknh.erc>
Twitter: @UONKNH_ERC http://twitter.com/UONKNH_ERC



KENYATTA NATIONAL HOSPITAL
P O BOX 20723 Code 00202
Tel: 726300-9
Fax: 725272
Telegrams: MEDSUP, Nairobi

Ref: KNH-ERC/A/128

5th April, 2019

Dr. Kagendo Kahunyo
Reg. No.H58/81172/2015
Dept. of Ophthalmology
School of Medicine
College of Health Sciences
University of Nairobi

05 APR 2019

Dear Dr. Kahunyo

RESEARCH PROPOSAL: A FIVE YEAR REVIEW OF PRESEPTAL AND ORBITAL CELLULITIS IN IN-PATIENTS AT KENYATTA NATIONAL HOSPITAL (P18/01/2019)

This is to inform you that the KNH- UoN Ethics & Research Committee (KNH- UoN ERC) has reviewed and approved your above research proposal. The approval period is 5th April 2019 – 4th April 2020.

This approval is subject to compliance with the following requirements:

- Only approved documents (informed consents, study instruments, advertising materials etc) will be used.
- All changes (amendments, deviations, violations etc.) are submitted for review and approval by KNH-UoN ERC before implementation.
- Death and life threatening problems and serious adverse events (SAEs) or unexpected adverse events whether related or unrelated to the study must be reported to the KNH-UoN ERC within 72 hours of notification.
- Any changes, anticipated or otherwise that may increase the risks or affect safety or welfare of study participants and others or affect the integrity of the research must be reported to KNH- UoN ERC within 72 hours.
- Clearance for export of biological specimens must be obtained from KNH- UoN ERC for each batch of shipment.
- Submission of a request for renewal of approval at least 60 days prior to expiry of the approval period. (*Attach a comprehensive progress report to support the renewal*).
- Submission of an *executive summary* report within 90 days upon completion of the study. This information will form part of the data base that will be consulted in future when processing related research studies so as to minimize chances of study duplication and/ or plagiarism.

Protect to discover