



## A CASE REPORT ON AN UNUSUAL ELONGATION OF THE SUSTENTACULUM TALII

Thomas Amuti, Anita Wambui, Innocent Ouko, Julius Ogeng'o

### ABSTRACT

The sustentaculum tali, as a horizontal shelf of the calcaneus serves as an attachment point for the ligamentous support of the foot. Any variations on it has therefore been linked to instability factors of the ankle joint. Studies have explored on the possible variations of this bony projection, but none have been documented on an unusually long elongation of the same. This study examined an unusually elongated sustentaculum tali found located on the left calcaneus of an adult Kenyan calcaneus. The right pair did not bear the same variation. This elongation on the calcaneus revealed that it had a length of 11.68mm, height of 7.68mm and thickness of 2.83mm. This elongated sustentaculum tali, even though a rare case should be considered in the cases of idiopathic subtalar joint instability.

**Keywords:** Sustentaculum tali, calcaneus

### INTRODUCTION

The sustentaculum tali is the medial process of the calcaneus (heel bone), also defined as a horizontal shelf arising from the anteromedial portion of the calcaneus. Its superior surface bears the middle calcaneal facet, which articulates with the talus. Inferiorly, a sulcus for the tendon of flexor hallucis longus is present (Thomas et al., 2000).

The sustentaculum tali also acts as a site for attachment for 3 ligaments; the plantar calcaneo-navicular (spring) ligament proximally, the tibio-calcaneal part of the deltoid ligament in the middle and the medial talocalcaneal ligament distally (Brian et al., 2005). These ligaments

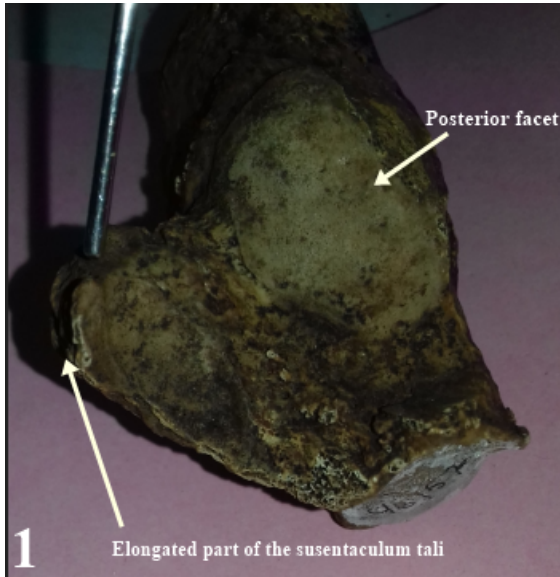
form part of the static stability factors of not only the subtalar joint but also the foot and by so, aids in the transmission of weight to the ground. Variations of the sustentaculum tali may therefore influence subtalar joint stability and predispose to flat foot (Daniel et al., 2011).

Among the variations that have been reported on the sustentaculum tali, is the presence of more than one articular facet on its superior surface (Nemade et al., 2014). However, no variations on the dimensions of the sustentaculum tali have been reported. Here, we present a case of an unusually elongated sustentaculum tali.

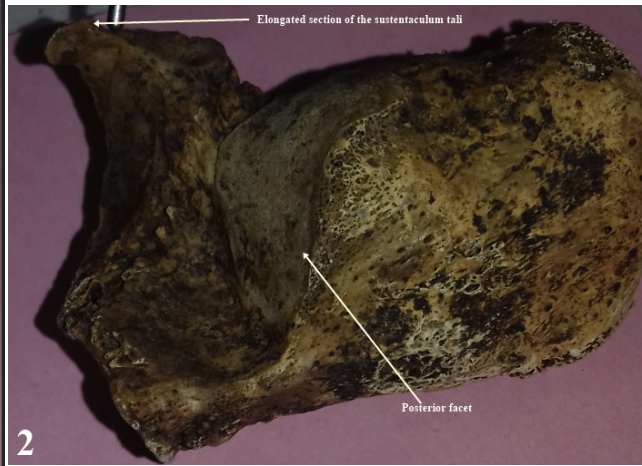
### CASE REPORT

While carrying out a study on the calcanei, at the National Museum in Nairobi, Kenya, we came across an unusual elongation (Figure 1-6) of the sustentaculum tali in a left calcaneus. Biodata of the bone revealed that it belonged to an adult Kenyan male. The right pair of the calcaneus of the same subject did not portray this unusual elongation. The bones were noted to have been excavated in the 1900's.

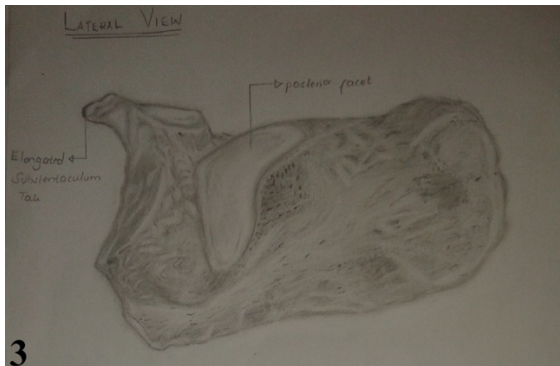
The elongation was arising proximally and curving towards the middle facet of the calcaneus. Dimension measurements of the elongated section of the left calcaneus revealed that it had a length of 11.68mm, height of 7.68mm and thickness of 2.83mm.



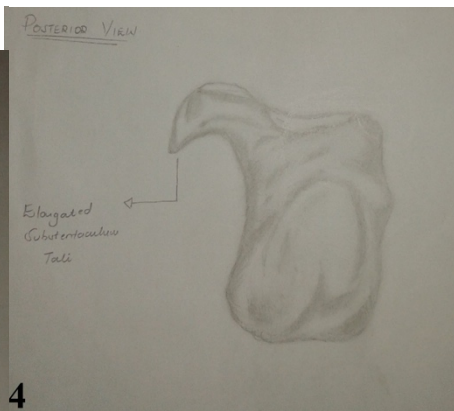
**Figure 1:** Image taken from the anterior view of the elongated process of the sustentaculum tali.



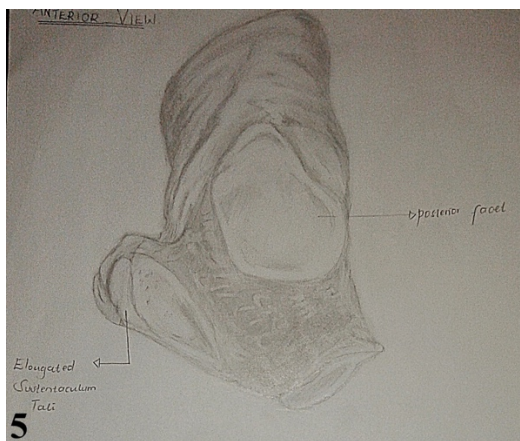
**Figure 2:** Image taken from the lateral view of the elongated process of the sustentaculum tali.



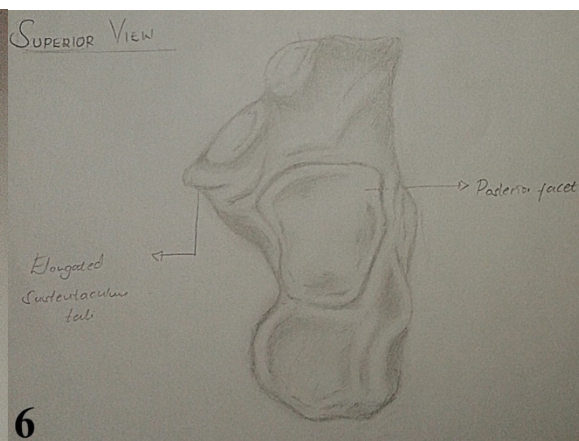
**Figure 3:** Drawing representing the lateral view of the elongated process of the sustentaculum tali.



**Figure 4:** Drawing representing the posterior view of the elongated process of the sustentaculum tali.



**Figure 5:** Drawing representing the anterior view of the elongated process of the sustentaculum tali.



**Figure 6:** Drawing representing the superior view of the elongated process of the sustentaculum tali.

## DISCUSSION

Our data on the elongated sustentaculum tali is the first to be reported in literature. There were therefore no previous papers done for comparison on humans, however, the sustentacular length has been reported to be longer in taxa adapted to running, jumping, and living partly in water and land where it favours parasagittal movements such as pushing back the soil. In creatures adapted to burrowing, however, the antero-posterior dimension of the sustentacular facet is generally reduced (Samuel et al., 2016). The rare elongated case thus noted could be due to the fact that it belonged to an African man who was more accustomed to running and jumping possibly during hunting and gathering of food in the 1900's where food was still scarce, and hunting was common in our setting.

The sustentacular width has been reported to be thicker in taxa adapted to climbing<sup>5</sup>. The transversely oriented shape of the sustentacular facet permits medio-lateral movements, crucial for these locomotor categories. In our case, the observed thickness could signify that it belonged to an individual who was accustomed to climbing, possibly tress, during hunting. The climbing would have given him an advantage of spotting prey from a distance. This could explain the extra thickness of the tali.

It is also possible that the variations observed could be due to individual genetic heterogeneity which influenced the development of the elongated of the tali as observed.

In conclusion, the elongated sustentaculum tali, is a rare case but should be considered in the cases of idiopathic subtalar joint instability.

## REFERENCES

1. Thomas A. Olexa, Nabil A. Ebraheim, Steve P. Haman 2000. The Sustentaculum Tali: Anatomic, Radiographic, and Surgical Considerations. *Foot & Ankle International*; 21: 5.
2. Brian J. Keener, Joseph A. Sizensky 2005. The Anatomy of the Calcaneus and Surrounding Structures *Foot Ankle Clin N Am*; 10:413 – 424.
3. Daniel P, Guido S. Carabelli, Luciano A. Poitevin 2011. Spring Ligament and Sustentaculum Tali Anatomical Variations: Anatomical Research Oriented to Acquired Flat Foot Study. *The Foot and Ankle Online Journal*; 4:1.
4. Nemade K.S, Meshram M.M, P. Kasote A, Y. Kamdi N 2014. Arthritis of the subtalar joint associated with sustentaculum tali facet configuration. *International Journal of Anatomy and Research*; 2:684-688.
5. Samuel G, Lionel H, Laurent M, Monique V-L 2016. Ecomorphological analysis of the astragalo-calcaneal complex in rodents and inferences of locomotor behaviours in extinct rodent species. *PeerJ*; 4: e2393.