

**SPECTRUM AND PATTERNS OF KNEE PATHOLOGY  
IN ADULT PATIENTS REFERRED FOR MRI TO  
KENYATTA NATIONAL HOSPITAL: A 3T MRI  
KENYAN PERSPECTIVE**


**PRINCIPAL INVESTIGATION:  
DR. SAGAR SURESH PATIL  
H58/6420/2017  
DEPARTMENT OF DIAGNOSTIC IMAGING AND RADIATION MEDICINE**

**DISSERTATION SUBMITTED AS PARTIAL FULFILLMENT FOR THE  
DEGREE OF MASTERS OF MEDICINE IN DEPARTMENT OF  
DIAGNOSTIC AND IMAGING RADIATION MEDICINE OF THE  
UNIVERSITY OF NAIROBI.**

**2022**

## DECLARATION

**I declare that this dissertation is my original work written under the supervision of Dr. Alfred Odhiambo Otieno and Dr. Nelson Mukora Kimani.**


Signature:  Date: 01/7/2022

**Dr. Sagar Suresh Patil**

## SUPERVISOR'S APPROVAL:

This dissertation has been submitted with our approval as University and Radiology supervisors.

**Dr. Alfred Odhiambo, M.B.Ch.B. (UoN), M.med. DRIM (UoN)**  
Senior Lecturer Department of Diagnostic Imaging and Radiation Medicine,  
University of Nairobi

Signature:  Date: 01/7/2022

**Dr. Nelson M Kimani, M.B.Ch.B. (UoN), M.med. DRIM (UoN)**  
Senior Lecturer Department of Diagnostic Imaging and Radiation Medicine,  
University of Nairobi

Signature:  Date: 02/7/2022

## **DEDICATION**

I dedicate this research to my parents, Dr Suresh Patil and Mrs Shailaja Patil and my sister Aparna without whose unwavering support this study would not have been possible.

I also dedicate this research to my late aunts.

## **ACKNOWLEDGEMENTS**

I would like to express my sincere and heartfelt gratitude to my supervisors Dr. Odhiambo and Dr. Kimani for their professional guidance and encouragement throughout the study period.

I would also like to express my gratitude to the following for the roles they played during this study:

- Mr. Wycliffe Ayieko, the biostatistician who assisted me with data analysis
- The management and staff of the Kenyatta National Hospital and University of Nairobi for their professional guidance and encouragement.
- To my colleague Dr. Manpreet for her support and encouragement.

# TABLE OF CONTENTS

<b>DECLARATION</b> .....	<b>ii</b>
<b>SUPERVISOR'S APPROVAL:</b> .....	<b>ii</b>
<b>DEDICATION</b> .....	<b>iii</b>
<b>ACKNOWLEDGEMENTS</b> .....	<b>iv</b>
<b>LIST OF TABLES</b> .....	<b>vii</b>
<b>LIST OF FIGURES</b> .....	<b>viii</b>
<b>LIST OF ABBREVIATIONS</b> .....	<b>ix</b>
<b>ABSTRACT</b> .....	<b>xi</b>
<b>CHAPTER ONE</b> .....	<b>1</b>
1.1 INTRODUCTION .....	1
1.2 LITERATURE REVIEW .....	3
1.3 ANATOMY OF THE KNEE JOINT .....	10
1.4 IMAGING MODALITIES OF THE KNEE .....	14
1.4.1 MAGNETIC RESONANCE IMAGING .....	14
1.4.2 ULTRASOUND .....	15
1.4.3 PLAIN RADIOGRAPHY.....	16
1.4.4 COMPUTED TOMOGRAPHY.....	16
1.5 PATHOLOGY OF THE KNEE AS SEEN ON MRI .....	17
<b>CHAPTER TWO</b> .....	<b>21</b>
2.1 STUDY JUSTIFICATION .....	21
2.2 STUDY QUESTION .....	21
2.3 STUDY SIGNIFICANCE.....	21
2.4 STUDY OBJECTIVES .....	21
2.4.1 BROAD OBJECTIVE .....	21
2.4.2 SPECIFIC OBJECTIVES .....	22
<b>CHAPTER THREE</b> .....	<b>23</b>
3.1 STUDY DESIGN AND METHODOLOGY.....	23
3.1.1 STUDY DESIGN .....	23
3.1.2 STUDY AREA DESCRIPTION.....	23
3.1.3 STUDY POPULATION .....	23
3.1.4 SAMPLING METHOD .....	23
3.1.5 INCLUSION CRITERIA.....	23
3.1.6 EXCLUSION CRITERIA .....	23
3.1.7 SAMPLE SIZE DETERMINATION .....	24
3.1.8 STUDY PROCEDURES .....	24
3.1.9 DATA COLLECTION PROCEDURES .....	25
3.1.10 MATERIALS AND EQUIPMENT .....	25
3.1.11 STUDY PERSONNEL .....	26
3.1.12 DATA COLLECTION TOOL.....	26

3.1.13 DATA HANDLING.....	26
3.1.14 ETHICAL CONSIDERATIONS .....	26
3.1.15 CONFIDENTIALITY OF PATIENTS .....	27
3.1.16 CONFIDENTIALITY OF DATA OBTAINED .....	27
3.1.17 BENEFICENCE/MALEFICENCE .....	27
3.1.18 DATA MANAGEMENT AND STATISTICAL ANALYSIS.....	27
3.1.19 DISSEMINATION OF RESULTS .....	28
<b>CHAPTER FOUR: RESULTS.....</b>	<b>29</b>
4.1 AGE AND GENDER CHARACTERISTICS .....	29
4.2 CLINICAL PRESENTATION AND DURATION .....	30
4.3 FINDINGS .....	31
4.4 SELECTED IMAGES FROM STUDY SAMPLE.....	37
<b>CHAPTER FIVE .....</b>	<b>41</b>
5.1 DISCUSSION.....	41
5.2 CONCLUSIONS .....	43
5.3 STUDY LIMITATIONS.....	44
5.4 RECOMMENDATIONS .....	45
<b>STUDY TIMELINE .....</b>	<b>46</b>
<b>BUDGET.....</b>	<b>47</b>
<b>REFERENCES .....</b>	<b>48</b>
<b>APPENDICES .....</b>	<b>51</b>
APPENDIX A: MRI SAFETY QUESTIONNAIRE AND CONSENT FORM.....	51
APPENDIX B: CONSENT FORM – ENGLISH.....	53
APPENDIX C: CONSENT FORM – KISWAHILI .....	59
APPENDIX D: DATA COLLECTION FORM.....	65
APPENDIX E: ETHICAL APPROVAL LETTER .....	67

## **LIST OF TABLES**

Table 1: Characteristics of the patients .....	29
Table 2: Clinical presentation of sample .....	30
Table 3: Joint effusion, ACL, PCL, MCL and LCL findings .....	32
Table 4: PT, MM, LM and other findings .....	33
Table 5: LPR, patella and articular cartilage findings .....	35
Table 6: Bone findings other than patella .....	36
Table 7: Other findings .....	36

## LIST OF FIGURES

Figure 1: Knee Anatomy.....	2
Figure 2: Sagittal T1W MRI of the knee .....	2
Figure 3: Axial T2W SPAIR MRI knee .....	3
Figure 4: Horizontal meniscal tear.....	17
Figure 5: Radial type tear in the lateral meniscus .....	18
Figure 6: Bucket handle tear of the meniscus .....	18
Figure 7:Arthroscopic view of ACL tear .....	18
Figure 8:ACL disruption and nonvisualization.....	19
Figure 9: Complete PCL tear .....	19
Figure 10: Grade I, grade II and grade III sprains of the MCL. ....	19
Figure 11: Gender distribution of sample .....	29
Figure 12: Age distribution of sample .....	30
Figure 13: Distribution of clinical symptoms in sample.....	31
Figure 14: Duration of symptoms in sample.....	31
Figure 15: Osteosarcoma involving right distal femur .....	37
Figure 16: Full thickness ACL tear.....	38
Figure 17: Baker’s cyst and a joint effusion .....	38
Figure 18: Bone marrow oedema of the inferior patella in the region of an undisplaced fracture.....	38
Figure 19: Complete ACL tear with a complex tear of the medial meniscus, a baker’s cyst, joint effusion, subcutaneous oedema in the anterior knee and lateral subluxation of the patella.....	39
Figure 20: Pigmented villonodular synovitis (PVNS). ....	39
Figure 21: Significant joint effusion, multiple enlarged reactive popliteal lymph nodes and a baker’s cyst.....	39
Figure 22: Bucket handle tear of the lateral meniscus and a high-grade PCL tear.....	40
Figure 23: Grade 1 MCL injury .....	40
Figure 24: Patellar cartilage chondral delamination injury, a displaced chondral body in the medial recess and a significant joint effusion .....	40



## LIST OF ABBREVIATIONS

<b>1.5T</b>	-	1.5 Tesla
<b>3T</b>	-	3 Tesla
<b>ACL</b>	-	Anterior cruciate ligament
<b>ALB</b>	-	Anterolateral bundle of posterior cruciate ligament
<b>AMB</b>	-	Anteromedial bundle of anterior cruciate ligament
<b>BFT</b>	-	Biceps femoris tendon
<b>COVID</b>	-	Corona virus disease
<b>CT</b>	-	Computed tomography
<b>CTA</b>	-	Computed tomography Angiography
<b>DICOM</b>	-	Digital Imaging and Communications in Medicine
<b>FS</b>	-	Fat saturated
<b>FSE</b>	-	Fast Spin Echo
<b>fsPDW</b>	-	Fat saturated Proton Density Weighted sequence
<b>GP</b>	-	General Practitioner
<b>IPFP</b>	-	Infrapatellar fat pad
<b>ITB</b>	-	Iliotibial Band
<b>LCL</b>	-	Lateral Collateral ligament
<b>LFC</b>	-	Lateral femoral condyle
<b>LM</b>	-	Lateral meniscus
<b>MCL</b>	-	Medial Collateral ligament
<b>MFC</b>	-	Medial femoral condyle
<b>MM</b>	-	Medial meniscus
<b>MRA</b>	-	Magnetic Resonance Angiography
<b>MRI</b>	-	Magnetic resonance imaging
<b>NPV</b>	-	Negative predictive value
<b>PACS</b>	-	Picture archiving and communication system
<b>PCL</b>	-	Posterior cruciate ligament
<b>PDW</b>	-	Proton Density Weighted sequence
<b>PFJ OA</b>	-	Patello-femoral joint Osteoarthritis
<b>PH</b>	-	Posterior Horn
<b>PLB</b>	-	Posterolateral bundle of anterior cruciate ligament
<b>PLC</b>	-	Posterolateral corner of the knee

<b>PMB</b>	-	Posteromedial bundle of posterior cruciate ligament
<b>PMC</b>	-	Posteromedial corner of the knee
<b>PMTC</b>	-	Popliteus musculo-tendinous complex
<b>POL</b>	-	Posterior oblique ligament
<b>PPE</b>	-	Personal protective equipment
<b>PPV</b>	-	Positive predictive value
<b>PTFJ</b>	-	Proximal tibio-fibular joint
<b>QFT</b>	-	Quadriceps femoris tendon
<b>SMT</b>	-	Semimembranosus tendon
<b>SNR</b>	-	Signal to Noise Ratio
<b>SOP's</b>	-	Standard operating procedures
<b>SPAIR</b>	-	Spectral Adiabatic Inversion Recovery
<b>SPSS</b>	-	Statistical Package for the Social Sciences
<b>T1W</b>	-	T1 Weighted sequence
<b>T2W</b>	-	T2 weighted sequence
<b>TSE</b>	-	Turbo spin echo

## **ABSTRACT**

### **Study Background**

The knee is one of the most common joints to be injured in the human body. This study aims to highlight the various types of injuries in the knee joint with state of the art 3T Magnetic resonance imaging (MRI) in subjects who meet the inclusion criteria.

The soft tissue detail provided by MRI is unparalleled. 3T MRI provides the highest signal to noise ratio (SNR) and hence improves identification of structures by improving anatomical detail. 3T magnets provide better spatial and temporal resolution than 1.5T magnets and are far more superior in diagnosis of articular cartilage lesions as evidenced by their greater sensitivity.

Furthermore, a 3T magnet overperforms in the detection of medial meniscus horizontal and unstable tears and anterior cruciate ligament (ACL) lesions are picked with greater diagnostic confidence and accuracy.

As of now, no such study has been undertaken in Kenya, and this study will help bridge the gap in knowledge and pave the way for more studies.

### **Broad Objective**

The main objective of this study is to ascertain the spectrum and patterns of pathology affecting structures in the knee joint, in patients undergoing MRI examinations using a 3T MRI scanner at the Radiology Department of Kenyatta National Hospital.

### **Study design and Site**

Descriptive prospective study at the MRI unit of the Department of Radiology, Kenyatta National Hospital, that serves the population in Nairobi and its environs.

### **Study Participants**

A total of 53 patients with knee symptoms who were referred for MR imaging of the knee.

### **Materials and methods**

A descriptive prospective study was done at the MRI unit of the Department of Radiology, Kenyatta National Hospital between April 2021 and June 2021. 53

consecutive patients referred to the Department of Radiology for a Knee MRI who fit the inclusion criteria were enrolled into the study. Once enrolled the demographic information of each patient was recorded. The MRI knee examination was then performed after which the images were analyzed on the DICOM viewer on the reporting workstation and findings were recorded in the data collection form. A report was also generated for each patient that was then validated by the consultant radiologist. Statistical analysis of the findings was then done using SPSS version 20 IBM and Microsoft Excel after which it was presented on tables and graphs. No arthroscopic findings were available to correlate with the imaging findings.

## **Results**

A total of 53 participants were recruited into the study. The mean age of the sample was 38.2 years (SD  $\pm$  12.3) with a range between 19 and 61 years. The median age was 37 years. The male to female ratio was 1:1.3. Most of the participants were in the 19-49 years age range. The right knee was affected more than the left knee. The patients were referred from A&E Casualty. The most common findings encountered were joint effusions, ACL tears, meniscal tears and degenerative joint disease. Of these, joint effusions accounted for 73.6% (n=39), ACL tears accounted for 35.9% (n=19), meniscal tears accounted for 18.9% (n=10) and degenerative joint disease accounted for 24.5% (n=13). ACL tears were more common in women with a male to female ratio of 1:3.8. The predominant meniscus injured was the medial meniscus which accounted for 13.2% (n=7). Patellar contusion was the most common finding in the patella accounting for 13.2% (n=7). 69.8% of patients had symptoms for more than two weeks. Knee pain was the most common presenting symptom (96%).

## **Conclusion**

Knee pain is more common in females than in males. The right knee is more commonly affected than the left knee. The most common finding was joint effusion secondary to another pathology followed and the most common soft tissue injury was an ACL tear. ACL injuries are more common in females than in males. This finding was not similar to other studies. Most ACL and PCL injuries have concurrent injuries. Degenerative changes seen on MRI increase with age.

## **CHAPTER ONE**

### **1.1 INTRODUCTION**

Knee pain is a common complaint in medical practice that leads to significant morbidity and disability. A compromised knee due to pain, stiffness or weakness results in substantial disability and challenges of mobility that affect a person's ability to carry out daily activities. Women have substantially more knee problems than men though the frequency in both genders skyrockets with age.

Clinical examination on its own is insufficient in identifying the etiology of knee pain. This usually necessitates use of various imaging modalities to increase the accuracy of identification of the cause of the pain. These include plain radiography, arthroscopy, ultrasound, computed tomography and magnetic resonance imaging (MRI). MRI excels as an imaging modality in depicting pathology of the knee. Its excellent soft tissue contrast resolution and multiplanar capacity makes MRI superior in knee imaging.

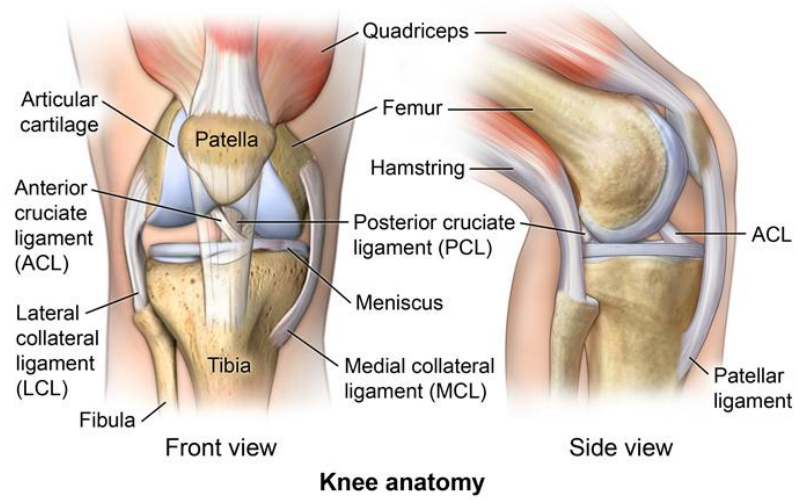
The knee is a complicated synovial hinge joint encompassing multiple individual joints or articular compartments namely: patellofemoral, medial femorotibial and lateral femorotibial. (1)

The combined efforts of muscles, tendons, ligaments and joint capsule extensions help to stabilize the knee in diverse directions, and offering mobility at the same instance. Multiple bursae in and around the knee joint allow for ease of motion of stabilizing structures in relation to each other. (1)

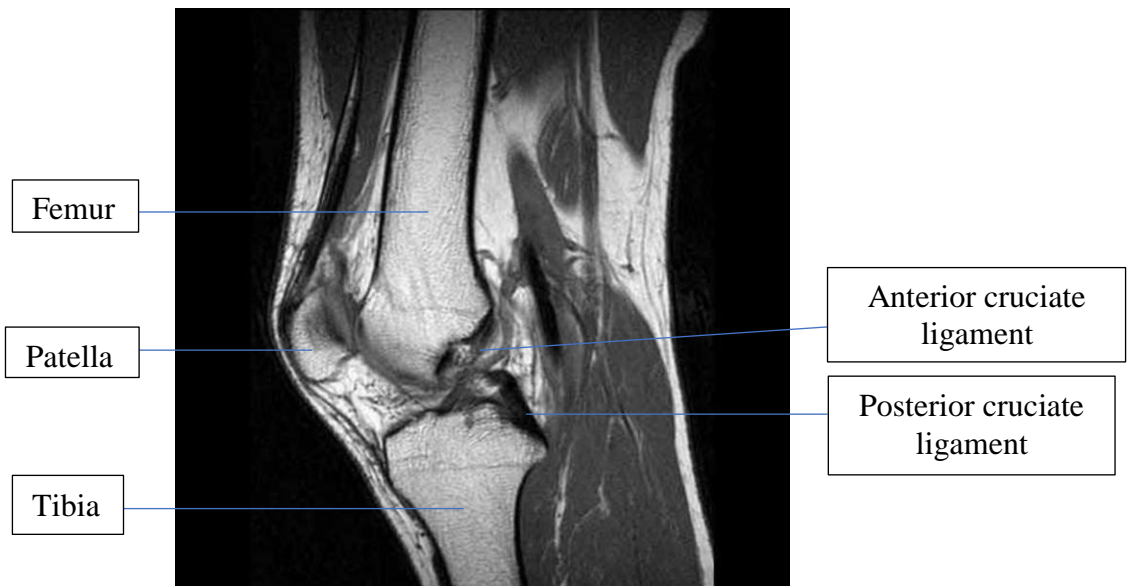
The main internal structures of the knee joint include the cruciate ligaments (anterior and posterior) and menisci (medial and lateral) also known as the semilunar cartilages. (1)

The knee joint is associated with high morbidity especially in sports and elderly and has a high propensity for trauma and degenerative changes.

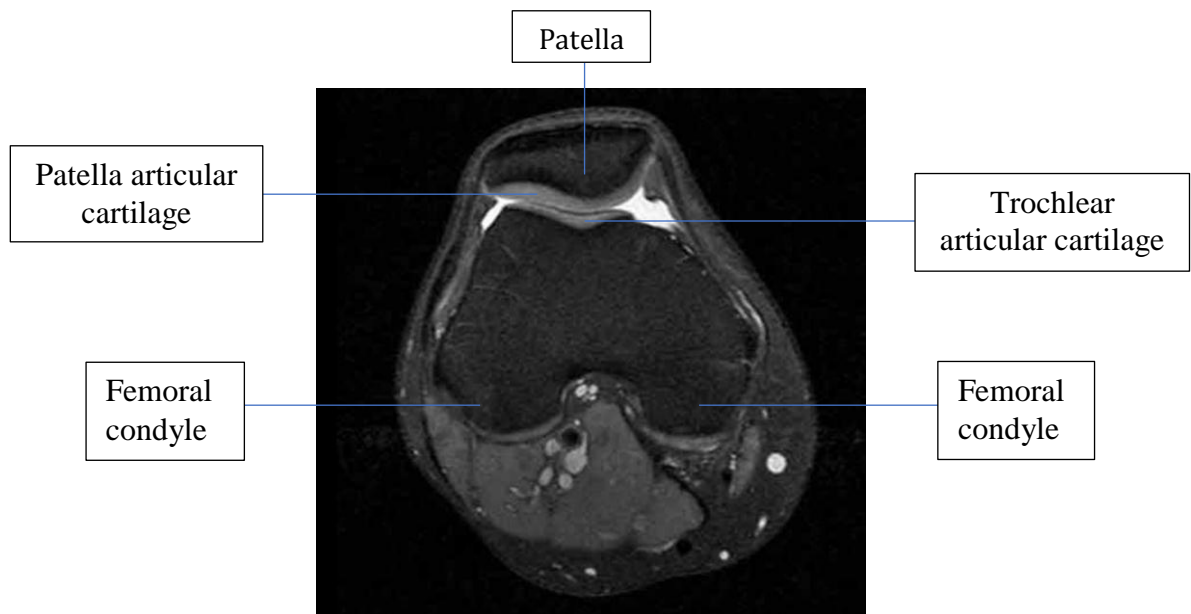
This study attempts to highlight the spectrum and patterns of knee pathology using 3T MRI as an imaging tool.



*Figure 1: Knee Anatomy*



*Figure 2: Sagittal T1W MRI of the knee*



*Figure 3: Axial T2W SPAIR MRI knee*

## **1.2 LITERATURE REVIEW**

A study conducted in Netherlands on the prevalence of musculoskeletal pain found a point prevalence of knee pain at 15.2%, following behind low back pain at 26.9%, neck and shoulder pain at 20.6% and 20.9% respectively. 3 out of 10 patients reported some degree of limitation in their daily life. (2)

The German SESAM 2 study showed that the most common cause of knee pain was osteoarthritis of the knee followed by other injuries. Of the 127 patients that consulted their GP, an almost equal proportion of male (49.6%) and female (50.4%) patients presented to their GP with knee pain. The peak incidence of knee pain was in the 45 to 64 year age range. (3)

In the Dutch Transition Project study, another general practice setting, more female patients (53.8%) consulted their general practitioner with knee pain. The study also revealed that men in the age range of 15 to 44 years suffered from new knee pain more commonly. Women on the other hand suffered from new knee pain between

ages of 65 to 74 years and suffered more often from knee pain at an age over 75 years than men. (3)

The **Hunt study** in Norway evaluated the one year prevalence of long standing musculoskeletal discomfort at various anatomical regions of the body and found an overall prevalence of 44.6%. The prevalence of knee pain was 12.8%, fourth to shoulder, neck and lower back pain. The prevalence of knee pain increased with age, being highest in the 80 years and above category for both men and women. In a similar study done in Greater Manchester, UK the results were different. The knee ranked second (19%) after the back (23%) in prevalence for pain. Most had pain in multiple areas and physical debility increased with years of life. (4)

A higher burden of knee disease is demonstrated by population-based surveys than studies done in the primary care setting which suggests fewer people with knee discomfort seek medical care.

**Orlando et al** in their prospective cohort study on 61 male and 11 female patients ranging between 17 and 59 years of age determined the accuracy, sensitivity, specificity and concordance of the findings from physical examinations and MRI of the knee, taking arthroscopy as the reference standard. They discovered that MRI showed a sensitivity of 92%, specificity of 74% and accuracy of 83% for MM injuries. MRI showed a sensitivity of 65%, specificity of 88% and accuracy of 82% for LM injuries. For ACL injuries, MRI showed a sensitivity of 87%, specificity of 74% and accuracy of 83%. On the other hand, clinical examination showed a lower sensitivity, specificity and accuracy for MM injuries than MRI. Clinical examination also showed a lower sensitivity but comparable specificity and accuracy for ACL injuries compared to MRI. Good concordance was seen between arthroscopy and MRI for both MM and LM injuries. (5)

**Chandru et al** in their prospective study of 26 male and 4 female patients with a history of knee injuries in the age group of 18-60 years compared and correlated clinical, MRI and arthroscopic findings in ACL and meniscal injuries of the knee. The right knee (19 patients) was more commonly affected than the left knee (11 patients). Domestic fall was the most common mode of injury. The MM injury was more common than LM injury. They found that clinical examination had sensitivity of



91%, specificity of 100%, and accuracy of 93% for ACL, sensitivity of 83%, specificity of 78%, and accuracy of 80% for medial meniscus, and sensitivity of 75%, specificity of 77%, and accuracy of 77% for lateral meniscus. MRI had sensitivity of 95%, specificity of 88%, and accuracy of 93% for ACL, sensitivity of 92%, specificity of 56%, and accuracy of 70% for medial meniscus, and sensitivity of 63%, specificity of 73%, and accuracy of 70% for lateral meniscus. The sensitivity and specificity of clinical examination compared to arthroscopy were 75% and 77%, respectively. They concluded that clinical diagnosis is necessary due to its high PPV for all lesions. MRI is an additional diagnostic exam for ligament and meniscal pathology of the knee. Routine MRI usage to confirm diagnosis is not recommended as the PPV is low but it can be used to exclude pathology since the NPV is high for all the lesions. (6)

**Sindhura et al** in their prospective study of 27 male and 3 female symptomatic patients in the 18-50 years age group evaluated traumatic ACL injuries using 3T MRI with arthroscopy as the gold standard. They found MRI had a higher sensitivity (100% vs 83%) than clinical examination in identifying complete ACL tears. MRI was also found to have a high NPV of 100% for complete ACL tears. Mid-substance tears were found to be the most common site. More males than patients suffered from ACL tears. Highest incidence of ACL tears was found in the 21-30 year age group. (7)

In a meta-analysis by **Smith et al** on the diagnostic efficacy of 3T MRI for meniscal and ACL injuries using arthroscopy as the reference standard and to compare it with a prior meta-analysis that used 1.5T MRI. 13 studies were reviewed. They found that 3T scanners did not have superior diagnostic efficacy for meniscal damage or ACL integrity when compared to 1.5T scanners. (8)

**Puri et al**, in a study involving 30 patients, studied correlation between clinical, MRI and arthroscopic findings of meniscal and ACL injuries. They found that MRI had better sensitivity (95% vs 85%) and specificity (100% vs 50%) in diagnosis of MM injuries compared with clinical examination. There was minimal difference in sensitivity and specificity of MRI and clinical examination for LM and ACL injury. They concluded that correlation between clinical examination, MRI and arthroscopy for meniscal and ACL pathology is important. (9)

**Singh et al**, in their exploratory retrospective study of 26 female and 13 male patients in the 18 to 69 year age group who had arthroscopy, investigated the accuracy of MRI diagnosis of soft tissue knee injury at Steve Biko Academic Hospital, with arthroscopy as the gold standard. They found a NPV, PPV, sensitivity and specificity of 97%, 55%, 83% and 87% respectively for an ACL injury. For a MM injury they found a NPV, PPV, sensitivity and specificity of 81%, 58%, 58% and 81% respectively. A NPV, PPV, sensitivity and specificity of 90%, 55%, 83% and 70% respectively were established for a LM injury. 27 out of the 39 patients were true negative cases for PCL tears. The highest number of false positive injuries were of the LM. Arthroscopy was more accurate in identifying a LM tear than MRI. On the other hand, MRI was more accurate than arthroscopy in identifying an ACL tear. MRI and arthroscopy were comparable in identifying MM tears in this study. They concluded that MRI was sensitive and specific for the ACL especially, and a high NPV for all four (MM, LM, ACL and PCL) structures was in keeping with prior literature and hence negative results can be used to avoid unnecessary surgical intervention to the patient's benefit. (10)

**Gorantla et al** in their cross-sectional study of 19 male and 11 female patients in the 30 to 60 year age group investigated the accuracy of clinical examination, MRI and arthroscopy in identifying internal derangements of the knee, with arthroscopy as the gold standard. MRI was found to be more sensitive (80% vs 73%), accurate (83% vs 82%) and have a high NPV (81% vs 77%) than clinical examination overall. On the other hand, clinical examination had a higher specificity (90% vs 87%) and PPV (88% vs 85%) than MRI overall. The accuracy and NPV of MRI however was significantly lower than international literature. They concluded that MRI was accurate in delineating intraarticular knee pathology but larger samples were needed for better results. (11)

**Gupta et al** in a prospective study of 20 patients in the 11-60 years age group compared MRI and clinical findings in the deranged knee, with arthroscopy as the gold standard. They found that MRI had a sensitivity and NPV of 91% and 96% respectively, for meniscal tear diagnosis. This was higher in contrast to clinical examination that had a sensitivity and NPV of 66% and 86% respectively.

Specificity and PPV of MR and clinical examination for meniscal tears were equivocal. Furthermore, MRI had a higher sensitivity (100% vs 88%) and NPV (100% vs 75%) than clinical examination for ACL tear diagnosis. They concluded that an NPV of 100% for MRI made it a good screening test for ACL tears. If an ACL was normal on MRI it would also be normal on arthroscopy.

Clinical examination on the other hand had a higher specificity (100% vs 50%) and PPV (100% vs 89%) than MRI in identifying ACL tears. They concluded that this high specificity of clinical examination in identifying ACL tears meant that any high clinical suspicion of an ACL tear using the clinical tests would show a corresponding tear on arthroscopy. Diagnostic accuracy for identifying ACL tears was 90% for both MRI and clinical examination in this study. (12)

**Khan et al** in their prospective study of 26 participants also explored the diagnostic capacity of clinical evaluation, 1.5T MRI and arthroscopy in traumatic meniscal and cruciate ligament injury, with arthroscopy as the gold standard. Overall, clinical examination was more sensitive (80% vs 74%) than MRI. MRI however was more specific (93% vs 86%) and accurate (84% vs 63%) than clinical examination in identifying internal knee derangements. Clinical examination had a higher NPV (93%) than MRI (88%). They concluded that both NPV and accuracy of MRI were lower compared to other studies due to a smaller patient number and operator dependence of arthroscopy. They also concluded that routine pre-operative use of MRI is not recommended even though it is the non-invasive examination of choice. It should be used as a screening investigation in patients with unclear indications for arthroscopic surgery. (13)

**Krakowski et al** in their study consisting of 49 female and 47 male patients with a mean age of 45 years who had previously qualified for knee arthroscopy, evaluated the diagnostic accuracy of clinical examination and 1.5T MRI in knee injuries. They discovered that clinical examination had a lower sensitivity (60-87% vs 96%) and higher specificity (52-75% vs 52%) than MRI for MM injuries. MRI and clinical examinations were found to be of comparable sensitivities and specificities for LM injury. For identifying ACL tears, MRI had a sensitivity of 75% which was comparable to clinical examination. MRI and clinical examination also had comparable specificities in detecting ACL tears. They concluded that MRI was more

accurate than clinical examination, in MM and LM injury identification but it was statistically insignificant. Thus, MRI should be used as an additional study to assess size of the meniscal pathology rather than for plain diagnosis. They also discovered that MRI is less accurate than clinical examination for identification of ACL injury. They suggested that patients should undergo MRI to answer particular questions about morphology of the lesion before surgery, rather than to confirm diagnosis. (14)

In a systematic review of relevant studies by **Crawford et al** that compared MRI and arthroscopy in the diagnosis of ACL tears, meniscal lesions and other pathology an accuracy, sensitivity, specificity, NPV and PPV of 86%, 91%, 81%, 83% and 90% respectively were found for diagnosing medial meniscal tears alone using MRI with arthroscopy as gold standard. An accuracy, sensitivity, specificity, NPV and PPV of 89%, 76%, 93%, 80% and 92% respectively were found for diagnosing lateral meniscus tears alone using MRI with arthroscopy as gold standard. Furthermore, in studies that investigated cases having all the three findings of MM, LM and ACL tears together an accuracy, sensitivity, specificity, NPV and PPV of 89%, 86%, 91%, 82% and 93% respectively were seen. They concluded that MRI is better at identifying patients having a medial meniscus tear than patients without a tear. Furthermore, they also concluded that MRI is marginally better at identifying patients without lateral meniscus tears than those with them. Overall, they established MRI displays a higher specificity (93%) than sensitivity (83%) and a higher NPV (92%) than PPV (84%). Diagnosis of chronic PCL injuries in different patients using MRI was not reproducible by different radiologists, a noticeable disadvantage of MRI. (15)

**Dave et al** in their multi-centre cross-sectional study of 146 patients in the age range of 18 to 45 years investigated the accuracy of clinical examination and 3T MRI in identifying intraarticular knee pathology compared to arthroscopy. They found that MRI had a sensitivity, specificity, PPV and NPV and accuracy of 79%, 79%, 77%, 81% and 47% respectively for a MM tear. A sensitivity, specificity, PPV, NPV and accuracy of 60%, 74%, 65%, 78% and 41% respectively were established for a LM tear using MRI. A higher MRI sensitivity (52% vs 17%) and PPV (55% vs 6%) were established for a complete ACL tear compared to a partial ACL injury while a higher NPV (96% vs 86%) was established for an incomplete ACL injury compared to a complete ACL tear. Comparable MRI specificities were established for a complete

and incomplete ACL tear (88% vs 89%). In the case of PCL tears, MRI had a higher sensitivity (63% vs 0%) comparable specificity (100% vs 99%) and lower missed diagnosis rate (38% vs 100%) for complete PCL tears compared to incomplete PCL injury. They also found that LM tears were more common than MM tears and that the posterior horn was the most frequent area to bear the brunt of injury in the menisci. The accuracy of MRI in depicting ACL tears was significantly lower in this study compared to the systematic review by Crawford et al and 3T MRI did not improve the accuracy. Clinical tests and MRI reports were found to be of equal accuracy in diagnosis of meniscal injury while clinical tests were more accurate than MRI for diagnosis of ACL and PCL injuries. (16)

**Smet et al** reviewed MRI reports and surgical records of 400 patients who had undergone both MRI examination and arthroscopy of the knee. They analyzed whether the presence of an ACL tear affected the sensitivity of detecting meniscal tears. They discovered that in the presence of an ACL tear, the sensitivity of detecting a MM tear dropped from 97% to 88%, and dropped from 94% to 69% for LM tears. They also noted that the overall sensitivity for LM tears was considerably less for posterior and peripheral tears than other tear sites and patterns. (17)

**Bonadio et al** in a prospective study of 28 male and 5 female patients in the 18 to 59 year age range evaluated the correlation between 1.5T MRI, clinical examination and intraoperative findings of PLC knee injuries. They found that on correlation of findings of clinical examination under anesthesia and intraoperative findings with MRI, a sensitivity of 100%, 87%, 58% and 24% for ACL, PCL, LCL and PMT lesions respectively were obtained. They concluded that PLC injury is difficult to visualize and interpret, and MRI should not be utilized alone for diagnosis. (18)

**Vallotton et al** in a blind and prospective study of 33 patients in the age range of 18-50 years compared MRI and arthroscopy of the knee in the diagnosis of patellar cartilage lesions. They found that the overall MRI sensitivity and specificity were 85% and 97%, respectively. The PPV, NPV and accuracy of MRI were 96%, 89% and 92% respectively. They did not find any significant difference between MRI and arthroscopy. (19)

**Drew et al** reviewed published literature from 27 research papers that assessed MRI, MRA and CT for the detection of chondral lesions of the knee. Overall, the specificity of the radiological measurements was higher than their sensitivities for identification of both tibiofemoral and patellofemoral articular cartilage lesions. The meta-analysis pooled by this study indicated that MRA and CTA were superior in detection of the PFJ chondral lesions compared with MRI. From the pooled meta-analysis MRA had a sensitivity of 70% and specificity of 99%. Sensitivity and specificity of CTA were 80% and 99% respectively. MRI had a sensitivity and specificity of 74% and 95%, respectively. MRI had a better diagnostic accuracy for detection of TFJ over PFJ chondral lesions. Sensitivity and specificity of MRI for detection of TFJ lesions was 88% and 82% respectively, while the sensitivity and specificity of MRI for detection of PFJ lesions was 74% and 95%, respectively. Unfortunately, there was inadequate data to compare the diagnostic precision of all three examinations for TFJ chondral lesions. (20)

**Figueroa et al** in their prospective study of 116 male and 74 female patients in the age range of 14 to 79 years evaluated the incidence and correlation between MR and arthroscopic findings of knee joint chondral lesions. They found that only 82 out of the 190 knees had at least one chondral lesion during arthroscopic surgery, 42 of them were male while 40 were female. There was a predilection for the MFC (32%), medial articular surface of the patellae (23%) and LFC (14.8%). On comparison of MRI and arthroscopic findings in the 82 patients, MRI showed a sensitivity and specificity of 45% and 100%, respectively in detecting chondral lesions, and the best accuracy with patellar defects. They concluded that higher magnetic field strengths can increase the MRI diagnostic yield for chondral lesions of the knee. (21)

### **1.3 ANATOMY OF THE KNEE JOINT**

The knee constitutes three bones (tibia, femur and patella) and is a complicated synovial hinge joint encompassing multiple individual joints or articular compartments namely: patellofemoral, medial femorotibial and lateral femorotibial. (1).

The articular surfaces of the knee joint are the deep surface of patella, the patellar (trochlear) surface on the distal femur, femoral condyles and the tibial condyles. Multiple ligaments, muscles and tendons help to support the knee joint. (1) (22)

The major ligaments that offer support to the joint include: (1) (22) (23) (24)

- i) The fibrous capsule
- ii) Medial collateral ligament (MCL)
- iii) Lateral collateral ligament (LCL)
- iv) Anterior cruciate ligament (ACL)
- v) Posterior cruciate ligament (PCL)
- vi) Medial meniscus (MM)
- vii) Lateral meniscus (LM)
- viii) Patellar ligament

The muscles and tendons that help support the joint include:

- i) The quadriceps femoris muscle and tendon
- ii) Hamstring muscles (semimembranosus, semitendinosus and biceps femoris)
- iii) Popliteus muscle and its tendon

The fibrous capsule is thin and deficient anteriorly where it is substituted by the quadriceps femoris, the patella and patellar ligament. The capsule attachment posteriorly is to the intercondylar line and intercondylar ridge of the femur and tibia, respectively. A gap exists in the posterolateral part of the capsule for the popliteus tendon to pass. (1) (22) (23) (24)

The menisci, also sometimes called the semilunar cartilages, are C-shaped fibrocartilaginous discs that are interposed between the distal femur and proximal tibial articular surfaces. They are divided into three parts: a smaller anterior horn, central body and a larger posterior horn. They function to increase the congruency of the tibial and femoral articular surfaces, lubricate the joint and act as shock absorbers. The MM is nearly semicircular and thicker behind than in front, while the LM is nearly circular and uniform in thickness from front to back. (1) (22) (23) (24)

The menisci appear uniformly hypointense on all MRI sequences. The anterior and posterior horns of the LM appear almost the same size on sagittal projections while the posterior horn of the MM is almost two-fold the size of the anterior horn.

Depending on whether the plane of imaging is through body or horn, the menisci appear triangular or wedge shaped, respectively on coronal projections.

Several anatomical variants of the menisci exist that can be mistaken for pathology such as the discoid meniscus and meniscal flounce. (1) (22) (23) (24)

The cruciate ligaments are crucial for anteroposterior stability and movement of the knee joint. The ACL and PCL prevent anterior and posterior translation of tibia on the femur, respectively. They are strong thick ligamentous bands that are named according to their attachments on the tibia.

The ACL runs from the intercondylar notch on tibia anteriorly and attaches to the medial part of the LFC. The ACL has two bands namely the AMB and the PLB identifiable on MRI. The PCL also has two bands, the ALB and PMB and runs from a depression on the posterior margin of the tibial plateau and attaches to the medial part of the MFC.

The ACL is best seen on sagittal and coronal projections. It appears as a non-uniform signal intensity straight tense band with multiple striations that runs parallel to the roof of the intercondylar notch on sagittal projections. The PCL, in contrast, appears as a uniform low signal intensity band lacking the striations of the ACL.

The MCL is the most important and strongest supporting structure of the knee present along the medial surface. Superiorly it is attached to the medial epicondyle of the femur just below the adductor tubercle and inferiorly divides into a superficial and deep part, that both attach to the medial surface of the tibia. The MCL is best seen on a single coronal section as a well-defined, thin, tense, linear band that is uniformly low signal on all MRI sequences. The LCL extends from the lateral epicondyle of the femur superiorly, and together with the BFT, attaches inferiorly to the head of the fibula. The LCL, ITB and BFT together are called the LCL complex. The LCL is also hypointense on all MRI sequences. (1) (22) (23) (24)

The extensor mechanism of the knee is responsible for extension of the knee. It is composed of the quadriceps femoris muscle group, QFT, the patella and the patellar tendon. Injury to any component will impair the extensor function. The quadriceps femoris muscle consists of four muscle heads: vastus lateralis, vastus medialis, rectus femoris and vastus intermedius.



The quadriceps femoris muscle attaches to the base of the patella with the help of its tendon, the QFT. The QFT on MRI appears as a straight hypointense band on both sagittal and coronal images. It features a striated configuration on the sagittal plane due to fat intermingled between the four muscle groups.

The patellar tendon (or ligament) is attached to the inferior pole of the patella and extends to the tibial tubercle. It is best seen on sagittal plane as a relatively homogenous hypointense band on all sequences. (1) (22) (23) (24)

The major structures of the posterolateral corner (PLC) of the knee joint are the LCL already mentioned previously, the popliteus tendon, the lateral head of gastrocnemius muscle and BFT. Other entities include the arcuate and popliteofibular ligaments. When the fabella is present an additional entity may be present, the fabellofibular ligament. The LCL and popliteus tendon are the only structures that are constantly identifiable on MRI while the others are extremely variable. These structures function in unison to maintain the stability of the PLC.

The popliteus muscle arises from the upper tibia posteromedially forming a tendon that proceeds into the joint through the popliteal tunnel to insert onto the LFC, posterior horn of LM and head of fibula. The popliteus tendon is a dynamic stabilizer which is normally seen as hypointense or isointense in signal on axial and coronal planes, respectively. An unrecognized PLC injury can be a cause of failed cruciate ligament reconstruction. It can also lead to chronic instability of the knee. (1) (22) (23) (24)

The posteromedial corner (PMC) consists of only the semimembranosus tendon and posterior oblique ligament (POL). The POL is formed by the condensation of superficial and deep portions of the MCL.

The articular cartilage over the femoral condyles, tibial plateau, trochlear process of femur and deep surface of patella on MRI should normally appear smooth and homogenous. It appears less hyperintense than joint fluid on fsPDW and isointense on PDW images. It usually has a graded appearance with deeper layers appearing darker than superficial layers.

Numerous fat pads are present around the knee. They represent collections of encapsulated adipose tissue that function to cushion forces generated across the joint. The major ones include the infrapatellar (Hoffa's), suprapatellar (quadriceps) and prefemoral fat pads. (1) (22) (23) (24)

As many as twelve bursae are present in and around the knee. Four anterior, four lateral and four medial. They are synovial lined and synovial fluid filled structures that reduce friction and ease motion between adjacent moving structures. They appear as low signal on T1W images and high signal on T2W images.

## **1.4 IMAGING MODALITIES OF THE KNEE**

### **1.4.1 MAGNETIC RESONANCE IMAGING**

Multiplanar MRI is the modality of choice for investigating injuries to the menisci, ligaments and tendons as well as occult fractures and bone bruises in the knee. MRI offers superior anatomical and pathological definition of soft tissues, ligaments, articular cartilage and fibrocartilage. (25)

With the advent of FSE and fat suppression techniques, the sensitivity and specificity of MRI in the discovery of meniscal and cruciate as well as articular cartilage injuries has been improved significantly. It has emerged as the cross-sectional imaging of choice for accurately depicting the bony comminution, displacement and depression seen in tibial plateau fractures. (25)

Development of new sequences, greater spatial resolution, shorter imaging times, higher SNR and reduced artifacts has further revolutionized MR imaging of the knee. MRI has made looking into the injured knee noninvasively possible and hence avoids invasive procedures and further morbidity. In addition, it represents a radiation free technique. (24) (25)

In most centres MRI has replaced diagnostic arthroscopy and arthrography. Sensitivity of MRI in diagnosing knee pathology is 80-100% (25). Magnetic field strengths of 1.5T or 3T can be used to image the knee. 3T offers a better signal to noise ratio (SNR) as well as better spatial and temporal resolution, than 1.5T MRI scanners (26). There is increased sensitivity and better grading of articular cartilage

damage with higher field strength of 3T (27). MRI is also a more sensitive imaging modality for early osteoarthritic changes.

3T scanners offer superior subjective visualization of the menisci and ligaments of the knee. Furthermore, it outperforms 1.5T scanners as far as diagnosis of horizontal and unstable tears of the medial meniscus are concerned. Anterior cruciate ligament (ACL) lesions are significantly better picked with greater diagnostic confidence using 3T machines.

3T scanners can shorten scan times without compromising on the accuracy of images, enabling management of high patient volumes without image quality compromise.

1.5T scanners on the other hand can reduce scan times but at the cost of decreased image quality. (27)

#### **1.4.2 ULTRASOUND**

It is a non-invasive imaging tool which can provide useful information on multiple pathology affecting components of the knee joint such as the ligaments, tendons, muscles, articular cartilage, synovial space and surrounding soft tissues. Furthermore, spectral and power doppler modes are at the operator's disposal for measurement of abnormal new blood vessel formation within the synovium lining of joints, tendons and soft tissue masses. Knee joint ultrasound is performed with a high frequency linear array transducer of high frequency (12 MHz), but a lower frequency (7-9 MHz) is sometimes better for posterior structures. The patient lies supine on a flat examination couch with both their knees exposed. (28)

Advantages of ultrasound are its low cost, dynamic real-time assessment, portability, alternative to MRI or CT for claustrophobic patients, higher spatial resolution than MRI ideal for superficial structure evaluation, offers dynamic assessment especially useful for superficial tendon tears and easy comparison with contralateral knee. Its disadvantages are that it is highly operator dependent requiring training and experience and it offers incomplete visualization of deep knee structures such as the cruciate ligaments, menisci and most of the articular cartilage. (28)

Ultrasonography of the knee is dismal in the diagnosis of deep bone, intramedullary pathology and bone marrow oedema as ultrasound waves are absorbed by bone and are also unable to penetrate bone. Furthermore, due to this reason the internal deeper

anatomy of the knee cannot be appreciated by ultrasonography (29). Ultrasound can visualize various injuries in the peripheral meniscus and superficial bone, but MRI is more sensitive for detecting meniscal pathology. Knee ultrasound can be used for evaluation of joint effusion and synovial inflammation. It also visualizes normal and abnormal fluid collections around the joint well. It does well in evaluating of superficial tendons such as the quadriceps, patellar, pes anserine and hamstring tendons. (28)

#### **1.4.3 PLAIN RADIOGRAPHY**

Xray is the first imaging modality of the knee that is frequently requested for by clinicians especially in the setting of trauma. It is commonly available and of low cost. (30)

It visualizes the bony components fairly well and hence fares well in bringing out bony pathology. Although sensitivity of plain radiography is high for identifying superficial fractures such as the patella and distal femur, it is rather low for femoral and tibial plateau fractures. Furthermore, sensitivity is also low in identifying two or three simultaneous fractures in the knee. (30)

Knee radiography is unable to view the intricate soft tissue structures within and around the knee such as ligaments, cartilage, menisci, tendons and muscles which are often injured in addition to bone fractures. (31)

Two standard projections that are taken routinely are the antero-posterior (AP) and lateral projections. The AP projection is usually taken in the standing position while weight bearing. Other alternative (special) projections exist which can be used in certain circumstances such as to delineate particular areas of the knee better such as the skyline view which visualizes the PFJ space much better or the tunnel view (intercondylar notch view) which demonstrates loose bodies within the knee joint better. (32)

In the setting of major trauma positioning of the patient is extremely challenging and fractures may be missed. In such cases CT scan is preferred. (30)

#### **1.4.4 COMPUTED TOMOGRAPHY**

As far as the knee is concerned, Computed tomography (CT) does very well in the acute setting in fracture delineation, in equivocal knee radiographs where an occult

fracture was not visualized or where a high clinical suspicion of a fracture still remains despite a normal radiograph of the knee (33).

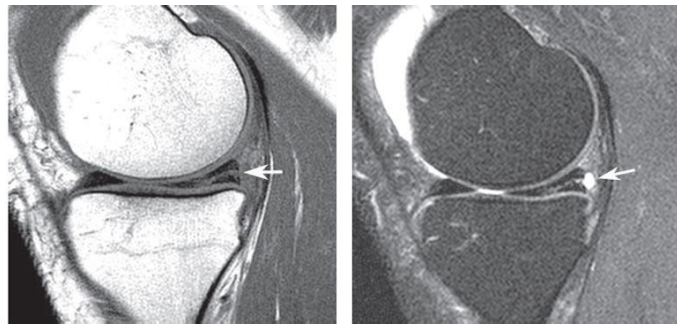
CT is recommended as a complimentary investigative modality to plain radiography in patients suspected of having tibial plateau fractures, complex injuries and multiple trauma. (30)

Although CT in the acute period has a high sensitivity and specificity for identifying bony avulsions and a high NPV for exclusion of ligamentous injury, it is unable to aptly visualize the soft tissue structures within the knee and MR imaging remains necessary. An additional limitation of plain radiography and CT imaging is harmful radiation. (33)

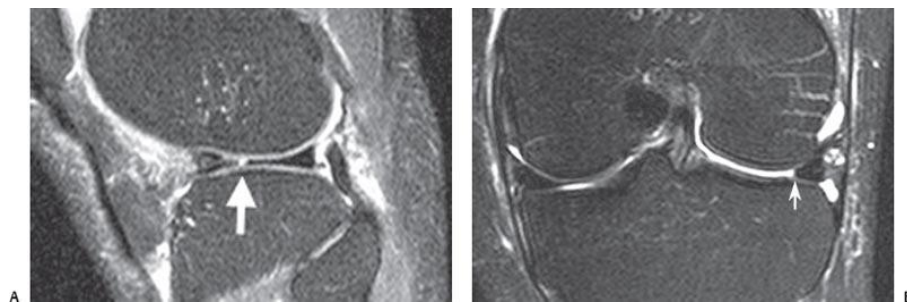
### 1.5 PATHOLOGY OF THE KNEE AS SEEN ON MRI

Knee pathology and causes of knee pain can arise due to affliction of the menisci, ligaments, articular cartilage, bony structures, soft tissues, infections, tumors or as referred pain from adjacent structures.

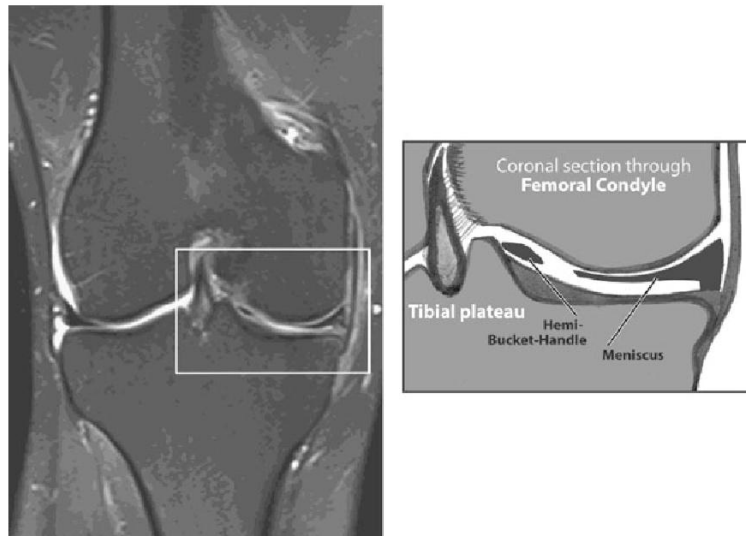
**Menisci pathology:** Majority are tears, which can be of basic or displaced types. (34) (35) (36) (37) (38)



*Figure 4: Sagittal T1W (A) and T2W FS (B) images demonstrating a horizontal meniscal tear (arrows) through the medial meniscus. Note that it is parallel to the tibial plateau.*

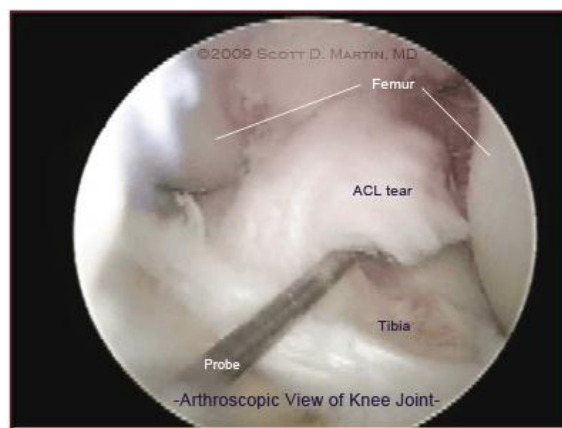

*Figure 5: Sagittal (A) and coronal (B) T2W FS MR images demonstrating a radial type tear in the lateral meniscus (arrows)*

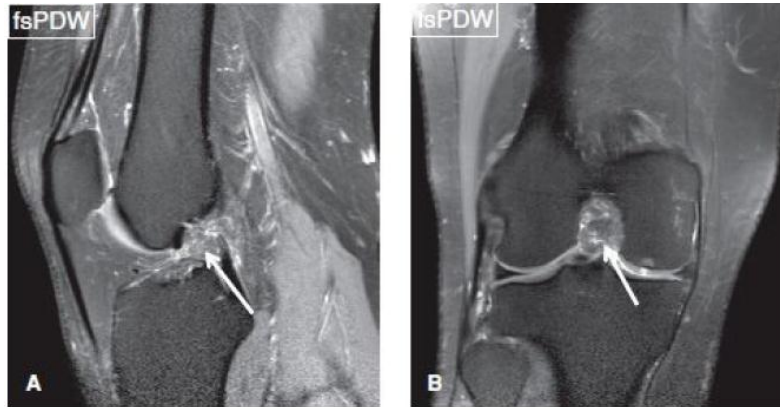


*Figure 6: Coronal T2W FS image demonstrating a bucket handle tear of the meniscus*

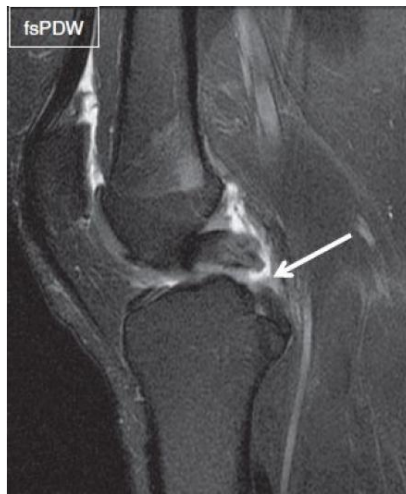**Ligaments:** Various injuries to the knee ligaments can cause pain in the knee, majority of which are either strains, partial tears or complete tears. Each of these have their characteristic imaging appearances on MRI. Strains have oedema around the ligament which appears as high signal on T2 FS MRI surrounding the affected ligament. A partial tear will appear as increased intraligamentous signal or partial discontinuity while complete tear will be seen as total discontinuity or complete lack of visualization of the affected ligament on multiple planes. (39) (40) (41) (42) (43) (44) (45) (46) (47) (48)



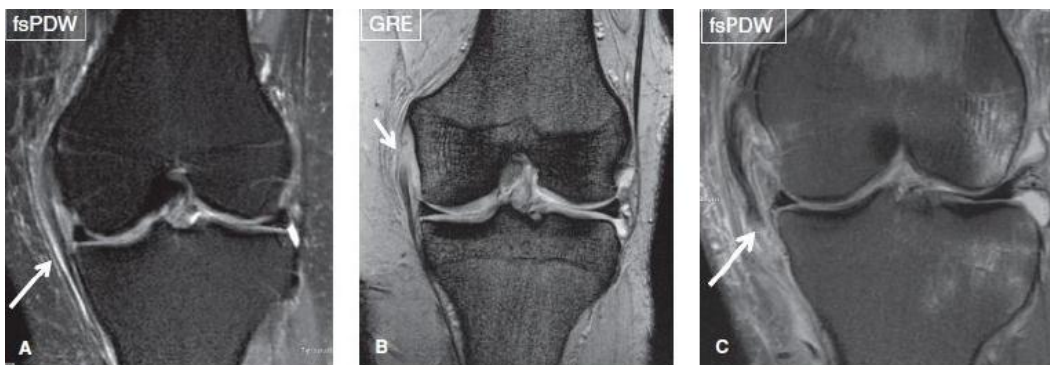
*Figure 7: Arthroscopic view of ACL tear*



*Figure 8:ACL disruption and nonvisualization. On sagittal (A) and coronal (B) images the ACL cannot be visualized in its normal anatomical location (arrows). There is also irregular soft tissue due to hemorrhage.*



*Figure 9: Complete PCL tear*



*Figure 10: Coronal MRI Images demonstrating a grade I (A) grade II (B) and grade III (C) sprain of the MCL (arrows).*

**Articular cartilage:** A variety of lesions in the articular cartilage of the knee can result in knee pain. It is greatly destroyed by osteoarthritis of the knee. (41) (49) (50)

**Bony structures:** Degenerative changes in the tibial, femoral and patellar articular surfaces will cause significant debility. The knee joint is amongst the most common joints to be affected by primary osteoarthritis, and is the most common joint disease in the elderly population. (41)

**Soft tissues:** This is an umbrella term referring to the muscles, tendons, synovial lining, joint capsule, blood vessels and nerves. Any insult to these structures can be a significant source of a visit for imaging due to pain or impaired knee function. (41)

**Infectious pathology:**

Septic arthritis - Commonly affects large joints such as the knee, hip and shoulder joints. This entity is commonly seen in the elderly, immunocompromised state, injection into the joint and prosthetic joints. If not recognized and treated, it results in irreversible joint damage within 48 hours of infection onset. Imaging is more of an adjunct to aspiration of the joint synovial fluid for diagnosis. When synovial fluid cannot be obtained, imaging is an important diagnostic tool. However, imaging such as ultrasound can be used in guiding retrieval of synovial fluid from the joint as it is quite superficial. (51) (52)

**Inflammatory lesions:** Several such conditions can affect the knee such as synovial osteochondromatosis, gout, pseudogout, neuropathic arthropathy, foreign body synovitis, rheumatoid arthritis, haemophilic arthropathy and amyloid arthropathy. (53)

**Tumors:** These either originate from structures in the knee joint or are deposits from other sites in the body called metastatic lesions. The tumors may be benign such as cysts, lipomas, osteoid osteoma, osteblastoma, cortical desmoid, fibrous cortical defect, non-ossifying fibroma, chondroblastoma, enchondroma, osteochondroma, aneurysmal bone cyst and giant cell tumor. Malignant tumors include osteosarcoma, Ewing sarcoma, multiple myeloma, synovial sarcoma, chondrosarcoma, lymphoma, metastasis and others. It is important to correlate the MRI findings with the x-ray films whenever available. (41)

**Referred pain:** Affliction of surrounding structures can result in knee pain. These include the lumbar spine, hip, ITB, ankle or feet. (41)



## **CHAPTER TWO**

### **2.1 STUDY JUSTIFICATION**

No such study has been undertaken locally with a 3T MRI machine. 3T MRI offers superior anatomical detail compared to a 1.5T MRI machine owing to better soft tissue contrast. 3T offers a better signal to noise ratio (SNR) as well as better spatial and temporal resolution, than 1.5T MRI scanners. 3T scanners offer superior subjective visualization of the menisci and ligaments of the knee. A higher sensitivity and better depiction of the articular cartilage damage grades is seen with 3T than 1.5T. Furthermore, it outperforms 1.5T scanners as far as diagnosis of horizontal and unstable tears of the medial meniscus are concerned. Anterior cruciate ligament (ACL) lesions are significantly better picked with greater diagnostic confidence using 3T machines.

3T can shorten scan times without compromising on the accuracy of images, enabling management of high patient volumes without image quality compromise. 1.5T scanners on the other hand can reduce scan times but at the cost of decreased image quality.

### **2.2 STUDY QUESTION**

What are the spectrum and patterns of adult knee pathology on Magnetic Resonance Imaging (MRI) at the Radiology Department of Kenyatta National Hospital?

### **2.3 STUDY SIGNIFICANCE**

This study will strive to show that MRI is indeed the gold standard non-invasive imaging modality to delineate the anatomy and pathology related to the knee joint. Since the only data available in our setting is a study by Thiga et al in 2008 using a 1.5T MRI, this study intends to make use of the new technological advances of 3T MR imaging to better appreciate these injuries without the need for invasive arthroscopy.

### **2.4 STUDY OBJECTIVES**

#### **2.4.1 BROAD OBJECTIVE**

To ascertain the spectrum and patterns of pathology affecting structures in the knee joint, in adult patients undergoing MRI examinations using a 3T MRI scanner at the Radiology Department of Kenyatta National Hospital.

#### **2.4.2 SPECIFIC OBJECTIVES**

1. To determine the spectrum and patterns of pathology affecting knee joint structures.
2. To determine the grade of pathology where applicable.

## **CHAPTER THREE**

### **3.1 STUDY DESIGN AND METHODOLOGY**

#### **3.1.1 STUDY DESIGN**

This was a descriptive prospective study of MRI knee examinations that was conducted at the Department of Radiology, Kenyatta National Hospital (KNH)

#### **3.1.2 STUDY AREA DESCRIPTION**

MRI unit in the Department of Radiology of Kenyatta National Hospital, the major tertiary referral hospital located in Nairobi County, the capital city of Kenya. KNH in addition is a teaching hospital for undergraduate and postgraduate medical students as well as other cadres of health. It mainly serves Nairobi, Central and Eastern parts of Kenya.

There are approximately 10-15 knee MRI exams that are done per month at the MRI unit of the KNH Department of Radiology.

#### **3.1.3 STUDY POPULATION**

The study population comprised patients who were referred for MRI evaluation of the knee at the Magnetic Resonance Imaging (MRI) unit of the Department of Radiology at Kenyatta National Hospital (KNH).

#### **3.1.4 SAMPLING METHOD**

Consecutive sampling was chosen for this study where patients meeting the inclusion criteria referred for an MRI scan of the knee were included in the study until the appropriate sample size was attained.

#### **3.1.5 INCLUSION CRITERIA**

1. Patients referred by the clinician for an MRI knee study
2. Patients with MRI data that is of good imaging quality for making a diagnosis
3. Patients above the age of 19 years
4. Patients who consent to being included in the study.

#### **3.1.6 EXCLUSION CRITERIA**

1. Patients with a contraindication to MR Imaging.
2. Patients with poor quality MRI data that is not significant enough to make a diagnosis.
3. Patients with a history of knee surgery e.g prosthesis, ACL reconstruction.
4. Patients who don't consent to being included in the study.

### 3.1.7 SAMPLE SIZE DETERMINATION

A representative sample size for this descriptive study was calculated using Fisher's formula which is the recommended formula for most descriptive research studies. It however is used for large populations i.e. 10,000 and above:

$$n_o = \frac{Z^2 \times p(1 - p)}{e^2}$$

**Where:**

(Cochran 1963)

$n_o$  = Sample size

Z = z-score associated with a level of confidence

p = Sample proportion expressed as a decimal

e = Margin of error (level of precision) expressed as a decimal

Factoring in a 95% confidence interval, z-score of 1.96, sample proportion p=0.5 and margin of error of 0.05 the representative sample size,  $n_o$  is 385.

The modification for Cochran formula of sample size calculation in smaller finite populations is:

$$n_f = \frac{n_o}{1 + \frac{(n_o - 1)}{N}}$$

**Where:**

$n_o$  = Cochran's sample size recommendation from above formula, 385

N = target population size, 60

$n_f$  = New adjusted sample size

Factoring in all the values the new adjusted sample size is 52.

To cater for patients dropping out during the study for various reasons, an attrition rate of 15% will be factored in bringing the final representative sample size,  $n_o$  to 61.

### 3.1.8 STUDY PROCEDURES

Patients who qualified for inclusion in the study were screened for safety and their verbal and written informed consent obtained using the safety questionnaire and consent forms provided.

The weight of the patient was noted. After explaining the procedure to the patients and instructing them to keep still within the scanner, were they then investigated using the Ingenia Elition 3.0T Philips MRI system at KNH. The acquired images were thereafter processed, analyzed and reviewed by the principal investigator and two

consultant radiologists. All processed images were recorded and stored on an external hard drive. The principal investigator prepared MRI reports for the patients, which were then verified by the supervising radiologists that possess over ten years of experience. Thereafter the reports were finalized. PACS archived MR images where possible and non-PACS MR images were used to record and analyze the imaging findings.

Important to note is that patients were not being followed up during the study.

### **3.1.9 DATA COLLECTION PROCEDURES**

The data collected included informed written consent using the written MRI Safety questionnaire and consent form (Appendix A) duly filled for each patient who agreed to be included in the study. Patient particulars including participant number, age, gender, relevant clinical history and indication for MRI study, date of MRI study and MRI findings and any remarks were also obtained using the data collection form shown.

### **3.1.10 MATERIALS AND EQUIPMENT**

MRI knee images were acquired by the Ingenia Elition 3.0T Philips MRI scanner at KNH MRI suite.

A standard knee MR Imaging protocol which included but was not limited to the following basic sequences, was used to obtain the diagnostic images. The basic sequences and their parameters included:

- 1) 3 plane localizer- taken in the beginning to localize and plan the sequences. Are T1 weighted low resolution scans. The coronal plane was used to plan the axial slices, while the axial plane was used to plan both sagittal and coronal slices.
- 2) PD axial 3mm slices
- 3) PD sagittal 3mm slices
- 4) PD FS axial 3mm slices
- 5) PD FS coronal 3mm slices
- 6) PD FS sagittal 3mm slices
- 7) T1 TSE coronal 3mm slices
- 8) T2 STIR sagittal 3mm slices

A dedicated knee coil was used to scan the knee in question with patient placed feet first supine. The knee was immobilized with cushions. Cushions were also placed

under the ankle for added comfort. The laser beam localizer was then centered over the lower border of the patella. The 3-plane localizer was then acquired to plan the different sequence planes as mentioned above. A FOV of 140-170mm, 3mm slice thickness and matrix of 256x256 pixels were used.

#### **3.1.11 STUDY PERSONNEL**

- The principal investigator
- Trained radiographers
- Consultant radiologists to validate reports
- Biostatistician

#### **3.1.12 DATA COLLECTION TOOL**

A structured data collection form (Appendix D) was completed by the principal investigator or radiographers present at the time of examination. The data collection tool is provided in Appendix C.

#### **3.1.13 DATA HANDLING**

The questionnaires were sorted at Kenyatta National Hospital. The filled questionnaires were stored under lock and key with the principal investigator during data collection and entry and later moved for safekeeping at an offsite location. Data were entered into a password protected excel sheet. Once entry was completed, the principal investigator compared the contents of the spreadsheet with the hard copy results to identify and correct any data input errors.

#### **3.1.14 ETHICAL CONSIDERATIONS**

- The research proposal was submitted to KNH/UON Research and Ethics committee for review and approval prior to commencement of the study.
- Institutional approval was obtained from the University of Nairobi and KNH.
- A signed informed consent was obtained from the patients before inclusion into the study population.
- The patient's name was not included in the study to maintain confidentiality. The information acquired will not be used for any other purposes other than the study.
- Confidentiality was maintained at all times during the study.

### **3.1.15 CONFIDENTIALITY OF PATIENTS**

The principal investigator ensured no identifiers were present that could link the research data to the study participants. Each study patient was allocated a unique participant identification number in data abstraction tool and database.

### **3.1.16 CONFIDENTIALITY OF DATA OBTAINED**

Restricted access to patient data was maintained at all times.

No unauthorized person was allowed access to patient records.

All electronic databases were password protected.

All the records were stored in a locked cabinet.

### **3.1.17 BENEFICENCE/MALEFICENCE**

The findings of this study will be published to improve the management of patients through enhancing knowledge of general radiologists and musculoskeletal radiologists. All patients were protected from any physical, social or economic harm.

### **3.1.18 DATA MANAGEMENT AND STATISTICAL ANALYSIS**

MRI knee images were reviewed by the principal investigator and two consultant radiologists to determine the injuries in each patient.

Data was recorded in the data collection form as shown in Appendix D. Multivariate data analysis was carried out with the assistance of a biostatistician. Statistical Package for Social scientists (SPSS Version 24 IBM) was used.

Analysis of patients' demographic data was conducted using descriptive characteristics. Data analysis included calculation of percentages of the different findings and pathologies seen in the knee. Comparison was made between the male and female participants.

### **3.1.19 DISSEMINATION OF RESULTS**

The findings of this study will be disseminated through the Department of Diagnostic Imaging and Radiation Medicine, University of Nairobi Library and University of Nairobi board of postgraduate studies.



## CHAPTER FOUR: RESULTS

### 4.1 AGE AND GENDER CHARACTERISTICS

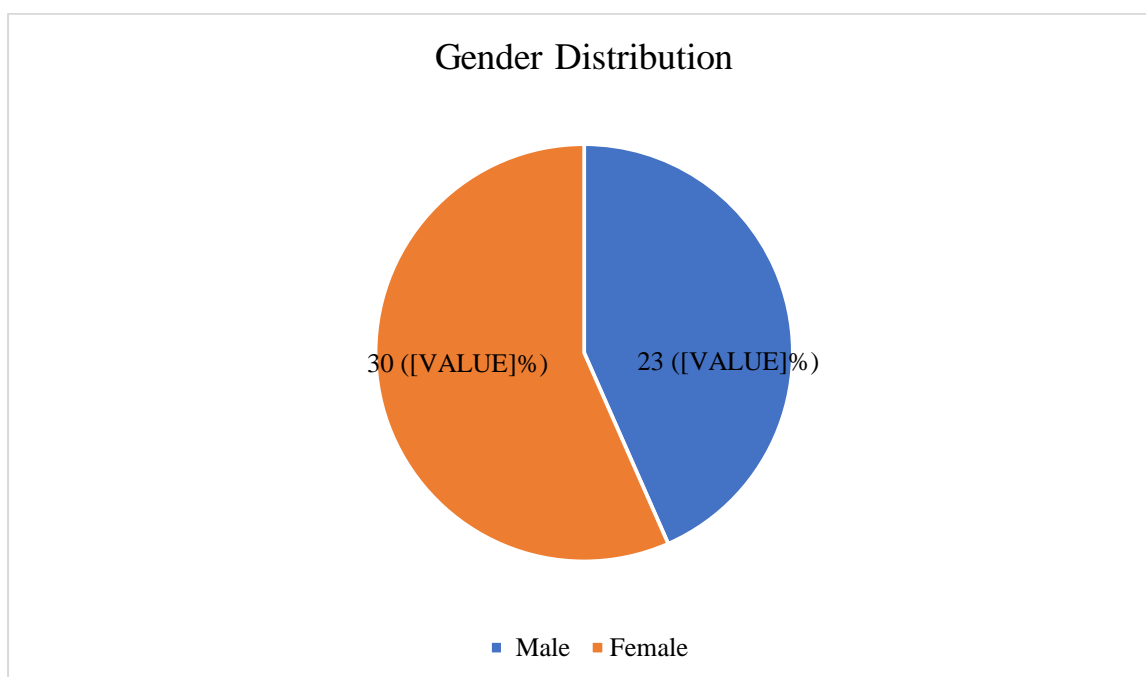
MRI images of 53 patients were included in this study. The mean age of the sample was 38.2 years (SD  $\pm$  12.3) with a range between 19 and 61 years. The median age was 37 years. The study results indicate there were 30 (56.6%) female patients, and 23 (43.4%) male patients with a male to female ratio of 1:1.3. Majority of the patients were between the ages of 19-29 (28.3%) years and 40-49 (28.3%) years. The most common cause of injury was due to trauma (31, 83.8%). The characteristics are as shown in Table 1 and Figure 11.

**Table 1: Characteristics of the patients**

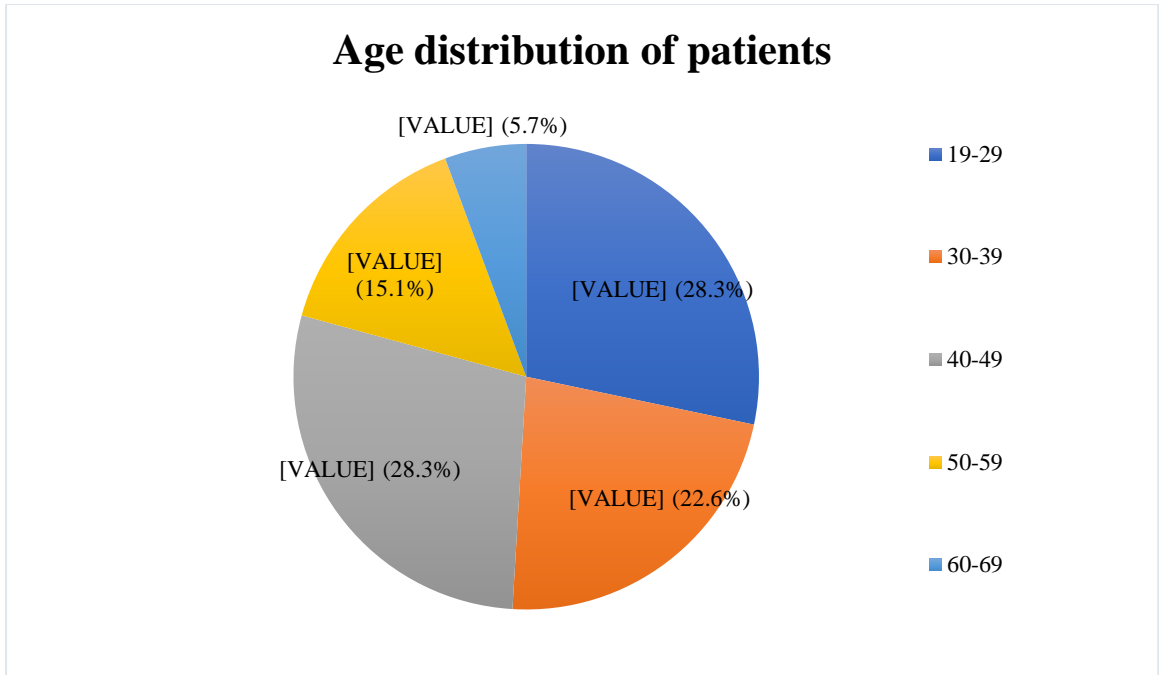
Gender	Frequency (n=53)	Percentage
Male	23	43.4
Female	30	56.6

Age	Frequency (n=53)	Percentage
19-29	15	28.3
30-39	12	22.6
40-49	15	28.3
50-59	8	15.1
60-69	3	5.7



*Figure 11: Gender distribution of sample*



*Figure 12: Age distribution of sample*

#### 4.2 CLINICAL PRESENTATION AND DURATION

The most common indication (clinical presentation) was knee pain in 51 patients (96%). 5 patients (9.4%) presented with knee pain and knee swelling, 3 patients (5.7%) presented with knee pain and reduced range of movement, 2 patients (3.8%) presented with knee swelling and a further 2 patients (3.8%) had knee pain and weakness. (Table 2)

37 patients (69.8%) had symptoms for more than two weeks while 16 patients (30.2%) had symptoms for less than two weeks. (Table 2)

The right knee (75%) was affected more than the left knee (25%).

**Table 2: Clinical Presentation of sample**

<b>Presentation</b>	<b>Male, n (%)</b>	<b>Female, n (%)</b>
Knee pain	18 (78.3)	23 (76.7)
Knee swelling	1 (4.3)	1 (3.3)
Knee pain/Knee swelling	0 (0.0)	5 (16.7)
Knee pain/Knee weakness	2 (8.7)	0 (0.0)
Knee pain/Reduced range of motion	2 (8.7)	1 (3.3)
<b>Duration</b>		
<2 weeks	5 (21.7)	11 (36.7)
>2 weeks	18 (78.3)	19 (63.3)

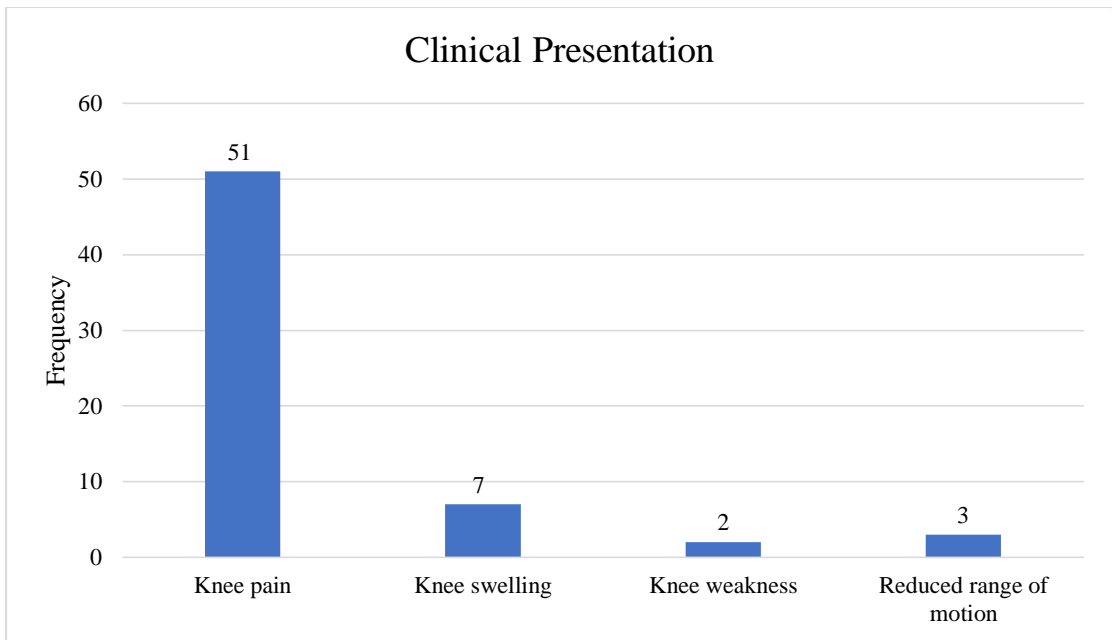


Figure 13: Distribution of clinical symptoms in sample

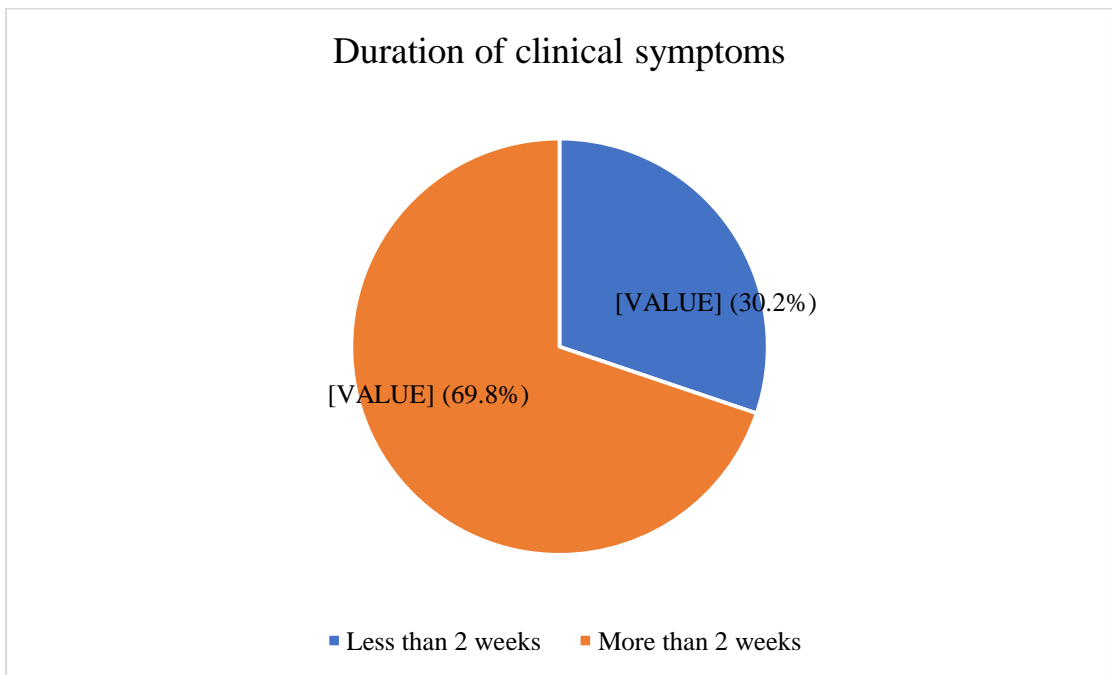


Figure 14: Duration of symptoms in sample

### 4.3 FINDINGS

A total of 39 (73.6%) patients had a joint effusion. Of these, 14 (26.4%) had mild, 11 (20.8%) had moderate and 14 (26.4%) had severe joint effusions. 14 (26.4%) patients did not have a joint effusion.

A total of 19 (35.9%) out of 53 patients showed a form of ACL injury. Of these, 9 (17%) patients had a complete ACL tear, 5 (9.4%) patients had a Grade 0 injury, 3 (5.7%) patients had a Grade 2 injury and 2 (3.8%) patients had Grade 1 injury. The male to female ratio of ACL injuries was 1:3.8. 31 (58.5%) patients showed a normal ACL. 1 (1.9%) patient each showed degenerative change and ganglion cyst.

A total of 48 (90.6%) showed a normal PCL. 2 (3.8%) patients exhibited a Grade 0 PCL injury and 1 (1.9%) patient suffered a Grade 2 PCL injury.

A total of 49 (92.5%) patients had a normal MCL. 1 (1.9%) patient had a Grade 2 injury, 1 (1.9%) patient had a Grade 3 sprain, 1 (1.9%) patient had a proximal avulsion and 1 (1.9%) patient had a distal attachment avulsion.

A total of 52 (98.1%) patients had a normal LCL. 1 (1.9%) patient had a grade 3 sprain. (Table 3).

**Table 3: Joint effusion, ACL, PCL, MCL and LCL findings**

<b>Joint effusion</b>	<b>Male, <i>n</i> (%)</b>	<b>Female, <i>n</i> (%)</b>
None	10 (43.5)	4 (13.3)
Mild	5 (21.7)	9 (30.0)
Moderate	5 (21.7)	6 (20.0)
Severe	3 (13.0)	11 (36.7)
<b>ACL injury</b>		
Normal	17 (73.9)	14 (46.7)
Grade 0 injury	1 (4.3)	4 (13.3)
Grade 1 injury	1 (4.3)	1 (3.3)
Grade 2 injury	1 (4.3)	2 (6.7)
Grade 3 injury (complete)	1 (4.3)	8 (26.7)
Degenerative change	1 (4.3)	0 (0.0)
Other lesions	0 (0.0)	1 (3.3)
Not seen	1 (4.3)	0 (0.0)
<b>PCL injury</b>		
Normal	20 (87.0)	28 (93.3)
Grade 0 injury	1 (4.3)	1 (3.3)
Grade 2 injury	0 (0.0)	1 (3.3)
Other lesions	1 (4.3)	0 (0.0)
Not seen	1 (4.3)	0 (0.0)

<b>MCL injury</b>		
Normal	22 (95.7)	27 (90)
Grade 2 injury	0 (0.0)	1 (3.3)
Grade 3 sprain	0 (0.0)	1 (3.3)
Proximal avulsion	0 (0.0)	1 (3.3)
Distal avulsion	1 (4.3)	0 (0.0)
<b>LCL injury</b>		
Normal	23 (100.0)	29 (96.7)
Grade 3 sprain	0 (0.0)	1 (3.3)

All 53 (100%) patients had a normal popliteus tendon, BFT and ITB.

A total of 42 (79.2%) patients had a normal medial meniscus. 4 (7.5%) patients showed degenerative changes, 3 (5.7%) patients had a complex tear, 2 (3.8%) patients had a horizontal tear, 1 (1.9%) patient each had a longitudinal and a bucket handle tear.

A total of 44 (83%) patients had a normal lateral meniscus. 6 (11.3%) patients exhibited degenerative change, 1 (1.9%) patient each exhibited a horizontal tear, bucket handle tear and radial tear.

A total of 52 (98.1%) patients had a normal QFT. The QFT was not seen in 1 (1.9%) patient signifying a complete tear.

A total of 51 (96.2%) patients had a normal patellar tendon. 1 (1.9%) patient exhibited a partial tear and 1 (1.9%) patient had features of tendinosis.

A total of 50 patients showed a normal MPR. 2 (3.8%) patients had a Grade 1 injury of the MPR while 1 (1.9%) patient had a Grade 3 injury of the MPR (Table 4)

**Table 4: PT, MM, LM and other findings**

<b>Popliteus tendon injury</b>	<b>Male, <i>n</i> (%)</b>	<b>Female, <i>n</i> (%)</b>
Normal	23 (100.0)	30 (100.0)
<b>Medial meniscus injury</b>		
Normal	20 (87.0)	22 (73.3)
Horizontal tear	1 (4.3)	1 (3.3)
Longitudinal tear	0 (0.0)	1 (3.3)
Bucket handle tear	0 (0.0)	1 (3.3)
Complex tear	2 (8.7)	1 (3.3)

Degenerative change	0 (0.0)	4 (13.3)
<b>Lateral meniscus injury</b>		
Normal	22 (95.7)	22 (73.3)
Horizontal tear	0 (0.0)	1 (3.3)
Bucket handle tear	0 (0.0)	1 (3.3)
Radial tear	0 (0.0)	1 (3.3)
Degenerative change	1 (4.3)	5 (16.7)
<b>Biceps femoris tendon</b>		
Normal	23 (100.0)	30 (100.0)
<b>Iliotibial band</b>		
Normal	23 (100.0)	30 (100.0)
<b>Quadriceps tendon injury</b>		
Normal	22 (95.7)	30 (100.0)
Not seen	1 (4.3)	0 (0.0)
<b>Patellar tendon injury</b>		
Normal	22 (95.7)	29 (96.7)
Tendinosis	0 (0.0)	1 (3.3)
Partial tear	1 (4.3)	0 (0.0)
<b>Medial patellar retinaculum injury</b>		
Normal	22 (95.7)	28 (93.3)
Grade 1	1 (4.3)	1 (3.3)
Grade 3	0 (0.0)	1 (3.3)

A total of 49 (92.5%) patients had a normal LPR. 2 (3.8%) patients had a Grade 1 injury and 2 (3.8%) patients had a Grade 2 injury.

A total of 34 (64.2%) patients elicited a normal patella. Patella alta was seen in 5 (9.4%) patients and a further 5 (9.4%) elicited contusions over the patella. 2 (3.8%) patients elicited a patella baja. Patellar subluxation and dislocation was noted in 2 (3.8%) patients. The rest of the findings are shown in Table 5.

The articular cartilage was noted to be normal in 37 (69.8%) patients. Articular cartilage injuries were noted in 16 (30%) patients, of which 10 were females and 6

were males. Chondrosis was seen in 10 (18.9%) patients and chondromalacia patella was noted in 6 (11.4%) patients.

**Table 5: LPR, Patella and articular cartilage findings**

<b>Lateral patellar retinaculum injury</b>	<b>Male, <i>n</i> (%)</b>	<b>Female, <i>n</i> (%)</b>
Normal	22 (95.7)	27 (90.0)
Grade 1	1 (4.3)	1 (3.3)
Grade 2	0 (0.0)	2 (6.7)
<b>Patella findings</b>		
Normal	17 (73.9)	17 (56.7)
Patella alta	1 (4.3)	4 (13.3)
Patella baja	1 (4.3)	1 (3.3)
Patella subluxation	0 (0.0)	1 (3.3)
Patella dislocation	1 (4.3)	0 (0.0)
Contusion	2 (8.7)	3 (10.0)
Osteochondral defect	1 (4.3)	0 (0.0)
Patella subluxation/Osteochondral defect	0 (0.0)	1 (3.3)
Patella subluxation/Contusion/Osteochondral defect/Normal variant	0 (0.0)	1 (3.3)
Fracture/Contusion	0 (0.0)	1 (3.3)
Patella alta/Patella subluxation	0 (0.0)	1 (3.3)
<b>Articular cartilage injury</b>		
Normal	17 (73.9)	20 (66.7)
CMP grade 1	1 (4.3)	2 (6.7)
CMP grade 2	0 (0.0)	1 (3.3)
CMP grade 3	1 (4.3)	1 (3.3)
Chondrosis	4 (17.4)	6 (20.0)

Other than the patella, the rest of the articulating bones of the knee were noted to be normal in 30 (56.6%) patients. Features of osteoarthritis alone were seen in 8 (15.1%) patients. A total of 5 (9.4%) patients showed a contusion while 1 (1.9%) patient each had an acute fracture and pathological fracture. A combination of injuries was noted in some patients as shown in Table 6 below.

**Table 6: Bone findings other than patella**

	<b>Male, n (%)</b>	<b>Female, n (%)</b>
Normal	13 (56.5)	17 (56.7)
Acute fracture	1 (4.3)	0 (0.0)
Contusion	2 (8.7)	3 (10.0)
Osteoarthritis	4 (17.4)	4 (13.3)
Pathological fracture	1 (4.3)	0 (0.0)
Contusion/Osteoarthritis	0 (0.0)	2 (6.7)
Contusion/Osteoarthritis/Pathological fracture	1 (4.3)	0 (0.0)
Contusion/Osteonecrosis	0 (0.0)	1 (3.3)
Contusion/Osteochondral lesion	0 (0.0)	1 (3.3)
Acute fracture/Contusion	0 (0.0)	1 (3.3)
Contusion/Osteochondral lesion/Osteoarthritis	1 (4.3)	0 (0.0)
Stress fracture/Contusion/Osteoarthritis	0 (0.0)	1 (3.3)

There were other findings amongst the patients, with the most common finding being soft tissue edema with 19 (35.8%) patients of the total presenting, followed by fat pad injury presenting in 13 (24.5%) of the patients, 10 (18.9%) patients presenting with popliteal cyst, 7 (13.2%) patients presenting with subchondral cysts, 6 (11.3%) patients with bursitis, 5 (9.4%) patients with a tumour, 4 (7.5%) patients with muscle injury, 3 (5.7%) patients with enlarged popliteal lymph nodes, 1 (1.9%) patient each with ganglion cyst, synovial osteochondromatosis, pigmented villonodular synovitis, abscess, haemarthrosis and synovitis. 10 (18.9%) patients had no other findings. Of the 5 patients with tumours, 2 patients had biopsy proven osteosarcomas, 2 patients had biopsy proven soft tissue sarcomas and 1 patient had imaging features suggestive of synovial sarcoma or pleomorphic undifferentiated sarcoma awaiting biopsy.

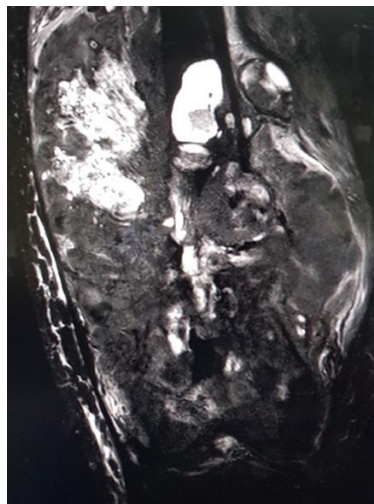
**Table 7: Other findings**

	<b>Frequency (n=53)</b>	<b>Percentage</b>
Bursitis	6	11.3
Fat pad injury	13	24.5
Popliteal cyst	10	18.9
Ganglion cyst	1	1.9

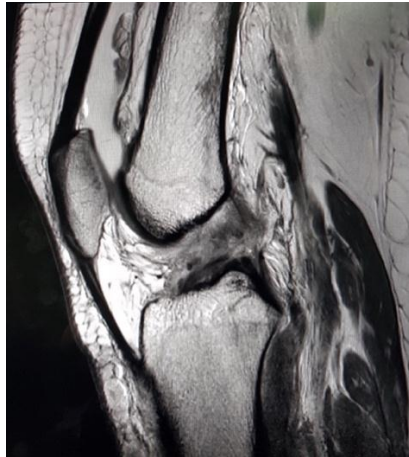

Subchondral cyst	7	13.2
Synovial osteochondromatosis	1	1.9
Soft tissue edema	19	35.8
Tumor	5	9.4
PVNS	1	1.9
Enlarged lymph nodes	3	5.7
Abscess	1	1.9
Haemarthrosis	1	1.9
Muscle injury	4	7.5
Synovitis	1	1.9
None	10	18.9

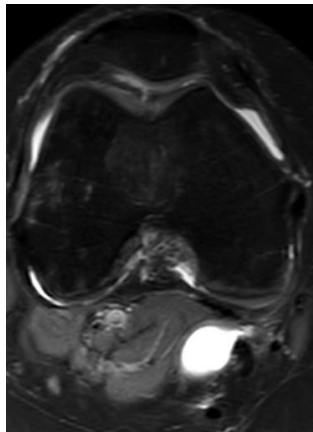
#### 4.4 SELECTED IMAGES FROM STUDY SAMPLE



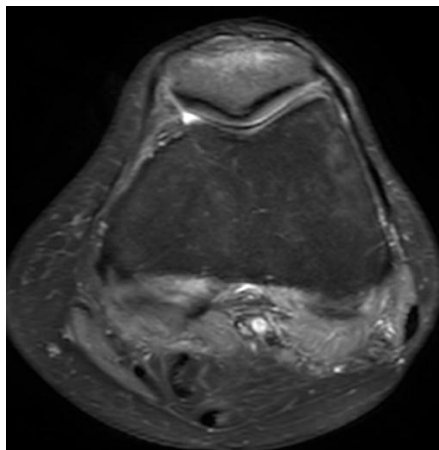
*Figure 15: 42-year-old male patient. T2 FS coronal image shows osteosarcoma involving right distal femur*



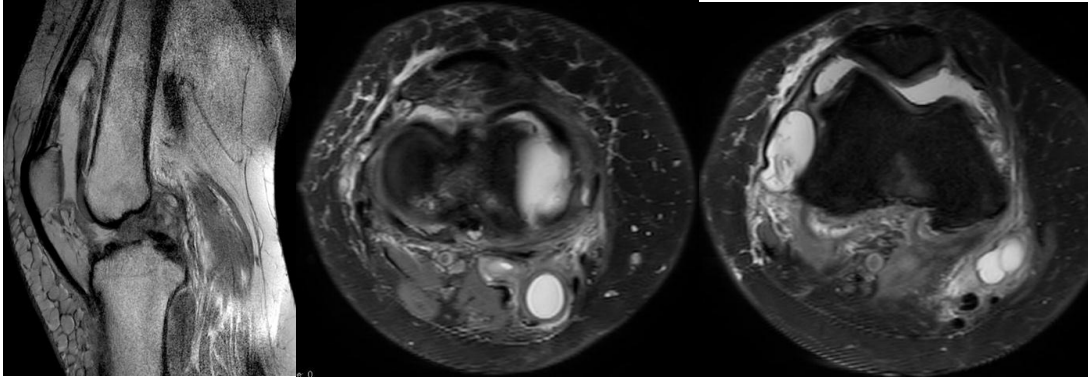
*Figure 16: 28-year-old female with chronic left knee pain. Sagittal PD image shows a significant joint effusion and complete disruption of the ACL suggestive of a full thickness tear.*



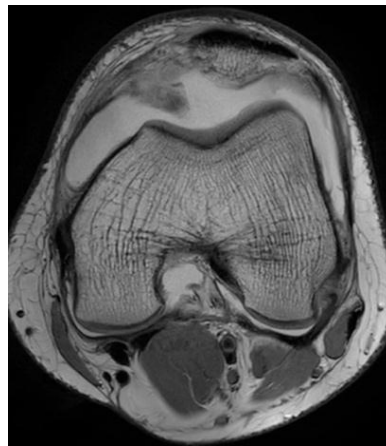
*Figure 17: 43-year-old female with long standing right sided knee pain. PD FS image shows a baker's cyst and a joint effusion*



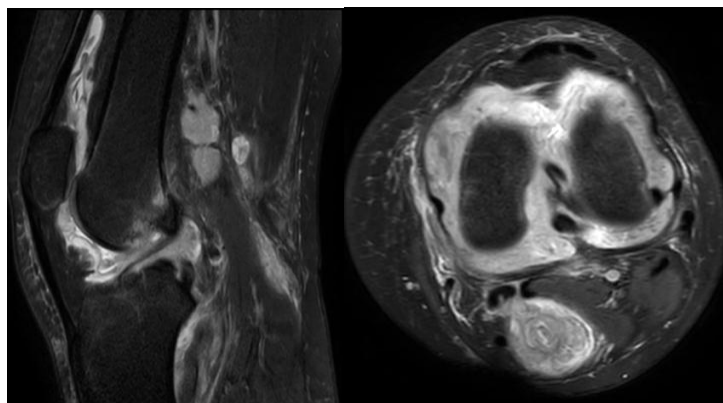
*Figure 18: Axial PD FS image of a 35-year-old female patient after a fall showing bone marrow oedema of the inferior patella in the region of an undisplaced fracture.*



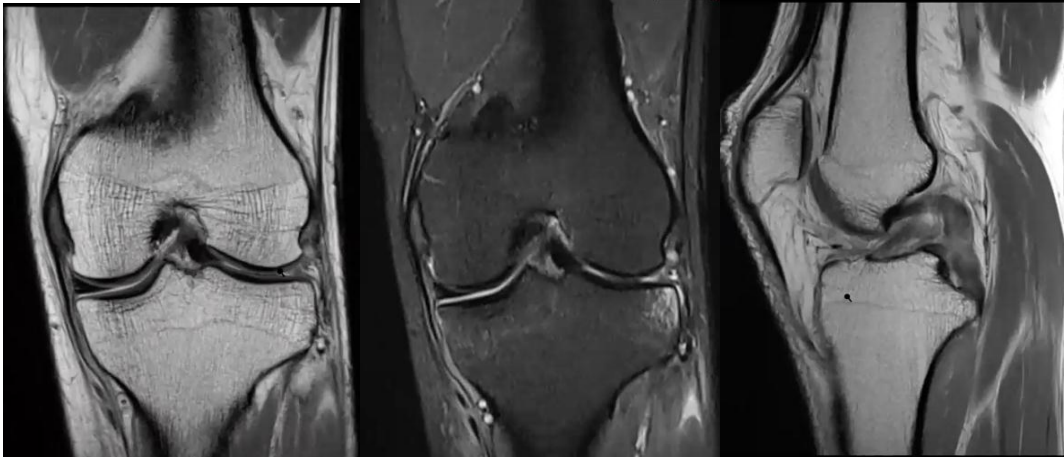
*Figure 19: 53-year-old female patient with long standing right knee pain. TIW sagittal image (left) shows discontinuity of ACL with fluid in the region of the tibial attachment in keeping with a complete ACL tear. Axial PD FS image (middle) shows a complex tear of the medial meniscus, a baker's cyst, joint effusion and subcutaneous oedema in the anterior knee. An axial PD FS image at a higher level (right) shows lateral subluxation of the patella.*



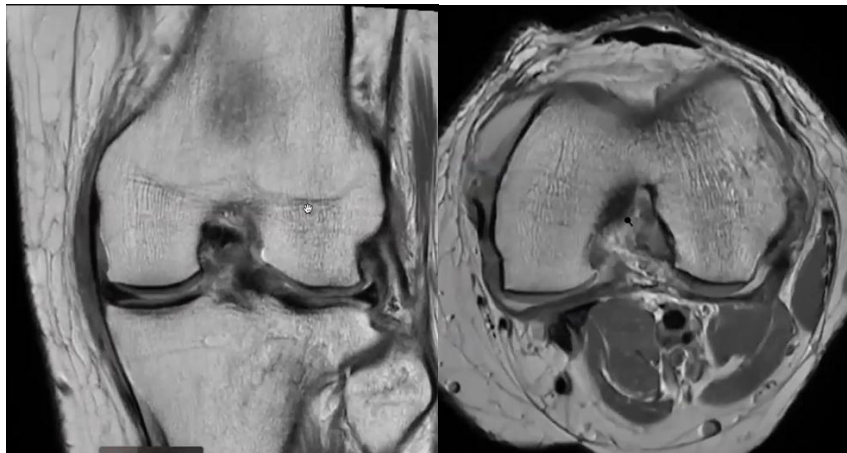
*Figure 20: Pigmented villonodular synovitis (PVNS) in a 20-year-old male patient. Axial PD Non-FS image shows a large volume joint effusion and focal nodularity of the synovium.*



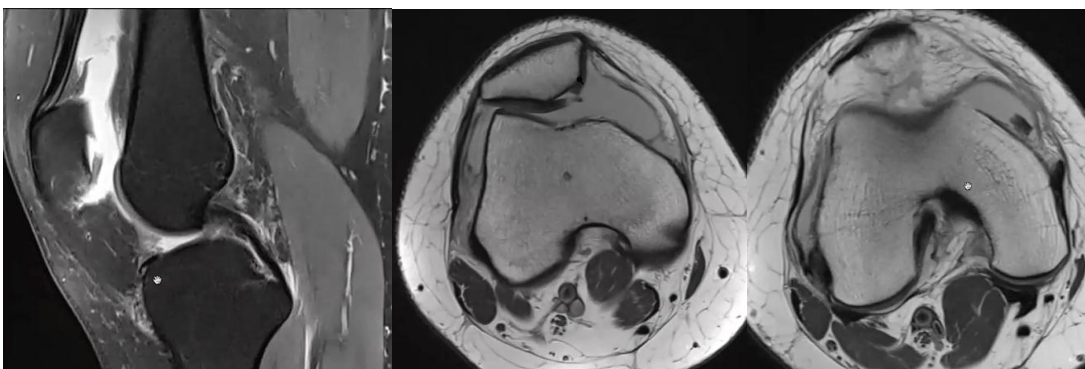
*Figure 21: A 23-year-old female patient with chronic left knee pain and swelling. Sagittal and axial PD FS images show a significant joint effusion, multiple enlarged reactive popliteal lymph nodes and a baker's cyst.*



*Figure 22: A 57-year-old female patient with a bucket handle tear of the lateral meniscus and a high-grade PCL tear.*



*Figure 23: A 25-year-old male patient with oedema surrounding the MCL which is otherwise normal. This was a Grade 1 MCL injury*



*Figure 24: 60-year-old female patient. Sagittal PD FS (left image) and axial PD Non-FS (middle and right images) showing a patellar cartilage chondral delamination injury with a displaced chondral body in the medial recess. A significant joint effusion is also seen.*

## CHAPTER FIVE

### 5.1 DISCUSSION

The main objective of this study was to determine the spectrum of injuries seen in the knee joint in adult patients who were referred to Kenyatta National Hospital.

Knee pain is a common cause of musculoskeletal pain. MRI is the major modality in the evaluation of the knee soft tissues but its accessibility is limited due to availability and cost.

Majority (69.8%) of patients had clinical symptoms for more than two weeks. This was similar to the local study by Thiga LM et al (55) which showed that 71.7% of patients had symptomatology for more than two weeks.

An almost equal proportion of male (78.3%) and female (76.7%) patients presented to casualty with knee pain. This was also seen in the German SESAM 2 study. (3)

Majority of the patients were in the 19-29 and 40-49 year age group and the right knee (71.9%) was affected more than the left (28.1%). This was similar to what Thiga LM et al (55) found in their study with majority of patients in the 26-50 year age group and the right knee (67.4%) was affected more than the left (32.6%). The commonest findings encountered in our study were ACL tears, meniscal tears, joint effusions and degenerative joint disease. Of these, joint effusions accounted for 73.6% (n=39), ACL tears accounted for 35.9% (n=19), meniscal tears accounted for 18.9% (n=10) and degenerative joint disease accounted for 24.5% (n=13).

Our study had a higher number of female (56.6%) than male (43.4%) patients presenting for an MRI of the knee with a male to female ratio of 1:1.3. This is similar to the study by Singh N et al (10). However, this finding was contrary to all the other studies reviewed which had more male than female patients. (3) (6) (7) (16) (49)

Majority of patients presented with complaints of knee pain (96%).

In our study we found a predominantly younger age group of patients presenting for an MRI knee scan. This is contrary to the German SESAM 2 and Dutch Transition Project studies (3). This was also contrary to the Ankit D et al study which had 60.7% males and 39.3% females presenting for an MRI of the knee after sustaining a knee injury. (16)

Our study showed more female (79%) than male patients (21%) suffered a form of ACL injury with a male to female ratio of 1:3.8. This is contrary to the study by Sindhura P et al which had 90% of male patients and only 11.1% of female patients

suffering an ACL tear (7). This is also contrary to the study by Chandru S et al which showed that more male patients suffered ACL injuries. (6)

We also found that many of the patients with an ACL injury also had a concurrent MM, MCL or LM injury. This agrees with the study by Sindhura P et al which in addition had associated LCL injuries. (7)

The PCL was not a commonly injured ligament in our study owing to its higher tensile strength than the ACL. This finding was similar to what Trunina MB et al found (48). However, all 3 patients that sustained a PCL injury also had an ACL injury. In addition, a patient with a PCL injury also had an ACL, MCL and MM injury. This reinforces the fact that PCL injuries are associated with other injuries in the knee, a finding that was also noted by Rodriguez W et al (47).

MM tears (70%) were more common than LM tears (30%) in our study, which agrees with studies by Patel I et al (6) and Orlando Junior N et al (5). However, Ankit D et al (16) in their study found LM tears were more common than MM tears. Amongst patients who had MM tears, the posterior horn was the most common location affected, accounting for 86%. This finding was also seen by Ankit D et al (16) in their study.

Articular cartilage injuries were reported in 16 (30%) patients of which 10 were female and 6 were male patients. A meta analysis by Drew BT et al (20) found that higher field strength MRI machines are superior to lower field strength machines and that higher grade lesions are better detected than lower grade ones. A study by Figueroa D et al (21) also concluded that higher field strength of 3T can increase MRI accuracy of detecting chondral knee lesions.

Majority of patients with findings of osteoarthritis in the knee were in the 40-59 year age group (69.2%).

The most common finding in this study was presence of a joint effusion secondary to a variety of causes. It was found in 73.6% of patients in our study. This agrees with a study by Chaudhuri S et al (54) which also found joint effusion to be the most common finding.

The main limitation in this study was the absence of arthroscopy findings to correlate with the imaging findings. It was not feasible to obtain the arthroscopic findings within the duration of the study and owing to the COVID-19 pandemic.

## **5.2 CONCLUSIONS**

1. Knee pain is more common in females than in males.
2. The right knee was affected more than the left knee.
3. The most common finding was joint effusion secondary to another pathology while the commonest soft tissue injury was an ACL tear.
4. ACL injuries are more common in females than in males.
5. Most ACL injuries and PCL injuries had concurrent injuries.
6. Degenerative changes seen on MRI increased with age.

### **5.3 STUDY LIMITATIONS**

1. Small sample size hence less pathologies were captured.
2. Lack of picture archiving and communication system at KNH Department of radiology limited any retrospective study which would have yielded a larger sample size.
3. Inability to compare with arthroscopy (gold standard) to establish the sensitivity and specificity of MRI vs arthroscopy due to time constraints and the pandemic.
4. Lack of succinct and exhaustive clinical information from referring clinicians on patient request forms created diagnostic challenges.



## **5.4 RECOMMENDATIONS**

1. A clear knee imaging protocol still needs to be established to standardize examinations and cut down on variability of the results and scan times.
2. There is a need to establish a dedicated picture archiving and communication system and storage capacity for patient MRI studies as many studies were already deleted when attempts were made to look at the studies again.
3. Great difficulty was encountered in acquiring clinical information particularly physical examination findings. Clinicians need to be sensitized on providing succinct and exhaustive details on the patients they refer for MR imaging. This will greatly improve interpretation of findings on MRI.
4. There is a need for a larger cohort of patients to be recruited in order to further elaborate on the knee MRI findings within the Kenyan population preferably with arthroscopic correlation.
5. Adoption of newer techniques such as T2 mapping of cartilage can be used for studies to quantify the degree of cartilage loss in osteoarthritis and identify biochemical changes associated with early osteoarthritis before conventional MRI.

## STUDY TIMELINE

2020 and 2021	Jan-Nov 2020	Dec 2020	Jan-Feb	Feb-Mar	March-June	July	July-Aug
Proposal Development							
Approval by supervisors							
ERC review							
Proposal Corrections by ERC							
Data collection							
Data analysis							
Results presentation							

## BUDGET

	<b>Allocation</b>	<b>Item/Breakdown</b>	<b>Amount (Ksh)</b>
1.	Ethics board (ERC)	Ethics fees	2,000
2.	Stationery and Electronics	Printing paper @ 1000/=	4,000
		Ink cartridge @ 1250/=	2,500
		Biro pens (1 box) @ 1000/=	1,000
		Folders @ 300/=	3,000
		Flash drives @ 500/=	2,000
3.	Data collection and analysis	Biostatistician services	30,000
4.	Image acquisition	Scanning of images	5,000
		Digital transfer of images	5,000
5.	Secretarial services	Typist fees	4,000
		Photocopy	7,000
6.	Printing and binding services	Drafts	10,000
		Proposal	9,000
		Final report	14,000
7.	Contingency (10% of Total Budget)		9,850
	<b>TOTAL AMOUNT</b>		108,350

## REFERENCES

1. Vohra S, Arnold G, Doshi S, et al. Normal MR Imaging Anatomy of the Knee. *Magn Reson Imaging Clin N Am*. 2011;19(3):637–53.
2. J Picavet HS, G Schouten JSA. Musculoskeletal pain in the Netherlands: prevalences, consequences and risk groups, the DMC(3)-study. *Pain* 2003;102(1–2):167–78.
3. Frese T, Peyton L, Mahlmeister J, et al. Knee Pain as the Reason for Encounter in General Practice. *ISRN Fam Med*. 2013;2013(Sesam 1):1–6.
4. Svebak S, Hagen K, Zwart JA. One-year prevalence of chronic musculoskeletal pain in a large adult Norwegian county population: Relations with age and gender - The HUNT study. *J Musculoskelet Pain*. 2006;14(1):21–8.
5. Orlando Júnior N, de Souza Leão MG, de Oliveira NHC. Diagnosis of knee injuries: comparison of the physical examination and magnetic resonance imaging with the findings from arthroscopy. *Rev Bras Ortop (English Ed)* 2015;50(6):712–9.
6. Patel I, Chandru V, Nekkanti S, et al. Clinical, Magnetic Resonance Imaging, and Arthroscopic Correlation in Anterior Cruciate Ligament and Meniscal Injuries of the Knee. *J Orthop Trauma Rehabil*. 2018;24:52–6.
7. Sindhura P, Suneetha P, Venkatesh M, et al. A Prospective Study of MRI (3 Tesla) Evaluation of Traumatic Anterior Cruciate Ligament Injuries with Arthroscopy Correlation. *Int J Contemp Med Surg Radiol*. 2019;4(4).
8. Smith C, McGarvey C, Harb Z, et al. Diagnostic efficacy of 3-T MRI for knee injuries using arthroscopy as a reference standard: A meta-analysis. *Am J Roentgenol*. 2016;207(2):369–77.
9. Puri S, Salgia A, Sanghi S, et al. Study of correlation between clinical, magnetic resonance imaging, and arthroscopic findings in meniscal and anterior cruciate ligament injuries. *Medical Journal of Dr. D.Y. Patil University*. 2013;6(3), 263
10. Singh N, Hanekom H, & Suleman F. The accuracy of magnetic resonance imaging diagnosis of non-osseous knee injury at Steve Biko Academic Hospital. *South African Journal of Radiology*. 2019; 23(1).
11. Gorantla R, Rao A. Correlation of Clinical examination, Magnetic Resonance Imaging (MRI) with Arthroscopic Findings in the Knee Joint. *Int J Contemp Med Surg Radiol*. 2018;3(4):147–9.
12. Gupta K, Sandhu P, Galhotra R, et al. Correlation of clinical, MRI and arthroscopic findings in diagnosing meniscus and ligament injuries at knee joint: A prospective study. *Journal of Orthopaedics and Allied Sciences*. 2013
13. Khan HA, Ahad H, Sharma P et al. Correlation between magnetic resonance imaging and arthroscopic findings in the knee joint. *Trauma Mon*. 2015;20(1):11–4.
14. Krakowski P, Nogalski A, Jurkiewicz A, et al. Comparison of diagnostic accuracy of physical examination and MRI in the most common knee injuries. *Appl Sci*. 2019;9(19).
15. Crawford R, Walley G, Bridgman S, et al. Magnetic resonance imaging versus arthroscopy in the diagnosis of knee pathology, concentrating on meniscal lesions and ACL tears: A systematic review. *Br Med Bull*. 2007;84(1):5–23.

16. Ankit D, Gakuya E. Accuracy of Clinical Evaluation and Mri Reporting Compared To Knee Arthroscopic Findings. *East African Orthop J*. 2019;13(September):64–71
17. De Smet A, Graf B. Meniscal tears missed on MR Imaging: Relationship to meniscal tear patterns and anterior cruciate ligament tears. *American Journal of Roentgenology*. 1994;162:905-911
18. Bonadio MB, Helito CP, Gury LA, et al. Correlation between magnetic resonance imaging and physical exam in assessment of injuries to posterolateral corner of the knee. *Acta Ortop Bras*. 2014;22(3):124–6.
19. Vallotton JA, Meuli RA, Leyvraz PF, et al. Comparison between magnetic resonance imaging and arthroscopy in the diagnosis of patellar cartilage lesions - A prospective study. *Knee Surgery, Sport Traumatol Arthrosc*. 1995;3(3):157–62.
20. Smith TO, Drew BT, Toms AP, et al. Accuracy of magnetic resonance imaging, magnetic resonance arthrography and computed tomography for the detection of chondral lesions of the knee. *Knee Surgery, Sport Traumatol Arthrosc*. 2012;20(12):2367–79.
21. Figueroa D, Calvo R, Vaisman A, et al. Knee Chondral Lesions: Incidence and Correlation Between Arthroscopic and Magnetic Resonance Findings. *Arthrosc - J Arthrosc Relat Surg*. 2007;23(3):312–5.
22. B D Chaurasia's Human Anatomy. Seventh edition
23. Anatomy for Diagnostic Imaging by Stephanie Ryan. Third edition
24. Montanari MC, Linares Villavicencio CG, Risco MR et al. MRI of the knee: normal and abnormal findings. 2018;1–23
25. Rajan S, Mohamed AJ. Evaluation of Role of Magnetic Resonance Imaging in Knee Joint Injuries in Correlation with Arthroscopy. *Int J Sci Study* 2017;5(1):1–6.
26. Ramnath RR, Magee T, Wasudev N, et al. Accuracy of 3-T MRI using fast spin-echo technique to detect meniscal tears of the knee. *Am J Roentgenol*. 2006;187(1):221–5.
27. Crema MD, Frank W, Marra MD, et al. Articular Cartilage in the Knee: Current MR Imaging Techniques and Applications in Clinical Practice and Research. *Radiographics*. 2011; 31:61–2.
28. Alves TI, Girish G, Brigido MK, et al. US of the knee: Scanning techniques, pitfalls, and pathologic conditions. *Radiographics*. 2016;36(6):1759–75.
29. Razek AAKA, Fouda NS, Elmetwaley N, et al. Sonography of the knee joint. *J Ultrasound*. 2009;12(2):53–60.
30. Mustonen AOT, Koskinen SK, Kiuru MJ. Acute knee trauma: Analysis of multidetector computed tomography findings and comparison with conventional radiography. *Acta radiol*. 2005;46(8):866–74.
31. Keynes TA, Wilfred CG. Radiography Limitations and Pitfalls. *Pitfalls in Musculoskeletal Radiology August 2017 pp.3-32*.
32. Clark's positioning in radiography. Thirteenth edition
33. Avci M, Kozaci N. Comparison of X-ray imaging and computed tomography scan in the evaluation of knee trauma. *Med*. 2019;55(10).
34. Smet AA De, Graf BK, Rosas HG. Diagnosis and Classification of Meniscal Tears - MRI. *Radiographics*. 2014;(1).
35. De Smet AA, Norris MA, Yandow DR, et al. MR diagnosis of meniscal tears of the knee: importance of high signal in the meniscus that extends to the surface. *AJR Am J Roentgenol* 1993; 161(1):101–107.

36. De Smet AA, Graf BK. Meniscal tears missed on MR imaging: relationship to meniscal tear patterns and anterior cruciate ligament tears. *AJR Am J Roentgenol* 1994;162(4):905–911
37. Magee T, Williams D. Detection of meniscal tears and marrow lesions using coronal MRI. *AJR Am J Roentgenol* 2004;183(5):1469–1473.
38. Rubin DA. MR imaging of the knee menisci. *Radiol Clin North Am* 1997;35(1):21–44
39. Robertson PL, Schweitzer ME, Bartolozzi AR, et al. Anterior cruciate ligament tears: Evaluation of multiple signs with MR imaging. *Radiology*. RSNA 1994
40. Kam CK, Chee DWY, Peh WCG. Magnetic Resonance Imaging of Cruciate Ligament Injuries of the Knee. *Can Assoc Radiol J*. 2010;61(2):80–9.
41. Chhabra A, Soldatos T. Musculoskeletal MRI Structured Evaluation. How to practically fill the Reporting Checklist. p 759-927.
42. Pedersen RR. The Medial and Posteromedial Ligamentous and Capsular Structures of the Knee: Review of Anatomy and Relevant Imaging Findings. *Semin Musculoskelet Radiol*. 2016;20(1):12–25
43. Hash TW. Magnetic Resonance Imaging of the Knee. *Sports Health*. 2013;5(1):78–107.
44. Roberts CC, Towers JD, Spangehl MJ, et al. Advanced MR Imaging of the Cruciate Ligaments. *Magn Reson Imaging Clin N Am*. 2007;15(1):73–86.
45. Hong SH, Choi J-Y, Lee GK, et al. Grading of Anterior Cruciate Ligament Injury. *J Comput Assist Tomogr*. 2003;27(5):814–9.
46. Guenoun D, Le Corroller T, Amous Z, et al. The contribution of MRI to the diagnosis of traumatic tears of the anterior cruciate ligament. *Diagn Interv Imaging*. 2012;93(5):331–41.
47. Rodriguez W, Vinson EN, Helms CA, et al. MRI appearance of posterior cruciate ligament tears. *AJR Am J Roentgenol*. 2008;191(4):1031.
48. Trunina MB, Eusebio JP, et al. Posterior cruciate ligament tears: description of MRI findings with arthroscopic correlation. 2013;1–17.
49. Rodrigues MB, Camanho GL. MRI Evaluation of Knee Cartilage. *Rev Bras Ortop*. 2010;45(4):340–6.
50. Chen A, Balogun-Lynch J, Aggarwal K, et al. Should all elective knee radiographs requested by general practitioners be performed weight-bearing? *Springerplus*. 2014;3(1):3–7.
51. Goldenberg DL, Brandt KD, Cohen AS, et al. Treatment of septic arthritis: comparison of needle aspiration and surgery as initial modes of joint drainage. *Arthritis Rheum*. 1975;18(1):83–90.
52. García-Arias M, Balsa A, Mola EM. Septic arthritis. *Best Pract Res Clin Rheumatol*. 2011;25(3):407–21.
53. Llander J, Palmer J, Rosón N, et al. Nonseptic monoarthritis: Imaging features with clinical and histopathologic correlation. *Radiographics*. 2000;20(SPEC.ISS.):263–78.
54. Chaudhuri S, Joshi P, Goel M. Role of Mri in Evaluation of Traumatic Knee Injuries. *J Evol Med Dent Sci*. 2013;2(7):765–71.
55. Thiga LM, Wambugu MN, Owinga SO. Findings of Magnetic Resonance Imaging of Intra-articular knee pathology: Radioarthroscopic correlation. 2008

# APPENDICES

## APPENDIX A: MRI SAFETY QUESTIONNAIRE AND CONSENT FORM

Participant Number: \_\_\_\_\_ Date: \_\_\_\_\_

Gender: \_\_\_\_\_ Age: \_\_\_\_\_ DOB: \_\_\_\_\_ Weight: \_\_\_\_\_

1. Have you undergone any surgeries in the past? List all in chronological order.

Yes  No

---

---

2. Do you have any of the following implants or devices in or on your body?

Joint replacement? Yes  No

Bone/joint pin, screw, wire, plate or nail? Yes  No

Bullet, shrapnel or any metal in the body? Yes  No

Wire sutures, surgical clips or surgical staples? Yes  No

Internal or external Body Piercings? Yes  No

Tattoos? Yes  No

Metal in your eyes or worked with metal extensively? Yes  No

Cochlear (ear) or Ocular (eye) implant? Yes  No

Hearing aid? Yes  No

Aneurysmal clips? Yes  No

Stent, Coil, Filter or Shunt? Yes  No

Neurostimulator or bone growth stimulator? Yes  No

Artificial heart valve(s)? Yes  No

Implanted cardiac defibrillator? Yes  No

Cardiac pacemaker? Yes  No

Any access ports or catheters? Yes  No

Implantable drug pumps? Yes  No

Dentures, dental plates or any dental work? Yes  No

3. For females in the reproductive age group

Are you pregnant? Yes  No

If unsure, is it possible you are pregnant? Yes  No

When was your last menstrual period? \_\_\_\_\_

Are you nursing (breast-feeding)? Yes  No

#### 4. Contrast study questionnaire

Have you ever undergone a radiological investigation where contrast or dye was used? Yes  No

Did you have any reaction while/after receiving the contrast or dye? Yes  No

If you had a reaction kindly provide details.

---

Do you have any allergies? Yes  No

If yes, please provide details.

---

---

Do you have kidney (renal) disease? Yes  No

Are you on any medications? Please list them below Yes  No

---

---

Before you step into the MRI suite, you must remove all metallic objects on you including mobile phone(s), watch, coins, credit cards, keys, jewelry, body piercings, hair clips and extensions, dentures, hearing aids, eyeliner, prosthetic limbs, and any other objects with a metallic component.

Patient consent to MRI procedure and intravenous administration of MRI contrast (if needed). Please Tick. (*This is only consent for the MRI procedure, not for participation in the research study*)

- I consent that the information provided above is correct to the best of my knowledge.
- I have read the information provided to me in the Consent Information Booklet, and I am fully aware of the benefits and risks of having an MRI scan done. I am also aware of the benefits and risks of receiving an injection of the gadolinium MRI contrast should the need arise during the study.
- I was given an opportunity to ask questions, which have been adequately answered.
- I thereby give consent to proceed with the MRI examination, and consent to injection of intravenous contrast should the need arise.
- I understand that I can consent to the MRI and still refuse to take part in the research study.

---

Patient Signature: \_\_\_\_\_

Emergency contact: \_\_\_\_\_

Witnessed By (Name and Signature): \_\_\_\_\_



## **APPENDIX B: CONSENT FORM – ENGLISH**

### **INFORMATION AND CONSENT FORM**

**Title of study: Spectrum and patterns of knee pathology in patients undergoing knee MRI examinations at Kenyatta National Hospital**

**Principle investigator:** Dr. Patil S.S (MMed Radiology student, University of Nairobi),

**Supervisors:** Dr. Kennedy Kimani (University of Nairobi), Dr. Alfred Odhiambo (University of Nairobi),

**Participant Number:** - \_\_\_\_\_

#### **Introduction:**

I would like to tell you about this study being conducted by the above-named investigators. The purpose of this form is to give you the information that will help you decide whether or not to be a participant in this study. Feel free to ask any questions regarding the purpose of this study, what happens if you participate, the possible risks and benefits, your rights as a volunteer and anything else about this research or form that is not clear. When we have answered all your questions to your satisfaction, you may decide to be in this study or not. Once you understand and agree to be in this research, I will request you to sign your name in this form. You should understand the general principles that apply to all participants in a medical research: i) Your decision to participate is entirely voluntary, ii) You may withdraw from the study at any time without necessarily giving a reason for your withdrawal, iii) Refusal to participate in this research will not affect the services you are entitled to in this health facility or other facilities. We will give you a copy of this form for your records.

**May I continue? YES / NO**

#### **What is this study about?**

The knee joint is one of the most common joints in the human body to be affected by injuries and other pathology. The purpose of this study is to ascertain what patterns of pathology will be seen in and around the knee joint(s) using MRI as the primary imaging investigation. You were referred by your doctor with a request for an MRI exam of the knee to be done. Therefore, I would like to recruit you into my study.

The researchers listed above are conducting a research study to determine the types and patterns of different pathology in the knee on MRI images of patients undergoing this imaging at Kenyatta National Hospital. Approximately 60 participants will be selected to participate in this study. We are requesting for your consent to participate in this study.

**What will happen if you decide to participate in this research study?**

If you agree to participate in this study, the following things will happen:

You will undergo MRI imaging of the knee in question, and the findings of the MRI report, will be collected as part of the raw data for this study.

We will ask for a telephone number where we can contact you if necessary. If you agree to provide your contact information, it will be used only by people working for this study and will never be shared with others. The reasons why we may need to contact you include to ask any follow up questions if needed or to confirm any further details if required.

If you decide to participate in this study, your name and other personal information will NOT be included in the study report and will be kept confidential at all times. Forms used to collect data will be destroyed after the study has concluded.

**Are there any risks, harms, discomforts associated with this study?**

Medical research has the potential to introduce psychological, social, emotional, and physical risks. Effort will always be put in place to minimize the risks. A potential risk of being in this study is the loss of privacy. We will keep everything you tell us as confidential as possible. We will use a code number to identify you in a password-protected computer database and will keep all your paper records in a locked file cabinet. However, no system of protecting your confidentiality can be absolutely secure, so it is still possible that someone could find out you were in this study and could find out information about you.

**Are there any benefits of participating in this study?**

You will not receive any extra advantage or benefit by participating in the study. You will not receive any gift or reward for participating in this study. There will be no direct compensation for participating in this study. You will still be required to meet

the cost of the examination as requested by your doctor, and as agreed upon by the diagnostic imaging service provider.

**Will being in this study cost you anything?**

Participation is free and entirely voluntary. You will not be forced to participate. You hold the right to refuse to participate in the study without giving any reason, and without your medical care or legal rights being affected.

If you decide not to participate in the study, your MRI examination will still be done (as long as you have consented and met the MRI safety requirements). You won't be denied the scan which your doctor has requested you to undergo. You and your doctor will still get the results of your scan, regardless of whether you participate in the study.

**Will you get a refund for money spent as part of this study?**

There is no expense involved in participating in this study. You will not receive any compensation, either financially or otherwise for participating in this study.

**Confidentiality of Information**

All the data collected in the research study will be kept confidential. Information may be shared by the researcher with faculty supervisors who are also doctors, solely to facilitate the research. Data that is presented in the final report will not include your name or any personal information.

All forms used to collect data will be treated with utmost confidence during the study period. All such material will be destroyed once the research study has been concluded.

**Contacts: what if you have a question in the future?**

If you have any questions or concerns about participating in this study, please call or send a text message to the principal investigator, Dr. Sagar Patil on +254728555701 or email [sagar.patil.sb89@gmail.com](mailto:sagar.patil.sb89@gmail.com). If you wish to get in touch with the lead supervisor, Dr Alfred Odhiambo you can do so on +254733870957 or email at [dr\\_aodhiambo@yahoo.com](mailto:dr_aodhiambo@yahoo.com). For more information about your rights as a participant in this research, you may contact the secretary/chairperson, Kenyatta National hospital- University of Nairobi Ethics and Research committee telephone number

2726300, ext-44102, Email [uonknh\\_erc@uonbi.ac.ke](mailto:uonknh_erc@uonbi.ac.ke). The study staff will pay you back for your charges to these numbers if the call is for study-related communication.

### **What are your other choices?**

Your decision to participate in this research is voluntary. You are free to decline participation in the study, and you can withdraw from the study at any time without suffering negative consequences. You will continue to receive the care and treatment needed even if you do not wish to participate in this study.

### **What else do I need to know?**

#### **a) What is MRI?**

MRI stands for Magnetic Resonance Imaging and it uses an MRI scanner with a very strong magnet and radio waves to create exceptionally detailed images of the body, especially soft tissues such as the joints, muscles, tendons, ligaments and so on. MRI is extremely beneficial in diagnosing diseases and conditions where normal X-ray and CT scan imaging are inadequate. Unlike X-ray and CT scan imaging, MRI does not use harmful ionizing radiation. The scan takes approximately 25-40 minutes. The magnetic field produced by the magnet has no harmful effects on the body, and is very safe. Many studies have proven this.

Since MRI uses a strong magnet, all metallic objects must be removed before entering the MRI suite. You should fill in the MRI safety questionnaire correctly to ensure that no metallic object such as cardiac pacemakers, cochlear implants or bone plates screws or rods are within your body. This will prohibit you from having the MRI scan.

The scan takes place in a confined place for approximately 25-40 minutes while you lay motionless. If you are claustrophobic or feel uneasy or anxious about this, you need to let the radiographer or radiologist know in advance. Once the scan is underway, you will hear a vibrating sound. You will need to remain still during the scan duration so that the quality of images is not spoilt by motion artifacts. During this time, you will be in constant communication with the radiographer or radiologist.

#### **b) Information for Female Patients**

If you are pregnant or think you might be pregnant, you need to inform the radiographer or radiologist so that the radiologist can discuss your situation with you and your referring doctor.

MRI examinations are not usually done in the first trimester of pregnancy unless the radiologist and your referring doctor feel it is absolutely necessary and the benefits outweigh the risks, and that no other suitable investigation is available.

### **c) MRI Contrast (Dye)**

During your scan, you may need an intravenous injection of a dye known as Gadolinium. The benefit of this dye is that it improves the accuracy of diagnosis and helps visualize diseases which would otherwise be missed.

The gadolinium is administered through a plastic tube called a cannula, which is inserted into a vein in your arm. This procedure is done by a trained and experienced professional. You may experience some pain or discomfort during the insertion into your arm.

In most cases, the injection of contrast is very safe, and no side effects occur. A minority (1 in 3500) of patients may experience minor side effects such as headache, nausea, sneezing or hives (swellings on the skin); which settle very quickly. These can be treated with medication if necessary.

Very rarely, (1 in 1 million), a severe anaphylactic reaction may occur such as difficulty in breathing, difficulty in swallowing, fast heart rate or shock. This requires emergency resuscitation. Despite this, a patient may die, although fortunately it is an extremely rare occurrence (1 in 10 million)

If you have kidney (renal) impairment or failure, you need to indicate this in the safety questionnaire and inform the radiographer or radiologist. If this is the case, you should NOT receive a Gadolinium injection because of the risk of life-threatening NSF (Nephrogenic Systemic Fibrosis).

If you have experienced a contrast related reaction previously to an X-ray, CT or Angiography procedure, you must indicate this in the safety questionnaire and inform the radiographer or radiologist as you are at a higher risk of having a contrast reaction.

If you are a breastfeeding mother, it is safe for you to receive a Gadolinium contrast injection and resume breastfeeding, only 0.0004% of the dose is absorbed by the child, which has been found to have no known adverse effect. If you still have concerns, you may abstain from breastfeeding for 24 hours.

## CONSENT FORM (STATEMENT OF CONSENT)

### Participant's statement

I have read this consent form or had the information read to me. I have had the chance to discuss this research study with a study counsellor. I have had my questions answered in a language that I understand. The risks and benefits have been explained to me. I understand that my participation in this study is voluntary and that I may choose to withdraw at any time. I freely agree to participate in this research study.

I understand that all efforts will be made to keep information regarding my identity confidential.

By signing this consent form, I have not given up any of the legal rights that I have as a participant in a research study.

I agree to participate in this research study: **Yes / No**

**Participant printed name:** \_\_\_\_\_

**Participant signature/thumb stamp:** \_\_\_\_\_ **Date:** \_\_\_\_\_

### Researcher's statement

**I, the undersigned, have fully explained the relevant details of this study to the participant named above and believe that the participant has understood and has willingly and freely given her consent.**

**Researcher's Name:** \_\_\_\_\_ **Date:**  
\_\_\_\_\_

**Researcher's signature:** \_\_\_\_\_

**Role in the study:** \_\_\_\_\_

**Witness** (*If a witness is necessary, a witness is a person mutually acceptable to both the researcher and participant*)

**Name:** \_\_\_\_\_

**Contact information** \_\_\_\_\_

## **APPENDIX C: CONSENT FORM – KISWAHILI**

### **FOMU YA HABARI NA UKUBALI**

**Kichwa cha Utafiti: Spectrum na mifumo ya ugonjwa kwa wagonjwa wanaofanya MRI ya goti katika Hospitali ya Kitaifa ya Kenyatta.**

**Mchunguzi mkuu :** Daktari Patil S.S ( Mwanafunzi wa MMed Radiology, Chuo Kikuu cha Nairobi),

**Wasimamizi:** Daktari Kennedy Kimani (Chuo kikuu cha Nairobi), Daktari Alfred Odhiambo (Chuo Kikuu cha Nairobi)

**Nambari ya mshiriki: - \_\_\_\_\_**

#### **Utangulizi :**

Ningependa kukuambia juu ya utafiti huu uliofanywa na wachunguzi waliotajwa hapo juu . Madhumuni ya fomu hii ni kukupa habari ambayo itakusaidia kuamua ikiwa ni mshiriki wa somo hili au la . Jisikie huru kuuliza maswali yoyote kuhusu madhumuni ya utafiti huu, kile kinachotokea kama wewe kushiriki, hatari na faida, haki yako s kama kujitolea na kitu kingine chochote kuhusu utafiti huu au aina hiyo si wazi. Wakati tumejibu maswali yako yote kukuridhisha, unaweza kuamua kuwa katika utafiti huu au la. Mara tu unapoelewa na kukubali kuwa katika utafiti huu ,Nitakuomba utia saina jina lako katika fomu hii. Lazima kuelewa kanuni za jumla zinazotumika kwa washiriki wote katika utafiti wa matibabu: i ) Y uamuzi wetu wa kushiriki kabisa hiari, ii) Y ou inaweza kujitoa katika utafiti wakati wowote bila lazima kutoa sababu ya kujitoa yako, iii) R efusal ya kushiriki katika utafiti huu hakutaathiri huduma una haki ya katika kituo hiki cha afya au vifaa vingine. Tutakupa nakala ya fomu hii kwa kumbukumbu zako.

#### **Je! Ninaweza kuendelea? NDIO / LA**

#### **Je! Utafiti huu unahusu nini?**

Pamoja ya goti ni moja wapo ya viungo vya kawaida katika mwili wa mwanadamu kuathiriwa na majeraha na ugonjwa mwingine. Madhumuni ya utafiti huu ni kuhakikisha ni aina gani za ugonjwa zitaonekana ndani na karibu na magoti (s) kwa kutumia MRI kama uchunguzi wa kimsingi wa picha. Ulielekezwa na daktari wako na ombi la uchunguzi wa MRI wa goti kufanywa. Kwa hivyo, ningependa kukuajiri katika masomo yangu.

Watafiti zilizoordheshwa hapo juu wanafanya utafiti utafiti ili kujua aina na mitindo ya ugonjwa mbalimbali katika goti kwenye MRI picha ya wagonjwa wanaendelea upigaji huu katika Hospitali ya Taifa ya Kenyatta  
Kenyatta. Takriban washiriki 60 watachaguliwa kushiriki katika utafiti huu. Tunaomba idhini yako kushiriki katika utafiti huu.

### **Ni nini kitatokea kama wewe kuamua kuwa katika hili utafiti?**

Ikiwa unakubali kushiriki katika utafiti huu, mambo yafuatayo yataotokea: Wewe kupitia MRI imaging ya goti katika swali, na matokeo ya ripoti MRI, itakuwa zilizokusanywa kama sehemu ya taarifa ghafi kwa ajili ya utafiti huu.

Tutauliza nambari ya simu ambapo tunaweza kuwasiliana nawe ikiwa ni lazima. Ikiwa unakubali kutoa anwani yako ya mawasiliano, itatumika tu na watu wanaofanya kazi kwa utafiti huu na hawatashirikiwa na wengine kamwe. Sababu ambazo tunaweza kuhitaji kuwasiliana na wewe ni pamoja na kuuliza maswali yoyote ya kufuatilia ikiwa inahitajika au kuthibitisha maelezo yoyote zaidi ikiwa inahitajika.

Ukiamua kushiriki katika utafiti huu, jina lako na habari zingine za kibinafsi HAZITAJALIWA kwenye ripoti ya utafiti na zitahifadhiwa kuwa siri wakati wote. Fomu zinazotumiwa kukusanya data zitaharibiwa baada ya utafiti kumalizika.

### **Je! Kuna hatari, madhara, usumbufu unaohusishwa na utafiti huu?**

Utafiti wa kimatibabu una uwezo wa kuanzisha hatari za kisaikolojia, kijamii, kihemko, na kiafya. Jitihada zitawekwa kila wakati ili kupunguza hatari. Hatari inayowezekana ya kuwa katika utafiti huu ni kupoteza faragha. Tutaweka kila kitu unatuambia kama siri iwezekanavyo. Tutatumia nambari ya nambari kukutambulisha kwenye hifadhidata ya kompyuta inayolindwa na nywila na tutaweka rekodi zako zote za karatasi kwenye kabati la faili lililofungwa. Walakini, hakuna mfumo wowote wa kulinda usiri wako ambao unaweza kuwa salama kabisa, kwa hivyo bado inawezekana kwamba mtu anaweza kugundua kuwa ulikuwa kwenye utafiti huu na angeweza kupata habari kukuhusu.

### **Je! Kuna faida yoyote ya kushiriki katika utafiti huu?**

Hautapata faida yoyote ya ziada au faida kwa kushiriki katika utafiti. Hautapokea zawadi yoyote au zawadi kwa kushiriki katika utafiti huu. Hakutakuwa na fidia ya moja kwa moja ya kushiriki katika utafiti huu. Bado utahitajika kukidhi gharama ya uchunguzi kama ilivyooombwa na daktari wako, na kama ilivyokubaliwa na mtoa huduma wa upigaji picha .

### **Je! Kuwa mgonjwa katika utafiti huu kutagharimu chochote?**

Kushiriki ni bure na kwa hiari kabisa . Hautalazimishwa kushiriki. Una haki ya kukataa kushiriki katika utafiti bila kutoa sababu yoyote, na bila huduma yako ya matibabu au haki za kisheria kuathiriwa.

Ikiwa unaamua kutoshiriki kwenye utafiti, uchunguzi wako wa MRI bado utafanywa (maadamu umekubali na kutimiza mahitaji ya usalama wa MRI). Hautanyimwa skana ambayo daktari amekuuliza upitie. Wewe na daktari wako bado mtapata matokeo ya skana yako, bila kujali ikiwa unashiriki kwenye utafiti.



## **Utarudishiwa pesa uliyotumia kama sehemu ya utafiti huu?**

Hakuna gharama inayohusika katika kushiriki katika utafiti huu. Hautapokea fidia yoyote, iwe kifedha au vinginevyo kwa kushiriki katika utafiti huu .

### **Usiri wa Habari**

Takwimu zote zilizokusanywa katika utafiti wa utafiti zitahifadhiwa kwa siri. Habari inaweza kugawanywa na mtafiti na wasimamizi wa kitivo ambao pia ni madaktari, ili kuwezesha utafiti. Takwimu ambazo zimewasilishwa katika ripoti ya mwisho hazitajumuisha jina lako au habari yoyote ya kibinafsi.

Aina zote zinazotumika kukusanya data zitashughulikiwa kwa ujasiri mkubwa wakati wa kipindi cha utafiti. Nyenzo zote hizo zitaharibiwa mara tu utafiti wa utafiti utakapomalizika.

### **Mawasiliano: vipi ikiwa una swali baadaye?**

Ikiwa una maswali yoyote au wasiwasi juu ya kushiriki kwenye utafiti huu, tafadhali piga simu au tuma ujumbe mfupi kwa mchunguzi mkuu, Dk Sagar Patil , 07 28555701 ama email [sagar.patil.sb89@gmail.com](mailto:sagar.patil.sb89@gmail.com). Hata unaweza kuuliza swali kwa msimamizi mkuu kwenye + 254733870957 ama email [dr\\_aodhiambo@yahoo.com](mailto:dr_aodhiambo@yahoo.com). Kwa habari zaidi juu ya haki zako kama mshiriki katika utafiti huu, unaweza kuwasiliana na katibu / mwenyekiti, hospitali ya kitaifa ya Kenyatta- Kamati ya Maadili na Utafiti ya Chuo Kikuu cha Nairobi nambari ya simu 2726300 , ext - 44102, Barua pepe [uonknh\\_erc@uonbi.ac.ke](mailto:uonknh_erc@uonbi.ac.ke) . Wafanyakazi wa utafiti watakulipa malipo yako kwa nambari hizi ikiwa simu ni ya mawasiliano yanayohusiana na utafiti.

### **Je! Chaguzi zako zingine ni zipi?**

Uamuzi wako wa kushiriki katika utafiti huu ni wa hiari. Wewe ni bure kwa kushuka kushiriki katika utafiti, na wewe unaweza kuondoka kutoka utafiti wakati wowote bila madhara mateso hasi. Utaendelea kupata matunzo na matibabu inahitajika hata ikiwa hutaki kushiriki katika utafiti huu.

### **Ni nini kingine ninahitaji kujua?**

#### **a) MRI ni nini?**

MRI inasimama kwa Upigaji picha wa Magnetic Resonance na hutumia skana ya MRI iliyo na sumaku kali na mawimbi ya redio kuunda picha za kipekee za mwili, haswa tishu laini kama vile viungo, misuli, tendon, mishipa na kadhalika. MRI ni ya faida sana katika kugundua magonjwa na hali ambapo picha ya kawaida ya X-ray na CT scan haitoshi. Tofauti na upigaji picha wa X-ray na CT, MRI haitumii mionzi

hatari ya ionizing. Scan inachukua takriban dakika 25-40. Uga wa sumaku unaozalishwa na sumaku hauna athari mbaya kwa mwili, na ni salama sana. Masomo mengi yamethibitisha hii.

Kwa kuwa MRI hutumia sumaku yenye nguvu, vitu vyote vya metali lazima viondolewe kabla ya kuingia kwenye chumba cha MRI. Unapaswa kujaza dodoso la usalama la MRI kwa usahihi ili kuhakikisha kuwa hakuna kitu cha metali kama vile watengeneza moyo, vipandikizi vya cochlear au screws za mifupa au fimbo ziko ndani ya mwili wako. Hii itakuzuia kufanya uchunguzi wa MRI.

Skana hufanyika mahali funge kwa takriban dakika 25-40 wakati umelala bila kusonga. Ikiwa wewe ni claustrophobic au unajisikia wasiwasi au wasiwasi juu ya hii, unahitaji kumruhusu mtaalam wa radiolojia au mtaalam wa radiolojia ajue mapema. Wakati skana inaendelea, utasikia sauti ya kutetemeka. Utahitaji kubaki kimya wakati wa muda wa skana ili ubora wa picha usiharibiwe na mabaki ya mwendo. Wakati huu, utakuwa unawasiliana kila wakati na mtaalam wa radiolojia au mtaalam wa radiolojia.

#### **b) Habari kwa Wagonjwa wa Kike**

Ikiwa una mjamzito au unafikiria unaweza kuwa mjamzito, unahitaji kumjulisha mtaalam wa radiolojia au mtaalam wa radiolojia ili mtaalam wa radiolojia ajadili hali yako na wewe na daktari wako anayemtaja.

Uchunguzi wa MRI haufanyiki katika trimester ya kwanza ya ujauzito isipokuwa kama mtaalam wa radiolojia na daktari wako anayekuelekeza wanahisi ni muhimu sana na faida huzidi hatari, na kwamba hakuna uchunguzi mwingine unaofaa unaopatikana.

#### **c) Dawa la rangi (Dye)**

Wakati wa skana yako, unaweza kuhitaji sindano ya ndani ya rangi inayojulikana kama Gadolinium. Faida ya rangi hii ni kwamba inaboresha usahihi wa utambuzi na husaidia kuibua magonjwa ambayo ingekosekana.

Gadolinium inasimamiwa kupitia bomba la plastiki linaloitwa branula , ambalo linaingizwa kwenye mshipa kwenye mkono wako. Utaratibu huu unafanywa na mtaalamu aliyefundishwa na uzoefu. Unaweza kupata maumivu au usumbufu wakati wa kuingizwa kwenye mkono wako.

Katika hali nyingi, sindano ya kulinganisha ni salama sana, na hakuna athari mbaya. Wachache (1 kwa 3500) ya wagonjwa wanaweza kupata athari ndogo kama

vile maumivu ya kichwa, kichefuchefu, kupiga chafya au mizinga (uvimbe kwenye ngozi); ambayo hukaa haraka sana. Hizi zinaweza kutibiwa na dawa ikiwa ni lazima.

Mara chache sana, (1 kwa milioni 1), athari kali ya anaphylactic inaweza kutokea kama ugumu wa kupumua, ugumu wa kumeza, kasi ya moyo au mshtuko. Hii inahitaji ufufuo wa dharura. Pamoja na hayo, mgonjwa anaweza kufa, ingawa kwa bahati nzuri ni tukio nadra sana (1 kati ya milioni 10)

Ikiwa una shida ya figo (figo) au kutofaulu, unahitaji kuonyesha hii kwenye dodoso la usalama na kumjulisha mtaalam wa radiolojia au mtaalam wa radiolojia. Ikiwa ndivyo ilivyo, HUPASWI kupokea sindano ya Gadolinium kwa sababu ya hatari ya kutishia maisha NSF (Nephrogenic Systemic Fibrosis).

Ikiwa umewahi kupata athari tofauti inayohusiana hapo awali na X-ray, CT au utaratibu wa Angiografia, lazima uonyeshe hii kwenye dodoso la usalama na umjulishe mtaalam wa radiolojia au mtaalam wa radiolojia kwani uko katika hatari kubwa ya kuwa na athari tofauti.

Ikiwa wewe ni mama anayenyonyesha, ni salama kwako kupata sindano ya kulinganisha ya Gadolinium na kuendelea kunyonyesha, ni 0.0004% tu ya kipimo huingizwa na mtoto, ambayo imeonekana kuwa haina athari mbaya inayojulikana. Ikiwa bado una wasiwasi, unaweza kuacha kunyonyesha kwa masaa 24.

## **FOMU YA MAJALIZO (TAARIFA YA MAJIBU)**

### **Taarifa ya mshiriki**

Nimesoma fomu hii ya idhini au habari hiyo imesomwa kwangu. Nimekuwa na nafasi ya kujadili utafiti huu wa utafiti na mshauri wa utafiti. Nimejibiwa maswali yangu kwa lugha ambayo ninaelewa. Hatari na faida zimeelezewa kwangu. Ninaelewa kuwa ushiriki wangu katika utafiti huu ni wa hiari na kwamba ninaweza kuchagua kujiondoa wakati wowote. Ninakubali kwa hiari kushiriki katika utafiti huu wa utafiti.

Ninaelewa kuwa juhudi zote zitafanywa kutunza habari kuhusu kitambulisho changu kuwa siri.

Kwa kusaini fomu hii ya idhini, sijatoa haki yoyote ya kisheria ambayo ninayo kama mshiriki katika utafiti wa utafiti.

Ninakubali kushiriki katika utafiti huu wa utafiti : **Yes / No**

**Jina la mshiriki aliyechapishwa:**

\_\_\_\_\_

**Saini ya mshiriki / stempu ya kidole gumba:** \_\_\_\_\_

**Tarehe:** \_\_\_\_\_

**Kauli ya mtafiti**

Mimi, aliyesainiwa chini, nimeelezea kabisa maelezo yanayofaa ya utafiti huu kwa mshiriki aliyetajwa hapo juu na ninaamini kwamba mshiriki ameelewa na kwa hiari na kwa hiari ametoa idhini yake.

**Jina la mtafiti:** \_\_\_\_\_ **Tarehe:** \_\_\_\_\_

**Saini ya mtafiti:** \_\_\_\_\_

**Jukumu katika utafiti:** \_\_\_\_\_

**Shahidi** (*mimi ni shahidi ni muhimu, shahidi ni mtu anayekubalika kwa mtafiti na mshiriki*)

**Jina:** \_\_\_\_\_

**Habari ya mawasiliano** \_\_\_\_\_

## APPENDIX D: DATA COLLECTION FORM

A.			
Title of Study: Spectrum of MRI findings in the symptomatic Adult Knee: A 3T MRI Kenyan Perspective			
Investigator: Dr Sagar Patil (M.B.Ch.B), Postgraduate Student, Dept. of Diagnostic Imaging and Radiation Medicine, University of Nairobi			
	Participant Number:	Age:	Sex:
B.			
Brief Clinical History:			
C.			
Indication for Knee MRI:			
D.MRIFindings:			
<i>Fluid:</i>			
<i>Medial compartment:</i>			
Medial meniscus-			
MCL-			
MFCC-			
MTPC-			
<i>Posteromedial Corner:</i>			
Semimembranosus tendon-			
POL-			
<i>Lateral compartment:</i>			
Lateral meniscus-			
LCL-			
LFCC-			
LTPC-			

<b><i>Posterolateral Corner:</i></b>
Popliteus tendon-
Popliteofibular ligament-
Arcuate ligament-
Proximal tibiofibular ligament-
<b><i>Anterior compartment:</i></b>
Alignment-
Quadriceps tendon-
Patellar tendon-
Patellar cartilage-
Trochlear groove-
Trochlear cartilage-
Plica-
Hoffa's fat pad-
TT-TG distance-
<b><i>Intercondylar compartment:</i></b>
<b><i>Anterior cruciate ligament:</i></b>
<b><i>Posterior cruciate ligament:</i></b>
<b><i>Bones:</i></b>
<b><i>Other:</i></b>
<b>IMPRESSION:</b>
<b>COMMENTS/REMARKS:</b>

## APPENDIX E: ETHICAL APPROVAL LETTER



UNIVERSITY OF NAIROBI  
COLLEGE OF HEALTH SCIENCES  
P O BOX 19676 Code 00202  
Telegrams: varsity  
Tel: (254-020) 2726300 Ext 44355

KNH-UoN ERC  
Email: [uonknh\\_erc@uonbi.ac.ke](mailto:uonknh_erc@uonbi.ac.ke)  
Website: <http://www.erc.uonbi.ac.ke>  
Facebook: <https://www.facebook.com/uonknh.erc>  
Twitter: @UONKNH\_ERC [https://twitter.com/UONKNH\\_ERC](https://twitter.com/UONKNH_ERC)



KENYATTA NATIONAL HOSPITAL  
P O BOX 20723 Code 00202  
Tel: 726300-9  
Fax: 725272  
Telegrams: MEDSUP, Nairobi

Ref: KNH-ERC/A/140

16<sup>th</sup> April 2021

Dr. Sagar Suresh Patil  
Reg. No. H58/6420/2017  
Dept. of Diagnostic Imaging and Rad. Medicine  
School of Medicine  
College of Health Sciences  
University of Nairobi



Dear Dr. Patil

RESEARCH PROPOSAL – SPECTRUM AND PATTERNS OF KNEE PATHOLOGY IN ADULT PATIENTS REFERRED FOR MRI TO KENYATTA NATIONAL HOSPITAL: A 3T MRI KENYAN PERSPECTIVE (P686/12/2020)

This is to inform you that the KNH- UoN Ethics & Research Committee (KNH- UoN ERC) has reviewed and **approved** your above research proposal. The approval period is 16<sup>th</sup> April 2021 – 15<sup>th</sup> April 2022.

This approval is subject to compliance with the following requirements:

- a. Only approved documents (informed consents, study instruments, advertising materials etc) will be used.
- b. All changes (amendments, deviations, violations etc.) are submitted for review and approval by KNH-UoN ERC before implementation.
- c. Death and life threatening problems and serious adverse events (SAEs) or unexpected adverse events whether related or unrelated to the study must be reported to the KNH-UoN ERC within 72 hours of notification.
- d. Any changes, anticipated or otherwise that may increase the risks or affect safety or welfare of study participants and others or affect the integrity of the research must be reported to KNH- UoN ERC within 72 hours.
- e. Clearance for export of biological specimens must be obtained from KNH- UoN ERC for each batch of shipment.
- f. Submission of a request for renewal of approval at least 60 days prior to expiry of the approval period. (*Attach a comprehensive progress report to support the renewal*).
- g. Submission of an *executive summary* report within 90 days upon completion of the study.

Protect to discover

This information will form part of the data base that will be consulted in future when processing related research studies so as to minimize chances of study duplication and/ or plagiarism.

For more details consult the KNH- UoN ERC website <http://www.erc.uonbi.ac.ke>

Yours sincerely,



**PROF. M.J. CHINDIA**  
**SECRETARY, KNH-UoN ERC**

c.c. The Principal, College of Health Sciences, UoN  
The Senior Director, CS, KNH  
The Chairperson, KNH- UoN ERC  
The Assistant Director, Health Information Dept, KNH  
The Dean, School of Medicine, UoN  
The Chair, Dept. of Diagnostic Imaging & Radiation Medicine, UoN  
Supervisors: Dr. Alfred Odhiambo, Dept. of Diagnostic Imaging and Rad. Medicine, UoN  
Dr. Nelson M. Kimani, Dept. of Diagnostic Imaging & Rad. Medicine, UoN