



**NORMAL BASE OF SKULL FORAMINA ANATOMY AND  
VARIANTS ON COMPUTED TOMOGRAPHY IN THE  
ADULT POPULATION IN NAIROBI, KENYA.**

**DR. JOAN MOCHAMA**

**H58/34174/2019**

**A DISSERTATION SUBMITTED IN PARTIAL FULFILMENT  
FOR THE AWARD OF MASTER OF MEDICINE IN  
DIAGNOSTIC IMAGING AND RADIATION MEDICINE  
UNIVERSITY OF NAIROBI**

**© 2023**


## STUDENT'S DECLARATION

I, **Dr. Joan Nyasuguta Mochama**, declare that the work contained herein is my original idea and has not been presented at any other university or institution of higher learning to the best of my knowledge.

**Dr. Joan Mochama**

**H58/34174/2019**

Signature: .....



Date: .....

16/11/2025

## SUPERVISORS' APPROVAL


This dissertation has been submitted with our approval as university supervisors.

**Dr. Callen Kwamboka Onyambu,**

M.B.Ch.B. (UON), M.Med. Diagnostic Imaging (UON), PGDRM (UON)

Senior Lecturer Department of Diagnostic Imaging and Radiation Medicine, University of Nairobi

Signature .....



Date .....

16/11/2023

**Dr. Enoch Olando Anyenda,**

BSc (UON), MSc (UON), PhD (Kanazawa University)

Lecturer Department of Diagnostic Imaging and Radiation Medicine, University of Nairobi

Signature .....



Date .....

16/11/2023

## DECLARATION OF ORIGINALITY FORM

### UNIVERSITY OF NAIROBI

This form must be completed and signed for all works submitted to the University for Examination.

Name of student: **Dr. Joan Nyasuguta Mochama**  
Registration Number: **H58/34174/2019**  
Faculty/School/Institute: Faculty of Health Sciences  
Department: Department of Diagnostic Imaging & Radiation Medicine

Course Name: Title of the work: **NORMAL BASE OF SKULL FORAMINA  
ANATOMY AND VARIANTS ON COMPUTED TOMOGRAPHY IN THE  
ADULT POPULATION IN NAIROBI, KENYA.**

#### DECLARATION

1. I understand what Plagiarism is and I am aware of the University's policy in this regard.
2. I declare that this Thesis (Thesis, project, essay, assignment, paper, report etc.) is my original work and has not been submitted elsewhere for examination, award of a degree or publication. Where other people's work, or my own work has been used, this has properly been acknowledged and referenced in accordance with the University of Nairobi's requirements.
3. I have not sought or used the services of any professional agencies to produce this work
4. I have not allowed, and shall not allow anyone to copy my work with the intention of passing it off as his/her own work
5. I understand that any false claim in respect of this work shall result in disciplinary action in accordance with University Plagiarism Policy.

Signature:  Date: 16/11/2023

## DEPARTMENTAL APPROVAL

This dissertation has been presented and approved by the Department of Diagnostic Radiology and Radiation Medicine.

**Dr. Callen Kwamboka Onyambu**

Chairperson

Department of Diagnostic Imaging and Radiation Medicine,

University of Nairobi.

P.O. Box 30197 – 00100, Nairobi

Signature: .....  .....

Date: ..... 16/11/2023 .....

## **DEDICATION**

I dedicate my research to my parents **Mr. John Mochama** and **Mrs. Alice Mochama**

## ACKNOWLEDGEMENTS

I am extremely grateful to God almighty for giving me the courage and wisdom to undertake this study.

I would like to express my utmost gratitude to my supervisor **Dr. Callen Onyambu** for her support, expertise and professional guidance throughout the period of study.

My sincere gratitude to my classmates who encouraged and guided me through the study duration.

Finally, I am grateful to my family and friends for their constant motivation and encouragement.

## TABLE OF CONTENTS

STUDENT’S DECLARATION .....	ii
SUPERVISOR’S APPROVAL .....	iii
DECLARATION OF ORIGINALITY FORM.....	iv
DEPARTMENTAL APPROVAL .....	v
DEDICATION.....	vi
ACKNOWLEDGEMENTS.....	vii
TABLE OF CONTENTS.....	viii
LIST OF TABLES.....	x
LIST OF FIGURES .....	xi
LIST OF ABBREVIATIONS.....	xii
ABSTRACT.....	xiii
1.0 CHAPTER ONE: INTRODUCTION.....	1
2.0 CHAPTER TWO: LITERATURE REVIEW.....	2
2.1 Foramen Ovale .....	3
2.2 Foramen Spinosum.....	4
2.3 Carotid Canal.....	6
2.4 Jugular Foramen.....	7
2.5 Imaging.....	8
2.6 Justification .....	9
2.7 Study Question .....	9
2.8 Objectives.....	9
2.8.1 Broad Objective.....	9
2.8.2 Specific Objectives .....	9
3.0 CHAPTER THREE: STUDY DESIGN AND METHODOLOGY .....	10
3.1 Study Design .....	10
3.2 Study Duration .....	10
3.3 Study Area Description .....	10
3.4 Study Population .....	10
3.5 Inclusion Criteria.....	10
3.6 Exclusion Criteria.....	10
3.7 Sample Size Determination.....	10



3.8 Recruitment and Consenting .....	11
3.9 Study Variables .....	11
3.10 Data Management and Analysis.....	12
3.11 Quality Assurance Procedures .....	12
3.12 Ethical Consideration .....	12
3.13 Confidentiality of Participants .....	13
3.14 Study Limitations .....	13
3.15 Dissemination of Results.....	13
4.0 CHAPTER FOUR: RESULTS .....	14
4.1 Study Demographics .....	14
4.2 Morphometry and Variant Anatomy of The Foramen Ovale.....	14
4.3 Morphometry and Variant Anatomy of The Foramen Spinosum .....	16
4.4 Morphometry and Variant Anatomy of the Carotid Foramen.....	16
4.5 Morphometry and Variant Anatomy of the Jugular Foramen.....	17
5.0 CHAPTER FIVE: DISCUSSION, CONCLUSION AND RECOMMENDATIONS.....	19
5.1 Discussion .....	19
5.1.1 Foramen Ovale .....	19
5.1.2 Foramen Spinosum .....	20
5.1.3 Carotid Foramen .....	21
5.1.4 Jugular Foramen .....	21
5.2 Conclusion.....	22
5.3 Recommendation.....	22
REFERENCES .....	23
APPENDICES .....	29
Appendix A: Consent Information Document .....	29
Appendix B: Consent form (Statement of Consent) .....	32
Appendix C: Fomu ya Idhini Ili Kushiriki Katika Utafiti.....	33
Appendix D: Data Collection Form .....	36
Appendix E: KNH/UoN-ERC Letter of Approval.....	38
Appendix F: Certificate of Plagiarism .....	40

## LIST OF TABLES

Table 1: Estimates for various sample sizes .....	11
Table 2: Age distribution .....	14
Table 3: Comparison of our Foramen Ovale results and data from other population groups ..	19
Table 4: Comparison of our Foramen Spinosum results and data from other population groups .....	20
Table 5: Comparison of Our Carotid Foramen Results and Data from Other Population Groups .....	21
Table 6: Comparison of our Foramen Ovale results and data from other population groups ..	22

## LIST OF FIGURES

Figure 1:Sex distribution chart.....	14
Figure 2:Round foramen Spinosum and Ovale.....	15
Figure 3:Oval foramen Spinosum and Ovale.....	15
Figure 4:Oval carotid foramen. Asymmetry in size of jugular foramen.....	16
Figure 5:Round carotid foramen.....	17
Figure 6:Jugular foramens with spine.....	18
Figure 7:Spineless Jugular foramen.....	18

## LIST OF ABBREVIATIONS

<b>ABS</b>	Anterior base of skull
<b>APD</b>	Antero-posterior diameter
<b>CC</b>	Carotid Canal
<b>CSB</b>	Central Skull Base
<b>CSF</b>	Cerebrospinal Fluid
<b>CT</b>	Computed tomography
<b>FOv</b>	Foramen Ovale
<b>FSp</b>	Foramen Spinosum
<b>HU</b>	Hounsfield Unit
<b>JF</b>	Jugular Foaramen
<b>KNH</b>	Kenyatta National Hospital
<b>ML</b>	Medial lateral
<b>MM</b>	Millimetres
<b>MMA</b>	Middle Meningeal Artery
<b>MRI</b>	Magnetic Resonance Imaging
<b>PN</b>	Pars Nervosa
<b>PV</b>	Pars Vascularis
<b>PSB</b>	Posterior Skull Base
<b>SPSS</b>	Statistical package for social sciences
<b>TD</b>	Transverse Diameter

## ABSTRACT

**Background:** Imaging the base of skull is challenging. This is because of numerous normal variants, complex anatomy, and the unfamiliarity of most radiologists with this region. This area is challenging to examine clinically, therefore CT and MRI are imaging modalities used in its assessment. Anatomical variations may be seen in the foramina in terms of Morphometry (size and shape) and consistency (present or absent). There is no local radiological study to define the average size and variations of skull foramina

**Aim:** To define the average size of some base of the skull foramina and the incidence of foramina variations in the Kenyan adult population.

**Methodology:** A prospective cross-sectional study was carried out at the Kenyatta National Hospital Radiology department from March 2022 to May 2022. Study subjects were 124 with normal base of skull on CT who met the inclusion criteria and consented to be included in the study

**Statistical analysis:** Microsoft Excel spreadsheet was used to enter data which was then exported to Statistical package for social sciences version (SPSS) 23.0. Demographic and morphometric characteristics was analyzed. Categorical data was presented in form of frequencies and percentages while continuous data was presented in form of means with standard deviations. The measurements of the base of skull foramina were analyzed and presented as means with standard deviations. The variant anatomy of the base of skull foramina was analyzed and presented as frequencies and percentages.

**Expected outcome:** The Morphometry and pattern of the variant anatomy of the base of skull foramina will be similar to findings from other studies.

## **1.0 CHAPTER ONE: INTRODUCTION**

The skull base is a complex and central bone structure. It forms the cranial cavity floor. It has numerous foramina through which blood vessels and nerves cross(1). Understanding its anatomy is important for the assessment of pathologic conditions and surgical planning (2).

Imaging the base of skull is challenging. This is because of numerous normal variants, complex anatomy, and the unfamiliarity of most radiologists with this region. This area is difficult to assess clinically and pathologies affecting this region are challenging to biopsy and operate on (3).

CT and MRI are used for the evaluation of patients with symptoms suspected to occur as a result of lesions affecting the central skull base. Comprehensive reports of skull base images by the radiologist are used in directing patient care thus underlining the major role played by the radiologist (3).

Advances over the last 2 decades in imaging of the skull have contributed to the evolution of skull-base surgery. Preoperative imaging information is used for surgical planning by skull-base surgeons and thus enabling them to access places that were earlier considered unapproachable (4).

Anatomical variations may be seen in the foramina in terms of Morphometry (size and shape), consistency (present or absent). Anatomical variations may modify approaches in planned surgeries. Many such anatomical variations are of clinical relevance (5).

## 2.0 CHAPTER TWO: LITERATURE REVIEW

The base of skull is formed by paired frontal, ethmoid, paired temporal, sphenoid, and occipital bones. It forms the cranial cavity floor. Facial structures are separated from the brain by the base of the skull. It can be subdivided into the anterior, middle, and posterior cranial fossae when assessed from above. There are however no separate boundaries for these fossae when assessed from below.

The anterior cranial fossa is separated from the orbits and the paranasal sinuses by the anterior base of skull (ASB). It forms the bottom of the skull anteriorly. The posterior wall of the frontal sinus forms its anterior border while the lesser wing of sphenoid and anterior clinoid processes form its posterior border. The roof of the nasal cavity and ethmoid sinuses form the floor medially while the orbital plates of the frontal bone form the floor laterally (6).

The floor of the middle cranial fossa is formed by the central skull base (CSB). Anteriorly it is formed by the anterior clinoid processes, tuberculum sellae, the lesser and greater wings of the sphenoid. Posteriorly it is formed by the petrous part of the temporal bone and the dorsum sellae (7).

The CSB may further be divided into three, the midline sagittal, parasagittal, and lateral compartments. The parasagittal compartment contains important neurovascular structures such as the cavernous sinus, foramen rotundum, superior orbital fissure, and foramen lacerum. (8).

The posterior surface of the clivus forms the anterior border of the Posterior base of skull (PSB). The petrous temporal bone forms the lateral superiorly while the condylar part of the occipital bone forms the lateral border inferiorly. The posterior border is formed by the squamous occipital and the mastoid temporal bones (9).

Neurosurgeons are now able to access previously inoperable lesions of the skull base due to improvements in microsurgical technique and the use of the operating microscope. Comprehensive knowledge of normal anatomy and pathologies that affect the skull base by the radiologist may help in determining the extent of foramina abnormality and help in planning the surgical approach (10).

The base of skull provides a conduit for various important structures through the numerous foramina found within it. Knowledge of the normal variants of the base of skull is useful in evaluating patients with skeletal dysplasia and disorders of skull base development so that variants are not misreported as fractures, destructive lesions, or chondrocranial malformations (11).

The base of skull foramina that will be evaluated in this study are Foramen Ovale, Foramen Spinosum, Carotid canal, and Jugular foramen

## **2.1 Foramen Ovale**

The foramen Ovale (FOv) is located in the floor of the middle cranial fossa at the base of the greater wing of the sphenoid. It is posterolateral to the foramen rotundum (12).

The FOv connects the infratemporal and middle fossa. Intracranially, it is anterior to the internal carotid artery. The FOv transmits the mandibular nerve the third division of the trigeminal nerve. It may further contain an accessory middle meningeal artery, small emissary veins, and occasionally a small venous plexus connecting the pterygoid plexus to the cavernous sinus (13).

The FOv has been shown to have various shapes in literature. In a study by Deepti et al. (2015) on dry skulls, the most common shape was oval seen in 80%, followed by almond~12%, round ~7%, and slit-shaped in ~2% (14). In a study on 200 head CTs by Shtapak (2021) the results were oval (84%), almond (12.5%), round (1%), slit-like (2%) and irregular (0.5%) (15).

The variations of the FOv are seen in terms of its shape or the presence of bony projections. The contents of the FOv are frequently interrupted by ligaments that can ossify. Ossification of the ligaments may divide it into two compartments. A complete and partial division was seen in 2.8% and 12.8% of cases respectively in a study by Ray et al. (2005) (16). The pterygospinous ligament (ligament of Civinini) that connects the sphenoid spine with the lateral pterygoid process may ossify and hinder access to the FOv(14) (17).

The pterygoalar ligament may ossify resulting in the pterygoalar foramen (Hyrtl's foramen). Ossification of this ligament may potentially result in compression of branches of the mandibular division of the trigeminal nerve (18).

The prevalence of the pterygospinous ligament has been reported as 2.6 - 17% (19), while that of the pterygoalar ligament has been reported as 2.6 - 30% (18).

A spine on the margin of the foramen may divide it into 2 compartments (16). Reymond et al. (2005) reported that in 4.5% of their cases, FOv was divided into 2 or 3 compartments (20). The FOv may be covered by an osseous plate that made it seem absent in the skull as noted by Skratz et al. (2006) (21).

There are different findings in literature in the evaluation of the diameters of FOv in different races. In a developmental study of the Japanese by Yanagi (1987) the average maximal length of FOv was reported 7.48mm (22),7.46 mm in the Nepalese population in a study by Ray et al.



(2005) (16). In a majority of cases, it was found to be oval shape, with average dimensions of  $7.11 \times 3.60$  mm (range  $5 \times 2$  mm to  $8 \times 7$  mm) in a study by Berge et al.(2001) (23).

In a study by Kanyata et al. (2015) on dry skulls in the Kenyan population, the right FOv was found to measure 7.69 mm on the right and 7.68mm on the left. (24). The mean length and breadth in males were  $7.75 \pm 1.16$ ,  $3.98 \pm 0.91$ , and in females, measurements were  $6.90 \pm 0.78$ ,  $3.57 \pm 1.04$  respectively in a CT study by Shtapak (2021) (15). Erbagci et al. (2010) found the average size of FOv to be  $3.7 \times 8.2$  mm on the right and  $4.1 \times 7.6$  mm on the left on a CT study in the Turkish population (25). Berlis et al. (1992) recorded measurements of  $4.2 \pm 0.87$ mm (breadth) and  $7.67 \pm 1.43$ mm (length) in a CT study in Germany (26).

Baskar et al. (2021) found the mean length of the left FOv to be  $8.5 \pm 1.32$ mm and the right was  $8.9 \pm 1.67$ mm in the South Indian population (27). Boduc et al. (2021) found the average length to be  $7.05 \pm 1.43$  mm in the Turkish population (28). Osunwoke et al. (2010) found the average length of the right FOv to be  $7.01 \pm 0.10$ mm and the left  $6.89 \pm 0.09$ mm in the Southern Nigerian population. (29).

As FOv is an important foramen used for diagnostic and therapeutic invasive procedures, knowledge of the comprehensive anatomy of FOv helps in identifying abnormal foramina during cross-sectional imaging. (16,20,22).

The FOv is therapeutically important to both neurosurgical and functional cranial neuroanatomy. The Meckel's cave can be accessed through it for procedures such as radiofrequency trigeminal rhizotomy and balloon compression. These procedures are used to alleviate symptoms of trigeminal neuralgia. FOv provides a transcutaneous approach to the skull base, as the Gasserion ganglion can be approached through it (20,30). Anatomical variations such as elongated or enlarged sphenoid spines that can obstruct and prevent glycerolrhizolysis as reported by Tubbs et al. (2009) should be kept in mind during such procedures (17). Variants such as pterygoalar and pterygospinous ligaments may compress mandibular nerve branches resulting in sensory loss and mastication weakness (18).

## **2.2 Foramen Spinosum**

The foramen spinosum (FSp) is posterolateral to the FOv in the middle cranial fossa. The middle meningeal artery and vein, and the meningeal branch of the oculomotor nerve pass through it. The FSp derives from the first pharyngeal arch within the sphenoid. It begins to ossify eight months after birth but may take up to seven years to develop fully into its bony ring-shaped formation (31).

The average size of the FSp was  $2.4 \times 2$  mm (range  $1 \times 1$  to  $4 \times 3$  mm) in a study by Berge et al. (2001) (23) and 2.6mm in a study by Yanagi (1987) in Japan (22). In a study on dry skulls in Turkey by Unver et al. (2014) the mean length of FSp was 2.90 mm with a standard deviation  $\pm 1.19$ mm and  $\pm 0.67$ mm on the right and left respectively (19). A CT study by Berlis et al. (1992) recorded measurements of  $1.86 \pm 0.60$ mm (breadth) and  $2.42 \pm 0.71$ mm (length) in Germany. (26)

Osunwoke et al. (2010) found the mean of the length of the right FSp to be  $2.34 \pm 0.05$ mm while that of the left was  $2.36 \pm 0.05$ mm in Southern Nigerian skulls (29). In a study on Ethiopian skulls, Worku et al. (2021) found the mean anteroposterior diameter (APD) of the FSp was 3.72mm and 3.37 mm on the right and left sides, respectively. The average transverse diameter (TD) was 3.3mm on the right side and 2.97 mm on the left side (32). The mean value of the length of foramen spinosum was  $2.05 \pm 1.09$ mm on right and  $2.05 \pm 0.60$ mm on left in a study by Chanda et al. (2019) in India (33).

The middle meningeal artery (MMA) normally arises from the maxillary artery. In variants such as absence of the FSp, it may be seen to arise from the ophthalmic artery. This may also be seen when the artery enters the cranial vault via the FOv. This is however rare and was seen in 1% of skulls in a study carried out by Berge et al. (2001) (23)

The absence of FSp is usually a normal variation seen in up to 3% of skull base CT studies which may be due to abnormal development and a different course of MMA. In such cases, MMA arises from the ophthalmic artery and enters the skull through the superior orbital fissure (34).

A rare congenital vascular anomaly known as persistent stapedia artery may also result in an absent or hypoplastic FSp (35).

Duplication of the FSp may be due to early division of the middle meningeal artery into anterior and posterior divisions. Congenital variants of the FSp occur as a result of defects in the development of the middle meningeal artery. Variations such as medial defects of the FSp asymmetry or absence of the FSp have been reported with a frequency of 26.8%, 16%, and 3.2% respectively. Duplication of the FSp is very rare (36).

Khan et al. (2012) studies of dry skulls revealed absent left FSp which was confluent with FOv on the same side. (37).

The FSp is an anatomical landmark. It is used as a guide during the microsurgical procedures involving the middle cranial fossa. The estimated distance between the FOv and FSp may facilitate localization of the FOv for percutaneous cannulation (38, 39).

## 2.3 Carotid Canal

The location of the Carotid canal (CC) is the apex of the petrous temporal bone in the middle cranial fossa (40, 41). The anterior limit of the CC is the posterior margin of the greater wing of the sphenoid bone while posteromedially it is the occipital bone (41). The CC is divided into the ascending and transverse petrous and ascending cavernous parts (42, 43). The CC transmits the internal carotid artery, internal carotid venous plexus, and sympathetic nerve plexus (44). CC has internal and external openings. The foramen lacerum is medial to the internal opening of the CC (41, 45). The Jugular foramen (JF) is posterior to the internal and external openings of the CC are anterior to the JF (40).

In a study carried out in the Turkish population by Özalp et al. (2019) (46), the length and width of the external CC were reported to be  $8.02 \pm 1.09$  mm and  $6.86 \pm 0.90$  mm on dry skulls. On CT, it was  $7.89 \pm 1.14$  mm in length and  $6.41 \pm 0.90$  mm in width. The external aperture was observed to be rounded in 62.5%, oval in 32.5%, and tear-drop shaped in 5% of cases. Berlis et al. (1992) recorded an ML measurement of 5.69mm on CT and APD measurements of 7.81 mm on dry skulls and 7.91mm on CT studies in the German population (26).

The ML diameter of the external CC was 7.52 mm in a study by Naidoo et al. (2017) (47) on dry skulls in South Africa which was larger than 5.27 mm reported by Watanabe et al. (2010) (48) and 5.00 mm by Yamamoto et al. (1987) (49) in the Japanese population.

Naidoo et al. (2017) reported the APD to be 5.41mm in a study in the south African population. (47). Yamamoto et al. (1987). recorded measurements of 4.9mm in the Japanese population (49). Calguner et al. (1997) (50) and Somesh et al. (2014) (40) recorded measurements of 6.75 mm in the population in Antolia and 8.14mm in the Indian population respectively.

Pupovac et al. (2021) (51) found the average width of the external aperture of the carotid canal to be  $5.85 \pm 1.45$  mm and  $6.17 \pm 1.57$  mm on right and left respectively in the Serbian population. CT angiography demonstrates the congenital absence of the carotid canal which is prevalent in 0.01% of CT of the skull base (52,53). It is mostly unilateral but may occasionally be bilateral (54).

A small carotid canal is associated with congenital lesions such as hypoplasia of the internal carotid artery and should not be confused with acquired pathologies which cause diffuse narrowing of the internal carotid such as segmental stenosis, a dissecting aneurysm, and fibromuscular dysplasia (54).

The knowledge of CC dimensions is essential, first, for the repair of carotid canal fractures, agenesis, or stenosis; second, for the treatment of diseases such as aneurysms or schwannoma

of structures passing through the carotid canal; and lastly, for morphometric distance evaluation with adjacent foraminal regions such as jugular foramen and foramen spinosum. (46,48,50)

## **2.4 Jugular Foramen**

The otic capsule and the basioccipital plate form the Jugular foramen (JF). It runs between the petrous temporal bone and the condylar occipital bone (55). Its course is oblique (56). The caroticojugular spine separates it from the CC anteromedially and the jugular tubercle separates it from the hypoglossal canal. The 'eagle's head' shape of the jugular tubercle helps to locate and separate the JF from the hypoglossal canal (6).

A septum divides the JF into antero-medial Pars nervosa (PN) and postero-lateral Pars vascularis (PV). The septum may be bony or fibrous. The PN is smaller than the PV and more constant in size. The glossopharyngeal nerve and the inferior petrosal sinus traverse it. The PV is larger than the PN but its size varies. It transmits the internal jugular vein, vagus nerve, accessory nerve, and posterior meningeal artery. (57)

A bony plate separates the JF from the hypotympanum. The caroticojugular spine separates the anteromedially placed CC from it while the jugular tubercle separates it from the hypoglossal canal (57)

The appearance of the JF is variable. Occasionally both the glossopharyngeal and the vagus nerves cranial nerves pass through the PN. The right JF is usually larger than the left in up to 75% of the population (57). In a study by Idowu (2004) side predominance of one of the JF was seen in 80% of cases. The predominance was 55% on the right and 25% on the left (58). In a CT study by Shtapak (2018) the Shape of JF was found to be irregular in all images reviewed. It was however not divided into Pars Nervosa and Pars Vascularis in only 3% of cases. Any intrusion in this foramen may lead to the obstruction and impingement of the structures present within, presenting clinically like Vernet's syndrome due to meningiomas. Obstruction can also be caused by paragangliomas (59).

In a study carried out by Aseta et al. (2016) in Kenya on dry skulls, septation was present in 96.2% of jugular foramina. The mean APD was  $11.17 \pm 2.05$ mm on the right and  $8.88 \pm 2.30$ mm on the left. The ML dimensions were  $17.47 \pm 2.18$ mm on the right and  $15.30 \pm 2.53$ mm on the left. The right JF showed larger dimensions than the left JF in 81.9% for the APD and 78.1% for the ML dimension (60).

In a study by Manawy et al. (2019) (61) in Egypt on dry skulls, the mean AP diameters were  $6.8 \pm 2.39$  mm on the right and  $5.4 \pm 1.58$  mm on the left. ML dimensions were (right –  $17.2 \pm 4.6$ mm on the right and  $14.6 \pm 2.07$ mm on the left.

In a study by Osonukwe et al. (2012) on dry skulls in Southern Nigeria, the mean length of the JF was found to be  $15.76 \pm 0.22$  mm and  $13.39 \pm 0.23$  mm on the right and left respectively. The mean width was  $9.34 \pm 0.18$  mm on the right and  $7.54 \pm 0.20$  mm on the left. The right JF was found to be larger than the left (62).

Saheb et al. (2015) found the mean length and width of the foramen to be  $24.48 \pm 3.17$  mm and  $7.51 \pm 1.56$  mm on the right and  $21.24 \pm 4.51$  mm and  $7.16 \pm 1.89$  mm on the left in the South Indian population (63). In a study by Kumar et al. (2019) the mean TD and APD of the JF on CT were  $13.43 \pm 2.47$  mm and  $7.82 \pm 1.88$  mm on the left and  $14.83 \pm 2.62$  mm and  $9.28 \pm 2.03$  mm on the right side (64).

Lang et al. (1983) recorded measurements of  $9 \times 17.0$  mm on the outer surface of the skull and  $7 \times 14.5$  mm on the internal skull base in the German population (65). Vlajkovic et al. (2010) found the ML diameter of the right and left JF to be 14.21 mm and 13.24 mm respectively in the Serbian population (66). Barros et al. (2021) recorded ML measurements of 16.61 mm on the right and 15.79 mm on the left in the Northeast Brazilian population (67). Skrzat et al. (2016) recorded measurements of 3.6–16.6 mm for the AP diameter and 7.8–23.1 mm for ML diameter in the Turkish population (68).

Tumors involving the JF may arise from within such as glomus jugulare tumors and schwannomas of the glossopharyngeal, vagus, and accessory nerves, or from structures surrounding the foramen, such as meningioma, chondrosarcomas, and metastases (69).

Advanced JF lesions may be removed by microsurgical procedures by neurosurgeons thus the need for familiarity with the detailed anatomy of the JF (70). Morphological studies provide useful information for anatomists, anthropologists, forensic and radiological practice (71).

## **2.5 Imaging**

The commonly used imaging modalities for assessment of the base of the skull are plain film, CT, and MRI. Plain film has been replaced by CT and MRI. Multislice Ct scanners can acquire thin sections of up to 0.5 to 0.6 mm and perform multiplanar reconstruction which allows for a more thorough evaluation of the base of skull. Acquired images are then reviewed using the bone window. CT best defines the bony anatomy and cortical margins of the base of skull foramina. MRI has an edge over CT in defining the contents of the foramina (57).

The skull base should be evaluated in two planes, axial and coronal, using 1.5 -3mm thin slices. A bone algorithm with a wide window setting of up to (4000HU) is used. If the coronal head position cannot be tolerated when obtaining direct coronal images, reconstructed images can be obtained from overlapping, thin axial scans measuring 1.5-2 mm (58).

## **2.6 Justification**

There are no local radiological studies done to ascertain the Morphometry and variant anatomy of various skull foramina in the Kenyan population. My study, therefore, aims at creating a local database on the size and variant anatomy of skull foramina on CT. Knowledge of the size and incidence of variations of base of skull foramina may aid in the diagnostic evaluation of radiologic images of the base of skull. This study aims to define the average size of some base of the skull foramina and the incidence of foramina variations. This will enable radiologists and researchers examining the foramina to have anatomical references.

## **2.7 Study Question**

- a. What is the normal morphometric measurement of base of skull foramina in people of African descent on head CT?
- b. What is the pattern of variant anatomy in base of skull foramina in people of African descent on CT?

## **2.8 Objectives**

### **2.8.1 Broad Objective**

To assess the Morphometry and anatomical variants of the base of skull foramina as seen on CT.

### **2.8.2 Specific Objectives**

- To measure anteroposterior & Transverse diameters of the Foramen Ovale, Foramen Spinosum, Carotid canal, and Jugular foramen by computed tomography.
- To establish the pattern of variant anatomy of base of skull foramina of the Foramen Ovale, Foramen Spinosum, Carotid canal, and Jugular foramen by computed tomography.

### **3.0 CHAPTER THREE: STUDY DESIGN AND METHODOLOGY**

#### **3.1 Study Design**

This was prospective cross-sectional study

#### **3.2 Study Duration**

The study was carried out in a period of 3 months starting March 2022 to May 2022

#### **3.3 Study Area Description**

Department of radiology, Kenyatta National Hospital (KNH). There are 2 CT machines at KNH. Siemens SOMATOM Definition AS+ 128 slices and NeuViz 64-slice computed tomography scan machines. An average of 120 Head CT scans is performed every month.

#### **3.4 Study Population**

All adult patients referred for head CT at KNH

#### **3.5 Inclusion Criteria**

All consenting adult patients undergoing head CT with normal base of skull CT

#### **3.6 Exclusion Criteria**

- Disease or tumor involving skull base.
- Patients with skull base fracture.
- Any congenital anomaly involving skull base.
- Patients who underwent surgery of the skull base.
- Patients who declined consent
- Patients aged less than 18 years.
- Scans with motion artifacts

#### **3.7 Sample Size Determination**

The sample size was 124 CT scans of the head

Sample Size was calculated using Fisher's formula:

$$n = \frac{(Z_{1-\alpha/2})^2 SD^2}{d^2}$$

$n$  = Desired sample size

$Z_{1-\frac{\alpha}{2}}$  = value from standard normal distribution corresponding to desired confidence level

( $Z=1.96$  for 95% CI)

**SD** = Standard deviation taken from a previous study

**d** = Precision (average differences from other mean measurements)

$$n = \frac{1.96)^2 1.31^2}{0.23^2} = 124$$

Using the formula, the following various estimates for sample size value were obtained. The largest value was used for the study. The Foramen Ovale had the highest number as shown in the table and thus was used for the study. Therefore, a sample size of 124 CT scans of the head were required for the study.

**Table 1: Estimates for various sample sizes**

	<b>Mean</b>	<b>From Study</b>	<b>Sample Size</b>
Foramen Ovale	<b>7.69 ± 1.31 mm</b>	<b>Kanyata et al (2015)</b>	<b>124</b>
Foramen Spinosum	<b>2.90±1.19 mm</b>	<b>Unver et al (2014)</b>	<b>56</b>
Carotid canal	<b>8.02±1.09 mm</b>	<b>Özalp et al (2019)</b>	<b>50</b>
Jugular foramen	<b>14.83±2.62 mm</b>	<b>Kumar et al (2012)</b>	<b>32</b>

### 3.8 Recruitment and Consenting

Patients who met the inclusion criteria were recruited from the radiology department of KNH. A simple random selection of patients presenting for a CT scan of the head at the radiology department was used. A consent form was provided. The participants were informed in a language they understand of the purpose of the study, that participation was voluntary and would not influence their ongoing treatment.

### 3.9 Study Variables

- Antero-posterior diameter
- Transverse diameter
- Type of variant anatomy
- Age
- Gender



### **3.10 Data Management and Analysis**

Demographic information was obtained from patient records. All patients who met the inclusion criteria were incorporated into the study. Head CT images acquired by NeuViz 64-slice computed tomography scan machine employed at KNH were evaluated. CT head axial section scans with no evidence of disease that might alter foraminal anatomy, from picture archiving & communication system (PACS) were reviewed independently by the primary investigator and verified by the supervisor consultant radiologist. Computer-assisted measurements of foraminal parameters were obtained for both right and left sides in the bone window.

Microsoft Excel spreadsheet was used to enter data which was then be exported to Statistical package for social sciences version (SPSS) 23.0. Demographic and morphometric characteristics were analyzed. Categorical data was presented in form of frequencies and percentages while continuous data was presented in form of means with standard deviations. The measurements of the base of skull foramina were analyzed and presented as means with standard deviations. The variant anatomy of the base of skull foramina were analyzed and presented as frequencies and percentages.

### **3.11 Quality Assurance Procedures**

The protocol that was used for the acquisition of head CT images at the KNH radiology department is a slice thickness of 5mm in the brain window with a reconstruction of 1mm slice thickness in the bone window. The window width that was used is 3000HU and Kvp of 120, effective mAs of up to 382, collimation of 128×0.6mm, exposure time per rotation of 1 second and pitch of 0.5 ratio.

Axial scans were obtained from the level of the base of skull to the vertex with reconstructions in adult patients who had consented to the study. Studies devoid of motion artifacts were used.

### **3.12 Ethical Consideration**

Prior to the commencement of this study, ethical approval was sought from the KNH and University of Nairobi Ethical Review committee. Institutional approval was sought from the KNH Scientific and Research department and the Department of Radiology. Participation in the study was voluntary and consented to both verbally and in writing. Patients were not subjected to additional procedures /expenses/risks by participating in the study. Patients included in the study were referred by clinicians and only those with justifiable requests had

Head CT. Ethical guidelines were employed in line with the World Medical Association Declaration of Helsinki

### **3.13 Confidentiality of Participants**

Restricted access to patient data. Only authorized persons were allowed to access participant records. All electronic databases were password protected and all records were stored in a locked cabinet. There were no identifiers linking research data to patients and each study patient was assigned a unique numerical code.

### **3.14 Study Limitations**

Breakdown of CT machines during the study. There was no reference standard for measurement of base of skull foramina on CT as a majority of studies were conducted on Dry skulls.

### **3.15 Dissemination of Results**

The findings of this study will be disseminated through the Department of Diagnostic Imaging and radiation medicine, University of Nairobi Library, and published in peer-reviewed journals.

## 4.0 CHAPTER FOUR: RESULTS

Head CT images of 124 patients with normal base of skull were reviewed.

### 4.1 Study Demographics

The distribution of ages ranged from 19 to 64 years. The mean age of the patients was 36.2 ±11.5 years. The overall gender distribution was (62.9%) Male and Females (37.1%).

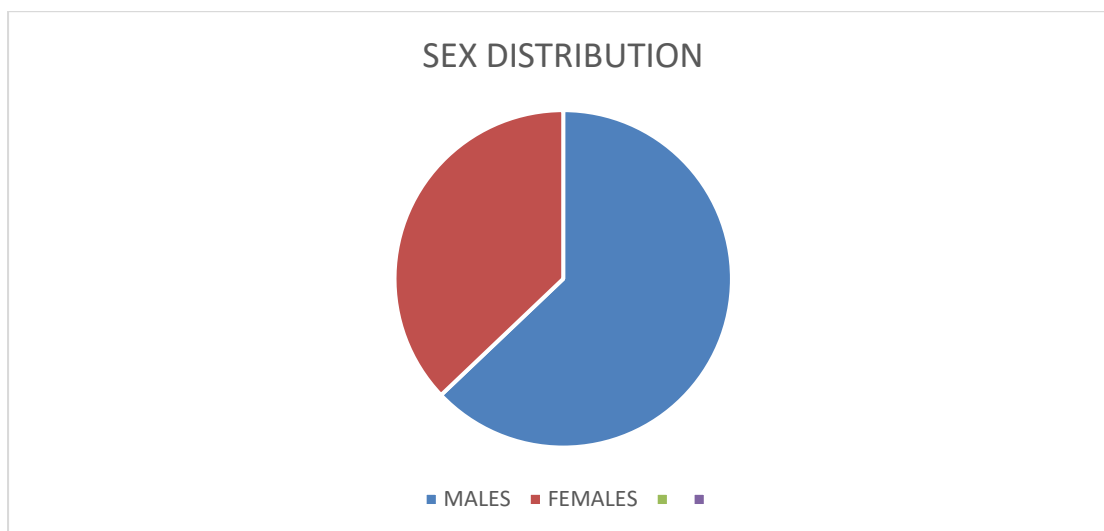


Figure 1:Sex distribution chart

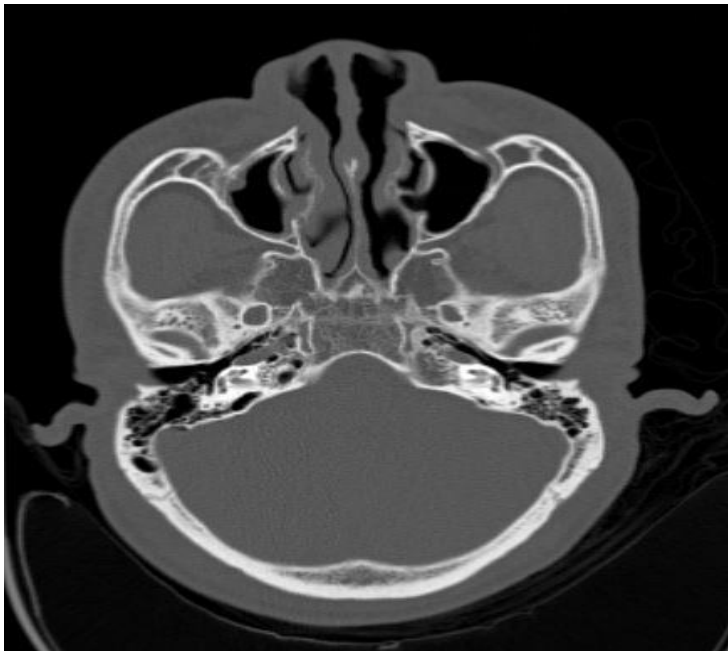Table 2:Age distribution

	Frequency (n=124)	Percent
<b>Age</b>		
≤20	9	7.3
21 – 30	39	31.5
31 – 40	33	26.6
41 – 50	29	23.4
>50	14	11.3
<b>Sex</b>		
Male	78	62.9
Female	46	37.1

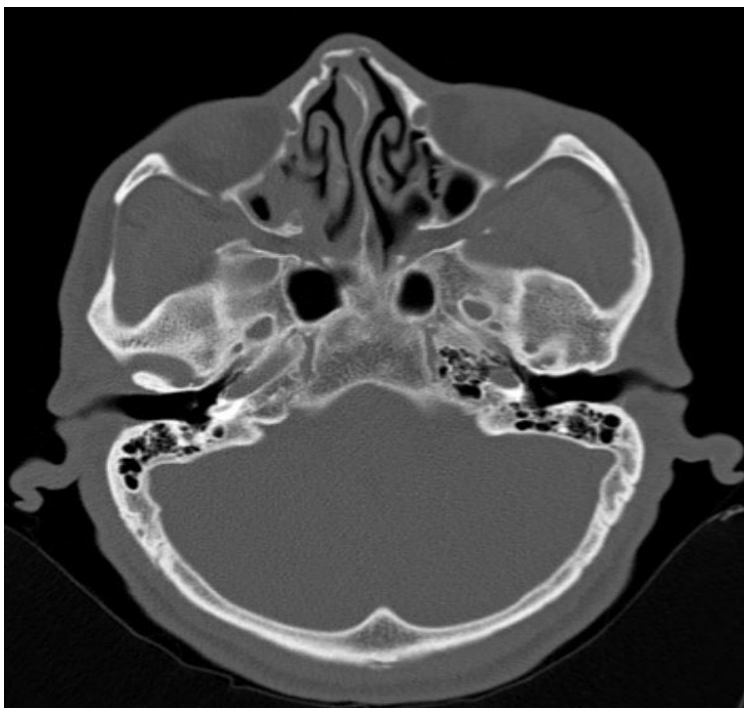
### 4.2 Morphometry and Variant Anatomy of The Foramen Ovale

The Foramen Ovale was present bilaterally in all the head CTs reviewed. The predominant shape was oval seen in 95.2 % and round in 4.8% of images reviewed No bony projections were seen within the F.Ov.

The mean measurements were an Antero-Posterior (AP) of  $7.50\pm 0.99\text{mm}$  and Medio-lateral diameter of  $4.08\pm 0.86\text{mm}$  on the Right. The Left side measured  $7.27\pm 0.93\text{mm}$  (AP) and  $3.97\pm 0.75\text{mm}$  (ML).



**Figure 2: Round foramen Spinosum and Ovale**



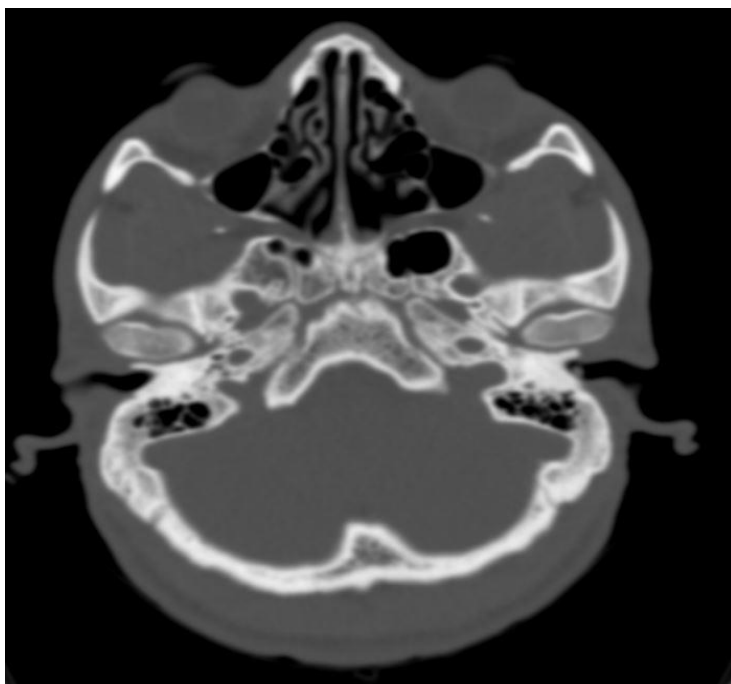
**Figure 3: Oval foramen Spinosum and Ovale**

#### **4.3 Morphometry and Variant Anatomy of The Foramen Spinosum**

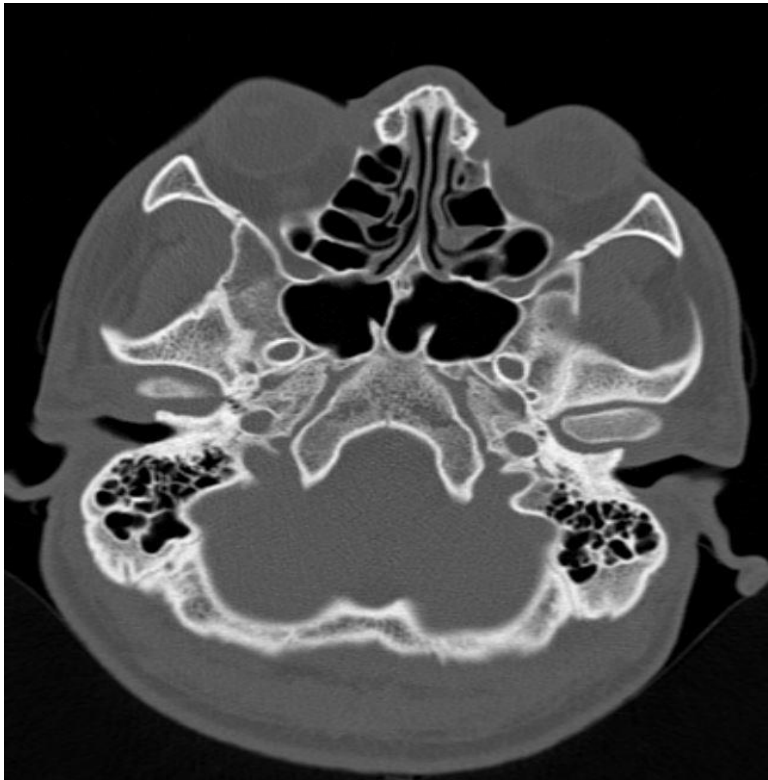The Foramen Spinosum was present bilaterally in all the head CTs reviewed. The predominant shape was round seen in 92.8 % and oval in 7.2% of images reviewed. The mean measurements were an Antero-Posterior (AP) of  $2.00\pm 0.39$ mm and a Medio-lateral diameter of  $1.90\pm 0.35$  mm on the Right. The Left side measured  $1.98\pm 0.39$ mm (AP) and  $1.86\pm 0.35$ mm (ML).

#### **4.4 Morphometry and Variant Anatomy of the Carotid Foramen**

The Carotid Foramen was present bilaterally in all the head CTs reviewed. The predominant shape was round seen in 69.4 % and oval in 30.6% of images reviewed, the mean measurements were an Antero-Posterior (AP) of  $5.58\pm 0.67$ mm and a Medio-lateral (ML) diameter of  $6.40\pm 0.72$ mm on the Right. The Left side measured  $5.32\pm 0.73$ mm (AP) and  $6.10\pm 0.88$ mm (ML).



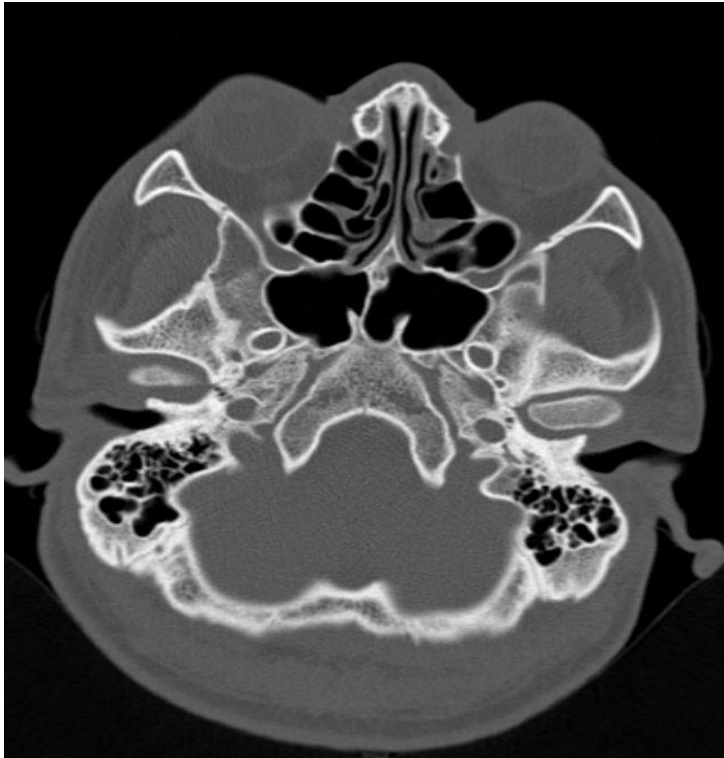
**Figure 4:Oval carotid foramen. Asymmetry in size of jugular foramen**



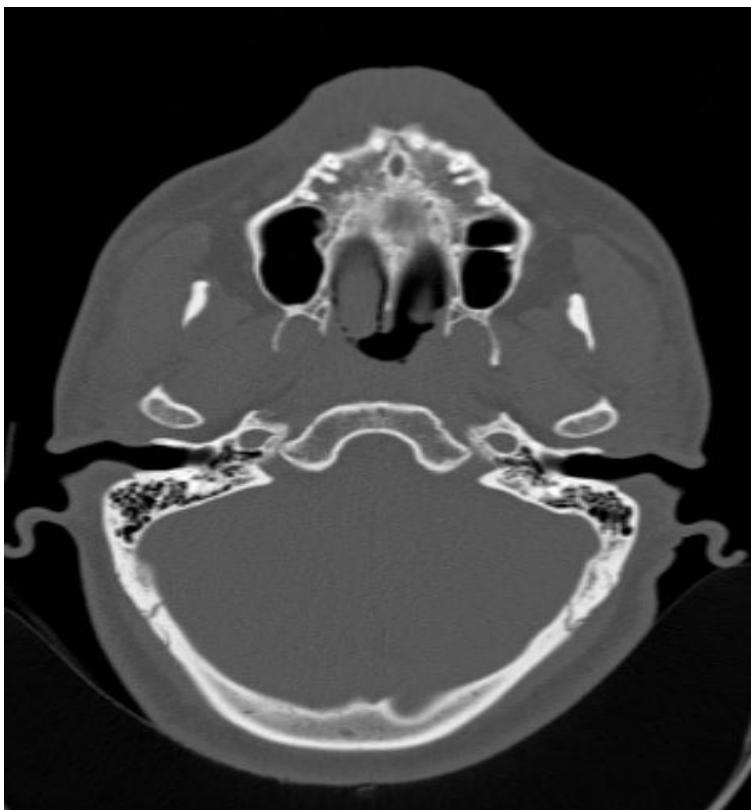**Figure 5:Round carotid foramen**

#### **4.5 Morphometry and Variant Anatomy of the Jugular Foramen**

The Jugular Foramen was present bilaterally in all the head CTs reviewed. It was irregular in shape in all images reviewed. A spine was present in 90.4% of CTs reviewed dividing the jugular foramen into Pars Nervosa and Pars vascularis. The mean measurements were an Antero-Posterior (AP) of  $10.65 \pm 2.03$ mm and Medio-lateral (ML) diameter of  $13.51 \pm 2.80$ mm on the Right. The Left side measured  $9.93 \pm 2.15$ mm (AP) and  $12.85 \pm 2.41$ mm (ML).



**Figure 6:Jugular foramens with spine**



**Figure 7:Spineless Jugular foramen**

## 5.0 CHAPTER FIVE: DISCUSSION, CONCLUSION AND RECOMMENDATIONS

### 5.1 Discussion

Previous anatomical studies on base of skull foramina have been carried out mostly on dry skulls. Calipers are used to measure the external or internal openings of the various base of skull foramina. Studies on dry skulls demonstrated differences in the size, shape and anatomical variations between different population groups. In the current study CT images of the base of skull in the bone window were reviewed.

#### 5.1.1 Foramen Ovale

The shape of the foramen Ovale was found to be predominantly Oval which was consistent with findings from other studies (14,15,29). Other shapes reported shapes include irregular, slit like and almond. There were no bony septations seen in this study. A study by Reymond et al. (12) reported a bony septation in 4.5% of cases. There is no statistical difference between the mean AP and ML measurements of the Foramen Ovale on the right and left. The P-value f was 0.058 for the AP and 0.260 for the ML measurement. This is consistent with findings from other studies (24,25,29)

**Table 3: Comparison of our Foramen Ovale results and data from other population groups**

STUDIES	AP RIGHT	ML RIGHT	AP LEFT	ML LEFT
Osunwoke et al. (2010) Southern Nigeria (87)	7.01±0.10	3.37± 0.07	6.89± 0.09	3.33±0.07
Baskar et al. (2021) South Indian	8.9±1.67		8.5±1.32	
Kanyata et al. (2015) Kenya DS (200)	7.69 ± 1.31	4.24 ± 0.64	7.68 ± 1.23	4.28 ± 0.74
Erbagci et al. (2010) Turkey (24) CT	8.2	3.7	7.6	4.1
Our study (124)	7.50±0.99	4.08±0.86	7.27±0.93	3.97±0.75

\*Measurements in Millimetres



A comparison of our results against data provided by Baskar et al. and Osunwoke et al. using an independent t-test showed that our measurements are significantly different from other populations. Our measurements were smaller than what was recorded in the South Indian population and Turkish population by Baskar et al. and Erbagci et al. respectively.

Our measurements were larger than what was reported in the Southern Nigeria by Osunwoke et al. Our results on the right were comparable to results from dry skulls in the Kenyan population by Kanyata et al.

### 5.1.2 Foramen Spinosum

Variations in shape were seen. The round shape was most common in our study which is comparable to findings from other studies (32,33).

The foramen Spinosum was present bilaterally in all the images reviewed. This was comparable to findings by Osunwoke et al. (29). It was however seen to be absent in 1% of skulls in some studies (23,32).

There is no statistical difference between the mean AP and ML measurements of the Foramen spinosum on the right and left. The P-value was 0.52 for the AP and 0.39 for the ML measurement. This is consistent with findings from other studies (29,32,33).

**Table 4: Comparison of our Foramen Spinosum results and data from other population groups**

	Right AP	ML	Left AP	ML
Worku et al. (2021) Ethiopia (64)	3.72 ± 1.33	3.3 ± 1.19	3.37 ± 1.26	2.97 ± 1.9
Chanda et al. (2019) India (30)	2.05 ± 1.09	1.33 ± 0.9	2.05 ± 0.60	1.67 ± 0.5
Osunwoke et al. (2010) Nigeria (87)	2.34 ± 0.05	1.66 ± 0.03	2.36 ± 0.05	1.61 ± 0.03
Unver et al. (2014) Turkey (62)	2.9 ± 1.19	1.90 ± 0.41	2.9 ± 0.67	2.01 ± 0.47
Our study (124)	2.00 ± 0.39	1.90 ± 0.35	1.98 ± 0.39	1.86 ± 0.35

\*Measurements in Millimeters

A comparison of our results against population data provided by Unver et al., Osunwoke et al., Worku et al. and Chanda et al. using an independent t-test showed that our measurements are significantly smaller than results from other populations

### 5.1.3 Carotid Foramen

The commonest shape of the carotid foramen was round which was consistent with findings from other studies (26,40).

The carotid foramen was present in 100% of CTs evaluated. This was in line with findings from other studies (46,47). Congenital absence of the carotid canal was prevalent in 0.01% skull bases according to a study by Pupovac et al. (51).

There is no statistical difference between the mean ML measurements of the Carotid foramen on the right and left. The P-value was 0.79 for the ML measurement (46,51).

The AP measurement of the right Carotid foramen was larger than the left with a P value of 0.004. Naidoo et al. reported that the AP measurement was larger on the left (46). There were however no statistically significant differences in size between the right and left carotid foramen noted in a study by Pupoval et al. (51)

**Table 5: Comparison of Our Carotid Foramen Results and Data from Other Population Groups**

CAROTID FORAMEN	AP RIGHT	ML RIGHT	AP LEFT	ML LEFT
Ozalp et al. (2019) Turkey (20)	7.90±1.08	6.34±0.91	7.87±1.23	6.49±0.91
Somesh et al (2014) India (82)	8.12 ± 0.99	6.31 ± 0.64	8.15 ± 1.00	6.19 ± 0.80
Pupovac et al. (2021) Serbia (60)	7.31±1.01	5.85±1.45	7.71±1.06	6.17±1.57
Our study	5.58±0.67	6.40±0.72	5.32±0.73	6.37±0.78

\*Measurements in Millimetres

A comparison of our results against population data provided by Ozalp et al., Somesh et al. and Pupovac et al. using an independent t-test showed that our AP measurements are significantly smaller compared to other populations

### 5.1.4 Jugular Foramen

The jugular foramen was irregular in all images reviewed and a spine present in a majority of cases consistent with findings from other studies (59,60,64)

The right Jugular foramen is larger than the left. There is a significant statistical difference between the mean AP and ML measurements of the Jugular foramen on the right and left. The P-value was 0.007 for the AP and 0.001 for the ML measurement. This is comparable to findings from other studies (60,62).

**Table 6: Comparison of our Foramen Ovale results and data from other population groups**

JUGULAR FORAMEN	AP RIGHT	ML RIGHT	AP LEFT	ML LEFT
Aseta et al. (2016) Kenya (105)	11.17 ±2.05	17.47 ±2.18	8.88 ±2.30	15.30 ±2.53
Osonukwe et al. (2012) (Nigeria (120)	9.34±0.18	15.76±0.22	7.54±0.20	13.39±0.23
Kumar et al. (2019) India(CT)(30)	9.28 ± 2.03	14.83 ± 2.62	7.82 ± 1.88	13.43 ± 2.47
Ekinci et al. (1997) Turkey(70)	8.4 ± 1.9	16.0 ± 2.5	7.6 ± 1.7	15.5 ± 2.6
Pereira et al. (2009) Brazil(111)	9.21 ± 1.95	15.82 ± 2.67	8.65 ± 1.57	15.86 ± 2.64
Our study	10.65±2.03	13.51±2.80	9.93±2.15	12.85±2.41

\*Measurement in Millimeters

A comparison of our results against other population data using an independent t-test was done. Our AP measurements were significantly larger than measurements from other populations. Our AP Measurement on the right was however comparable to findings by Aseta et al. on dry skulls in the Kenyan population. The ML measurement was smaller compared to findings from other populations except for the measurement on the left which was comparable to findings by Kumar et al. in the Indian population

## 5.2 Conclusion

Head CT Imaging can be used in morphometric and variant anatomy evaluation of Base of skull foramina. Variable morphometric measurements and anatomic variations were noted in comparison with different population groups. Differences may also be attributed to differences in the method used in the study, subjective interpretation of the researchers who conducted the study and possibly a genetic element because of differences between populations in different geographic locations

## 5.3 Recommendation

Larger multicentre studies should be done for comparison of findings

## REFERENCES

1. Lieberman, D. E., Ross, C. F., & Ravosa, M. J. (2000). The primate cranial base: Ontogeny, function, and integration. *American Journal of Physical Anthropology*, 43(Suppl 31), 117–169.
2. McBratney-Owen, B., Iseki, S., Bamforth, S. D., Olsen, B. R., & Morriss-Kay, G. M. (2008). Development and tissue origins of the mammalian cranial base. *Developmental Biology*, 322, 121–132.
3. Dobre, M. C., & Fischbein, N. (2014). ‘Do not touch’ lesions of the skull base. *Journal of Medical Imaging and Radiation Oncology*, 58, 458–463.
4. Curtin, H. D., & Chavali, R. (1998). *Imaging of the skull base. Radiologic Clinics of North America*, 36, 801–817, v–vi.
5. Yammine, K. (2014). Evidence-based anatomy. *Clinical Anatomy (New York, N.Y.)*, 27(6), 847–852.
6. Harnsberger, R., Hudgins, P., Wiggins, R. et al. (2004). Diagnostic imaging head and neck(1e). AMIRSYS.
7. Som, P. M., & Curtin, H. D. (2002). *Head and Neck Imaging (4 e)*. Elsevier Health Sciences.
8. Borges, A. (2009). Imaging of the central skull base. *Neuroimaging Clinics of North America*, 19(3), 441–468.
9. Chong, V. F. H., Khoo, J. B. K., & Fan, Y. F. (2004). Imaging of the nasopharynx and skull base. In *Neuroimaging Clinics of North America* (Vol. 14, Issue 4, pp. 695–719). Neuroimaging Clin N Am.
10. Laine, F. J., Nadel, L., & Braun, I. F. (1990). CT and MR imaging of the central skull base. Part 1: Techniques, embryologic development, and anatomy. *Radiographics*, 10(4), 591–602.
11. Madeline, L. A., & Elster, A. D. (1995). Postnatal development of the central skull base: Normal variants. *Radiology*, 196(3), 757–763.
12. Reymond, J., Charuta, A., & Wysocki, J. (2005). The morphology and morphometry of the foramina of the greater wing of the human sphenoid bone. *Folia Morphologica*, 64(3), 188–193.

13. Edwards, B., Wang, J. M., Iwanaga, J. et al. (2018). Cranial Nerve Foramina Part I: A Review of the Anatomy and Pathology of Cranial Nerve Foramina of the Anterior and Middle Fossa. *Cureus*, 10(2), e2172.
14. Deepti A. J & Thenmozhi,(2015) Anatomical variations of Foramen Ovale, *Journal of Pharmaceutical Sciences and Research*, Vol. 7(6), 327-329.
15. Sthapak, E. (2021). A CT Study to examine Morphometry and anatomical Variations of Foramen Ovale. *The FASEB Journal*, 35(S1). Advance online publication.
16. Ray, B., Gupta, N., & Ghose, S. (2005). Anatomic variations of foramen ovale. *Kathmandu University Medical Journal*, 3(1), 64–68.
17. Tubbs, R. S., May, W. R., Jr., Apaydin, N. et al. (2009). Ossification of ligaments near the foramen ovale: An anatomic study with potential clinical significance regarding transcutaneous approaches to the skull base. *Neurosurgery*, 65(6, Suppl), 60–64.
18. Kamath B. K., & K, V. (2014). Anatomical Study of Pterygospinous and Pterygoalar Bar in Human Skulls with their Phylogeny and Clinical Significance. *Journal of Clinical and Diagnostic Research : JCDR*, 8(9), AC10.
19. Unver Dogan, N., Fazlıogulları, Z., İlknur Uysal, I. et al. (2014). Anatomical examination of the foramina of the middle cranial fossa. *International Journal of Morphology*, 32(1)
20. Skrzat, J., Walocha, J., Srodek, R. et al. (2006). An atypical position of the foramen ovale. *Folia Morphologica*, 65(4), 396–399.
21. Yanagi, S. (1987). [Developmental studies on the foramen rotundum, foramen ovale, and foramen spinosum of the human sphenoid bone]. *The Hokkaido Journal of Medical Science*, 62(3), 485–496.
22. Berge, J. K., & Bergman, R. A. (2001). Variations in size and in symmetry of foramina of the human skull. *Clinical Anatomy (New York, N.Y.)*, 14(6), 406–413.
23. Kanyata, D., Odula, P., Nyamai, L. A. et al. (2015). Morphology and Location of Surface Landmarks of Foramen Ovale in Kenyans. *International Journal of Morphology*, 33(2), 471–475.
24. Erbagci, H., Kizilkan, N., Sirikci, A. et al. (2010). Computed tomography based measurement of the dimensions of foramen ovale and rotundum in trigeminal neuralgia. *Neurosciences (Riyadh)*, 15(2), 101–104.
25. Berlis, A., Putz, R., & Schumacher, M. (1992). Direct and CT measurements of canals and foramina of the skull base. *The British Journal of Radiology*, 65(776), 653–661.

26. Baskar, S. S., & Karthick, S. (2021). MORPHOMETRIC AND MORPHOLOGICAL STUDY ON FORAMEN OVALE. *Global Journal for Research Analysis*, 21–22, 21–22. Advance online publication.
27. Boduc, E., & Ozturk, L. (2021). Morphometric Analysis and Clinical Importance of Foramen Ovale. *European Journal of Therapeutics*, 27(1), 45–49.
28. Osunwoke, E. A., Mbadugha, C. C., Orish, C. N. et al. (2009). A morphometric study of foramen ovale and foramen spinosum of the human sphenoid bone in the southern Nigerian population. *Journal of Applied Biosciences*, 26, 1631–1635.
29. Kaplan, M., Erol, F. S., Ozveren, M. F. et al. (2007). Review of complications due to foramen ovale puncture. *Journal of Clinical Neuroscience*, 14(6), 563–568.
30. Khairnar, K. B., & Bhusari, P. A. (2013). An anatomical study on the foramen ovale and the foramen spinosum. *Journal of Clinical and Diagnostic Research: JCDR*, 7(3), 427–429.
31. Worku, M. G., & Clarke, E. (2021). Morphometric analysis of the foramen spinosum and variations of its shape, number, and relation to the spine of the sphenoid bone. *Translational Research in Anatomy*, 24, 100124. Advance online publication.
32. Chanda, C., Singh, K. K. P., Ranjan, R. et al. (2019). Anatomical Variations of Foramen Spinosum in Adult Human Skulls of Jharkhand Population. *IOSR Journal of Dental and Medical Sciences (IOSR-JDMS) e-ISSN*, 18, 1–07. <https://doi.org/10.9790/0853-1804180107>
33. Manjunath K.Y. (2001) Anomalous Origin of The Middle Meningeal Artery-A review J Anat Soc India, 50:179-183
34. Dilenge, D., & Ascherl, G. F., Jr. (1980). Variations of the ophthalmic and middle meningeal arteries: Relation to the embryonic stapedia artery. *AJNR. American Journal of Neuroradiology*, 1, 45–54.
35. Ginsberg, L. E., Pruett, S. W., Chen, M. Y. et al. (1994). Skull-base foramina of the middle cranial fossa: Reassessment of normal variation with high-resolution CT. *AJNR. American Journal of Neuroradiology*, 15(2), 283–291.
36. Khan, A., & Hassan, A. (2012). Anatomic Variants of Foramen Ovale and Spinosum in Human Skulls. *International Journal of Morphology*, 30, 445–449.
37. Zdilla, M. J., Hatfield, S. A., & Mangus, K. R. (2016). Angular Relationship Between the Foramen Ovale and the Trigeminal Impression: Percutaneous Cannulation Trajectories for Trigeminal Neuralgia. *The Journal of Craniofacial Surgery*, 27(8), 2177–2180.

38. Zdilla, M. J., Hatfield, S. A., McLean, K. A. et al. (2016). Orientation of the Foramen Ovale: An Anatomic Study With Neurosurgical Considerations. *The Journal of Craniofacial Surgery*, 27(1), 234–237.
39. Somesh, M. S., Sridevi, H. B., Murlimanju, B. V. et al. (2014). Morphological and Morphometric Study of the carotid canal in Indian Population. *International Journal of Biomedical Research*, 5(7), 455–460.
40. Standring, S. (2008). *Gray's Anatomy: The Anatomical Basis of Clinical Practice*. Elsevier Ltd.
41. Teufel, J. (1964). Einbau der Arteria carotis interna in den Canalis caroticus unter Berücksichtigung des transversalen Venen-abflusses. *Morphologisches Jahrbuch.*, 106, 188–274.
42. Faiz, O., & Moffat, D. (2002). *Anatomy at a Glance*. Blackwell Science Ltd.
43. Moore, K. L., Dalley, A. F., & Agur, A. M. R. (2010). *Clinically Oriented Anatomy* (6th ed.). Lippincott Williams & Wilkin.
44. Özalp, H., Beger, O., Erdoğan, O. et al. (2019). Morphometric Assessment of the Carotid Foramen for Lateral Surgical Approach. *The Journal of International Advanced Otolaryngology*, 15(2), 222–228.
45. Naidoo, N., Lazarus, L., Ajayi, N. O. et al. (2017). An anatomical investigation of the carotid canal. *Folia Morphologica*, 76(2), 289–294. Advance online publication.
46. Watanabe, A., Omata, T., Koizumi, H. et al. (2010). Bony carotid canal hypoplasia in patients with moyamoya disease. *Journal of Neurosurgery. Pediatrics*, 5(6), 591–594.
47. Yamamoto, M., Jimbo, M. & Ide, M. (1987). X-ray CT study of the carotid canal. *International Atomic Energy Agency*, 9(6): 659–664
48. Calgüner, E., Turgut, H. B., Gözil, R. et al. (1997). Measurements of the carotid canal in skulls from Anatolia. *Acta Anatomica*, 158(2), 130–132.
49. Pupovac, N., Pekić, S., Erić, M. et al. (2021). Morphological And Morphometric Analysis Of The External Aperture Of The Carotid Canal In Serbian Population.
50. Chen, C. J., Chen, S. T., Hsieh, F. Y. et al. (1998). Hypoplasia of the internal carotid artery with intercavernous anastomosis. *Neuroradiology*, 40(4), 252–254.
51. Pilleul, F., Guibaud, L., Badinand, N. et al. (2001). Bilateral internal carotid agenesis: Value of CT angiography and correlation to embryogenesis. *European Radiology*, 11(5), 858–860.

52. Osborn, A. G. (1999). *Diagnostic cerebral angiography* (2nd ed.). Lippincott Williams & Wilkins.
53. Ayeni, S. A., Ohata, K., Tanaka, K. et al. (1995). The microsurgical anatomy of the jugular foramen. *Journal of Neurosurgery*, 83(5), 903–909.
54. Lo, W. W., & Solti-Bohman, L. G. (1984). High-resolution CT of the jugular foramen: Anatomy and vascular variants and anomalies. *Radiology*, 150(3), 743–747.
55. Harnsberger, R., Osborn, A. G., Ross, J. S. (2006). *Diagnostic and surgical imaging anatomy: brain, head and neck, spine*. Amirsys Inc.
56. Idowu, O. E. (2004). The jugular foramen — A morphometric study. *Folia Morphologica*, 63(4), 419–422.
57. Sthapak, E. (2018). Anatomical variations of Jugular Foramen and its clinical implication: CT Study. *Neurosciences & Brain Imaging*, 2(1).
58. Aseta, F. B., Mwachaka, P. M., Mandela, P. I. et al (2016). Variant Anatomy of the Jugular Foramen: An Osteological Study. *Academia Anatomica International*, 2(2).
59. Manawy, S., & El-Sawaf, E. (2019). Study the anatomical variation of the Jugular Foramen in Egyptian dry skulls (Morphological and Morphometric studies). *The Journal of American Science*, 15(5), 17–25.
60. Osunwoke, E., Oldipo, G., Gwunireama, I. U. et al. (2012). Morphometric analysis of the foramen magnum and jugular Foramen in adult skulls in Southern Nigerian population. *AM J Sci Ind Res*. 3. 446-448.
61. Saheb, S., Shruthi B. N., Havaladar, P. et al. (2015). Morphometric Study of Jugular Foramen. *International Journal of Medical Sciences*, 2, 164–166.
62. Kumar, A., Tripathi, A., Raizaday, S. et al. (2019). Anatomical and Radiological Study of Jugular Foramen. *National Journal of Clinical Anatomy*., 08, 121–125. Advance online publication.
63. Lang, J., & Schreiber, T. (1983). Uber Form und Lage des Foramen jugulare (Fossa jugularis), des Canalis caroticus und des Foramen stylomastoideum sowie deren postnatale Lageveränderungen. *HNO*, 31, 80–87.
64. Vlajković, S., Vasović, L., Daković-Bjelaković, M. et al. (2010). Human bony jugular foramen: Some additional morphological and morphometric features. *Medical Science Monitor*, 16(5), BR140–BR146.



65. Barros, P. M., José J.C., Elayne C.O., et al. (2021) Relationship between jugular foramen dimensions and neurocranium shape, *Translational Research in Anatomy*, Volume 24, 100129, ISSN 2214-854X
66. Skrzat, J., Mróz, I., Spulber, A. et al. (2016). *Morphology, topography, and clinical significance of the jugular foramen*. *FOLIA MEDICA CRACOVIENSIA* Vol. LVI, 1, 71–80
67. Samii, M., & Tatagiba, M. (1996). Tumors of the Jugular Foramen. *Neurosurgery Quarterly*, 6, 176–193. Advance online publication
68. Tekdemir, I., Tuccar, E., Aslan, A., Elhan, A., Deda, H., Ciftci, E., & Akyar, S. (1998). The jugular foramen: A comparative radioanatomic study. *Surgical Neurology*, 50, 557–562.
69. Saheb, H. S., Mavishetter, G. F., Thomas, S. T. et al. (2010). Morphometric study of the jugular foramen in human adult skulls of South India. *J Biomed Sci Res.*, 2, 240–243.
70. Parmar, H., Gujar, S., Shah, G. et al. (2009). Imaging of the anterior skull base. *Neuroimaging Clinics of North America*, 19, 427–439.
71. Laine, F. J., Nadel, L., & Braun, I. F. (1990). CT and MR imaging of the central skull base. Part 2. Pathologic spectrum. *Radiographics*, 10, 797–821.

## APPENDICES

### Appendix A: Consent Information Document

#### **PARTICIPANT INFORMATION AND CONSENT FORM SAMPLE ADULT CONSENT FOR ENROLLMENT IN THE STUDY**

(To be administered in English or any other appropriate language e.g., Kiswahili translation)

**Title of Study: Normal Base of Skull foramina anatomy and variants on computed tomography in people of African descent in Nairobi, Kenya.**

**Principal Investigator and institutional affiliation: DR. JOAN N. MOCHAMA,  
RESIDENT AT UNIVERSITY OF NAIROBI, DEPARTMENT OF DIAGNOSTIC  
IMAGING AND RADIATION MEDICINE**

#### **Introduction:**

I would like to tell you about a study being conducted by the above-listed researcher. The purpose of this consent form is to give you the information you will need to help you decide whether or not to be a participant in the study. Feel free to ask any questions about the purpose of the research, what happens if you participate in the study, the possible risks and benefits, your rights as a volunteer, and anything else about the research or this form that is not clear. When we have answered all your questions to your satisfaction, you may decide to be in the study or not. This process is called 'informed consent'. Once you understand and agree to be in the study, I will request you to sign your name on this form.

You should understand the general principles which apply to all participants in medical research:

- i) Your decision to participate is entirely voluntary
- ii) You may withdraw from the study at any time without necessarily giving a reason for your withdrawal
- iii) Refusal to participate in the research will not affect the services you are entitled to in this health facility or other facilities.

We will give you a copy of this form for your records.

May I continue? YES / NO

This study has approval by The Kenyatta National Hospital-University of Nairobi Ethics and Research Committee protocol No. \_\_\_\_\_

**What Is This Study About?**

The study is about evaluating the anatomy of the base of skull foramina. Participants in this research study will also have their CT Head images reviewed. No additional investigations or tests will be required. There will be approximately 124 participants in this study randomly chosen. We are asking for your consent to consider participating in this study.

**What Will Happen If You Decide to Be in This Research Study?**

If you agree to participate in this study, the following things will happen: Informed Consent will be obtained. Your head CT images will be reviewed by the principal investigator and measurements of the base of skull foramina entered into a database for analysis.

**Are There Any Risks, Harms Discomforts Associated with This Study?**

This study involves the use of X-rays which is a form of ionizing radiation which may have some adverse effects. Proper protocols will be used to limit the radiation dose.

Medical research has the potential to introduce psychological, social, emotional, and physical risks. Efforts should always be put in place to minimize the risks. One potential concern of being in the study is the loss of privacy. We will keep everything you tell us as confidential as possible. We will use a code number to identify you in a password-protected computer database and will keep all of our paper records in a locked file cabinet.

**Are There Any Benefits Being in This Study?**

The information obtained from the review of your Head CT images will be used to create a local database of the anatomy of skull base foramina in the Kenyan population so that researchers and clinicians examining the foramina may have an anatomical reference. This will be a significant contribution to science.

**Will Being in This Study Cost You Anything?**

No additional costs will be incurred.

**What Are Your Other Choices?**

Your decision to participate in research is voluntary. You are free to decline participation in the study and you can withdraw from the study at any time without injustice or loss of any benefits.

### **What If You Have Questions in Future?**

If you have further questions or concerns about participating in this study, please call or send a text message to the study staff at the number provided at the bottom of this page.

For more information about your rights as a research participant, you may contact the following persons.

Secretary, Kenyatta National Hospital-University of Nairobi Ethics and Research Committee  
Telephone No. 2726300 Ext. 44102 email [uonknh\\_erc@uonbi.ac.ke](mailto:uonknh_erc@uonbi.ac.ke).

Supervisor: Dr. Callen Onyambu, Telephone number +254721539987

The study staff will pay you back for your charges to these numbers if the call is for study-related communication.

## **Appendix B: Consent form (Statement of Consent)**

### **Participant's statement**

I have read this consent form or had the information read to me. I have had the chance to discuss this research study with a study counselor. I have had my questions answered in a language that I understand. The risks and benefits have been explained to me. I understand that my participation in this study is voluntary and that I may choose to withdraw at any time. I freely agree to participate in this research study. I understand that all efforts will be made to keep information regarding my identity confidential. By signing this consent form, I have not given up any of the legal rights that I have as a participant in a research study.

I agree to participate in this research study: Yes/ No

I agree to provide contact information for follow-up: Yes /No

Participant \_\_\_\_\_ printed \_\_\_\_\_ name:

Contact (mobile number): \_\_\_\_\_

Participant signature / Thumb stamp \_\_\_\_\_ Date \_\_\_\_\_

### **Researcher's statement**

I, the undersigned, have fully explained the relevant details of this research study to the participant named above and believe that the participant has understood and has willingly and freely given his/her consent.

Researcher's Name: Dr. Joan Mochama Date: \_\_\_\_\_

Signature \_\_\_\_\_

Role in the study: Principal investigator.

For more information contact Dr. Joan Mochama at 0724838422 from 8 am to 5 pm, all weekdays.

## **Appendix C: Fomu ya Idhini Ili Kushiriki Katika Utafiti**

**Kichwa cha Utafiti: Anatomia ya foramina ya msingi wa fuvu kutumia miale ya X-ray.**

**Mpelelezi mkuu na ushirika wa kitaasisi: DR. JOAN N. MOCHAMA, MWANAFUNZI WA SHAHADA YA UZAMILI KATIKA RADIOLOGY. CHUO KIKUU CHA NAIROBI, IDARA YA RADIOLOGY**

Napenda kukuambia juu ya utafiti unaofanywa na mtafiti aliyeorodheshwa hapo juu. Madhumuni ya fomu hii ya idhini ni kukupa habari utahitaji kukusaidia kuamua ikiwa sio mshiriki katika utafiti. Jisikie huru kuuliza maswali yoyote juu ya madhumuni ya utafiti, nini kinatokea ikiwa unashiriki katika utafiti, hatari na faida zinazowezekana, haki yako kama kujitolea, na kitu kingine chochote kuhusu utafiti au fomu hii ambayo haij wazi. Wakati tumejibu maswali yako yote kwa kuridhika kwako, unaweza kuamua kuwa kwenye masomo au la. Utaratibu huu unaitwa 'ridhaa iliyo na habari'. Mara tu utakapoelewa na kukubali kuwa katika masomo, nitakuomba utie saina jina lako kwenye fomu hii.

Unapaswa kuelewa kanuni za jumla zinazotumika kwa washiriki wote katika utafiti wa matibabu:

- i. Uamuzi wako wa kushiriki ni hiari kabisa
- ii. Unaweza kujiondoa kutoka kwa masomo wakati wowote bila kutoa sababu ya kujiondoa kwako
- iii. Kukataa kushiriki katika utafiti hautaathiri huduma unayostahiki katika kituo hiki cha afya au vifaa vingine.

Tutakupa nakala ya fomu hii kwa rekodi zako.

Naweza kuendelea? NDIO LA

Utafiti huu umedhibitishwa na Itifaki ya Kamati ya Maadili ya Kitaifa ya Kenya ya Chuo Kikuu cha Maadili na Utafiti cha Nairobi.

### **Hili Ndani ya Kufunda Hili?**

Utafiti huu una nia ya kuchambua anatomia ya foramina ya msingi wa fuvu. Picha za CT ya kichwa ya ashiriki wa utafiti huuzitachambuliwa Hakuna uchunguzi wa ziada au vipimo vitakavyohitajika. Kutakuwa na washiriki takriban 124 katika utafiti huu waliochaguliwa kwa nasibu. Tunaomba idhini yako kufikiria kushiriki katika utafiti huu.

### **Nini Kitakuwaje Kama Utaona Kuwa Katika Fundo Hili La Utafiti?**

Ikiwa unakubali kushiriki katika utafiti huu, picha zako za kichwa za CTI zitafanyiwa uchambuzi na mtafiti mkuu na foramina itapimwa na kufanyiwa uchambuzi

### **Je Kuna Hakuna Athari Zaidi, Dhambi Za Kiumbusho Zinazoonekana Na Dunia Hii?**

Katika harakati ya kuchukua picha miale ya X-ray itatumika na yanaweza kuwa na madhara. Itifaki zitatumika kupunguza kipimo ya mionzi.

Hatari moja ya uwezekano wa kuwa katika utafiti ni kupoteza faragha. Tutaweka kila kitu unachotwambia kama siri iwezekanavyo. Tutatumia nambari ya kukutambulisha katika hifadhidata ya kompyuta iliyolindwa na nywila na tutaweka rekodi zetu zote za karatasi katika baraza la mawaziri lililofungwa.

Je! Kuna faida zozote za kupata ndani ya masomo haya? Utafiti huu utatoa msingi utakaosaidia wanaradiologia na watafiti kuelewa foramina ya msingi wa fuvu zaidi. Habari hii ni mchango kwa sayansi

### **Kuwa Kujifunza Kwenye Fundi Hilo Kuliweza Kufanya Chochote?**

Hakuna gharama za ziada zitakazopatikana.

### **Nini Kuna Kesho Zako Zaidi?**

Uamuzi wako wa kushiriki katika utafiti ni wa hiari. Uko huru kukataa kushiriki katika masomo na unaweza kujiondoa kutoka kwa masomo wakati wowote bila dhulma au upotezaji wa faida yoyote.

### **Nini Kama Una Maswali Kwa Fedha?**

Ikiwa una maswali zaidi au wasiwasi juu ya kushiriki katika utafiti huu, tafadhali piga simu au tuma ujumbe wa maandishi kwa wafanyikazi wa utafiti kwa nambari iliyotolewa chini ya ukurasa huu.

Kwa habari zaidi juu ya haki zako kama mshiriki wa utafiti unaweza kuwasiliana na watu wafuatayo.

Katibu, Hospitali ya Kitaifa ya Kitaifa ya Chuo Kikuu cha maadili cha Kenya na Kamati ya Utafiti ya Nambari ya 2726300 Ext. 44102 barua pepe [uonknh\\_erc@uonbi.ac.ke](mailto:uonknh_erc@uonbi.ac.ke).

Msimamizi: Dr. Callen Onyambu, Namba ya simu +254721539987

Wafanyikazi wa masomo watakulipa kwa malipo yako kwa nambari hizi ikiwa simu ni ya mawasiliano yanayohusiana na masomo.

**Kichwa Cha utafiti: Anatomia ya foramina ya msingi wa fuvu kutumia miale ya X-ray.**

**Jina la Mtafitu: Dr. Joan N. Mochama, mwanafunzi wa Shahada ya Uzamili Katika Radiology Chuo Kikuu cha Nairobi, Idara ya Radiology.**

Mimi ninathibitisha kuwa nimesoma na kuelewa au nimeelezwa na kuelewa hati ya ‘‘Consent Information Document’’ kwa ajili ya utafiti huu. Nimepewa fursa ya kuuliza maswali ambayo majibu yao yamekuwa ya kutosha. Ninaelewa kuwa ushirika wangu ni wa hiari na kwamba sijalazimishwa kushiriki. Naelewa kwamba naweza kukataa bila ya kutoa sababu yoyote, bila ya huduma ya matibabu yangu au haki za kisheria kuathirika. Ninaelewa kwamba sitapokea fidia yoyote, fedha au vinginevyo, na sitapokea matibabu yoyote ya upendeleo, zawadi au tuzo, kwa ajili ya kishirika katika utafiti huu. Ninaelewa kwamba taarifa yangu binafsi itakuwa siri, lakini kwamba yoyote husika matibabu, habari kuhusu matokeo ya uchunguzi wangu na taarifa zilizokusanywa itakuwa itapatikana kwa mtafiti, na inaweza kuangaliwa na wasimamizi wake.

Mimi nawapa ruhusa ya kuwa na upatikanaji wa habari hii.

Ninatoa idhini ya kushiriki katika utafiti huu Ndio/ La

Ninatoa idhini ya kuwapa nambari zangu za simu: Ndio/ La

Jina la mshiriki: \_\_\_\_\_

Nambari ya simu \_\_\_\_\_

Sahihi/muhuri wa kidole: \_\_\_\_\_ Tarehe: \_\_\_\_\_

Jina la mzazi/ mlezi anayetoa idhini kwa mshiriki ambaye ni mdogo:

\_\_\_\_\_

Sahihi/muhuri wa kidole: \_\_\_\_\_ Tarehe: \_\_\_\_\_

Jina la mtafiti: **Dkt. Joan Mochama**

Tarehe: \_\_\_\_\_ Sahihi: \_\_\_\_\_

Kwa maelezo zaidi wasiliana na Dr. Joan Mochama kwa nambari ya simu 074838422 kutoka 8 asubuhi mpaka 5 jioni, siku za wiki



## Appendix D: Data Collection Form

**Title: Normal Base of Skull foramina anatomy and variants on computed tomography in people of African descent in Nairobi, Kenya**

**Investigator:** Dr. Joan N. Mochama, Resident Department of Diagnostic Imaging and Radiation Medicine, University of Nairobi

### Biodata

Age .....

Gender .....

Xray Number.....

Date Of Examination .....

Patient's Unique Number.....

### Foramen Ovale

	Right	Left
Maximum Anteroposterior Diameter (mm)		
Maximum Mediolateral Diameter (mm)		

	Oval	Round	Almond	Slit	Irregular	Other
Shape						

### Variant Anatomy

Absent	
Spine	

### Foramen Spinosum

	RIGHT	LEFT
Maximum Anteroposterior Diameter (mm)		
Maximum Mediolateral Diameter(mm)		

	Oval	Round	Almond	Slit	Irregular	Other
Shape						

**Variant Anatomy**

<b>Absent</b>	
<b>Duplication</b>	
<b>Confluent With Foramen Ovale</b>	

**Carotid Canal**

	<b>RIGHT</b>	<b>LEFT</b>
<b>Maximum Anteroposterior Diameter (mm)</b>		
<b>Maximum Mediolateral Diameter(mm)</b>		

	<b>Oval</b>	<b>Round</b>	<b>Almond</b>	<b>Slit</b>	<b>Irregular</b>	<b>Other</b>
<b>Shape</b>						

**Variant Anatomy**

<b>Absent</b>	
<b>Other</b>	

**Jugular Foramen**

	<b>Right</b>	<b>Left</b>
<b>Maximum Anteroposterior Diameter (mm)</b>		
<b>Maximum Mediolateral Diameter(mm)</b>		

	<b>Oval</b>	<b>Round</b>	<b>Almond</b>	<b>Slit</b>	<b>Irregular</b>	<b>Other</b>
<b>Shape</b>						

**Variant Anatomy**

<b>Absent</b>	
<b>Other</b>	

## Appendix E: KNH/UoN-ERC Letter of Approval



UNIVERSITY OF NAIROBI  
FACULTY OF HEALTH SCIENCES  
P O BOX 19676 Code 00202  
Telegrams: varsity  
Tel: (254-020) 2726300 Ext 44355



KENYATTA NATIONAL HOSPITAL  
P O BOX 20723 Code 00202  
Tel: 726300-9  
Fax: 725272  
Telegrams: MEDSUP, Nairobi

### KNH-UoN ERC

Email: [uonknh\\_erc@uonbi.ac.ke](mailto:uonknh_erc@uonbi.ac.ke)  
Website: <http://www.erc.uonbi.ac.ke>  
Facebook: <https://www.facebook.com/uonknh.erc>  
Twitter: @UONKNH\_ERC [https://twitter.com/UONKNH\\_ERC](https://twitter.com/UONKNH_ERC)

Ref: KNH-ERC/A/13

10<sup>th</sup> January, 2022

Dr. Joan N. Mochama  
Reg. No. H58/34174/2018  
Dept. of Diagnostic Imaging and Radiation Medicine  
Faculty of Health Sciences  
University of Nairobi



Dear Dr. Mochama,

**RESEARCH PROPOSAL: NORMAL BASE OF SKULL FORMINA ANATOMY AND VARIANTS ON COMPUTED TOMOGRAPHY IN THE ADULT POPULATION IN NAIROBI, KENYA (P692/08/2021)**

This is to inform you that KNH-UoN ERC has reviewed and approved your above research proposal. Your application approval number is **P692/08/2021**. The approval period is 10<sup>th</sup> January 2022 – 9<sup>th</sup> January 2023.


This approval is subject to compliance with the following requirements;

- i. Only approved documents including (informed consents, study instruments, MTA) will be used.
- ii. All changes including (amendments, deviations, and violations) are submitted for review and approval by KNH-UoN ERC.
- iii. Death and life threatening problems and serious adverse events or unexpected adverse events whether related or unrelated to the study must be reported to KNH-UoN ERC 72 hours of notification.
- iv. Any changes, anticipated or otherwise that may increase the risks or affected safety or welfare of study participants and others or affect the integrity of the research must be reported to KNH-UoN ERC within 72 hours.
- v. Clearance for export of biological specimens must be obtained from relevant institutions.
- vi. Submission of a request for renewal of approval at least 60 days prior to expiry of the approval period. Attach a comprehensive progress report to support the renewal.
- vii. Submission of an executive summary report within 90 days upon completion of the study to KNH-UoN ERC.

Protect to discover

Prior to commencing your study, you will be expected to obtain a research license from National Commission for Science, Technology and Innovation (NACOSTI) <https://research-portal.nacosti.go.ke> and also obtain other clearances needed.

Yours sincerely,



**PROF. M.L. CHINDIA**  
**SECRETARY, KNH-UoN ERC**

c.c. The Dean-Faculty of Health Sciences, UoN  
The Senior Director, CS, KNH  
The Chairperson, KNH- UoN ERC  
The Assistant Director, Health Information, KNH  
The Chair, Dept. of Diagnostic Imaging and Radiation Medicine, UoN  
Supervisor: Dr. Callen K. Onyambu, Dept. of Diagnostic Imaging and Radiation Medicine, UoN

Protect to discover



Appendix F: Certificate of Plagiarism

Normal Base of Skull Foramina Anatomy and Variants On  
Computed Tomography In The Adult Population In Nairobi,  
Kenya.

ORIGINALITY REPORT

<b>14%</b> SIMILARITY INDEX	<b>10%</b> INTERNET SOURCES	<b>8%</b> PUBLICATIONS	<b>4%</b> STUDENT PAPERS
--------------------------------	--------------------------------	---------------------------	-----------------------------

PRIMARY SOURCES

<b>1</b>	Abhijit A Raut, Prashant S Naphade, Ashish Chawla. "Imaging of skull base: Pictorial essay", Indian Journal of Radiology and Imaging, 2021 Publication	1%
<b>2</b>	repository-tnmgrmu.ac.in Internet Source	1%
<b>3</b>	www.researchgate.net Internet Source	1%
<b>4</b>	archive.org Internet Source	1%
<b>5</b>	Ajaykumar C. Morani, Nisha S. Ramani, Jeffrey R. Wesolowski. "Skull Base, Orbits, Temporal Bone, and Cranial Nerves: Anatomy on MR Imaging", Magnetic Resonance Imaging Clinics of North America, 2011 Publication	1%
<b>6</b>	www.scielo.cl Internet Source	1%