

**STUDIES ON RHABDITIS SPECIES ASSOCIATED WITH
BOVINE PARASITIC OTITIS**

BY


MATHIAS MWANGINGA TIKATIKA MATANDALA

A thesis submitted in partial fulfillment for the
degree of Master of Science in Veterinary
Pathology and Microbiology of the University
of Nairobi.

Department of Veterinary Pathology and Microbiology
Faculty of Veterinary Medicine
University of Nairobi.

DECLARATION

This is my original work and has not been submitted for a degree at any other University or Institution.



M. M. T. Matandala

This work has been submitted to the University of Nairobi for examination with our approval as University supervisors




Prof. G. M. Mugeru

Department of Pathology and Microbiology

Faculty of Veterinary Medicine

P.O Box 29053

Nairobi, Kenya



Dr T. A. Ngatia

Department of Pathology and Microbiology

P. O. Box 29053

Nairobi, Kenya

DEDICATION

This work is dedicated to my mother Msemwa Senguga.

Thanks are due to Dr. E. A. Ngala for their invaluable advice, supervision, encouragement, cooperation and suggestions all through the course of this study and in the thesis preparation.

My sincere appreciation and thanks are due to the Department of Entomology Services (EASD) for funding my studies at the University of Nairobi and my work. I wish also to mention the assistance of Dr. G. N. Odu (EASD) and Dr. J. K. Mwangi (EASD) during their respective periods while carrying out field work in their respective districts. A note of thanks is also extended to the field staff in various districts and various divisions for their support during the field work.

The expert technical and scientific facilities provided by Dr. J. N. Ayoo of the University of Nairobi, are highly appreciated. I am also grateful to the members of technical staff in the Department of Entomology and Parasitology for their assistance during laboratory and experimental studies.

Finally I thank my wife, Leontine, my daughter Betty and my son John for their support, prayers and understanding during the study.

ACKNOWLEDGEMENT

I am deeply indebted to my supervisors Professor G.M Mugeru and Dr. T. A. Ngatia for their invaluable close supervision, encouragement, cooperation and suggestions all through the course of this study and in the thesis preparation.

My sincere appreciation and thanks are due to the German Academic Exchange Services (DAAD) for funding my studies at the University of Nairobi and this work. I wish to extend my gratitude to Drs O.N. Ouma (DVO, Kajiado) and G.K. Njihia (DVO, Murang'a) for their assistance to me while carrying out my field work in their respective districts. A vote of thanks is also extended to the field staffs in Central Kajiado and Makuyu divisions for their support during the field work.

The support, encouragement and constructive criticism rendered by Dr.J. M. Ayuya of the University of Nairobi, are highly acknowledged. I am also grateful to the members of technical staff to the Department of Pathology and Microbiology for their assistance during my laboratory and experimental studies.

Finally I thank my wife Laurencia, my daughter Betty and my son Patrick for their support, prayers and inexhaustible encouragement.

TABLE OF CONTENTS

DECLARATION	i
DEDICATION	ii
ACKNOWLEDGEMENT	iii
TABLE OF CONTENTS	iv
LIST OF FIGURES	viii
LIST OF TABLES	xi
LIST OF APPENDICES	xii
ABSTRACT	xiii
1. INTRODUCTION	1
2. LITERATURE REVIEW	
2.1 Occurrence and distribution	5
2.2 Etiology	6
2.3 Epidemiology	21
2.4 Pathogenesis	24
2.5 Clinical Signs	25
2.6 Pathology	27
2.7 Diagnosis	28
2.8 Treatment	28
2.9 Control	29
3. MATERIALS AND METHODS	
3.1 Field Study	
3.1.1. Areas of study	30
3.1.1.1 Kajiado District	30
3.1.1.2 Murang'a District	31

3.1.2	Point prevalence	32
3.1.3	Identification of nematode species associated with infection	32
3.1.4	Assessment of the role played by dips as reservoirs of the nematodes	33
3.1.4.1	Identification of nematode species supported by dips in the areas of study	33
3.1.4.2	Survival rates of the nematodes in different acariades used in the areas of study	34
3.2	Experimental study	35
3.2.1	Experimental animals	35
3.2.2	Determination of ear bacterial flora	36
3.2.3	Nematode preparation	36
3.2.3.1	<i>Rhabditis blumi</i>	36
3.2.3.2	<i>Rhabditis bovis</i>	37
3.2.3.3	Harvesting of the worms	37
3.2.4	Infecting protocol	38
3.2.5	Clinical examination	39
3.2.6	Pathology examination	39
4.	RESULTS	
4.1	Field study	42
4.1.1	Point prevalence	42
4.1.2	Nematode spp associated with the infection	45

4.1.3	Assessment of the role played	46
	by dips as reservoirs of the nematode	
4.1.3.1	Nematode spp supported by	
	dips in the areas of study	46
4.1.3.2	Survival rates of the nematodes	
	in the different acaricides	
	used in the areas	47
4.2	Experimental study	
4.2.1	Clinical response to the infection	49
4.2.1.1	Group 1. Animals infected with <u>Rh.</u>	
	<u>bovis</u>	50
4.2.1.2	Group 2. Animals infected	
	with <u>Rh. blumi</u>	53
4.2.1.3	Group 3. Control animals	53
4.2.2	Gross pathology	
4.2.2.1	Group 1. Animals infected	
	with <u>Rh. bovis</u>	57
4.2.2.2	Group 2. Animals infected	
	with <u>Rh. blumi</u>	57
4.2.2.3	Group 3. Control animals	58
4.2.3	Histopathology	
4.2.3.1	Group 1. Animals infected	
	with <u>Rh. bovis</u>	58
4.2.3.2	Group 2. Animals infected	
	with <u>Rh. blumi</u>	60
4.2.3.3	Group 3. Control animals	60

4.2.4	Bacterial isolation	61
5.	DISCUSSION, CONCLUSIONS AND RECOMMENDATIONS	
5.1	Discussion	71
5.2	Conclusion	82
5.3	Recommendations	83
6.	REFERENCES	85
7.	APPENDICES	91
Fig. 1	Subsidiary canal procedure and	92
Fig. 2	Subsidiary canal procedure and	93
Fig. 3	Subsidiary canal procedure and	94
Fig. 4	Subsidiary canal procedure and	95
Fig. 5	Subsidiary canal procedure and	96
Fig. 6	Subsidiary canal procedure and	97
Fig. 7	Subsidiary canal procedure and	98
Fig. 8	Subsidiary canal procedure and	99
Fig. 9	Subsidiary canal procedure and	100
Fig. 10	Subsidiary canal procedure and	101
Fig. 11	Subsidiary canal procedure and	102
Fig. 12	Subsidiary canal procedure and	103
Fig. 13	Subsidiary canal procedure and	104
Fig. 14	Subsidiary canal procedure and	105
Fig. 15	Subsidiary canal procedure and	106
Fig. 16	Subsidiary canal procedure and	107
Fig. 17	Subsidiary canal procedure and	108
Fig. 18	Subsidiary canal procedure and	109
Fig. 19	Subsidiary canal procedure and	110
Fig. 20	Subsidiary canal procedure and	111
Fig. 21	Subsidiary canal procedure and	112
Fig. 22	Subsidiary canal procedure and	113
Fig. 23	Subsidiary canal procedure and	114
Fig. 24	Subsidiary canal procedure and	115
Fig. 25	Subsidiary canal procedure and	116
Fig. 26	Subsidiary canal procedure and	117
Fig. 27	Subsidiary canal procedure and	118
Fig. 28	Subsidiary canal procedure and	119
Fig. 29	Subsidiary canal procedure and	120
Fig. 30	Subsidiary canal procedure and	121
Fig. 31	Subsidiary canal procedure and	122
Fig. 32	Subsidiary canal procedure and	123
Fig. 33	Subsidiary canal procedure and	124
Fig. 34	Subsidiary canal procedure and	125
Fig. 35	Subsidiary canal procedure and	126
Fig. 36	Subsidiary canal procedure and	127
Fig. 37	Subsidiary canal procedure and	128
Fig. 38	Subsidiary canal procedure and	129
Fig. 39	Subsidiary canal procedure and	130
Fig. 40	Subsidiary canal procedure and	131
Fig. 41	Subsidiary canal procedure and	132
Fig. 42	Subsidiary canal procedure and	133
Fig. 43	Subsidiary canal procedure and	134
Fig. 44	Subsidiary canal procedure and	135
Fig. 45	Subsidiary canal procedure and	136
Fig. 46	Subsidiary canal procedure and	137
Fig. 47	Subsidiary canal procedure and	138
Fig. 48	Subsidiary canal procedure and	139
Fig. 49	Subsidiary canal procedure and	140
Fig. 50	Subsidiary canal procedure and	141
Fig. 51	Subsidiary canal procedure and	142
Fig. 52	Subsidiary canal procedure and	143
Fig. 53	Subsidiary canal procedure and	144
Fig. 54	Subsidiary canal procedure and	145
Fig. 55	Subsidiary canal procedure and	146
Fig. 56	Subsidiary canal procedure and	147
Fig. 57	Subsidiary canal procedure and	148
Fig. 58	Subsidiary canal procedure and	149
Fig. 59	Subsidiary canal procedure and	150
Fig. 60	Subsidiary canal procedure and	151
Fig. 61	Subsidiary canal procedure and	152
Fig. 62	Subsidiary canal procedure and	153
Fig. 63	Subsidiary canal procedure and	154
Fig. 64	Subsidiary canal procedure and	155
Fig. 65	Subsidiary canal procedure and	156
Fig. 66	Subsidiary canal procedure and	157
Fig. 67	Subsidiary canal procedure and	158
Fig. 68	Subsidiary canal procedure and	159
Fig. 69	Subsidiary canal procedure and	160
Fig. 70	Subsidiary canal procedure and	161
Fig. 71	Subsidiary canal procedure and	162
Fig. 72	Subsidiary canal procedure and	163
Fig. 73	Subsidiary canal procedure and	164
Fig. 74	Subsidiary canal procedure and	165
Fig. 75	Subsidiary canal procedure and	166
Fig. 76	Subsidiary canal procedure and	167
Fig. 77	Subsidiary canal procedure and	168
Fig. 78	Subsidiary canal procedure and	169
Fig. 79	Subsidiary canal procedure and	170
Fig. 80	Subsidiary canal procedure and	171
Fig. 81	Subsidiary canal procedure and	172
Fig. 82	Subsidiary canal procedure and	173
Fig. 83	Subsidiary canal procedure and	174
Fig. 84	Subsidiary canal procedure and	175
Fig. 85	Subsidiary canal procedure and	176
Fig. 86	Subsidiary canal procedure and	177
Fig. 87	Subsidiary canal procedure and	178
Fig. 88	Subsidiary canal procedure and	179
Fig. 89	Subsidiary canal procedure and	180
Fig. 90	Subsidiary canal procedure and	181
Fig. 91	Subsidiary canal procedure and	182
Fig. 92	Subsidiary canal procedure and	183
Fig. 93	Subsidiary canal procedure and	184
Fig. 94	Subsidiary canal procedure and	185
Fig. 95	Subsidiary canal procedure and	186
Fig. 96	Subsidiary canal procedure and	187
Fig. 97	Subsidiary canal procedure and	188
Fig. 98	Subsidiary canal procedure and	189
Fig. 99	Subsidiary canal procedure and	190
Fig. 100	Subsidiary canal procedure and	191

LIST OF FIGURES

Figure 1.	<u>Rhabditis bovis</u>	anterior end.	11
Fig. 2.	<u>Rhabditis bovis</u>	Posterior	12
Fig. 3.	<u>Rhabditis bovis</u>	female reproductive structures	13
Fig. 4.	<u>Rhabditis blumi</u>	anterior end	14
Fig. 5.	<u>Rhabditis blumi</u>	posterior end	15
Fig. 6.	<u>Rhabditis blumi</u>	female reproductive structures	16
Fig. 7	<u>Rhabditis freitas</u> ,	male, female reproductive structures	17
Fig. 8	<u>Rhabditis freitas</u>	posterior end	18
Fig. 9	<u>Rhabditis costai</u>	male, female and anterior end	19
Fig. 10	<u>Rhabditis costai</u>	posterior end	20
Fig. 11	Left ear of animal B2	showing discharges in the conchal and tragus region	54
Fig. 12	Left ear of animal B3	showing discharges blocking the entrance to the ear canal	54
Fig. 13	Right ear of animal B2	showing bloody discharge soiling the pinna, ear base and the cheek	55
Fig. 14	Left ear of animal B3	showing discharge draining through the tragus to soil the ear base	55

Fig. 15	Right ear of animal B1 showing discharge in the conchal region and blocking the ear canal	56
Fig. 16	Animal B2 with bilateral otitis is emaciated and droopy ears	56
Fig. 17	Cartilaginous part of the left ear canal of animal B2 showing a thickened epidermis	63
Fig. 18	Osseous part of the right ear canal of animal B1 showing an area in the thickened epithelium	63
Fig. 19	Osseous part of the right ear canal of animal B1 showing an area in the thickened epithelium infiltrated with inflammatory cells, mainly neutrophils	64
Fig. 20	Osseous part of the right ear canal of animal B1 showing the papillary layer of the dermis infiltrated with eosinophil, plasma cells, lymphocytes and macrophages	64
Fig. 21.	Junction of the cartilaginous and the osseous part of the left ear canal of animal B1 showing extensively eroded epithelium and cellular infiltrated dermis	65
Fig. 22.	Osseous part of the left ear canal of animal B1 showing a desquamated epithelium and cellular infiltrated dermis at higher magnification	65

Fig. 23.	Osseous part of the right ear canal of animal B2 showing cellular infiltrated dermis under intact epithelium	66
Fig. 24.	Osseous part of the left ear canal of animal B3 showing a desquamated epithelium and cellular infiltrated dermis	66
Fig. 25.	Osseous part of the right ear canal of B2 showing the reticular layer of the dermis densely infiltrated with mononuclear cells	67
Fig. 26	Actively secreting ceruminous glands in the left ear of animal B1	67
Fig. 27.	Osseous part of the right ear canal of animal B3 showing a keratinized epithelium and organizing dermis	68
Fig. 28.	Osseous part of the left ear canal of B7 showing disrupted epithelium and cellular infiltrated dermis	68
Fig. 29.	Osseous part of the left ear canal of animal B7 showing the dermis densely infiltrated with mononuclear cells	69
Fig. 30.	Normal cartilaginous part of the left ear canal of animal B9	69
Fig. 31.	Less active ceruminous glands from the left ear canal of animal B9	70
Fig. 32.	Normal osseous part of the left ear canal from animal B11	70

LIST OF TABLES

Table 1.	Experimental design to determine the pathogenicity of <u>Rhabditis</u> spp in cattle	38
Table 2.	The prevalence of Bovine Parasitic otitis in the traditional herds from Central Kajiado Division	44
Table 3.	Area prevalence of Bovine Parasitic otitis in Makuyu Division	44
Table 4.	Nematode species associated with Bovine Parasitic otitis in Makuyu	45
Table 5.	Mean survival time of <u>Rh. bovis</u> in Kajiado dip samples	48
Table 6.	Mean survival time of <u>Rh. bovis</u> and <u>Rh. blumi</u> in Makuyu dip samples	48
Table 7.	Clinical response to the infection for 90 days	51

LIST OF APPENDICES

- Appendix 1. Clinical response to the infection in a period of 90 days 91
- Appendix 2. Worm isolation from the infected ears during the 90 days 93
- Appendix 3. Bacteria isolation from the ears before the experiment 94
- Appendix 4. Bacteria isolation from the ears at the end of the experiment 95

ABSTRACT

A field study was carried out to determine the prevalence of Bovine parasitic otitis in the semi arid (hot dry) and the high potential (cold humid) areas of Kenya. A prevalence ranging from 27.3% to 78.3% was recorded in the semi arid areas of Kajiado and of between 5% and 13.6% in the high potential areas of Makuyu (Murang'a) where the disease also occurred in a less severe form. There was a significant difference in the prevalence ($P < 0.001$) and severity of the disease between the two agro-ecological regions. However, the observations in the semi arid areas were comparable to what have been reported from the hot and humid (coastal) areas where the disease is known to be more prevalent. Rhabditis (Rh) bovis alone was found to be associated with the infection in the semi arid while Rh. bovis and Rh. blumi in separate or mixed infection were identified from the high potential areas. Where it occurred alone, Rh. blumi was found to be associated with mild and chronic cases.

Rh. bovis was not isolated from any of the dips used by infected cattle while Rh. blumi was recovered from one dip. The nematodes survived in dip samples from the understrength dips for an average of 3 days for Rh. bovis and more than 3 weeks for Rh. blumi. In freshly prepared correct strength acaricide solutions, both species were killed within 10

minutes by Amitraz a diamide (Triatix-Coopers) and in less than 2 hours by Chlorfenvinphos (Supona, Shell and Supadip, Wellcome). In Delnav (Delnav DFF-Wellcome) and in water Rh. bovis survived for only 3 days whereas Rh. blumi survived for 28 days. Delnav and understrength Chlorfenvinphos dips are good reservoirs of Rh. blumi but can act as source of infection for both species during cattle dipping.

In an experimental study to determine the pathogenicity of the two Rhabditis species, three of the four cattle infected with Rh. bovis developed a bilateral moderate, severe, or very severe otitis externa within 5 to 17 days (10) after infection. The clinical, pathological and histological changes were similar to what have been reported on field cases of the disease. No animal infected with Rh. blumi developed clinical otitis, but all of them showed a unilateral or bilateral increase in soft cerumene secretion from which worms were recovered. The reaction receded soon after the worms disappeared from the canal. One ear in which the reaction persisted for 76 days had a hyperaemic mucosa. This together with two others, showed a partly disrupted and necrotic epidermis and inflamed dermis on histological examination. The changes however, appeared to be a result of the pyogenic bacteria found in the ears rather than from worms. These results support the field study and other reported studies that Rh. blumi is a less pathogenic free living species whose occurrence in the ear may be a chance contamination.

1.0 INTRODUCTION

Bovine parasitic otitis also known as Nematode otitis is a serious external ear infection of cattle. The disease is normally chronic but it may occasionally be acute. It is clinically characterized by presence of thick grey or brown foul smelling aural discharge containing many tiny worms. In some cases the infection extends into the middle ear to cause otitis media. Further extension can either result into pharyngitis or meningoencephalitis, clinically manifested by central nervous symptoms (Jibbo, 1966). The normally herd problem causes economic losses through chronic wasting, lowered productivity and deaths resulting from the infection, intercurrent diseases and culling of chronically infected animals. More losses are attributed to treatment and control measures which are not specific.

Although the disease was first reported as far back as 1956 (Round, 1962), it is only recently that it has become known and its economic importance appreciated. It is believed to be widespread in East Africa, other African countries and elsewhere (Msolla et al, 1986). In Tanzania, the condition is known to occur in all coastal and several up country regions, where a prevalence of over 70% has been reported (Msolla et al, 1986). Its distribution and prevalence in Kenya is not well known. Although the disease is known to be more prevalent in areas with hot and humid type of climate, it has also been reported from areas with

hot dry and cold humid types of climate (Msolla et al, 1986; Odongo and D'Souza, 1989). The significance of the disease in these areas is yet to be determined.

The disease is primarily caused by a nematode of the genus Rhabditis. Several species are believed to be involved (Lweno et al 1983). Four species have so far been identified. Two of these; Rh. bovis (Kreis, 1964) and Rh. blumi (Sudhaus, 1974) have been described from Tanzania, and the other two; Rh. freitas and Rh. costai from Brazil (Martin Junior, 1985). Rh. bovis and Rh. blumi commonly occur together in infection but usually with the latter occurring in fewer numbers. Rh. blumi has been found to flourish well in manure and soil for several months unlike Rh. bovis which survives for less than a week (Msolla et al, 1986). These observation may imply that Rh. blumi is more adapted to free-living than the latter. Sudhaus (1980) however, has shown experimentally that it is adapted to parasitism of warm blooded animals. Using Rh. bovis, Lweno et al, (1983) and Msolla et al, (1986) have successfully reproduced the disease in cattle and rabbits respectively. However, the distribution and pathogenicity of Rh. blumi has not been studied.

The condition is usually complicated by pyogenic and putrefying bacteria most of which are normal flora of the auditory canal. In neglected cases myiasis infestation may also occur (Jibbo, 1966).

Several means of transmission of the disease have been

advanced and some studied. Diptanks used in tick control have been incriminated to play a major role (Jibbo, 1966). Higher incidences of the disease occur in dipped than in sprayed animals (Msolla, 1984). In an epidemiological study by Msolla et al, (1986), up to 20 viable nematodes were recovered from 100ml of 0.25% toxaphene dipwash obtained from a diptank routinely used by infected herds. The worms survived in the solution for two weeks. Manure and mud are believed to be reservoirs and sources of infection. Flies are thought to play a significant role in the spread of the disease. (Kreis, 1964; Jibbo, 1966; Msolla et al, 1989)

Different combinations of anthelmintics and antibiotics have been tried to treat the condition (Jibbo, 1966; Msolla et al, 1985; Odongo and D'souza, 1989). The effectiveness of these treatments have been limited by the fact that, reinfection occurs a few days following a successful treatment, cases at advanced stage do not respond to treatment while early diagnosis and treatment is tedious and expensive. Control seems to be the more sound approach to fight the disease. Control measures directed at dip tanks (Msolla et al, 1987) and manure removal from resting and sleeping bomas (Jibbo, 1966) have been suggested and tried. However, these measures will be useful only if the Rhabditis species supported by the reservoirs happen to be the pathogenic ones.

The main objectives of this study were:

1. To determine the point prevalence of the disease in areas with hot dry (semi arid) and cold humid (high potential) type of climates in Kenya.
2. To identify the Rhabditis species associated with the infection in the areas.
3. To determine the role played by diptanks as reservoirs of the nematodes in the areas.
4. To determine the pathogenicity of the various Rhabditis species found to be associated with the infection in the areas.

2.0 LITERATURE REVIEW

2.1 OCCURRENCE AND DISTRIBUTION

Bovine parasitic otitis was first reported in Kenya by Barnett in 1956 at Lariak East Ranch, Rumuruti (Round, 1962) and in Tanzania by Molloy in 1959 at Mkwaja Ranch, Tanga, (Jibbo, 1966). Currently it is believed to be wide spread in East Africa (Soulsby, 1982). In Kenya it has been reported in several districts including Nakuru, Narok, Murang'a, Taita Taveta and Nyandarua (Odongo and D'souza, 1989, Anon, 1980-1990). However, the prevalence of the disease in this country is not well known. In Tanzania where more epidemiological studies are being carried out, it is known to occur in all coastal and several upcountry regions. It has also been reported in Uganda, Zimbabwe, Botswana, Sudan and Egypt (Msolla et al, 1986). Outside Africa, it has been reported in Brazil (Martin Junior, 1985) The disease is possibly more widespread than it is currently known. The apparent wide distribution may be a result of animal movements, increased use of diptanks and the increased awareness of the disease among veterinarians and livestock owners.

The disease is known to be more prevalent in hot humid areas such as the coastal areas where a prevalence of over 70% has been recorded. But recently it has been reported from hot and dry areas such as the semi arid areas of Dodoma region in Tanzania (Msolla et al, 1986) and Rift Valley

province in Kenya (Odongo and D'souza, 1989). The same authors have also reported it from cold humid areas such as the high potential areas of Mbeya region in Tanzania and Central province in Kenya.

2.2 ETIOLOGY

The condition is primarily caused by a nematode of the genus Rhabditis. Various species of the normally free-living genus are believed to be associated with the infection (Lweno et al, 1983). Two species; Rh. bovis and Rh. blumi have been identified in Tanzania and two others; Rh. freitas and Rh. costai in Brazil.

Rhabditis bovis was identified and described by Kreis (1964) from aural samples obtained from Mkwaja Ranch, Tanga in Tanzania. He classified it to belong to the superfamily Rhabditoidea Travasso, 1920, family Rhabditidae Oerley, 1880 and subfamily Rhabditinae Micoletzky, 1922. It is a tiny nematode measuring between 0.8 mm and 1.1mm long, males being shorter (0.8-0.85mm) and thicker than females (1.0-1.1mm). The body is pointed at both ends.

The anterior end shows six flat lips each of which presents a number of papillae. The mouth is prismatic, longer in female than in male (Fig.1a). Posteriorly the mouth ends in a prisme, a well developed mouth dilatation which comes into contact with the oesophageal cuff. The oesophagus is rhabditiform (Fig.1b) a characteristic feature of the genus. At the front end, the oesophageal lumen

widens behind the cuff and then thins out further on. There is a well developed middle bulb found exactly at the middle of the oesophagus. The bulb is smaller than the terminal (posterior) bulb and it has no shutter apparatus (valve). Behind it is the thin isthmus surrounded by a nerve ring. The isthmus leads to the posterior bulb which is round and with a well developed shutter apparatus. The rest of the alimentary canal does not present any peculiarity. The posterior end thins out and sharpens into a long tail in the female (Fig. 2a) while it is broader, ending in a short tail which is completely enclosed in the copulatory bursa in male (Fig. 2b and 2c).

The male worm resembles Rh. strongyloides but it is smaller and thinner than the latter which measures 1.3 - 2.3 mm in length. Its anal pad (Fig. 2c) does not reach the margin of the copulatory bursa to form the anal tubercle found in Rh. strongyloides. The spicules are clearly separated and are wide proximally but pointed at their distal ends. The gubernaculum has a proximal curved club appearance on dorsoventral view (Fig. 2b) but a digit like appearance on lateral view (Fig. 2c). Its distal end broadens to give a plate like appearance similar to that of Rh. aspira. The copulatory bursa is large (Fig. 2b and 2c) and encloses the distal half of the spicules. Laterally it is supported by nine pairs of rib-shaped rays. There are two preanal pairs, four postanal pairs including the largest pair and three closely placed terminal pairs.

The female sexual apparatus (Fig. 3) are symmetrically positioned on either side of the centrally placed vulva. It is a viviparous nematode and in a mature worm, about 10-12 eggs and/or larvae can be seen. The larvae develop very fast in the uterus and may show their digestive apparatus at a relatively early stage. The eggs usually at different developmental stages, some at morula stage and some with coiled larvae, are not always grouped together; some can also be found around the vulva. The vulva presents well developed lips. The ovaries are enveloped though not in their totality.

The life cycle of Rh. bovis in the host and in free-living state has not yet been studied. In culture it has been found to multiply and develop very fast completing the life cycle within 24-48 hours (Lweno et al, 1983). The species was probably a saprophytic nematode which due to unfavorable external conditions turned into an ectoparasite. Unlike many members of the genus which are free-living, it has been found under laboratory conditions to survive for less than a week in manure and soil (Msolla et al, 1986). Also it cannot easily be recovered from manure and soil obtained from infected animal resting area (Msolla et al, 1990). Lweno et al, (1983) have been able to reproduce the disease in cattle and Msolla et al, (1986) in rabbits using this species.

Rh. blumi was identified and described by Sudhaus (1974) from aural samples obtained from several ranches in

coastal regions of Tanzania. The nematode has the same size as Rh. bovis but unlike the latter, the female posterior ends in a short tail. The nematode has many of the general characteristics of the genus. It has a rhabditidal buccal capsule and rhabditiform oesophagus (Fig.4). The corpus of the oesophagus gradually enlarges posteriorly to the metacarpus which unlike in Rh. bovis does not have the middle bulb. There is a well developed posterior bulb with a shutter apparatus behind the isthmus.

In the male the short tail can either touch the copulatory bursa or extend a short distance beyond it (Fig. 5a and 5b). The copulatory bursa is large and is pointed posteriorly. Laterally it is supported by eight pairs of rays. The preanal group of the rays comprises of sparsely arranged three pairs with the most anterior being the smallest. The postanal group also has three pairs which include the largest rays while the terminal group has two pairs and a third pair whose rays are reduced into a form of setae.

The female sexual apparatus are symmetrically arranged extending posteriorly and anteriorly from the centrally placed vulva. It is also a viviparous nematode (Fig.6). About 49 eggs develop at the same time in the female and out of these an average of 24 hatch to juveniles in the uterus. It takes seven days following copulation for the young to attain maturity. But it takes only 2-3 days for the larvae outside the female to develop to adult although it can take

more time in unfavorable conditions. The adults live for another 7-15 days.

The distribution of Rh. blumi is not known but it may be as wide spread as Rh. bovis. In clinical cases it is usually found in mixed infection with the latter but normally in a much smaller proportion (Msolla et al., 1986). Under laboratory conditions it has been found to flourish for several months in manure and soil (Msolla et al., 1986). In a field study, Msolla et al., (1989) recovered it in large numbers from soil and manure obtained from animal resting areas. These observations indicate that the species is a free-living nematode. However, Sudhaus (1980) in his studies on the upper limiting temperature of different saprophagous Rhabditis species observed Rh. blumi to be adapted to parasitism in warm blooded animals.

Two more species have been identified and described by Martin Junior (1985) in Brazil. The first, Rh. freitas Fig. 7 and 8) was isolated from aural samples obtained from Formosa county in the state of Goias while the second one Rh. costai (Fig. 9 and 10) was identified from Sertanozinho county in the State of Sau Paulo.

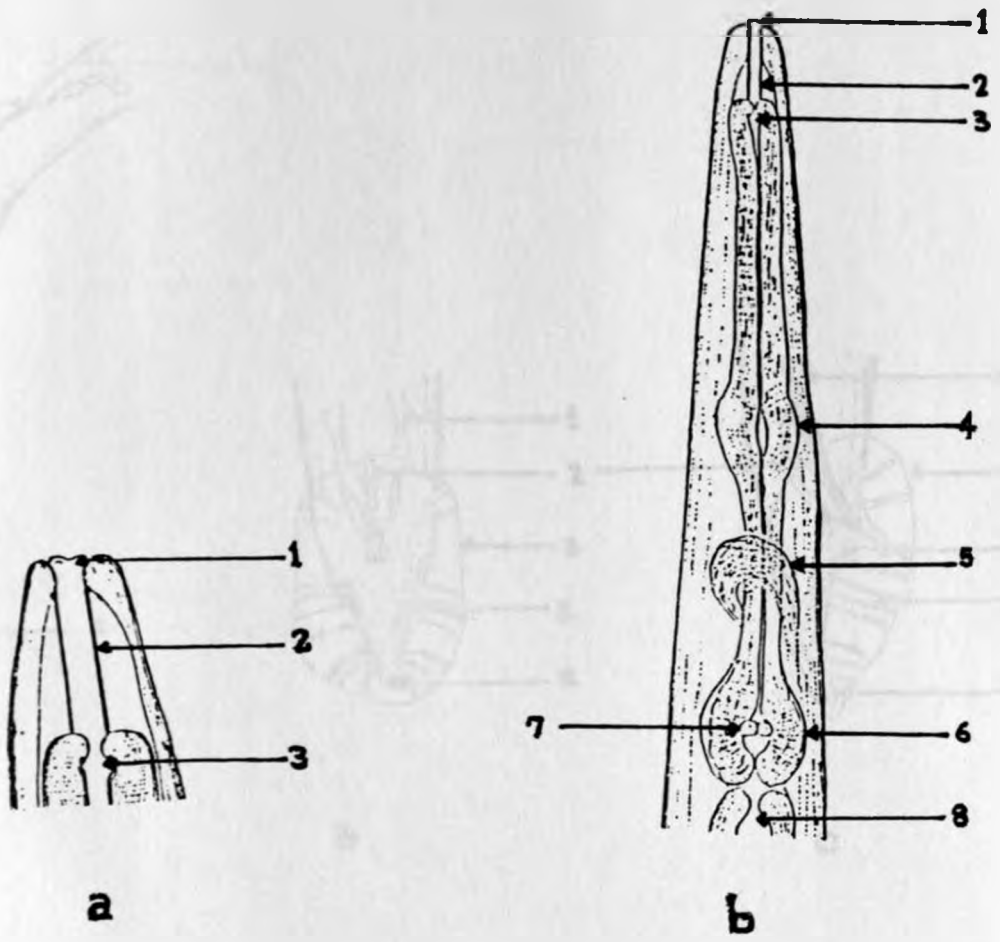


Fig. 1. *Rhabditis bovis*: Anterior end.
 a) Head - female x 660 b) oesophagus - male x330:
 1. Prismatic mouth, 2. buccal capsule, 3. oesophageal cuff, 4. middle bulb, 5. nerve ring, 6. posterior bulb 7. shutter apparatus (valve) 8. anterior alimentary canal.

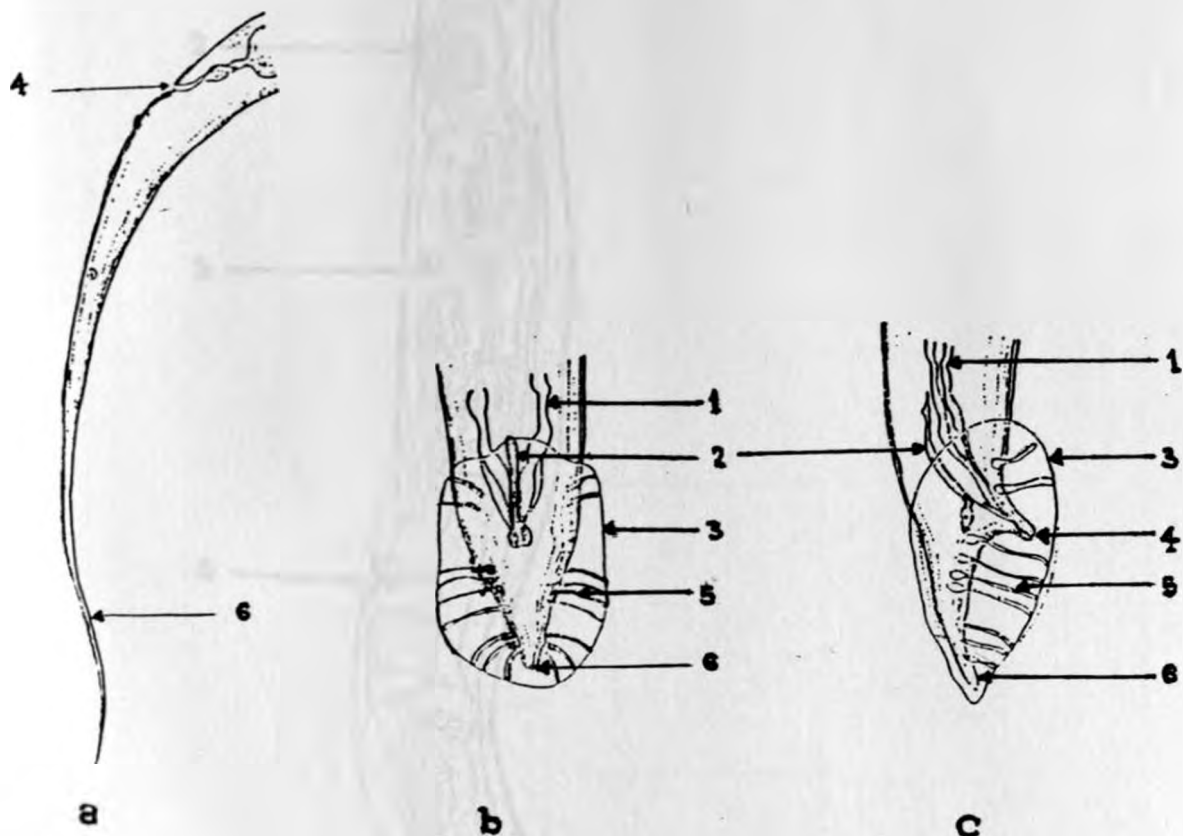


Fig. 2. Rhabditis bovis: Posterior end.

a) Female Posterior end x 200 b) Male Posterior end, dorsoventral view x 330 c) Male Posterior end, lateral view x 330: 1. Spicules, 2. gubernaculum, 3. cepulatory bursa, 4. anal pad (anal opening). 5. rays, 6. tail.

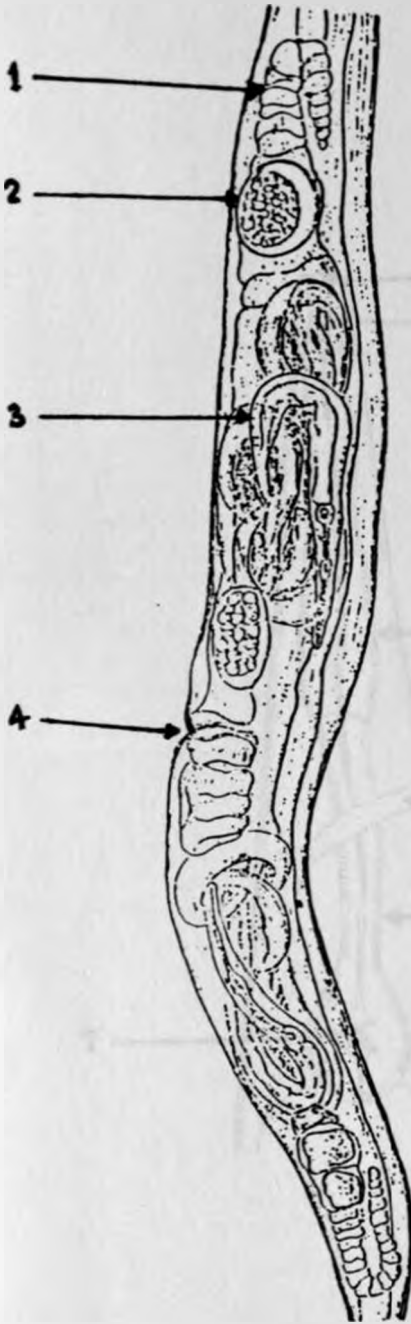


Fig. 3. Rhabditis bovis:
Female reproductive structures x 130.
1. Ovary 2. egg , 3. larva, 4. vulva.

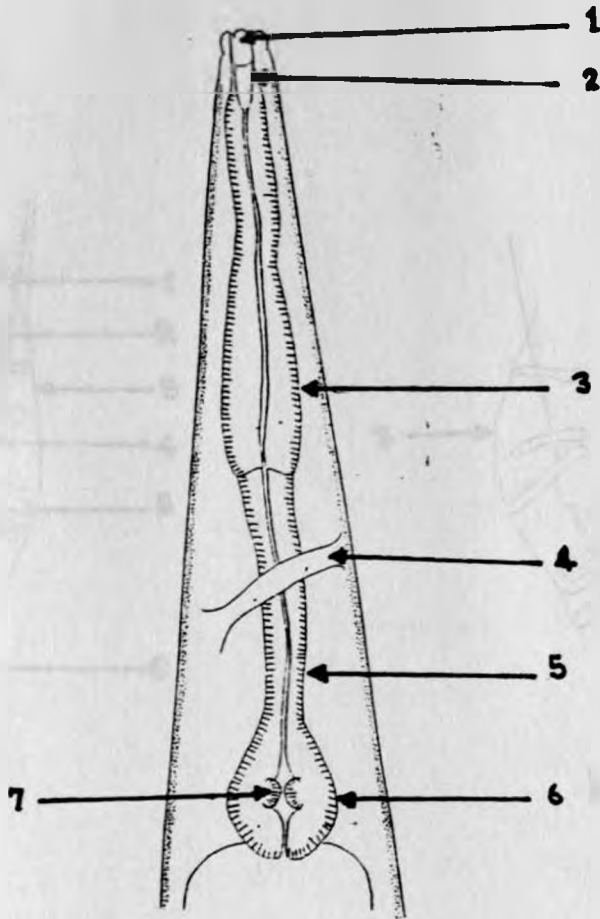


Fig. 4. *Rh. blumi*: anterior end

**1. mouth 2. buccal capsule 3. oesophagus corpus
4. nerve ring 5. oesophagus isthmus 6. posterior
bulb, 7. valve.**

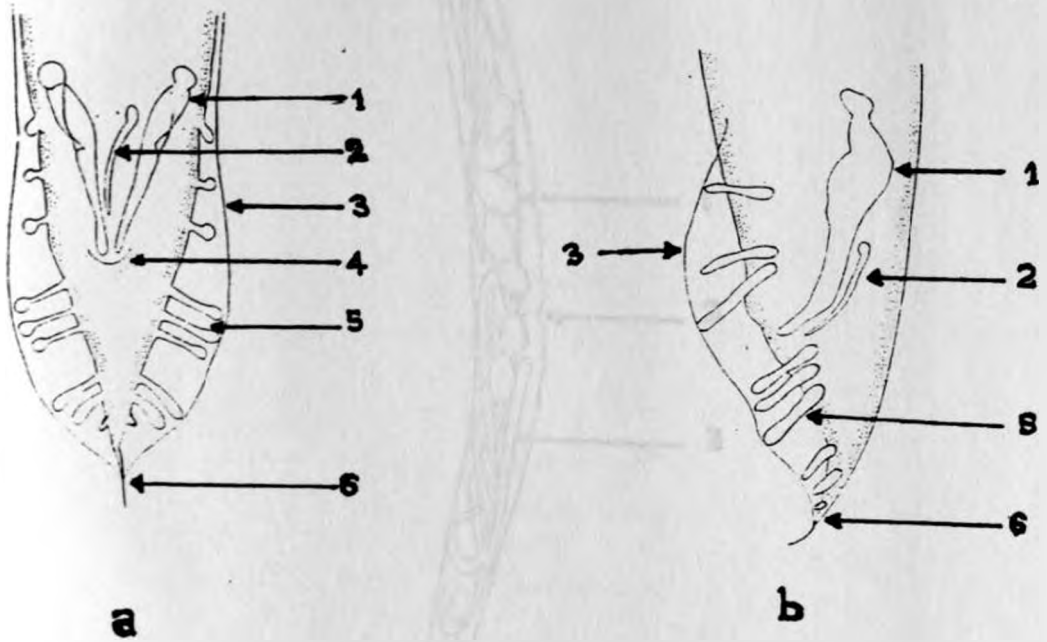


Fig. 5. Rh. blumi male posterior end.

a) dorsoventral view b) lateral view

1. spicules 2. gubernaculum 3. copulatory bursa

4. Anal opening 5. rays 6. tail

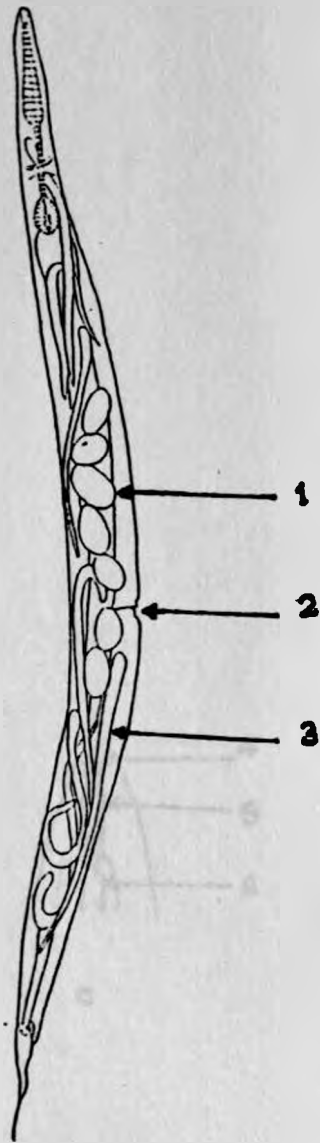


Fig. 6. Rh. blumi female reproductive structures.
1. vulva 2. eggs 3. larva

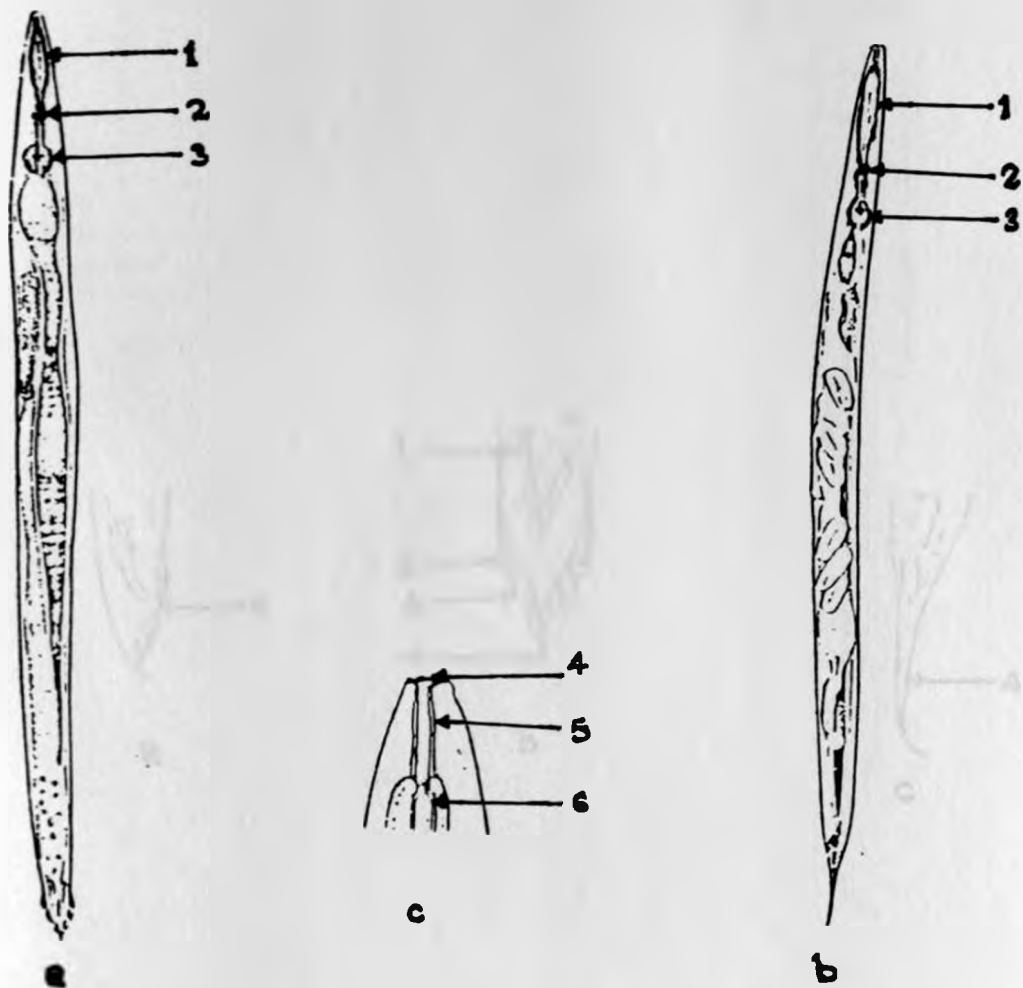


Fig. 7. *Rhabditis freitas*
 a. male b. female c. anterior end - the head.
 1. corpus of the oesophagus, 2. nerve ring
 3. posterior bulb, 5. buccal capsule 4. mouth
 6. oesophageal cuff.

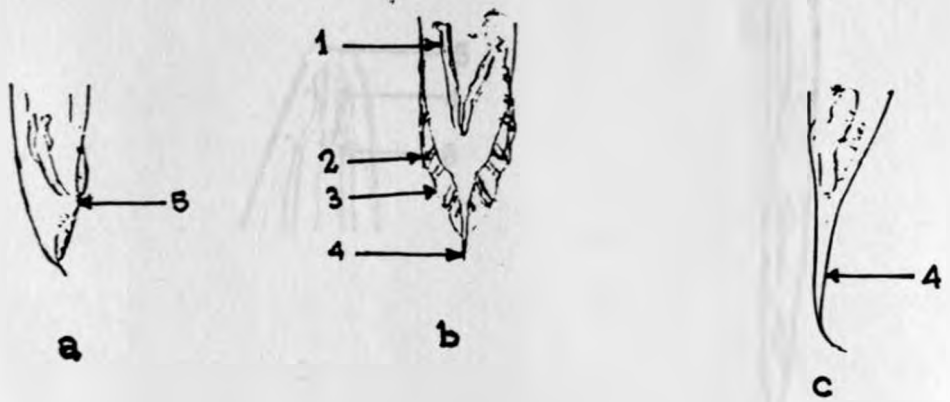


Fig. 8. Rhabditis freitas. posterior end.
 a. male posterior end lateral view, b. male dorsoventral view c. female posterior end
 1. spicules 2. rays, 3. copulatory bursa
 4. tail 5. anal pad.

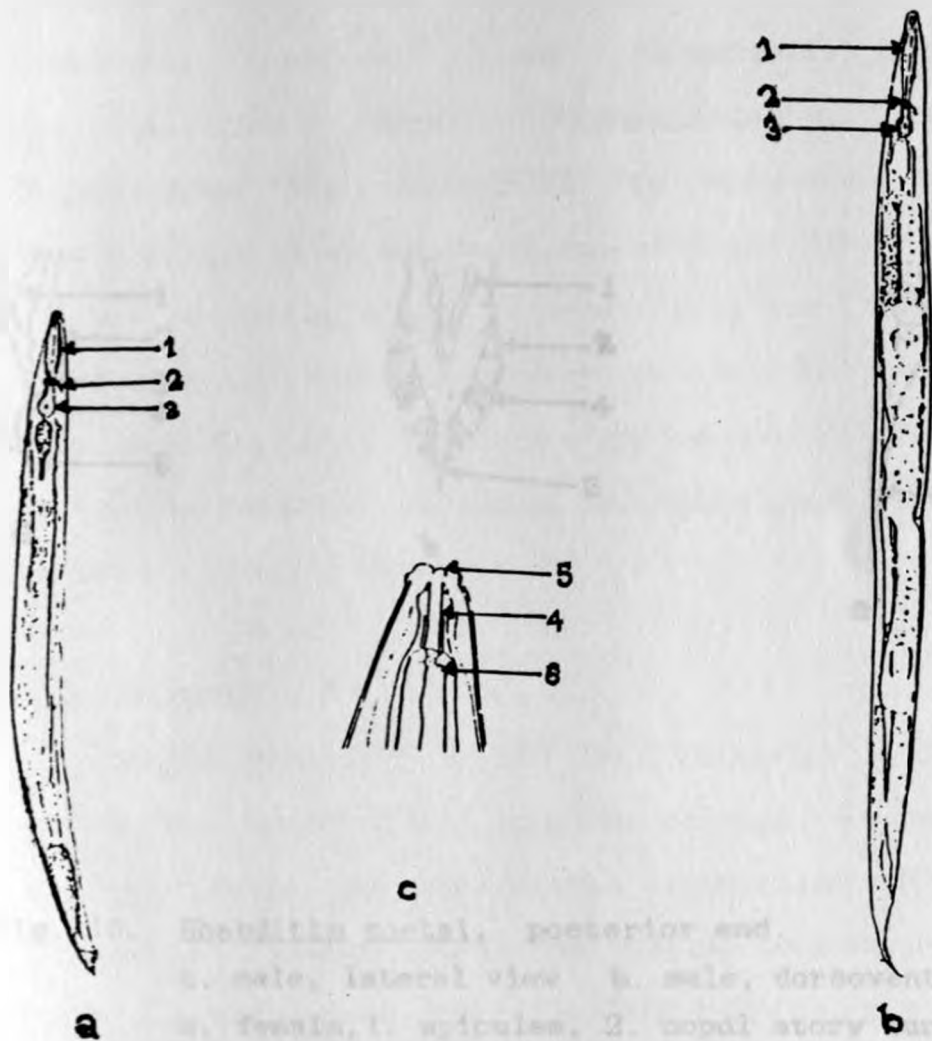


Fig. 9. *Rhabditia costali*
 a) male b) female, c) anterior end, the head
 1. corpus of the oesophagus, 2. nerve ring,
 3. posterior bulb 4. buccal capsule 5. mouth
 6. oesophageal cuff.

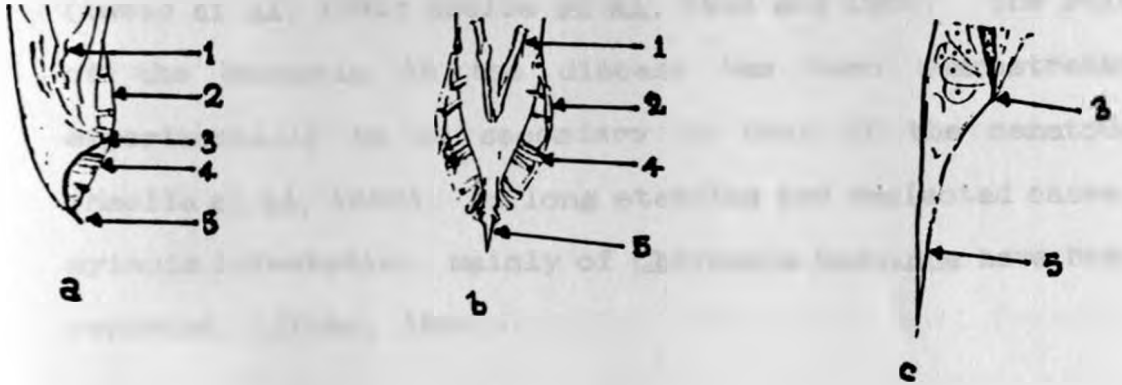


Fig. 10. *Rhabditis costai*. posterior end.
a. male, lateral view b. male, dorsoventral view,
c. female, 1. spicules, 2. copulatory bursa .
3. anal pad, 4. rays 5. tail.

In addition to the nematode, several bacteria have been isolated from clinical cases of the disease. The most frequently isolated include; Pseudomonas aeruginosa, Corynebacterium bovis, Corynebacterium pyogenes, Streptococcus spp, Klebsiella spp and other coliforms (Lweno et al, 1983; Msolla et al, 1984 and 1986). The role of the bacteria in the disease has been demonstrated experimentally to be secondary to that of the nematode (Msolla et al, 1986). In long standing and neglected cases, myiasis infestation, mainly of Chrysomia bezziana have been reported. (Jibbo, 1966)

2.3 EPIDEMIOLOGY

Bovine Parasitic Otitis is principally a disease of cattle but recent field studies carried out in Kajiado district (Kenya) have shown that it may also affect goats (Odongo and D'souza, 1989). The disease is prevalent in hot humid areas with more incidence during the rainy season. In cattle, an infection rate of 75-80% in a herd with as low as 4-5% clinical cases has been recorded (Jibbo, 1966; Msolla et al, 1984). This indicates that the infection is a herd problem. Zebu cattle are more susceptible than the exotic breeds. This is attributed to the anatomy of the external auditory meatus which is longer, narrower and with more secretory glands than the exotic breeds. These features create a warm environment favourable to the saprophytic nematode and bacteria (Jibbo, 1966; Harvey, 1980). All age

groups are equally affected but more severe clinical cases occur in immature animals (Lweno et al., 1983; Msolla et al., 1984).

Several means of transmission of the disease have been suggested and some studied to a certain extent. Diptanks used in tick control have been incriminated to serve as reservoirs and sources of infection (Kreis, 1964; Jibbo, 1966). The disease is more prevalent in dipped than sprayed cattle (Lweno et al., 1983). In a field study, Msolla et al. (1984) observed an incidence of up to 80% in dipped animals but less than 5% in sprayed animals, implying that dipping plays a greater role than other possible means of transmission. In another epidemiological study (Msolla et al., 1986), as many as 20 viable Rhabditis worms were recovered from 100mls of toxaphene dipwash obtained from a diptank routinely used by infected herds. The worms were found to survive for up to 15 days in the dipwash and remained viable and even multiplied in freshly prepared 0.25% toxaphene for up to 28 days. The worms are introduced into the diptanks from the environment by contaminated hooves and directly from clinically infected animals by aural discharge during dipping. Healthy animals then pick the infection from the diptanks (Msolla et al., 1984).

The occurrence of the disease in herds which are neither dipped nor sprayed, implies the existence of other modes of transmission (Lweno et al., 1983). Flies have been incriminated in the spread of the disease. The idea is

supported by the appearance of many flies around the infected ears, involvement of myiasis in the infection (Jibbo, 1966) and the high incidence coinciding with the increased fly activities during the warm humid weather (Msolla et al., 1986). The flies can easily pick up the worms from the aural discharge on the external pinna, around the earbase and the neck region from where a worm recovery rate of up to 93% has been recorded (Msolla et al., 1984). Msolla et al., (1989) recovered Rh. bovis and Rh. blumi from flies caught around the ears of infected cattle.

Manure and mud are thought to act as reservoirs of the nematode. The habit of cattle scratching their ears with hooves can result into direct introduction of the nematode from the contaminated manure and mud (Jibbo, 1966). Migration of the tiny worms from the soil into the ear of an animal lying down is not likely to take place (Dunn, 1978; Scott, 1988). Flies which breed in manure contaminated with the free-living nematode can spread the infection from farm to farm. In different studies, larvae of Rh. dubia, Rh. curvicaudata and an unidentified Rhabditis spp, were found twined around the intersegmental furrows of the abdomen of Psychodid flies (Owl midge or Hairy moth) which had developed in manure (Tod et al., 1971). However, in a laboratory (Msolla et al., 1986) and a field study (Msolla et al., 1989), it was shown that manure and mud support Rh. blumi better than Rh. bovis

Transmission by direct contact and aural discharge is least significant since healthy cattle kept with clinically infected ones for five months in a closed room did not contract the disease (Lweno *et al.*, 1983). However, infected animals are considered to be the major source of the infection and are responsible for the spread of the disease from endemic to clean areas, (Msolla *et al.*, 1984).

2.4 PATHOGENESIS

The pathogenesis of the disease is not well known. The length of the external ear canal, presence of hair tufts, wax, epithelial debris, increased glandular secretion stimulated by warmth and humidity and traumatic wounds such as tick bite or defective ear tag wounds, are thought to predispose the infection (Jibbo, 1966; Hayes *et al.*, 1987). The gross and histological lesions of the infected ear indicate that the nematode causes erosion and ulceration of the top epithelial cover. This allows the normally present bacteria to reach the lower epithelium and sub-epithelium where they cause necrotizing or suppurative inflammation depending on the type of bacteria involved. In histological sections, the worms are not seen beyond the epithelial layers (Lweno *et al.*, 1983).

From the inflamed outer ear, the bacteria can extend into the middle ear through a damaged tympanic membrane to cause otitis media. Damage to the facial nerve can result in facial paralysis. From the middle ear the bacteria can

extend further through the pharyngotympanic tube to the pharynx to cause pharyngitis. They can also extend into the inner ear up to the brain resulting in meningoencephalitis. (Jibbo, 1966; Lweno et al, 1983). Subsequent to the development of the external ear lesions, flies are attracted by the foul smelling excudate causing further damage leading to severe otitis and myiasis infestation. Immunity to the disease is not known to occur, but in some chronic cases the nematode may be eliminated and the healing result in complete blockage of the meatus (Msolla et al, 1986).

2.5 CLINICAL SIGNS

The initial signs of the condition usually pass unnoticed. However, in the advancing stage, the infected animal becomes dull, frequently shakes the head and flaps the affected ear which may become droopy. The affected ear initially contains a bloody discharge mixed with pus which later on becomes dirty brown or dirty grey in colour. The discharge has a characteristic putrid odour which can be perceived from a distance. This increases in amount with time thereby blocking the meatus and oozing out to soil the hair below and the front aspect of the ear, the cheek as well as the neck region. There is swelling of the external meatus thereby distorting it and even completely occluding the lumen leading to deafness. There may also be swelling of the base of the ear, local lymph nodes and even the

eyelids. There is alopecia at the base of the ear and the front aspect of it due to the detachment of the dried discharge. In the chronic cases the infection may disappear and the healing of the wound result in a complete and permanent occlusion of the meatal lumen. The infection may be unilateral or bilateral and it is painful. The animal grazes little, loses condition and the hair coat becomes rough. In lactating animals, there is a drop in milk production. (Jibbo, 1966, Msolla et al., 1986).

Involvement of the middle ear results into pharyngitis. This is clinically manifested by impaired chewing of the cud and swallowing. Green fluid may be seen dropping from the angle of the mouth on the side of the affected ear as a result of this. Infection of the inner ear and subsequently the brain is manifested by stiffness of the neck, holding the head down and circling towards the affected side. Where the facial nerve is affected, there will be facial paralysis, closing of the eye, sagging of the lip and dilation of the nostril on the affected side. The gait becomes unsteady and later, the animal lies down on lateral recumbency, usually towards the affected side with paddling motions few days before death. There are cases where no signs other than the nervous symptoms are observed though closer examination of the ear reveals the infection (Jibbo, 1966). The external meatus of one or both ears will be found covered with a thin film of yellowish or greyish putrid material in which myriads of actively moving worms

can be seen with naked eyes. Normally the mortality rate is low, about 3-4%, but it can reach up to 10% in unattended to and neglected cases. More deaths are attributed to intercurrent diseases of the stressed animals (Jibbo, 1966; Lweno et al, 1983; Msolla et al, 1986).

2.6 PATHOLOGY

Apart from the general emaciation in the chronic cases, all the postmortem lesions are confined to the head. There is a dirty brown or dirty grey discharge from the external meatus in which motile worms can be seen. The mucous membrane is initially red but later becomes ulcerated and eroded either partly or extensively. The epithelium may become swollen to obliterate the lumen. In long standing cases, the conchal is perforated and the base of the ear is so undermined that the ear can easily fall off. Pharyngitis and local lymphadenitis are features of the chronic cases associated with otitis media. When the brain is involved there is meningoencephalitis consisting mainly of gangrene and abscessation of the lateral side of medulla oblongata and the cerebellum. Usually the cranial border of this lesion is thickened and necrotic (Kreis, 1964; Jibbo, 1966, Lweno et al, 1983).

Histological examination of tissue sections from the external ear shows superficial epithelial desquamation or severe loss of epithelium down to the subepithelium. The exudate underlying the epithelium consists of necrotic

epithelial cells, some lymphocytes, plasma cells, macrophages and neutrophils as well as sections of worms. The subepithelium is infiltrated with both mononuclear and polymorphonuclear cells (Lweno et al, 1983).

2.7 DIAGNOSIS

Diagnosis of the disease is based on the epidemiology and clinical signs which are fairly specific. It is confirmed by otoscopic and microscopic examination of wet smear preparation of the aural discharge to demonstrate the presence of worms (Jibbo, 1966).

2.8 TREATMENT

Various topical treatments with combinations of anthelmintics and antibiotics have been tried with variable effectiveness. A combination of 3.9% W/V gamma-isomer BHC (Coopers) with sulphonamide powder, Benzene hexachloride DDVP (Nuvan-CIBA) and Loxerane with Oxytetracycline powder have shown a reasonable success (Jibbo, 1966). Subcutaneous injection of the broad spectrum anthelmintic Ivermectin at a dose rate of 10 mg/50 kg body weight accompanied with topical application of antibiotics is 95% effective (Msolla et al, 1985). However, the drug is expensive, thus limiting its use on a large scale. Other drugs tried include, trichloroform (Neguvon-Bayer) with oxytetracycline and a mixture of tannic acid and salicylic acid in ethanol (Odongo and D'souza, 1989). Despite the appreciable response in

various treatment trials, reinfection occurs a few days following a successful treatment (Jibbo, 1966; Msolla et al, 1986), advanced stages of the disease do not respond to any treatment and since the condition is usually a herd problem, treatment is expensive (Msolla et al, 1987).

2.9 CONTROL

In an attempt to control the disease several approaches have been put forward. Regular diagnosis and treatment of early cases may reduce the spread of the disease in a herd (Jibbo, 1966). However, the approach is tedious especially in large herds and ranch animals as it involves ear examination of all animals in the herd. Removal and proper disposal of manure from the night and resting bomas and paddocks may also reduce the spread (Jibbo, 1966). The approach however will be more effective in the control of Rh. blumi than Rh. bovis infection.

Control through the diptanks have been tried (Msolla et al, 1987). Application of 2.08 ppm of nicotine (obtained from tobacco extract) in 0.25% toxaphene dipwash was found to be 95% effective in treatment and control of the disease in animals dipped twice a week for 12 weeks. The nematode which were easily recovered from the dipwash before the treatment could not be recovered within 48 hours following the treatment. The treatment kills the worms in the infected ears and in the dipwash, and it has no effect on the toxaphene efficacy to tick control.

3.0 MATERIALS AND METHODS

3.1 FIELD STUDY

3.1.1 Areas of Study

Two districts with the history of the disease were selected from two different ecological regions of Kenya. One division was picked from each district and from each division areas of study were selected. Several traditional herds of cattle were chosen and from each herd thirty or more animals of mixed age and sex were randomly sampled and studied. One dairy farm with exotic breeds of cattle was studied in each division. Dipwash samples from the dips used by the animals in the areas were collected and analysed.

3.1.1.1 Kajiado District

Kajiado is mainly a semi arid (hot and dry) district in the Rift Valley province located in the southern part of the country. The local cattle population comprises of improved zebus managed in large traditional herds and ranches. Tick control is carried out by dipping in private and communal dips and some herds by hand spraying. The commonly used acaricides include; Delnav (Delnav DFF, Wellcome), Chlorfenvinphos, (Supadip DFF, Wellcome), emulsifiable Chlorfervinphos (Supona 50%, Shell) and Amitraz adiamide (Triatix, Coopers). Central Division was selected from the district and in it the following areas and herds in brackets

were studied; a) Kajiado(1. Mailitisa Slaughter house. 2. County council farm 3. Yiare 4. P. Silonga), b) Isinya (1. P. Kosencha 2. M. Leiyo 3. B. Ntooki)and c) Kitengela (1. Ngumila 2. Sapul 3. Magui 4. Kirema 5. Mutunkei 6. Mmari)

3.1.1.2 Murang'a District

Murang'a District is in the high potential agro ecological zone (cold humid climate) in the central Kenya. There was no confirmed Bovine parasitic otitis case in the District veterinary office's (DVO) Field reports. However, sporadic cases of otitis externa were reported mainly from Makuyu division which is relatively dry compared to other divisions of the district. The division has several ranches and many small scale farmers keeping few (1-5) improved zebus or cross breeds under pasture management. There has been little changes from Chudleigh's (1974) report that there were about 60% of the farms running 1-2 zebus, 10-30% running grade cattle and 20% with no cattle at all. Tick control is carried out by dipping mainly in communal dips, using Supadip. Five communal dipping centres were selected each to represent an area of study and the number of cattle dipped per day to represent the herd size. The centres with the dipping rates in brackets are; Kalianne (60), Mihango (130), Pundamilia (450), Malema (360) and Kenjugu (380). Nanga Estate dairy farm with 68 Friesian and Ayrshire cows managed in a fenced farm with no contact with other animals in the area, was studied.

3.1.2 Point Prevalence

Sampled animals were clinically examined physically and otoscopically for the general symptoms of the disease and presence of discharge and lesions in the ear canal. Ear swab samples were taken from each ear of all the sampled animals and transported in physiological saline to Kajiado DVO's or University laboratories for microscopic examination. The samples were examined under a dissecting microscope for the presence of worms. Animals were considered to be infected if they were found to show clinical signs and/or presence of worms in the ear canal.

3.1.3 Identification of the nematode species associated with the infection

The nematode species were identified morphologically by microscopic examination. Each ear swab sample found under the dissecting microscope to contain worms, was diluted with physiological saline and left for an hour to sediment. A drop of the sediment was drawn and put on a microscopic slide, a drop of lugol's iodine added to it (to kill and stain the worm) before applying a cover slip. The preparation was examined under a compound microscope at x 100-400. Up to 100 worms were studied from each sample. Where a mixed species infection was suspected, the sample was subcultured in serum agar and incubated at 30°C for seven days so as to enable the number of Rh. blumi increase.

3.1.4 Assessment of the role played by dips as reservoirs of the nematode

The history of tick control in each herd of study was obtained from the owner. The type of acaricide used, frequency of dipping and replenishment of the dip were recorded.

3.1.4.1 Identification of the nematode species supported by dips in the areas

Six dips in Kajiado and five in Makuyu used by the herds of study were examined. The dips from Kajiado with the type of acaricides in brackets are; Yiare (Triatix), Kosencha (Delnav), Leiyo (Supadip), Olkenos (Supona), Ngumila (Supadip) and Mutunkei (Delnav). Those from Makuyu are; Pundamilia, Mihango, Kalianne, Malema and Kenjugu. They are all communal and use Supadip acaricide.

Dip samples were collected from the dips and processed following the procedure described by Msolla *et al* (1986) with modifications. One litre was collected before dipping, during dipping and one after the dipping session. In the laboratory, each sample was thoroughly mixed and 100ml of it poured in a flask, diluted with water and left for an hour to sediment. The supernatant was discarded and the process repeated twice. Five millilitres of the sediment was drawn at a time, put in a petri dish, diluted with ten millilitres of saline and examined under dissecting microscope. The worms were counted and removed by a dropper for

morphological identification under a compound microscope. Five hundred millilitres of each original sample were examined.

Ten millilitres of the original sample were poured into a petri dish. An average of 100 live worms of the species found to be associated with the infection in the area were introduced. A petri dish containing water was used as a control. The time taken for all the worms to die was recorded. Ten replicas of the process were carried out and a mean survival time determined. The remaining amount of the original sample was taken either to Kabete veterinary laboratories or Wellcome Limited laboratory for strength analysis.

3.1.4.2 Survival Rates of the Nematodes in the Different Acaricides used in the areas of study

Fresh solutions at the recommended concentration of the four acaricides commonly used in the areas of study were prepared at the following dilution rates in water; 1:2200 (0.05% W/V) for Delnav and supadip, 1:1000 (0.05% W/V) for Supona and 1:500 (0.025% W/V) Triatix. Ten millilitres of each aliquot and of water were separately put in petri dishes and to it an average of 100 live worms of each species separately introduced and left at room temperature. The worm death rates were determined by counting the live worms under a dissecting microscope until all were dead. Ten replicas of the procedure were carried out and the mean

survival time of each nematode species in each acaricide solution and water determined.

3.2 EXPERIMENTAL STUDY

(Comparative Pathogenicity of Rh. bovis and Rh. blumi)

3.2.1 Experimental Animals

Eleven yearling cattle were used in this study. Eight yearling zebu bulls were obtained from Narok district and three weaner bulls from the University Veterinary farm. The animals were clinically examined to assess their health status. They were physically, otoscopically and microscopically examined for ear infection. They were also screened for trypanosomiasis using blood smear, buffy coat and antigen ELISA test. Three of them were found to be infected. The whole group was treated with Dibenzamidinediacetate (Veriben, Sanofi Canada) and oxytetracycline (Adamycin 10%/, Teva/ Israel) to take care of any other systemic infection. They were dewormed using levamisole (Nilzan plus, Coopers) and hand sprayed twice a week with Amitraz adiamide (Triatix, Coopers) for tick control. During the three weeks of acclimatization, the animals were monitored for any change in the body condition, body temperature and ear conditions. At the end of this period, they were placed into three groups, two of four animals each and one of three animals. Each group was confined in a flyproof room in the Isolation Unit of the Department of

Veterinary Pathology and Microbiology. They were fed on hay, wheat bran (Unga Feeds (K) Ltd) and mineral licks (Super maclick, Animal feeds (K) Ltd) and supplied with water ad-libitum. They were left for a period of two weeks to adapt themselves to the confinement before being infected.

3.2.2 Determination of Ear Bacterial Flora

Bacterial flora in each ear of the experimental animals before and at the end of the experiment was determined. The entrance to the ear canal was cleaned using a piece of cotton wool soaked in alcohol. A sterile ear swab was then inserted deep into the canal, rotated several times and removed. The swab was put in nutrient broth and incubated at 37°C overnight. The bacteria were identified by cultural growth, morphology and staining characteristics as well as biochemical tests. (Cowan,1985)

3.2.3 Nematode Preparation

Two Rhabditis species were used in the study. The nematodes were obtained from clinical cases in the areas of study.

3.2.3.1 Rhabditis blumi

A pure culture of Rh. blumi was obtained from Mrs Peris Wambui's cow during a dipping session at Pundamilia dipping centre in Makuyu division, Murang'a District. Ear swabs

were taken from the animal, transported in physiological saline, cultured and maintained in sterile manure at 30°C for three weeks. The organisms had been found during the study to flourish and survive longer in manure than in serum or blood agar. Three days before infecting the experimental animals, the worms were harvested from the manure by washing the surface with saline and subcultured in serum agar. A few drops of oxytetracycline (Adamycin 10%, Teva) were added to the inoculated serum agar to eliminate bacterial growth and the plates incubated at 37°C for three days.

3.2.3.2 Rhabditis bovis

Pure cultures of Rh. bovis were obtained from Mr. Simon Mutunkei's herd at Kitengela in Central Kajiado. Ear swabs from infected cattle were washed in physiological saline, and the washes immediately transferred into serum agar plates. This was aimed at reducing the worm deaths observed earlier on when transported in saline. A few drops of the antibiotic were added to the culture. In the laboratory, the species of the worms were determined and the pure cultures incubated at 37°C for three days.

3.2.3.3 Harvesting of the Worms

On the third day of incubation, the nematodes were separately harvested from the cultures by washing the agar surface with saline. the worm species in each harvest was confirmed. The harvest of each species was diluted by

physiological saline at a rate of 1:5 and centrifuged at 2000 r.p.m for 5 minutes. The supernatant was discarded and the process repeated three times to wash the worms and remove the antibiotic which had been incorporated into the culture. The final sediment was diluted to give an average worm count of 1200 worms/ml. The worm count showed an average of 58% and 63% of the worms in the Rh. blumi and Rh. bovis suspension respectively to be larvae.

3.2.4 Infecting Protocol

The three groups of the experimental animals were given treatments as shown in table 1 below:

Table 1. Experimental design to determine the pathogenicity of Rhabditis spp in cattle.

<u>GROUP</u>	<u>ANIMALS</u>	<u>TREATMENT GIVEN TO BOTH EARS</u>
1	B1, B2, B3,B4	Infected with <u>Rh. bovis</u>
2	B5, B6, B7,B8	Infected with <u>Rh. blumi</u>
3	B9, B10, B11	Left to serve as controls

One millilitre of the worm suspension containing about 1200 worms was introduced deep into the canal of each ear using a dropper. The ear was massaged and held upright for about a minute to enable the suspension to settle in the canal. The worm number used in the infection was considered

sufficient to take care of the worm losses resulting from the head shaking and for the possibility that some of the worm developmental stages may not have been infective.

3.2.5 Clinical Examination

The development of the disease was monitored after every two days for a period of 90 days. The animals were examined for changes in body condition, body temperature, head and ear posture and the size of the retropharyngeal lymph nodes. Detailed examination of the ears was carried out physically and otoscopically to check for the presence of discharges and lesions. An otoscope (Gowlands Ltd, Coydon England) with three sets of specula was used. Each group was examined using a different speculum. The speculum was cleaned using a piece of cotton wool soaked in alcohol after single ear examination. Ear swab samples were taken after every one examination using a sterile ear swab, washed in physiological saline and examined under a dissecting microscope for the presence of worms. The worm species were confirmed by morphological examination of wet smear preparation of the ear swab samples under a compound microscope.

3.2.6 Pathological Examination

At the end of the experiment, all the animals were sacrificed. Routine postmortem examination was carried out on each animal. Detailed examination of the head was carried

out. The head was disarticulated at the atlanto-occipital joint and examined for otitis. The concave and convex surface of the pinna were thoroughly examined. An incision was made along the lateral side of the pinna extending from the tragus to the temporal bone, thereby exposing the cartilaginous part of the ear canal. The pharyngeal region was exposed and examined for possible extension of the infection.

The osseous part of the ear canal, the middle and inner ear were opened following the procedure described by Jensen et al (1982 and 1983). The skin, auricula, tongue, muscles, hyoid bones, larynx, ventral soft tissues, mandible, retropharyngeal lymph nodes, calvarium and the brain were removed. The remaining skull was placed on a table on lateral position with the intended ear upward. A wooden probe was inserted into the full length of the osseous part of the ear canal. Using a regular dehorning saw, straight vertical plain incision was sawed parallel to the probe along the posterior edge of the canal through the tympanic cavity. The bones posterior to the incision were removed and the osseous canal and the tympanic cavity exposed by dissecting through using bone rongeurs, bone cutting forceps, tissue forceps, knives and scissors. After examining the regions through the cut surface, the ear segments were separated from the skull with another incision anterior to the ear canal and parallel to the first incision together with further dissection. The ear segment and the

auricula containing the cartilaginous part of the canal were fixed in 10% formalin solution for histological examination.

For microscopic studies the ear canal was separated from the bony and the cartilaginous walls of the fixed tissue by dissecting it through. This was then processed by the paraffin method, sectioned transversally and stained with Hematoxylin and Eosin stains. (Putt, 1972). The preparation was examined under a compound microscope.

4. RESULTS

4.1 FIELD STUDY

4.1.1 Point Prevalence

The prevalence of the disease in the traditional herds studied from Central Kajiado is shown in table 2.

A total of 413 cattle were examined out of 1729 cattle from 11 traditional herds in Central Kajiado. A prevalence rate ranging from 27.3% to 78.3% with the overall average rate of 58.4% was obtained through physical, otoscopic and microscopic examination. Bilateral and unilateral involvement of varying degrees of severity ranging from severe to mild and chronic otitis were noted.

Severely infected animals showed a loss of body condition. Although farmers reported occurrence of cases with central nervous symptoms, no single case was encountered in this study. On microscopic examination of ear swab samples, 202 of the infected animals (83.8%) were found to have worms in one or both ears. Some chronic cases had no worms while several of the clinically negative animals had worms.

Fifty eight out of 120 cattle slaughtered in two days at Mailitisa slaughter house were examined. Eight of these animals were found to be infected giving an infection rate of 13.8%. There was no infection in 35 cows examined from the Kajiado county council dairy farm. Here, the exotic breed animals are managed in a fenced farm with no contact with other animals in the area.

Two hundred cattle were examined out of 1380 cattle dipped in the five dipping centres during this study in Makuyu. The area prevalence of between 5% and 13.6% with the overall prevalence of 9.5% being recorded during the study (Table 3). Bilateral and unilateral clinical cases of moderate to mild and chronic severity were observed. No case with severe otitis or central nervous signs was encountered. Microscopic examination revealed 14 cases of the infected animals (73.7%) to have worms in one or both ears. Some chronic cases were without worms while some of the clinically negative animals had worms in their ears. There was no infection in the Nanga Estate dairy farm.

There was a significant difference in the prevalence ($P < 0.001$) and severity of the disease between the hot dry (semi arid) areas of Kajiado and the cold humid (high potential) areas of Makuyu division.

Table 2. The Prevalence of Bovine Parasitic Otitis in the Traditional Herds from Central Kajiado.

Herd	No. of cattle		No. of cattle infected			Prevalence %	Cases with worms	T C M	A
	per Herd	Examined	Bilaterally	Unilaterally	Total				
Yiare	236	45	18	5	23	51.1	18	D	T
Silonga	132	40	16	14	30	75.0	26	HS	T
Kosencha	140	45	12	13	25	55.5	20	D	De
Leiyo	120	30	5	8	13	43.3	10	D	S
Ntooki	96	30	11	4	15	50.0	15	D	S
Ngumila	136	46	25	11	36	78.3	30	D	T
Sapul	97	31	4	7	11	35.5	7	HS	De
Magui	250	30	8	12	20	66.7	13	HS	De
Kirema	62	33	12	9	21	63.6	21	HS	De
Mutunkei	200	50	28	10	38	76.0	36	D	De
Mmari	260	33	3	6	9	27.3	6	HS	S
Total	1729	413	142	99	241	58.4	202		

Key

TCM	-	Tick Control Method	A	-	Acaricide
HS	-	Hand Spray	D	-	Dip
De	-	Delnav	T	-	Triatix
S	-	Supadip			

Table 3. Area Prevalence of Bovine Parasitic Otitis in Makuyu Division

Dipping Centre (Area)	No. of cattle		No. of cattle infected			Prevalence %	Cases with worms
	per Herd	Examined	Bilaterally	Unilaterally	Total		
Kalianne	60	22	1	2	3	13.6	3
Mihango	130	40	0	2	2	5.0	0
Pundamilia	450	58	4	3	7	12.1	5
Malema	360	35	1	1	2	5.7	2
Kenjugu	380	45	1	4	4	11.1	4
Total	1380	200	7	12	19	9.5	14

All the dips use Supadip type of acaricide. The dipping centre is considered as an area of study and the day dipping rate as the herd size.

4.1.2 Nematode Species Associated with the Infection

Rhabditis bovis was found to be associated with the infection in all the 202 cases from Central Kajiado. Many female and male worms at different developmental stages were present in each of the ear swab samples.

Of the 14 cattle found to have worms in their ears from Makuyu, 6 (42.9%) were infected with Rh. bovis, 6 (42.9%) with Rh. blumi and 2 (14.2%) had unilateral mixed infection with the two species (Table 4). Rh. blumi was mainly found to be associated with chronic and mild infections which were characterized by presence of dark greenish or brown discharge in the ear canal. In the mixed infections, Rh. blumi occurred in lower proportions. All developmental stages were present in each of the swab samples.

Table 4. Nematode species Associated with Bovine Parasitic otitis in Makuyu

Dipping Centre (area)	No. Cattle with worms	No. of cattle with <u>Rh. bovis</u>			No. with <u>Rh. blumi</u>			No. with mixed infection		
		Bilateral	Unilateral	Total	Bilateral	Unilateral	Total	Bilateral	Unilateral	Total
Kalianne	3	2	0	2	1	0	1	0	0	0
Mihango	0	0	0	0	0	0	0	0	0	0
Pundamilia	5	0	2	2	1	2	3	0	0	0
Malewa	2	1	0	1	0	0	0	0	1	1
Kenjugu	4	1	0	1	0	2	2	0	1	1
Total	14			6			6			2

4.1.3 Assessment of the Role Played by Dips as Reservoirs of the nematodes

4.1.3.1 Nematode Species Supported by Dips in the Areas of Study

No worm was recovered from any of the dip samples obtained from the six dips studied in Kajiado. However, the mean survival time of Rh. bovis (The species found to be associated with the infection in the area) in the samples was 10 minutes in 51% understrength Triatix, 8 hours in 19% understrength supona, 3 days in over 50% understrength supadip, 30% overstrength Delnav and water and 4 days in 15% understrength Delnav. With the exception of Olkenos which was replenished two weeks before, all the dips had not been replenished for the last six months. Five dips were between 15% to 52% understrength while one was 30% overstrength (Table 5). During the study, larvae were found to survive longer than the adults in all dip samples. Gravid worms easily ruptured releasing their contents through the vulval opening.

In Makuyu, two live and 10 dead Rh. blumi worms were recovered from 500 ml of a dip sample obtained from Pundamilia dip. No worm was recovered in samples from the other dips. The mean survival time ranged from 3 to 4 days for Rh. bovis and from 21 to more than 28 days for Rh. blumi in the various dip samples (Table 6). With the exception of

Pundamilia which was replenished a month before, all the other dips had not been replenished for the last six months. All dip samples were understrength.

Rh. bovis survived for an average of 3 days in all samples and in distilled water. Larvae survived longer while gravid worms easily ruptured in all the samples. Rh. blumi on the other hand, survived and even multiplied in Mihango, Pundamilia and Malema dip samples which were muddy and at a very low concentration. It also survived for three weeks in water. Larvae survived longer than the adults.

4.1.3.2 Survival Rates of the Nematodes in Normal Concentration of the different Acaricides used in the Areas of Study.

Both species were found to be highly susceptible to Triatix in which a mean survival time of five minutes for adults and 10 minutes for larvae was observed. They both survived in Supona and Supadip for an average of an hour for adults and 2 hours for larvae. Rh. bovis survived for 24 and 48 hours in Delnav and for 48 and 72 hours in water for adults and larvae, respectively. Rh. blumi on the other hand, survived for 21 days for adults and 28 days for larvae in Delnav and water.

Table 5. Mean Survival Time of Rh. bovis in Kajiado dip Samples

Dip	Acaracide	Concentration %W/V		As % of Recommended	Mean survival time
		Used	Recommended		
Yiare	Triatix	0.012	0.025	51% Understr.	10 minutes
Kosencha	Delnav	0.0425	0.05	15% "	4 days
Leiyo	Supadip	0.010	0.05	50% "	3 days
Olkenos	Supona	0.045	0.05	19% "	8 hours
Ngumila	Supadip	0.024	0.05	52% "	3 days
Mutunkulei	Delnav	0.0649	0.05	30% Overstr	3 days
Control	Distilled water	0.0	0	0	3 days

Table 6. Mean Survival Time for Rh. bovis and Rh. blumi in Makuyu Dip Samples.

Dip	Acaricide used	Concentr. % W/V	% to normal concentration	No. & spp. of worms/L recovered	Mean survival time	
					<u>Rh. bovis</u>	<u>Rh. blumi</u>
Kalianne	Supadip	0.033	34% underst	-	3 days	21 days
Mihango	Supadip	0.018	74% "	-	4 days	>28 days
Pundamilia	Supadip	0.017	66% "	4 <u>Rh. blumi</u>	3 days	>28 days
Malema	Supadip	0.024	52% "	-	3 days	>28 days
Kenjugu	Supadip	0.031	38% "	-	3 days	21 days
Control	Water	0.0	0.0	-	3 days	21 days

4.2 EXPERIMENTAL STUDY

4.2.1 Clinical Response to the Infection

The clinical response to the infection during the 90 days of the experiment is shown in Appendix 1 and summarized in Table 7.

The response was classified as mild, moderate, severe and very severe (Lweno et al., 1983)

Mild clinical response was characterized by presence of small amounts of dark brown (increased glandular secretion) or dirty grey discharges otoscopically seen lining the inner ear canal epithelium. The epithelium was with or without mild inflammation or ulcerations.

Moderate Clinical Response had changes visible on visual and otoscopic examination. It was characterized by partly or extensively hyperaemic, ulcerated or necrotic canal epithelium which was also lined with discharge. The discharge showed a tendency of accumulating in the deep canal lumen.

Severe Clinical Response was characterized by the discharge accumulating in the entire canal and extending outward to soil the inner surface of the pinna. The epithelium was extensively ulcerated and/or necrotic and in some case thickened. The ear was sometimes droopy and frequently flapped.

Very Severe Clinical Response showed aural discharge oozing out of the canal (otorrhea) and draining through the tragus

region of the pinna to matt the pinna edges, ear base, the cheek and even the neck region. The epithelium of the canal was extensively ulcerated and necrotic and in some cases proliferated and thickened. The ear was usually droopy and frequently flapped. The head was sometime tilted towards the affected side.

4.2.1.1 Group 1: Animals Infected with Rh. bovis

Three of the four animals in this group showed some clinical response to the infection. All developed bilateral infections. The response ranged from moderate to severe, to very severe otitis. The incubation period varied from 5 to 17 days with an average of 10 days. Except in one ear of animal B3 (with a course of 26 days), the infection persisted to the end of the experiment. Worms were present in the ears with clinical response throughout the observation period.

The clinical reactions started with hyperaemia and swelling of the mucosa of the osseous part of the ear canal, which was later covered with a waxy brown material (increased glandular secretion). The amount of the discharge increased with time. Initially the discharge was semifluid and dirty-brown in colour. This spread outward along the canal walls and lumen. Later, the discharge changed into foul smelling, bloody, tenacious, and dirty-grey or dark brown exudate which oozed out from the canal to matt the concave surface of the pinna (Fig.11 and 12).

Table 7 Clinical Response to the Infection for 90 Days.

Group	animal	Ear	Incubation period-days	Clinical response	Course of the infection days
1	B1	R	10	X	80 (Up to the end of expt.)
		L	17	++	73 ,,
	B2	R	5	X	85 ,,
		L	5	X	85 ,,
B3	R	14	+	26	
	L	7	X	83 ,,	
B4	R		-		
	L		-		
2	B5	R		-	
		L	10	+--	3
	B6	R		-	
		L	17	+--	14
B7	R	10	+--	24	
	L	10	+--	51	
B8	R	14	+--	47	
	L	14	+--	76 (up to the end of expt.)	

KEY

- L Left Ear
- R Right Ear
- No clinical response (reaction)
- +-- Mild clinical reaction
- + Moderate clinical reaction
- ++ Severe clinical reaction
- X Very (more) severe clinical reaction

In more severe cases, the discharge oozed out (otorrhoea) and drained through the tragus to stain the pinna edges, ear base, cheek and even the neck region. (Fig.13 and 14). At a more advanced stage the discharges changed into thick dirty grey, less smelling material which tended to accumulate at the concha and blocked the ear canal, (Fig.15). In more severe cases, bouts of copious blood tinged, pussy exudate resembling a ruptured abscess were occasionally seen exuding out of the canal. Wavy motions of the worms were observed in the discharges at all stages on visual and otoscopic examination. Rh. bovis at different developmental stages was recovered from all the ear swabs.

The hyperaemia and swelling of the osseous canal mucosa was followed by patchy ulceration of the epithelium under the discharges. The lesions extended outwards and became extensive with time to give a raw (red) surface. Later, the epithelial tissue became necrotic and in some areas thickened and folded, especially in the osseous part. However, lesions did not extend beyond the canal entrance. There was slight enlargements of the retropharyngeal lymph nodes on the side with severe otitis. Severely affected animals were found to frequently flap the ears which were droopy. (Fig.16). Apparently, there was no rise in body temperature or pharyngeal and central nervous impairments. Animal B2 which had bilateral more severe otitis lost condition towards the end of the experiment (Fig.16).

4.2.1.2 Group 2. Animals Infected with Rh. blumi

There were mild clinical reactions in all the group 2 animals. There were two unilateral and two bilateral response. The reaction was characterized by increased dark brown soft material (cerumine secretion) covering mainly the osseous canal from which worms were recovered. There were no lesions associated with the discharge. The incubation period ranged from 10 to 16 days with an average of 12 days and a course of between 3 and 76 days (Table 7). In one ear of animal B8 the reaction persisted up to the end of the experiment but in the rest, it receded as soon as the worms disappeared from the canals (Appendix 1 and 2).

4.2.1.3 Group 3. Control animals

There was no clinical response in all the group 3 animals. The mucous membrane of the entire ear canal remained pinkish, smooth and shiny but patchily covered with waxy dark brown cerumine secretion. No worm was recovered from any of the animals' ear during the course of the experiment.

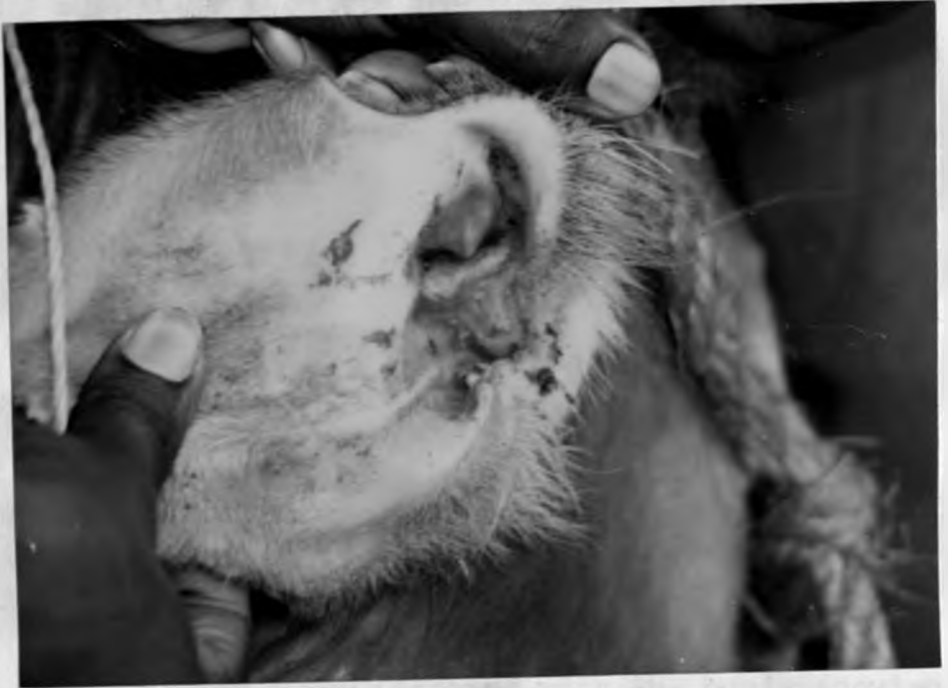

Fig. 11. Animal B2 left ear infected with Rh. bovis showing dirty grey discharge accumulating in the whole conchal region of the pinna and extending through the tragus.

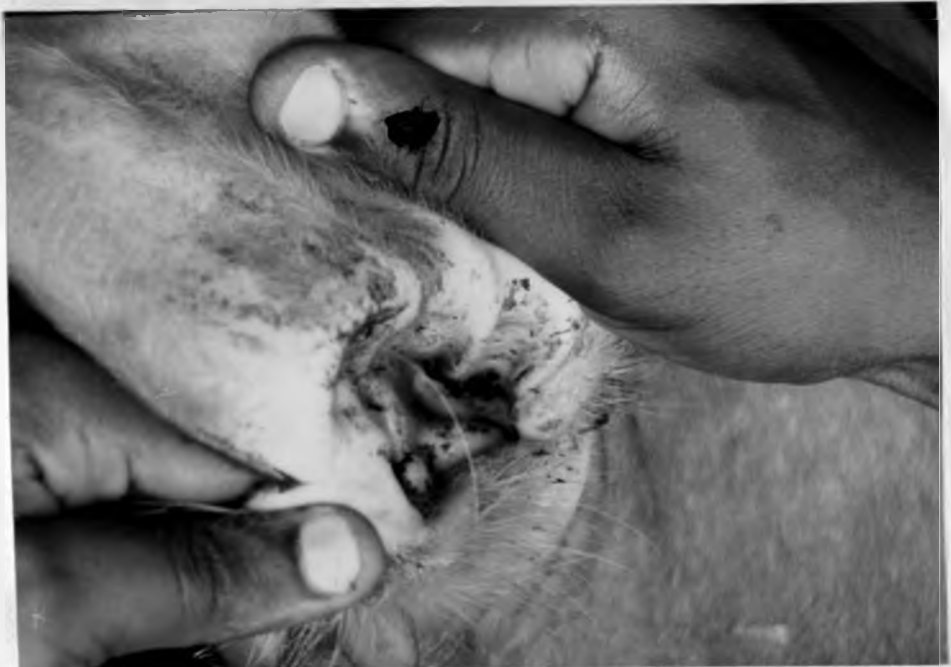

Fig. 12. Animal B3 left ear infected with Rh. bovis showing thick discharge blocking the entrance to the ear canal.

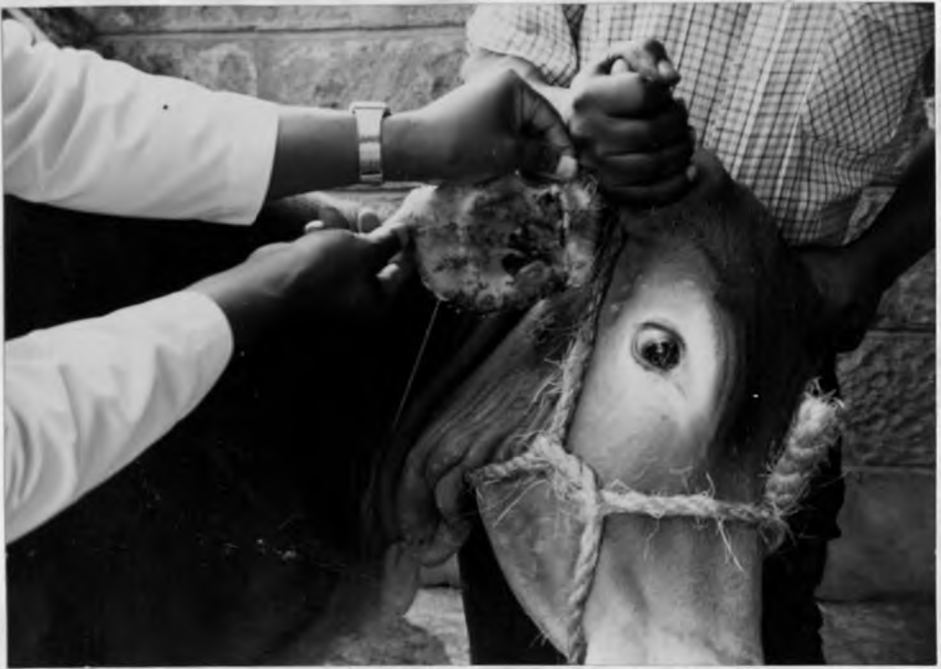

Fig. 13. Animal B2 right ear infected with Rh. bovis showing copious bloody dark brown discharge oozing out of the canal soiling the whole concave surface of the pinna, pinna edges, ear base and the cheek.

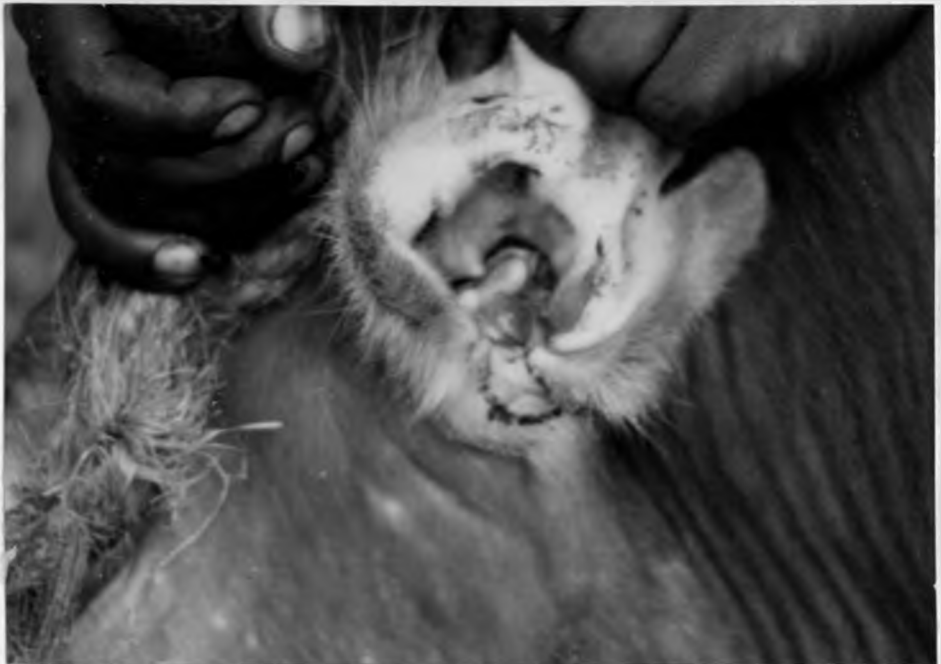

Fig. 14. Animal B3 left ear infected with Rh. bovis showing the conchal region with discharge draining through the tragus to matt the ear base

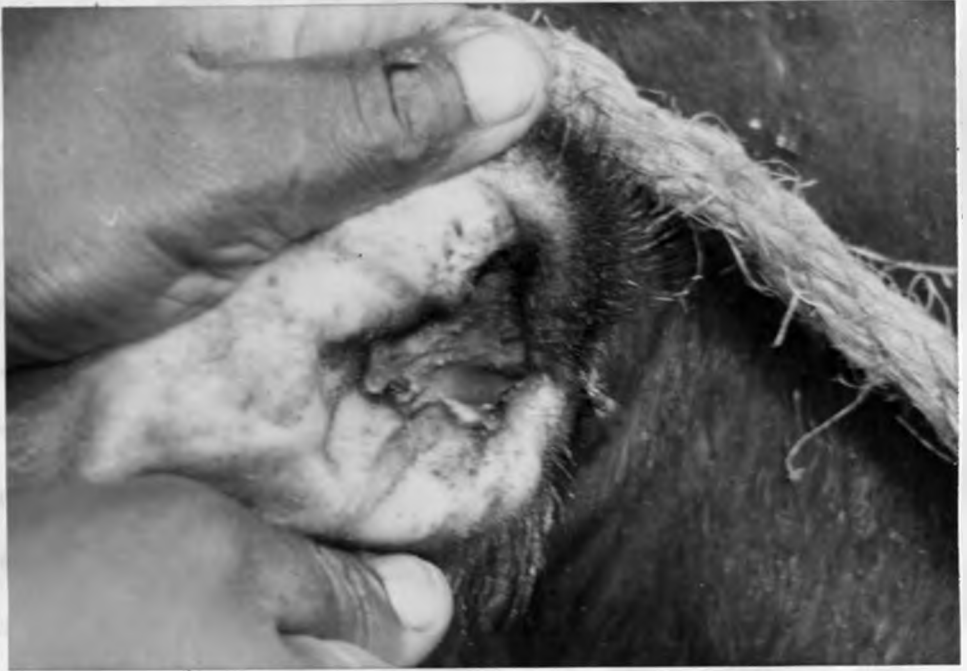

Fig. 15. Animal B1 right ear infected with Rh. bovis showing dirty grey discharge accumulating in the conchal region of the pinna and blocking the canal entrance.



Fig. 16. Animal B2 infected with Rh. bovis and developed bilateral otitis. The animal is emaciated and the more affected ear is droopy.

4.2.2 Gross Pathology

4.2.2.1 Group 1. Animals Infected with Rh. bovis

Except for animal B2 which was emaciated (Fig.16) the routine postmortem examination did not reveal any pathological change in the body systems other than the ears of all other animals in this group. There was thick greyish discharge with wavy motions along the entire ear canal and the conchal region of the right ear of animal B1, both ears of B2 and the left ear of B3. The left ear of B1 had a slimy yellowish grey discharge lining the osseous canal. Under the discharge in all the affected ears was an ulcerated and necrotic epithelium. The lesions were more pronounced in the osseous part of the canal. Slight thickening of some portions of the osseous canal mucosa of right ear of animal B1 and left ear of B3 were observed. There were no morphological changes in the middle ear where an empty tympanic cavity lined by smooth shiny mucous membrane was observed in all the ears. The eustachian tube, the inner ear and the brain were also not affected. Both ears of animal B4 and the right ear of B3 had no pathological change.

4.2.2.2 Group 2. Animals Infected With Rh. blumi

Animal B5 died 50 days after infection and 26 days after eliminating the nematodes and recovering from a 3 day mild clinical reaction in the left ear. The animal died as a result of being crashed in a feeding trough by other

animals. No pathological changes associated with infection could be seen in any of the two ears of any animal. The left ear of animal B8 had a slimy greyish exudate along the osseous canal walls. Underneath the discharge the epithelium had areas of hyperaemia (redness) and Rh. blumi was recovered from the discharge. There were no pathological changes in the ears of the rest of the animals in the group.

4.2.2.3 Group 3. Control Animals

There were no pathological changes in all the animals (B9, B10 and B12). The mucous membrane of the canal remained pinkish, smooth and shiny but patchy with waxy dark brown ceruminal secretion. No organisms were recovered from the canals.

4.2.3 Histopathology

4.2.3.1 Group 1. Animals infected with Rh. bovis

The right ear of animal B1 and the left ear of animal B2 showed a proliferative canal mucosa reaction of the type of (Fig.17) or with excessive keratin layer and keratin hair follicles. The osseous part was more thickened, five times its normal thickness. In some parts the thickened epithelium was disrupted and necrotic. There were areas with dense aggregates of inflammatory cells (mainly neutrophils (Fig.19)). The dermis was either

animals. No pathological changes associated with the infection could be seen in any of the two ears of the animal. The left ear of animal B8 had a slimy greyish brown exudate along the osseous canal walls. Underneath the discharge the epithelium had areas of hyperaemia (reddened) and Rh. blumi was recovered from the discharge. There was no pathological changes in the ears of the rest of the animals in the group.

4.2.2.3 Group 3. Control Animals

There were no pathological change in all the control animals (B9, B10 and B12). The mucous membrane of the ear canal remained pinkish, smooth and shiny but patchy stained with waxy dark brown cerumine secretion. No worm was recovered from the canals.

4.2.3 Histopathology

4.2.3.1 Group 1. Animals infected with Rh. bovis

The right ear of animal B1 and the left ear of B2 showed a proliferative canal mucosa reaction of the canal. The cartilaginous canal epidermis was thickened and devoid of (Fig.17) or with excessive keratine layer and keratinized hair follicles. The osseous part was more thickened up to five times its normal thickness. In some parts the thickened epithelium was disrupted and necrotic. There were areas with dense aggregates of inflammatory cells (Fig. 18) mainly neutrophils (Fig.19). The dermis was either fibrotic

or disrupted and highly infiltrated with inflammatory cells, more so in the osseous canal. The cells comprised of eosinophils, lymphocytes, plasma cells and macrophages (Fig.20). The inflammatory reaction did not go beyond the dermis.

Both ears of animal B2 and the left ear of B1 had focally or extensively desquamated, disrupted and necrotic epithelium. In the cartilaginous part, the epithelium was either focally affected or remained intact but was hyperkeratinized including the hair follicles. In most cases the osseous canal epithelium was extensively desquamated starting from its junction with the cartilaginous part (Fig.21). In some areas it was completely eroded or only a thin layer of one or two cells remained (Fig.22). Where erosion was not complete it was infiltrated with neutrophils, eosinophils and plasma cells mainly along the dermal papillae. The dermis under a damaged or intact epithelium (Fig.23) was in most parts disrupted and infiltrated with inflammatory cells. The papillary layer was infiltrated with eosinophils, neutrophils, plasma and mononuclear cells (Fig.24) while the reticular layer had dense aggregates of mononuclear cells (Fig.25). The reaction extended into the hypodermis (subcutis) of the osseous canal of the right ear of animal B2. The ceruminous glands had dilated lumens which were lined with columnar secretory cells and dilated ducts; an indication of hyperactivity (Fig.26). No nematodes were

observed in all layers of the mucosa of the affected canals.

The right ear of animal B3 which had recovered from a moderate clinical reaction 50 days before slaughter had patchy erosion and areas of intact keratinizing osseous epithelium. There was dermal reorganization represented by fibrosis and many capillaries but with few eosinophils and neutrophils (Fig.27). Both ear canals of animal B4 which had not shown any clinical response had few eosinophils in the intact epidermis and some mononuclear cells in the dermis.

4.2.3.2 Group 2. Animals Infected with Rh. blumi

There were patches of disrupted and necrotic epidermis as well as cellular infiltration in the dermis of the left ear canal of animals B5, B7 and B8. The inflammatory cells comprised of neutrophils, macrophages, plasma cells, mononuclear cells and few eosinophils. The reaction was more severe in animal B7 where the affected areas had both the epidermis and dermis seriously disrupted and the dermis infiltrated with dense aggregates of cells mainly mononuclear cells (Fig.28 and 29). The ceruminous glands were hyperactive in most of canals in the group. The other ears of the animals did not show any pathological change.

4.2.3.3 Group 3. Control Animals

There was no pathological change in the ear canals of all animals in this group. The cartilaginous portion of the

canal had a relatively thin keratinizing stratified squamous epithelium. It had many hair follicles which could extend deep into the hypodermis. The dermis had many sebaceous glands and few ceruminous glands or their ducts (Fig.30). The ceruminous glands which were mainly found in the hypodermis (subcutis) had cuboidal and sometimes columnar secretory cells (Fig.31). The osseous portion of the canal had a relatively thick non keratinizing stratified squamous epithelium. The portion had no hair follicles and it was non-glandular (Fig.32). This observation conforms with the description of the normal histology of the ruminant ear canal (Trautmann, 1952).

4.2.4 Bacterial Isolation

The following bacteria (with the number of isolation per number of ears in brackets) were isolated from the ear canals of the experimental animals before infection: Beta hemolytic Bacillus spp (15), Streptococcus spp -, Beta hemolytic (4), Alpha hemolytic (7), and non hemolytic (1), Staphylococcus aureus (8), Staph. albus (2), Staph. epidermidis (1), Pseudomonas spp (4), Escherichia coli (2), and Enterobacter (1).

At the end of the experiment the isolates were: Streptococcus spp Alpha haemolytic (12), Beta haemolytic (2), non haemolytic (1), Staphylococcus aureus (11), Staph. epidermidis, (1), Beta haemolytic Bacillus spp. (8), E. Coli

(5), Pseudomonas spp (5), Micrococcus spp (1), and Proteus vulgaris (1).

The occurrence of the bacteria in each ear canal of the experimental animals before and at the end of the experiment is shown in Appendices 3 and 4.

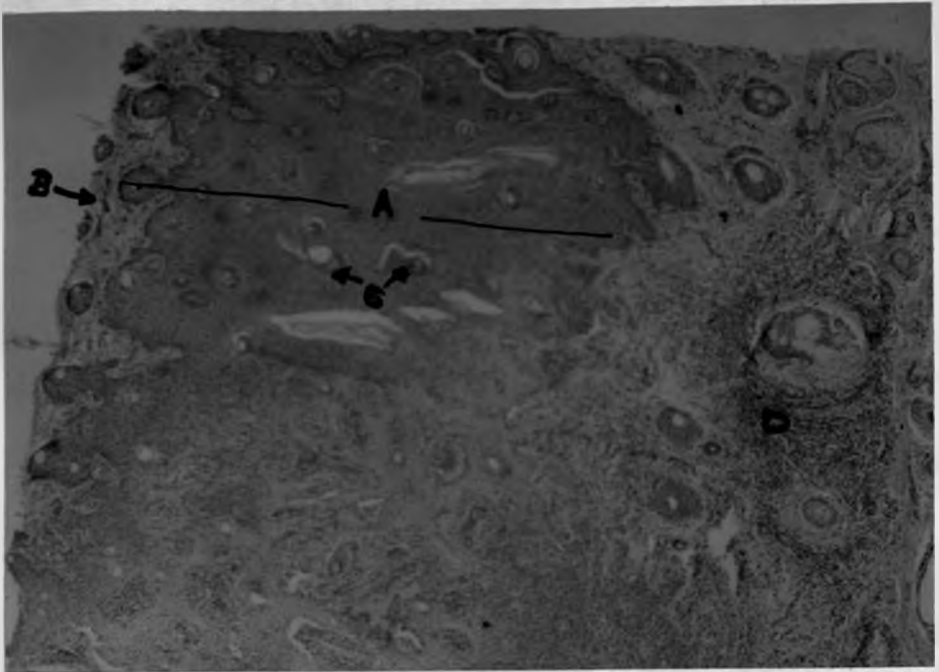


Fig. 17. Cartilaginous part of the left ear canal of animal B3 infected with Rh. bovis showing a thickened epidermis (A) devoid of keratine layer (B) but with keratinized hair follicles (C). The dermis is infiltrated with inflammatory cells (D) (H & E)x40



Fig. 18. Osseous part of the right ear canal of animal B1 infected with Rh. bovis. Extremely thickened epithelium (A) with areas of inflammatory cell infiltrations (B). The dermis is also infiltrated (C) (H & E)x40

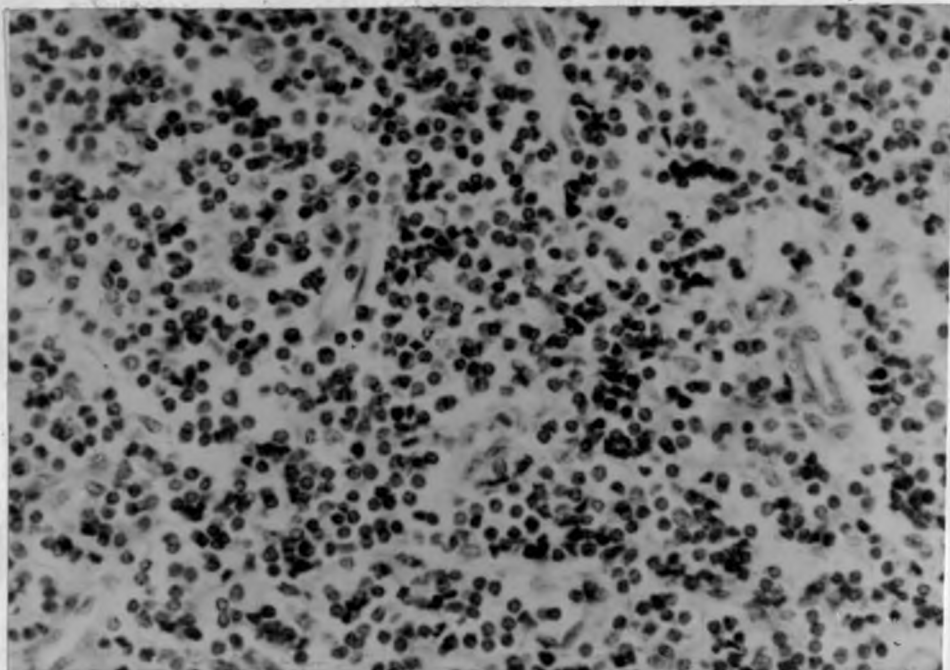


Fig. 19. Osseous part of the right ear canal of animal B1 infected with Rh. bovis. An area of the thickened epithelium which is infiltrated with inflammatory cells, mainly neutrophils (H & E)x400.

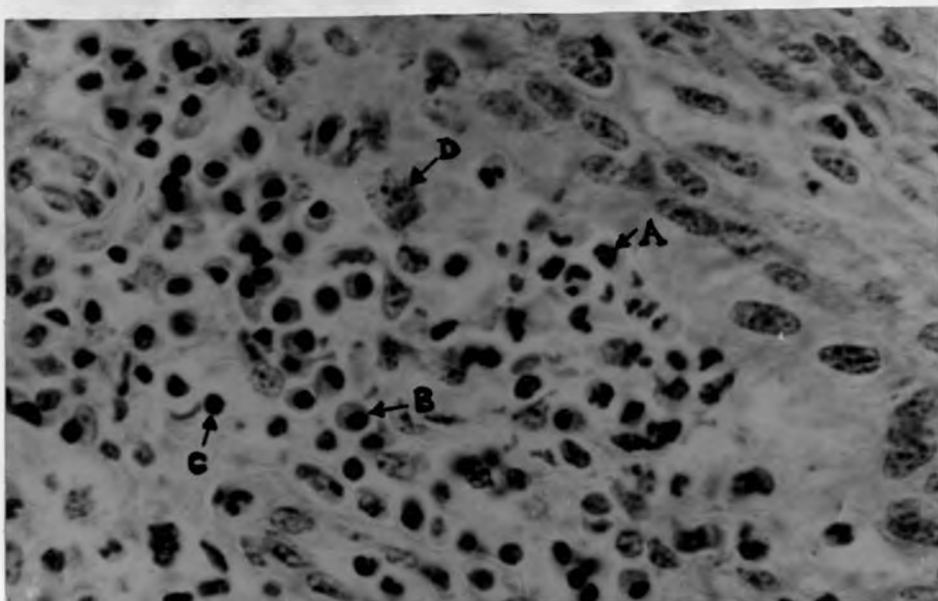


Fig. 20. Osseous part of the right ear canal of animal B1 infected with Rh. bovis. The papillary layer of the dermis under the thickened dermis showing many eosinophils (A), plasma cells (B), lymphocytes (C) and macrophages (D) (H & E) x630

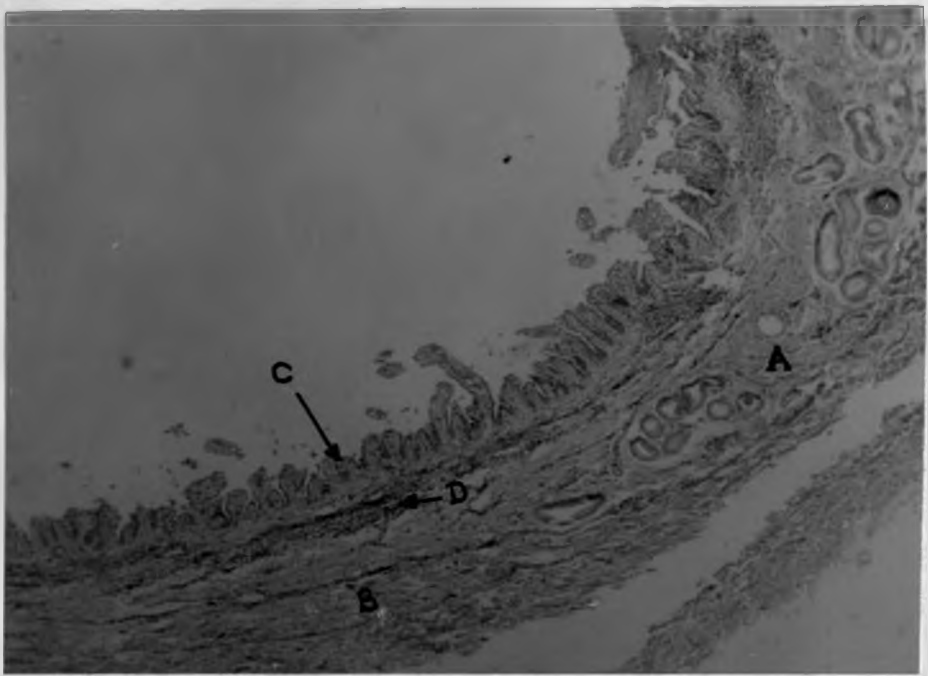


Fig. 21. Junction of the cartilaginous (A) and the osseous part (B) of the left ear canal of animal B1 infected with Rh. bovis. The epithelium is extensively eroded (C) and the dermis is infiltrated with inflamatory cells (D) (H & E)x40.

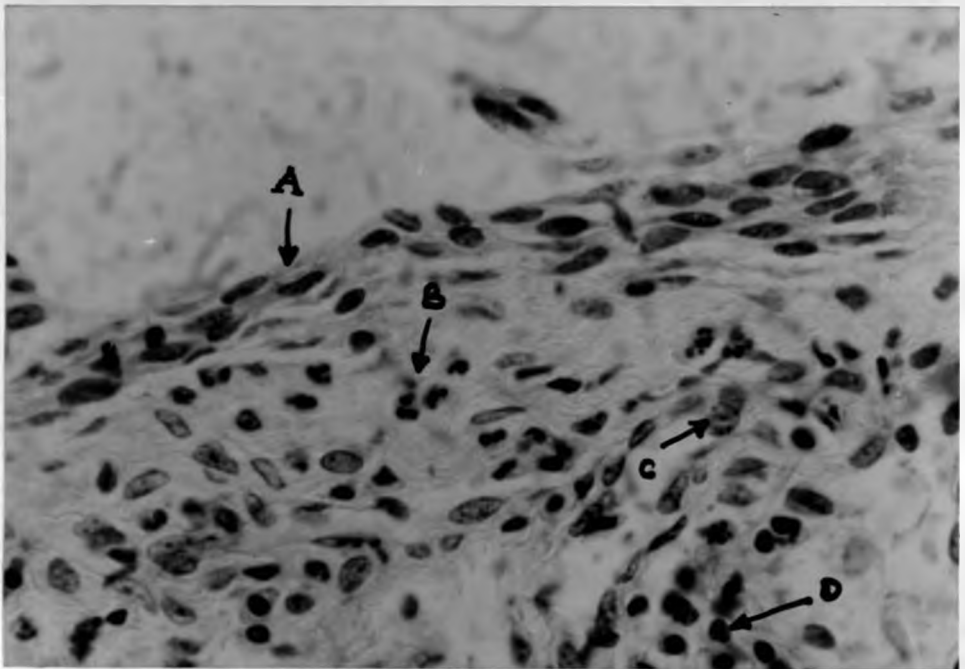


Fig. 22. Osseous part of the left ear canal of animal B1 infected with Rh. bovis. The epithelium is desquamated leaving only a thin layer (A). The papillary layer of the dermis is infiltrated with eosinophils (B) macrophages (C) and lymphocytes (D) (H & E) x630

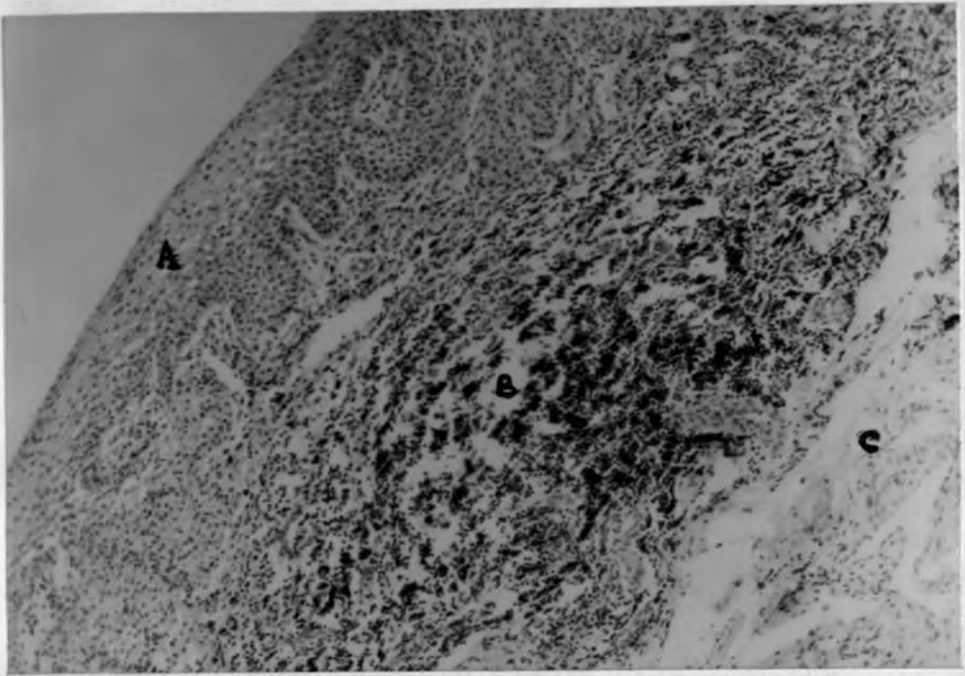


Fig. 23 Osseous part of the right ear canal of animal B2 infected with Rh. bovis showing a disrupted and inflammatory cell infiltrated dermis (B) between intact epidermis (A) and hypodermis (C) (H & E)x100

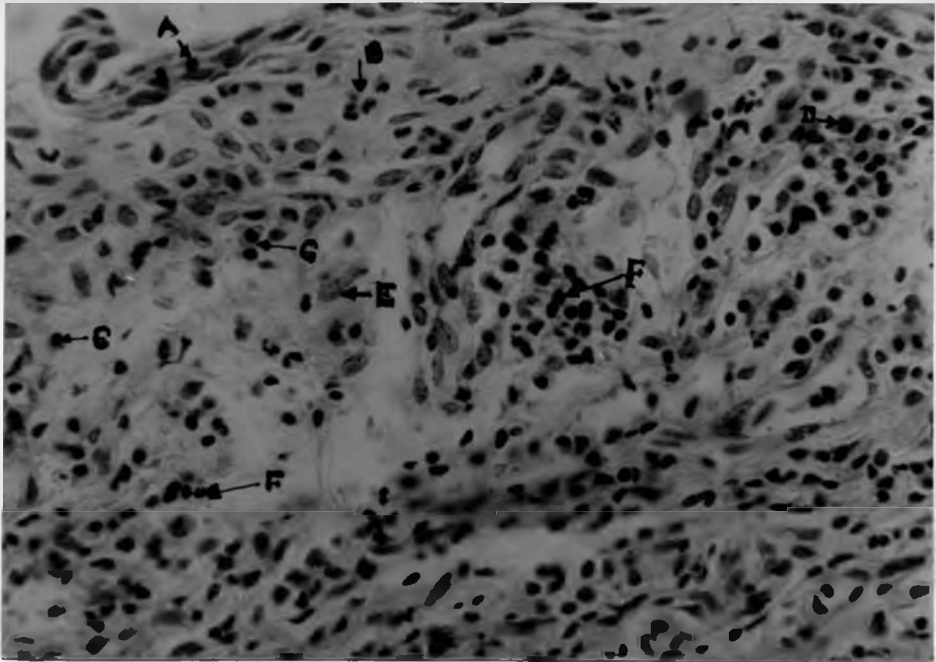


Fig. 24. Osseous part of the left ear of animal B3 infected with Rh. bovis. The epithelium is desquamated leaving only a thin layer (A). The papillary layer of the dermis is infiltrated with eosinophils (B) plasma cells (C), neutrophils (D), macrophages (E), and lymphocytes mainly towards the reticular layer. (H & E)x400

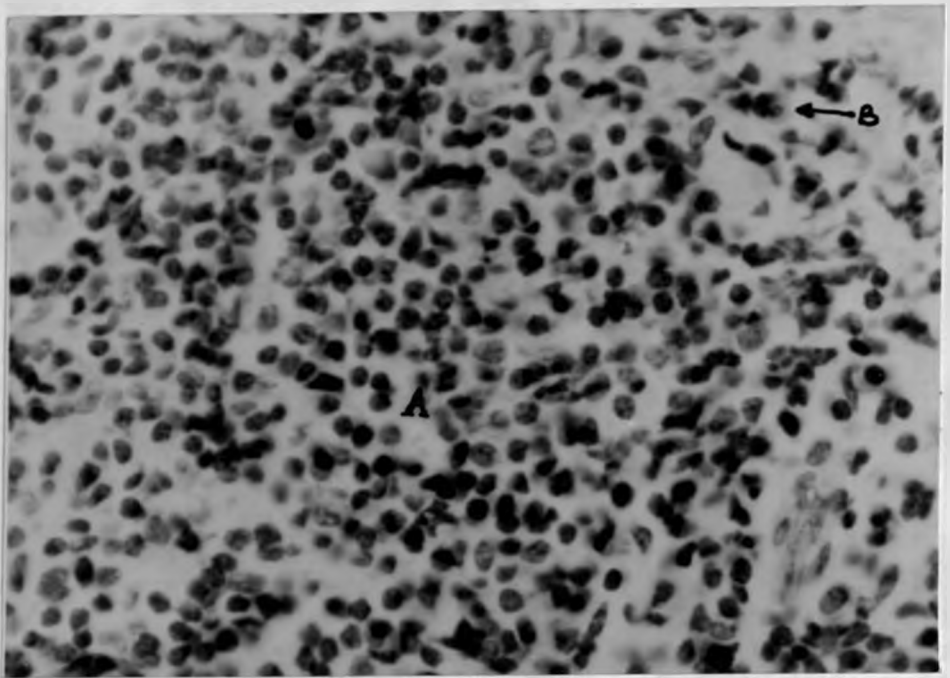


Fig. 25. Osseous part of the right canal of animal B2 infected with Rh. bovis. The reticular layer of the dermis is densely infiltrated with mainly mononuclear cells. (A). Few eosinophils are seen towards the less cellular papillary layer (B) (H&E) X 630

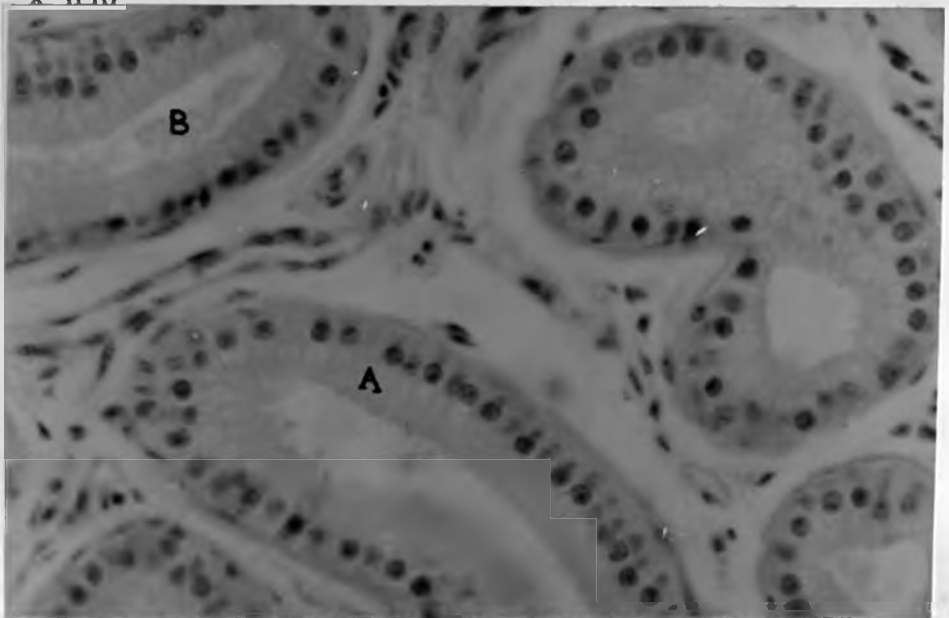


Fig. 26. Cerumineous glands in the hypodermis of the left ear of animal B1 infected with Rh. bovis. The secretory cells are columnar (A) the lumen is dilated and in some places filled with eosinophilic material (B) (H & E)x630

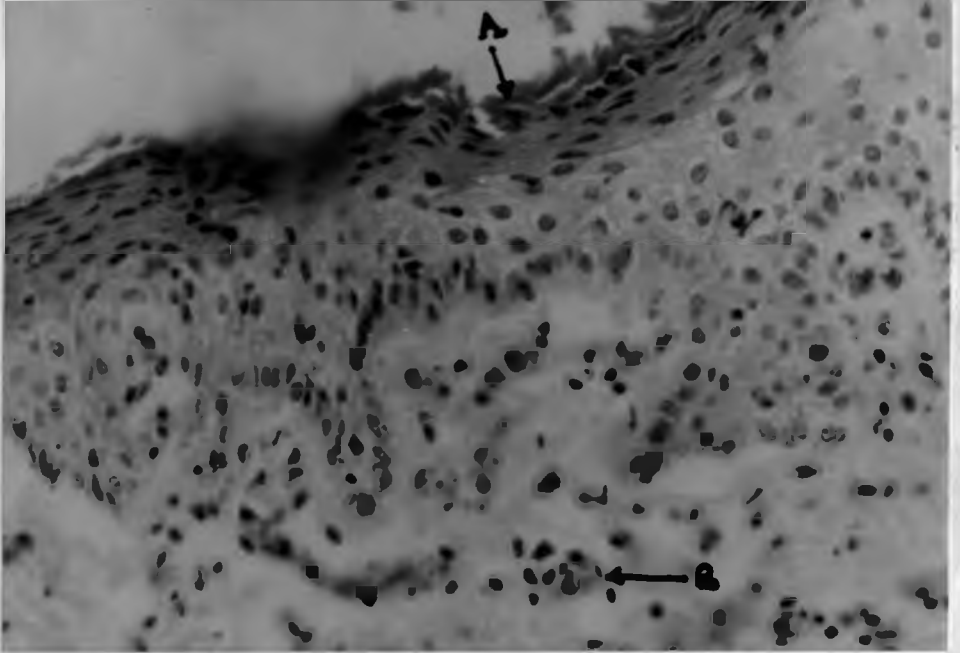


Fig. 27 Osseous part of the right ear of animal B3 infected with Rh.bovis but had eliminated the worms 50 days before slaughter. The epithelium is keratinized(A)(normally is nonkeratinized) and the dermis is organizing represented by many capillaries (B) (H & E)x400



Fig. 28 Osseous part of the left ear canal of animal B7 infected with Rh.blumi. The epithelium is disrupted (A)and the dermis is infiltrated with inflammatory cells.(B) The hypodermis (C) is not affected (H & E)x10

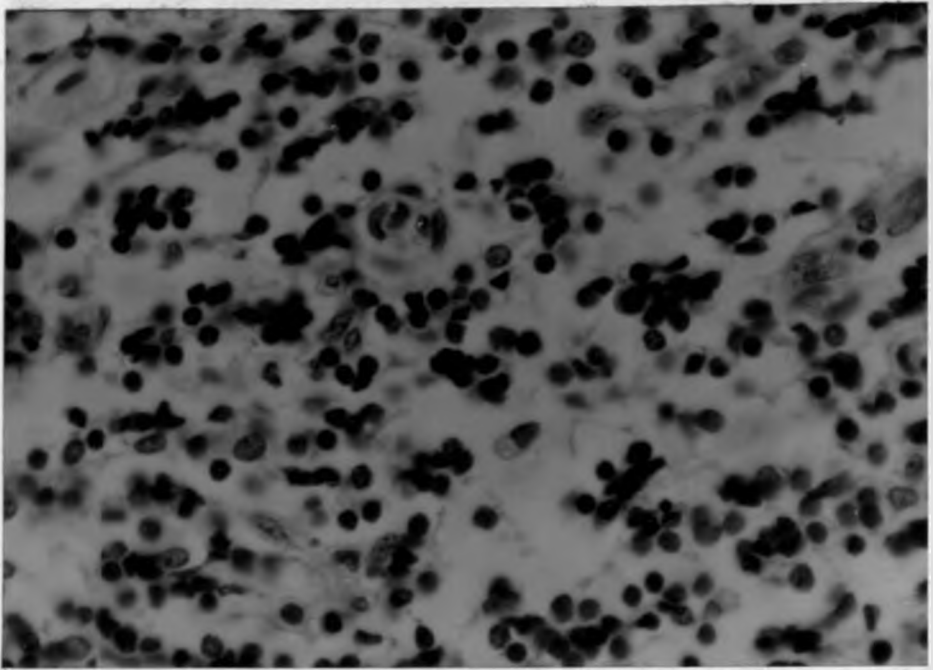


Fig. 29 Osseous part of the left ear of animal B7 infected with Rh. blumi. The dermis is infiltrated mainly with mononuclear cells (H & E)x630

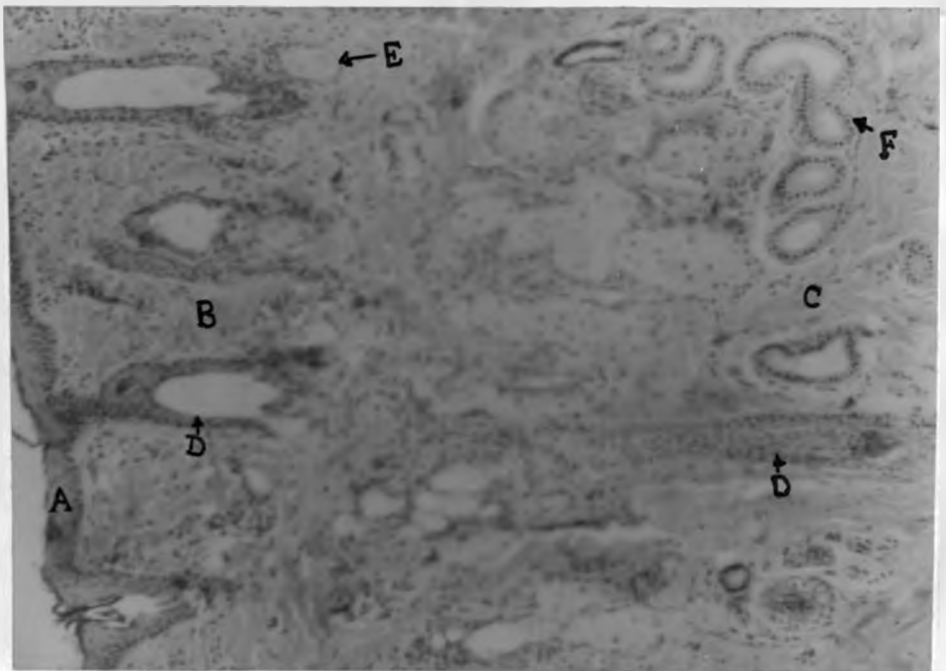


Fig. 30 Cartilaginous part of the left ear canal of animal B9 showing the cornified stratified squamous epithelium (A), dermis (B) and hypodermis (C), hair follicle extending into the hypodermis (D), sebaceous glands (E) and cerumineous glands in the hypodermis (F) (H & E)x100

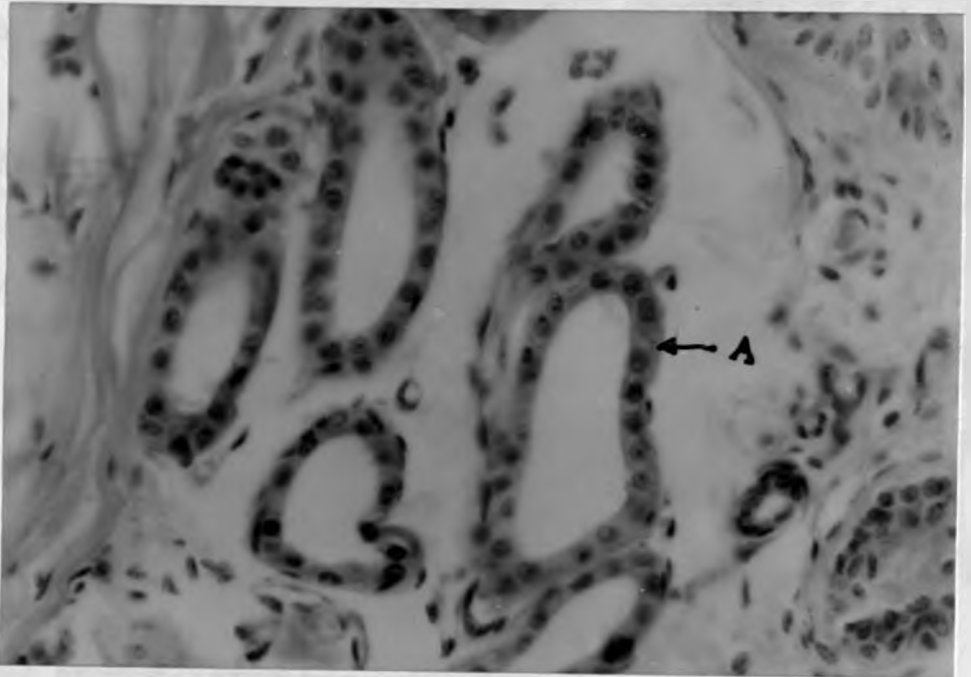


Fig. 31 Less active cerumineous glands from the left ear canal of animal B9 which was not infected. The glands have cuboidal secretory cells(A) (H & E)x630




Fig. 32 Osseous part of left ear canal of animal B11 showing a normal non cornified stratified squamous epithelium (A). a thin dermis(B) overlying a nonglandular hypodermis (C). The part of canal has no hair follicles (H & E)x10

5.0 DISCUSSION, CONCLUSIONS AND RECOMMENDATIONS

5.1 DISCUSSION

One of the objectives of this work was to determine the prevalence of the disease in the local breeds of cattle from the hot dry and the cold humid areas of Kenya. During the study, a prevalence of up to 78.3% was recorded from the hot dry areas of Kajiado while a prevalence of up to 13.6% was recorded from the cold humid areas of Murang'a. There was a significant difference in the prevalence of the disease ($P < 0.001$) between the two areas. The disease was more severe in the hot dry areas than in the cold humid areas. The prevalence and severity of the disease observed in this study in the hot dry areas were comparable to those of the hot humid coastal areas of Tanzania (Msolla, 1984) where the disease is known to be of more economic importance. This observation appears to be economically significant since the extensive semi arid and arid (hot dry) areas of East Africa are predominantly populated with the more susceptible local breeds of cattle. For instance in Kenya the areas which form the Kenyan rangelands account for 88% of the country's land areas and more than half of the country's cattle are found in these areas. (Bekure et al, 1991).

High temperatures and moisture contents in the ear canal are believed to be among the predisposing factors of otitis externa in domestic animals and man (Hayes et al,

1987). These conditions are believed to stimulate excessive ceruminal secretion in the canal in which the saprophytic bacteria and parasites multiply to a pathogenic level. In the hot dry areas, animal dipping for tick control results in increase in the ear canal moisture contents which together with the high ambient temperatures provide the favourable environment for the development of the disease. This is supported by the high incidences encountered in the dipped animals in the areas. However, the role of the increased moisture content in the development of the disease may be confirmed by reproducing the disease under controlled ear canal moisture contents.

During the study no case with central nervous symptoms, a fatal stage of the disease, was observed although some cattle owners in Kajiado reported to have lost cattle through this disease. Infected animals showed loss of body condition which may have been as a result of reduced grazing caused by fly worry and painful inflammatory changes in ear canal. Poor body condition predisposes the animal to intercurrent diseases. Farmers' experiences in Kajiado suggest that infected animals are more susceptible to East Coast Fever than uninfected ones.

The infection was absent in the exotic dairy animals in the farms studied in Kajiado and Murang'a. The animals in these farms were managed in fenced areas without contact with other animals in the vicinity. The absence of the disease therefore could be as a result of management rather

than the susceptibility. Lweno et al, (1983) and Msolla et al, (1986) have reported occurrence of the disease in exotic dairy animals.

83% of the infected animals were found to have nematodes in the ears. This indicates that the otitis observed was parasitic. Some chronic cases were without nematodes. Higher proportion of cases without nematodes were observed in the cold humid areas (26.3%) compared to the hot dry areas (16.2%). The difference may be due to lowered nematode activity in the cold areas. Occasionally in chronic cases the nematodes are eliminated (Msolla et al, 1986). The elimination may be a result of the host immune response or due to excessive accumulation of exudate in the canal amplified by the secondary bacteria infection thereby creating an unfavourable environment for the nematodes. Such observation has been reported in parasitic otitis in dog and sheep (Jubb et al, 1985, Morgan, 1992). Many animals without clinical otitis were found to have nematodes in their ear canals. Msolla, (1984) reported a morbidity of up to 75-80% in a herd with as low as 4-5% clinical cases. This observation suggests that presence of other predisposing factors are important for an infected ear to develop a clinical parasitic otitis.

Rhabditis nematodes were found to be associated with the infection. Unlike in other parasitic Rhabditis such as Rh. strongyloides infection in which only the larval stage is parasitic (Levine et al, 1950, Scott, 1988), all

developmental stages were present in all the ear swab samples examined. This implies that the life cycle of the worms is completed within the host ear. As a result of this infected animals serve as sources of infection to others and of environmental contamination over a long period of time. Rhabditis bovis and Rh. blumi were identified during the study. These are the same species found to be associated with the infection in different parts of Tanzania (Msolla et al. 1986). This observation may suggest that the two could be the main species associated with the disease in East Africa and possibly in Africa as whole.

There was a significant difference in the occurrence of the two species between the hot dry areas and the cold humid areas. There was also a difference in the severity of the disease they caused. Rh. bovis alone was found in the hot dry areas but both species were found in the cold humid areas where they occurred separately or in mixed infection. Rh. blumi is known to flourish well in moist soil and manure which are considered to be its reservoirs. Its absence from the hot and dry areas may be attributed to the harsh dry environment which dominates a long period of the year. On the other hand in the cold and humid areas the species can survive and breed in the moist soil, manure and garbage which do not easily dry. Msolla et al. (1989) have demonstrated the occurrence of large numbers of the species in soil and manure from sleeping and collecting pens especially during rainy season. They also observed a

positive correlation between the number of nematodes and the moisture content of the manure and soil. Rh. bovis seems to depend on means other than manure and soil as its reservoir.

The role of Rh. blumi in the development of the disease may be less significant when compared to Rh. bovis. In this study it was found alone only in mild and chronic cases. In mixed infection it occurred in lower proportion than the Rh. bovis. These observations are in agreement with those of Msolla et al (1986). The free-living species may be a mere contaminant of the chronic otitis where the pathogenic Rh. bovis has been eliminated. On reaching the bacterial infected wounds, the worms proliferate by feeding on the bacteria and debris. Similarly it can contaminate the cerumene contained in the healthy canal where its irritation results into mild inflammatory changes. Saprophilus Rhabditis species are known to occur where bacteria are plentiful on which they feed. It has been shown that their breeding depends on ingestion of living bacteria (Goodey, 1963). It is possible that like Rh. axei a pseudoparasite of animal and human (Levin et al, 1963), Rh. blumi can also be found in other body parts which come in contact with the contaminated soil. It is also possible that it may contaminate wounds in body parts other than the ear. Attempts to isolate the worms from other parts of the animal body may be carried out to confirm this.

Rhabditis bovis was found to cause more severe otitis in the hot dry areas than in the cold humid areas. The

severity in the hot dry areas was comparable to those of hot humid areas. It seems that, low ambient temperatures in the cold humid areas have a negative effect on the activities and multiplication rates of the ectoparasite. Further more, low temperatures have less stimulating effect on the ear canal glandular secretion which is required to create the favourable environment for the development of the disease.

Rh. bovis was not isolated from any of the dips studied while Rh. blumi was recovered from one Supadip dip which was 66% understrength. Almost all the dips studied were muddy and understrength. The failure to recover the worms could be a result of inadequate stirring of the dipwash during sample collection. Although Msolla (1984) reported occurrence of the worms in all layers of dipwash, it has been observed during this study that the worms usually settle at the bottom where they may become trapped in the mud.

When introduced in the dip samples obtained from the field, Rh. bovis survived for an average of 3 days in over 30% understrength Supona and Supadip but survived for only 8 hours in 19% understrength Supona. Rh. blumi survived and even multiplied in over 50% understrength Supadip. In the correct strength solutions of the two acaricides which are different preparations of chlorfenvinphos, both species survived for less than two hours. Chlorfenvinphus is a member of group two organophosphate insecticide. Organophosphates are known to have anthelmintic activity and some have been used for this purpose (Brander and Pugh,

1977). This study shows that understrength muddy dips of the two acaricides are good reservoirs of Rh. blumi. However, the survival time of Rh. bovis is long enough for the nematodes to be transmitted into a healthy ear during dipping. Moreover, the survival limit does not seem to be a result of the acaricide effect, for the same survival time is observed in water.

Rh. bovis was found to survive for an average of 3 days in Delnav dip samples which were between 15% understrength and 30% overstrength and in correct strength fresh preparation. Rh. blumi survived for more than 28 days in such fresh preparation. This shows that Delnav (Dioxathin) a member of group one organophosphates has no effect whatsoever on the worms. Farmers in Kajiado complained that Delnav was responsible for the disease. However, the use of the acaricide has been prohibited in many parts of Kenya due to the development of tick resistance against it. The survival rate of Rh. blumi observed in this study is similar to that of what was referred to Rh. bovis in toxaphene, (a member of chlorinated hydrocarbons) observed by Msolla, (1984). From this study it seems that they were dealing with Rh. blumi rather than Rh. bovis. As low as 52% understrength Amitraz adiamide dipwash (Triatix) was found to be lethal to the worms. Amitraz adiamide is a member of Armidin group of insecticides. Both species died within 10 minutes in the correct strength fresh preparation of this acaricide.

In all cases larvae were relatively more resistant to the acaricides than the adults. Rhabditis larvae have a relatively thicker cuticle which is less permeable to water soluble substances than the adults (Skryabin, 1984). In an adverse condition they develop an even thicker coat to become survival larvae which can survive longer (Brockelman and Jackson, 1974).

In this study it has been observed that Delnav and understrength Supona and Supadip dips serve as reservoirs both species. Msolla et al (1987) tried to control the disease through treating toxaphene dips with nicotine. The treatment killed the worms in the dips and from the infected ears during dipping. The approach seems to be more advantageous as it treats the reservoir and the infected and carrier animals at the same time. However it is known that nicotine has a narrow range of safety. (Brander and Pugh, 1977). It is also important to know its efficacy when combined with acaricides other than toxaphene. Use of amitraz diamide and correct concentrations of Chlorfenvinphos dips may have the same results. Topical application of these acaricides especially of amitraz diamide to cleaned ears can be tried.

During the experimental study to determine the pathogenicity of the two nematode species, three of the four cattle infected with Rh. bovis developed a moderate to very severe bilateral otitis within an average of 10 days. Lweno et al (1983) in their study, reported an incubation period

of 14 days. The infection persisted up to the end of the 90 days period of the experiment. Worms were present in the infected ears all along the course of the infection. The severity of the disease, however, decreased towards the end of the experiment. More lesions were found in the inner canal unlike in the field cases where the lesions can extend outwards up to the conchal region. This may be due to the absence of flies which are known to enhance the extent of the damage (Lweno et al 1983). The experiment was terminated before the disease could enter the chronic stage. The clinical, pathological and histopathological changes observed in these animals were similar to those observed in a field study by Lweno et al (1983). This confirms that Rh. bovis is a pathogenic species associated with the disease.

No animal developed clinical otitis in all the four cattle infected with Rh. blumi although all of them showed a unilateral or bilateral increased cerumine secretion from which the worms were recovered. The reaction commenced within an average of 12 days following infection but receded soon after the disappearance of the worms from the canal. This may imply that the species is less or not pathogenic. It seems that the presence of the worms in the ear canal causes irritation which stimulates excessive glandular secretion. The increased cerumine supports more growth of the aural bacterial flora whose activities changes it into a soft dark brown material. The saprophytic worms then proliferate by feeding on the bacteria and debris.

The reaction persisted up to the end of the experiment only in the left ear of animal B8. At postmortem, the ear had a hyperaemic and slight patchy erosion of the epithelium. Proteus vulgaris and alpha-hemolytic Streptococcus spp. were isolated from the ear. On histological examination, the left ears of animals B5, B7 and B8 which had alpha-hemolytic Streptococcus spp and Staphylococcus aureus, showed patches of disrupted and necrotic epithelium. The dermis had areas of inflammatory cell infiltration mainly neutrophils, mononuclear cells, macrophage and few eosinophils. This observation and the mild clinical reactions found to be associated with Rh. blumi in the field cases may be a result of bacteria rather than the nematode. The bacteria proliferate to a pathogenic level under the favourable ear canal created by the nematode irritation. The bacteria have been reported in animal otitis, (Fraser, 1961; Jensen et al., 1983).

Several pyogenic and putrefying bacteria were isolated from the ears with or without otitis in all the experimental animals at the end of the experiment. Most of these were present in the ears even before infection. The bacteria caused suppurative and necrotizing inflammation in the animals infected with Rh. bovis but failed to produce the same effect in animals infected with Rh. blumi and in control animals. Lweno et al., (1983) and Msolla et al., (1986) in their attempt to reproduce the disease in cattle and rabbits respectively, observed that addition of bacteria

in the Rh. bovis inocula made little difference in the development of the disease. Normally the intact skin is impervious to many bacteria. The bacteria take advantage of the worm damaged skin to complicate the infection. They are also responsible for the reported otitis media and meningo-encephalitis which is the cause of death in the disease. (Lweno et al, 1983). Further more the bacteria are responsible for the chronic cases where the nematode has been eliminated, (Msolla et al, 1986).

The clinical, pathological and histopathological changes observed in Rh. bovis infected group appear to be in agreement with the pathogenesis of the disease as proposed by Lweno et al, (1983). Initially the worms cause irritation to the canal walls resulting in increased glandular secretion. This secretion is soft and dark brown in colour resembling a bloody discharge. The worms then erode layer after layer of the epidermis. The non cornified osseous epithelium appears to be more susceptible to the worm attack. The bacterial flora excessively multiply in the increased cerumine secretion from where they invade the worm caused wounds to produce the necrotizing or suppurative inflammation. The bacterial invasion extends deep as the worms continue to erode the surface. This leads to haemorrhages hence the blood tinged discharge observed in some cases. In the right ear of animal B2 the inflammatory changes were found to extend deep into the hypodermis suggesting that with time the lesion could extend across the

entire canal wall to affect the cartilaginous or the bony walls. The worms were not seen at any level of the canal wall, an indication that they do not burrow into the tissue but erodes it from the surface. It is not known whether the erosion is physical or enzymatic.

The histological changes observed included epidermal necrosis, erosion, proliferation or hyperkeratosis. There was dermal necrosis, fibrosis and inflammatory cell infiltration. Inflammatory cells commonly observed were eosinophils and neutrophils in the epidermis and dermal papillary layer, and plasma cells, macrophage and large lymphocytes mainly in the reticular layer. Most of these changes are not specific to the worm infection. They have been reported in bacteria otitis in different animals. (Fraser, 1961; Jubb et al., 1985; Scott, 1988). However, the presence of eosinophil seems to be associated with the worms. The cells are known to be part of the immune response to parasitic infections (Wakelin, 1987; Roitt, 1988) This may suggest that the disappearance of the worms in the chronic cases is a result of host immune response.

5.2 CONCLUSION

From this study it is concluded that Bovine Parasitic Otitis is as prevalent and severe in the hot dry (semi arid) areas as it is in the hot humid (coastal) areas but it is less so in cold humid areas. The otitis externa observed in the areas of study was a nematode otitis since more than 70%

of the cases had nematodes. Rh. bovis and Rh. blumi are the nematode species associated with the infection in East Africa but Rh. blumi occurs in humid rather than in dry areas. Delnav and understrength Chlorfenviphos dips are better reservoirs of Rh. blumi but can act as source of infection of both species. Amitraz a diamide (Triatix) and the recommended concentration of Chlorfenviphos are lethal to both species. Rh. bovis is a pathogenic species but its pathogenicity seems to be affected by low ambient temperatures. However, its occurrence in many cases without clinical otitis suggests that some predisposing factors are necessary for the disease to develop. Rh. blumi is a less pathogenic free-living species whose occurrence in ears with or without otitis may be a result of by chance contamination.

5.3 RECOMMENDATIONS

In view of the results observed from this study it is recommended that:

1. More studies be carried out to establish the distribution and prevalence of the disease in various parts of the country.
2. More studies be carried out to establish the role played by the various proposed predisposing factors such as ear moisture content, wounds and specific aural flora, in the development of the disease.
3. Field trials of the treatment and control of the disease using the lethal acaricides and antibiotic be

carried out.

4. Studies be carried out to determine the host immune response to the infection with a view to develop an immunological control measure.
5. Studies be made to determine the possible occurrence of Rh. blumi in animal body parts other than the ear in order to establish whether the species has a predilection to the ear or its occurrence there is a by chance contamination.

REFERENCES

- Anon, (1980-1990). Field Reports: Ministry of livestock Development, Veterinary Department, Kenya: Bovine Otitis.
- Bekure, S., de Leeuw, P.N., Grandin, B.E., and Neate, P.J.H.(1991). An analysis of the livestock production system of Maasai pastoralists in eastern Kajiado District, Kenya: Maasai herding. ILCA system study. Addis Ababa, Ethiopia. pp. 7-9.
- Bovien, P.(1937). Some types of association between nematodes and insects. PhD Thesis, Kobenhavn, pp. 61-67.
- Brander, G.C and Pugh, D.M. (1977). Veterinary applied Pharmacology and Therapeutics. 3rd Ed. Bailliere Tindal, London. pp. 412-422.
- Brockelmann, C.R. and Jackson, G.J. (1974). Rhabditis maupasi: Occurrence in food snail and cultivation. Experimental parasitology 36, 114-122.
- Chudleigh, P.D.(1974). A description of small holder ruminant production systems in high potential areas of Kenya. Ministry of Agriculture, Technical Report No.4 pp. 49-55.
- Cowan, S.T. (1985), Cowan and Steel's manual of medical bacteria 2nd Ed. Revised. Cambridge Iniversity Press
- Daniel, W.W.(1987). Biostatistic: A foundation for analysis in the Health Sciences. 4rd Ed. John Wiley and Sons.

- Dunn, A.M. (1978). *Veterinary Helminthology*. 2nd Ed. William Heinemann Medical Books Ltd pp. 56.
- Fraser, G. (1961). Histopathology of external auditory meatus of the dog. *Journal of Comparative Pathology* 71, 253-258.
- Goodey, J.B. (1963). *Soil and fresh water nematodes*. 2nd Ed. John & Wileys & Sons Inc. pp.208.
- Harvey, C.E. (1980). Ear canal disease in the dog: medical and surgical management. *Journal of American Veterinary and Medical Association* 177. 136-139.
- Hayes, H.M., William Prickle Jr.L. and Wilson, G.P. (1987). Effects of the ear type and weather on the hospital prevalence of canine otitis externa. *Research in Veterinary Science* (3) pp. 294-298.
- Jensen, R., Pierson, R.E, Weibel, J.L, Tucker, J.O., and Swift, B.L (1982). Middle ear infection in feedlot lambs. *Journal of American Veterinary and Medical Association*, 181 (8) 805-807.
- Jensen, R., Maki, L.R., Lauerman, L.H., Raths, W.R., Swift, B.L., Flack, D.E., Hoff, R.L., Hamcock, H.A., Tucker, J.O., Horton, D.P. and Weibel, J.L. (1983). Cause and pathogenesis of middle ear infection in young feedlot cattle. *Journal of American Veterinary and Medical Association*. 182.(9) 967-972.
- Jibbo, J.M.C. (1966) Bovine parasitic Otitis. *Bulletin of Epizootic Diseases of Africa* 14, 59-63.

- Jubb, K.V.F., Kennedy; P.C., and Palmer, N. (1985).
Pathology of domestic animals 3rd Ed. vol.1 Academic
Press Inc.
- Kassuku, A.A, Mawere M.S. and Msalilwa L.P. (1989).
Laboratory cultivation of Rhabditis bovis on different
culture media. Tanzania Veterinary Bulletin 9 (2), 34-
37.
- Kreis, H.A. (1964) "Ein neuer nematode aus clem auberen
Gehorgang von Zeburindern in Ostafrika, Rhabditis bovis
n. sp." Schweizer Archiv fur Tlerheilkunde 106, 373-
378.
- Levine, N.D., Miller, L.J., Morrill, C.C. and Mansfield, M.E.
(1950). Nematode of dermatitis in cattle associated
with Rhabditis Journal American Veterinary and Medical
Association 116, 294-296.
- Levine, N.D., Birch, C.L., Dolowy, W.C. and Mckinney, R.E
(1963) Rhabditis axei, a Pseudoparasitic nematode of
the dog. Journal of American Veterinary Association 142
(12 1404-1405.
- Little C.J.L., Lome, J.G., Gibbs, C. and Pearson, G.R
(1991). Inflammatory middle ear disease of dog: the
clinical and pathological features of cholesteatoma, a
complication of otitis media. Veterinary Record 128,
319-322.

- Little C.J.L., Lane, J.G., and Pearson, G.R. (1991).
Inflammatory middle ear disease of the dog: the
pathology of otitis media. *Veterinary Record* 128, 293-
296.
- Lweno, M., Semuguruka, W.D. and Mhoma, J.R. (1983).
Nematode Otitis: Etiological and Pathological aspects.
Tanzania Veterinary Bulletin. 5 (1); 8-15.
- Martin Junior, W. (1985). Rhabditis (Rhabditis) freitasi sp.
n.e Rhabditis (Rhabditis) costai sp.n (Nematoda-
Rhabditidae) isolados de otite bovina. *Mem. Inst.*
Oswaldo Cruz, Rio de Janeiro 80 (1): 11-16.
- Morgan, K.L.(1992). Parasitic Otitis in sheep associated
with psoroptes infestation: a clinical and
epidemiological study. *Veterinary Record*. 130: 530-532.
- Msolla, P., Falmer-Hansen, J., Musemakweli, J., and Monrad,
J. (1983). Epidemiology and Treatment of Bovine
Parasitic Otitis. *Proceedings of the 1st Tanzania
Veterinary Association Scientific Conference. TVA. 1,*
78-93.
- Msolla, P. (1984). The epidemiology of Bovine Parasitic
Otitis. *Proceedings of the 2nd Tanzania Veterinary
Association Scientific Conference TVA. 2, 99-109.*
- Msolla, P., Falmer-Hansen, J. Musemakweli, J. and Monrad, J.
(1985). Treatment of Bovine Parasitic Otitis using
Ivermectin. *Tropical Animal Health and Production*. 17,
166-168.

- Round M.C. (1962). Helminth Parasites of domesticated animals in Kenya. *Journal of Helminthology*. 36(4), 375-449.
- Scott, D.W. (1988). *Large animal dermatology*. W.B. Saunders Company. pp 265-266.
- Skryabin, K.I.(1984) *Key to Parasitic nematodes*. Vol.4. Amerid Publishing Co. Prt Ltd, New Delhi pp. 99-131.
- Soulsby E. J. V.(1982). *Helminths Arthropods and protozoans of domesticated animals* 7th Ed. Baillier Tindall.
- Sudhaus.W. (1974). Zur Systematik, Verbreitung, Okologie und Biologie neuer und Wenig bekannter Rhabditiden (Nematoda) *Zool.Jb. Syst. Bd. 101*. 417-465.
- Sudhaus, W.(1976). In *Vergleichen Untersuchungen zur phylogenic systematik, Okologie, biologie and ethologie der Rhabditides (Nematoda)*. E. Schweizerbar Sche Verlagsbuch handlung. Nagele U. Obermiller Stuttgart 1976.
- Sudhaus, W. (1980). Vergleichen untersuchugen zur oberen grenztemperatus saprobionter Nematoden der gattieng Rhabditis. *Nematologica* 26, 75-82.
- Tod. M.t; Jacobs, D; and Dunn, A.M. (1971). Mechanism for the dispersal of parasitic nematode larvae. *Journal of Helminthology* XLV, 133-137.
- Trautmann, A. and Fiebiger, J. (1952). *Fundamental of the histology of domestic animals*. Translated and Revised 9th ed. Comstock Publishing Associates N.Y.
- Wakelin, D. (1987). *Immunity to parasite: How animals control Parasite infection*. Edward Arnold. USA

APPENDIX 1. CLINICAL RESPONSE TO THE INFECTION IN A PERIOD OF 90 DAYS

GROUP	1								2								3						
	B1		B2		B3		B4		B5		B6		B7		B8		B9		B10		B11		
EAR	R	L	R	L	R	L	R	L	R	L	R	L	R	L	R	L	R	L	R	L	R	L	
D A Y O F E X A M I N A T I O N A F T E R I N F E C T I O N	3	-	-	-	-	-	-	-	-	-	-	-	-	-	-	-	-	-	-	-	-	-	
	5	-	-	+-	+-	-	-	-	-	-	-	-	-	-	-	-	-	-	-	-	-	-	-
	7	-	-	+-	+-	-	+-	-	-	-	-	-	-	-	-	-	-	-	-	-	-	-	-
	10	+-	-	+-	+-	-	+	-	-	-	+-	-	-	+-	+-	-	-	-	-	-	-	-	-
	14	+-		+	+	+-	+	-	-	-	-	-	+-	+-	+-	+-	-	-	-	-	-	-	-
	17	+	+	++	++	+-	++	-	-	-	-	-	+-	+-	+-	+-	+-	-	-	-	-	-	-
	20	++	+	++	++	+-	++	-	-	-	-	-	-	+-	+-	+-	+-	-	-	-	-	-	-
	22	++	+	++	++	+	x	-	-	-	-	-	+-	+-	+-	+-	+-	-	-	-	-	-	-
	25	++	+	x	++	+	x	-	-	-	-	-	-	+-	+-	+-	+-	+-	+-	-	-	-	-
	28	x	++	x	++	+	x	-	-	-	-	-	+-	+-	+-	+-	+-	-	-	-	-	-	-
	31	x	++	x	++	+	x	-	-	-	-	-	+-	+-	+-	+-	+-	-	-	-	-	-	-
	34	x	++	x	x	+	x	-	-	-	-	-	-	+-	+-	+-	+-	-	-	-	-	-	-
	37	x	+	x	x	+	x	-	-	-	-	-	-	+-	+-	+-	+-	-	-	-	-	-	-
40	x	+	x	x	+-	x	-	-	-	-	-	-	+-	+-	+-	+-	-	-	-	-	-	-	
44	x	+	x	x	-	x	-	-	-	-	-	-	+-	+-	+-	+-	-	-	-	-	-	-	
47	x	+	x	x	-	x	-	-	-	-	-	-	+-	+-	+-	+-	-	-	-	-	-	-	
50	x	+	x	x	-	x	-	-	DEAD	-	-	-	+-	+-	+-	+-	-	-	-	-	-	-	
52	X	+	x	x	-	x	-	x	''	-	-	-	+-	+-	+-	+-	-	-	-	-	-	-	

GROUP		1								2								3							
ANIMAL		B1		B2		B3		B4		B5		B6		B7		B8		B9		B10		B11			
EAR		R	L	R	L	R	L	R	L	R	L	R	L	R	L	R	L	R	L	R	L	R	L		
D A Y A F T E R I M P E C T I O N	52	x	+	x	x	-	x	-	-	DEAD	-	-	-	+-	+-	+-	-	-	-	-	-	-	-		
	55	x	+	++	x	-	x	-	-		-	-	-	+-	+-	+-	-	-	-	-	-	-	-		
	58	x	+	++	x	-	x	-	-		-	-	-	+-	+-	+-	-	-	-	-	-	-	-		
	61	x	+	++	x	-	x	-	-		-	-	-	+-	+-	+-	-	-	-	-	-	-	-		
	64	++	+	x	x	-	x	-	-		-	-	-	-	-	+-	-	-	-	-	-	-	-		
	68	++	+	x	x	-	x	-	-		-	-	-	-	-	+-	-	-	-	-	-	-	-		
	71	x	+	x	x	-	x	-	-		-	-	-	-	-	+-	-	-	-	-	-	-	-		
	75	x	+	x	x	-	x	-	-		-	-	-	-	-	+-	-	-	-	-	-	-	-		
	78	x	+	x	x	-	x	-	-		-	-	-	-	-	+	-	-	-	-	-	-	-		
	81	x	+	x	++	-	x	-	-		-	-	-	-	-	+	-	-	-	-	-	-	-		
	84	x	+	x	++	-	++	-	-		-	-	-	-	-	+-	-	-	-	-	-	-	-		
	87	++	+	x	++	-	++	-	-		-	-	-	-	-	+-	-	-	-	-	-	-	-		
			++	+	x	++	-	++	-	-		-	-	-	-	-	+-	-	-	-	-	-	-	-	

KEY

R Right ear
L Left ear
- No clinical response
+- Mild clinical response
+ Moderate clinical response
++ Severe clinical response
x Very severe clinical response

Group 1 Animals infected with Rh. bovis
2 Animals infected with Rh. blumi
3 Control animals

APPENDIX 2. WORM ISOLATION FROM THE INFECTED EARS DURING THE 90 DAYS

GROUP		1				2				3				
ANIMAL		B1	B2	B3	B4	B5	B6	B7	B8	B9	B10	B11		
EAR		R	L	R	L	R	L	R	L	R	L	R	L	
D A Y O F E X A M I N A T I O N A F T E R I N F E C T I O N	7	A	A	P	P	A	A	P	A	A	P	A	A	
	10	P	A	P	P	A	A	P	P	P	P	P	P	
	17	P	P	P	P	P	A	A	A	P	P	P	P	
	20	P	P	P	P	P	A	A	A	P	P	P	P	
	22	P	P	P	P	P	A	A	A	P	P	P	P	
	28	P	P	P	P	P	A	A	A	P	P	P	P	
	34	P	P	P	P	P	A	A	A	A	P	P	P	
	40	P	P	P	P	P	A	A	A	A	P	P	P	
	44	P	P	P	P	P	A	A	A	A	P	P	P	
	50	P	P	P	P	P	A	A	DEAD	A	A	A	P	P
	55	P	P	P	P	P	A	A		A	A	A	P	P
	61	P	P	P	P	P	A	A		A	A	A	A	P
	68	P	P	P	P	P	A	A		A	A	A	A	A
	75	P	P	P	P	P	A	A		A	A	A	A	P
81	P	P	P	P	P	A	A		A	A	A	A	P	
87	P	P	P	P	P	A	A		A	A	A	A	P	
90	P	P	P	P	P	A	A		A	A	A	A	P	

KEY

- R Right ear
- L Light ear
- A Worms Absent
- P Worms Present
- Group 1. Animals infected with Rh. bovis
- 2. Animals infected with Rh. blumi
- 3. Control animals

APPENDIX 3. BACTERIA ISOLATED FROM THE EARS BEFORE THE EXPERIMENT

Animal	Bacteria in the right ear	Bacteria in the left ear
B1	<i>Staphylococcus aureus</i> <i>Micrococcus</i> spp Beta-haemolytic <i>Streptococcus</i> spp	<i>Corynebacterium pyogene</i> Alpha-haemolytic <i>Streptococcus</i> spp Beta-haemolytic <i>Bacillus</i> spp
B2	Alpha-haemolytic <i>Streptococcus</i> spp Beta-haemolytic <i>Bacillus</i> spp	<i>Pseudomonas</i> spp Alpha-haemolytic <i>Streptococcus</i> <i>Staphylococcus aureus</i>
B3	<i>E. Coli</i> Beta-haemolytic <i>Streptococcus</i> spp <i>Staphylococcus aureus</i>	<i>E. coli</i> Alpha-haemolytic <i>Bacillus</i> spp
B4	<i>Enterobactor</i> non haemololytic <i>Streptococcus</i> spp Beta-haemolytic <i>Bacillus</i> spp	<i>E. Coli</i> Beta-haemolytic <i>Bacillus</i> spp
B5	<i>Pseudomona</i> spp <i>Staphylococcus aureus</i>	Alpha-haemolytic <i>Streptococcus</i> spp <i>Staphylococcus aureus</i>
B6	<i>Pseudomonas mallei</i> <i>Staphylococcus aureus</i>	Alpha-haemolytic <i>Streptococcus</i> spp Beta-haemolytic <i>Bacillus</i> spp
B7	<i>Pseudomonas</i> spp <i>Staphylococcus aureus</i>	alpha-haemolytic <i>Streptococcus</i> spp <i>Staphylococcus aureus</i>
B8	<i>Pseudomonas mallei</i>	<i>Proteus vulgaris</i> alpha-haemolytic <i>Streptococcus</i> spp
B9	Alpha-haemolytic <i>Streptococcus</i> spp Beta-haemolytic <i>Bacillus</i> spp	Beta-haemolytic <i>Bacillus</i> spp <i>Staphylococcus epidermidis</i>
B10	Alpha-haemolytic <i>Streptococcus</i> spp Beta-haemolytic <i>Bacillus</i> spp <i>Staphylococcus aureus</i>	Alphahaemolytic <i>Streptococcus</i> spp <i>Staphylococcus aureus</i>
B11	<i>E. Coli</i> Alpha-haemolytic <i>Streptococcus</i>	<i>E. Coli</i> <i>Staphylococcus aureus</i>

APPENDIX 4. BACTERIA ISOLATED FROM THE EARS AT THE END OF THE EXPERIMENT

Animal	Bacteria in the right ear	Bacteria in the left ear
B1	Beta-haemolytic <i>Streptococcus</i> spp Beta-haemolytic <i>Bacillus</i> spp	Beta-haemolytic <i>Streptococcus</i> spp Beta-haemolytic <i>Bacillus</i> spp <i>Staphylococcus aureus</i>
B2	B-haemolytic <i>Bacillus</i> spp	Beta-haemolytic <i>Bacillus</i> spp <i>Staphylococcus albus</i>
B3	Beta-haemolytic <i>Streptococcus</i> spp <i>Staphylococcus aureus</i>	<i>E. Coli</i> Alpha-haemolytic <i>Streptococcus</i> spp
B4	Non haemolytic <i>Streptococcus</i> spp Beta-haemolytic <i>Bacillus</i> spp <i>Staphylococcus albus</i>	<i>E. Coli</i> Beta-haemolytic <i>Bacillus</i> spp
B5	<i>Pseudomonas</i> spp <i>Staphylococcus aureus</i>	Alpha-haemolytic <i>Streptococcus</i> spp Beta-haemolytic <i>Bacillus</i> spp
B6	Beta-haemolytic <i>Bacillus</i> spp <i>Staphylococcus aureus</i>	Alpha-haemolytic <i>Streptococcus</i> spp Beta-haemolytic <i>Bacillus</i> spp
B7	Beta-haemolytic <i>Bacillus</i> spp <i>Staphylococcus aureus</i>	Beta-haemolytic <i>Bacillus</i> spp <i>Staphylococcus epidermidis</i>
B8	<i>Pseudomonas</i> spp	Beta-haemolytic <i>Bacillus</i> spp
B9	Beta-haemolytic <i>Bacillus</i> spp Alpha-haemolytic <i>Streptococcus</i> spp	Alpha-haemolytic <i>Streptococcus</i> spp Beta-haemolytic <i>Bacillus</i> spp
B10	<i>Pseudomonas</i> spp Alpha-haemolytic <i>Streptococcus</i> spp <i>Staphylococcus aureus</i>	<i>Pseudomonas</i> spp Alpha haemolytic <i>Streptococcus</i> spp <i>Staphylococcus aureus</i>
B11	Beta-haemolytic <i>Bacillus</i> spp alpha-haemolytic <i>Streptococcus</i> spp	Beta-haemolytic <i>Streptococcus</i> spp <i>Staphylococcus aureus</i>

9050