

THE ROLE OF DIAGNOSTIC RADIOLOGY
IN THE MANAGEMENT OF
PORTAL HYPERTENSION

IN

KENYATTA NATIONAL HOSPITAL - NAIROBI

A dissertation submitted in part -
fulfilment for the Degree of Master of
Medicine (Diagnostic Radiology),
University of Nairobi.

July 1986

DR. ARNOLD RODRIGUES M.D. (MILAN)

University of NAIROBI Library



0324959 6


UNIVERSITY OF NAIROBI
LIBRARY

DECLARATION

Candidate:

This dissertation is my original work and has not been presented for a degree in any other University.

Signed: _____




Dr. Arnold Rodrigues M.D. (Milan)

Supervisor:

This dissertation has been submitted for examination with my approval as University Supervisor.

Signed: _____



Dr. J.M.K. Kitonyi, M.B.Ch.B., M.Sc., M.Med.

CONTENTS

	<u>PAGE</u>
SUMMARY	1
INTRODUCTION	3
MATERIALS & METHODS	24
RESULTS	39
DISCUSSION	49
CONCLUSION	89
RECOMMENDATIONS	91
REFERENCES	93
ACKNOWLEDGEMENTS	106

SUMMARY

A retrospective and prospective study of 50 patients with portal hypertension was carried out at Kenyatta National Hospital (K.N.H.), Nairobi, from November 1980 to November 1985. Patients were classified into five aetiological categories on the basis of clinical, histological and radiological data. Their age, sex, ethnic group, aetiological and geographical distribution were analysed.

Portal Hypertension affected a generally younger age group (mean 24.3 years). The overall sex ratios approximated the normal male:female 1.4:1 ratios of KNH and the Kamba were found to predominate most aetiological categories. Over 60% of the patients in the study had their residence in the Eastern Province. The role and relative merits of ultrasound and other radiological investigations in influencing patient management is discussed.

While splenoportovenography proved to be the single most influential radiological investigation, particularly in deciding between the surgical or medical management of the patients, real time ultrasound showed potential as a rapid, simple non-invasive screening technique for these patients. The lack

of splenic and superior mesenteric vein swelling, which is always present in the normal subject during the Valsava manoeuvre appeared to be the most sensitive criteria for ultrasonic diagnosis of portal hypertension.

Both endoscopic injection sclerotherapy and shunt surgery in carefully selected patients proved to be equally successful in improving the quality of the patients life keeping it relatively free from life threatening haemorrhage in the one year follow up period. Proposals for a more rapid, accurate diagnostic and management protocol are made.

INTRODUCTION

Liver diseases in tropical countries take up a significant amount of the physician's time (54). They affect a generally younger age group and follow a different aetiological pattern from that encountered in Europe and North America.

Portal hypertension is common in Africa. Often it is a manifestation of a disease other than cirrhosis which accounts for almost 85% of patients with portal hypertension in industrialised countries (26). The hepatosplenic form of schistosomiasis is probably the commonest cause in Africa. Childhood infection with *S. Mansoni* reached a 65% in studies conducted in a population of schoolchildren in the Machakos district in the Eastern Province of Kenya (1). Only a small percentage of patients infected with schistosomiasis eventually develop portal hypertension. However, the number of young patients with a history of haematemesis with hepatosplenomegaly being referred from Provincial and District hospitals to the Medical Outpatient Clinic (Parasitology and Liver Clinics) at Kenyatta National Hospital, Nairobi (KNH) (the general referral centre for the whole country),

for further investigation and management, is on the increase. This increase, coupled with the need to offer these patients the maximum benefit of the specialised diagnostic facilities and management techniques, together with reducing the period of their hospitalisation to the minimum, prompted this study.

The objectives of this study were therefore to evaluate critically the role of Diagnostic Radiology compared with clinical and laboratory diagnostic methods currently in use, and their subsequent influence on the management of patients at K.N.H. This study is aimed at:

- Determining the age, sex and ethnic patterns of portal hypertension seen at this hospital.
- Identifying the possible aetiology and geographic distribution of portal hypertension using Diagnostic Radiology as an adjunct to already established clinical and laboratory criteria.
- Evaluating the subsequent management of these patients once the diagnosis and possible aetiology had been established, and the role

that radiology plays in this.

- Discussing the relative merits and order in which these investigations could be performed.
- Proposing a possible protocol that could be used for a more rapid investigation and treatment of these patients.

DEFINITION

By definition portal hypertension implies a persistent increase above the normal in portal vein pressure. Direct portal pressure measured at surgery over 300 mm of saline, intra splenic pressures more than 220 mm of saline or wedged hepatic vein pressures more than 180 mm of saline above inferior vena cava pressure are all reliable indices of portal hypertension (45b).

NORMAL ANATOMY

The splenic vein is formed by the convergence of the short splenic radicles. The course of this vein varies; sometimes it is straight, sometimes tortuous. It regularly meets the termination of the superior mesenteric vein and forms a caudally convex curve. The length of the splenic vein ranges from 5 - 15 centimetres and its diameter ranges from 0.5 - 1.8 centimetres.

The portal vein collects blood from the splanchnic area and transports it to the liver. The portal vein begins at the level of the second lumbar vertebra, posterior to the head of the pancreas, at the junction of the splenic and superior mesenteric veins. The portal vein is about 6 - 8 centimetres long and 1.2 centimetres in diameter and contains no valves. At the liver hilum it separates into a right branch that supplies the right lobe, and a left branch that supplies the left, caudate and quadrate lobes. The portal venous blood flows through the hepatic sinusoids from the splanchnic region and returns to the systemic venous circulation by way of the hepatic veins and inferior vena cava.

The ligamentum teres meets the left branch of the portal vein and contains within it one or more potential lumina after the neonatal period (umbilical and paraumbilical veins) that are remnants of the foetal circulation running from the umbilicus to the left portal vein.

The most frequent variations in portal anatomy are in the inferior mesenteric vein which may join

the superior mesenteric vein instead of the splenic vein, and in the left gastric (coronary) vein which may join the splenic instead of the portal vein (12).

Portal venous blood passes through one capillary system in the splanchnic viscera into another capillary system, the hepatic sinusoids. Portal venous blood differs from most other venous blood:

- a) in being under slightly higher pressure in order to overcome the resistance of the hepatic sinusoids.
- b) in being less depleted in oxygen because of relatively high blood flow through the splanchnic area.
- c) and in containing many nutrients and bacterial waste products from the intestine en route to the liver.

About three quarters of hepatic blood flow and about half of the total oxygen consumption is supplied by the portal vein, while the hepatic artery contributes the remainder. Normal fasting hepatic flow approximates 1500 ml per minute (46). The high pressure arterial and low pressure portal venous streams unite at the level of the hepatic

sinusoid. It is for this reason that one cannot do a side to side portocaval shunt, as the liver quickly becomes necrotic due to blood flowing retrograde (55).

AETIOLOGY

Most types of portal hypertension result from increased resistance to blood flow in the portal vein, liver or hepatic vein. The fact that hepatic blood flow is reduced in portal hypertension indicates this abnormal resistance.

It is a common consequence of chronic liver disease: most frequently due to alcoholic liver cirrhosis (50) in industrialised countries whereas in developing countries the hepatosplenic form of schistosomiasis is a more frequent cause (59).

Obstruction to portal flow may result from several intra and extra hepatic processes, including thrombosis of the extra hepatic portal vein from neonatal umbilical sepsis, inflammatory obliteration of hepatic architecture as in the case of cirrhosis or hepatosplenic schistosomiasis. The major hepatic veins leading from the liver to the inferior vena cava may be blocked (Budd-Chiari Syndrome) often in conjunction with obstruction to the

inferior vena cava (50).

In all but two varieties of portal hypertension, it appears that the primary cause is an anatomical lesion which increases the resistance to blood flow through the portal bed. The two forms where the increase in vascular resistance may not be the primary cause are:

- 1) Portal hypertension due to arterio-venous fistulae in the splanchnic bed, in which an increased splanchnic arterial inflow is probably the primary problem, with a secondary increase in portal vascular resistance.
- 2) Idiopathic portal hypertension in which only minor anatomical changes are evident and are possibly secondary to an increase in the splenic blood flow.

Increased splanchnic flow must also be considered. In most of the conditions mentioned, including chronic malaria and schistosomiasis, the splenic flow is very much increased. Patients with portal hypertension may show thickening, sclerosis and partial thrombosis of the main portal vein radicles. In a similar manner as the arterial system, the portal vein may undergo degenerative changes in response to increased flow and pressure. Such

increased flow, is however, not thought to be the major factor in maintaining portal hypertension (50).

PATHOPHYSIOLOGY

Portal hypertension results from either an anatomical or a functional obstruction of blood flow into this unique conduit system that delivers blood from one set of capillaries, in the intestinal wall and spleen, to another in the hepatic sinusoids. The obstruction may occur at any point from the origin of the portal system in the splanchnic bed, to its exit into the systemic circulation via the inferior vena cava. This is accompanied by dilatation and stasis of the venous blood proximal to the obstruction. There is thus a decrease in the amount of blood flowing through the normal vascular channels with a reciprocal increase in collateral blood flow around the liver. The final level of pressure in the portal bed depends on:

- the degree of vascular obstruction,
- the resistance in the collateral vessels, and
- the rate of inflow of blood into the splanchnic bed.

Since the stimulus for collateral blood flow is the increase in portal tension, the latter can

never entirely be relieved by the collateral flow. Pathological responses to portal hypertension are of importance in the development of major complications of liver disease and include bleeding oesophageal varices from the establishment of collateral circulation, ascites, hepatic encephalopathy and the development of splenomegaly and hypersplenism.

1. The collateral circulation develops by enlargement of pre-existing bridging channels, by re-opening of embryonic channels such as the umbilical vein, and most importantly, by reversal of the direction of flow within the tributary veins so that blood is carried away from the portal system and eventually into the systemic veins. Blood can flow in either direction within the portal system because of the absence of valves within the veins. This, together with the increased vascular resistance, gives rise to varices. Although varices often extend throughout the length of the oesophagus, bleeding usually occurs in the lowermost five centimetres and in the region of the fundus. This is probably due to the fact that in this segment the veins penetrate the muscularis mucosa to become subepithelial and therefore more vulnerable to the effects of high

intraluminal pressure. The channels connecting the portal and caval venous systems can be divided into four main groups (8).

- (a) The left gastric (coronary) vein normally drains into the portal vein although sometimes it drains into the splenic vein. At the cardia of the stomach, it communicates with the gastric and oesophageal venous plexus which leads into the azygos system and then into the superior vena cava.
- (b) The inferior mesenteric vein communicates with the splenic vein superiorly and with the middle and inferior haemorrhoidal veins inferiorly.
- (c) The umbilical and paraumbilical veins are potentially patent embryonic channels lying in the falciform ligament and connect the left branch of the portal vein with the veins of the exterior abdominal wall. Retrograde flow through these vessels results in dilatation of the superficial veins of the periumbilical abdominal wall and produces the caput medusae of the Cruveillier-Baumgarten Syndrome. Multiple small veins bridge the two systems wherever an abdominal organ is in contact with the retroperitoneal

tissues or is fixed to the abdominal wall. These include the veins from the bare area of the liver to the diaphragm (veins of Sappey) and those developing from previous abdominal surgery.

Anastomotic vessels between the spleen and left renal vein open up creating natural spleno-renal shunts.

The specific collateral channels that develop in any given patient are very variable and depend, to some extent, on the site of the portal obstruction. If the block is extrahepatic, collateral vessels tend to bridge the obstructed segment and join the portal vein distal to the obstruction, but there are no firm rules.

When the obstruction is in the main portal vein at the porta hepatis or within the liver, most of the flow is diverted through extra hepatic channels into the superior or inferior vena cava or both.

Occasionally the collateral system is so efficient that despite the presence of obstruction, the portal vein is adequately decompressed and pressures may be within normal limits. The radiological demonstration of collateral circulation is then the evidence of obstruction to portal flow.

2. In cirrhosis, the ascites is mainly due to the hypoproteinaemia although some forms as a consequence of sinusoidal hypertension and hepatic lymph formation in excess of what can be carried away by hepatic lymphatics (45b). Portal hypertension alone rarely causes ascites, as evidenced by the low incidence of ascites in extra-hepatic portal vein thrombosis.

3. The collateral circulation which develops as a consequence of portal hypertension leads to shunting of nitrogenous intestinal products and other toxic substances around the liver into the systemic circulation and produces the neuro-psychiatric changes designated as hepatic encephalopathy.

4. Splenomegaly is a frequent accompaniment of portal hypertension, but studies indicate that the size of the spleen does not correlate with the level of portal hypertension (53, 55, 64). The width of the splenic and portal veins is often influenced by conditions such as portal stasis and increased intraabdominal pressure, as in the patient with ascites.

The hypervolemia seen in portal hypertension is logically explained by the dilatation of the entire portal venous bed and adjacent collateral veins.

CLASSIFICATION OF PORTAL HYPERTENSION

Portal hypertension clinically may be classified into two main groups: presinusoidal and intrahepatic (50). This distinction is a practical one. The presinusoidal forms, which include obstruction to the sinusoids by Kupffer and other cellular proliferation, are associated with relatively normal hepatocellular function. Consequently, if patients with this type suffer a haemorrhage from oesophageal varices, liver failure is rarely a consequence. In contrast, the intrahepatic types are associated with hepatocellular disease. Patients with this type suffering haemorrhage frequently go into liver failure.

1. The presinusoidal forms are divided into:

- a) Extrahepatic presinusoidal which is caused by obstruction to the main portal vein
- b) Intrahepatic presinusoidal forms are caused by lesions in the portal zones and within the sinusoids of the liver. In Africa schistosomiasis is by far the most important cause in this group.

2. Intrahepatic sinusoidal and post sinusoidal.

Cirrhosis of all types is the most important cause.

The obstruction to portal venous flow is at all

levels within the liver and not simply post sinusoidal as previously thought.(50)

From the angiographic point of view, there are great differences between the different syndromes of portal hypertension.(56, 60)

The patency of the splenoportal axis is shown by splenoportovenography. However, persistent opacification of any tributaries other than the splenic vein is abnormal and indicates increased resistance within the portal system.

1. Extrahepatic obstruction

a) Splenic vein thrombosis causes partial or sectorial portal hypertension. Splenoportovenography shows a block in the splenic vein or in the splenomesenteric trunk due to thrombosis. The splenic pulp pressure is elevated.

b) Portal vein thrombosis: Obstruction in the main portal vein causes generalised portal hypertension due to an extrahepatic block. It may lead to cavernous transformation of the portal vein. The splenic pulp pressure is raised.

Both these cases tolerate surgery better because of the integrity of the liver.

2. Intrahepatic obstruction is obstruction within the liver parenchyma and causes generalised portal hypertension. Splenoportovenography shows a patent splenoportal axis.

a) In hepatosplenic schistosomiasis the portal space is reduced to a block of fibrous tissue, due to the organisation of the *S. Mansoni* granulomata. The portal pressure is raised.

b) Alcoholic liver cirrhosis microscopically presents with centrilobular fibrosis with partial or complete obliteration of the centrilobular veins giving rise to portal hypertension.

Splenoportovenography demonstrates a patent portal vein but a marked diminution of the total hepatic vascular bed and an irregularity of the main branches. In many instances the liver is mottled. This is most commonly explained by an extrahepatic collateral circulation so that the liver receives an abnormally small quantity of contrast.

c) Idiopathic Portal Hypertension includes all causes of portal hypertension of unknown origin. There is no histological evidence of schistosomiasis, cirrhosis or any other specific hepatosplenopathy.

There may be narrowing of secondary and subsequent branches of the portal vein indicating that this is the site of increased resistance. The liver parenchyma is little affected.

3. Post Hepatic Obstruction. Relevant causes include hepatic vein or inferior vena cava obstruction but more commonly in Africa, this is secondary to hepatocellular carcinoma. None of these, however, is a common cause of portal hypertension.

In summary:

Clinical Classification

1. Presinusoidal
 - Extrahepatic
 - Intrahepatic
2. Intrahepatic sinusoidal and post sinusoidal

Angiographic Classification:

1. Extrahepatic Obstruction
 - Splenic Vein Thrombosis
 - Portal Vein Thrombosis
2. Intrahepatic Obstruction
3. Post Hepatic Obstruction

The main complication of portal hypertension is oesophageal variceal haemorrhage which may be treated medically or surgically. Two approaches exist to the treatment of oesophageal varices - one aimed at reducing portal pressure, and the other at occluding varices without affecting portal pressure. Portal pressure may be reduced pharmacologically or surgically. Vasopression infusion has the dual effect of constricting splanchnic arterioles thereby decreasing portal venous flow and also that of reducing portal resistance (23).

Propranolol has been shown to lower portal pressure, reduce liver blood flow and cardiac index (23). The mechanism underlying the reduction on portal pressure is not entirely clear, but there is a direct relation between the reduction in hepatic blood flow produced by propranolol and the fall in portal pressure (62).

The most effective of the several surgical methods for lowering portal pressure, is the creation of a shunt between the portal and systemic circulation. Portal pressure is appreciably

lowered, but at the expense of a reduction in hepatic blood flow because of blood that bypasses the liver. Surgical shunting is associated with the development of hepatic encephalopathy in about one third of patients (14, 45, 57). There are many variations of the shunt procedure, including mesocaval and distal splenorenal shunts, but generally they have not achieved this purpose. (15) The outcome of shunt surgery depends primarily on the age of the patient and on hepatocellular function, which tends to deteriorate after shunting (44b).

Numerous techniques exist to occlude varices. Temporary control of bleeding oesophageal varices can be achieved by direct compression with the Sengstaken - Blackmore tube. A more permanent occlusion can be obtained by a variety of techniques including sclerotherapy, embolisation and transection of the varices.

Sclerotherapy can be effected by several approaches but direct endoscopic injection sclerotherapy (EIS) is the one at present used at KNH. (27, 35) The sclerosant, ethylolamine oleate, is injected directly into each varix and is attempted only after the bleeding has stopped and once the patient's condition

has stabilised. Repeated injections are made to prevent the recurrence of varices.

Most reports of endoscopic sclerotherapy have indicated a reduction in episodes of re-bleeding and perhaps an improved rate of survival at one year (35). Complications of this technique include oesophageal ulceration at the site of injection, which normally is without complication, but late formation of a stricture can occur. (21).

Due to individual variations in patients (i.e. aetiology, age, duration, degree of hypersplenism, availability, size and proximity of suitable portal and systemic veins, as well as the tendency and frequency of severe bleeds) management must be individualised. At Kenyatta National Hospital (KNH) initially patients are managed medically, and, only after their condition has stabilised following an acute haemorrhagic episode and further investigations have been carried out, is surgical intervention considered. Radiology contributes significantly to this work up.

Ideally a Sengstaken-Blackmore tube for balloon tamponade is instituted to contain the haemorrhage. Fluid replacement is started until cross matched blood is available, more so, if blood loss is

obviously large. Gastric suction is initiated to reduce abdominal distension and the risk of aspiration.

If, in spite of these measures, active bleeding is evident, an intravenous infusion of vasopressin (20 - 40 I.U.) in 100 - 200 ml of 5% glucose is administered over a 20 - 40 minute period. This is repeated if bleeding re-occurs.

At present only patients who actually have their residence in Nairobi are being involved in a trial with EIS. This is because of the necessity of frequent endoscopy sessions and the prohibitive transport expenses for patients from outside Nairobi. A study combining beta blockers and EIS therapy is being presently considered (49) at KNH.

In those patients in whom surgery is contemplated three cardiothoracic and vascular surgeons and one paediatric surgeon are involved in the various procedures that are performed at KNH.

From a management standpoint patients are divided into the following groups:

- Young infants with ascites
- Children or adults with suitable vessels for shunt surgery
- Unshuntables

In infancy massive bleeding is rare, most patients present with a gradual increase of abdominal girth due to ascites when 2 - 6 months of age.

Management is directed towards arresting bleeding by EIS in an attempt to permit the child to grow sufficiently to withstand major surgery should the angiographic findings demonstrate its feasibility.(30).

Candidates are considered for shunt surgery if they are young, have a good liver function and have a relatively large arterial perfusion as is the case in extrahepatic obstruction, hepatosplenic schistosomiasis and idiopathic portal hypertension.(28).

Individuals, either because of the nature of their obstructive processes, state of their liver function or unsuitability of their vessels for shunting procedures are considered unshuntables. These patients are considered for EIS at KNH. In other centres (23, 52) trials have been carried out combining beta blockers and EIS. It is important to underline that these trials have been restricted to patients who are alcoholic cirrhotics with portal hypertension, a pattern different from this environment.

MATERIALS AND METHODS

The fifty patients with portal hypertension in this study were admitted to medical or surgical wards of the Kenyatta National Hospital between November 1980 and November 1985.

The clinical and diagnostic studies were:

- a) History and physical examination with reference to presenting complaints and their duration. Attention was paid to a positive history of haematemesis with palpable splenomegaly and to the geographical origin of the patient.
- b) A confirmation of upper gastro-intestinal bleeding was made by both gross and microscopic examination of stool. When possible, endoscopy was performed. The stools were also examined for schistosomal ova.
- c) Blood studies included a complete haemogram, liver function tests and a coagulation screen.
- d) Histological studies included a 'trucut' needle liver biopsy in all cases, not only to determine the state of the liver tissue, but also to evaluate the nature and extent of any distortion. Open biopsies were performed on patients who

underwent surgery.

A rectal snip was performed and examined for ova of schistosomiasis.

- e) The extent of splenomegaly was measured clinically below the subcostal margin and recorded as the number of centimetres in full inspiration.

It was also measured on plain abdominal X ray films and in some patients with ultrasound. Consideration was then given to the following investigations, best performed in this order:

- 1) An ultrasound scan of the spleen and liver, particular attention being given to the splenoportal axis with and without the Valsava manoeuvre. (7,10)
- 2) Upper gastrointestinal endoscopy to attempt to identify the site of bleeding and any other co-existing pathology. (49, 51b).
- 3) Upper gastrointestinal barium studies with particular attention for oesophageal or gastric varices. If no varices were demonstrated on a swallow, a single contrast barium meal was performed.

- 4) In patients with an adequate coagulation function, a direct splenic puncture splenoportovenography was considered. (6, 20, 31, 42, 47, 48) Manometry (47.) was performed prior to splenoportovenography.
- 5) Patients with poor coagulation function, despite repeated blood transfusions and vitamin K supplements and those with massive ascites were considered for arterioportography. (24,29)

27
TECHNIQUES

ULTRASOUND

Patients were examined supine using an Aloka SSD - 180 real time ultrasound machine. Liquid paraffin was smeared on the abdomen, which was scanned longitudinally, transversly and obliquely. When excessive bowel gas interfered with the scan the patient was requested to be ambulant for a period of half an hour before being scanned again.

Both the liver and spleen were examined, their sizes and echogenic patterns noted. The splenic vein at its origin, and where possible, along its path was identified. Its length, diameter, patency and distensibility was also studied with and without the Valsava manoeuvre. The level of the splenic hilum was marked on the skin surface. The same was done for the portal vein at the hilum which was then followed along its length to the point of the confluence of the splenic and mesenteric veins.

ENDOSCOPY

Was performed by a gastroenterologist in the treatment room of the ward to which the patient had been admitted using an Olympus GFK P2 end-on

flexible fibre endoscope under sedation.

The surgeons in this study instead used a Nagus rigid oesophagoscope under general anaesthesia.

BARIUM STUDIES

Upper gastrointestinal barium contrast studies were performed in the gastrointestinal screening room of the Department of Diagnostic Radiology at K.N.H. All patients were starved from midnight on the night prior to the examination. In cases of the children in this study, they were performed first on the list on the morning of the examination. For the small children the barium paste or meal was fed to them by their mothers or by the accompanying nurses who were more familiar to them, outside the screening room. In this way, the children were more calm and reassured during the screening procedure and this also ensured that no barium was spilled on the gown. Children were promised a reward of a sweet or chewing gum by the radiologist as an enticement not to cry. It successfully facilitated salivation, enabling a good mucosal coating to be achieved and motion blur on the films caused by a crying child was avoided. The children were

examined in the supine and prone positions only. Thick barium sulphate (Micropaque 40% weight by volume) paste was used. Each patient took small mouthfuls of this paste which travelled down the oesophagus slowly coating the mucosa along the path. Spot X ray films were taken of the middle and lower oesophagus in both dilated and contracted phases, with and without the Valsava manoeuvre. Adult patients were examined in both erect and supine positions and in both oblique positions and no muscle relaxants were used in this study.

If oesophageal or gastric varices were not demonstrated a single contrast barium meal using thin barium was performed later to evaluate if any other lesion could be demonstrated as the source of the haematemesis or maelena.

Post operatively barium swallow examinations were used to assess any changes in the size of the varices or complications of the operative procedure. (21).

SPLENIC PULP MANOMETRY AND SPLENOPORTOVENOGRAPHY

This was done in the Angiographic unit of the Department of Diagnostic Radiology at KNH. An emergency tray containing drugs for resuscitation and to deal with complications of the procedure was in this room .(28b)

Patients were examined in the fasting state. They received the standard bowel preparation for patients undergoing abdominal contrast examinations which was two tablets of Dulcolax b.d. for three days prior to the examination coupled with a low residue diet for the same period. A preliminary film was taken to ascertain that the patient was correctly positioned and that the exposure factors and collimation was correct. Gonadal protection was possible in males and the 10 day rule observed in females.

The exact size of the spleen and its extension below the left costal margin in full inspiration was measured in centimetres from this film for later correlation with clinical and ultrasonographic measurements.

With the patient supine on the horizontal X ray table 5cc of 1% procaine hydrochloride was

injected into the ninth intercostal space on the left mid axillary line. The skin was anaesthetised first, and subsequently the deeper tissues. A small skin incision with a surgical blade was made to facilitate the needle and catheter passage into the spleen. An 18 gauge longwell ten centimetre venocatheter with stylet was advanced into the spleen in suspended inspiration, cranially and in the frontal plane toward the splenic hilum. This was done to avoid the complication of puncturing the colon or the pleural cavity and to minimise extrasplenic leakage of contrast. The exact position of the hilum had been predetermined and marked on the skin surface by an ultrasound examination.

Suspended inspiration was obtained by instructing the patient to take in a deep breath and to hold it until the stylet was withdrawn leaving only the flexible teflon catheter in situ. The patient was then allowed to breathe with small, shallow breaths. The examination was carried out under General Anaesthesia in young patients under the age of

nine years. Two cc of normal saline was injected into the catheter to ensure its patency. On withdrawal of the stylet from the catheter a steady flow of dark venous blood from the catheter indicated its correct positioning. This was confirmed by a 5 cc injection of 60% Urografin under fluoroscopic control: A small amount of contrast was immediately shown to pool around the catheter tip and then rapidly pass through the splenic radicles into the splenic vein and collaterals.

A soft plastic tubing filled with normal saline was then connected to the catheter and the splenic pulp pressure measured. (47) The height in centimetres of the column of normal saline that it supported was taken to be the portal pressure. The X-ray table top served as a baseline or zeropoint for the lower end of the manometer.

For the injection of contrast the soft plastic tubing was substituted with a heavier plastic tube connection with a "luerlok" at both ends. This was done to avoid leakage of contrast from the force of the injection.

A rapid hand injection of 30 cc of 60% Urografin from a 50 cc syringe was then made. The injection

took 3 - 4 seconds giving a flow rate of 7 - 8 cc per second. Lead gloves were not used, as the connecting tube insured that the syringe was out of the direct path of X-rays, but a protective lead apron was worn by all assisting in the procedure. The exposures were set at 80 kv 300 mA and 0.1 sec and 14" x 14" films were used with a Puck automatic serial changer. The focus film distance was 1 metre. Film exposures were made at 1 second intervals for five seconds starting after half the contrast injection had been made and a sixth exposure was made after a further delay of two seconds. In this way both early and late film sequences were obtained (6, 20, 31, 42, 47, 48). The skin radiation dose that the patient received was monitored by two thermo-luminescent dose meters placed on the left chest wall and in the left epigastric region of the abdomen. Splenoportovenography was not performed in the following situations:

- if the platelet count was below $85,000\text{mm}^3$
- if the prothrombin time index (PTI) was less than 75%
- and the inability of the adult patient to co-operate.

ARTERIOPORTOGRAPHY

This was performed on severely ill patients whose coagulation function and gross ascites contraindicated splenoportovenography (9, 24, 29). A preliminary film (14" x 14") was taken and was also used for later photographic subtraction. With the patient lying supine on the Xray table both femoral arteries were palpated and the easiest was selected for the puncture. If pulsations on both sides were equal, the right side was used.

A 6F torque controlled cobra shaped catheter and guide wire had been selected and their compatibility checked by passing the guide through the catheter.

Using an aseptic technique, local anaesthetic 8 - 10 cc of 1% procaine hydrochloride was infiltrated either side of the artery down to the periosteum. A 5 mm transverse incision was made over the artery to avoid binding of soft tissues on the catheter. Using a Seldinger needle the arterial puncture was made at the apex of the femoral artery arch with the needle directed 45° cephalad to the skin surface and slightly medially. In this way the needle was

in direct line with the lumen of the artery. This approach avoided either the puncture of the artery deep into the pelvis where haemostasis could not be secured by pressure, or a too distal puncture resulting in the catheterization of the profunda artery.

The needle was advanced through the soft tissues until pulsations were felt transmitted through its tip. If the pulsations were located to one side or the other, the needle was considered to be either medial or lateral to the artery and was, therefore repositioned. Both walls of the artery were punctured with a stab. The needle was slowly withdrawn and pulsatile blood flow from the end of the needle indicated a satisfactory puncture.

When good flow was obtained the guide wire was inserted through the needle and advanced without any force up the artery under fluoroscopic control. When it reached the descending aorta the needle was withdrawn over the guide, with firm pressure on the puncture site to prevent bleeding. The guide wire was wiped clean with a wet swab and the arterial puncture site was first dilated. On removal

of the dilator, while maintaining firm pressure on the puncture site, the guide wire was again wiped clean and the catheter was threaded over it. The catheter was advanced up to the descending aorta under fluoroscopic control, after which the guide wire was completely withdrawn. The catheter was then connected to a syringe of saline and after aspiration of air bubbles, was flushed. When possible, a sub selective position of the catheter tip into the splenic artery was sought.

When the sub-selective position was not possible, a coeliac artery pump injection of 60 cc of Urografin 76% over 3-4 seconds was made. This demonstrated the splenic artery clearance time, the tail of the pancreas and, most important, the venous return from the spleen. Film exposures were made with 80 Kv 300mA 0.1 sec. at a rate of two per second for 6 seconds during the injection, then after a pause of three seconds an exposure of one film per two seconds for eight seconds. There were a total of 16 films taken.

The skin radiation dose that the patient received was also measured, as in the case of splenoportovenography, with two thermoluminescent dosimeters placed on the chest and abdomen.

Arteriopography did not have any contra-indications.

PROCEDURE OBSERVATIONS FOR ANGIOGRAPHY.

- A) Immediately prior to the examination an ultrasound scan of the spleen assisted in identifying the exact position of the hilum where a skin surface mark was made. This greatly facilitated the direction toward which the splenic puncture needle had to be oriented.
- B) The patient was instructed to have complete bed rest, lying propped up with a pillow on the left flank, for the six hours following the procedure. This position significantly reduced the size of any haematoma.
- C) $\frac{1}{4}$ hourly observations were taken for the first hour followed by half hourly observations for the following two hours and then hourly for the subsequent three hours.
- D) 24 hours following splenoportovenography another ultrasound scan of the spleen was performed to establish the existence, and extent, of any haematoma.

For arterioportography, the puncture site on the shaved groin was manually compressed for 15

minutes immediately after the catheter had been withdrawn. The patient left the department only when adequate pulsations were felt on the popliteal and dorsalis pedis regions.

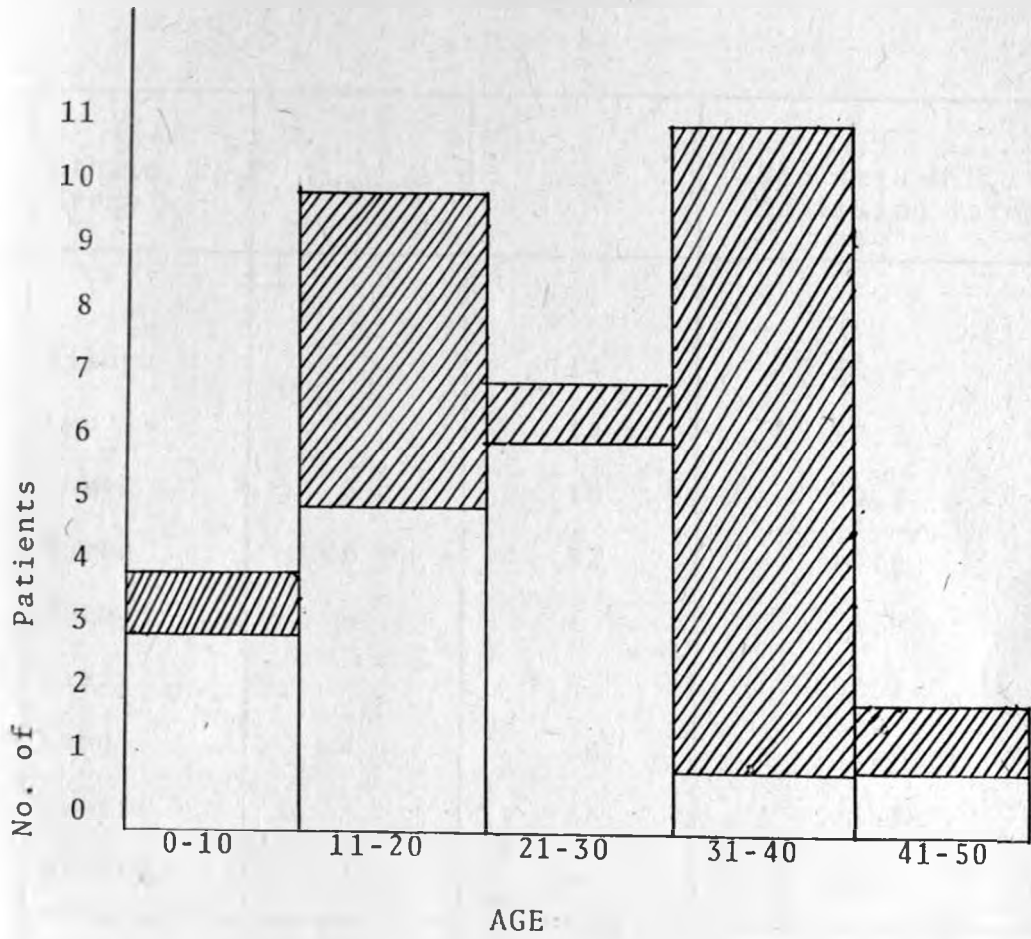The patient was instructed to have complete bed rest for the next twelve hours and not to flex the leg on the side the arterial puncture had been made for the same period.

In addition to the observations in (C) above, the nursing staff were also instructed to feel the popliteal and dorsalis pedis pulses for the following six hours, reporting their absence to the ward doctor immediately.

RESULTS

The results obtained in this study are presented in the form of the following Tables 1 - 9.

Table 1.

AGE AND SEX DISTRIBUTION

Key



Males



Females

Table 2.

ETHNIC DISTRIBUTION

Ethnic Group	Number	%	Kenyatta N.H. Admission Rates %
Kikuyu	7	14	33.9
Luo	7	14	17.2
Luhya	5	10	9.2
Kamba	26	52	19.8
Meru	-	-	3.9
Kisii	-	-	2.2
Embu	4	8	1.7
Maasai	-	-	3.3
Others	1	2	8.8
Total	50	100	100

SEX AND AGE DISTRIBUTION ACCORDING
TO AETIOLOGIC CATEGORY

AETIOLOGIC	NUMBER (%) POSITIVE			MEAN AGE
CATEGORY	TOTAL	♂	♀	(RANGE)
EXTRAHEPATIC OBSTRUCTION	12	5	7	14.75 (6-36)
HEPATOSPLENIC SCHISTOSOMIASIS	18	12	6	23.45 (9-45)
CIRRHOSIS	5	5	-	29.2 (18-34)
IDIOPATHIC	13	6	7	24 (6-35)
TROPICALSPLENO- MEGALY SYNDROME	2	1	1	30 (13-47)
TOTAL	50	29	21	23.15

Table 4.

ETHNIC AND SEX DISTRIBUTION ACCORDING TO AETIOLOGY

ETHNIC GROUP	Extra Hepatic Obstr.	Hepato Splenic Obstr.	Cirrh.	Idiop.	Trop.. Spl. meg. Synd.	Total
Kamba ♂	1	10	2	1	-	14
♀	2	4	-	5	1	12
Kikuyu ♂	2	1	1	1	-	5
♀	2	-	-	-	-	2
Luo ♂	1	1	1	2	1	6
♀	-	1	-	-	-	1
Luhya ♂	1	-	-	2	-	3
♀	1	1	-	-	-	2
Embu ♂	1	-	1	1	-	3
♀	-	-	-	1	-	1
Other ♂	-	-	-	-	-	-
♀	1	-	-	-	-	1
TOTAL	12	18	5	13	2	50

Table 5.

BLOOD BIOCHEMICAL AND HAEMOGLOBIN
LEVELS ACCORDING TO AETIOLOGY

AETIOLOGIC CATEGORY	Haemoglobin (Range)	Serum Albumin	Serum Bilirubin
EXTRA HEPATIC OBSTRUCTION	9.86 (7.2-13.8)	37.28 (30-42)	1.57 (1.2-2)
HEPATOSPLENIC SCHISTOSOMIASIS	10.08 (7.5-13.5)	35.7 (22-46)	1.5 (0.3-5.6)
CIRRHOSIS	12.26 (8-16.4)	31.4 (26-43)	3.12 (1.0-8.1)
IDIOPATHIC	9.2 (6.6-11.7)	36 (27-44)	3.21 (0.7-3.4)
TROPICAL SPLENO- MEGALY SYNDROME	13.5 (12.1-14.0)	37.5 (35-40)	1.85 (1.2-2.5)

Table 6.

HEPATOSPLENOMEGALY ACCORDING TO AETIOLOGY

AETIOLOGICAL	LIVER SIZE (cm)	SPLEEN SIZE (cm)
CATEGORY	(RANGE)	(RANGE)
Extra Hepatic Obstruction	4.5 (2-7)	9.85 (6-22)
Hepatosplenic Schistosomiasis	2.75 (2-4)	9.26 (4-20)
Cirrhosis	4 (2-6)	7.25 (5-9)
Idiopathic	6.5 (4-12)	11.6 (8-20)
Tropical Spleno Megaly Syndrome	-	12.5 (7-18)

Table 7.

MANAGEMENT ACCORDING TO AETIOLOGY

AETIOLOGICAL CATEGORY	NUMBER (%)	M A N A G E M E N T	
		MEDICAL	SURGICAL
EXTRA HEPATIC OBSTRUCTION	12 (24%)	10	2
HEPATOSPLENIC SCHISTOSOMIASIS	18 (36%)	8	10
CIRRHOSIS	5 (10%)	5	-
IDIOPATHIC	13 (26%)	5	8
TROPICAL SPLENO- MEGALY SYNDROME	2 (4%)	2	-
TOTAL	50	30	20

Table 8.

PORTAL PRESSURES ACCORDING TO AETIOLOGY

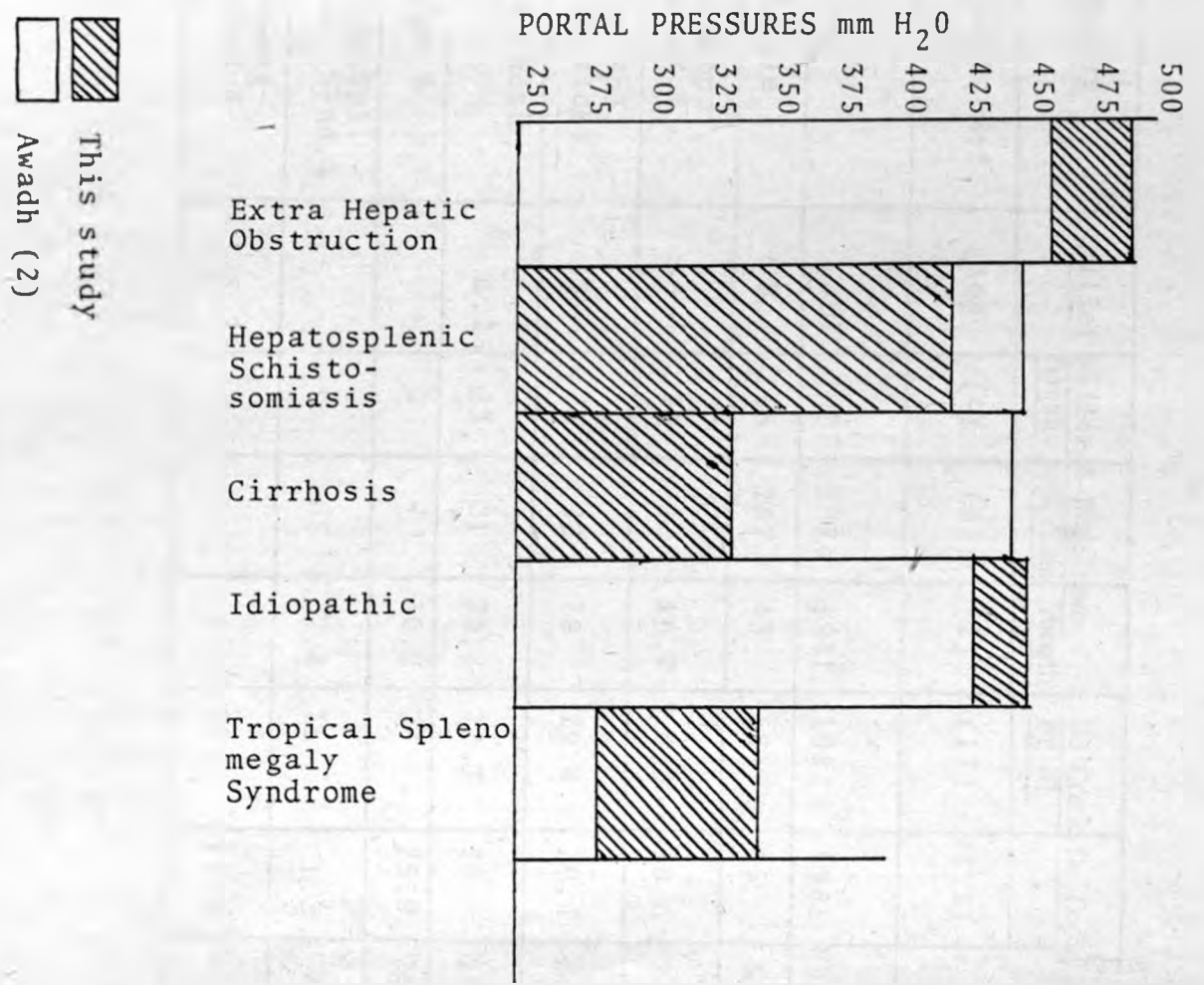
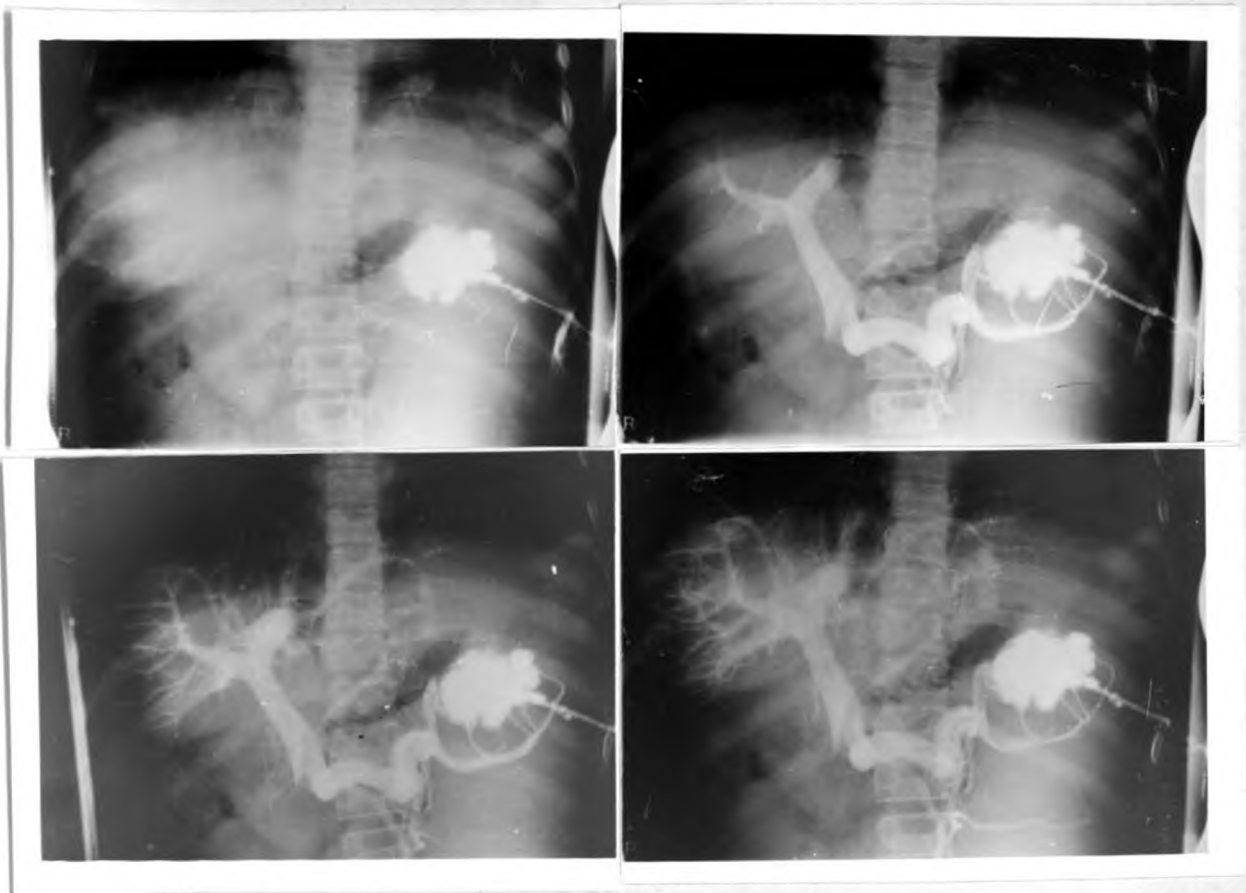


Table 9.

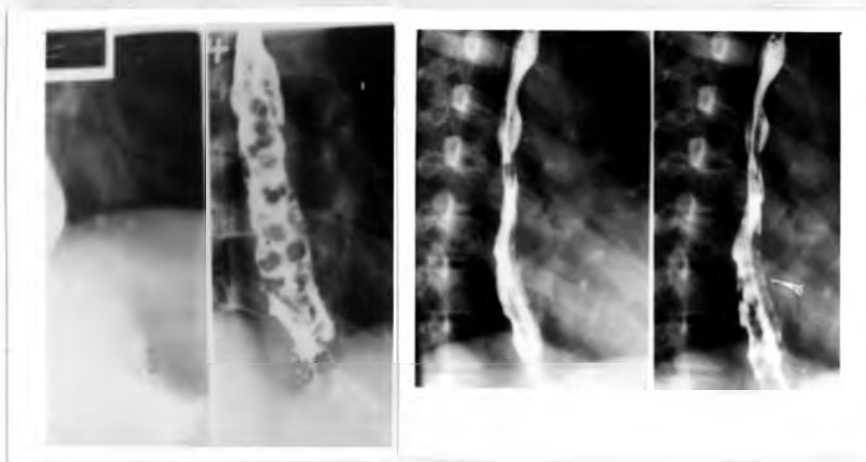STUDIES ON PORTAL HYPERTENSION IN KENYA

<u>Workers</u>	<u>Miller</u>	<u>Miller & Bagsh.</u>	<u>Miller & Bagshawe & Cam</u>	<u>Miller & Bagshawe Awadh</u>	<u>De Cock et al</u>	<u>De Cock</u>	<u>Present</u>
Source Ref.	(36)	(4)	(5)	(2)	(17)	(18)	
Year	1967	1972	1974	1981	1982	1983	1985
Sample	32	155	287	43	68	85	50
Ex.Hep. Obstr.%	50	24	22	16.2	8.8	10.6	24
Hep.Spl. Schisto.%	35	28	22	28	29.4	29.4	36
Cirrhosis %	6.25	23	21	23.2	22.1	20	10
Idio.%	-	2	-	30.2	25	25.9	26
Trop.Spl. meg. Synd.%	-	-	35	2.4	1.5	1.2	4
Undiagnosed %	3.75	-	-	-	13.2	12.9	-

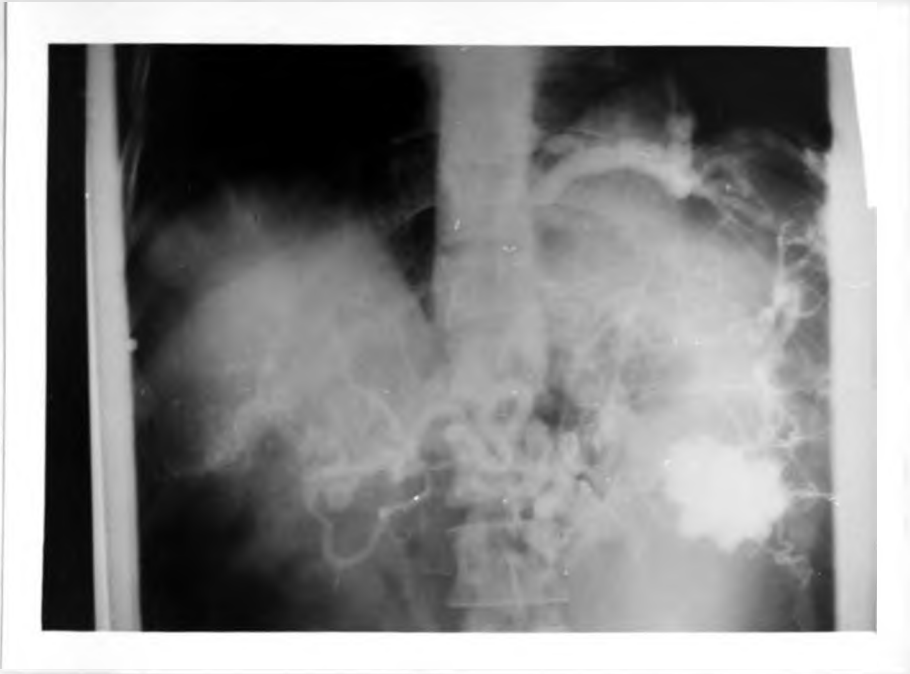

Splenoportovenogram performed using a serial changer. Exposures made at one second intervals. Contrast is first seen deposited in splenic pulp and then gradually opacifies the splenic and portal vein. Finally the intrahepatic vasculature is demonstrated. Note the filling defect caused by contrast stained blood meeting non contrast stained blood at the junction of the superior mesenteric vein and splenic vein.

(i)

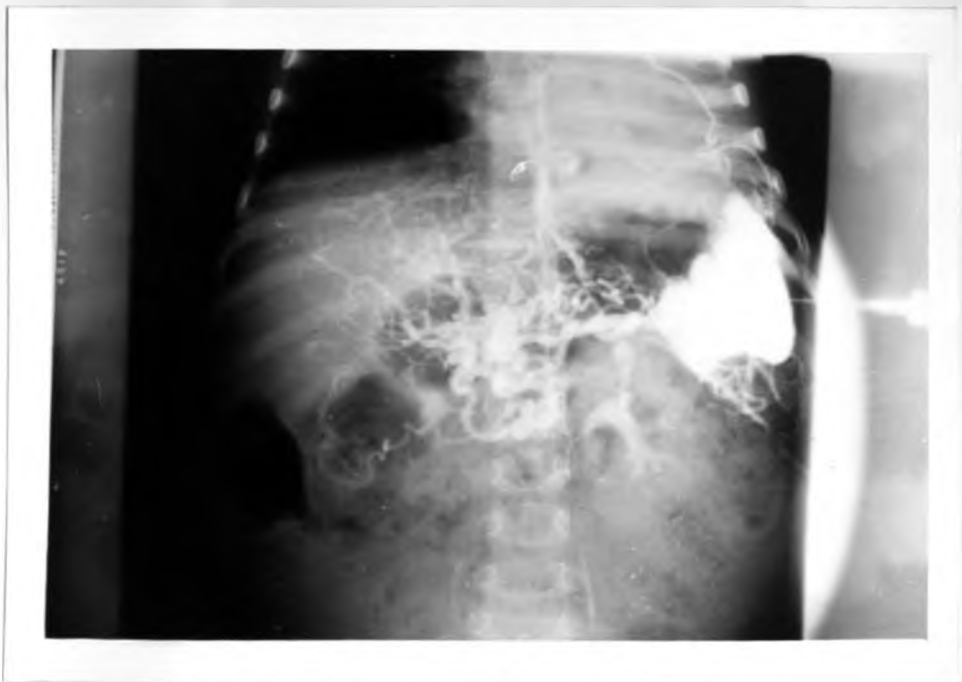

Oesophageal varices demonstrated on barium swallow examination. (Different patients).

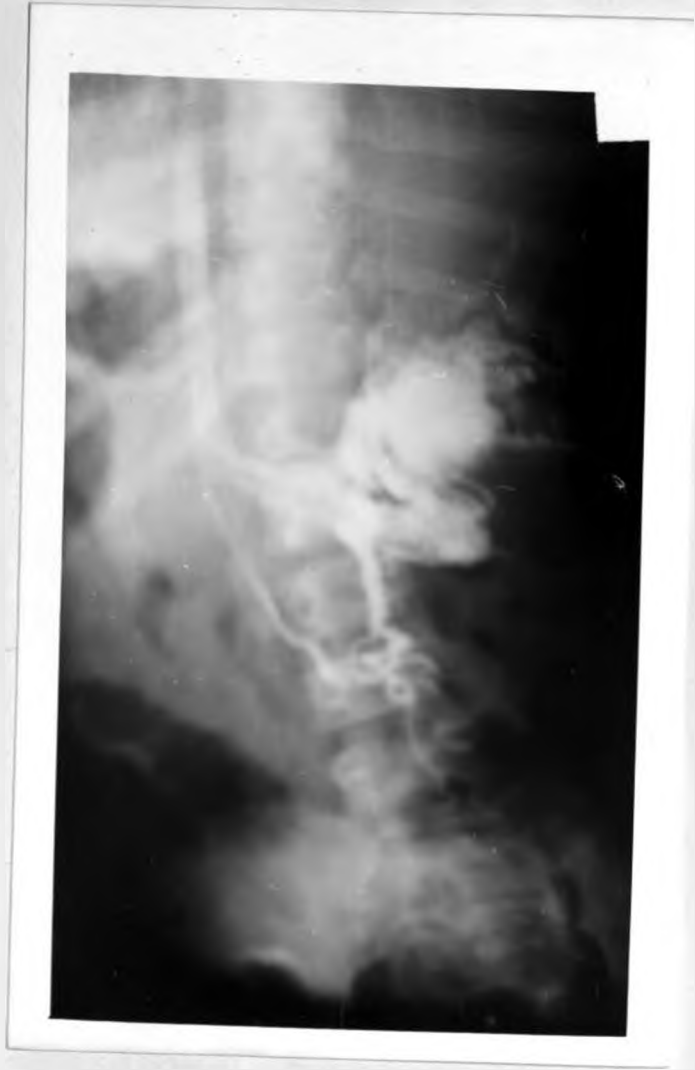

Gross collateral circulation with late
gastric varices demonstrated.

(iii)

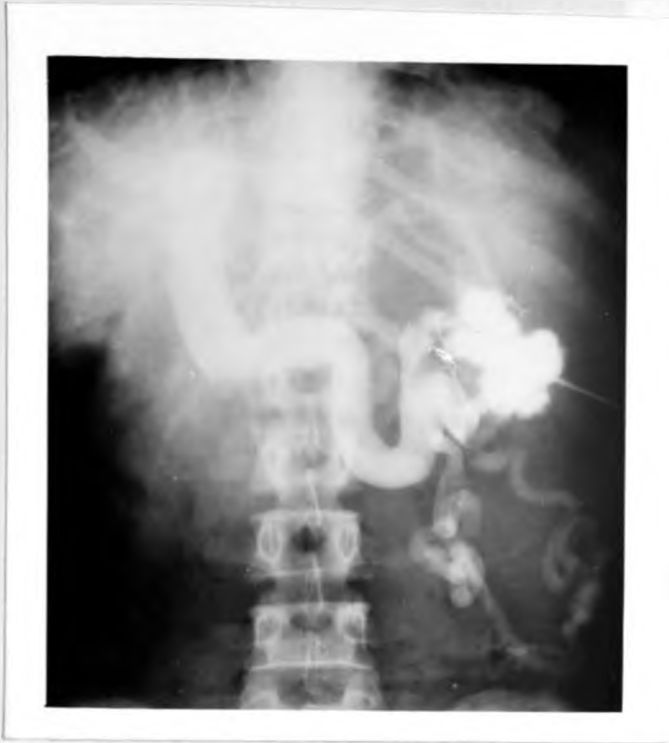

Extensive gastro-oesophageal varices with
cavernomatous transformation of portal vein.

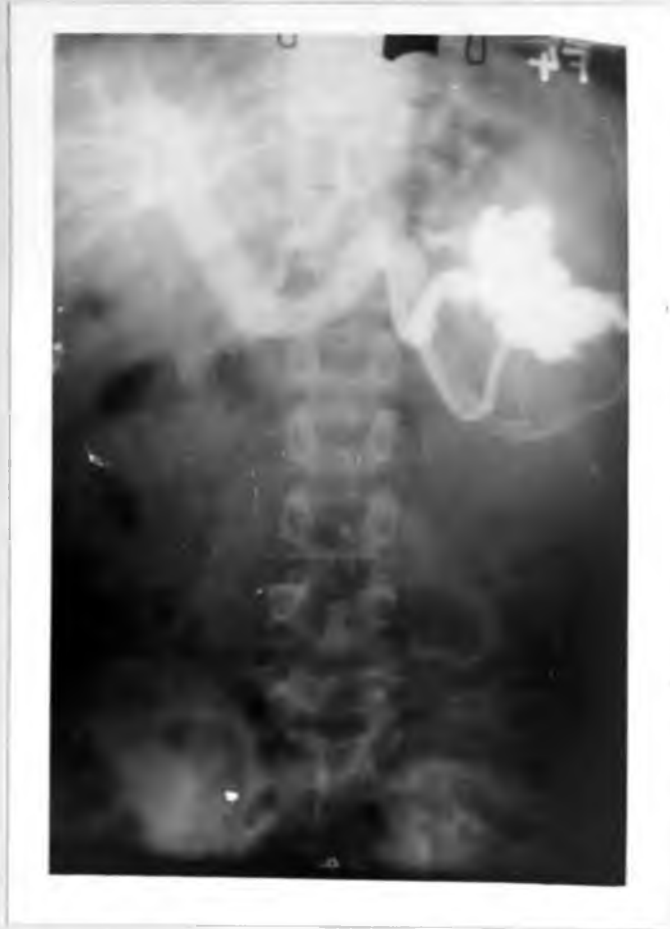

Spontaneous spleno renal shunt

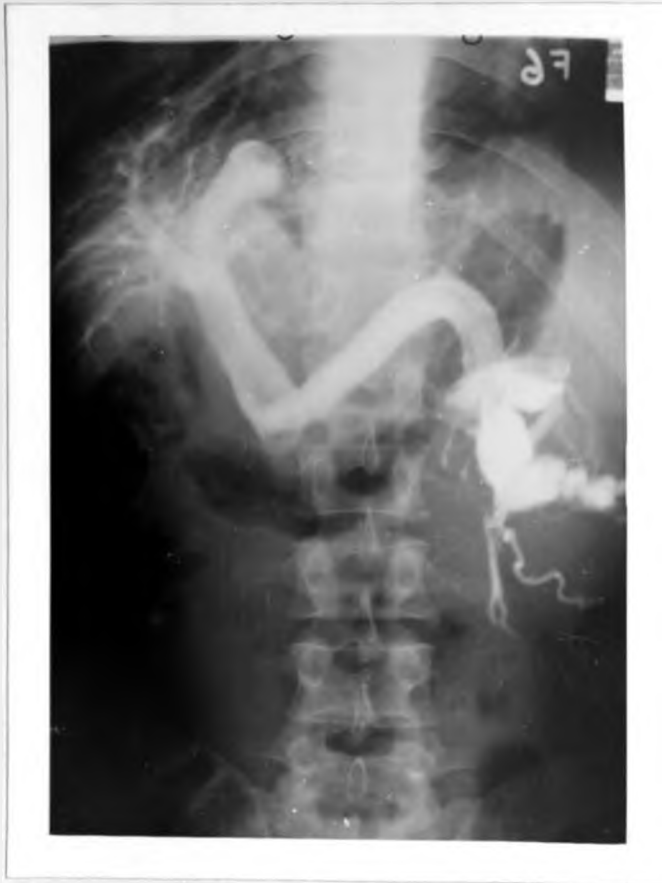Contrast is seen shunted from the splenic vein into the left renal vein. The inferior venacava is opacified.



Superior and inferior mesenteric collateral system.
Splenoportovenography demonstrates extensive collateral channels via the superior and inferior mesenteric venous system extending into the pelvis.

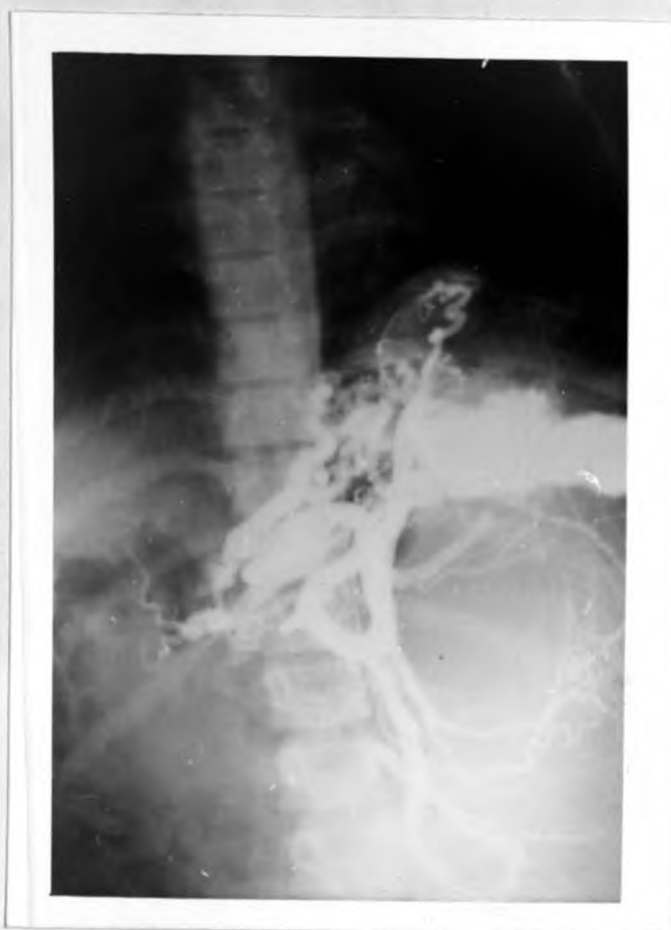

Intrahepatic vasculature demonstrated in patient with cirrhosis of liver. Note the "withered tree appearance".

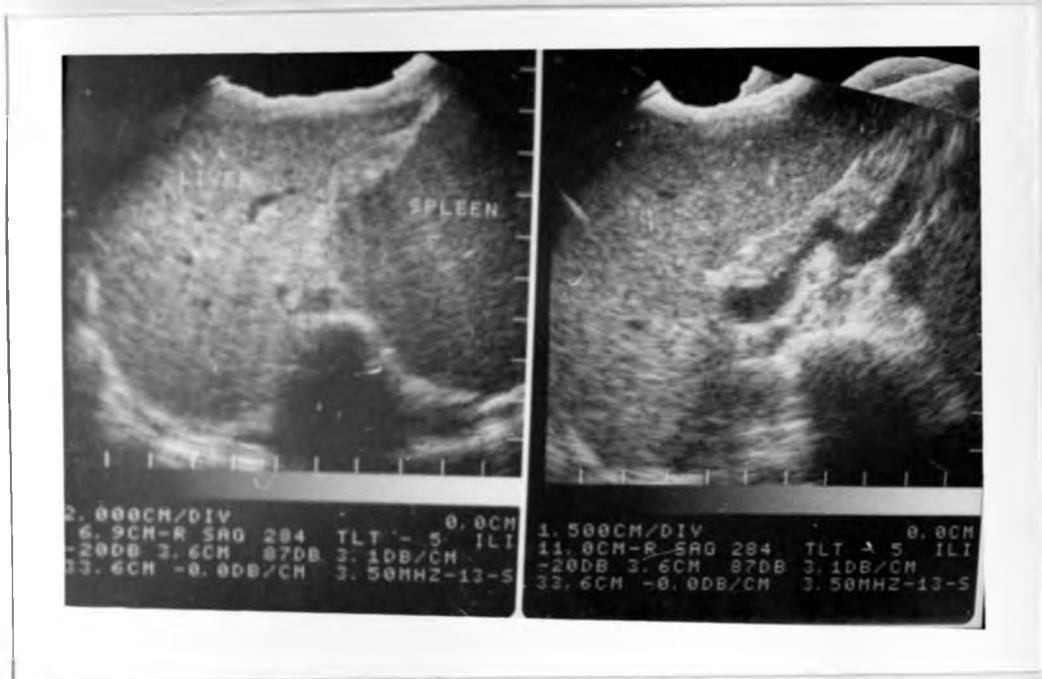


Spleno peritoneal and spleno renal collaterals,
in a patient with proven cirrhosis.

(viii)



Superior mesenteric collateral system demonstrated. In addition there are extensive gastroesophageal varices that are filled by both coronary and short gastric vessels.



Ultrasound scan of the portal system. A tortuous splenic vein is visualised. Dilatation of splenic vein with and without the valsava manoeuvre is best shown on real time ultrasound.

(x)

DISCUSSION

AGE, SEX, ETHNIC & GEOGRAPHIC DISTRIBUTION

The mean ages in four of the five aetiological categories were remarkably similar (overall mean of 24.3 years) except for the category of extrahepatic obstruction who were much younger (mean 14.7 years). This is understandable if one considers the aetiology of extrahepatic obstruction, neonatal sepsis and endophlebitis.

The higher age incidence of portal hypertension in the other aetiological categories can be attributed to the fact that the pathological obstructive process requires time to develop the symptoms of haematemesis from oesophageal varices.

Clearly the overall mean age of the patients (24.3 years) in this study indicates that the patients are mainly younger than anywhere else and therefore a deeper understanding of the various aetiological agents and possible preventative measures are warranted.

There were 29 males to 21 females giving a sex ratio of 1.38:1 comparable to the normal male: female admission ratio at K.N.H. of 1.4:1. The age range for males was 6 - 47 years with a mean of 25.2 years

while that for females was 6 - 35 years with a mean of 18.8 years making the females a much younger group than the males. Notably there was a 1:5 male:female ratio among the Kamba with idiopathic portal hypertension and a 5:2 male:female ratio among the Kamba with hepatosplenic schistosomiasis. No plausible explanation for this can be made and neither can an explanation as to why the females in this study were younger.

The fact that the mean age of patients in the hepatosplenic schistosomiasis group was low (23.4 years) second only to the Extrahepatic Obstruction category suggests that the liver damage had already been done and therefore childhood exposure seems the most important factor for this complication of schistosomiasis. However, oesophageal varices are known to develop in only a small minority of persons infected in areas of heavy transmission.

52% of the patients studied were Kamba while they account for 19.8% of the general admissions. 8% of the patients were Embu who make up only 1.7% of the general admissions at K.N.H. Embu District borders with Machakos and Kitui Districts, the home of the Kamba in this study, and are all in the Eastern Province of Kenya. Thus 60% of the patients studied had their geographic residence in the Eastern Province.

The 14% of Kikuyu patients came from Central Province originally, although 4% were now settled elsewhere. They would have been expected to make up a greater percentage of the patients as they account for one third of the general admissions at K.N.H.

The 14% of Luo patients is slightly under the expected 17.2% of their general admissions while the 10% of the Luhya patients compares favourably with their general admissions.

As a cause of portal hypertension hepatosplenic schistosomiasis appeared to be relatively more important among the Kamba making up 77% of all patients in this aetiological category.

The ethnic and geographic distribution of hepatosplenic schistosomiasis is not surprising since heavy transmission of *S. Mansoni* occurs in Eastern and Nyanza Provinces (17, 25, 40).

Patchy transmission of *S. Mansoni* occurs in parts of Central and Western Provinces, explaining the modest number of Kikuyu and Luhya patients in this category. It is known that the snails that harbour the *S. Mansoni* populate the slow moving waters of irrigation canals, now a common site in Eastern and Nyanza Provinces.

LABORATORY FINDINGS

The lowest mean haemoglobin levels were found among the patients in the category of idiopathic Portal Hypertension. The lowest mean serum proteins and lowest Prothrombin Time Indices together with the highest bilirubin levels were to be found among the cirrhotics and fitted in well with the picture of hepatocellular disease and compromised liver function. There was no significant variation in the above values in the other diagnostic groups.

Analysis of mean liver and splenic sizes did not reveal any significant differences except that the cirrhosis had the smallest liver sizes while patients with Tropical Splenomegaly syndrome had the largest spleens.

BARIUM SWALLOW EXAMINATION

Although varices were demonstrated in 71% of the patients, this high figure could well be due to the fact that a positive history of haematemesis was part of the criteria in patient selection in this study. Varices therefore, if they had bled, were already of considerable size, being easily demonstrable, on a barium swallow examination.

Other centres (51b) report an accuracy of 30% in the demonstration of varices on barium studies.

Previous workers (36) described this examination as a reliable method for the demonstration of oesophageal varices. However, they must be then be large, and they can more easily be mistaken for air bubble filling defects. In this study when a barium swallow failed to demonstrate oesophageal varices, a barium meal demonstrated a gastric ulcer in one patient and duodenal ulcers in two others. In these three cases they were presumed to be the source of bleeding in the presence of splenomegaly. Endoscopy had not been possible in any of these patients. Double contrast examinations would have definitely helped to pick up smaller lesions of the stomach and duodenum, ordinarily missed on routine single contrast examinations.

Post operatively, a barium swallow examination served to identify any early or late changes in the oesophagus either following ESI or shunt surgery. Most of the varices remain visible on the films because of sclerosis. Endoscopy however, would have been more influential in patient management (26b) post-operatively, as the exact state of the varices could have been determined, thereby permitting sclerotherapy to be performed if necessary.

Endoscopy in most centres has now replaced radiological examination in the assessment of patients with acute upper gastrointestinal bleeding (16, 22, 58).

It can be performed even on severely ill patients in whom radiological films may be difficult to obtain. Early oesophageal varices can be detected on endoscopy and not only moderate or large ones that may be demonstrated on barium swallow examinations.

Endoscopy has the additional advantage of detecting surface erosions (oesophagitis, gastritis, shallow erosions or ulcers) that accounted as the source of bleeding in 25% of patients in one series. These surface erosions would have probably been missed on a barium meal examination (58). Figures of barium meal examinations missing 20-40% of duodenal ulcers, misdiagnosing a duodenal ulcer as the site of active bleeding in another 30% have been recorded by Cotton (16). A second lesion can be missed in 10% to 20% particularly when caused by oesophagitis or gastric erosions co-existing with a duodenal ulcer. More than one potential

bleeding site may be identified in 33% of patients in a barium meal examination (58) but only endoscopy will furnish precise information.

The accuracy of double contrast barium examinations in demonstrating lesions approximates 54% (22, 58, 64) if performed within two weeks of the haemorrhagic episode. This accuracy cannot be approximated at KNH where outpatients may be investigated between two to three months from when they might have first presented with haemetemesis at the hospital. The figure of 85% obtained in visualising oesophageal or gastric varices in this study compares well with studies elsewhere. (38) However in only 44% of the patients in this study was endoscopy in fact possible because of technical reasons. In the endoscopic study of the origin of upper gastrointestinal haemorrhage done at this hospital (22) in 1978 a precise visual diagnosis of the site was made in 89% of the patients. However, only 20% were attributable to bleeding varices, duodenal ulcers being the most common pathology (53%) encountered.

The 20% encountered in the above study and

the 36% met with in Harare (63) is still much higher than in European and North American series, (58) but never approximating the most important cause of upper gastro-intestinal bleeding referred to by other workers (36). As endoscopy was not always possible within the first 24 hours of an acute bleeding episode, the accuracy of up to 95% reported elsewhere was not achieved. It is an accepted fact that endoscopic accuracy yields get progressively less as the time between the onset of the bleeding commences to the time when endoscopy is performed increases (34).

Coexisting dual pathology (varices with gastric or duodenal ulcers) were not found to be as common as documented elsewhere (58). It is possible that in this study once varices were demonstrated in a Barium swallow they were assumed to be the source of bleeding and further investigations for other pathology was not carried out. Another contributory factor was that the proportion of alcoholic cirrhotics in this study (10%) was small compared to those conducted elsewhere (58,63) Although the figures of the patients in this study who were endoscoped was

was small (44%), endoscopy definitely played a more significant role in patient management, by offering the physician or surgeon a precise site and aetiological source of the upper gastrointestinal bleeding, early in the course of the disease than barium studies.(26). This is verified by the Harare (63) and Nairobi studies (22).

Although it has been reported in some centres (48) that 30% of patients may have laceration of the splenic capsule or the development of a considerably sized subcapsular haematoma following splenoportovenography, none of the patients in this study developed this problem as documented by ultrasonography 24 hours following the procedure, and neither did emergency splenectomy become necessary (9). Perhaps the splenic capsule in this study group were more resistant to insult than in studies conducted elsewhere. Perhaps the technique needle size (18G flexible plastic catheter instead of metallic catheters) and post-procedure patient position were responsible for the avoidance of this complication.

In four cases (8%) splenoportovenography was attempted in patients with considerable ascites. Although splenic puncture was successful in all four cases and the splenic pulp pressure recorded, the catheter was dislodged from the splenic pulp during the actual filmed injection sequence. This resulted in a subcapsular injection in two patients and a peritoneal injection in the other two. This can be attributed to the lack of the tamponade effect of the lateral chest wall. The ascites was making the spleen float away from the wall. It is also possible that the pressure of the injection contributed to the detachment of the catheter from the splenic pulp. It might have been avoided by a caudal subcostal approach.

Perisplenic accumulation of contrast occurred in the 4 cases cited above and in seven others, which were, none the less, diagnostically useful examinations.

Pain radiating to the left arm occurred in one patient, probably due to the extravasation of contrast along the catheter tract and consequent dissection beneath the splenic capsule.

Reactions to the contrast medium causing mild sweating and nausea was recorded only once.(28b) This only necessitated patient reassurance and the examination was successfully completed. The patient who had this reaction was, incidentally, a cirrhotic with poor liver function.

ANGIOGRAPHY

Among the patients with non-diagnostic liver biopsies splenoportovenography clearly allocated twelve patients in the Extrahepatic Obstruction category. Six patients had a complete block of the splenic vein and six had the portal vein obstructed. The mean age was 14.7 years which made them the youngest age group studied. They also had the highest mean portal pressure recorded in this study. There were 5 males and 7 females.

Hepatosplenic schistosomiasis was diagnosed in 18 patients on the basis of positive liver biopsies. A patent splenoportal axis was demonstrated although in not all cases was it possible to comment usefully on the state of the

intrahepatic branches. The mean age was 23.4 years, making this category the second youngest group. The male:female ratio was 1:2 and the mean portal pressure recorded was 420 mm of Normal Saline.

Liver biopsies clearly allocated 5 patients into the category of cirrhotics. Splenoporto-venography demonstrated patent portal and splenic veins with a characteristic withered tree appearance of the intrahepatic branches. The 5 patients were all male and in all there was a positive history of chronic alcohol ingestion. The mean age was 29.2 years with a range from 18 - 34 years. The mean portal pressure was 332 mm of normal saline making this group record the lowest portal pressures. There were 13 patients with normal or non specific changes noted in the liver biopsies who, on splenoprotovenography had patent splenic and portal veins with normal intrahepatic branches and, were allocated in the category of idiopathic portal hypertension. The main portal pressure was 445 mm of normal saline with no sex preponderance.

They also formed a younger age group with a mean of 24 years.

The diagnosis of two cases of Tropical Splenomegaly Syndrome were made on the basis of liver biopsies, splenic aspirates and immunological studies. Neither had any evidence of *S. Mansoni* infection but both had a positive history of chronic malaria infection. Splenoportovenography demonstrated both splenic and portal veins patent with a notable enlarged diameter. There was one male and one female patient and the mean portal pressure was 340 mm of normal saline. The patients were aged 47 and 13 years respectively.

In most of these cases splenoportovenography showed abnormal gastric and oesophageal collaterals with varying degrees of tortuosity of the vessels notably in the extrahepatic occlusion. Cavernamatus transformation was observed in two cases with splenic vein occlusion. It is important to note that occlusion of the portal vein cannot be proved radiologically. The patency of the vein can be confirmed by complete filling

with contrast. Failure to visualise the vein may have been due to spontaneous reversal of flow, with the portal vein becoming an outflow tract from the liver, or perhaps because all the contrast has been shunted through a massive left gastric vein, or rapidly through a natural splenorenal shunt.

It is likely that in the series done by Miller (37) many patients were rejected for surgery on the basis of non visualised portal veins on splenoportovenography. They were presumed to be thrombosed. Relating this to the fact that Miller was not using the presently available rapid serial film changer, it is possible that the co-ordination between the timing of the single film exposure and injections of the contrast without screening, caused the splenic/portal vein not to appear opacified on the single exposure. This lent itself to an erroneous interpretation of splenoportovenography findings. Two patients

in this category underwent laparotomy and were actually found to have patent portal veins.

As a consequence of a more accurate radiological examination, more patients in this study than in Miller's were able to benefit from successful surgical management.

De Cock (17, 18) in his two series recorded 8.8% and 10.6% respectively in the category of Extrahepatic Obstruction. This variance with the present study can be attributed to the fact that there were 18 children in this series while there were only 6 in his. Miller too (36) perhaps was dealing with a much younger age group.

On the basis of these figures therefore, the same importance attached by Miller to this aetiological category as a cause of portal hypertension in 1970 (4) cannot be made. His theory on its pathogenesis is plausible (36) but the study of the cultures of the thrombosis for dysentery bacilli as being the possible initiating cause was never done (38). It is doubtful the statistical significance that can be attached to a sample of 32 patients (4).

Hepatosplenic Schistosomiasis was by far the predominant cause of portal hypertension in this study, accounting for 36% of all cases. Although this is higher than the 30% obtained by De Cock (17) or the 25% of Bagshawe and Cameron (5) or the 28% of Bagshawe (4) all of whom had conducted their studies at this hospital, it is in agreement with all of them, in that it is the single most important cause.

Patients in this study with cirrhosis made up 10% of the total. There was no tribal preponderance except for the Kamba who made up 40% of this group with the Kikuyu, Embu and Luo with 20% each. All patients had a known history of chronic alcohol consumption and were all males. Recent immunological studies by De Cock (17) Okoth (39) and Pettigrew (43) have demonstrated a higher incidence of Hepatitis B surface antigen (HBsAg) in African cirrhotics suggesting that viral hepatitis B (HBV) may be the main cause in the pathogenesis of cirrhosis in Africans and not only alcohol as is the case elsewhere (34, 50).

The fact that the cirrhotics in this study were all known alcoholics with an age range of 18 - 34 confirms that alcohol liver disease is

on the rise in developing countries.

The 4% in this study is small compared to the 35% obtained by Bagshawe and Cameron (5) in the category of patients with Tropical Splenomegaly Syndrome (T.S.S.). This can be attributed to the more precise immunological diagnostic instruments now available, together with a better understanding of its pathogenesis and the revaluation of this category by various workers since then (17, 64).

It is also probably that many cases in the above study (5) were not classified as Idiopathic Portal Hypertension, and were grouped as T.S.S., as this category has been included relatively recently.

Idiopathic portal hypertension emerged as a significantly more important category and the findings of this study approximate those of De Cock (17) and Awadh (2).

Among the cirrhotics, the portal vein tended to adopt the vertical position and appeared to be displaced to the right side of the origin.

A marked enlargement of both splenic and portal veins was taken to indicate a high flow situation. A decrease in their diameters could be attributed to periportal fibrosis which was verified in 6 cases at laparotomy.

In intrahepatic obstruction the commonest collaterals visualised in this study were the left gastric vein that communicated with the superior vena cava via the oesophageal plexus. This was observed in 21 patients (52%). Demonstrable communications via inferior vena cava through the inferior mesenteric vein and haemorrhoidal plexus was observed in only two cases. A natural spontaneous spleno-renal shunt was seen in one case.

The intrahepatic vasculature demonstrated on splenoportovenography allowed the distribution, number and appearance of branches of the portal vein to be usefully interpreted in 41 (82%) of the patients. The intrahepatic pattern was indistinguishable from the normal pattern in the idiopathic category and most cases with hepatosplenic schistosomiasis, although in a few cases a

variable degree of reduction of the calibre or fewer branches was noted. In cirrhosis the hepatic radicles often demonstrated a sharp cut off appearance.

Through splenoportovenography it was possible to gauge the patency, position and calibre of the portal and splenic veins. A morphological analysis of the porto systemic collaterals was also possible - their location, number size and flow pattern. The presence of a filling defect was detected in the contrast opacified venous channels indicating thrombosis (verified at laparotomy) in one case. However, a filling defect found at the junction of the splenic and superior mesenteric vein in six cases was attributed to a flow phenomenon, in which non contrast stained blood from the superior mesenteric vein caused a filling defect at the junction on meeting with the contrast filled splenic vein.

Venous stasis was shown by dilatation of the veins and filling of the collateral vessels with contrast. The diameters and lengths of the portal and splenic veins and collateral vessels measured on splenoportovenography films were comparable

with the ultrasound findings. When the obstruction was extrahepatic the collateral circulation developed towards the portal system distal to the obstruction (hepatopetal flow) and was recorded in 12 patients (24%). In the cases where the obstruction was intrahepatic the collateral vessels drained the congested portal vascular area toward the low pressure systemic veins and not towards the liver (hepatofugal circulation). This was documented in 26 patients (52%).

The extent and capacity of the collateral circulation as judged by the number and size of the collaterals correlated well with the magnitude of the portal flow to the liver. The appearance, time and intensity of liver specification was obvious in the hepatographic phase. The greater the degree of opacification, the larger the portal flow to the liver. The most common collaterals visualised were those of the left gastric vein. The short gastric veins and the superior and inferior mesenteric veins were also occasionally visualised. Non visualisation of the portal vein but visualisation of the splenic vein occurred

when a particularly large left gastric vein allowed diversion from the liver of nearly all the contrast stained blood after it had opacified the splenic vein. In addition, as reported elsewhere (47), most of the mesenteric venous flow was likewise diverted and continued toward the liver. Non visualisation of both portal and splenic veins occurred once when a large spontaneous spleno-renal shunt diverted the contrast stained blood from the liver, at a point immediately beyond the splenic vein. In addition, most of the mesenteric flow was likewise diverted from the liver, either through the coronary system or in a segmentally reversed course along the splenic vein to the natural shunt.

The arterial phase of arteriography (AP) gave information on the state of the liver and pancreatic perfusion as well as variations in their anatomy (as would have been expected in a hepatoma, cirrhosis or an arterio-venous fistula) in a manner not possible in a venous study. The venous phase information, however, could not fully emulate the contrast density produced in the splenic or portal veins obtained

by direct injection into the splenic pulp. It has been necessary to fall back on splenoportovenography in centres where arterioportography is routinely performed because of poor opacification of the venous system (14).

The quantity of contrast medium required (50 ml of 76% Urografin) and the number of films required to film the sequences (16 14" x 14" films) increased the cost of the examination significantly. The need to resort to the subtraction technique to obtain diagnostically useful films of the venous phase was also a further increase in time and personnel involved as compared with splenoportovenography.

The radiation dose that the patient received in AP was higher than in splenoportovenography (1439m Rad compared to 827m Rad) can be explained by increased screening time required to position the catheter into the coeliac axis.

Miller (36) considered the intraoperative pressure greater than 155mm of normal saline, measured by direct canalization of the portal vein to be indicative of portal pressure. The portal pressures measured in this study were the

intrasplenic pulp pressure measured by direct puncture and the findings are comparable to the 28 patients of Awadh (2) series. A notable deviation from Awadh's series was the much lower mean portal pressure recorded for patients with cirrhosis 332 mm of normal saline compared to 443 of Awadh's study.

No direct relation has been found between the portal venous pressure and its potential for bleeding but larger varices have been associated with an increased risk of haemorrhage (19, 32). Neither has any relation been found between the portal pressure and the degree of splenomegaly which relates better with the duration of symptoms (53, 55, 64).

ULTRASOUND

Thirty five patients in this study underwent a real time ultrasound scan. Of these 20 subsequently underwent laparotomy. Thirty five normal patients were also scanned and these served as a control group.

It was possible to visualise the portal vein (PV) in 28/35 (80%) of the patients with portal hypertension and in 32/35 (91.4%) of the normal patients.

The calibre of the PV measured at its origin in the normals was never greater than 1.3 cm. In 16/38 (57.1%) of subjects with portal hypertension the calibre was equal to or greater than 1.3 cm.

During the Valsava manoeuvre a 5 - 100% calibre increase in the splenic vein (SV) and superior mesenteric vein (SMV) was observed with a negligible calibre variation in the PV in normal subjects.

In patients with portal hypertension the SMV was visualised in 23/35 (65.7%) and SV in 29/35 (82.8%). The PV was dilated (>1.3 cm) in 13/28 (46.4%), the SMV (>1 cm) in 13/23 (56%) and the SV in 17/29 (58%). No calibre changes or changes less than 10% were observed in the SV in 28/29 (96.5%) and in 23/23 (100%) in the SMV during the Valsava manoeuvre.

Of the 20 patients (57.1%) with portal hypertension scanned who then underwent laparotomy, only 3/7 (42%) whose portal veins were not visualised on ultrasound were found to have thrombosed portal veins.

It was technically not possible to scan those patients who underwent shunt surgery to determine the patency of the shunt port operatively because of gross gaseous distention and interposition of the laparotomy scar.

Ultrasound emerged as a quick, inexpensive and non-invasive method of assessing the calibre and patency of the splenic and portal veins and their tributaries. In 57.1% of subjects with portal hypertension, a calibre of >1.3 cm was observed in the portal vein. The lack of splenic and superior mesenteric vein swelling, which is always present in the normal subject, appeared to be the most sensitive criteria for ultrasonic diagnosis of portal hypertension.

The 42% accuracy of ultrasound in diagnosing a thrombosed portal vein by its non visualisation during the scan is not as sensitive as angiography. None of the surgeons involved (28, 29) in this study would have been willing to operate on exclusively ultrasonic findings.

MANAGEMENT

Endoscopic sclerotherapy for bleeding oesophageal varices gained interest after disappointing results were obtained in trials of portocaval surgery. Although balloon tamponade vasopressin infusion or both may provide haemostasis, only about one third of patients were still alive one year after their first bleeding episode - a fact that presumably reflects the high incidence of re-bleeding and the severity of the

underlying liver diseases. The results of recent randomized trials have favoured sclerotherapy over the established medical regimen (52).

Although studies comparing portocaval shunting with standard medical therapy have demonstrated a reduction in the incidence of variceal haemorrhage in patients treated surgically, they failed to demonstrate any significant improvement in survival in such patients (11, 45), as compared with medical controls.

Theoretically, endoscopic sclerotherapy should result in some obliteration of varices and decrease in re-bleeding associated with shunt surgery, but without subjecting patients to laparotomy and portocaval anastomosis. Thus, a "modified medical" programme for treatment of variceal haemorrhage, including the use of sclerotherapy should have been superior to shunt therapy. The study conducted by Cello et al (11) demonstrated that there was no significant difference in long term survival between sclerotherapy and shunt groups, and concluded that sclerotherapy was less costly than shunt surgery and as effective for the treatment of oesophageal varices.

They were, as most of the European and North American studies, dealing with alcohol induced cirrhotics with portal hypertension - a different pattern from that encountered at K.N.H.

To date 20 sclerosing injection sittings have been performed in six of the patients in this study. All injections were done after an acute bleeding episode and not as a prophylactic measure.

Each of the six patients have had an average of three sittings. Three patients have undergone successful shunt surgery and two are currently being considered. One patient died while awaiting ESI to be initiated and two have had re-opening of collaterals, demonstrated on splenoportovenography, shown at a distance of six months.

Injection into the varix was the aim, although undoubtedly some sclerosant leaked out into the tissues. However the complications reported by Farooq (21) were not encountered in this study. Endoscopic sclerosing injection therapy is expected to bring about temporary control averaging 12 - 18 months in children (16b) but as Kyambi (30) confirms, this time is vital so as to allow the child to grow and have a greater chance of withstanding major surgery. The greatest disadvantage with ESI is that it is a slow time consuming procedure requiring

a considerable amount of experience to be usefully performed. Regular three monthly endoscopic examinations are necessary and this is not always possible. However, it is to be borne in mind that it is easier to train and acquire experience as an endoscopist than a vascular surgeon.

Barium swallow examinations in these patients have been of use in demonstrating the presence of oesophageal varices before EIS and showed the minimal changes following sclerotherapy. Patient management was not significantly altered, and they continue to require repeated EIS sessions.

Perhaps the progress of ESI would be best evaluated by the endoscopist himself and clinically by the decrease in frequency of upper gastrointestinal bleeds. Shah (49) is of the opinion that endoscopy is definitely a first line approach, but is complementary to, and not exclusive, of, barium swallow examinations.

20 patients were managed surgically, of whom two had stapling operations and two had gastric transection and porta azygos disconnection. 16 patients underwent a distal-splenorenal shunt operation, 2 a porto-caval and 2 a mesocaval shunt. Of the porto-caval shunts, which had been performed on patients

earlier on in this series, one, when last seen at the clinic three years after surgery, had been well until then but was showing signs of encephalopathy. The other has been lost to follow up.

Two patients with the Warren shunt died within two weeks of the procedure. Eight patients have to date been followed up in the surgical clinic and have had no major complaints, notably there has been no recurrence of haematemesis. Three of the female patients have since delivered healthy full term infants. The other patients managed surgically have been lost to follow up. A factor that could have influenced this is that many patients on discharge are advised follow up at the nearest hospital to avoid them incurring additional travel expenses to Nairobi.

Two patients in this study required three attempts each to achieve a satisfactory shunt. One of these patients died on the twelfth post-operative day.

Surgery was followed by cessation of the life threatening haemorrhage, a return of the abdominal girth to normal, alleviation of abdominal distress, improvement of the nutritional state of the patient, and disappearance of the splenomegaly.

These results contrast with Millers recommendation (37) that only two operations are suitable for decompression: Portocaval shunts and supra-diaphragmatic proto-azygos disconnection.

Gastric transection was twice performed in this study as advocated by Miller (27, 38) and a partial gastrectomy was done in one patient when the acute upper gastrointestinal bleeding had been incorrectly attributed to a bleeding duodenal ulcer. It was only in theatre that the real source of bleeding (gastric and oesophageal varices) was discovered. This patient was then subsequently investigated and operated on, with a distal splenorenal shunt. The patient is well to date. This case in point is useful to reaffirm the need for routine endoscopy to be performed on all acutely bleeding patients to establish the source of bleeding.

Some surgeons (28) maintain that there is no room for paliative surgical measures, on the basis that, often, these measures are in themselves sufficiently major as elective shunt surgery would have been.

Both Kariuki (28) and Kyambi (30) unlike Miller (38) agree that shunt surgery must be approached with an open mind, without any preconceived shunt operation as Miller suggests(38).

In the patients that underwent shunt surgery it has not been possible to measure their post shunt portal pressure because in most cases splenectomy had been performed. It was thus not possible to confirm the expected 33% decrease in portal pressure post operatively as recorded in other centres (45b) However, there is ample clinical information to indicate that there was a significant decrease in portal pressure in that, in those patients in whom it has been possible to follow up, there has not been any re-bleed. Barium swallow examinations done at a distance of six months post operatively have also revealed no radiological evidence of varices. Endoscopy has not been done on these patients.

The post operative mortality figures in this study can be attributed to poor patient selection and operation technique in two cases. In one case the liver function tests were borderline, and the patient had signs of impending hepatic

coma following a severe haemorrhage prior to surgery. In the other case inappropriate anaesthesia (halothane) could have precipitated liver failure. This patient had had to be taken three times to theatre until a satisfactory shunt was attained. Better patient selection is possible utilising radiology, but vascular surgical technique is attained only by experience. The other four patients who died during this series were as follows: one died a year later following a stapling operation as a consequence of a massive haemorrhage, another while awaiting an operation, a third while awaiting sclerotherapy and the fourth after a massive haemorrhage. It is patently clear that portal hypertension per se is not a surgical indication. The major surgical problem remains the patient with bleeding oesophageal varices.

Splenoportovenography provided the surgeon with pictorial information on the venous system (55, 61), but the ultimate decision on the type of shunt could only be left to the surgeon at the time of the operation.

The criteria on the patient selection for surgery based on age, liver function and radiological

findings needs to be carefully adhered to. Linton (33) used liver function tests as the criterion for selection. Child(12, 13), however, used clinical risk categories largely to assess the operative risk. Both these criteria are helpful in predicting the long term survival and incidence of encephalopathy. Warren (61) and associates advocate another form of patient selection based on haemodynamic findings.

Haemodynamic information obtained through splenoportovenography or arterioportography is of prognostic value as regards both operative mortality and long term survival (61).

There is still need for portosystemic decompression but perhaps to quote Conn (14) "we must learn to select better who should be shunted or to shunt better those we select".

Among the patients managed medically, a reduction of the spleen size following several months of treatment Chloroquin 300 mg once weekly or Proguanil 100 mg od prescribed according to what was available, and Hycanthon 100 mg od.

A 30% reduction was observed in 17 patients (34%) on an ultrasound scan while 10 patients

were lost to follow up and no reduction was noted in 7 patients (14%).

Among those managed by EIS there was a notable decrease in the haemorrhagic episodes, after repeated treatment sessions over a period of one year. Three of these patients underwent shunt surgery and currently two are being considered for it.

Kyambi (30) comments that shunt surgery in children has a greater probability of success if the patient is over five years and suitable vessels are demonstrated on splenoportovenography to perform a shunt. He admits that the shunt operations that he has performed in children are still too few to be of any statistical significance. Difficulty of post operative follow up as experienced by Miller (38) remains a problem.

In the whole context of patient management not enough can be said about the preventative aspect of the various causes of portal hypertension. Health education, better sanitation, more efficient irrigation, early screening, diagnosis and treatment would all be goals that any government would like to attain.

Special problems in the diagnosis and management of portal hypertension in the 18 children (36%) in this study were encountered. Most of them required general anaesthesia and often the procedure had to be postponed for technical reasons. In three cases arteriportography was necessary, because of the failure of splenoportovenography in one case, poor coagulation function despite vitamin K supplement in another, and to rule out an arterious venous malformation in the last, after splenoportovenography findings were equivocal. Eight children were in the group with Extrahepatic Obstruction. In only one child was it possible to confirm a history of neonatal omphalitis. Thrombosis of the splenic vein was demonstrated in four of these patients while the other four had thrombosed portal veins demonstrated in splenoportovenography. None of these children were considered for surgery as no suitable vessels were demonstrated. In the hepato-splenic schistosomiasis group there were 6 children all of whom were managed medically. Only one of the three children in the category of idiopathic portal hypertension underwent shunt surgery. A modified

Warren distal splenorenal shunt was performed on this case and to date the patient is well. The possibility of EIS being performed in children was entertained, particularly as recent reports indicate that these patients improve gradually with the time and are perhaps better off without surgery (49). This was not possible as there is no paediatric fibre optic endoscope working in the Hospital.

Ultrasound is a far more simple procedure that does not have any radiation hazard. The initial findings suggest that it is able to furnish useful information of the spleno-portal axis and further studies in the applications to the investigation and in the management of patients with portal hypertension is warranted.

Fibre optic endoscopy is well tolerated by patients and complications are rare. A fundamental decision and concerted effort needs to be made in training post-graduate students in internal medicine, the skills and possibilities of well performed endoscopy. Indeed, teaching endoscopy is a heavy additional burden on the relatively few who are currently trained. There are only twelve physicians in the country (nine of whom are in Nairobi) who

routinely perform endoscopy on their patients (49). The time taken in acquiring the necessary skill and experience for endoscopy is outweighed by the time and expense involved in training a vascular surgeon. The subsequent endoscopic follow up and treatment of these patients could well take place at the level of the nearest provincial or district hospital, making the job of a provincial physician more challenging and rewarding. Doubts have been cast regarding the influence and thus the utility of the upper gastro-intestinal barium investigations in the diagnosis and management of patients with portal hypertension. A barium study, when it demonstrates oesophageal varices, cannot furnish accurate information confirming that the varices, simply by virtue of their demonstration, are, in fact, the source of the upper gastro-intestinal bleeding.

Demonstrating and recording their presence on film does not alter the patients management. Rather it can be rationalised and discouraged by stating that it exposes the patient to unnecessary radiation, increases the costs in time, personnel and materials.

The accuracy of single contrast barium meal examination in demonstrating any further pathology

that might account for an upper gastro intestinal bleeding in the presence of splenomegaly, is also cast into doubt.

Endoscopy (26) is definitely better and more accurate as a first line investigation but well performed double contrast meals are not obsolete, in centres with limited facilities. They are safe and relatively quick procedures, detecting about 80% of gross lesions with few false positives (16).

Splenoportovenography performed using a serial changer was the single most useful radiological examination done assisting in the classification and pre-operative work up of patients with portal hypertension. It furnished the following information that significantly influenced patient management:

- establishment of portal hypertension through the measurement of the portal pressure.
- location of collaterals and their size, including oesophageal and gastric varices.
- estimation of the volume of both the intra and extra hepatic portal venous flow.
- establishment of the patency but not occlusion of the portal vein.

It appears that only portal systemic shunting and beta blocking agents are likely to reduce portal

pressure in the long term. In contrast to surgical procedures, there is no evidence that propranolol, although lowering hepatic blood flow as well as portal pressure, increases portasystemic shunting. Patients with poor liver function fare badly after protocaval shunt surgery, and the pharmacological reduction in portal pressure with propranolol may be a better alternative. The combination of propranolol with a method of variceal sclerosis may well prove to be particularly effective management for these patients portal hypertension.

The correct management in selected patients may well be the combination of variceal ablation, with a pharmacological reduction in portal pressure. The question of the ideal management of portal hypertension still remains but to quote Conn (15b), "I am still asked what is ideal treatment for an individual patient and, sometimes 'what would you want done if you were bleeding from varices?' To paraphrase my response of 10 years ago to this question, if I were bleeding from oesophageal varices, I should like to be treated at an academic institution, preferably where a controlled clinical comparison of sclero-therapy, beta-adrenergic

blockade and shunt surgery were in progress. I would hope that my bleeding was promptly controlled. I would pray to meet the criteria of inclusion, since the prognosis of those who do is much better than those who do not. I would fervently hope to be selected - randomly, of course, - for the operative or endoscopic group. Then in the light of previous findings, and with faint heart and much guilt, I would refuse treatment. If I were selected to receive propranolol, I would probably comply".

CONCLUSIONS

1. The age distribution of the patients studied in the present study is comparable with that of Bagshawe and Cameron (1974) and Awadh (1981) and confirms that it is a younger age group that presents with portal hypertension at K.N.H.
2. The ethnic distribution in this study confirmed that portal hypertension was more frequent amongst the Kambas than all the other tribes combined. 60% of the patients in this study came from the Eastern province.
3. The aetiological pattern in the present series followed a different trend compared to earlier studies in Kenya, in that almost a third of all patients had no obvious cause to explain (hence idiopathic) the portal hypertension, an entity not previously realised by earlier workers.
4. There was an inexplicable increase in the male:female ratio of Kamba patients (1:5) in this category and a reverse ratio (5:2) in the same ethnic group in the category of hepatosplenic schistosomiasis.
5. Ultrasound has a role to play in the early

diagnosis of these patients and also during their management and can be easily performed even at peripheral centres. The role of endoscopy in the diagnosis and management of the patients is more accurate than radiology, however, in a set up of limited facilities, they are complementary.

6. The surgical and medical management has proved to be fair at a distance of a year, but probably many more patients could benefit from less invasive medical management if the diagnosis and possible aetiology could be established early. Those patients who underwent surgery did well generally, but better selection is necessary.

RECOMMENDATIONS

1. Further studies on the use of ultrasound are warranted to decide if reliable criteria can be established to incorporate it as a preliminary investigation for all patients with a history of upper gastro intestinal haemorrhage in the presence of splenomegaly.
2. Endoscopy be performed in the acute stage as a first line investigation in all patients with upper gastro intestinal haemorrhage. In places with limited facilities, barium swallow examinations have a role, in complementing endoscopic findings and also in investigating the complications of EIS.
3. Splenoportovenography apart from providing adequate pictorial information that assists in the possible aetiological classification of the patient, also notably influences patient management. It ought to be considered in all patients with portal hypertension.
4. Arterioportography can be performed if splenoportography is contraindicated or does not yield sufficient information.

5. Further studies in the medical management of these patients, particularly with beta blockers and EIS are warranted as they are cheaper and much easier to perform. Treatment and follow up is possible even at the provincial and district levels.
6. The high prevalence of Portal Hypertension in the Eastern Province warrants further study in the feasibility of setting up a primary diagnostic and treatment centre there for a more effective management of patients nearer their homes.
7. The aspect of prevention and treatment of the various aetiological factors leading to portal hypertension (particularly because a generally younger age group is affected here more than elsewhere) be studied and the necessary preventive and therapeutic action be taken.

REFERENCES

1. ARAP SIONGOK, T.K., MAHMOUD, A.A.F. OUMA
WARREN, K.S., MULLER, A.S., HANDA, A.K.,
YOUSER H.S.

Morbidity in Schistosomiasis Mansoni
In Relation to Intensity of Infection:
Study of a Community in Machakos, Kenya.

American Journal of Tropical Medicine and
Hygiene (1976) 25:273-284.
2. AWADH SWALEH

Pattern of Portal Hypertension of the
Kenyatta National Hospital, Nairobi.

Master of Medicine thesis
University of Nairobi 1981.
3. BAGSHAWE A.C. & MILLER, J.R.M.

The Aetiology of Portal Hypertension
Associated with Gross Haemorrhage in Kenya.

East African Medical Journal 1970: 47:3:185-187.
4. BAGSHAWE, A.C. & MILLER, J.R.M.

Portal Hypertension in "Medicine in a Tropical
Environment."

Editors : Sharper A.G., Kubakamusoke J.W.,
and Hutt M.S.R.

British Medical Association 1972:pp 409-423.
5. BAGSHAWE A.C. & CAMERON H.M.

Idiopathic Tropical Splenomegaly and Portal
Hypertension in "Health and Disease in Kenya."

Editors: Vogel L.C., Muller A.S., Odingo R.S.,
Onyango Z., and De Geus A.

East African Literature Bureau 1974:pp 445-452.

6. BERGSTRAND I,
Splenoportovenography in "Angiography."
Editor: Abrams H.
Little Brown and Company 1971.
7. BOLONDI L., CAVALLARI A., MAZZIOTTIA.,
SOLIANI L., ARIENTI V., POSATI L.,
LABO G.

Ultrasonography in the Diagnosis of Portal
Hypertension and Control of Porta Caval
Shunts.

In "Proceedings of Sero Symposium No. 34"
Editors Orloff M.J., Stipa S., and Ziporo
Academic Press, London 1980: pp.119-121
8. BORON M.G., WOLF B.S.

Splenoportovenography
Journal of the American Medical Association
(1968) 406:3:pp 629-634.
9. BURCHELL A.R., MORENO A.H., PANKE W.P.,
& ROUSSELOT L.M.

Some Limitations of Splenic Portovenography.

Annals of Surgery (1965) 162:pp. 359-369.
10. CALDER J.F., DE COCK K.M., STASS B.

Diagnostic ultrasound in abdominal
disease - First experiences in Kenya.

East African Medical Journal (1980) 57 pp.607-614.
11. CELLO J.P., GRENDALL J.H., CRASS R.A.,
TRUNKEY D.D., COBB E.E., & HELLBRON D.C.

Endoscopic Injection Sclerotherapy v/s
Shunt in patients with Severe Cirrhosis
and Variceal Haemorrhage.

New England Journal of Medicine (1984)
311:pp.:1591-93.

12. CHILD III, C.G.
The Hepatic Circulation and Portal Hypertension.
Saunders. Philadelphia (1954) Ch. 15.
13. CHILD III C.G.
The Liver and Portal Hypertension
W.S. Saunders, Philadelphia (1964).
14. CONN H.O., LINDENMUTH W.W., MAY C.J.,
RAMSBY G.R.
Prophylactic Portacaval Anastomosis
A Tale of Two Studies.
Medicine (Baltimore) 1972; 51:27-40.
15. CONN H.O., RESNICK R.H., GRACE N.D. et al
Distal Spleno Renal Shunt Versus
PortaCaval Surgery: Current Status of a
Controlled Trial.
Hepatology (1981) 1:1:151-60.
- 15b. CONN H.O.
In 'Clinics in Gastroenterology' (1985):286
- 15c. CONN H.O., MITCHELL J.R., BRODOFF M.G.
A Comparison Of The Radiological And
Endoscopic Diagnosis Of Oesophageal
Varices.
New England Journal of Medicine.
(1961): 265: 160-64.
16. COTTON P.B.
Fibre Optic Endoscopy and the Barium Meal
- Results and Implications.
British Medical Journal (1973) 2:pp. 161-65.

- 16b. CYWES S., LOUW J.H.

Portal Hypertension in Children

Proceedings of the International Liver Conference with Special Reference to Africa.

Pitmans London (1973) pp. 283 - 86.

17. DE COCK K., AWADH S., RAJA R.S., WANKIA B.M., LUCAS S.B.

Oesophageal Varices in Nairobi:

A Study of 68 cases.

American Journal of Tropical Medicine and Hygiene (1982) 31: 579-88.

18. DE COCK K.

Splenomegaly and Portal Hypertension in Nairobi, Kenya.

A study in Geographical Medicine.

Doctor in Medicine Thesis.

University of Bristol (1983).

19. DE GRADI A.E.

Oesophageal Varices, Splenic Pulp Pressure and Directional Flow In Patients With Alcoholic Liver Cirrhosis.

American Journal of Gastroenterology (1975) 59 : pp. 15 - 22.

- 20 ECKMAN C.

Portal Hypertension : Diagnosis and Surgical Management.

Acta Chirurgica Scandinavia (1957) Supplement No. 222.

21. FAROOQ P.A.

The Esophagus after Endoscopic Injection Sclerotherapy:
Acute and Chronic changes.

Radiology (1984). 153: 37-42

22. HANSEN D.P., & DALY D.S.

A Fibre Endoscopic Study of Acute
Gastro Intestinal Haemorrhage in
Nairobi, Kenya.

American Journal of Tropical Medicine
and Hygiene (1978) 27:1 pp.197-200.

23. HAYES P.C., SHEPHERD A.N., BOUCHER A.

Medical Treatment of Portal Hypertension
and Oesophageal Varices.

British Medical Journal (1983) 287:733-36.

24. HERLINGER H.

Arteriopography

Clinical Radiology (1978) 29 pp. 255-275.

25. HIGHTON R.B.

Schistosomiasis in "Health and Disease
in Kenya."

Editors: Vogel I.C., Muller A.S.,
Odingo R.S., Onyango Z.,
and De Geus A.

East African Literature Bureau pp. 347-355.

26. HOLDSWORTH C.D., BARDHAN K.D., BALMFORTH C.H.,
DIXON R.A.

Upper Gastro Intestinal Endoscopy: Its
Effects on Patient Management.

British Medical Journal (1979):1, 775-76.

27. JOHNSTON G.W.

Endoscopic Sclerotization and Oesophageal
Transection Using the S.P.T.U. Gun.

In Proceedings of Serono Symposium No. 34
Editors: Orloff M.S., Stipa S., and Ziparo.

Academic Press, London 1980:pp.25-31.

28. KARIUKI J.K.N.

Specialist Cardiothoracic and Vascular
Surgeon

Kenyatta National Hospital, Nairobi.

Personal Communication (1985).

28b. KITONYI J.M.K.

Reactions and Cardio-Vascular Changes
at Excretion Urography.

East African Medical Journal (1981)
58:942.

29. KREEL L., & WILLIAMS R.

Arteriovenography of the Portal System.

British Medical Journal (1964) 2:1500-1503.

30. KYAMBI J.

Paediatric Surgical Specialist

Department of Surgery, University of Nairobi.
Personal Communication (1985).

31. LEGER L.H.

Splenoportovenography - Diagnostic Phe
of the Portal Venous System.

Charles C. Thomas, Springfield, Illinois (1966).
pp. 3 - 67.

32. LEBREC D., DE FLEURY P., RUEFF B., NAHUM H.,
BENHAMON S.P.
Portal Hypertension, Size of Oesophageal
Varices and Risk of Gastro-intestinal
Bleeding in Alcoholic Cirrhosis.
Gastroenterology (1980):79:1139-44.
33. LINTON R.R.
Selection of Patients for Portocaval Shunts,
With Summary of 61 Cases.
Annals of Surgery (1951) 134:pp.433
34. LITTLE G., MATTHEWS H.R.
Endoscopic Assessment of Oesophageal Disease.
British Medical Journal (1980) 1269-70.
35. MACDOUGALL B.R.D., WESTABY D., THEODOSSI A.,
DAWSON J.L., WILLIAMS R.
Increased Long Term Survival in Variceal
Haemorrhage Using Injection Sclerotherapy.
Results of a Controlled Trial.
Lancet (1982): 1: 124-127.
36. MILLER J.R.M.
Portal Hypertension in Nairobi.
East African Medical Journal (1967)
44:9 pp 376 - 386.
37. MILLER J.R.M.
Portal Hypertension
East African Medical Journal (1972)
49:3 pp. 243 - 245.

38. MILLER J.R.M.

Former Head of Surgical Services Government
Of Kenya.

Personal Communication (1985).

39. OKOTH F.A.

The Pattern of Liver Cirrhosis at Kenyatta
National Hospital, Nairobi.

Master in Medicine Thesis
University of Nairobi (1984).

40. OOMEN L.

Hepatosplénomegaly in Machakos District.

East African Medical Journal (1970)
47 : 12 pp.

41. ORLOFF M.J.

Emergency Diagnosis and Medical Management
Of Bleeding Oesophageal Varices in Proceedings
of Serono Symposium No. 34.

Editors: Orloff M.J., Stipa S., and
Ziparo V.

Academic Press, London (1980) pp . 2 - 11.

42. PANKE W.F., MORENO A.H., POUSSELOT L.M.

The Diagnostic Study of the Portal Venous
System.

Medical Clinics of North America (1960)
44: 727 - 742.

43. PETTIGREW N.M., BAGSHAW A.F., CAMERON H.M.,
CAMERON C.H., DORMAN J.M., MACSWEEN R.N.M.

Hepatitis B Surface Antigenemia in Kenyans
With Chronic Liver Disease.

Transactions of the Royal Society of Tropical
Medicine and Hygiene (1976):70:462-65.

44. RAIA S.

Portal Hypertension in Schistosomiasis

In Proceeding of Serono Symposium No. 34

Editors: Orloff M.J., Stipa S., and Ziparo.

Academic Press, London (1980) pp. 301 - 312.

44b. RESNICK R.H., CHALMERS T.C., ISHIHARAA.

And the Boston Inter hospital Liver Group.

A Controlled Study of the Prophylactic Porto-caval Shunt : A Final Report.

Annals of Internal Medicine (1969)
70: 675 - 88.

45. REYNOLDS T.B., DONOVAN A.J., MIKKELSEN W.P., REDEKER A.G., TURRILL F.L., WEINER J.M.

Results of a 12 Year Randomised Trial of Porto-Caval Shunt in Patients with Alcoholic Liver Disease and Bleeding Varices.

Gastroenterology (1981) 80: 1005-11.

45b. REYNOLDS T.B.

Portal Hypertension in Diseases of the Liver.

Editor: Schiff
Lippincott Philadelphia (1975). pp. 268-301.

46. RICHARDSON P.P.I., & WITHRINGTON P.G.

Liver Blood Flow I & II
Gastroenterology (1981):81:159-173(1)
& 365-375(11).

47. ROUSSELOT L.M., & BURCHELL A.R.
Portal Venography and Manometry in Diseases of the Liver, 4th Edition.
Editor: Shiff L.J.B.
Lippincott, Philadelphia (1975). pp.309-353.
48. RUZICKA F.F. Jr.
Percutaneous Splenoportovenography In Vascular Paentgenology.
Editors: Schobinger R.S. and Ruzicha F.F.
MacMillan, New York (1964). pp. 1359-88.
49. SHAH M.V.
Senior Lecturer Department of Medicine University of Nairobi (1986).
Personal Communication.
50. SHERLOCK S.
Progress Report: Portal Circulation and Portal Hypertension.
Gut (1978) 19: 70-83.
51. SHERLOCK S.
The Portal Venous System and Portal Hypertension
Diseases of the Liver and Biliary System
6th Edition.
Blackwell Scientific Publications (1981):
134-76.
- 51b. SILBER W.
Endoscopy and Portal Hypertension
Proceedings of the International Liver Conference with Special Reference to Africa.
Pitmans, London (1978) pp.286-7.

52. SORENSEN T.I.A.et al.

Sclerotherapy After First Variceal
Haemorrhage in Cirrhosis.

New England Journal of Medicine (1984)
311:25; 1594 - 1600.

53. TUMEN H.J.

Hypersplenism and Portal Hypertension.

Annals of New York Academy of Sciences
(1970) 170:p.332.

54. TERRY S.I.

Tropical Gastroenterology in Jamaica.

Tropical Doctor (1980) 10:147 - 151.

55. VIALLET A., MARLEAU D., HUET M., MARTIN F.,
FARLEY A., VILLENEUVE J.P., & LAVOIE P.

Haemodynamic Evaluation of Patients with
Intrahepatic Portal Hypertension.

Gastroenterology (1975) 69: 1297 - 1300.

56. VIAMONTE M., WARREN W.D., FOMON J.J.,
MARTINEZ L.O.

Angiographic Investigations in Portal Hypertension

Surgery Gynaecology and Obstetrics.
(1970) 130: pp 37 - 53.

57. VOORHEES A.B., PRICE J.B., & BRITTON R.C.

Portosystemic Shunting Procedures for
Portal Hypertension. Twenty Six Years
Experience in Adults with Cirrhosis of
the Liver.

American Journal of Surgery (1970) 119:501.

58. WALDRAM N., DAVIS M., NUNNEREY H.,
WILLIAMS R.
- Emergency Endoscopy after Gastro Intestinal
Haemorrhage in 50 Patients.
- British Medical Journal (1974) 4: 94- 98.
59. WARREN K.S.
- Hepatosplenic Schistosomiasis - A Greatly
Neglected Disease of the Liver.
- Gut (1978) 19: 572 - 577.
60. WARREN W.D., RESTREPO J.B., RESTESS J.C.,
& MULLER W.H.
- The Importance of Haemodynamic Studies in
the Managemnet of Portal Hypertension.
- Annals of Surgery (1963) 158:387
61. WARREN W.D., FOMON J.J., VIAMONTE M.,
& ZEPPA R.
- Pre-Operative Assessment of Portal Hypertension.
- Annals of Surgery (1967) 165: 999 - 1012
62. WESTABY D., GIMSON A.E.S., BIHARI D.,
CROSSLEY I.A., WILLIAMS R.
- Selective and Non Selective Beta Blockade
In The Reduction of Portal Hypertension.
- Gut (1982): 155 - 57.
63. WICKS A.C.B., THOMAS G.E., CLAN D.J.
- Comparison of Fibre Endoscopy in Acute
Upper Gastro-Intestinal Haemorrhage in
Africans.
- British Medical Journal (1975) 4:259-260.

64. WILLIAMS R. et al.

Portal Hypertension in Idiopathic Tropical
Splenomegaly.

Lancet (1966) : 1: 329.

ACKNOWLEDGEMENTS

I would like to thank Professor P.E.S. Palmer, Professor J. Kyambi, Dr. J.M.K. Kitonyi, Dr. S.B. Ojwang, Dr. M.V. Shah and Dr. J.K.N. Kariuki for their helpful advice and constant encouragement in the preparation of this dissertation and finally thanks to Edith D'Sa for the patience and care in typing it.