

**A 10-YEAR AUDIT OF THE CLINICAL FEATURES AND  
HISTOPATHOLOGIC SUBTYPES OF  
AMELOBLASTOMA AT A NAIROBI CENTRE**

**BY**

**DR. ADELIN L. VILEMBWA - DEPARTMENT OF ORAL  
AND MAXILLOFACIAL SURGERY - SCHOOL OF DENTAL  
SCIENCES, UNIVERSITY OF NAIROBI**

**A THESIS SUBMITTED IN ACCORDANCE WITH THE  
REQUIREMENTS FOR PARTIAL FULFILMENT FOR  
THE MASTERS DEGREE IN ORAL AND  
MAXILLOFACIAL SURGERY, SCHOOL OF DENTAL  
SCIENCES**

**UNIVERSITY OF NAIROBI**

UNIVERSITY OF NAIROBI  
MEDICAL LIBRARY

***AUGUST 2006***



# TABLE OF CONTENTS

## PAGE

Title.....	i
Table of contents.....	ii
Declaration.....	iv
Dedication.....	v
List of tables.....	vi
List of figures.....	vii
Acknowledgements.....	viii-ix
Abbreviations.....	x
Abstract .....	xi- xii

### CHAPTER 1:Introduction and Literature Review

1.1	Introduction.....	1
1.1.2	Proliferative studies of ameloblastoma.....	2
1.2	A review of the literature.....	3
1.2.1	A historical note and the geographical distribution of Ameloblastoma.....	”
1.2.2	Pathogenesis.....	”
1.2.3	Epidemiology .....	5
1.2.4	Age and Gender Distribution of ameloblastoma.....	6
1.2.5	Clinical presentation of ameloblastoma.....	7
1.2.6	Distribution by site of ameloblastoma.....	”
1.2.7	Radiological features.....	8
1.2.8	Histological classification.....	9
1.2.9	Aetiology.....	13
1.2.10	Treatment and prognosis.....	14
1.3	Research problem.....	16
1.4	Research justification.....	16
1.5	Objectives.....	17

### CHAPTER 2:Study Materials and Methods

2.1	Study site .....	18
2.2	Study design.....	”
2.2.1	Study type.....	”
2.2.2	Study population and sampling size.....	”
2.2.3	Data collection instruments and techniques.....	”
2.2.4	Variables.....	19
2.3	Ethical considerations.....	”
2.4	Data analysis .....	”

### CHAPTER 3:Results


Demographic characteristics		
3.1.	Age and gender distribution.....	21
3.2.	Symptoms at presentation .....	22

3.3.	Jaw site distribution of ameloblastoma .....	23
3.4	Radiological features .....	24
3.5.	Description of the histopathological features .....	25
3.6	Frequency of recurrence .....	33
<b>CHAPTER 4:Discussion .....</b>		<b>34</b>
	<b>References .....</b>	<b>41</b>
	<b>Appendices .....</b>	<b>47</b>

UNIVERSITY OF MEDICAL LIBRARY

## Declaration


I declare that this thesis is my original work and has not been presented for the award of a degree in any other University.

Signed  Date 15/11/06  
Dr. Vilembwa Adeline  
(Candidate)


## SUPERVISORS:

This thesis has been submitted with our approval as University Supervisors.


1. DR.J. F. ONYANGO, BDS, MSc, FDSRCS.  
SENIOR LECTURER,  
DEPARTMENT OF ORAL AND MAXILLOFACIAL SURGERY- ORAL  
PATHOLOGY AND ORAL MEDICINE  
SCHOOL OF DENTAL SCIENCES,  
UNIVERSITY OF NAIROBI,  
P. O BOX 19676, KNH 00200, NAIROBI.

Signature:  Date: 16/11/2006

2. DR. MARK L. CHINDIA, BDS, MSc, FFDRCSI.  
SENIOR LECTURER,  
DEPARTMENT OF ORAL AND MAXILLOFACIAL SURGERY - ORAL  
PATHOLOGY AND ORAL MEDICINE,  
SCHOOL OF DENTAL SCIENCES,  
UNIVERSITY OF NAIROBI,  
P.O BOX 19676, KNH 00200, NAIROBI.

Signature:  Date: 16/11/2006

3. DR. DAVID O. AWANGE, BDS, MMedSc.  
SENIOR LECTURER  
DEPARTMENT OF ORAL AND MAXILLOFACIAL SURGERY - ORAL  
PATHOLOGY AND ORAL MEDICINE  
SCHOOL OF DENTAL SCIENCES,  
UNIVERSITY OF NAIROBI  
P. O BOX 19676, KNH 00200, NAIROBI.

Signature:  Date: 16/11/06

## ***Dedication***

*This thesis is dedicated to my father Mr. Jairus Vilembwa and Mother Gladys Minage for the sacrifice they went through in educating me and prayerfully encouraging me through this period of study.*

*To my husband and children, without their help and understanding, I could not have accomplished my goal and to my mentors and teachers for providing the education and helping me through difficult times.*

## **List of Tables**

- Table 1.** Distribution of ameloblastoma according to age groups
- Table 2.** Site distribution of ameloblastoma in the mandible.
- Table 3.** Site distribution of ameloblastoma in the maxilla.
- Table 4.** Radiographic features according to gender.
- Table 5.** Radiographic features according to histological type of ameloblastoma.
- Table 6.** Frequency of histopathological types of ameloblastoma.
- Table 7.** Frequency of recurrence of the various subtypes of ameloblastoma lesions.

## List of figures

- Figure 1. Bar- chart showing symptoms at presentation of ameloblastoma.
- Figure 2. Histogram showing comparison of histological types between males and females.
- Figures 3(a). and 3(b). Photomicrographs showing histopathological section of the plexiform ameloblastoma. ( Haematoxylin and eosin stain; magnification x 100).
- Figure 4. Photomicrograph showing histopathology section of the desmoplastic subtype of ameloblastoma. ( Haematoxylin and eosin stain; magnification x100).
- Figure 5. Photomicrograph showing histopathology section of the follicular subtype of ameloblastoma. (Haematoxylin and eosin stain; magnification x100).
- Figure 6. Photomicrograph showing histopathology section of malignant ameloblastoma. (Haematoxylin and eosin stain; magnification x100).
- Figure 7. Photomicrograph showing histopathology section of the cystic ameloblastoma. (Haematoxylin and eosin stain; magnification x100).
- Figure 8. Photomicrograph showing histopathology section of the true cystic ameloblastoma. (Haematoxylin and eosin stain; magnification x100).
- Figure 9. Photomicrograph showing histopathology section of a mixed follicular and plexiform ameloblastoma with cystic degeneration. (Haematoxylin and eosin stain; magnification x100).
- Figure 10. Photomicrograph showing histopathology section of the unicystic ameloblastoma. (Haematoxylin and eosin stain; magnification x100).

## Acknowledgements

I would like to thank the **Director of Kenyatta National Hospital** and the University of Nairobi for their permission to conduct this study. I am greatly indebted to my supervisors **Dr. Fred Onyango, Dr. Mark Chindia** and **Dr. David Awange** for their stimulation, guidance and encouragement that have been most instrumental for the completion of this study.

I am also grateful to Kenyatta National Hospital for providing the financial support and for granting me study leave and providing access to the patient's files used in this study.

Many thanks to the staff at the University of Nairobi, Oral Pathology and Oral Medicine laboratory for providing the histopathology reports and specimens used for this study.

**Dr. Elizabeth Dimba** and **Dr. Kevin Wakoli** of the Oral Pathology and Oral Medicine Division school of Dental Sciences for their helpful discussions, encouragement and constructive comments and their willingness to share their knowledge on ameloblastoma; and their interest in my research. My special regards also go to **Dr. Antony Njiru** (KNH – Department of Oral Pathology) for his helpful suggestions and reviews of this write – up.

To **Alice Lakati** of Medical Training Centre for guiding the statistical analysis. Special thanks to **Serah Mzenge** of the School of Dental Sciences for retrieving the patients records used in this study. My regards also go to **Edgar Odari, Cecilia Wanjala** (of University of Nairobi, Medical School Library), **Anderson Nyongesa** and **Isaiah Masibo** for their secretarial services during the writing of this thesis. Special regards to **Alice Ruto** and **Josiah Otwoma** of the Division of Oral Pathology and Oral medicine for



their assistance in ensuring I got the histopathological reports and for retrieving the slides for the photomicrographs and for allowing me to use the laboratory during the time of this study.

Lastly, my appreciation to **Dr. Meshack Ong'uti**, PhD, for providing scientific research material that formed an invaluable resource material and basis for this study.

## List of Abbreviations

- AOT** - Adenomatoid Odontogenic tumour
- CT Scan** - Computed Tomography Scan
- EGFR** - Epidermal Growth factors receptor
- KNH** - Kenyatta National Hospital
- Mabs** - Monoclonal antibodies
- PCNA** - Proliferating cell nuclear antigen
- UNDH** - University of Nairobi Dental Hospital
- WHO** - World Health Organization

# ABSTRACT

**Background:** The pattern of ameloblastoma in Africans has shown a marked difference from that of non -African populations. Previous studies on ameloblastoma in the Kenyan population have been inconclusive and with the availability of more data over the years, a clinicopathological re-evaluation of any feature that can provide further insight on ameloblastomas in the general Kenyan population based on histopathological subtypes were highly desirable. This report presents a clinicopathological analysis of 184 cases of ameloblastoma reported in Nairobi, Kenya.

**Objective:** To describe the clinicopathologic pattern of ameloblastoma in Kenyans.

**Study Site:** University of Nairobi Dental Hospital, division of Oral Pathology and Oral Medicine .

**Study Design:** A descriptive audit including all patient records with a histopathologically confirmed report of ameloblastoma based on the routine Haematoxylin and Eosin staining during the period of January 1995 and December 2005. Data with respect to the patient's ages, gender, tumour location, duration and presenting symptoms as well as the radiographic findings and histopathological subtypes of the ameloblastoma were analysed.

**RESULTS:** A total of 184 patient records were included in this study among whom 82 (44.6%) were male and 102 (55.4%) were female with an overall age range of 10 – 80 years (mean = 30.2 ,  $SD\pm 14.1$ ). Among the male cases the age range was 10 to 80 years (mean = 29.9 years) while among the female cases it was 11 to 73years (mean = 30.5years). At presentation, the duration of the lesions ranged from 1 month to 20 years with the mean among males having been 46.3months while it was 44.4months

among female cases. Regarding the location of the lesions; 172 (93.5%) were found in the mandible, 11(6.0%) in the maxilla and 1(0.5%) in the soft tissues.

The posterior mandible was the most commonly affected site while the anterior portion was the most commonly affected site in the maxilla. Swelling was the most commonly reported symptom in 182(98.9%) of the cases. Pain was a symptom in 64(36.0%) of the cases, while mobile teeth or a history of dental extraction was recorded in 104(57.5%) of the cases. Purulent discharge was reported by 39(21.7%) of the cases while paraesthesia was reported in 10(5.6%) of them. The distribution of the histopathological subtypes of ameloblastoma revealed that 133(88.7%) were of the solid type while the unicystic group were 8(6%). Malignant lesions accounted for 9 cases (6.0% of the total). Five cases of ameloblastoma had developed in a cyst lining and one co-existed with a calcifying odontogenic cyst. Cystic ameloblastoma was a group commonly reported by the pathologist and accounted for 34(18.5%) of the lesions. Twenty eight (15.2%) of the ameloblastoma were observed to have recurred. Radiographically, the multilocular appearance of the lesion was the most recorded picture and accounted for 127 out of the 184(69.4%) of the lesions while unilocularity was present in 56 (30.60%) of the lesions.

### **Conclusion:**

This study showed that there was no significant difference in gender presentation of ameloblastoma, though females presented at a slightly older age. The mean age of presentation was a decade younger (29.9 years) with 59.2% of the cases presented below 30 years of age. Site presentation of ameloblastoma in this study concurs with other studies. There was, however, a diversity in the histopathological subtypes in the benign and malignant ameloblastomas observed in this study calling for a need to standardize the use of nomenclature so that comparison of different results may be prudent.

## CHAPTER 1

### 1.1 . Introduction

The ameloblastoma is a persistent tumour that slowly increases in size over many years but with some aggressive features in its pattern of growth. The World Health Organization (WHO) monograph on histological classification of odontogenic tumours defines ameloblastoma as a benign locally invasive polymorphic neoplasm consisting of proliferating odontogenic epithelium which usually has a follicular or plexiform pattern lying in a fibrous stroma.<sup>1</sup> While the main histological patterns, the follicular or plexiform types may predominate in an individual case, infrequently both patterns are present. Most authors divide ameloblastoma into solid, unicystic or malignant variants based on histological classification. The relative frequency of occurrence of ameloblastoma has been reported to be 11% of all odontogenic tumours and 1% of all oral tumours.<sup>2</sup> The tumour may occur more frequently in black Africans than in any other racial groups.<sup>3,4</sup> The size of the tumour at presentation varies considerably and the gross morphology can be solid, cystic or both. The rate of growth varies and malignant transformation rates of 2%-4.5% have been reported.<sup>5,6</sup>

The patterns of biological behaviour and hence agreement as to appropriate treatment of ameloblastoma remain controversial.<sup>7,8</sup> There is little evidence to show that histological and/or clinical features have any significant bearing on behaviour and prognosis<sup>1</sup> and no systematic study has been done to evaluate the biological behaviour of the ameloblastoma. Retrospective studies based on clinical presentation have attempted to correlate the morphological features with aggressive behaviour or the potential for recurrence without success.<sup>7,9</sup> Ueno et al. (1986), however, showed that follicular lesions showed a multilocular radiographic appearance.<sup>10</sup>

A pathological re-evaluation of any features which may indicate aggressiveness is thus necessary for optimal management of patients with ameloblastoma. Successful prediction of clinical outcome continues to be unsatisfyingly low, so that any additional

prognostic information which could be combined with the clinicopathological features and help identify ameloblastoma with the biological potential for aggressive behaviour is highly needed. Use of immunohistochemical techniques using monoclonal antibodies (Mabs) has been applied to gain insight into the behaviour of a number of neoplasms. These methods have not been applied extensively to ameloblastoma.

### **1.1.2. Proliferative studies of ameloblastoma**

One of the most important characteristics of aggressiveness in a tumour is its rate of growth. The estimation of proliferative activity is considered a major approach to the determination of aggressiveness, tumour progression and for the metastatic potential of neoplasms.<sup>11</sup> Some immunochemical probes used in the verification of ameloblastoma have concluded that histological patterns or cytological patterns, related to the proliferating activity of ameloblastoma use of antiproliferating cell nuclear antigen (PCNA) and anti-Ki-67 antibodies have been found to be good indicators in assessing the proliferating activity of each type of ameloblastoma. These studies have shown that solid ameloblastoma in relation to clinical appearance have the highest labelling index for PCNA and Ki-67 followed by the mixed type.<sup>12, 13, 14</sup> Onguti et al.<sup>15</sup> reported that follicular ameloblastoma had a higher PCNA and Ki-67 labelling indices than plexiform ameloblastoma while Kim and Yook (1994)<sup>16</sup> reported that the PCNA labelling index of the plexiform ameloblastoma was higher than the follicular ameloblastoma. This suggests that PCNA and Ki-67 labelling can be used as proliferating markers for ameloblastoma.

Recent studies by Vered et al. (2003) to investigate the presence of Epidermal growth Factor receptor (EGFR) in ameloblastoma have shown that all ameloblastomas are EGFR-Positive.<sup>17</sup> This has been complemented by other studies.<sup>18</sup> The extensive presence of EGFR demonstrated by ameloblastomas can be candidates for anti-EGFR in the locally aggressive tumour. There is, however, no evidence to date that a locally aggressive tumour can be a candidate for the anti-EGFR treatment especially for the large infiltrative tumours or recurrences. Ameloblastomas can thus be included in the EGFR - positive tumours that can benefit from these agents to reduce the size of large tumours

and to treat unresectable tumours that are in close proximity to vital structures.<sup>17</sup> Cell proliferation can also be evaluated by counter- staining with silver stains and correlating the silver-stained nuclear organizer regions. This has shown a good correlation between the number of such regions per nucleus and the proliferative capacity of tumours by use of silver stains.<sup>19</sup>

## **1.2 A Review of the literature**

### **1.2.1 Historical note and the geographical distribution of ameloblastoma**

Carsock (1827) was the first to give an original description of ameloblastoma while Broca in 1868 produced the first report in scientific literature. Falkson in 1879 gave the first complete histological description of the term 'adamantinoma'. The term ameloblastoma was suggested by Ivy and Churchill in 1934 because the old term 'Adamantinoma' coined by Falkson and later Malassez (1885) erroneously implied the formation of hard tissue. Since the enamel organ type in ameloblastoma does not undergo differentiation to the point of malformation; hard tissue is not present in the tumour mass. Willis (1948) suggested that the term "ameloblastoma" as well as its predecessor "adamantinoma" were misnomers as the tumour did not develop from ameloblasts, nor did it form enamel, and postulated that "it would be better to call them carcinomas of the tooth-germ residues", re-affirming his opinion of the malignancy of the neoplasm. For this reason it is necessary to study each evolutionary step of odontogenesis to try and associate the observed histological details common in ameloblastoma, in order to detect eventual space-time errors capable of impairing the elaboration of dental tissues in a neoplasm which theoretically is composed of forming cells of this tissue .<sup>20</sup>

### **1.2.2 Pathogenesis**

Slavkin (1988) suggested the existence of chemical mediators produced by the cells; autocrine factors, elaborated by the cells at a determined time of development which at the actual cell to modify its behaviour from then on. These autocrine factors in the specific case of odontogenesis act at the time of proliferation of the cells of the basal layer orienting them to form the dental lamina and the dental buds. The paracrine factors are formed by some cells and are liberated into tissue space, acting on neighbouring cells by altering their behaviour and not the behaviour of the secreting cells. Paracrine factors are responsible for mesenchyme condensation near the epithelial tissue in proliferation. Why these environmental factors are different in ameloblastomas is not known<sup>21</sup> Ameloblastoma is thus justly considered to be one of the most unexplained odontogenic tumours because of its clinical and histological features. Clinical feature presentation



even when combined with radiological findings and histopathological types cannot determine the biological behaviour and, therefore, the prognosis of an individual ameloblastoma.

### 1.2.3 Epidemiology

The incidence and prevalence figures for ameloblastoma are somewhat unreliable but a marked difference in the frequency of occurrence of the tumour between major population groups has been recorded.<sup>22,23,24</sup> Studies by Reichart et al. (1995) found that Asians developed ameloblastoma more often than Caucasians and the disease was more frequent in black ethnic groups than in any others. The South African incidence has been reported to be approximately 5.6 new cases of ameloblastoma per million inhabitants per year.<sup>2</sup> European countries have reported an incidence of 0.6 new cases per million inhabitants per year while the incidence in many south East Asia countries is not known with precision.<sup>22</sup> The need for prospective studies to establish the actual incidence in definitive ethnic groups is thus highly desirable.

The reported relative frequency of ameloblastoma out of all odontogenic tumours ranges from 11% to 13%. Chidzonga et al. (1996) reported a relative frequency of 78% while Odukoye et al. (1995) and Mosadamii (1969) reported relative frequencies of 58.5% and 65.5% respectively in Zimbabwe and Nigeria.<sup>23,24,25</sup> Chinese studies by Lu et al.(1998) and Wu and Chan (1985) found relative frequencies of ameloblastoma of 58.6% and 45% respectively.<sup>26,27</sup> In a Kenyan study by Onyango et al. (1995), the relative frequency of ameloblastoma was found to be 78.2% of all odontogenic tumours.<sup>28</sup> In Turkey, the frequency of ameloblastoma was slightly lower than in the African and Asian studies although it still ranked highest among odontogenic tumours with a relative frequency of 36.2%<sup>29</sup>. These figures differ from European and American studies which reported relative frequencies of between 10% and 23.7%, second to odontoma which was the most common odontogenic tumour.<sup>30,31</sup> These figures apparently indicate that the relative frequencies of ameloblastoma as found in Africa and Asia are the highest. Sawyer et al.(1985) proposed a racial predilection, though this has been disputed by other authors who have attributed this higher relative frequency in Africans to a “harvesting effect”.

<sup>32,33</sup> A few studies on relative frequency and incidence rate are available <sup>34,35,36</sup> although the epidemiologic terms used made it difficult to extract reliable figures for comparison. There is no proven racial preference though there appears to be a validation in the site commonly affected in different races and there is no significant geographic variation noted.

#### **1.2.4 Age and gender distribution of ameloblastoma**

Ameloblastoma manifests in patients mostly between 20 and 50 years with a peak in the 4<sup>th</sup> and 5<sup>th</sup> decades of life. Cases of ameloblastoma in children under one year have been reported. Only 1.8% of the patients were younger than 10 years in a review by Reichart et al. (1995). It was reported that the median age was 35.9 years while the average age at first diagnosis from developed countries was 39.1 years compared to 27.7 years in patients from developing countries. In African races, the ameloblastoma has been observed to occur in much younger age groups than Caucasians (mean age 25.5 and 38.9 years) respectively <sup>3,35,36</sup> Overall on the basis of age distribution, it appears Africans tend to get ameloblastoma at a younger age and further investigation into the possible cause is needed .

There seems to be no definite gender predilection with ameloblastoma in most reported series; although there was a significant age difference at first diagnosis between women (35.2 years) and men (39.2 years) reported by Reichart et al. (1995). The age difference at first diagnosis is explained by the assumption that women seek medical help earlier than men. This belief is, however, disputed by Reichart et al.(1995) who showed that females sought medical advice 9 months later than men. The difference in the pattern of bone trabeculae between the genders has also been attributed to the observed differences. <sup>15,16</sup> Another speculation is that the presence of the tumour in the smaller jaws of women may mean that the tumours are symptomatic earlier than in men, but other factors such as the hormonal influence acting locally and the environment could also be contributory factors. <sup>33,34</sup>

### **1.2.5 Clinical presentation of Ameloblastoma**

Clinically, ameloblastomas originate intra-osseously with minimal or no symptoms and are, therefore, seldom diagnosed early. The ameloblastoma presents as a slow growing and painless mass that may reach a considerable size with swelling being the primary symptom in a majority of patients. Late symptoms include pain due to superinfection, regional paraesthesia in exceptional cases, toothache, tooth mobility and superficial ulceration of the oral mucosa. Intra-oral bleeding, a tooth extraction site that fails to heal and rapid growth of a lump in the jaw have also been reported. In the more uncommon maxillary lesions, invasion of the maxilla, cheek swelling or epistaxis have been reported as presenting symptoms.<sup>37</sup>

The average duration of symptoms is thought to be 2.3 years. In Caucasians, the duration until the first diagnosis was found to be 1.8 years, 2.4 years in blacks and 3.1 years in Asians<sup>2,37</sup> The duration of symptoms in a Tanzanian study ranged from one year to more than fifteen years in some cases.<sup>38</sup> In a Kenyan study, the duration of symptoms was reported as 3 months to 7 years with a mean of 2.2 years.<sup>28</sup> In developing countries, patients seek medical treatment as long as 5 years after the first symptoms. Several reasons have been attributed for the delay in attending hospital and the patients will only present to hospital when the symptoms cause functional disability. Presence of readily available dental services in America and Western European countries, where routine oral diagnosis is a basic requirement, lead to the early detection of jaw tumours.

### **1.2.6 Distribution by Site**

Tumour site at presentation varies and can be intra-osseous or peripheral. The average size of tumours in patients from developing countries is larger than in those from industrialised countries.<sup>2,32,33,35</sup> Adekeye (1980) reported the presence of massive tumours from developing countries, considering that patients from developing countries have massive tumours at a much younger age than those from industrialized countries.<sup>35</sup> The possibility of environmental factors such as malnutrition as aetiological factors or factors intrinsic to the tumour may each play a role in the differences in growth characteristics between populations.<sup>2,15,16</sup> It is argued that because of inadequate

accessibility to health facilities in developing countries, the tumour is not diagnosed early. In spite of the reasons, the biological behaviour of tumours in patients from developing countries appears to be different and the need for a prospective study to determine the differences is indicated. A review by Reichart et al. (1995) of 3677 cases showed that the ratio between maxillary and mandibular ameloblastomas was 1:5.4 and of the later 70% were in the molar-ramus, 20% in the premolar, and 10% in the symphyseal area. A report from the case reports in the same study between the maxillary and mandibular tumours was 1:2.2. This difference was thought to have been due to the fact that the maxillary tumours were more often reported because this was a more uncommon site. Maxillary tumours occur most commonly in the molar and premolar areas. Other studies concur with the western studies.<sup>10,27,37</sup>

Greater involvement of the anterior mandible in parts of western and central Africa has been cited by various authors contrasting the fact that the mandibular molar region is the most affected site.<sup>39,40,41</sup> Reichart et al.(1995) also indicated that the anterior region of the mandible is significantly more frequently affected in blacks than Caucasians and Asians. Of interest is the fact that lesions affecting both sides of the jaw are more common in blacks than Caucasians and Asians, presumably because midline lesions affected both sides. Tumours in blacks at presentation were massive and involving more than one anatomical site so that the precise area of origin, whether posteriorly or anteriorly was difficult to define. In a Tanzanian study 9.7% of the ameloblastomas were located in the maxilla and 90.3% in the mandible.<sup>38</sup>

### **1.2.7 Radiological features**

The radiological pattern of ameloblastomas is thought to vary according to the stage of development of the tumour<sup>15</sup>. Incidental findings of radiolucent lesions on radiographs may often be the first sign of the disease. Radiologically, the tumour may be present as a unilocular or multilocular radiolucency. Reichart et al. (1995) indicated 51% as having unilocular appearance and 49% had a multilocular appearance. Reichart also pointed out that a multilocular appearance seen on radiographs could histologically be that of the unicystic ameloblastoma hence the terms unilocular and multilocular (rather than uni- and multicystic) should be used to describe the radiological appearance. The unilocular

variety has well defined borders with no apparent periosteal bone reaction and when associated with a tooth, the tooth tends to be encased in the tumour. Ueno et al.(1986) in a series of 104 patients from Japan found that the unilocular ameloblastomas tended to be more prevalent in the younger individuals than those with the multilocular appearance. Of significance is the Nigerian study by Akinosi and Williams (1955) who described many of the lesions as having been monocystic. Unicystic ameloblastomas are reported to be more prevalent among children in western countries than in African children, a difference that was thought to reflect ethnic and geographic differences.<sup>32</sup> The unicystic ameloblastoma was not found in the Tanzanian study by Simon et al. (2002) raising the possibility that they could have been diagnosed and treated as odontogenic cysts on the basis of clinical and radiological findings.<sup>38</sup> Maxillary ameloblastomas rarely show multilocularity making a radiological diagnosis of maxillary ameloblastoma against the appearance of the antrum quite difficult but these lesions are also quite few, hence it is difficult to ascertain these findings.<sup>37,42</sup> Previous surgery in the maxilla due to reported cases of recurrences of maxillary tumours may distort the radiological appearance.

Use of Computed Tomography Scans (CT Scans) have been useful in delineating the extent of the ameloblastoma and identifying the spread in both bone and soft tissues though there is no good evidence that their use has improved clinical outcome. The CT scan has, however, been useful in providing excellent anatomic details and in demonstrating the curvature of the buccal and lingual surfaces which are not easily seen on conventional radiographs.

### **1.2.8 Histological Classification of Ameloblastoma**

So far the histological classification most widely accepted separates ameloblastomas into unicystic, multicystic, and malignant subtypes. The unicystic type of ameloblastoma consists of a tumour well contained within the layers of a fibrous cyst wall. This is important in that this type of ameloblastoma remains well contained within the cyst wall and complete removal can be achieved with local excisions. It has a recurrence rate of 6.7 – 35.7% after conservative management pattern. The multicystic ameloblastoma has a behaviour pattern that allows growth to an enormous size typically invading into adjacent

tissues. The infiltrative growth has been noted to occur between spaces in the cancellous bone by erosion rather than by invasion of any cortical bone.

The peripheral type of ameloblastoma appears to arise directly from the surface epithelium or from residues of the dental lamina outside bone. This variant is rare, and accounts for 1-5% of ameloblastomas. Malignant variants of ameloblastoma have been reported with unusual mitotic activity together with pleomorphism of the neoplastic cells and their nuclei, justifying the diagnosis of malignancy. The common subtypes of malignant ameloblastoma are divided into malignant ameloblastoma and ameloblastic carcinoma. This variant of ameloblastoma is also rare and accounts for 2%- 4.5%.<sup>29,33</sup> The histological classification of ameloblastoma has undergone many changes so that any comparison of retrospective studies is difficult.

The WHO histological typing of odontogenic tumours based on the conventional histological techniques is the most commonly used for standardization. Classic microscopic appearance of ameloblastoma is one of epithelial strands, nests of cords composed of a peripheral palisading rim of columnar or cuboidal cells with reticular or acanthomatous areas. The most dominant histopathological types are follicular and plexiform patterns. The follicular form is highly cellular with varying amounts of connective tissue stroma and closely resembles the enamel organ with a central area of loosely arranged cells resembling the inner enamel epithelium. The columnar cells show palisading with nuclei polarized away from the basement membrane, while the plexiform type of tumour has its columnar cells arranged in cords and strands between islands of fibrous tissue and the stellate reticulum like cells are sparse. The two variants may also appear together in the same tumour. There is no reported correlation between the histopathological type and the clinical nature of the lesion to date.<sup>1,2</sup> The histological classification of ameloblastoma can thus be based on:

- a) Tumour morphology with the main variants being unicystic ameloblastoma, multicystic (solid) ameloblastoma or malignant variants.
- b) Histomorphology based on cellular morphology or cellular pattern include six main variants which are reported as follicular ameloblastoma, plexiform ameloblastoma, acanthomatous ameloblastoma, granular cell ameloblastoma,

basal cell ameloblastoma and desmoplastic ameloblastoma all found mainly in the multicystic or the solid ameloblastoma.

***Histomorphology of subtypes:***

- ***Acanthomatous ameloblastoma***

This shows follicular tumour islands with squamous metaplasia and/or keratin production. This is most often seen in the follicular ameloblastoma.

- ***Basaloid ameloblastoma***

Shows discrete small islands interconnected by narrow cords of cells, no well-developed stellate-type centres and the cuboidal cells lack the reverse nuclear polarity of subnuclear vacuoles.

- ***Desmoplastic ameloblastoma***

This has greater amounts of stroma, the epithelium is arranged in narrow, compressed cords occasionally rounding up into islands. With a centre that has a compact spindled appearance. Reverse polarity of columnar cells are uncommon.

- ***Granular cell ameloblastoma***

The cells are large with a granular pink cytoplasm in the centres of the tumour islands, usually of the basic follicular type, and it is very eosinophilic in nature. It is documented to be very aggressive in nature with a high recurrence rate. Several cases have been reported that have metastasized.

***Unicystic ameloblastoma***

- This consists of a cyst lined by ameloblastic epithelium with a tall columnar basal layer, subnuclear vacuoles, reverse nuclear polarity and a thin layer of oedematous degenerate appearing stellate cells. This variant of ameloblastoma has not been reported in the maxilla and is most common in the molar-ramus region of the mandible. This has further been sub-classified into three groups;

- Group 1- Unilocular cystic lesions with ameloblastomatous epithelium of columnar basal cells and hyperchromatic nuclei, nuclear palisading with polarization interlacing spaces between the cytoplasmic vacuoles.
- Group 2- The mural type – a nodule projects into the lumen of a cyst and on examination the nodule exhibits a plexiform pattern.
- Group 3- So called extra-mural type where part of the wall of the cyst is infiltrated by the typical plexiform or follicular ameloblastoma. This variant behaves like the solid ameloblastomas and should be treated as such.

The unicystic ameloblastomas are more prevalent among the younger age group and are reported to occur a decade earlier<sup>41,42,43,44</sup> and is also usually associated with the mandibular third molar.

#### **Adenomatoid ameloblastoma**

This type is less frequent and has histological features of both ameloblastoma and adenomatoid odontogenic tumour (AOT) including calcified tissue but it has great potential for extension and recurrence.<sup>45</sup> The presence of ameloblastoma arising concurrently with a calcifying odontogenic tumour has been observed and reported.<sup>46</sup>

#### **Malignant ameloblastomas**

The WHO classification refers to malignant ameloblastoma as a neoplasm in which typical histological features of ameloblastoma are seen in the primary tumour located in the jaw as well as in any associated metastatic deposits in the lymphnodes or lungs. According to Slootweg et al.(1984) the term ameloblastic carcinoma is used to denote the presence of cytological evidence of malignancy in the primary, recurrent or metastatic tumour regardless of whether or not there is metastasis. The term malignant ameloblastoma has meanwhile been reserved for those lesions which despite their apparent histological innocuousness, have given rise to metastasis with the same degree of benignity as the primary lesions.<sup>47</sup> The incidence of ameloblastic carcinoma is greater than that of malignant ameloblastoma by a 2:1 ratio.<sup>33</sup> Two types of typical ameloblastoma considered as a differential diagnosis of ameloblastic carcinoma are the



acanthomatous ameloblastoma, which exhibits varying degrees of squamous metaplasia and even keratinisation of the stellate reticulum portion of the tumour islands, though the peripheral pallisading is maintained and no cytologic features of malignancy are found. The kerato-ameloblastoma is a rare variant of ameloblastoma with prominent keratinizing cysts that may cause some alarm and distract the pathologist from the otherwise ameloblastomatous feature.<sup>48</sup> A squamous cell carcinoma arising in the lining of an odontogenic cyst is an additional consideration in the differential diagnosis.<sup>49</sup> The term ameloblastic carcinoma can be applied to include focal evidence of malignant disease including cytologic atypia and mitoses with undisputable features of classic ameloblastoma. It is, however, not usually easy to differentiate clearly between ameloblastic carcinoma and malignant ameloblastoma. These lesions should thus form a basis for a future prospective study so that they are accurately identified, differentiated from each other and followed-up so that their natural history and prognosis can be further defined. Cases of ameloblastoma should thus be studied carefully, correlating their histologic pattern with biologic behaviour to detect subtle changes in histology that may predict aggressive behaviour.

### 1.2.9 Aetiology

The aetiology of ameloblastoma remains obscure. A number of possible causal factors have been implicated including:

- a) Irritation mainly in the posterior mandible in association with difficulty of eruption of the third molar.
- b) Previous oral injection associated with the extraction of teeth or injury to the teeth or jaws were causes in a third of cases in a survey by Robinson (1937).<sup>34</sup>
- c) Trauma or infections have been considered to have a significant role.<sup>50</sup>
- d) Nutritional deficiencies such as rickets have been considered though this has not been proved in experimental animals on a rachitogenic diet.<sup>51</sup>
- e) Systematic administration of carcinogens especially N-methyl-N-nitrosurea solution has been shown to cause proliferation of ameloblastoma in animals indicating that carcinogens may be a causal factor.<sup>52</sup>
- f) Viral pathogenesis has been indicated by Stanley et al. (1964), Main and Dave (1966) in animal experiments. They found neoplastic growths thought to be

counterparts of ameloblastoma by injection of the polyoma virus.<sup>53</sup>

- g) Development of ameloblastoma from the dental follicle surrounding the third molar has been reported.<sup>54</sup>
- h). Ameloblastoma arising from odontogenic cysts also forms a plausible theory with Khan (1989) generally credited with the profound theory that ameloblastoma arises in a dentigerous cyst.<sup>43</sup>
- i). Ameloblastoma has not been reported in families so that a genetic basis is a remote possibility. Therefore, for an individual case, a clear aetiological factor is rarely identified.

### **1.2.10 Treatment and Prognosis**

To date, there is no established rationale for the different therapeutic approaches by various surgeons such that the treatment modalities have varied greatly from simple enucleation and radical resection to the combination therapy of surgery, radiotherapy and chemotherapy. Surgery is still, however, the mainstay of treatment although recurrences are reported even after satisfactory primary surgical treatment unless the histopathology is suggestive of malignancy. Clinical features may also fail to provide an adequate indication of aggressive behaviour. From the literature reviews, the decision on a protocol for treatment may depend on a number of factors including size, location of the tumour, clinical appearance, growth rate, neighbouring structures, histology, clinical presentation of recurrence, general condition and age of the patient. Maxillary tumours according to location are more difficult to treat and are considered more aggressive than their mandibular counterparts although they are indistinguishable histopathologically.

The maxillary bone is thin and its proximity to vital structures usually allows uncontrolled spread of these tumours and may spread unimpeded to the maxillary sinus, orbital floor and base of the skull. The mandibular tumours in contrast, especially those in the anterior region are contained because of the thick cortical plates. Posterior mandibular tumours behave like the maxillary tumours because of the spongy nature of the bone which facilitates spread while conservative therapy can have residual tumour resulting in multiple recurrences. The age of the patient also influences the choice of therapy. Children under the age of 10 years may not be considered for radical surgery due to the

potential of interfering with the jaw and also reconstruction becomes a major challenge. Patients of advanced age, considering the life expectancy and time span of developing recurrences may not necessarily undergo satisfactory primary surgical treatment thus requiring that other forms of adjunct therapy for multiple recurrences be implemented.

**Prognosis:** Ameloblastoma remains a tenacious tumour with a high rate of recurrence if inadequately treated. The prognosis of ameloblastoma has been analysed with regard to age, location, histological variants, radiological features and mode of treatment. However, as yet, no clear determinant has emerged. The radiological appearance of ameloblastoma also influences the therapeutic approach. Ueno et al. (1989) reviewed a series of 91 mandibular ameloblastoma categorized as unilocular or multilocular and reported 35% of patients (14 out of 30) developed a recurrence with conservative treatment whereas 61% of patients with multilocular (17 of 28) developed recurrence after undergoing conservative treatment. Of the remaining 23 patients who had had radical surgery only 2(9%) experienced a recurrence. Ueno et al. (1986) in an earlier study also found a high incidence of tumour recurrence with the honeycomb or soap bubble appearance. Whether these radiological features could suggest an aggressive phenotype is not known.

The histological appearance of the recurrent tumour is said to be indistinguishable from that of the original tumour though its behaviour is reported to be more aggressive. Ueno et al. (1986) links the follicular type of tumour to an increased recurrence. The most common cause of recurrence of ameloblastoma as reported by Sartiano and Schreiner (1975) was inadequate resection of tumour followed by inadequate excision of the diseased periosteum, muscle or oral mucosa as well as leaving residual tumour fragments in the wound. The period of recurrence was reported to have been shorter at 4.9 years after conservative surgery when compared to 11.1 years when radical surgery was done.<sup>7,8,9</sup> Local recurrences may occur in patients who have undergone primary surgical treatment so that other forms of adjunct therapy for multiple recurrences have been recommended. The use of cryotherapy and radiotherapy has been used.<sup>55</sup> Orthovoltage has been used in patients with originally massive tumours but had

recurrences after initial radical surgery. The use of a high voltage source of radiotherapy has shown good post-treatment results.<sup>56</sup> The use of radiotherapy only for inoperable cases has been suggested by Gardner (1988)<sup>55</sup> although previous reports by Ueda and Kaneda (1991) concluded that previous cases of radio-resistance of ameloblastoma earlier on was due to less sufficient radiation therapy.<sup>56</sup> Radiosensitivity of the tumour has been confirmed by use of megavoltage radiotherapy and hence postulations that radiotherapy in conjunction with surgery may have a place in the management of selected patients.<sup>57</sup> Chemotherapy has been used in patients with recurrent tumours .<sup>56</sup> The difference in response to various treatment modalities may be due to the variation of the proliferative activity within and between different tumours. Clearly identifying indicators in ameloblastoma to predict tumour biology may indicate the use of combination therapy to treat ameloblastoma.

### **1.3 RESEARCH PROBLEM**

Clinicopathological features of ameloblastoma among African populations in general and Kenyans in particular is not well documented. An earlier study of clinicopathological features had indicated some peculiar characteristics, however, the study was inconclusive. Additional data has since become more available which will help define the features more clearly. This study supplements studies executed in other African countries and compares with other studies from western countries.

### **1.4 JUSTIFICATION**

One of the objectives of a pathological classification is to try and predict biological behaviour when studying tumours but this has proved impossible with ameloblastoma since the presence of atypia, mitotic activity, tumour type, degree of differentiation and cellular diversity are rarely found in the mainly benign ameloblastoma and are thus of little significance in predicting biological behaviour. The need to have all patient bio-data studied would help in patients management, patients assessment, recall purposes such as in transportation and the need for computer links to local hospitals is highly desirable in order to assess a potential correlation between recurrence and histopathological pattern of the tumour as most patients are lost to follow- up after a few reviews post-operatively.

The recurrence rate of ameloblastoma is quite prolonged so that follow- up should be indefinite. This study would advance our understanding of this ubiquitous but controversial tumour.

## **1.5 OBJECTIVES**

### **Main Objective**

To describe the clinico-pathologic features of ameloblastoma occurring among a Kenyan population.

### **Specific objectives**

1. To describe clinical features of ameloblastoma occurring in patients managed at the UNDH.
2. To determine any differences in the distribution of clinical and pathological characteristics of ameloblastoma by age, gender and sight.
3. To describe the pattern of histopathological subtypes of ameloblastoma

## CHAPTER 2

### STUDY MATERIALS AND METHOD

#### 2.1 STUDY SITE

##### **University of Nairobi School of Dental Sciences (UNDH):**

This is the main teaching dental hospital which is about 3.5 kilometres from the city centre.

#### 2.2 Study design

**2.2.1 Study type:** This was a descriptive retrospective study.

##### **2.2.2 Study population and sample size**

All patient records with histopathologically confirmed reports of ameloblastoma diagnosed at the oral pathology and oral medicine laboratory of the UNDH using the routine Haematoxylin and Eosin staining were retrieved. The study reviewed all biopsy records reported from January 1995 to December 2005 which included all age groups. Review of records indicated that approximately 20 patients with a histopathological diagnosis of ameloblastoma were seen per year and, therefore, over a 10-year period it was estimated that 240 patients would be found. The actual study sample was 184 cases. A total of 196 records were traced among which 184 were complete so that in the ten-year period, 93.9% of the records were available.

##### **2.2.3 Data collection instruments and techniques**

A specially designed data collection chart (Appendix 2) was used by the investigator to record the study information. The patients' files were retrieved according to the inpatient or outpatient hospital registration and the patients demographic information obtained, the clinicopathological presentation in terms of the duration of the lesions, associated symptoms and the site of the tumour. The investigator then examined all the radiographs of each study case and the information entered in the data collection form.

##### **2.2.4 Variables**

- Patients' clinical features were recorded to include the patient's age (in years), gender, duration of symptoms (in months), subtype of ameloblastoma as histopathologically reported and; the presenting symptoms.
- Radiologic records (for those available) and the following data quantified; site of the lesion, cortical expansion and cortical plate integrity, unilocularity or multilocularity and root resorption. Dependent variables recorded included solid ameloblastoma, malignant ameloblastoma or unicystic ameloblastoma and the site of the lesion.

### **2.3 Ethical considerations**

Approval was obtained from the Kenyatta National Hospital and the University of Nairobi Ethics, Research and Standards Committee (Appendix 1) and a copy given to the UNDH central records registry to facilitate perusal of patients' files in strict confidentiality within the records department. All patients' records were reviewed in strict confidentiality within the institutions and promptly returned to the records clerks for filing to prevent their loss.

### **2.4 Data Analysis**

- Data were analysed using the statistical package for social science (SPSS version 12.0) for windows.
- Data cleaning was done by running frequencies and all missing data counter-checked and corrected where necessary from the original form to improve the validity of the results.
- Descriptive analysis was carried out to determine the relative frequency of ameloblastoma reported in the 10 years and also clinical and pathological characteristics of ameloblastoma by sample tallying.
- Inferential statistics and independent T-tests were used to determine associations between males and females.
- Level of significance was assessed at  $\alpha = 0.05$ .
- Chi-square test ( $\chi^2$ ) was used to compare the gender distribution between males and females of clinical and pathological features of ameloblastoma.

- Analysis of variance ( ANOVA) and Bonferroni tests were done to analyse any significant difference between the solid, unicystic and malignant variants with regard to mean age of presentation.



## CHAPTER 3:

### RESULTS

#### DEMOGRAPHIC CHARACTERISITICS

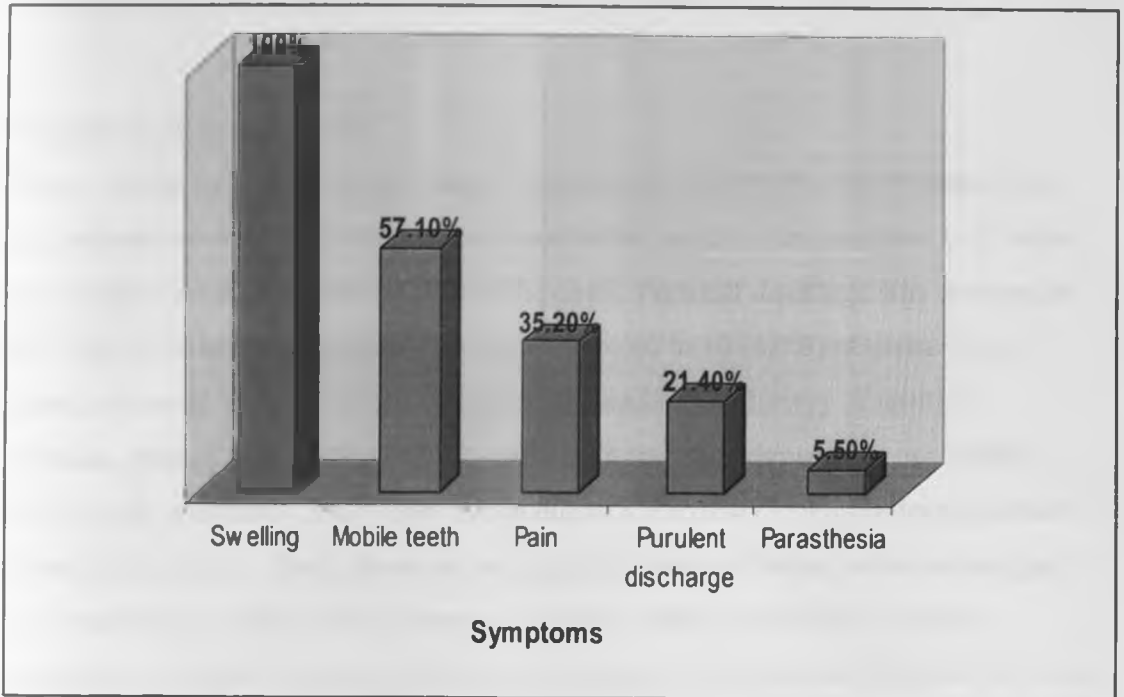
##### 3.1 Age and gender distribution of Ameloblastoma

A total of 184 cases with ameloblastoma were included in the study among whom 82(44.6%) were male and 102 (55.4%) were female with an overall age range of 10 to 80 years (mean = 30.20; SD±14.07). Among the male cases, the age range was 10 to 80 years (mean =29.9 years) while among the female cases it was 11 to 73 years (mean = 30.5 years). This was, however, not statistically significant ( $P > 0.05$ ). The 20 – 29- year age group was the most commonly affected with 70 (38.0%) of the cases. Cases below thirty years of age were significant with 109 (59.2%). The frequency of ameloblastoma by age group is shown in Table 1.

**Table 1. Distribution of ameloblastoma according to age group**

<i>Age group</i>	<i>Frequency</i>	<i>Percentage</i>
10-19	39	21.2
20-29	70	38.0
30-39	38	20.7
40-49	18	9.8
50-59	6	3.3
60-69	8	4.3
70+	5	2.7
<b>TOTAL</b>	<b>184</b>	<b>100.0</b>

The mean age of presentation of the unicystic ameloblastoma was 23.50 years while the multicystic ameloblastoma presented at 39.2 years. The mean age of presentation of the malignant ameloblastoma was 43.7 years. There was a statistical significance in the mean age of presentation of the unicystic and malignant ameloblastoma as shown by the ANOVA and confirmed by the Bonferroni tests signifying that they represented the true ages of the two sub-types of ameloblastoma in the study group, [( $P < 0.05$  (0.008)].



**Fig. 1. Pattern of symptoms at presentation of ameloblastoma**

### **3.3 Jaw site distribution of ameloblastoma**

Regarding the location of the lesions, 172 (93.5%) were found in the mandible while 11(6.0%) were located in the maxilla and 1(0.5%) was located in the soft tissue in the region of the anterior mandible. The posterior mandible was the most commonly reported site while the anterior segment was the most commonly affected site in the maxilla. Some lesions had crossed both sides of the jaws and these anatomic sites were recorded as such. The mandible to maxilla ratio was 8.5:1. Unicystic ameloblastoma were located more in the mandible 7 (4.7%) while one was in the maxilla. Eight of the malignant lesions were reported in the mandible while one was reported in the maxilla. There was, however, no statistical significance in the site of the lesion in relation to the histopathological presentation (Tables 2 and 3).

The multicystic ameloblastoma presented earlier with the first symptoms being reported at 42.9 months and 54.4 months for the unicystic ameloblastoma while the malignant ameloblastoma presented at a mean duration of 43.3 months.

### **3.2 Symptoms at presentation**

Swelling was the most commonly reported symptom in 182 (98.9%) of the cases. Pain was a symptom in only 64 (36.0%) of the cases while mobile teeth or a history of dental extraction was recorded in 104 (57.5%) of the cases. Purulent discharge was reported in 39 (21.7%) of the cases while parasthesia was reported in 10 (5.6%) of them. Other reported associated symptoms included severe anaemia and a history of multiple transfusion, protein malnutrition with severe weight loss was recorded in one elderly patient and the presence of nasal obstruction due to a maxillary ameloblastoma had been reported in one patient. One patient had an incidental tumour finding when an enlarged follicle was biopsied after disimpaction of a wisdom tooth. Superficial ulceration, bleeding due to trauma on eating, trismus and an extraction socket that failed to heal were less frequently reported symptoms. The mean duration of symptoms was 46.3 months for males and 44.4 months for females with 1 month having been the minimum duration of presentation while the longest presented at 240 months (Fig. 1).

**Table 2. Site distribution of ameloblastoma in the mandible**

<i>Mandible site</i>	<i>Frequency</i>	<i>Percentage</i>
Anterior mandible	24	13.9
Premolar - Molar	21	12.2
Angle to Ramus	95	55.2
Right Angle- Left Angle	9	5.2
Entire Left	6	3.5
Entire Right	10	5.8
Body of Mandible	7	4.2
<b>Total</b>	<b>172</b>	<b>100.0</b>

**Table 3. Site distribution in the maxilla**

<i>Site</i>	<i>Frequency</i>	<i>Percentage</i>
Anterior maxilla	4	36.4
Left posterior maxilla	2	18.2
Right posterior maxilla	3	27.2
Entire maxilla	1	9.1
Entire left	1	9.1
<b>Total</b>	<b>11</b>	<b>100</b>

### 3.4 Radiological features

A multilocular appearance was the most common radiographic feature recorded accounting for 127 (69.4%) cases while unilocularity accounted for 56 (30.6%) of the lesions. There was, however, no statistical significance of the radiological features with gender and the histopathological subtype of the lesions (Tables 4 and 5).

**Table 4. Pattern of radiological features according to gender**

<i>Radiological findings</i>	<i>Male</i>	<i>Female</i>	<i>Frequency</i>
Multilocular	57	70	127
Unilocular	24	32	56
<b>Total count</b>	<b>81</b>	<b>102</b>	<b>183</b>

**Table 5. Pattern of radiological features according to histopathological type of Ameloblastoma**

<i>Radiological findings</i>	<i>Multilocular</i>	<i>Unilocular</i>	<i>Total</i>
Multicystic	98 (92.5%)	34 (79.1%)	132
Unicystic	3 (2.8%)	5 (11.6%)	8
Malignant	5(4.7%)	4 (9.3%)	9

(NB: percentage within radiological findings).

### **3.5 Histopathological patterns of the various subtypes of ameloblastoma**

Histopathology revealed that 133 (88.7%) were of the multicystic type, while the unicystic group were 8(5.3%). The malignant variants accounted for 6.0% (9) of all the lesions. The *cystic ameloblastoma* occurring mainly in the plexiform or follicular ameloblastoma was a separate entity reported by the oral pathologist and accounted for 18.5% (34) of all the ameloblastoma lesions. The follicular ameloblastoma and its co-occurrence with the other subtypes was the most commonly reported subtype (Fig. 2 and table 6).

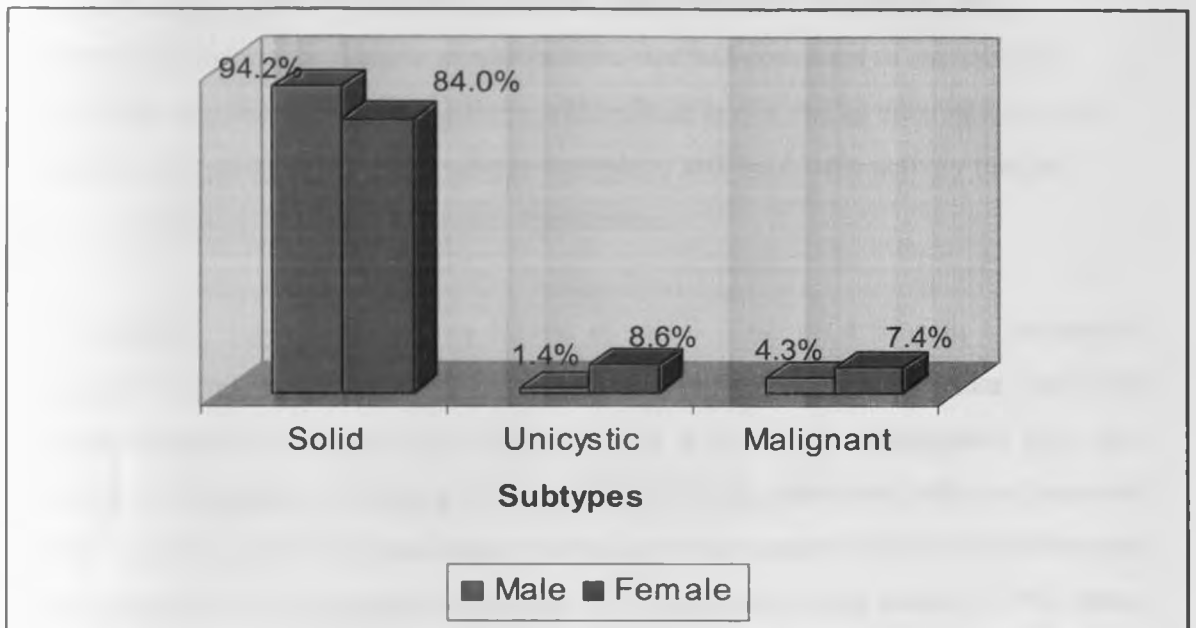


Fig. 2. Distribution of the ameloblastoma subtypes according to gender.

Table 6. Frequency of histopathological subtypes of ameloblastoma

Subtype	Frequency
Follicular subtype	34
Plexiform subtype	5
Granular	1
Desmoplastic	1
Acanthomatous	1
Basaloid	0
Mixed subtypes	60
Arising in dentigerous	2
Arising from dental follicle	1
Arising from odontogenic keratocyst	2
Arising from radicular cyst	1
Arising with calcifying odontogenic cyst	1
No pattern specified	12
Mixed subtypes with squamous metaplasia	12
Cystic ameloblastoma	34
Malignant	9
Unicystic	8
<b>TOTAL</b>	<b>184</b>

UNIVERSITY OF NAIROBI  
MEDICAL LIBRARY

The malignant ameloblastoma accounted for 6% (9) of all the lesions. Of these lesions of malignant ameloblastoma were reported including one ameloblastic carcinoma. *Other malignant variants* that were reported included ameloblastoma co-existing with squamous cell carcinoma (1), one ameloblastoma that had converted to ameloblastic fibro-odontosarcoma, one ameloblastoma with cellular atypia and an enigmatic form of ameloblastoma associated with squamous metaplasia and lipoblastic activity that had been previously reported as a low grade liposarcoma.

*Cystic ameloblastoma* included two lesions of ameloblastoma arising in a keratocyst lining, two arising in a dentigerous cyst lining and one arising in a radicular cyst. One ameloblastoma was reported as co-existing with a calcifying odontogenic cyst and another was reported as having arisen in a dental follicle associated with an impacted wisdom tooth. A total of 42 cases were reported as cystic ameloblastomas, of which eight had originated from odontogenic cyst linings. Of these, twenty were males (47.6%, mean age 27.4 years, age range 10-60years). Females comprised 22 of the cases (52.4%, mean age 29.6 years, age range 12-64 years). The age difference was, however, not statistically significant ( $p > 0.05$  [0.623]). The mean duration for this histopathological subtype was 46.3 months (minimum 1 month, maximum 180 months, median= 21 months). Mean duration of symptoms at presentation was 30 months for males and 18 months for females. There was, however, no statistical significance in duration of symptoms between the genders with cystic ameloblastoma. ( $p > 0.05$  (0.0800)). Sixteen cases had no histopathological pattern reported. The diversity of the histopathological patterns of the ameloblastoma lesions in this study is illustrated in Fig. 3 to 10.




Fig 3(a)

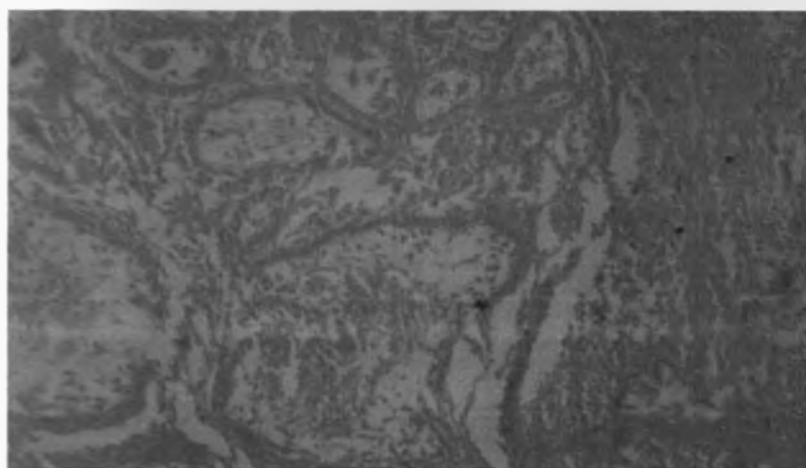


Fig 3(b)

Figs. 3(a) and (b). Plexiform ameloblastoma: Photomicrographs showing chronically inflamed haemorrhagic connective tissue stroma containing anastomosing strands of stellate reticulum – like cells bordered by cuboidal ameloblast –like cells (arrowed) with reversed nuclear polarities (Haematoxylin and eosin stain; magnification x100).





Fig. 4. Photomicrograph of the desmoplastic ameloblastoma subtype. Showing cellular and collagenous fibrous stroma containing irregular-shaped follicular islands of loosely arranged stellate reticulum-like cells surrounded by cuboidal preameloblast-like cells with reversed nuclear polarities. The stroma has areas of chronic inflammation and haemorrhagic areas (Haematoxylin and eosin stain; magnification x100).

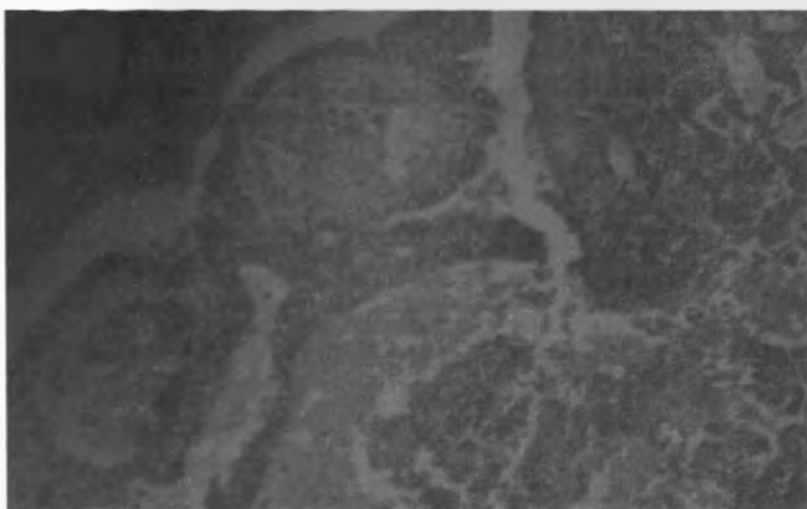


Fig. 5. Photomicrograph of the follicular subtype of ameloblastoma showing multiple follicles lined by ameloblasts-like cells dispersed in an extensive well vascularized

fibrocellular stroma. There is variability in follicular organization with some follicles containing stellate reticulum-like tissue while others exhibit central vascularity. There is no cellular pleomorphism (Haematoxylin and eosin stain; magnification x100).



Fig.6. Photomicrograph of malignant ameloblastoma showing multiple large follicles of ameloblast-like cells with a central stellate reticulum dispersed in a thin fibrous tissue stroma. The ameloblast-like cells have undergone anaplastic transformation and exhibit marked cellular and nuclear pleomorphism, mitotic figures and nuclear chromatism (Haematoxylin and eosin stain; magnification x100).

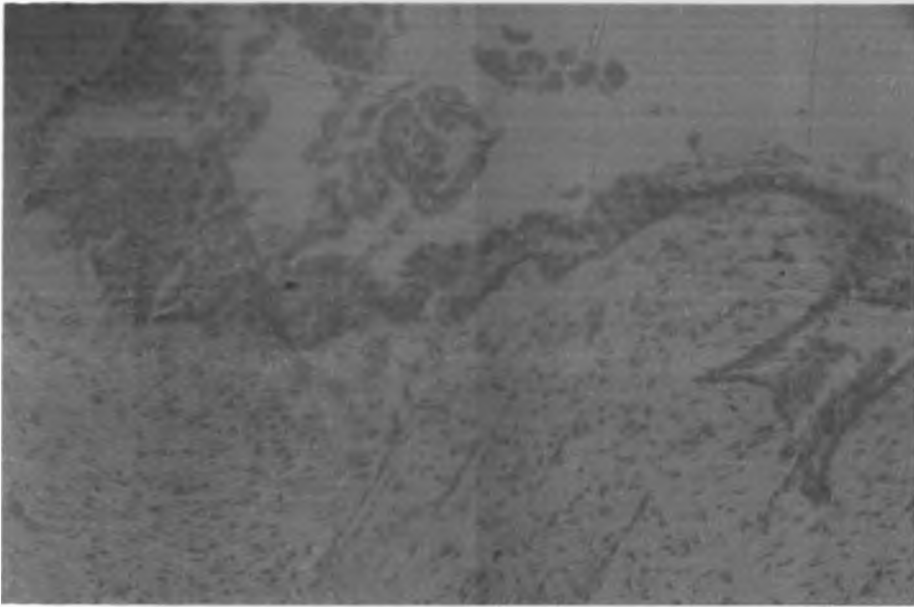


Fig. 7. Photomicrograph of the cystic ameloblastoma showing a thin lining of cuboidal preameloblastic- like cells supported by a chronically inflamed fibrous connective tissue wall. The thin lining in some instances proliferates into loosely arranged stellate reticulum-like cells. The connective tissue stroma is covered by hyperplastic keratinized stratified squamous epithelium with long rete-ridges (Haematoxylin and eosin stain; magnification x100).

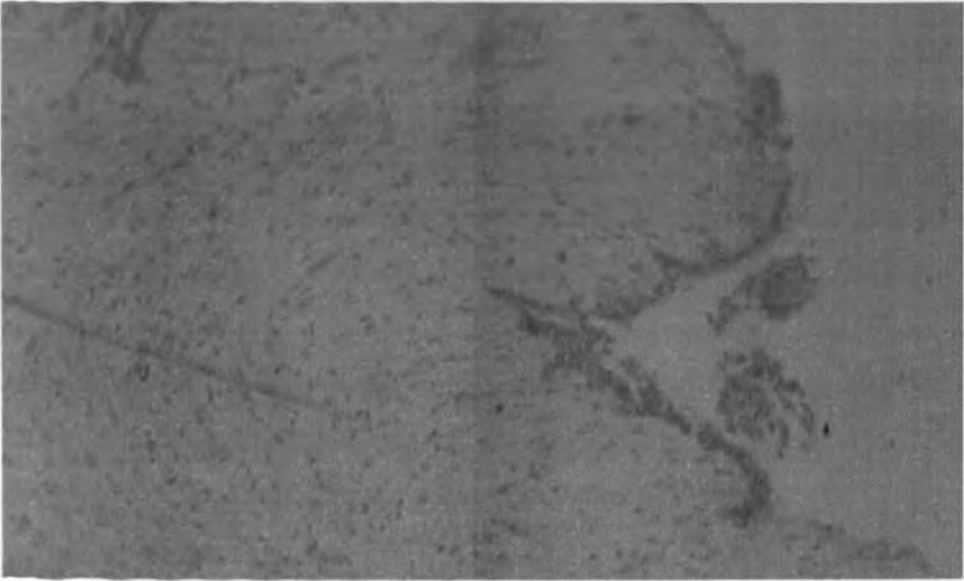


Fig. 8. Photomicrograph showing the true cystic ameloblastoma (Haematoxylin and eosin stain; magnification x100).




Fig. 9(a)

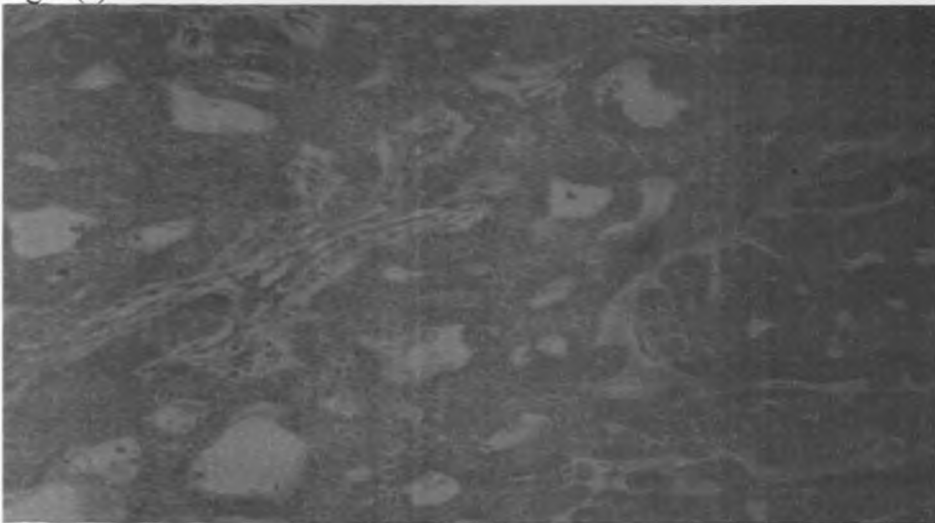

Fig. 9(b)

Fig. 9 (a) and 9 (b). The mixed follicular- plexiform and cystic subtypes showing chronically inflamed haemorrhagic connective tissue stroma containing follicular islands and sheets of anastomosing strands of ameloblastic epithelium with areas of cystic degeneration (Haematoxylin and eosin stain; magnification x100).

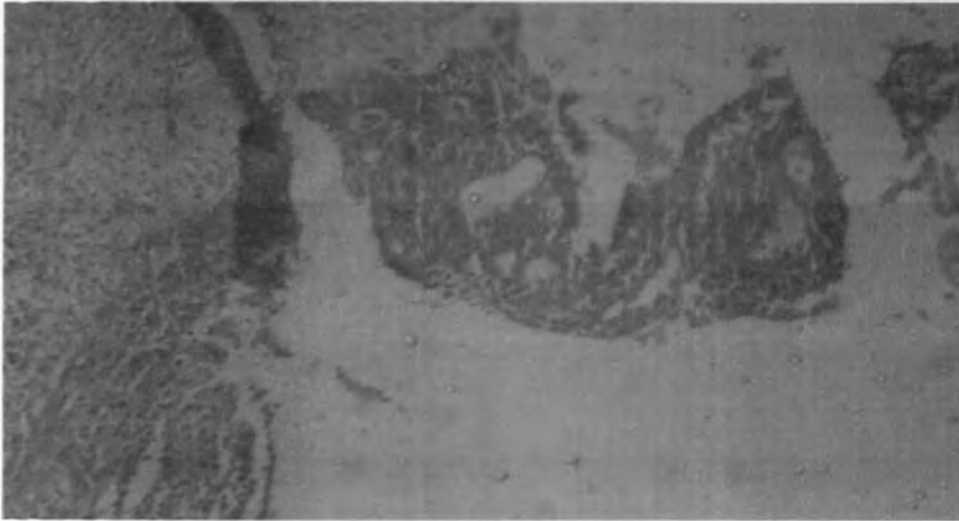


Fig. 10. The Unicystic ameloblastoma photomicrograph showing a section of irregularly arranged haemorrhagic chronically inflamed connective tissue walls or capsules surrounding cystic areas and supporting a thin and sometimes variably hyperplastic epithelial lining. In many instances the lining proliferates into loosely arranged stellate reticulum-like cells and ameloblastic epithelium the proliferation sometimes infiltrates into the walls or capsule (Haematoxylin and eosin stain; magnification x100).

### 3.6 Frequency of recurrence

Twenty-eight (15.22%) of a the lesion of ameloblastoma were reported to have recurred after conservative treatment among which 13 were male and 15 female cases. The follicular subtype was the most reported to have recurred at 39.3%. The mean age of recurrence was 36.6 years (SD±30.1 – 43.2 years) with an age range of 12 years to 70 years (median = 30.0 years). The mean duration of recurrence was 78.9 months (S.D± 52.9 months – 104.9 months), with a minimum duration of 4 months and a maximum of 228 months (median = 60.0 months). (Table 7).

**Table 7. Frequency of recurrence of the various subtypes of the ameloblastoma lesions.**

<i>Subtype</i>	<i>Frequency</i>	<i>Percentage</i>
Follicular	11	39.3
Cystic	9	32.2
Unicystic	2	7.1
Malignant	2	7.1
No pattern	4	14.3
<b>TOTAL</b>	<b>28</b>	<b>100.0</b>

## CHAPTER 4

### DISCUSSION

Most of the data available on ameloblastoma is from non-Africans and this may be the reason for relatively few reports on these tumours especially from Africa. Several reports on ameloblastoma have been published with studies showing that ameloblastoma occurs with equal frequency in men and women<sup>2,25,32</sup> however, a Nigerian study<sup>25</sup> and an Indian study<sup>36</sup> showed a male preponderance. The present study showed a slight female preponderance with a male to female ratio of 1: 1.2. The age distribution is usually from the first to the seventh decades of life with a mean age in the 4<sup>th</sup> to 5<sup>th</sup> decades of life. In the present study, the mean age was 30.2 years and a distinct peak in the 2<sup>nd</sup> and 3<sup>rd</sup> decades of life which support the observation that ameloblastoma appears to occur in younger age groups in Africans than in caucasians<sup>2</sup>. This has, however, been disputed by a recent Tanzanian study by Simon et al. (2005) in a prospective study that found ameloblastoma to have an equal distribution between males and females with a mean age of 35 years.<sup>58</sup>

A mandibular to maxillary ratio of 8.5: 1 was noted in the present study with 93.5% of the ameloblastoma presenting in the mandible and 6.0% in the maxilla while 0.5% (1) was located in the soft tissues. This observation is similar to that reported in other studies in Nigerian and Japan.<sup>4,10,27</sup> The molar- ramus area is the most frequently involved in the Japanese and whites.<sup>2,10,25</sup> The present study implicated that the molar-ramus was the most involved anatomical site of predilection with 51.6%, a figure slightly lower than that reported in other studies. The occurrence of ameloblastoma more frequently in the anterior region in blacks has been reported<sup>23,25,32</sup>, a finding which was not noted in this study. The site differences noted could have several explanations; an unknown site of origin may be the most possible description for the large tumours, and that tumours in African populations present when they are massive and may involve more than one anatomic site so that the precise area of origin is difficult to judge. This was observed in this study where 9(5.2%) of the ameloblastomas extended from the right to left angle of the mandible and 16(9.3%) involved the entire left or right side of the mandible.

The observed differences in the location of the original tumour may have been affected by the massive spread of the tumour to the anterior region in the mandible in Africans thus raising the frequency of occurrence. For example, tumours in the premolar region cross the symphysis and may be classified as anterior hence contributing to the high figures. Improved screening in developed countries means the disease is identified earlier so that description of site is likely to be more accurate.

The time lapse between the appearance of clinical signs and symptoms and reporting to hospital ranged from 1 month to 240 months (20years). This considerable delay in patients presenting themselves to the hospital may be due to pressing socio-economic priorities. In many instances patients tend to go to hospital only when there is unbearable pain, discomfort or gross interference with function. In the Kenyan society oral health is given a low priority compared to more life threatening medical conditions. Other contributing factors to the long delays are the long distances one had to travel to the appropriate centre and the financial implications, the introduction of cost sharing (user fees), the purchase of reconstruction plates which are costly, ignorance of patients, social acceptability and failure of health workers at primary health facilities to diagnose and refer patients as early as possible.

Radiological features in this study proved to be a challenge as massive ameloblastomas were shown to have variable radiological appearance though most were either unilocular or multilocular. Of the multicystic (solid) ameloblastomas; 74.2% were multilocular and 38.1% were unilocular. This was in contrast with Reichart et al. (1995) who observed that multilocularity was present in 49% while 51% were unilocular. Ueno et al. (1986) reported a unilocular pattern in the younger age groups. Of the unicystic lesions; 11.6% exhibited unilocularity while 2.8% were multilocular. Among the malignant variants, 4.7% were multiloculated while 9.3% were unilocular. There was, however, no statistical significance between the histological type of ameloblastoma and the patients' gender when related to the radiological findings. Chidzonga et al. (1990) reviewed 117 cases of ameloblastoma in Zimbabwe and documented that 81.2% were multilocular while 18.8% were unilocular. It is hypothesized that unilocularity is a stage in the tumour



progression rather than a permanent feature. This finding should, however, not be underestimated since the biological behaviour of the unilocular type of ameloblastoma differs from that of the histological unicystic ameloblastoma, which is known to be less aggressive contrasting with the histologically multicystic ameloblastoma which has been considered to be more aggressive. Unilocular lesions are thus likely to be unicystic but in the large radiological multilocular lesions, it is impossible to distinguish between the unicystic and multicystic lesions on the basis of the radiological features on plain films as has been proved in this study. Most of the tumours showed resorption of teeth regardless of the histological type. This resorption of roots may help differentiate ameloblastomas from other odontogenic cysts. <sup>15</sup>

Histomorphologic appearance of ameloblastoma is typical but it exhibits varied histological patterns. The two predominant patterns being follicular and plexiform. The follicular, acanthomatous, granular, plexiform and desmoplastic subtypes were all reported in this study, except for the basaloid subtype. Mixed variants of the above subtypes were seen and formed the largest proportion of all the multicystic ameloblastomas accounting for 63 of the total, 133 multicystic (solid) subtypes reported in the study. The follicular subtypes whether alone or occurring with the other subtypes were the most frequently diagnosed and accounted for 39.5%. The unicystic type accounted for 5.3%, concurring with a Tanzanian study. <sup>38</sup> The mean age of patients with the solid (multicystic) ameloblastoma was 29.48 years (Range 27.1-31.9 years, median of 26.0 years); the youngest was 10 years and the oldest reported as 70 years. This is a decade younger compared to western studies where the mean age of presentation has been reported as 39.6 years. <sup>2,25</sup> Another commonly reported histopathological pattern in this study was the cystic ameloblastoma, which comprised 34 (18.5%) of the total ameloblastoma reported.

This variant was reported as having microcystic or in the predominant plexiform or follicular pattern and occasionally formed cystic regions and hence justifiably reported as cystic ameloblastoma. There was no statistical significance in the gender pattern of affliction for the cystic ameloblastomas whose mean age of occurrence was 28.5 years. The mean duration of presentation for this variant was at 46.3 months. Five of the cystic

ameloblastoma lesions were reported to have developed from the various odontogenic cysts including one which was co-existing with a calcifying odontogenic cyst. Twelve of the ameloblastoma were reported without further characterization. The malignant variants formed 4.9% (9) of the total lesions with four cases reported as malignant ameloblastoma and one reported as ameloblastic carcinoma. This is slightly higher when compared to western figures of malignancy though statistically insignificant.<sup>2,7</sup> The remaining were *rare variants of malignant ameloblastomous lesions* reported as (a) ameloblastoma arising with squamous cell carcinoma, (b) ameloblastoma that had converted to ameloblastic fibro-odontosarcoma, (c) ameloblastoma with cellular atypia and (d) an enigmatic variant reported as ameloblastoma associated with squamous metaplasia and lipoblastic activity that had previously been reported as low grade liposarcoma. These rare variants of malignancy thus call for a concise histopathological evaluation of the gross specimen for proper and definitive diagnosis. The malignant lesions were observed more in the mandible than the maxilla. The histological subtypes showed no relationship to specific radiological appearances, though as a general observation, it was notable that the follicular mixed subtypes had a multilocular appearance.

The presence of malignant ameloblastoma has been reported in a wide range of age groups with a mean age of 30.1 years.<sup>22,25,47</sup> This was lower than the mean age of 43.7 years reported in this study. Most malignancies have also been reported to most commonly involve the posterior portion of the mandible an observation that is in agreement with this study. In our study the radiographic appearance of the malignant lesion was consistent with that of the benign ameloblastoma. Whether the ameloblastoma may transform biologically and histopathologically from a classic ameloblastoma to a malignant lesion is controversial. It is thus important that in future, these lesions should be accurately identified, differentiated from malignant ameloblastoma and followed so that their natural history and prognosis can be further defined.

A recurrence prevalence of 15.2% of these ameloblastomas was noted implying a prevalence rate of 10.3% to 20.4% in the overall population of patients with

ameloblastoma after conservative treatment with curettage or enucleation. This concurs with other studies.<sup>2,8,9</sup> The commonly cited recurrence rate for the unicystic variants ranges from 6.7% to 35.7%<sup>42, 44</sup>. While the recurrence rates for the solid or multicystic type vary from 17.7% to 27.7%<sup>10, 33</sup> with a radical treatment and from 20% to 90% when a conservative surgical approach is followed. Recurrence prevalence in this study is consistent with that reported in the above studies. The follicular subtype had the highest reported recurrences an observation that has been reported in other studies.<sup>2, 9, 10</sup> The presence of recurrence of two malignant lesions could be due to the fact that they could have been treated on the basis of a radiological appearance of the lesion resembling an odontogenic cyst.

The lower recurrence rate for the unicystic ameloblastoma are thought to be a reflection of the different morphology between the unicystic and multicystic variants rather than as a result of a lower proliferative capacity so that they are easily enucleated, whereas the complex morphologic growth pattern of the multicystic ameloblastoma is likely to lead to incomplete excision of tumours, resulting in recurrence and a worse prognosis.<sup>22, 33, 50</sup>

## CONCLUSIONS:

This study has established that ameloblastoma in this population group was observed to have a peak in the 2<sup>nd</sup> decade of life and that patients below 30 years of age formed more than half of the cases.

- Most of the ameloblastomas were of the multicystic type with the mixed subtypes forming the largest proportion.
- Unicystic variants formed eight of the cases of ameloblastomas with the majority occurring in the posterior mandible and only one in the maxilla.
- The malignant variants were nine in total, constituting a larger percentage than that reported in the literature. Some of these malignant lesions were quite unique and have not been reported in any literature. These included ameloblastoma co-existing with squamous cell carcinoma, an ameloblastoma that had converted to an ameloblastic fibro-odontosarcoma, ameloblastoma with cellular atypia and an enigmatic form of ameloblastoma associated with squamous metaplasia and

lipoblastic activity that had been previously reported as a low grade liposarcoma. Eight of these malignant lesions were reported in the mandible.

- Some of the ameloblastoma lesions had no specific pattern reported.
- Cystic ameloblastoma was a subtype that formed a significant proportion of the lesions and was reported to be associated with the follicular or plexiform subtypes. This lesion has not been reported in literature.
- Six of these ameloblastoma lesions were reported to have originated from various odontogenic cysts while one was reported as co-existing with a calcifying odontogenic cyst.

### **Recommendations:**

- There is a need for prospective studies to establish the actual incidence and true age distribution of ameloblastomas especially in the African population groups. This would provide clues crucial in understanding the disease aetiology and could be used to project the future trends of ameloblastoma and possibly help in clinical management.
- A clear differentiation between the terms and nomenclature related to radiological appearances and histology is necessary so that standardization of their use would assist proper diagnosis and comparison of different results.
- There is a need to document these tumours as results will clarify the magnitude of this problem and aid in formulation of management, care and follow-up.
- Apart from the main predominant histopathological types, the ability to identify other morphological features identified in these studies in the haematoxylin and eosin sections and the need to understand their behavioural characteristics by immunohistochemical studies prospectively may prove significant in the management of ameloblastoma in future. In addition to clinical and histopathological documentation, basic research aspects are still of importance so that the growth pattern and tumour spread data of the different types of ameloblastoma are highly desirable.

## REFERENCES

1. Kramer, I.R.H, pindborg, J.J. and shear, M. Histological typing of odontogenic tumours World Health organization of International histological classification of tumours: 2nd edition Berlin Springer – Verleg 1992 ; PP 1-42.
2. Reichart. P.A, phillipsen. H.P and Sonner,S. Ameloblastoma: biological profile of 3677 cases. Oral Oncol, Eur J cancer 1995; 31B:86-99.
3. Ajagbe, H.A, and Daramola, J.O. Ameloblastoma; a survey of 199 cases in the University of college Hospital, Ibadan Nigeria J. Natl Med Association 1987; 79:324-327.
4. Smith, C.J. Odontogenic neoplasms and harmatomas of oral diseases in the tropics; Oxford Medical 1992PP; 367-385.
5. Herceg , S.J and Harding R.L Malignant ameloblstoma with pulmonary metastases: report Reconstn Surg1972;49:456-460.
6. Kunze E, Donath K and Luhr H.G et al. Biology of metastasizing ameloblastoma. Pathol Res Pract 1985;180:526-535.
7. Gardner D.G. and Pecak A.M. The treatment of ameloblastoma based on pathological and anatomic principles .Cancer 1980;46:2514-2519.
8. Williams T.P. Management of ameloblastoma. J. oral and maxillofac surg, 1993; 51:1064-1070.
9. Gardner D.G. A pathologist approach to the treatment of ameloblastoma .J oral maxillofacial surg 1984; 42:161-166.
10. Ueno S, Mushimoto K and Shirasu R. A clinicopathologic study of ameloblastoma. J oral maxillofac surg 1986; 44:361-365.
11. Weinberg D.S, Morore D.H and Vartanian R. Correlation of Ki -67 antigen

- expression with Mitotic figure index and tumour grade in breast carcinomas using the hard paraffin MIB-I antibody. *Human pathol* 1994; 25; 337-342.
12. Weingberg DS. Proliferation indices in solid tumours. *Adv pathol lab Med* (1993) 5:163-191.
  13. Ota Y, Goto J, sasaki J. Immunohistochemical studies of ameloblastoma with special emphasis on Keratin. *Tokai J Exp Clin Med* 1988; 13:219-226.
  14. Funaoka K, Arisue M, Kobayschi I. Immunohistochemical detection of proliferating cell nuclear antigen (PCNA) in 23 case of ameloblastoma. *Oral Oncol Eu J.cancer* 1996; 32:328-332.
  15. Onguti MN, Crutchely AT Howells GL et al. Ki -67 antigen in ameloblastoma : correlation with clinical and histological parameters 54 cases of ameloblastoma in Kenya. *Inte. J. Oral Maxillofac surg* 1997; 26:376-379.
  16. Kim J and YOOK J. I. Immunohistochemical study on proliferating cell nuclear antigen expression in ameloblastoma. *Oral Oncol ,Eur J cancer* 1994;30B :126-131.
  17. Vered Marilena, Izhar Shobat, Amos Buchner .Epidermal growth factor receptors in ameloblastoma. *Oral Oncol, Eur J* 2003; 39:138-143.
  18. Li T. J Browne RM, Matthews JB Expression of epidermal growth factor receptors by Odontogenic jaw cysts. *Virchows Arch pathol Anat Histopathol* 1993; 423:137- 147.
  19. Raymond W.A and Leong A.S –Y. Nuclear organizer regions related to growth fractions in human breast carcinoma. *Human pathol* 1989; 20:741-746.
  20. Shear M. Developmental odontogenic cysts. An update. *J. Oral Pathol Med.* 1994; 23: 1 – 11.

21. Slavkin Hc: Intracellular communication during odontogenesis In: Developmental aspects of oral biology. Arch Oral Biol 1988, 9:165-199.
22. Larson A and Almeran H. Ameloblastoma of the jaws .An analysis of consecutive series of all cases reported to the Swedish cancer Registry during 1958 to 1971. Act pathol microbial scan 1978; 86:337-346.
23. Mosadamii, A. Odontogenic tumours in an African population. Analysis of twenty- nine cases seen over a 5 year period. Oral surg Oral Med Oral Pathol 1969; 40:502-521.
24. Chindzonga MM, Perez V.M.L and Alvarez A.L.IP. Ameloblastoma: The Zimbabwean experience over 10 year's .Oral surg 1996; 82:38-41.
25. Odukoye O. Odontogenic tumour: an analysis of 289 cases. J. Oral pathol Med 1995; 24:452-457.
26. LU Y, Xuan M, Takata T. Odontogenic tumours. A demographic study of 159 cases in a Chinese population .Oral surg 1998; 86:707-714.
27. Wu PC and Chan K.W. A survey of tumours of the jaws in Hongkong Chinese. Brit J Oral Maxillofac surg 1985; 23:92-1023.
28. Onyango JF, Awange D.O, Wakiaga JM. Oral tumours and tumour –like conditions in Kenya: Histologic distribution East African Med J 1995; 72:560-563.
29. Daley T.D Wysocki G.P and Pringle G.A. A relative incidence of odontogenic tumours and oral jaw cysts in a Canadian population. Oral surg 1994; 77:276-280.
30. Gunham O, Erseven G and Ruacan S. Odontogenic tumours; A series of 409 cases .Austr Dent J 1990; 35: 518-522.
31. Mosqueda –Taylor A, Ledesma –Montes C, Cabellero- Sandoral S.

- Odontogenic tumours in Mexico: a collaborative retrospective study of 349 cases.  
Oral surg 1994; 84:672-675.
32. Sawyer DN, Mosadomii A, Page O.G et al. Racial predilation of ameloblastoma?  
A probable answer from Lagos (Nigeria) and Richmond Virginia (U.S.A) J oral  
Med 1985; 40:27-31.
33. Regezi JA, Kerr DA, Courtney RM .Odontogenic tumours: analysis of 706 cases.  
J. oral surg 1978; 36: 771-778.
34. Robinson H.B.G. Ameloblastoma : A survey of 379 cases from literature . Ach  
pathol 1937; 23:831.
35. Adekeye E.O. Ameloblastoma of the jaws: A survey of 109 Nigerian patients. J  
oral surg 1980; 38:36-41.
36. Potdar G.G, Ameloblastoma of the jaw as seen in Bombay India .Oral surg 1969;  
28:297-303.
37. Tsaknis P.J and Nelson J.F .The maxillary ameloblatoma. An analysis of 24 cases  
J, oral 1980; 42:93-96.
38. Simon E.N.M, Stoelinga E, Vuhavula E et al. Odontogenic tumours and tumour-  
like lesions in Tanzania. East medical Journal 2002; 79:3-7.
39. Akinosi JO, Williams AO. Ameloblastoma in Ibadan, Nigerian. Oral surg 1955;  
8-281-287.
40. Daramola JO, Ajabe HA and Oluwasanmi JO.Ameloblastoma of the jaws in  
Nigerian children : a review of sixteen cases. Oral surg Oral Med Oral pathol  
1975; 40:458-463.
41. Oluseyi FA, Akinola L.L, Wasiu LA. Odontogenic tumours in Nigerian children



- and adolescents – A retrospective study of 92 cases. *World journal of surg Oncol* 2004; 2: 39 - 42.
42. Leider As, Eversole LR, Barkin ME. Cystic ameloblastoma: a clinicopathologic analysis. *Oral surg Oral Med Oral Pathol* 1985; 60:624 – 630.
43. Khan M.A Ameloblastoma in young persons: A clinicopathologic analysis and aetiological investigation .*Oral surg Oral Med Oral pathol* 1989; 67:706-715.
44. Phillipson HP, Reichart PA. Unicystic ameloblastoma: a review of 193 cases from the literature. *Oral Oncol, Eur J Cancer* 1998; 34: 317 – 325.
45. Raubenheimer EJ, Van Heerden WF, Naffke CE. Infrequent clinicopathological findings in 108 ameloblastoma. *J oral Pathol Med* 1995; 24; 227-232.
46. Tajima Y, Yokose S, Sakamoto E. Ameloblastoma arising in calcifying odontogenic cyst. Report of a case .*Oral surg Med pathol oral Radiol Endod* 1992; 74:776-779.
47. Slootweg PJ, Muller H. Malignant ameloblastoma or ameloblastic carcinoma. *Oral surg Oral Med Oral pathol* 1984; 57:168-167.
48. Naser H.A, Said AL –Naief, Harry L. Keratoameloblastoma of the maxilla. A case report and review of the literature .*Oral surg Oral Med pathol Oral Radiol* 1997; 84; 535-539.
49. Gardner AF .The odontogenic cyst as a potential carcinoma: a clinicopathological appraisal *J. AM Dent Assoc* 1967; 78:746-755.
50. Forsberg HJ. Adamantinoma; Histopathological and prognostic studies .*Acta chir scand* 1951;102-404.
51. Getschikter H. Adamantinoma of the jaw : *American T cancer* 1935; 20: 90.
52. McGlashan NO, Walters CL, Mclean A.E. Nitrosamines in African Alcoholic

- spirits and oesophageal cancer. *Lancet* 1968; 11:1017.
53. Csiba A, Okros I.D, Ziich CS et al. Virus –like particles in Human ameloblastoma. *Arch Oral Biology* 1970; 15:817-826.
54. Chindia M, Guthua S.w ,Mwaniki D.L Ameloblastoma after surgical removal of an impacted mandibular molar. *Int. J Oral Maxillofac surg* 1991;20:73-74.
55. Gardner D.G. Radiotherapy in ameloblastoma. *Int. J Oral maxillofac surg* 1988; 17:201-205.
56. Ueda M, Kaneda T. Combined chemotherapy and radiotherapy for advanced maxillary ameloblastoma. *J. Cranio-Maxillo. Facio surg* 1991; 272-274.
57. Atkinson CH, Harward A.R, Cumming B.J. Ameloblastoma of the jaw; A reappraisal of the role of mega voltage radiation . *Cancer* 1984; 53:869.
58. Simon N.M.E. Mathias A.W.M, Vuhavula E, Ngassapa D, Stoelinga P.J.W. A 4 – year prospective study on epidemiology and clinicopathological presentation of odontogenic tumours in Tanzania. *Oral Surg Oral Med Oral Pathol Oral Radiol Endod* 2005; 99: 598 – 602.

## APPENDIX 1



Ref: **KNH-ERC/01/3136**

### **KENYATTA NATIONAL HOSPITAL**

Hospital Rd. along, Ngong Rd.

P.O. Box 20723, Nairobi.

Tel: 726300-9

Fax: 725272

Telegrams: "MEDSUP", Nairobi.

Email: [KNHplan@Ken.Healthnet.org](mailto:KNHplan@Ken.Healthnet.org)

Date: **17<sup>th</sup> November 2005**

Dr. Adeline Vilembwa  
Dept. of Oral & Maxillofacial Surgery  
Faculty of Dental Sciences  
University of Nairobi

Dear Dr. Vilembwa

**RESEARCH PROPOSAL: "PATTERN OF HISTOLOGICAL SUBTYPES VERSUS CLINICOPATHOLOGICAL PRESENTATION OF AMELOBLASTOMA AT THE UNIVERSITY OF NAIROBI, FACULTY OF DENTAL SCIENCES" (P176/10/2005)**

This is to inform you that the Kenyatta National Hospital Ethics and Research Committee has reviewed and **approved** your above cited research proposal for the period 17<sup>th</sup> November 2005 – 16<sup>th</sup> November 2006. You will be required to request for a renewal of the approval if you intend to continue with the study beyond the deadline given.

On behalf of the Committee, I wish you fruitful research and look forward to receiving a summary of the research findings upon completion of the study.

This information will form part of database that will be consulted in future when processing related research study so as to minimize chances of study duplication.

Yours sincerely,

**PROF A N GUANTAI**  
**SECRETARY, KNH-ERC**

c.c. Prof. K.M.Bhatt, Chairperson, KNH-ERC  
The Deputy Director CS, KNH  
Dean, Faculty of dental Sciences, UON  
The chairman, Dept of Oral & Maxillofacial Surgery, UON  
The HOD, Medical Records, KNH  
Supervisors: Dr. J. F. Onyango, Dept. of Oral & Maxillofacial Surgery, UON  
Dr. D. O. Awange, Dept. of Oral Pathology, UON  
Dr. M. L. Chindia, Dept. of Oral & Maxillofacial Surgery, UON

UNIVERSITY OF NAIROBI  
MEDICAL LIBRARY

## APPENDIX 2.

### Appendix 2. Data collection form.

1. Patients file number
2. Age (years)
3. Gender    M   
                  F
4. Site of Lesion

	Posterior	Premolar	Anterior
Maxilla			
Mandible			
Mandible and Maxilla			

5. a) Presenting symptoms
  - Swelling
  - Pain
  - Purulent discharge
  - Symptomless
  - Pain and parasthesia
  - Swelling and discomfort
  - Pain and swelling
  - Tooth mobility
  - Local discomfort
  - Delayed healing of extraction socket
  - Unknown

5. b) Duration of symptoms
6. Histological subtype of ameloblastoma
7. Radiographic findings
  - a.) Unilocular

Multilocular

Cortical expansion

Soap bubble

b.) Effect on teeth

Resorption of roots

Displacement

No effect

### APPENDIX 3

Appendix 3. Mixed subtypes of ameloblastoma as reported.

1. Follicular, acanthomatous
2. Follicular, cystic
3. Follicular, plexiform, cystic
4. Follicular, plexiform, acanthomatous
5. Follicular, acanthomatous, cystic
6. Acanthomatous, granular, cystic
7. Plexiform, follicular, keratinization
8. Mixed with squamous metaplasia
9. Granular acanthomatous]
10. Keratinizing acanthomatous
11. Follicular, plexiform
12. Cystic ameloblastoma
13. Follicular, acanthomatous
14. Granular, cystic
15. Follicular with calcifying odontogenic cystic