

THE PATTERN OF RADIOLOGICAL PRESENTATION

OF

LOWER URINARY TRACT OBSTRUCTION

AT

KENYATTA NATIONAL HOSPITAL

A dissertation submitted in part fulfilment for the degree of Master of Medicine (Diagnostic Radiology), University of Nairobi.

February, 1991

DR. ZABLON O. OGUTTU MBCHB (NAIROBI).

**MEDICAL LIBRARY  
UNIVERSITY OF NAIROBI**

University of NAIROBI Library



0324733 5

DECLARATION

Candidate:

This dissertation is my original work and has not been presented for a degree in any other University.

Signed:




DR. ZABLON O. OGUTTU MBChB (Nairobi)

Supervisor:

This dissertation has been submitted for examination with my approval as University Supervisor

Signed:



Dr. M. W. Wachira  
Ag. Chairman/Lecturer,  
Department of Diagnostic Radiology  
University of Nairobi.

D E D I C A T I O N

To my wife SERAFFIN  
for her support and patience  
during the preparation of  
of this dissertation

D E D I C A T I O N

To my wife SERAFFIN  
for her support and patience  
during the preparation of  
of this dissertation

TABLE OF CONTENTS

Summary .....	1
Introduction .....	2
Materials and Method .....	4
Results .....	8
Illustrations .....	15
Discussion .....	19
Bibliography .....	45

## SUMMARY

A one year prospective study was done on 82 patients who presented to x-ray department, Kenyatta National Hospital with a clinical diagnosis of lower urinary tract obstruction. Forty-nine patients had micturating cystourethrography done on them while 33 patients had ascending urethrography done. The age range was 10 months to 76 years. There were 79 males and three females.

There were 19 patients (23.2%) of age 10 years and below. The most frequent disorder in this age group was posterior urethral valves accounting for 36.8% while 10.5% of cases were normal.

In the age group 11 years and above, urethral stricture was found to be the most common abnormality accounting for 58.9%. Out of these 54.2% were in age group 21 - 40 years.

## INTRODUCTION

This study done at Kenyatta National Hospital attempts to categorise lower urinary tract obstruction in terms of site, size and frequency of occurrence. Only radiological aspects were considered. Surgical aspects were omitted due to difficulties encountered in patients follow-up. The re-attendance to the clinics were irregular and far apart.

As a whole, this is a baseline study the author undertook having realised that very little had previously been done in our set up. It is also noteworthy that whatever has been done centres only in adults with urethral strictures. This study therefore undertakes to review all age groups.

Micturating cystourethrography or ascending urethrography was used as a means of investigating lower urinary tract.

Several authors have reviewed lower urinary tract obstruction with regard to the cause. Books V. (1968) (6) showed that 73% of the 100 patients he reviewed had strictures at the bulbous urethra, this being the most common site. These were patients with post-infection strictures. This common site was confirmed by Gerald J. De Lacey (1973) (11). In his study, De Lacey et al (4,11) also showed that periurethral ducts and glands are filled (69%) in cases of chronic obstruction.

Ruptured urethra has also been shown to be a cause of lower urinary tract obstruction (De Lacey 1973) (11). In 1986 (Adwok) (1) looked at urethral strictures at Kenyatta National Hospital. He showed that bulbous urethra was the commonest site. Musau C.K. (1989) reviewed bladder function in patients with paraplegia and showed that road traffic accident was the commonest cause.

Various methods have been used to demonstrate lower urinary tract using contrast media. Lower urinary tract was first demonstrated radiologically

by Cunning in 1910 using Agyrol (22) as the contrast media. Knutson introduced knutson clump for injecting contrast media in 1921 (12). In 1941 (Brodny M.L.) (7,12) introduced a catheter nowadays known as Brodny's catheter which sticks to urethral meatal opening. Becker (1968) (5) confirmed that it was easier to do pressure injections with it than Knutson clump.

Hyman 1965 (12,20) and Apap 1971 (12) performed ascending urethrograms by injecting contrast through a Folley's catheter. Gerald de Lacey (1977) (12) suggested and performed drip infusion technique using hydrostatic pressure.

Voiding vacuum cystourethrography was shown to be good for girls and patients with hypospadias (Becker J. et al 1968) (5).

Suprapubic cystotomy tube has been used (Fitts) (16) to perform micturating cystourethrography. Its advantage is that there is no mechanical interference with lower urinary tract or contaminated (Thompson) (37). Nowadays out-flow obstruction is determined by cine pressure flow studies (3).

Various kinds of contrast media have been used in demonstrating lower urinary tract. They have basically been either iodinated oily contrast medias, barium suspensions or iodinated water soluble contrast media.



## MATERIALS AND METHOD

A study period of one year reviewed 82 patients who presented to the x-ray department for evaluation of lower urinary tract obstruction. The mode of investigation was either micturating cystourethrography or ascending urethrography.

The patients were referred either from out patient clinics or from the wards. The patient, or their escorts, presented their request forms at the reception desk, whereupon the same were sent to the author to scrutinize. All age-groups were considered.

The criteria for inclusion was clinical history suggestive of obstruction to voiding plus its complication.

The patients were then given an appointment for the examination to be carried out. No special preparations were required and the examinations were done preferably in the mornings. The information related to the patient was recorded thus:-

- 1). Name, age and sex of patient
- 2). Inpatient or Outpatient number
- 3). X-ray department registration number
- 4). Clinical history of the disease plus any other attendant complication
- 5). Clinical diagnosis

The only contraindication to the examination considered was the presence of active lower urinary tract infection as shown by pus per-urethra.

- 5 -

## ASCENDING URETHROGRAPHY

### Requirements:

- 1). Fluoroscopy table with image intensifier(s)
- 2). Folley's catheter
- 3). Contrast media - water soluble meglumine diatrizoate (52% weight for volume, Sodium diatrizoate (8% weight for volume) with an iodine content of 290mg/ml (Urograffin 60% from Schering). This was diluted with Normal Saline Ratio 1:1.
- 4). Catheterization tray.

### Technique:

The patient was told to lie in supine position on the fluoroscopy table. The external genitalia was exposed and examined to rule out pus per-urethra. Through aseptic technique a folley's catheter (usually No. 18) lubricated with K-Y jelly (from Johnson & Johnson), was inserted upto the forsa navicularis and the balloon inflated using approximately 2cc of normal saline. This was done so as to retain the catheter in position during injection phase. An artery forceps was used to clump the open end of the folley's catheter.

Contrast was drawn into a 20cc syringe and injected through a needle puncture on the folley's catheter. The patient was placed in oblique position so as to see the urethra in profile as contrast traversed it under fluoroscopy.

Spot films of the urethra were taken and any abnormalities detected were also taken in profile by turning the patient to suitable positions. The patient was then requested to wait in the waiting area as the films were processed. The patient was only allowed to go away when the films had been found to be adequate for reporting. He was advised to collect the results from the referring doctor.

These films were then reported on with the guidance of the supervisor. The information recorded during reporting included:-

- 6 -
- 1). presence of abnormality in urethra,
  - 2). site and nature of the abnormality,
  - 3). presence of complication and its characteristics.

In this study, no female presented for ascending urethrogram.

#### MICTURATING CYSTOURETHROGRAPHY

The general requirements were as for ascending urethrography. The patient was given an open fronted gown to wear on arrival at the examination area.

In supine position on the fluoroscopy table, the patient was examined for any frank pus per-urethra, which was the only contraindication to the examination.

Under aseptic technique, a lubricated Folley's catheter (size 18) was inserted through the urethral meatus into the bladder. The balloon was inflated using approximately 20cc of air so as to retain the catheter. Urine in the bladder drained into a receiver.

The open end of the catheter was clumped using artery forceps and a needle puncture made along the catheter wall for injecting contrast media. This modification was necessary since the hospital lacked the normal infusion 250mls contrast packages. Several 20cc syringes were filled with contrast media which was then injected into the bladder through the needle puncture under screening. The bladder was observed during the filling phase for site, size shape, condition of the wall, any fistulous communications and reflux into the uretus.

When the bladder was reasonably distended, spot films were obtained as follows:-

- postero-anterior projection of bladder,
- left anterior oblique projection,
- right anterior oblique projection.

The last two projections were done to expose the vessico-ureteric junction in order to reveal minimal reflux.

Additional contrast was then injected into the bladder until there was an urge to micturate or excessive lower abdominal pain. The catheter was then removed and the patient allowed to pass urine in anterior oblique position so as to observe the urethra in profile. Spot films of urethra and bladder were taken. The patient was then requested to interrupt micturation so as to assess the degree of voluntary control and presence of reflux under stress. Lastly the patient was allowed to pass urine exhaustively before obtaining a post-micturate film of the bladder. A film that includes the kidney, ureters and bladder area was then taken. The films were processed for reporting.

For children of age 5 years and below, a naso-gastric tube (5F) was inserted into the bladder and fixed to the penis using an adhesive tape. The rest of the procedure was the same. These films were reported with the help of the supervisor.

The major features looked for were:-

- 1). ability of bladder to initiate micturation,
- 2). any fistulous communication,
- 3). filling defects,
- 4). any obstruction to urinary flow and its complications.

## RESULTS

The relevant data from the 82 patients examined were analysed as given in the tables of results. Out of the 82 patients investigated, 3 were females. 10 were children of age group 10 years and below while the rest were adults.

In 10 patients the age was indicated in the form only as adult, in which case the patients could not be grouped into any specific age group. Twenty-three out of 82 patients (28%) who presented for examination had no history given in the forms except for the working diagnosis. Six out of these 23 were in the age group of 10 years and below.

Age group 10 years and below, the major complaints were dribbling of urine (4 patients) recurrent urinary tract infection (3 patients) haematuria (one patient) and traumatic rupture of the urethra during surgery. Four patients had previously been operated for repair of anorectal malformations.

In age group 11 years and above, clear history suggestive of obstruction was given for 34 patients. Seventeen patients had no clinical history given in the request form. The remaining 12 patients histories had dribbling urine as the major features. The other associated features were recurrent urinary tract infection, frequency, dysuria, previous discharge per-urethra, previous passage of sounds.

In age group 0 - 10 years the most frequent diagnosis clinically was posterior urethral valves (42%), urethral stricture (15.8%) and incontinence (26%). Fistulous communication at different levels accounted for the rest. In age group 11 years and above urethral stricture was the most common clinical diagnosis (71.2%), incontinence (11%) and prostatic enlargement in (4.7%) as illustrated in the tables.

Radiologically the most frequent diagnosis was posterior urethral valves (ref.table 4). All the abnormal fistulous communications (21.6%) were due to post-surgical complications. Three cases were between bladder urethra and rectum while one case was between urethra and rectum.

Of the patients with strictures in this age group, one had congenital meatal stenosis. One patient had been bitten by a dog and the phalus amputated. This patient was draining through a suprapubic catheter and an attempt to micturate after filling the bladder was unsuccessful.

In age group 11 years and above the most common radiological diagnosis was urethral stricture (58.9%) as shown in table 5. It is noteworthy that one female patient had VVF, one patient had false passage, three had filling of cowpers ducts, one filling of seminal vesicle and prostate utricle was seen in one case.

Forty-nine out of the 82 patients were done micturating cystourethrogram. Only 5 patients had reflux, 4 of them age group 0 - 10 years and one was an adult. All the 19 children were investigated using micturating cystourethrogram. Bladder diverticula were seen in 2 patients with posterior urethral valves.

Age group	Males	Females	Total
12 - 10	18	1	19
11 - 20	6	-	6
21 - 30	16	1	17
31 - 40	10	1	11
41 - 50	8	-	8
517	11	-	11
Adults	10	-	10
Total	79	3	82

Table 1:

Table showing male to female ratio in different age groups.

Clinical Diagnosis	Frequency	Percentage
Urethral stricture	3	15.8%
Post-urethral valve	8	42.1%
Incontinence	5	26.2%
Leakage of urine from areas other than urethra	3	15.8%

Table 2

Frequency distribution of primary clinical diagnosis in the 19 patients below 11 years of age.

Clinical Diagnosis	Frequency	Percentage
Urethral stricture	48	76.2%
Benign prostatic hypertrophy	3	4.7%
Ca-bladder	2	3.2%
Cystocele	2	3.2%
Incontinence	7	11.1%
Bladder mass	1	1.6%
Total	63	100%

Table 3:

Frequency distribution and percentages of the given different primary clinical diagnosis in patients 11 years and above.

Diagnosis	Frequency	Percentage
Post-urethral valve	7	36.8%
Fistulous communications	4	21.6%
Bladder neck obstruction	2	10.5%
Stricture of urethra	2	10.5%
Neurogenic bladder	1	5.8%
Normal	3	15.8%

Table 4:

Frequency distribution and percentages of radiological diagnosis in patients 0 - 10 years.

Diagnosis	Frequency	Percentage
Urethra stricture	37	58.9%
Prostatic enlargement	9	11.1%
Normal	10	16.2%
Post urethral valve	1	1.58%
Neurogenic bladder	1	1.58%
Bladder neck obstruction	1	1.58%
Urethral filling defects	2	3.0%
Abandoned investigation	2	3.0%
Total	63	100%

Table 5:

Frequency distribution and percentages of different radiological diagnosis of patients 11 years and above.



It is important to note that 3 patients with urethral strictures had filling of the accessory ducts of seminal vesicle and cowper's glands. In 4 cases of stricture, there were patients with abnormal leakage of urine to the subcutaneous tissue of skin surface. One case of probable bladder calculus was seen.

Age	No. of stricture	Percentage
0 - 10	2	5.24%
11 - 20	1	2.6%
21 - 30	14	35.9%
31 - 40	6	15.3%
41 - 50	3	7.8%
517	4	10.4%
Adults	9	23.1%

Table 6:


Frequency distribution on urethral stricture versus age.

\*Note that 6 out of 39 patients had multiple strictures. No specific age group was given.

Clinical presentation	No. of Patients
Straining and retention	22
Discharge (previously)	17
History of previous surgery	4
No history except for clinical diagnosis	10
Dribbling of urine	1
Failed P.O.S.	2
Pain	
Road traffic accident	1

Table 7:

The major clinical representation for patients positively diagnosed to have urethral stricture.



Histogram showing percentage distribution of strictures with site. There are a total of 48 strictures with 6 patients having more than one stricture out of 39 patients.

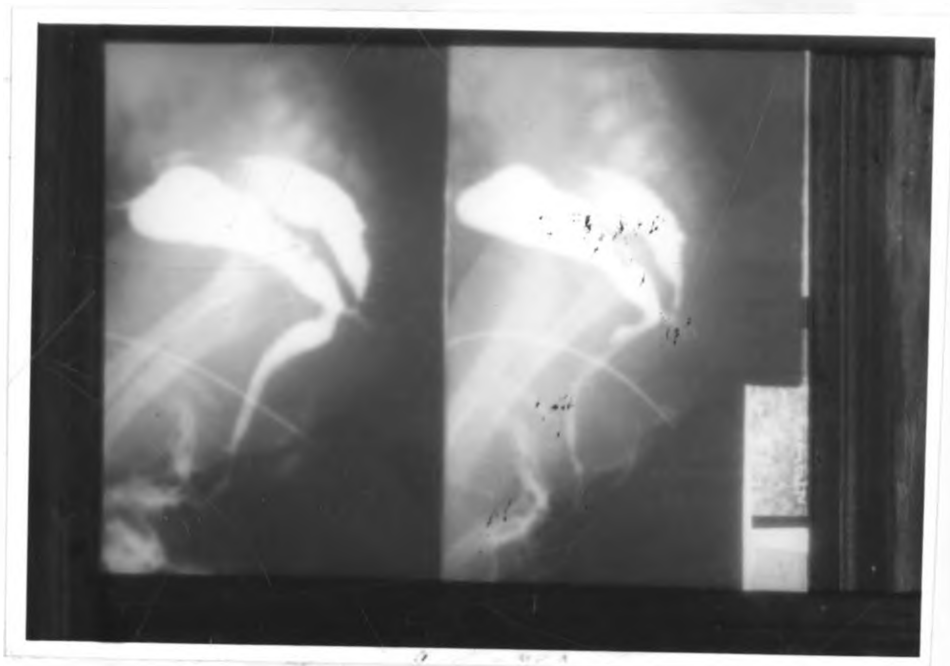


Illustration 1

1½ month old child who was done anoplasty. This patient developed a fistula between rectum and urethra.

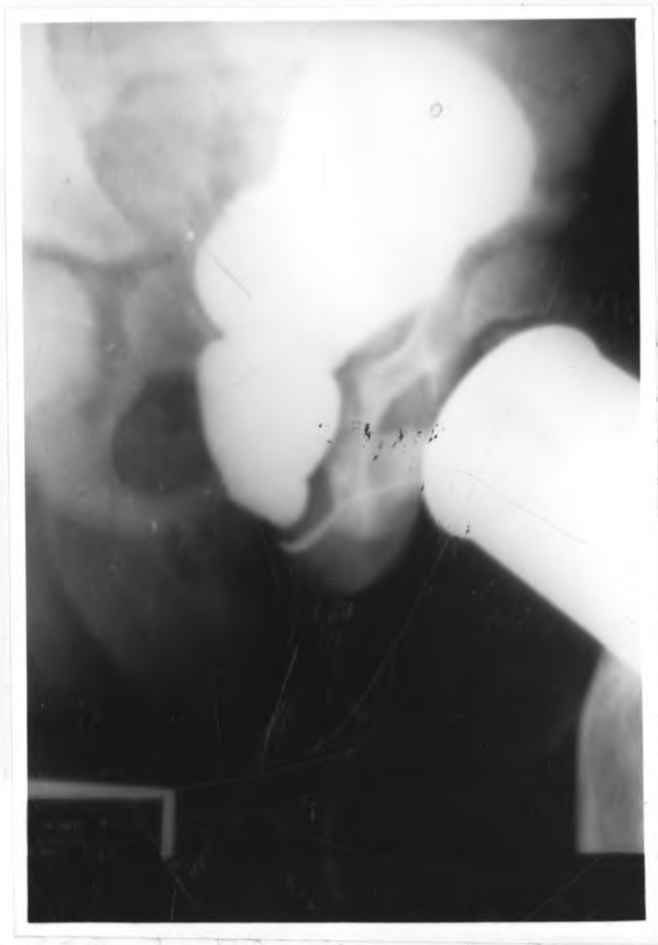


Illustration 2

A 10 year old boy with Posterior Urethral Valves showing dilated Posterior urethra. This patient had been unsuccessfully operated on previously.

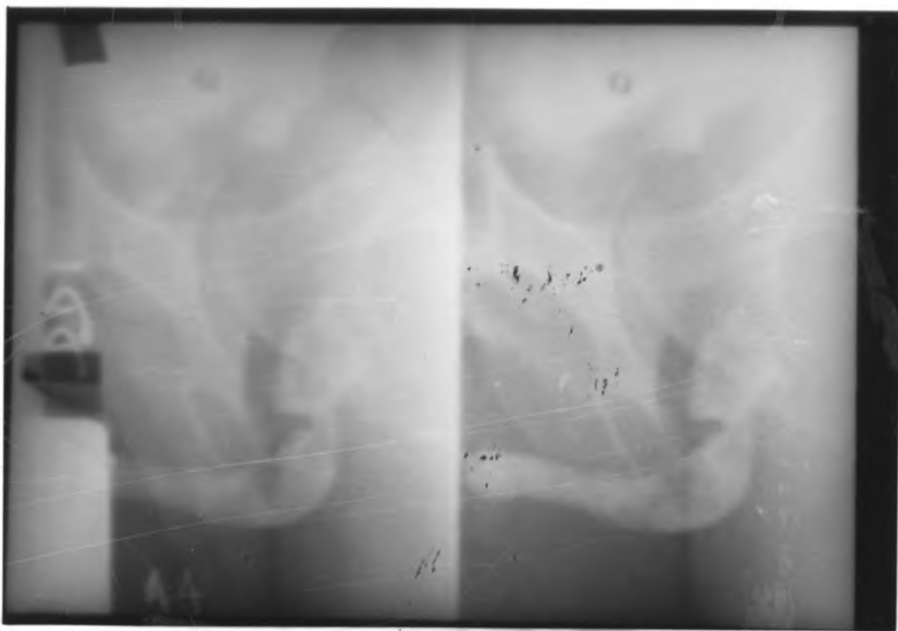


Illustration 3

Multiple paraurethral filling defects indicative of either pus pockets or clots. This patient has had passage of sound on several occasions following urethral stricture.

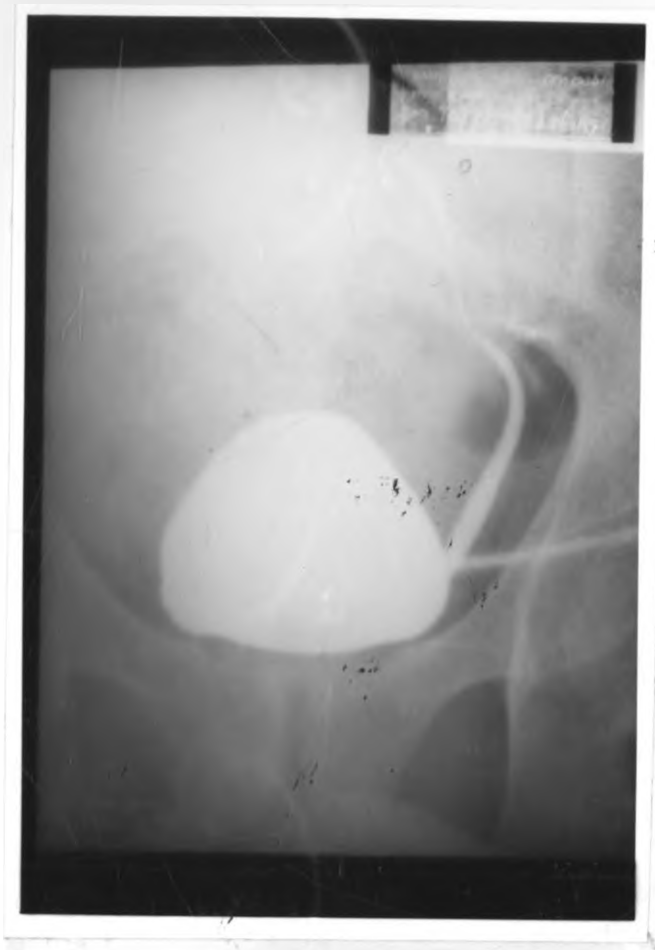

Illustration 4

An example of vescico-ureteric reflux. This patient has had 12 years of obstruction due to urethral stricture. There is a suprapubic drainage tube.

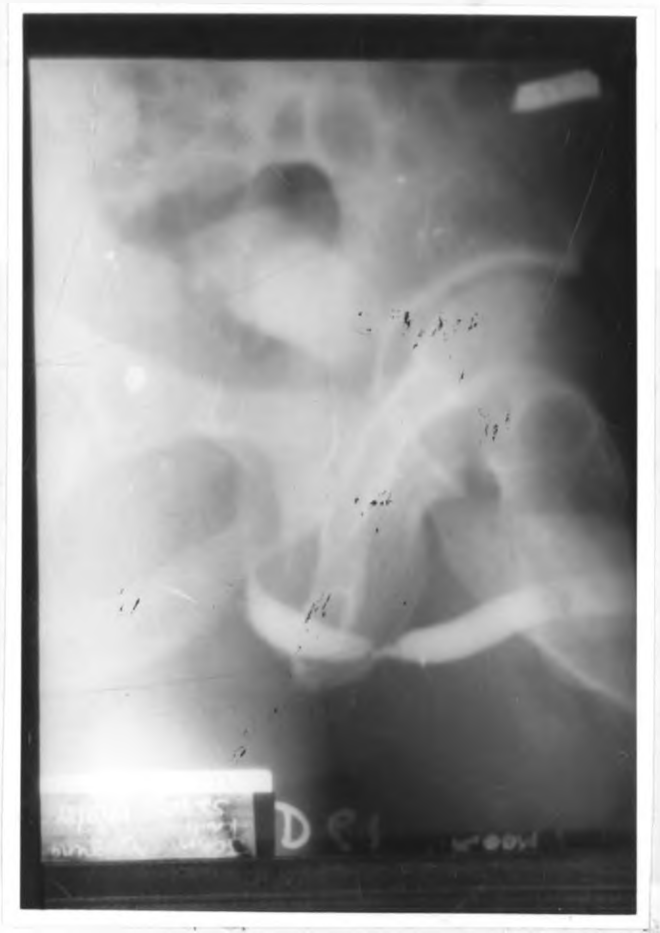

Illustration 5

A single stricture in the bulbous urethra. This patient has a previous history of urethritis.



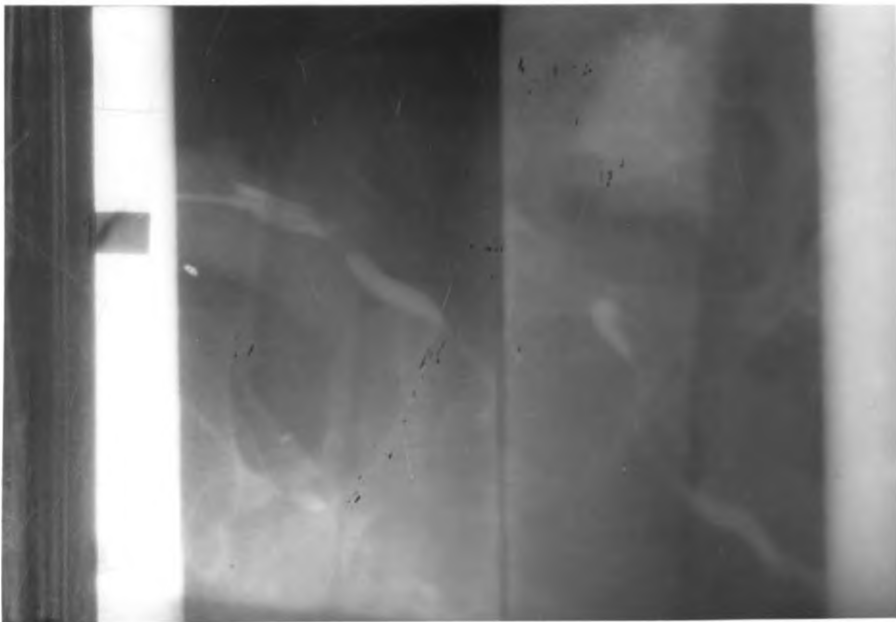


Illustration 6

A long stricture in the prostatic bed following prostatectomy.

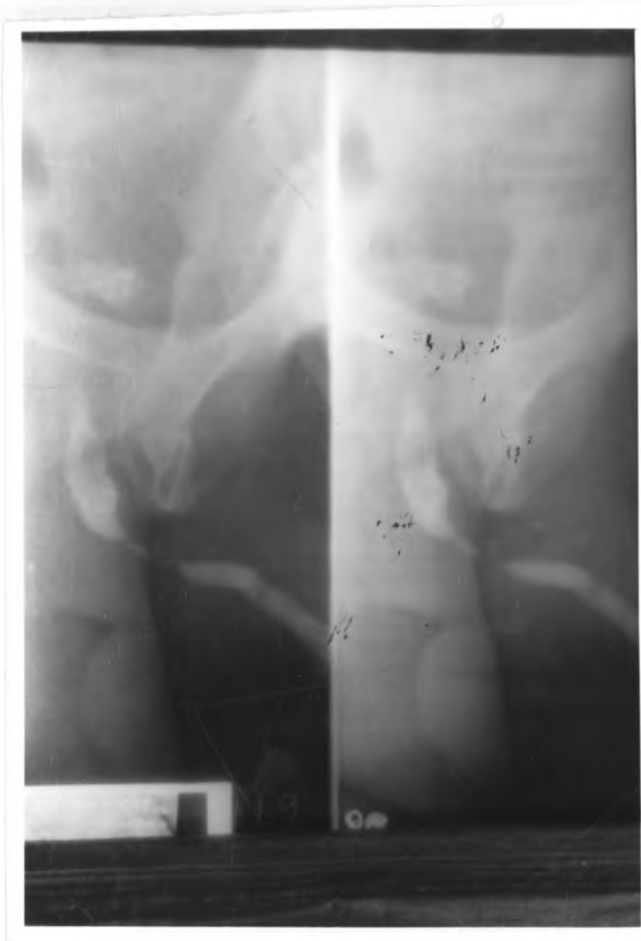

Illustration 7

An example of multiple strictures ( two in number) in the bulbous urethra. This patient had previous urethritis.



Illustration 8

Fistulous communication between urethra, scrotum and perineum.  
30 year old male patient with a long standing history of urethral stricture  
following several bouts of urethritis.

MEDICAL LIBRARY  
UNIVERSITY OF NAIROBI

...../23

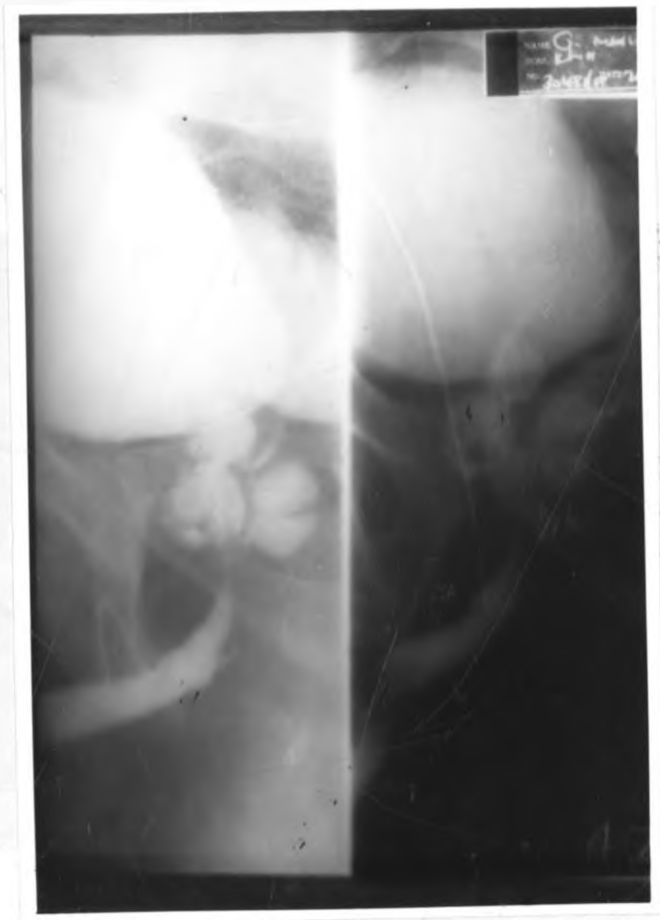

Illustration 9

A 60 year old male patient showing the filling of the paraurethral ducts and their glands.

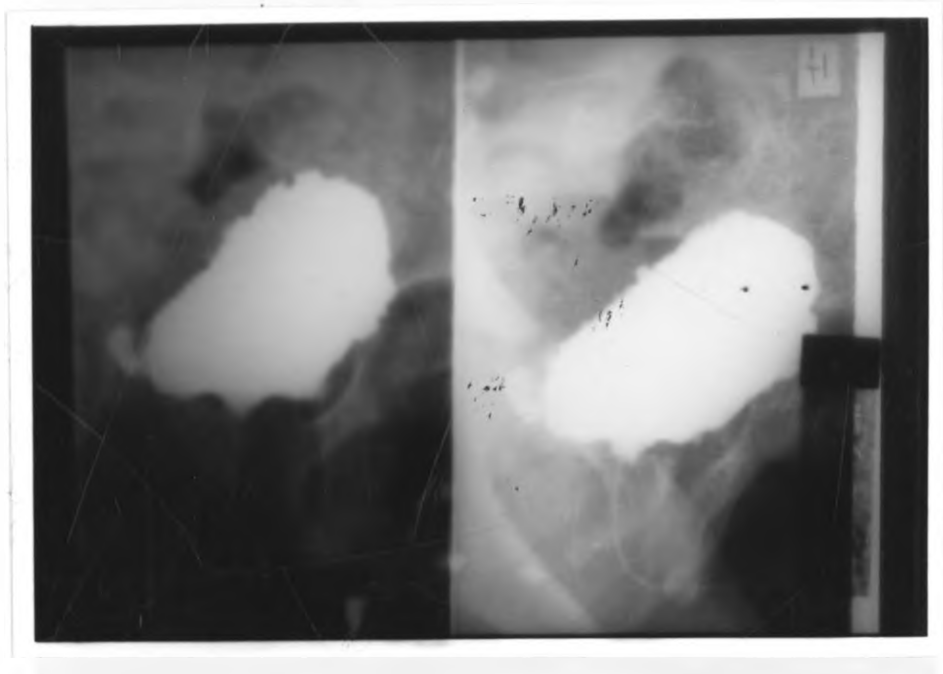


Illustration 10

Bladder trabeculations and diverticular demonstrated in a patient with bladder outlet obstruction.

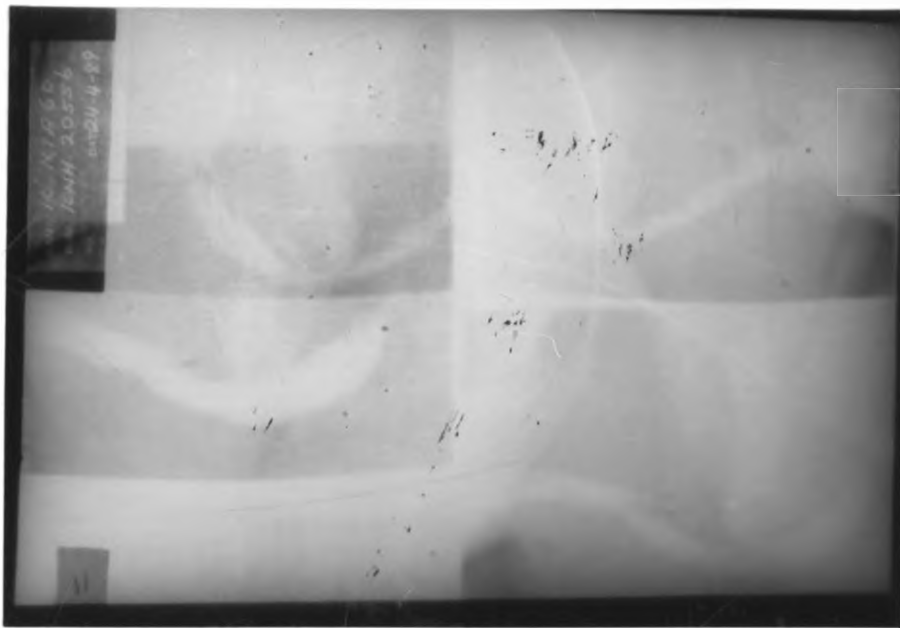

Illustration 11

False passage demonstrated in a patient had P.O.S. done following urethral stricture.

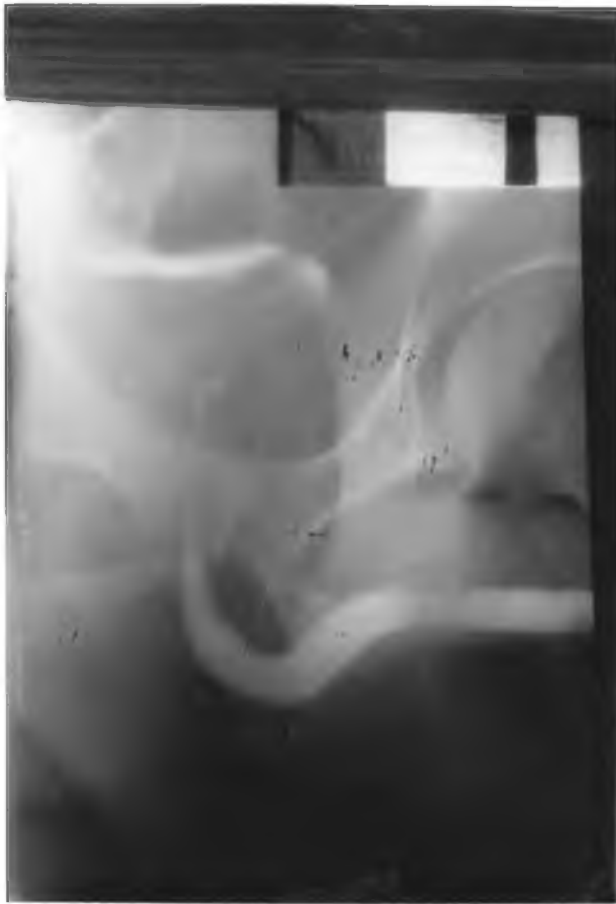

Illustration 12

Stretching of the urethra in a patient with prostatic hypertrophy.

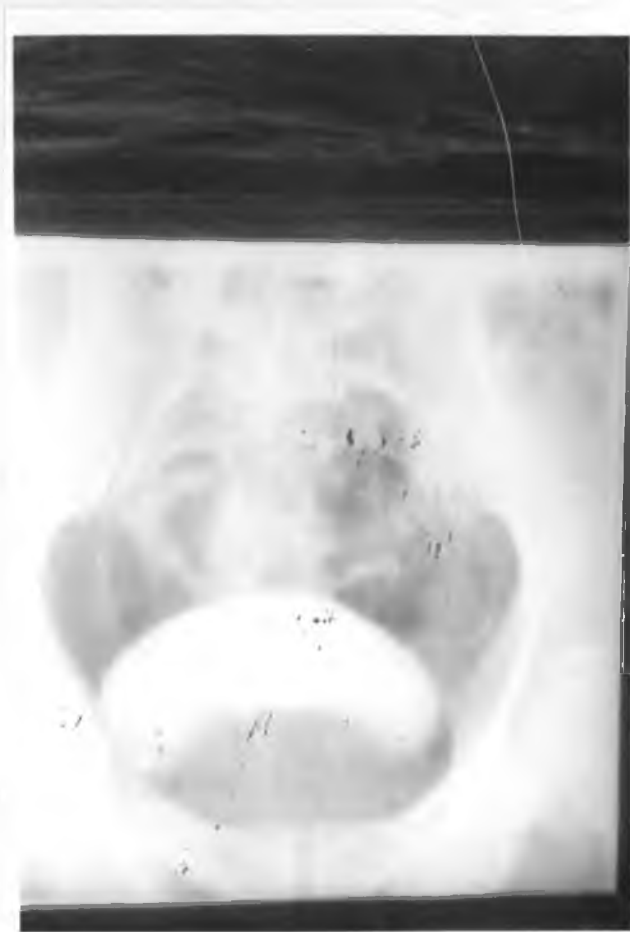


Illustration 13

Inferior impression on the bladder due to prostatic hypertrophy.



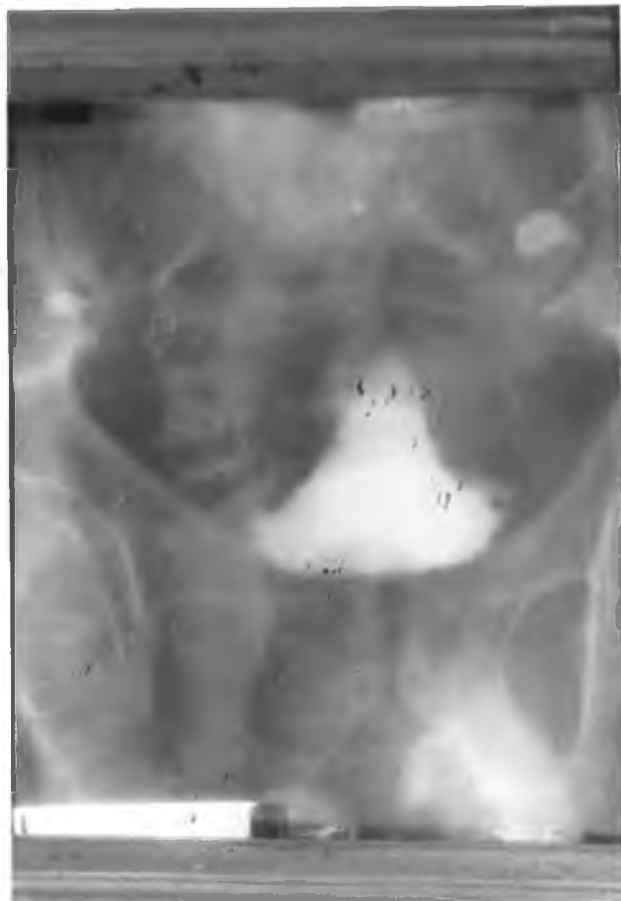

Illustration 14

Pine tree appearance in a patient with neurogenic bladder.

## DISCUSSION

Lower urinary tract obstruction is a condition characterized by difficulty in passing urine. The abnormality is found anywhere from bladder outlet to the urethral meatus. It may be neurological, mechanical or anatomic (19). The predominant causes of obstruction are different with regard to ages. This study therefore has shown the different abnormalities as seen radiologically in our set up at Kenyatta National Hospital. Posterior urethral valve is the major cause of obstruction in children 10 years and below, while urethral stricture is the major cause in people 11 years and above.

The lower urinary tract consists of the bladder and urethra. Embryologically, the allantois, hindgut and mesonephric duct opens in the cloaca. In the cloaca, proctodeum is separated from the endodermal tissue by the cloacal membrane. The urorectal septum migrates caudally dividing the cloaca into the posterior rectal sinus and anterior urogenital sinus. The perineum is formed by fusion of urorectal membrane and cloacal membrane (14).

Urogenital sinus differentiates into 2 segments:-

- 1). vesicle urethral canal - This forms the urinary bladder and proximal portion of the urethra.
- 2). Definitive urogenital sinus - Here is where the main urethra develops from.

The mucosa of the urethra develops from the endoderm while trigonal mucosa is mesodermal. Normally the bladder is intrapelvic between the pubic symphysis anteriorly and rectum posteriorly. The pelvic floor forms the inferior border. The ureters open at the base while the urethra also originates from the base.

The bladder is usually slightly abdominal in children attaining its normal pelvic position at 20 years of age (8). The mucosa is smooth when bladder is distended and thrown into folds when bladder is relaxed. However, the trigonal mucosa remains smooth even during relaxation phase. The trigonal mucosa is continuous with the internal sphincter and therefore works as a unit. The intraureteric ridge forms the cephalic border of the trigone. The angle of insertion of the ureter to bladder and the presence of Waldeyer's ring forms uni-directional valvular element, thus preventing reflux in normal circumstances (8,27,36).

The male urethra is divided into two major portions (25,27) thus posterior and anterior. The posterior part comprises of the prostatic and membranous urethra while the anterior part is divided into bulbous and pendulous urethra. The prostatic urethra starts from the bladder neck upto the distal end of the verumontaneum. It is averagely 3cm long and horse shoe shaped with anterior concavity due to presence of verumontaneum which is posteriorly placed (approximately 3mm high and 15 - 17mm long).

The prostatic sinuses which are depressions beside the verumontaneum are perforated by the prostatic ducts from the lateral lobes of the prostate. Distal to these are colliculus seminalis where the prostatic utricle and ejaculatory ducts open. The membranous portion is short and starts from the end of the verumontaneum to the bulbous urethra. It pierces the urogenital diaphragm, measuring about 2.5cm in length. The urogenital diaphragm is located at about 1cm distal to the verumontaneum. Its other anatomical landmark is that it is approximately 2.5cm below and behind symphysis pubis. The urogenital diaphragm marks the position of the external sphincter. It is the narrowest part of the urethra.

Bulbous urethra begins from around the urogenital diaphragm and ends at the peno-scrotal junction. It has a proximal cone shape. Pendulous urethra begins from the peno-scrotal junction to the meatal opening. It is narrower than the bulbous since it is suspended by the suspensory ligament.

Voiding is controlled by 2 types of sphincter thus -

- Two smooth muscles
- One striated muscle

The two smooth muscle sphincters are:-

- 1). internal sphincter around the bladder neck.
- 2). intrinsic sphincter around the distal prostatic and membranous urethra. These two control passive continence.

The striated muscle sphincter surrounds the intrinsic sphincter and is under somatic control. Continence is provided in conjunction with pelvic floor muscles.

Female urethra is about 4 - 6cm in length, pierces the urogenital diaphragm, opening at a position approximately 1cm posterior to the clitoris. The ducts of the glands of skene open into it. Innervation of the bladder is through the sympathetic system  $L_1$  and  $L_2$  and sacral autonomic  $S_2, S_3$ . Afferent supply is either through sympathetic into the dorsal nerve routes  $L_1, L_2$  and lower T; or along the sacral autonomic into sacral dorsal nerve routes. Cortical control is at the medial aspect of the cerebral hemisphere in the motor area. The path of afferent fibres is unknown (38).

Physiology of micturation is under both passive and active control (38). When the sympathetic system is stimulated, the bladder relaxes and sphincters contract. These two events lead to urinary accumulation. The afferents then record bladder fullness and pain during distensions. At a certain limit this leads to relaxation of the sphincters and detrussor stimulation which

- 32 -

is followed by bladder emptying. Voluntary micturation then takes over through increased intra-abdominal pressure mediated by contracting abdominal wall muscles.

This anatomic and dynamic function of the lower urinary tract is demonstrated through various methods by use of contrast media. In early parts of this century and before, air was used as a negative contrast agent to demonstrate the bladder. However it proved difficult since there had to be a gas-less and stool-free rectum coupled with dangers of air embolization (34a).

The positive contrast media initially used were iodinated oily contrast media mainly lipiodol and sodium iodide which was water soluble. Oily contrast media was avoided due to risk of embolization. Sodium iodide (concentration 7 - 12%) was avoided due to associated iodism and chemical cystitis. Sodium iodide for intravenous urography was initially introduced by Rowntree around 1930's (34).

Binz and Vonlichtenbergl introduced some iodine-pyridine compounds around 1930's which were later used for cystourethrography e.g.

1. Uroselectan B (Disodium salt of 3.5 diiodo-4-pyridoxyl-N-methyl-2.6-dicarboxylic acid. Molecular weight 493.51% iodine) (34a).
2. Per-Ambrodil 3.5 diiodo-4-pyridone-N-acetate of diethanolamine 51% iodine by weight (34a).
3. Iodoxy-(N-methyl 3.5 diiodo-4-pyridone-2.6 decarboxylic acid) causes local irritation (34a).
4. Diodone-(Diethanolamine salt of 3.5-Diiodo-4-Pyridone-N-acetic acid (34b)).

This was the most commonly used contrast media only replaced recently by more conventional forms of urographic contrast medius. Concentration of 15 - 50% was used depending on patients size.

5. Visco-Rayopake (2,4-dioxo-3-iodo-6methyl tetrahydropyridine-N-acetic acid with diethanolamine polyvinylalcohol gives the viscosity base) (21).

Barium sulphate 15 - 20% concentration has also been used. Its contra- indications are:-

- 1). diverticular disease,
- 2). residual urine more than 30cc
- 3). vesicle ureteric reflux

In view of the above three, its use in cystography was discontinued (36a & b).

6). More recently water soluble sodium, or methylglucamine, or a combination of sodium and methylglucamine salts of diatrizoates, isothalmates and metrizoates have been used. These are iodinated compounds, used in iodine concentration of about 30%.

The advantage of the water soluble contrast media is their ability to adhere to the mucosal surface and show even minute details. They are also less toxic when absorbed into the body.

## GENERAL CONSIDERATIONS

The predominant abnormalities encountered in children differ from those in adults. In children, the abnormalities are mainly developmental while in adults they are mainly acquired. This study has confirmed this by showing that posterior urethral valvular lesion is the more frequent obstructing lesion in children while in adults, it is acquired urethral stricture. (Table 4,5).

Another important observation is the lack of adequate history from the referring doctors. It has been shown that 28% of all patients had no history given in the form except for the working diagnosis. This is an area that needs improvement since a fair interpretation of results depends on the history given. Age specification should also be stressed since it is known that certain diseases occur at certain given age limits.

Generally the major causes of obstruction are as follows:-

### Children

- 1). Urethral valvular diseases mainly Posterior Urethral Valve
- 2). Neurogenic bladder dysfunction
- 3). Diverticula
- 4). Urethral stricture
- 5). Calculi and foreign bodies
- 6). Tumours
- 7). Congenital bladder neck hypertrophy.

Other minor causes include ectopic ureterocele, phinosis, meatal stenosis and urogenital sinus abnormalities.

### Adults

- 1). Urethral stricture
- 2). Prostatic enlargement
- 3). Neurogenic bladder
- 4). Tumours of bladder, urethra and surrounding areas
- 5). Calculus and foreign bodies
- 6). Urethral injuries (Acute)

The patients usually present with straining, poor urinary stream, overflow incontinence and recurrent urinary tract infection. Children sometimes present with failure to thrive coupled with diarrhoea and vomiting. Adults will present with the above symptoms in addition to hesitancy, intermittency, frequency and nocturia. They may also present with either of the following:-

- symptoms related to primary pathologic disturbance leading to obstruction e.g. haematuria in patients with stones or tumours
- symptoms related to abdominal mass
- symptoms that relate to renal failure or infection

The majority of adult patients included in this study presented with a history of urethritis. Two patients had been treated unsuccessfully with passage of sounds, four patients had been operated in the relevant area; mainly by prostatectomy. One patient had been treated for traumatic rupture of the urethra. Leakage of urine as a possible complication was seen in two patients clinically.

The physical findings usually depend on cause but there may be palpable bladder and other abdominal masses. There are no specific characteristic findings on urinalysis or blood chemistry that directly points to lower urinary tract abnormality. They only point to renal failure.

The study has shown that the most common clinical diagnosis necessitating investigation were as in Table 2 for children and Table 3 for adults.



Posterior urethral valves (42.1%) and incontinence (26.3%) cases were the majority in children. In adults approximately 76% of patients presented with a clinical diagnosis of urethral stricture, 11% with incontinence and 4.7% with prostatic hypertrophy. The rest are minor.

Obstruction can be diagnosed in utero using ultrasonography by demonstration of enlarged bladder, hydronephrosis and oligohydramnios. They may have associated hypertrophy of detrussor muscles, urinoma, urinary ascitis and pulmonary hypoplasia.

Usually the diagnosis is dependent on one of the following:-

- 1). Demonstration of abnormal retention of urine by recovery through catheter
- 2). By visualization of dilated upper urinary tracts and delayed drainage through intravenous urography
- 3). By showing abnormal retention of contrast instilled by retrograde fashion
- 4). Demonstration of obstructing lesion by either cystoscopy, or, ascending urethrography, or, micturating cystourethrography
- 5). X-ray visualization of calculus
- 6). Demonstration by cystogram of secondary changes due to obstruction such as trabeculation and diverticulum in the bladder
- 7). More recently by doing cine/pressure/flow studies to demonstrate the level of obstruction by pressure differences and flow rates

Using the above observations, an attempt should be made towards making a definitive diagnosis of the lesion causing obstruction. All complications of obstruction should be looked for and documented. This study has positively diagnosed posterior urethral valves in 36.8% of all children and the rest follow as given in Table IV. This compares well with other studies (Flecher's E.W.) (17), which showed that posterior urethral valves is the main cause of obstruction in children (7 out of 11 studied). In the same study one patient had neurogenic bladder, one had bladder neck obstruction due to sacrococcygeal neuroblastoma and one had epispadias. The present review is comparable to the above since it has also revealed

one case of bladder neck obstruction due to a tumour in the perineal area, and one case neurogenic bladder. Two patients had urethral stricture, one due to previous operation and the other due to dog bite with consequent amputation of the phalus. For the latter patient micturating cystourethrography was attempted through a suprapubic catheter since no catheter could be passed through the urethra. Four children had abnormal fistulous communications demonstrated, (illustration ). Three were between the rectum and bladder and one between urethra and rectum. These were thought to be due to surgery for repair of anorectal malformations however, these communications have been known to be due to ectopic anus as a result of adequate migration of urorectal septum that separates the urogenital sinus and the rectum (8,14).

The radiologically positively diagnosed conditions in adults are shown in Table V. Urethral stricture forming the majority with 58.9% followed by prostatic enlargement, 11.1%. 16.2% were normal. There was one case of posterior urethral valve beyond 10 years of age. This patient had previously been operated upon and the valve supposedly resected. However, on later re-examination, the valves were intact (illustration ). Failure of resection is a known phenomenon and some patients have been operated more than once. There was one case of neurogenic bladder following a road traffic accident. There were also two patients with paraurethral filling defects. These were thought to be pus pockets, however there was no pus discharge observed from the urethral meatus (illustration ).

#### POSTERIOR URETHRAL VALVES

This is the most common obstructive lesion seen in childhood. It is mainly a disease of boys. The majority usually present in the first year of life as shown by Naithoo (50%) (29), a figure which compares well with 56% in the

the present study. In Harare they diagnosed 39 cases in 13 years, which is an average of 3 cases per year (29). The same author also states that in Nigeria and Sudan they diagnose an average of 7 cases per year. This compares well with the present study which has diagnosed 7 patients in one year. These patients usually present with straining on micturation, incontinence and recurrent urinary tract infection. The present study positively diagnosed 7 patients, 4 of whom presented with a history of recurrent urinary tract infection, 3 with a history of incontinence and 2 had no history attached.

Valves are congenitally abnormal structures of unclear origin. They were first demonstrated radiologically by Burns in 1916 and classified by Young et al in 1939 into three types (18).

Type I Flat with a central hole

Type II Single flap originating from one side of the urethra

Type III Two flaps from both opposing sides of the urethra

Tolmatschew (1870) and Williams (1968) suggested that these were mucosal ridges which usually develop when the urethra is about 50mm, then sweep downwards and laterally from verumontaneum to fuse anteriorly (18).

Baxy (1930) thought that the valves were remnants of urogenital membranes. Lawsley (1914) postulated that they were anomalous junctions of prostatic utricle and urogenital duct. Watson (1921) thought that they were fusion of epithelium with the dorsal walls of urethra. Monie (1921) thought that they were congenital narrowing of urethra causing mucosal prolapse during micturation.

The hallmark of diagnosing posterior urethral valves is micturating cysto-urethrography where the dilated posterior urethra must be shown (9). Usually the patient is catheterized upto the bladder for injection of contrast. There should be no resistance during catheterization since the valves collapse on the wall, and due to the same reason ascending urethrography will always be normal. Once the bladder is full and bladder views have been obtained, the patient is then allowed to pass urine. The valves will then be demonstrated as dilatation of posterior urethra usually with distal tapering. Linear lucencies may occasionally be seen along the margins of the valve cusps within the dilated posterior urethra (illustration ). If the valves are of the diaphragmatic type then there will be very little to differentiate it from a urethral stricture.

The complications that can be demonstrated are like those in any other form of lower urinary tract obstruction, however, it is important to note that vesico ureteric reflux (Illustration ) occurs in a high percentage of these patients (  $2/3$  ) (8,9). The present study has shown that about half of the positively diagnosed patients with posterior urethral valves had reflux. The definitive treatment is by resection. The prognosis is poor if diagnosed in the first few weeks of life due to in-utero renal damage. This developmental anomaly may sometimes be associated with renal dysplasia, prune-belly syndrome and pulmonary hypoplasia.

#### URETHRAL STRICTURE

This is an abnormal narrowing of the lumen at any level from bladder outlet to meatus. It is the commonest cause of lower urinary tract obstruction in adults, approximately 58% in the present study. Strictures are either congenital or acquired. Congenital strictures are very rare and may be part of the prune belly syndrome or in association with anal atresia (36).

Acquired strictures are either:-

- post-traumatic
- post-inflammatory
- due to tumours

The majority of these patients usually present with difficulty in passing urine and previous infections (Table VI). This is usually a disease of young adults as confirmed in our study where 51% were in the age range of 21 - 40 years. In this study 9 out of 37 patients positively diagnosed could not have their proper ages ascertained, and therefore were referred to as adults.

#### DIAGNOSIS

The diagnosis of urethral strictures depends on the demonstration of the narrowed segment (illustration ). This can be done either by performing an ascending urethrography or micturating cystourethrography. Micturating cystourethrography is more accurate since it will show pre-stenotic dilatation even in very minor cases of obstruction. In such cases ascending may be normal.

Strictures can either be long or short. They could also occur singly or multiply. The long strictures are usually associated with trauma. This includes both accidental and iatrogenic forms. In case of treatment, usually the stricture follows surgery, especially prostatectomy (illus. ) or it may follow a long duration of catheterization. The short strictures are usually post infective and may sometimes be multiple (illustration ). In this study the majority of the patients (70%) had single strictures.

The major known complications seen in patients with urethral stricture are same as those seen in patients with any form of lower urinary tract obstruction. These include fistulous communications between the urethra and perineum or scrotum (illustration ), filling of the paraurethral ducts and their glands due to back pressure effect (that is the seminal vesicles and the prostate) (illustration ). This only occurs in presence of obstruction (10,11), bladder trabeculations and diverticula, vesicle-ureteric reflux (illustration ). Of all the adults examined with micturating cystourethrography only one had reflux demonstrated. False passage due to attempted passage of sound was demonstrated in one patient (illustration ). Four patients had fistulous communications. Of these, one was post-prostatectomy, one had 1st stage repair of the urethra and two had watering can appearance.

#### POST INFLAMMATORY STRICTURE

The majority of acquired strictures are post-inflammatory with a history of previous urethritis (Adwok 71%, Campbell 90%) (1). They are usually short and are due to healing with fibrosis associated with shortening of the affected part. The periurethral glands are usually affected.

Strictures develop from a few weeks to several years after an episode of urethritis (1,11). Ghonococcal infection is the commonest cause of stricture formation (1,24) with some authors putting it up to 61% and non-ghonococcal 39% (Arya G.P.) (2). (Marcus R.T.) has also shown the importance of non-ghonococcal urethritis. The other organisms implicated are tuberculosis, schistosomiasis, trichomoniasis, strept-foecalis, viridans, albus, aureus (1,2). Ghonoccal infection is usually associated with anterior urethral strictures while the others are usually found posteriorly (36).

## POST-TRAUMATIC STRICTURES

These are usually associated with either fracture pelvis, direct trauma, instrumentation and following prostatectomy (36). Stricture following prolonged catheterization is usually found at the peno-scrotal junction. The history is usually clear in these cases.

Traumatic urethral injuries are classified into three different types both clinically and radiologically (32).

## CLINICAL CLASSIFICATION

- I. Incomplete - urethra intact but contused, thus the catheter can be passed
- II. Partial - there is a hole in the urethra - this can be shown by using pericatheter urethrography
- III. complete separation

## RADIOLOGICAL CLASSIFICATION

- Type I Incomplete - urethrography shows intact urethra, it is either compressed or contused.
- Type II Partial or complete tear present above the urogenital diaphragm, urethrography demonstrates leakage above the urogenital diaphragm therefore contrast in pelvis.
- Type III Partial or complete rupture below the urogenital diaphragm, contrast is seen in perineum or scrotum.

Type III is the commoner of the three.

## TUMOURS

These are not very common causes of obstruction and therefore are not discussed in detail. It is important however to note that carcinoma of bladder can develop as a result of longstanding urethral strictures (31). The incidence is about 4% and time lapse is approximately 1 - 33 years.

Hypertrophied verumontaneum may resemble a tumour. In this study there were two patients with round filling defects, may be tumours (illustration ).

#### PROSTATIC HYPERTROPHY

This is seen radiologically as stretching of urethra coupled with inferior impression on the bladder (illustration ). These patients usually present with retention of urine and (Stone D.G.J.) has shown that on rare occasions they may cause rupture of the bladder (35).

This is usually a disease of the elderly and in our study only those patients who are fifty years and above give these features.

#### BLADDER NECK OBSTRUCTION

Primary bladder neck obstruction is usually found exceptionally in males. It may also be secondary to ectopic ureterocele, bladder calculi, tumour of the prostate (especially Rhabdomyosarcoma) (9, 30).

Congenital bladder neck obstruction can be a cause or a result of obstruction (22) in which case there is the detrusor and bladder neck hypertrophy with consequent incontinence.

Classically, they present with poor stream, haematuria, infections and pain. In this study a case of impression around the bladder neck was encountered (illustration ). Usually bladder neck obstruction is shown by lateral view on micturating cystourethrogram (4).

#### NEUROGENIC BLADDER

These people have no obvious obstruction but rather loss of control of micturation due to neurogenic dysfunction. Complete lower motor neurone lesion produces large volume low pressure bladder which voids by straining. (illustration )



- 44 -  
Upper motor neurone lesions results into small volume high pressure bladder which voids reflexly.

### CONCLUSION

The following observations came out of with regard to this study:-

- 1). posterior urethral valve is the most comon cause of obstruction in paediatric age group.
- 2). post-inflammatory urethral stricture is common in adults (21 - 40 years) and benign prostatic hypertrophy in the elderly.

The complications here as anywhere else are fistulous communications and filling of periurethral glands and ducts.

High percentage of patients do ndot have proper history indicated in their request forms and therefore the difficulty of correcting radiological findings arise.

- 45 -  
BIBLIOGRAPHY

- 1). Adwok urethral stricture at  
Kenya National Hospital.  
E.A.M.J. March 1986 Vol, 63 No. 3
- 2). Arya O.P. Some highlights in aetiology  
of non-ghonococcal discharge in  
males in Kampala. E.A.M.J.  
No. 1972
- 3). Bates, C.P. & Gurney C.E. 1971 synchronous line/pressure/flow  
cystography. A method of routine  
hydrodynamic investigation. British  
Journal of Radiology 44:44-56.
- 4). Bateson E.M. bladder neck obstruction. The  
value of MCU in demonstrating  
this complication of urethral  
stricture. Brit. J. of radiology  
43:713-718 Oct. 1970.
- 5). Becker J.A. & Gregorie A. 1968 retrograde urethrography  
Journal of urology 100, 92-93
- 6). Brooks V. & Bateson E.N. cystourethrography in the  
University Hospital of West  
Indies. From department of  
surgery and radiology, University  
Hospital Mona Kingston & Jamaica.
- 7). Brondy M.L. New instrument for urethrography  
in males. Journal of urol.  
46, 350 - 354.
- 8). Caffey Paediatric x-ray diagnosis.  
Paper page (618-656) bladder and  
urethra 835-837.
- 9). Caffey Pp 1551 - 1552 Paediatric x-ray  
diagnosis.

- 40 -
- 10). Currarino & Fugua F. (1972) Cowpers glands in the urethrogram  
American Journal of Roentgenology  
116, 838 - 42
  - 11). De Lacey J., Gerald et al (Miami Florida)  
Urethral stricture and urethral  
rupture. Am. J. of Roentgenology  
1973 Vol. 119, 822, 31.
  - 12). De Lacey et al (St. Georges Hospital London)  
urethrography simplified, the  
drip infusion technique. Br.  
J. of Radiology 50, 138 - 140  
February 1977.
  - 13). Paul and Juhl  
Essentials of Roentgen  
interpretation.  
2nd Edition
  - 14). Fazana F.  
a textbook of medical embryology  
Normal and abnormal development  
pp 254 - 261.
  - 15). Flanagan James J.  
urethrography: recognition of  
cowpers glands and ducts. Clinical  
radiology (1982) 33, 71 - 73.
  - 16). Fitts F.B. Jr. et al  
criteria for examination of the  
urethra during excretory urethro-  
graphy: Radiology 125 (1) 47-52  
October 1977.
  - 17). Fletcher E.W.L.  
Retchiffe. Infirmary Oxford.  
Suprapubic MCU clinical radiology  
(1978) 29, 309 - 311

- 18). Gerald Friedland, William R. Fair, Duncan E. Govan and Roy Filly  
Department of radiology, diagnostic division and department of surgery urology division, Stanford medical centre, Stanford California. Posterior urethral valves: Clinical Radiology (1977) 27:367 - 380
- 19). Furgersson  
Clinical surgery, chapters 27,36 37, 38.
- 20). Hodges and Kaplan  
Year book of medical publishers 1948 pp 261
- 21). Hyman and Yulis G.B. 1965  
improved technique for male urethrography. Journal of urology 93, 62 - 63
- 22). Joseph Warkany:  
year book of medical publishers pp 1074 - 1079
- 23). Marcus R.T.  
East African Medical Journal Nov. 1966 Observations of urethral infections in males.
- 24). McCallum R.W.  
Interventional uro-radiology. Urethral disease and interventional cystourethrography.
- 25). McCallum R.W. (1979)  
Radiological clinics of North America XVII,II, 227 - 44 - the adult male urethra.
- 26). McDonald  
radiological clinics of North America
- 27). Meschan  
An atlas of Anatomy Basic to radiology pp 1012 - 1020.

- 28). Musau C.K. dissertation for M.Med. 1989 U.o.N.
- 29). Naitloo K.J. & J.M.S. Luyombya  
East African Medical Journal, clinical review of congenital urethral valves and their management in Harare.
- 30). Nelson's text book of paediatrics, pp 1152 - 1159 13th Edition
- 31). Owior R. East African Medical Journal, January 1975 - carcinoma of bladder and urethra in patients.
- 32). Ronald C. Allison  
Urethrography in pelvic trauma. From urology service, United States airforce medical centre, Keesler air force base, Missisipi  
Journal of urology 1974 June Vol. III.
- 33). Sabiston  
A textbook of surgery.  
pp 1731 - 1733
- 34). Shanks & Kerley  
textbook of x-ray diagnosis  
1945 pp 491  
1950 pp 714 - 16
- 35). Stone D.G.E.  
Archives of surgery 23:129, 1931  
spontaneous rupture of the bladder.
- 36). Sutton  
A textbook of radiology and medical imaging pp 1198 - 1207, 4th Edition
- 37). Thompson; J.W. & Rudge, N. (1968)  
Method of micturating cystourethrography in children. Journal of urology  
99, 116 - 117.
- 38). Wright  
Applied physiology, 9th Edition pp 767-773. Physiology of micturation.