

SICKLE CELL ANAEMIA

In Adults at the Kenyatta National Hospital,  
Nairobi, Kenya.

A description of the natural clinical  
course and the important pathological  
complications of homozygous sickle  
cell disease is given.

by P.M. MWANGEMI M.B., Ch.B. (Nairobi)

Submitted in part for the degree of  
MASTERS OF MEDICINE (M.Med.)

In Internal Medicine, of  
SICKLE CELL ANAEMIA

In Adults at the Kenyatta National Hospital  
Nairobi, Kenya //

by Dr. P.M. Mwangemi M.B., Ch.B. (Nbi.)

Dr. Philip Mwangi Mwangemi

19th April, 1979

University of NAIROBI Library



0324899 4

SICKLE CELL ANAEMIA

In adults at the Kenyatta National Hospital,  
Nairobi, Kenya.


" A description of the natural clinical  
course and the important pathological  
complications of homozygous sickle  
cell disease in adults".....

by P.M. MWANGEMI M.B., ChB. (Nairobi)

Submitted in part for the degree of  
MASTER OF MEDICINE (M.Med.)

In Internal Medicine, of  
UNIVERSITY OF NAIROBI.

I certify that this dissertation is my  
original work and that it has not been  
presented in any other University.

  
.....  
Dr. Philip Masege Mwangemi

15th April, 1977

## ACKNOWLEDGEMENTS

I wish to thank Professor W.H. Philip Hill for suggesting this topic.

I am greatly indebted to the following, whose support and encouragement made this study possible:-

To Doctors N.K. deleeuw, Tom Ogada and A.G. Kendall for special tutorials in Haematology.

To Dr. E.G. Kasili of the Department of pathology for coagulation studies referred to in the text.

To Professor L.R. Whittaker for the radiological reports.

To Mr. N. Bakker for ophthalmological consultation.

I am very grateful to Mrs. Elfreda Njenga for Secretarial assistance, the Sister-in-charge and all the nursing staff in the Haematology Clinic for their cooperation throughout the study.

My thanks go to Mrs. N. Ouna and Mr. Douglas Muchaba of the Department of Medicine for special haematological Laboratory work.

The photographs in the appendix were prepared by the Health Education Division of the African Medical and Research Foundation, and the technical assistance is gratefully acknowledged.

# C O N T E N T S

## INTRODUCTION

Methodology ..... 3

## RESULTS

Reports ..... 5

Haematological data .....11

DISCUSSION .....13

CONCLUSION .....23

## APPENDIX

Figures I, II, III .....25,26,27

Plates A - K .....28

REFERENCES .....38

## SUMMARY:

The clinical, haematological, radiological and other data were collected from 38 adults of both sexes and analysed with a view to describing the natural history of homozygous sickle cell disease at the Kenyatta National Hospital. The report demonstrates marked variability in the clinical features of sickle cell anaemia in the adult population.

The improved standard of living and the availability of health facilities have had a favourable influence on the clinical course of sickle cell anaemia at the Kenyatta National Hospital. In the steady state the chronic haemolytic anaemia was characterized by significant reticulocytosis. The other bone marrow functional elements were similarly active as evidenced by the neutrophil leucocytosis. Persistently low mean corpuscular volume (MCV) was found in 20% of the subjects who also had the microcytic hypochromic features on the peripheral blood smear consistent with iron deficiency. The dietary history confirmed nutritional iron lack, but it is planned to screen the family members for the S-beta-thalassaemia trait in a future study.

The clinical spectrum of sickle cell anaemia in these adults is characterized by the vascular occlusive crises and multi-organ pathological complications both of which constitute an important reason for hospital admission. Avascular femoral head necrosis, chronic osteomyelitis, leg ulceration and cholelithiasis contributed significant morbidity. Severe chronic haemolytic anaemia on the other hand was the cause of fatal intractable heart failure in one case and most likely was contributory to the second death reported in the present series.

It is hoped that this report will stimulate more interest in the clinical aspects of sickle cell anaemia in East Africa. Now that the biochemical studies have made such great strides, it is only fitting that more attention should be directed towards the practical application of these technological advances.

## MATERIAL AND METHODS

It was planned that 40 adult subjects be available for this study during the period 1st June, 1971 to 31st December, 1976. Each subject would be registered and interviewed about the symptoms of the disease, family history, and clinical features. A complete physical examination would be done and the investigations planned.

## INTRODUCTION

A prospective clinical study of the adults with sickle cell anaemia was suggested in May, 1975 by Dr. W.H. Philip Hill of MC Gill University, Montreal, Canada, when he was in Nairobi as a visiting Professor of Medicine. It was proposed to report the clinical and haematological data of homozygous sickle cell disease during a period of 18 months till December, 1976.

In each case the diagnosis of the sickle cell anaemia was to be established on clearly defined criteria:- Chronic haemolytic anaemia, a positive sickling test, and the cellulose acetate haemoglobin electrophoresis demonstrating S, F and Hb<sub>A2</sub> only. The peripheral blood film was to show the typical diagnostic features of sickle cell anaemia as well. The adults of both sexes defined as those aged 15 years and above, were to be interviewed at the Haematology Clinic of the Kenyatta National Hospital on two monthly appointments at first but it was envisaged that longer clinic appointments would be made to coincide with the school holidays where this was thought necessary. The main source of the referrals to the clinic was to be the health institutions in Nyanza, Western and Coast Provinces which have the highest sickle cell rates in Kenya (1). The haematological studies would be carried out in the Department of Medicine laboratory but the general laboratory data would be obtained from the main Hospital (K.N.H.) Clinical pathology laboratories.

## OBJECTIVES

- (a) To describe and where possible quantify the clinical features of sickle cell anaemia in the adults at the Kenyatta National Hospital, Nairobi.
- (b) To document the multiorgan pathological complications of sickle cell anaemia.
- (c) To assess the significance of the modifying factors in sickle cell anaemia.

## CLINICAL MATERIAL AND METHODOLOGY

It was planned that 40 adults would be available for this study during the period 1st June, 1975 to 31st December, 1976. Each subject would be registered and interviewed about the symptoms of the disease, family history, and dietary intake. A complete physical examination would be done and the investigations planned:-

The venepuncture blood samples anticoagulated with ethylene diamino tetra acetic acid (E.D.T.A.) was obtained during each visit for the coultergram and reticulocyte count. A peripheral blood smear was made by direct finger tip capillary puncture stained and reported in the Department of Medicine. Anticoagulated venous blood was collected for the cellulose acetate haemoglobin electrophoresis and the foetal haemoglobin estimation by the Betke Method (2), which was to be modified for higher HbF levels (greater than 5%).

The one minute alkaline denaturation method of Singer and Chernoff (3) was used for higher HbF levels because it produces more accurate data when the HbF is greater than 5%. The reticulocyte preparation was made on the same day the blood was collected. Three drops of anticoagulated venous blood (E.D.T.A.), was mixed with six drops of freshly made brilliant cresyl blue and the mixture incubated at 37°C for ten minutes. The smear was then made and allowed to dry at room air and temperature. The reticulocytes were counted among 500 mature erythrocytes. The biochemical tests included the total bilirubin estimation (direct and indirect), plasma proteins, blood urea, and electrolytes. The prothrombin time was measured against a control of 14 seconds, the alkaline phosphatase and transaminase enzyme activity were determined along with the liver function tests mentioned above.

The postero-anterior and lateral views of the chest x-rays were required in each case for the cardiopulmonary study, plain abdominal x-rays and the oral cholecystograms were obtained for the study of the hepatobiliary systems. Each subject had an electrocardiogram done and reported in the Cardiology Division. Consultation to the ophthalmologist (Mr. Bakker) was made once during the study period. The males were screened for the glucose -6- phosphate dehydrogenase deficiency by the Spot Test Method. Stool and urine examinations were carried out in the Parasitology and microbiology laboratories. In the case of the stool examination for helminths, the concentration method was universally employed but when schistosomiasis was very strongly suspected, the Keto Test and rectal mucosal examinations were done.

The specialities of surgery, radiology, and obstetrics were consulted when the need arose. The sickle cell crises were documented when the subjects were hospitalized and the relevant investigations to determine if there were precipitating factors, carried out. The management of the occlusive vascular sickling crises was according to the protocol recently recommended (4).



## RESULTS

The age distribution in 38 adults with sickle cell anaemia revealed a preponderance of young adults where 63.10% of those reported were under 20 years of age. (Figure 1) The sex ratio was 1:1, the total age range was 15 - 33 years with the mean of 18.21 years for the males and 20.32 years for the females. The breakdown figures for the population groups reported in this series are depicted in Table 1 and show the marked predominance of the people around the Lake Victoria Basin. The figures lend further support to the observations made by others that the sickle cell haemoglobinopathy distribution follows closely that of the Plasmodium falciparum. (5)

TABLE 1

<u>Tribe</u>	<u>Male</u>	<u>Female</u>	<u>Total</u>	<u>Percentage</u>
Luo	15	12	27	71.05
Luhya	4	4	8	21.06
Baganda (Jinja-Kampala)	-	2	2	5.26
Sukuma (Mwanza)	-	1	1	2.63
	<u>19</u>	<u>19</u>	<u>38</u>	<u>100.00</u>

## CLINICAL FEATURES

The history of symptoms dating back to the early childhood was obtained in the majority (nearly 90%) while the remainder were uncertain about the age of onset of the disease.

The main symptoms were those of painful bone and joint episodes fairly descriptive of the hand and foot syndrome during the paediatric age. Frequent admission to hospital and in some cases anaemia severe enough to require a blood transfusion, was reported and the impression given was of chronic ill-health, distinguishing the child from the other siblings. The abdominal symptoms were more difficult to quantify. One Luo boy who had a successful laparotomy in 1960 for a simulated abdominal surgical emergency not proved at operation was found to have gallstones demonstrated by cholecystography in 1975, see photograph (H). In the adults the clinical features were characterized by a steady haematological state punctuated by occasional occlusive vascular sickling crises and the multiorgan pathological complications listed in tables II and III. The environmental factors that had unfavourable influence on the natural history of the sickle cell anaemia were bacterial



infections, malaria, and the low ambient nocturnal temperatures of Nairobi because of the high altitude (5,452 ft.) The dietary lack of elemental iron may play an important role in the clinical and haematological status of these subjects. The dietary history showed that the main source of iron was vegetable food-stuffs. There was no history of chronic blood loss and stool examination did not show the intestinal parasites which are a common cause of iron deficiency anaemia in Kenya.

TABLE II  
Clinicopathological complications

Mean age at onset	Years	Male	Female	Total	Percentage (of total)
Chronic leg ulceration	18	4	-	4	10.51
Chronic osteomyelitis	13	1	2	3	7.89
Recurrent tonsillitis	7	1	2	3	7.89
Hip joint disease	18	2	3	5	13.15
		<u>8</u>	<u>7</u>	<u>15</u>	<u>39.44</u>

Multiple pathological complication were noted as well:-  
One female aged 17 years had multiple osteomyelitic lesions in the limbs and severe hip disease, see photographs (B,C,D).  
One male aged 18 years had a unilateral femoral head necrosis, chronic leg ulceration pigment gallstones and chronic heart failure (see text).

Analysis of the hepatobiliary pathology showed gallstones in four out of fourteen subjects investigated with the oral cholecystogram. One out of two adults aged 30 - 34 years had gall bladder disease, see photograph (G).

TABLE III  
Gall Bladder disease in sickle cell anaemia

Age Range (Years)	Number Examined	Positive Gallstones	Percentage
15 - 19	8	2	25%
20 - 29	4	1	25%
30 - 34	2	1	50%
	<u>14</u>	<u>4</u>	<u>100%</u>

The main symptoms in gall bladder disease among the adults with the homozygous sickle cell haemoglobinopathy were pain in the right upper quadrant associated with intermittent attacks of jaundice over a variable duration. It was not possible to ascertain with certainty the age at the time of onset.

The biochemical liver function tests were not helpful in the diagnosis and the only consistently reproduced symptom in this study was the right upper quadrant abdominal pain. In one instance the pain was found to be due to chronic peptic ulcer as evidenced by positive barium contrast studies and a negative oral cholecystogram.

### CARDIOVASCULAR MANIFESTATIONS

There was evident hyperdynamic circulation in all the subjects. Exertional dyspnoea palpitations and fatiguability were the cardinal symptoms in the cardiovascular system. Swelling of both feet was found in one male subject who had circulatory congestion because of chronic heart failure. The blood pressure showed significant pulse pressure of 60 mm Hg. The commonest cardiac murmurs were the ejection systolic type and the S<sub>3</sub> gallop was documented even when there were no other signs of circulatory congestion. These murmurs were elicited in the left second intercostal space and at the cardiac apex equally. The chest x-ray showed marked cardiac enlargement with the cardiothoracic ratio of 0.51 to 0.65 and the mean of 0.58.

The electrocardiogram showed marked left ventricular hypervoltage in young adults in about 70% of the recordings; Left ventricular hypertrophy with a strain pattern in 4 subjects under 20 years of age (i.e. 10%); however 20% of the ECG recordings were in the normal limits. The ECG data lacked in specificity and diagnostic features in the homozygous sickle cell disease. The chest x-rays on the other hand persistently showed marked cardiomegaly, and in a few, unexplained pulmonary opacification consistent with the "pulmonary syndrome" described in sickle cell anaemia.

### THE LIVER AND SPLEEN

A moderately enlarged liver was reported in 8 adults. There was no sex difference and in all the cases the Hepatomegaly was reported as 3 fingers breaths below the right costal margin (i.e. greater than 4 cm), and the total liver span was increased in the mid-clavicular line.

The aetiology was clear in only one case where there was chronic heart failure and passive congestion of the liver as a result. In the rest there was no obvious aetiological factor and it was presumed that the hepatomegaly was part of the sickle cell pathological process.

Persistent splenomegaly was found in only two young adults both aged 16 years. The laboratory data were not helpful in determining the aetiology because all the investigations for the common causes of splenomegaly were negative. Schistosomiasis was excluded by the negative rectal mucosa examination. The haemoglobin electrophoresis confirmed the homozygous sickle cell disease in both cases.

#### OCULAR COMPLICATIONS

There was marked paucity in eye symptomatology. The direct ophthalmoscopic examination of the ocular fundi showed peripheral retinal venous tortuosity, dilation and occlusion proportionate with the age of the subject. In the older adults, vascular occlusion, mild neovascularization, and vascular sheathing were the main features reported by the ophthalmologist. Abnormal retinopathological changes of vascular sheathing, looping and occlusion were reported in one 15 years old Luo boy who had the S-O-arab haemoglobinopathy.

#### NEUROLOGICAL COMPLICATIONS

The history of epilepsy was obtained in two adults aged 16 years. In one the features were typical of grandmal seizures while in the other the lateralizing signs involving the right arm and leg suggest a localized intracranial lesion. There was no E.E.G. recording to confirm the suspected diagnosis.

#### OBSTETRICAL AND GYNAECOLOGICAL FEATURES

Nineteen females were available for the study. There was history of delaying menarche in sixteen of them with the mean age at menarche of 16.50 years (range 15.3 years to 17 years). A total of four pregnancies was reported in two mothers whose ages were 22 years and 33 years at the time of making this report. The older woman had her first baby boy when she was 23 years and the last born is now 8 years old. She gives no history of obstetrical complications during gestation or labour on confinements. The other subject had her first baby when she was 20 years old without any obstetrical complications although arrangements were at hand to ensure safe delivery at the Kenyatta National Hospital Maternity Wing supervised by a Senior Obstetrician in consultation with the Haematologist.

MORTALITY

Two male adults died during the period of study (i.e. 5.26 per cent). Their case summaries will be presented below:-

CASE 1

1.A. was a 16 years old Luo boy from the Kisumu District of Nyanza Province seen at the Haematology clinic of the Kenyatta National Hospital. There was a history of painful bone and joint episodic attacks since the early childhood. The younger brother has sickle cell anaemia but the rest of the siblings have no similar illness.

The patient had severe sickle cell anaemia with frequent hospital admission because of the sickle cell crises and the following complications:- right sided epileptic fits, bronchial asthmatic attacks, left saphenous venous thrombosis and chronic leg ulceration in the left medial malleolar region. The haematological data depicted in table 4 (cf.19), confirm chronic haemolytic anaemia and reticulocytosis. The haemoglobin electrophoresis confirmed the HbSS and the foetal haemoglobin was estimated at 0.9% (Betke Method). The blood smear showed the typical features of sickle cell anaemia but also a hypochromic microcytic picture. The bone marrow had no stainable iron. He was treated with folic acid, proguanil, and ferrous sulphate. Skin graft for the leg ulcer was attempted but it failed to take.

The clinical course deteriorated and he had to be hospitalized to the Health Centre nearest his home for management of severe anaemia. Whole Blood transfusion was given and this precipitated circulatory congestion and heart failure which was the most likely cause of death in this case. Permission of postmortem examination was not granted.

COMMENT

The clinical data demonstrate the variability in the natural history of sickle cell anaemia. The multiorgan pathological involvement and severe anaemia contributed to the morbidity and the fatal outcome. Blood transfusion should not be recommended as a routine measure and instead packed red blood cell infusion or exchange blood transfusion, may be considered when there is life threatening severe anaemia.

CASE 2

S..M. was an 18 year old Luhya boy from Kakamega with the confirmed diagnosis of sickle cell anaemia who was seen at Kenyatta National Hospital in July, 1976.



There was history of 4 years progressive dyspnoea and palpitations on slight exertion. He was treated at the District Hospital in Kakamega but because there was no improvement he was transferred to Nairobi for further management. The family history revealed that one of the siblings had died of a similar illness at the age of 10 years.

The patient was anaemic, jaundiced and febrile ( $38.5^{\circ}\text{C}$ ) at the time of admission. He had pitting ankle oedema, and an ulcer of 2 cm in diameter around the left lateral malleolus. The main findings were in the cardiopulmonary system:-  
The radial pulse was 120 minute in sinus rhythm, blood pressure 130/70mmHg and the respirations were 36/minute and regular. The apex beat was displaced to the left sixth intercostal space outside the mid-clavicular line. There was an ejection systolic murmur and  $S_3$  gallop in the left second intercostal space and at the cardiac apex.(Figure III Pp.27)

The lung bases were full of fine crepitations heard bilaterally, see photograph (K).

The liver was enlarged 5cm below the right costal margin and the span increased along the midclavicular line. The spleen was not palpable. The haematological data confirmed chronic haemolytic anaemia and reticulocytosis, Table 4 (cf.14).

The oral cholecystogram showed multiple gallstones, and there was left femoral head avascular necrosis.

The patient did not respond to the therapeutic measures instituted which included folic acid, paludrine, digoxin and frusemide. Terminally he developed severe epistaxis and the coagulation screen showed the features of disseminated intravascular coagulopathy (D.I.C.) • The platelets were reduced to  $16,000/\text{mm}^3$ , red blood cells to  $1,400,000/\text{mm}^3$ , and the haemoglobin was 5.6gm/dl with a reticulocyte count of 10%. These findings are also consistent with hyperhaemolytic crisis. Permission for post mortem examination was not granted.

COMMENT:

This case illustrates the end organ failure in sickle cell anaemia. There was chronic heart failure and progressive hepatic cell decompensation as evidenced by the abnormal prothrombin time which failed to respond to parenteral vitamin K therapy. The aetiological factors in the disseminated intravascular coagulopathy appear to be multifactorial and most likely the vascular stagnation of blood because of the heart failure and severe hepatic derangement were contributory.

HAEMATOLOGICAL DATA

The haematological results collected during the study have been analysed and the mean values depicted in Tables 4, 5 and Figure II.

There was no sex difference in the mean haemoglobin and foetal haemoglobin values ( $p= 0.10$ ) when the data were subjected to the student t-test statistical analysis.

TABLE 4:

MALES: Mean Haemotological Data

Age Yrs	Hb gm/dl	PCV %	RBC $10^6/\text{mm}^3$	WBC $10^3/\text{mm}^3$	MCHC %	MCV fl	Retics %	Hbl %
21	8.30	23	3.303	16.540	34.95	87.50	11.30	1.3
17	9.75	30	3.353	13.054	13.66	84.00	9.00	11.0
15	7.38	23	3.205	15.128	31.89	76.16	8.10	4.0
15	9.85	29	4.573	8.944	33.33	70.80	15.10	12.0
24	8.45	29	3.105	15.050	28.44	92.33	7.50	5.0
20	8.46	26	3.306	14.580	31.73	81.98	8.00	2.0
15	8.33	27	3.926	12.720	29.84	79.22	8.16	6.0
23	8.17	26	3.440	11.460	30.74	90.33	9.10	2.0
18	8.35	26	3.543	13.800	31.04	75.30	8.05	0.9
16	7.24	26	3.168	19.500	27.22	80.40	9.00	4.0
16	8.29	26	3.500	14.507	31.76	76.60	10.92	5.2
18	8.74	26	4.126	10.933	26.88	68.84	15.90	4.3
28	8.66	26	3.188	13.188	33.07	83.25	8.00	1.9
18	7.62	23	2.366	15.750	31.98	108.00	19.00	3.2
30	8.70	26	5.077	10.660	33.33	60.70	7.50	5.0
18	12.35	38	4.370	10.100	31.83	76.00	14.00	7.0
19	8.50	25	2.740	11.460	33.73	90.33	9.00	11.0
18	8.83	26	3.163	11.354	33.35	87.33	8.00	19.0
16	7.68	23	4.615	17.188	32.44	73.74	16.51	0.7
18.21	8.85	26	3.825	14.378	31.71	81.78	10.68	5.6

The blood film examination provided invaluable unquantifiable information. The typical features of sickle cell anaemia were similar to those reported in the literature. The immature cellular elements were consistently found suggesting significant normoblastemia; neutrophilia and thrombocytosis. The Howell-Jolly bodies were noted and these features implied marked hyposplenism.

TABLE 5:

FEMALE: Mean Haematological Data

Age Yrs	Hb gm/dl	PCV %	RBC $10^6/\text{mm}^3$	WBC $10^3/\text{mm}^3$	MCHC %	MCV fl	Retics %	HBF %
17	8.79	24	3.374	8.760	35.41	104.20	11.76	10.00
16	8.27	26	3,146	12.624	30.661	86.61	9.60	5.50
19	9.87	28	3.630	12.080	34.98	79.60	6.93	8.00
26	8.42	27	2.543	14.833	30.91	106.60	10.92	1.50
21	8.71	27	2.823	20.760	31.71	102.00	11.40	3.40
18	10.68	33	3.579	13.230	32.01	103.00	15.80	12.00
21	8.38	26	2.519	17.070	31.84	99.50	16.70	4.00
16	8.31	26	2.574	17.230	31.44	90.30	17.50	5.90
16	10.14	32	4.732	12.550	30.80	69.00	9.50	3.00
19	8.14	25	2.633	11.700	31.24	98.40	13.50	3.60
20	8.10	22	2.491	18.811	31.39	98.00	16.50	3.50
33	7.70	23	2.400	6.500	32.91	96.00	4.00	10.10
21	8.80	27	3.650	7.600	32.00	77.00	8.00	9.00
18	8.20	23	2.510	12.879	34.76	86.77	15.10	4.10
16	9.00	26	3.200	13.300	33.71	83.00	8.60	8.20
17	7.40	22	2.350	17.620	33.33	95.40	17.50	7.60
19	7.31	21	2.385	11.950	32.31	91.33	10.50	7.00
23	8.90	26	2.500	12.879	35.23	92.22	10.10	8.60
15	8.35	23	3.090	18.975	35.18	88.77	15.30	6.80
20.32	9.06	27	3.864	15.716	32.72	91.10	11.73	6.41

RETICULOCYTES

Figure II shows the distribution of reticulocytes according to the age of the subjects. The reticulocytes response declines with the advance in age. This observation suggests that bone marrow activity tends to revert to the normal from the hypercellularity reported in the younger subjects. In the adults reported in the present series hypoplastic sickling crises were not documented.

There was evidence of iron deficiency-----

...../13



from the bone marrow and coultergram reports. Eight adults consisting of 5 males and 3 females had low mean corpuscular volume (less than 80 fl.), and the blood film showed a microcytic hypochromic picture. The bone marrow studies were available in 5 cases and four of these showed depleted iron stores, the fifth was normal. The dietary history demonstrated inadequacy of elemental iron, because the main source of the metal was from the plant foods. Further investigations are indicated and are underway to exclude the S-beta thalassaemic syndromes. The haemoglobin A<sub>2</sub> estimation gives the value of 2 - 3% in the subjects but the family studies are not complete and these will be the subject of a subsequent report. The stool examinations have so far failed to incriminate the helminths as the causal factor of the iron deficiency state co-existing with chronic haemolytic anaemia.

DISCUSSION

There was preponderance of younger adults in the series reported here where 63.15% were under 20 years of age. This observation reflects the national pattern in Kenya and the other developing countries. The homozygous sickle cell haemoglobinopathy has been characterized by a high infant and childhood mortality in Eastern Africa and the chances of survival, to adulthood were estimated at 14% in Uganda and 35% in Kenya (6). These reports published in 1954 had only small samples available for analysis and they made some basic assumptions about random mating and static sickling rates which tend to invalidate the conclusions drawn.

There has been tremendous improvement in the standard of living and health care in the last 20 years in Kenya. This feature of the economic life has had a major impact on the natural history of sickle cell anaemia so that more children can survive to adulthood. Improved health facilities have facilitated the diagnosis to be made early enough for the communicable diseases to be more effectively controlled. This was the experience from the West Africa where the role of the environmental factors in the morbidity and mortality of sickle cell anaemia has been recognised (7).

Analysis of the children attending the paediatric Haematology clinic showed no significant departure from the experience in this disease described in the literature. The disorder has its onset in the early childhood period (8).

The sickle cell gene in Kenya has a high prevalence rate in the Lake Victoria Basin (9, 5).

In this area Plasmodium falciparum is holoendemic and it has been postulated that this infection sustains the high rates of the sickle cell gene as propounded by the proponents of the balanced Polymorphism theory. Malaria infection has a deleterious effect on the clinical course of sickle cell anaemia. The acceleration of haemolysis by two mechanisms has been proposed as the main explanation for the observed severe anaemia and intractable heart failure (11).

Although the hypothesis on the protective value of the sickle cell gene from the malignant malaria complications has received world wide acclaim, it is important to consider the other mechanisms which may be in operation to maintain a high sickle cell gene frequency in the face of increased mortality in the homozygous state. In the traditional African culture where polygamy is widely accepted it is obvious that one man with the gene can transmit it to more children if he has more than one wife than in the monogamy system (10). The persistence of splenomegaly in the adults with the homozygous sickle cell disease is an unusual feature in the natural clinical course of this disorder in which autosplenectomy characteristically takes place by about 7 - 10 years of age. There was evidence of splenic hypofunction in all the subjects (including the two with palpable spleens below the left costal margin) presumed on the basis of the presence of Howell-Jolly bodies in the peripheral blood smear. The lack of the splenic filtering apparatus in autosplenectomy is comparable to the surgical removal of the spleen in which case the antibody production by the splenic reticuloendothelial tissues is also depressed. Critical review of the literature on the subject of bacterial infections in splenectomized individuals suggests that the host defence mechanisms impaired by the disease process for which the spleen was removed were more important in predisposing to the overwhelming infections reported. There was no obvious preponderance of particular bacterial infections when the indication for the splenectomy was trauma for example (12).

The demonstration of significant hyposplenism in this study is interesting and should reinforce the recommendations made on the antimalaria prophylaxis in areas where transmission of this infection is anticipated. There was no justification for antibiotic prophylaxis and it is preferred to treat such bacterial infections when they occur with a well defined course of antibiotics. The immunological status of sickle cell anaemia individuals has been the subject of intensive investigation.. The predominant feature has been

the demonstration of the depressed activity of the alternate pathway of the complement system. The  $C_3b$  component which is responsible for the opsonin ability of the host organism is persistently abnormal in sickle cell anaemia and this has been proposed as the most likely mechanism by which these individuals are unable to handle the pneumococcus (13, 14). It has been suggested that the predominance of pneumococcal meningitis in sickle cell anaemia during the paediatric age where otherwise the Haemophilus influenzae is the commonest organism, is thought to be due to the impairment of the host defence system (15). These proposed mechanisms do not completely explain the observed pattern of infections in sickle cell anaemia and further work is required to clarify the picture (16). The osseous salmonella infection commonly found in sickle cell anaemia has been shown to be caused by a wide range of the salmonella species and is characteristically multiple (17).

The experience gained in East Africa has shown that carefully planned therapeutic regime should include the appropriate antibiotics and aspiration with a wide bore needle initially. The aspiration under local anaesthetic produces significant relief of pain and also helps to establish the bacteriological diagnosis. Elective sequestrectomy is advisable once the acute phase is over and the involucrum has been formed to preserve the skeletal framework (18).

#### PULMONARY INFECTION, PULMONARY EMBOLISM AND INFARCTION

The pneumonic process in sickle cell anaemia is very difficult to differentiate from pulmonary infarction because both conditions occur commonly in sickle cell anaemia. They both give pleuritic chest pain and may lead to haemoptysis which can be indistinguishable in the two disorders. The only valuable physical sign is that of purulent sputum which of course confirms a pneumonic process but does not necessarily exclude co-existing pulmonary embolization.

Polymorphonuclear leucocytosis is found in both conditions and does not help in the differentiation. The chest radiograph confirms infiltrative lesion the nature of which remain to be explained. The upper lobar infiltrates are usually due to infective processes and the lower lobar ones are commonly associated with the thromboembolic phenomena. It is imperative that the diagnosis should be established so as to enable the appropriate therapy to be initiated in good time (19). The therapeutic test is baffling and may not provide the expected answer because there is considerable delay in response to the antibiotics therapy in pneumonic



The sickle cell cardiomyopathy proposed by some on the basis of consolidation in sickle cell anaemia compared with the general population. Of all the diagnostic aids proposed in this arena of confusion the demonstration of "the blister cells" in the peripheral blood smear of the patients with pulmonary embolism and not in pneumonia was applauded as very promising (20).

The variability in size and shapes including the burr cells, and crenated forms have led to further review of this problem, and indeed these haematological changes resemble those described in microangiopathic disorders the only difference being their direct association with the pulmonary embolism as postulated in the original study. Further studies are required to test the reproducibility and specificity of this observation.

### CARDIOVASCULAR MANIFESTATION

The hyperdynamic status in sickle cell anaemia is produced by the increased cardiac output as a compensatory mechanism to ensure adequate oxygen supply to the peripheral tissues. In the study reported here and the literature on the subject it appears as though the heart rate does not change much in the anaemic persons and so for the increased cardiac output to be sustained, the stroke volume must be increased proportionately. The negative correlation of the level of haemoglobin and the cardiac output is not reproducible in sickle cell anaemia and the cardiac compensatory mechanisms are stretched to the full even when the haemoglobin is above the cut off point of 7.0 grms/dl below which decompensation is expected (21). The clinical features particularly the cardiac symptoms and signs are fairly comparable with those found in the other anaemias. The exercise intolerance, palpitations and leg oedema occur in severe anaemia generally. The cardiac murmurs were the result of increased blood flow through normal heart valves but the diastolic and Duroziez's murmurs which have been associated with severe anaemia present a difficult problem and as rheumatic heart valve disease is common in this country the latter constitutes an important differential diagnosis. The mid-diastolic murmurs may be produced by increased blood flow through the normal mitral valve orifice and have been observed in the other conditions (e.g. ventricular septal defects) where "relative mitral stenosis" is described purely on the basis of the haemodynamic changes. Cardiac catheterization is indicated where a valvular lesion amenable to corrective surgery is suspected to coexist with the homozygous sickle cell haemoglobinopathy. Present knowhow and equipment permit cardiac studies to be done without the general anaesthetic, thus making the workup of the case less hazardous and the diagnosis more certain than it was 20 years ago (22).

The sickle cell cardiomyopathy proposed by some on the basis of the degenerative changes found at necropsy is difficult to prove and in one series where this pathological entity was proposed as the main diagnosis, there is serious doubt as to the sickle cell disorder being the aetiological factor. The consumption of alcohol does suggest that the cardiac lesions found were caused by ethanol and the nutritional deficiencies thereof so that the aetiology was multifactorial at least (23).

Cardiac failure on the other hand is due to left ventricular failure as a result of its inability to cope with the volume load. The abnormal rheology of sickle cell anaemia predisposes to hypoxaemia of the heart muscle which because of its inherent ability to perform efficiently with minimal oxygen requirements manages to function till the critical point of oxygen tension is attained. Increasing the red blood cell mass cautiously is the therapeutic regime recommended and this is best done with packed red blood cell transfusion. Exchange blood transfusion may be required as a life saving measure. On the other hand, the digitalis therapy has doubtful value in the sickle cell anaemia complicated with intractable heart failure and its recommendation is still controversial.

#### CHOLELITHIASIS

The correlation of the symptomatology and gall bladder disease demonstrated by the oral cholecystogram was fairly good whereby 34% positive gallstones were diagnosed in those who complained of right upper quadrant abdominal pain, and intermittent jaundice. The biochemical liver function tests were not helpful because of the chronic haemolytic jaundice so that only significant direct hyperbilirubinaemia was regarded as suggesting extrahepatic obstruction but not necessarily diagnostic of this condition. There are instances in the current study where despite elevated levels of direct acting bilirubin there were no demonstrable gallstones. The elevation of alkaline phosphatase was more indicative of hepatobiliary disease but then the osseous source of the enzyme could not be excluded and in this respect the estimation of 5-nucleotidase could have helped to make the test more specific for the hepatobiliary disorder.

The incidence of cholelithiasis determined from the post-mortem studies fails to reflect the true picture in life and in recent years radiological investigation has come out with more valid data on the incidence of this disorder among the patients with sickle cell anaemia. There is direct correlation

of this complication with the age of the subject and those over 30 years of age have the highest incidence which is greater than 50% in some series (24).

This pattern was confirmed by the current study. Plain abdominal x-rays were negative which is very likely because of variable calcium composition of the pigment gallstones. This is in contrast with the reported experience in the Western World where up to 60% of those studied had radiopaque gallstones(25).The chemical analysis of these gallstones shows that they are made of calcium bilirubinate. Cholecystectomy has been recommended for the intractable symptoms of pain, and vomiting severe enough to disrupt the normal life of the patient. On the other hand the gall bladder disease is associated with serious complications estimated at the rate of 35%, while Cholecystectomy carries a mortality of 1.10% even in good hands (26).

Elective surgery is to be preferred and the patient should be prepared with fresh blood transfusion to boost the haematocrit by about 50%. Consultation with the anaesthetist is mandatory to ensure adequate oxygenation during the operation and in the immediate postoperative period.

#### OCULAR COMPLICATIONS

The direct ophthalmoscopic examination revealed marked tortuosity in the retinovasculature most marked peripherally. In sickle cell disease in general the most pathognomonic changes occur in the superior posterior temporal region and these are best demonstrated by the indirect ophthalmoscopic examination. In recent years it has been noted that the tortuosity of retinal vessels occurs in people without sickle cell anaemia and that by employing fluorescein angiography, more subtle pathological changes in the capillary network have been described in a larger series from Jamaica (27). In this particular study retinal detachment, an ominous and dreaded complication, was documented for the first time in homozygous sickle cell disease. The lack of symptomatology in the face of significant pathological changes may be explained by the rare involvement of the macula. On the other hand infarction of the macula has been shown to be readily reversible and accompanied by a fair amount of recovery of the vision in sickle cell anaemia (28).

The reports on the ocular findings in the current study in Nairobi represents a preliminary account and more detailed work employing the retinal fluorescein angiography and photography as well as the magnification and illumination provided by the slit-lamp bismicroscope to document the bulbar conj-

nctival vascular changes, is recommended to enable data to be assembled for purposes of comparison with those reported in the literature (29).

AVASCULAR NECROSIS OF THE FEMORAL HEAD

The clinical features of hip pain and a limp confirmed the experience of others where these are the main presenting complaints. The age of onset is later than in the Legg-calves Perthe's disease but the differentiation of these conditions must be made on the basis of haematological studies as well. The earliest lesions in sickle cell anaemia and in the HbSc disease resemble the Legg-Perthes lesion and respond very well to a non-weight bearing therapeutic regime (30). The majority of those diagnosed in the Nairobi study had fairly well advanced disease with serious functional disability of the hip joint. Major reconstructive orthopaedic surgery is recommended for bilateral hip joint disease (McMurray osteotomy). Unilateral femoral head necrosis with significant joint destruction is best treated with hip arthrodesis.

The sad state of affairs in the current report is largely due to the delay in diagnosis because of late presentation. It is recommended that the anteroposterior x-ray of the hip held in lateral rotation be done more frequently, to facilitate early diagnosis of femoral head necrosis in sickle cell anaemia so that non-weight bearing treatment can be instituted without unnecessary delay in the early hip joint disease. The osseous lesions in sickle cell anaemia are produced by inadequate blood supply and also if anastomotic vascular patterns are not developed fast enough. The shafts of long bones usually have adequate blood supply but there is evidence to the effect that infarction of the long bones in sickle cell anaemia occurs frequently in children (31). The frequency of bacterial infections in the bones leaves the aetiological factors open to suggestions and it is very tempting to propose that bacterial colonisation of the dead bone takes place as a secondary phenomenon. In this report chronic osteomyelitis was found co-existing with femoral head necrosis and for this reason the terminology "aseptic necrosis of the femoral head" is considered inaccurate and has been avoided in the present account where the emphasis is laid on bone avascularity.

Neutrophil leucocytosis, thrombocytosis and polycy-  
tosis confirmed the bone marrow hyperactivity by ...../20  
with chronic haemolytic anaemia. The crystalloids estimated



## CHRONIC LEG ULCERATION

The most reproducible clinical feature of leg ulceration has been the anatomical site of the lesion in the medial malleolus. The other features of chronicity and refractility to all forms of treatment have been universally noted. Large series from Jamaica report a high incidence of this disorder about 75% which occurs before the age of 30 years and that in the older subjects there is a tendency of spontaneous healing. The surgical therapy employing pinch skin grafts using the local anaesthetic only has had good results compared with the more aggressive programmes (32).

The management of these ulcers has presented the plastic surgeons with immense problems and recently an elaborate scheme combining conservative and surgical management has been proposed but the results will have to stand the test of time (33). There is otherwise no break through in therapy yet and the results have all along been discouraging because of recurrence of the ulcers at the alarming rate of 97.4% within two years following apparent cure in some series.

## PREGNANCY AND CONCEPTION

Pregnancy in sickle cell anaemia introduces additional hazards notably spontaneous abortion and increased maternal morbidity from the pulmonary thromboembolism, and urinary tract infection. The foetal loss is estimated at 34.6% thought to be due to placental insufficiency because of the vaso occlusive lesions common in sickle cell anaemia (34). The experience in Nairobi is very limited but leaves a couple of points for consideration particularly those related to the mild features of the sickle cell anaemia and pregnancy. The clinical features and haematological data are all diagnostic of the homozygous sickle cell disease. The main differential diagnosis of a mild sickle cell anaemia syndrome during pregnancy are the heterozygous states of the sickle haemoglobinopathies.

The S-beta-thalassaemic syndromes feature prominently and must be excluded by the Hb<sub>A<sub>2</sub></sub> estimation and family studies for the S-beta-thalassaemia trait.

The HbS-D-haemoglobinopathy is best diagnosed with the Agar gel electrophoresis at acid pH. (6.2) as described in the literature (35).

## HAEMATOLOGICAL DATA

Neutrophil leucocytosis, thrombocytosis and reticulocytosis confirmed the bone marrow hyperactivity consistent with chronic haemolytic anaemias. The erythrocyte estimation

by the coulter counter method failed to demonstrate a proportionate increase in red blood cell count compared with the marked neutrophilia. Erythroid hyperactivity was obvious from the degree of reticulocytosis and normoblastemia documented in this and other studies (36). The tendency of the reticulocyte count to fall with age is an interesting finding that must remain to be explained fully.

The total red blood cell mass may be reduced because of the enhanced destruction of the mature erythrocytes. The examination of the peripheral blood smears persistently demonstrated the irreversibly sickled erythrocytes in the homozygous sickle cell state. This sickle cell shape is markedly different from the normal biconcave shape characterized by excess of surface area to the cell volume. Red blood cell deformability is a function of the biconcave shape and is responsible for survival in the circulation for 120 days compared with the reduced red blood cell survival in the sickle cell anaemia of 17-20 days. The physical characteristics of the normal deoxygenated haemoglobin have been compared with those of the deoxygenated sickle cell haemoglobin and found to differ morphologically as well as in the chemical structure (37).

The haemoglobin forms polymers and aggregates which eventually crystallize in the normal haemoglobin type (HbAA) while in the deoxygenated sickled haemoglobin the polymers formed are of different molecular organization which assemble into long rod-like structures (tactoids). The sickling phenomenon as described above has been shown to be due to a sol-gel transformation rather than the crystallization processes described in the earlier literature on this subject. The irreversibly sickle erythrocytes assume this peculiar shape because of the intracellular organization of the abnormal haemoglobin which introduces many disadvantages and increased red cell destruction in the microcirculation at the capillary level where the cells have to pass in a single file. The sickled erythrocytes are more rigid than the biconcave cells of the normal haemoglobin and as a result they produce capillary blockade and vascular stasis with the intravascular changes in pH favouring further sickling. The accelerated red blood cell destruction provides ready explanation for reported low erythrocyte counts found in this study.

The other factors that very likely depress the production of the erythropoietin from the renal juxta glomerular apparatus remain to be investigated. There is peculiar oxygen dissociation curve in sickle cell anaemia, whereby the shift to the right increases tissue oxygen extraction in the renal

apparatus where the erythropoietin is produced. The erythropoietin production fails to respond to the reduced red blood cell mass and haematocrit as a result, which normally operate in a feed back system.

The relative folic acid deficiency found in sickle cell anaemia probably contributes to depressed erythropoiesis found (38). The role of folic acid deficiency was difficult to assess in the present study because all the subjects received routine folic acid supplements with reasonably good compliance.

### HAEMOGLOBIN INTERACTION

More recently the advances in technology employing the combined x-ray diffraction and electron microscopic studies have facilitated the exploration of the abnormal haemoglobins. The haemoglobin rod-like structures in the sickle cell haemoglobin have been characterized and it is hoped that when the contact surfaces become completely mapped it will be feasible to plan therapeutic regimes aimed at interrupting the sickling phenomenon (39).

The clinical features of haemoglobin S-o-arab reported in one patient in the present series confirm the experience of others. The Clinical features were severe with chronic haemolytic anaemia and osteomyelitis (photograph E.F.) These clinical and haematological data are comparable with those described in the homozygous sickle cell disease (40). The differentiation between the -O- and -C- haemoglobinopathies is very difficult on clinical grounds and the conventional haemoglobin electrophoresis is inconclusive because the -O- and -C- occupy the same position. The Agar gel haemoglobin electrophoresis at pH 6.2 will separate the Hb -C- from the Hb -O-. The haemoglobin -O- can be further characterized by chemical analysis of the constituent amino acids of the beta chain (i.e. finger printing of the peptide chain).

The foetal haemoglobin has a favourable influence when it is evenly distributed throughout all the erythrocytes as is the case in the Hereditary persistent Foetal Haemoglobin (H.P.F.H.) where anaemia and clinical symptoms have not been described. It has been suggested that the foetal haemoglobin has ameliorating effects because of its ability to stay out of the gel formed during the sickling phenomenon. In sickle cell anaemia the foetal haemoglobin is unevenly distributed in the red blood cells and it would appear to have no demonstrable benefit in the clinical features of the homozygous sickle cell disease.

On the other hand Jamaican series show that lower levels of the foetal haemoglobin occur in sickle cell anaemia complicated with chronic leg ulceration than in the patients who did not have such ulcers (41). These data have not been sufficiently tested for reproducibility.

Experience at the Kenyatta National Hospital is limited because of the small number of patients with chronic leg ulceration encountered in the present study.

### CONCLUSIONS

1. Sickle cell anaemia carries significant morbidity and a mortality of about 5% in the adults at the Kenyatta National Hospital. It appears as if the clinical course is less severe during the early childhood in those who reach adulthood. The factors which determine a more favourable clinical course and outcome include improved standard of living and the availability of health facilities.
2. Bacterial infections and malaria in the tropical environment, have deleterious effects on the clinical and haematological steady state of sickle cell anaemia. None specific upper respiratory tract infections and chronic osteomyelitis appear to respond poorly to antibiotic therapy. Cautious surgical intervention under the general anaesthetic seems to control refractile osteomyelitis and pyogenic tonsillitis.
3. The main multiorgan pathological complications in the homozygous sickle cell disease among adults are avascular bone necrosis, gallstones, chronic leg ulceration and chronic heart failure.
  - (a) The avascular necrosis of the femoral head presents too late for the non-weight bearing treatment to be of value. Major reconstructive orthopaedic surgery has to be undertaken to correct the severe deformity of the hip found in the present series.
  - (b) The gallbladder disease diagnosed by the oral cholecystogram most likely represents under reporting because this procedure has a lower yield of positives than the percutaneous intravenous or transhepatic cholangiography. The oral cholecystography requires less expertise and equipment on the other hand and as it is generally more readily available it should form part of the routine work up in the adults with sickle cell anaemia.



- (c) The chronic leg ulceration showed some of the typical features of the anatomical site and refractility to therapeutic measures. The follow up period is too short to permit concrete conclusions to be made.
  - (d) Intractable heart failure because of severe anaemia seems to be a serious terminal complication in sickle cell anaemia at the Kenyatta National Hospital.
4. Nutritional iron lack and relative folic acid deficiency disrupt the steady haematological status and account for a more severe clinical course, otherwise the characteristic haematological features were those of chronic haemolytic anaemia and reticulocytosis.
  5. Sickle cell anaemia afflicts young people and is very likely to interrupt their school attendance because of frequent hospitalization for the management of sickling crises and pathological complications. In the areas where there is a high prevalence of the sickle cell gene, a special clinic should be established to facilitate regular follow up, the documentation and management of the complications. Genetic counselling about the marriage partners, antimalaria drug prophylaxis and folic acid supplements are recommended.

**Figure 1**

The distribution of subjects with sickle cell anaemia according to age in years.

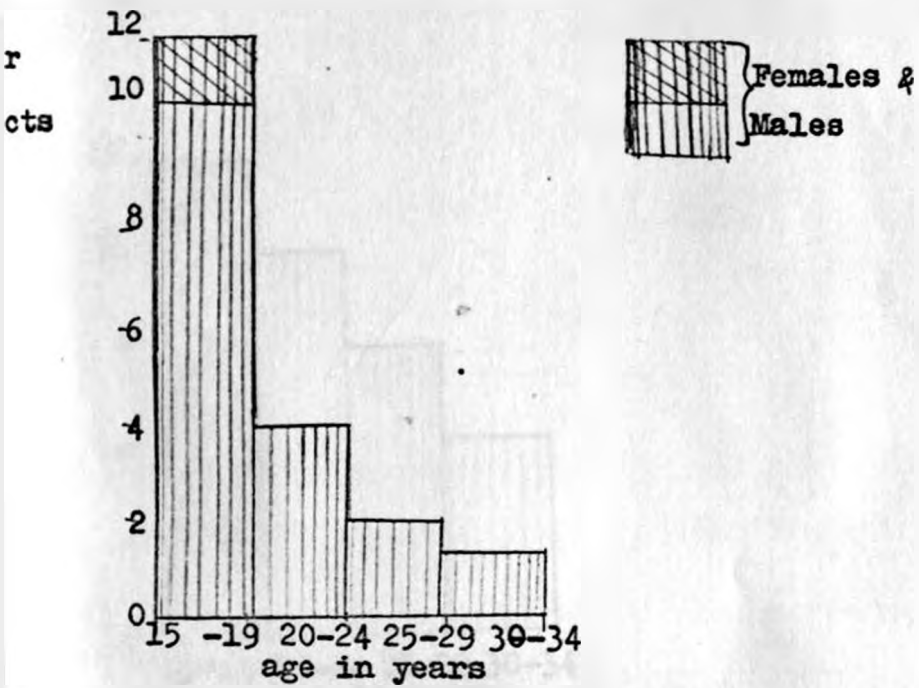
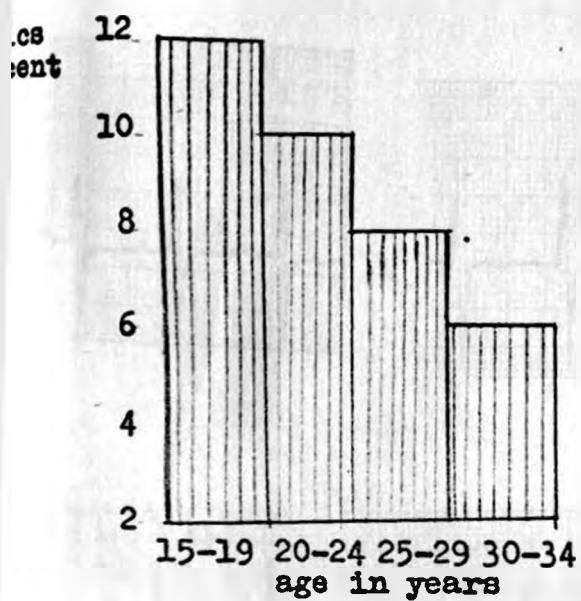


Figure II

The distribution of reticulocytes according to age.





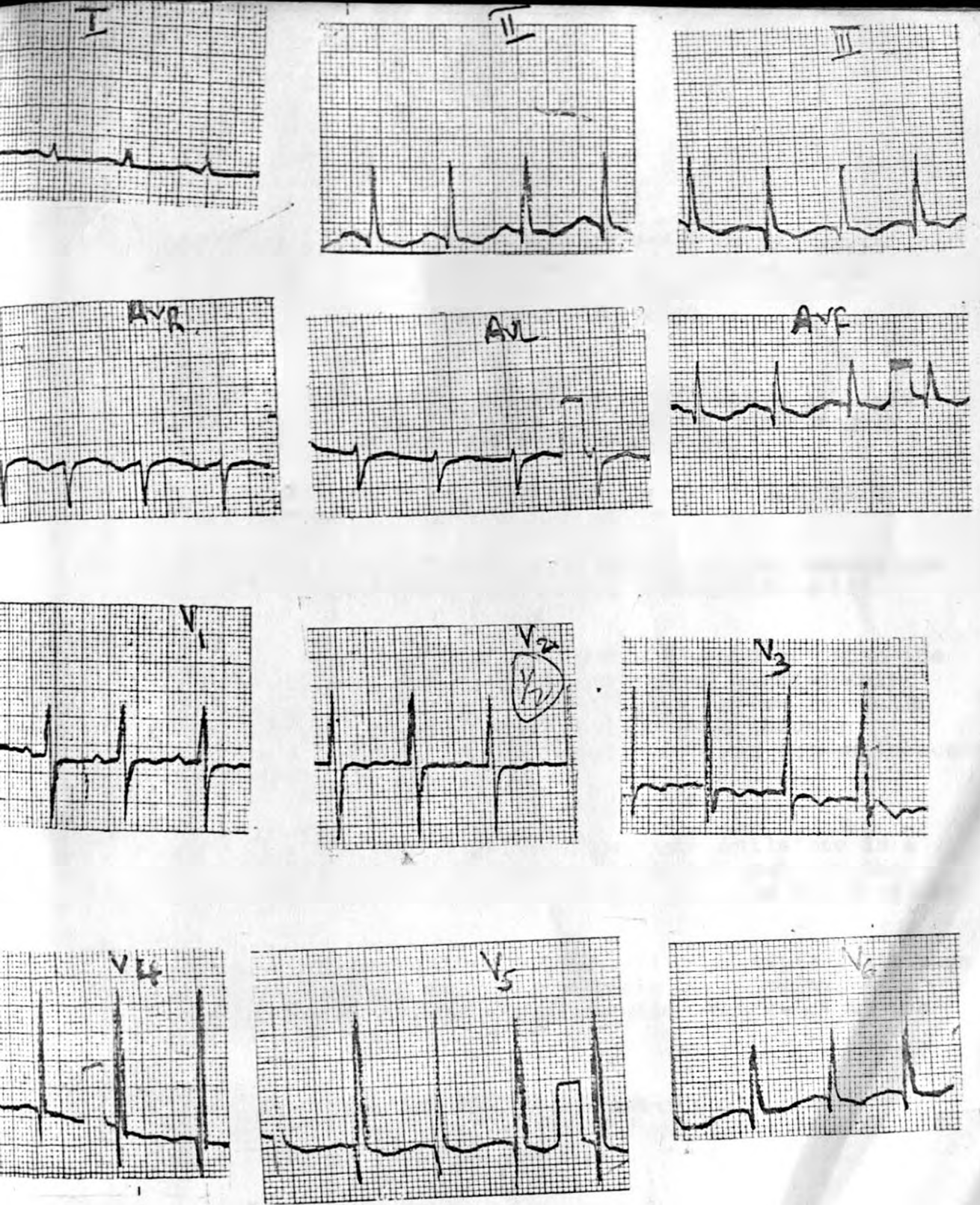


FIGURE III

The electro-cardiogram of S.M (above):- shows generalized cardiomegaly, sinus tachycardia, S.T. segment depression and T wave changes.

PLATES A - K

A. (L.W.)

The postero-anterior and lateral views of the chest x-ray of a 21 years old female, the cardiothoracic ratio is 0.57, there is marked pulmonary vascular prominence in the right out-flow tract.

B. C. D. (RA)

The P.A. chest x-ray of a 17 years old Luhya girl with sickle cell anaemia showing generalized cardiomegaly and marked pulmonary vascular prominence.

The right femoral head has been destroyed and the hip joint completely disorganised (C).

The radius shows irregular cortical bone thickening and sequestrum diagnostic of chronic osteomyelitis (D).

E. F. (G.O.)

The P.A. chest x-ray of a 15 years old Luo boy with the S-O-arab haemoglobinopathy shows marked cardiomegaly (C.T. = 0.65). The right femoral shaft shows irregular cortical bone thickening consistent with chronic osteomyelitis due to mixed bacterial flora (stapnylococcus pyogenes and E. Coli (F)).

G. (M.S.)

The oral cholecystogram shows multiple gallstone in a 33 years old mother of three. History of pain in the right upper abdominal quadrant and jaundice was obtained.

H. (G.O.)

The oral cholecystogram demonstrating multiple gallstones in a 21 years old male with history of abdominal pain and laporatomy for simulated surgical emergency at the age of 7 years.

I. (J.A.)

The oral cholecytogram shows a non-functioning gallblader in an eighteen years female; hospitalized for abdominal pain and jaundice.

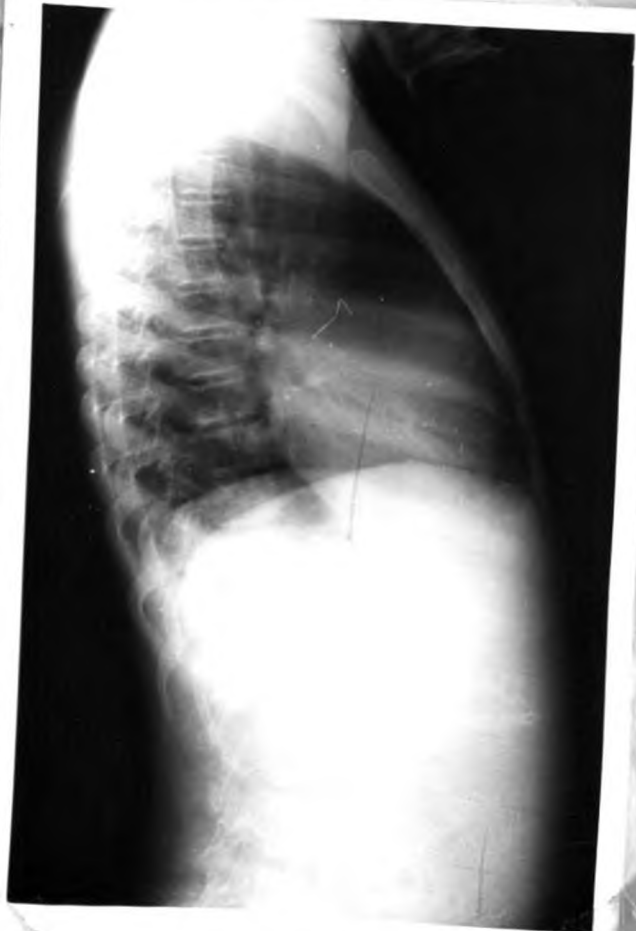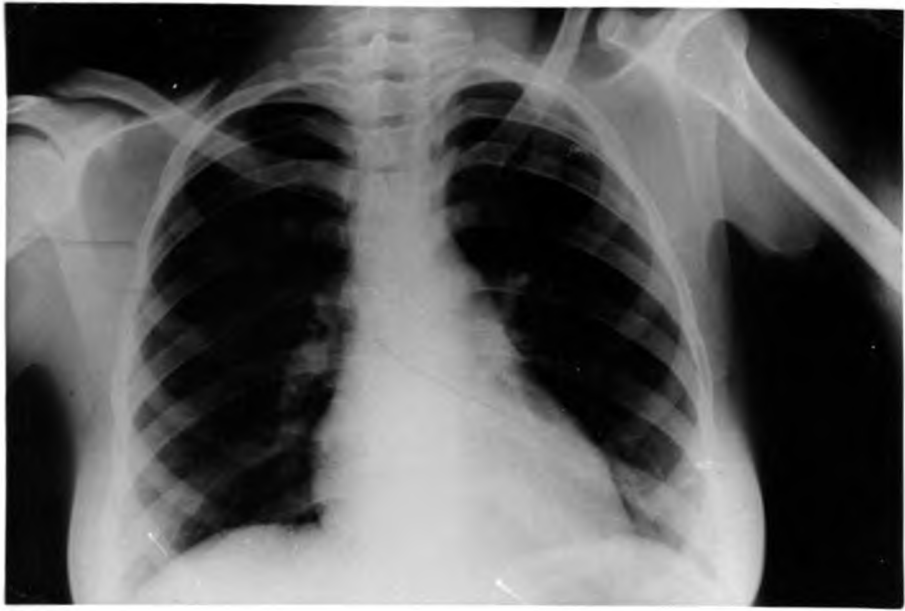J. (G.O.)

X-ray of the right hip of an 18 years old Luo boy with history of hip pain and a limp for one year. There is severe femoral head necrosis. Haemotological data confirmed sickle cell anaemia and foetal haemoglobin (HBF) of 19 per cent.

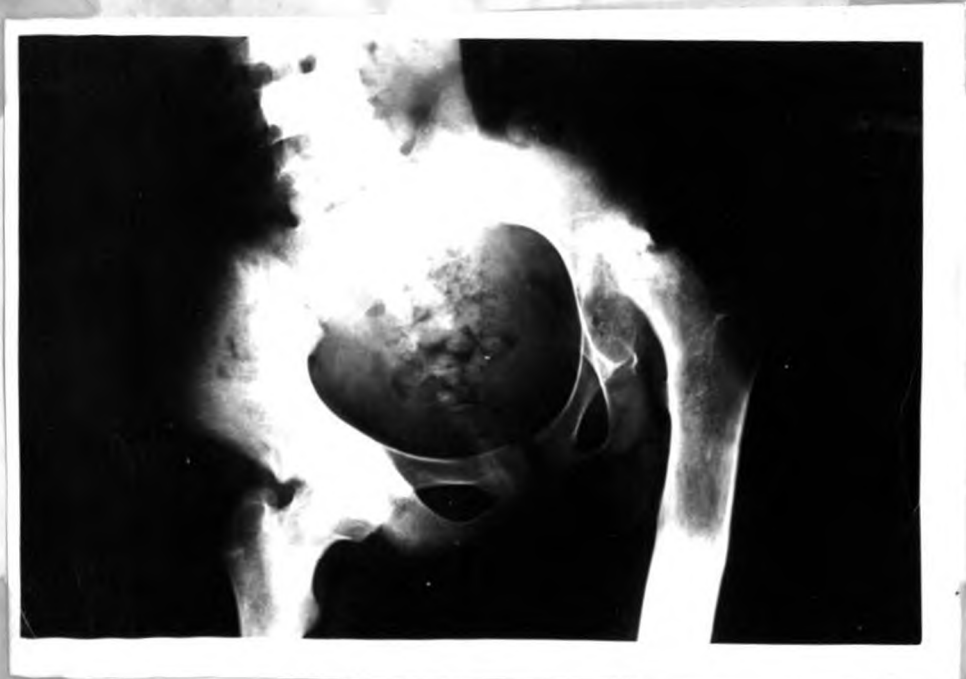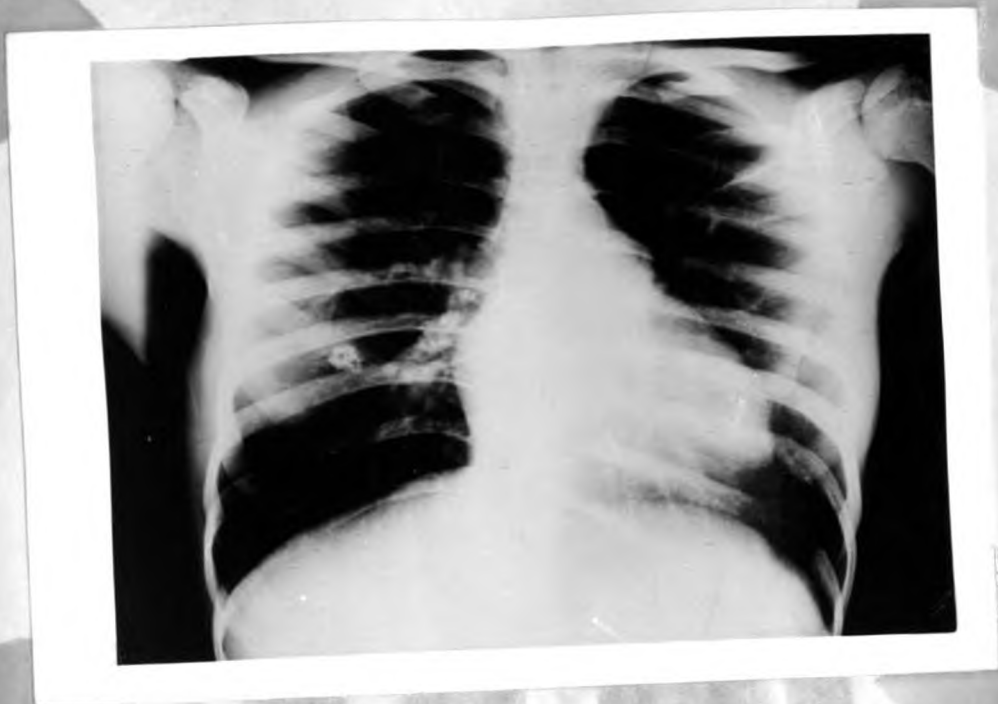K. (S.M.)

The P.A. chest radiograph demonstrating cardiomegaly, marked pulmonary vascular congestion and kyphosis in an 18 years old male with history of progressive dy and heart failure for four years discussed in the text.

A

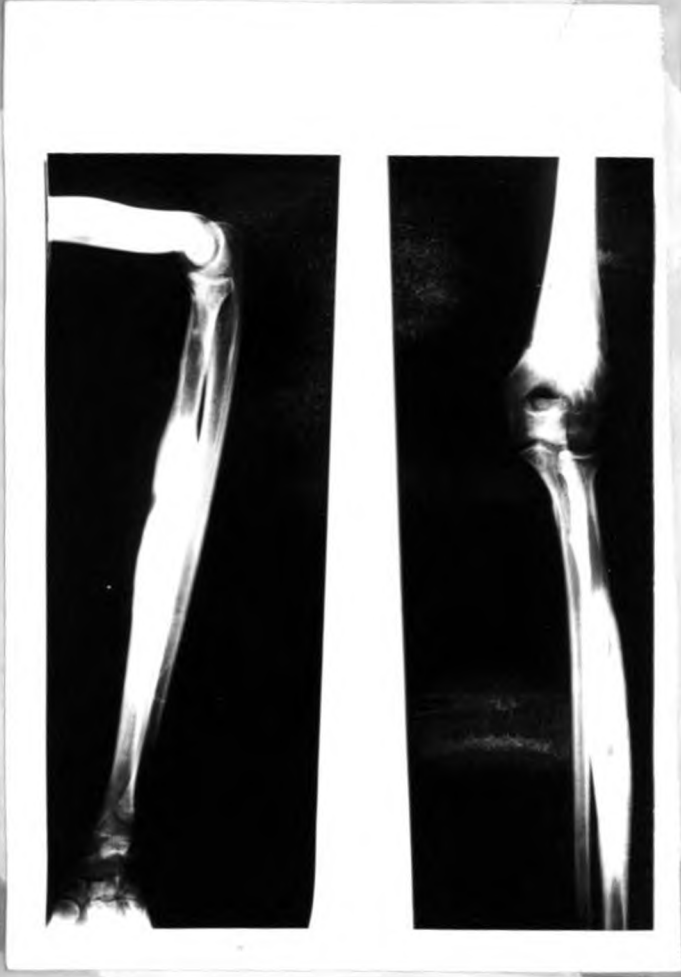

B ; C

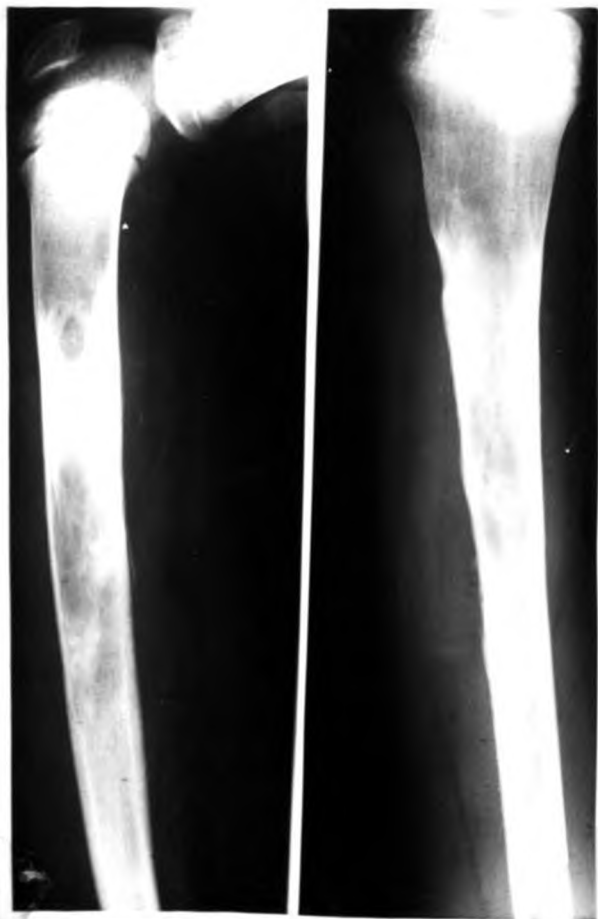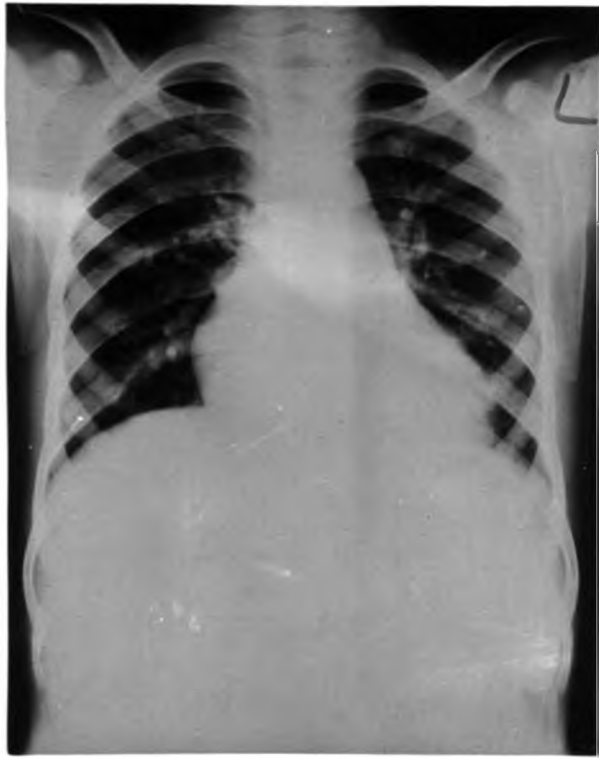




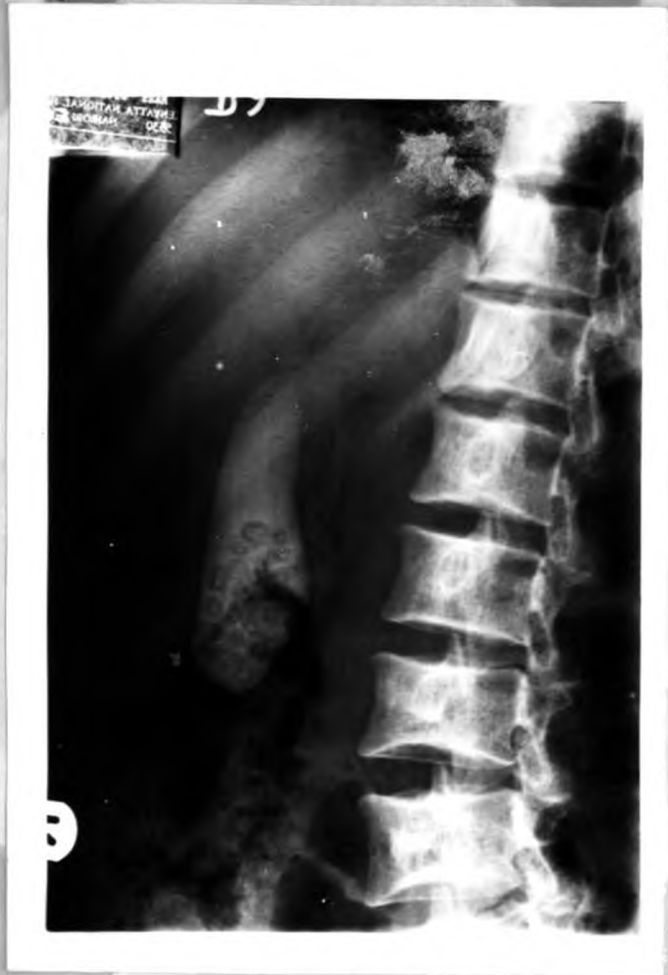D



E; F

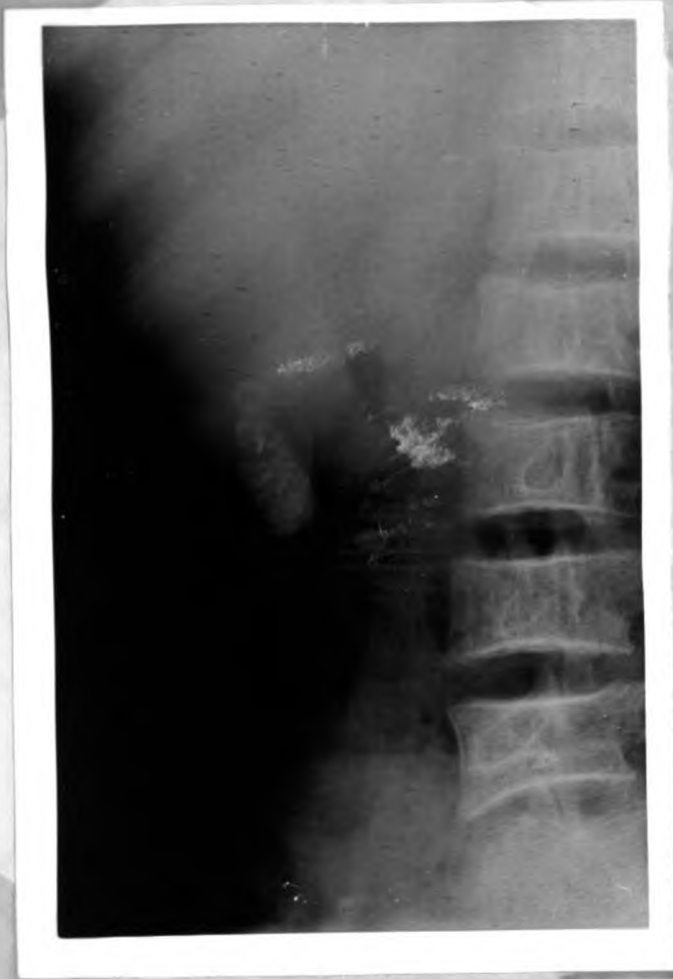

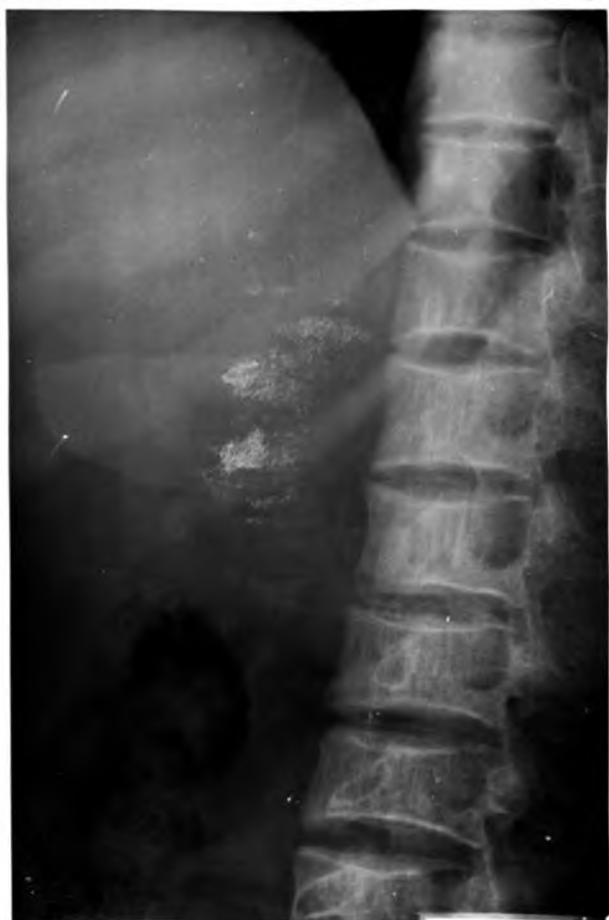G

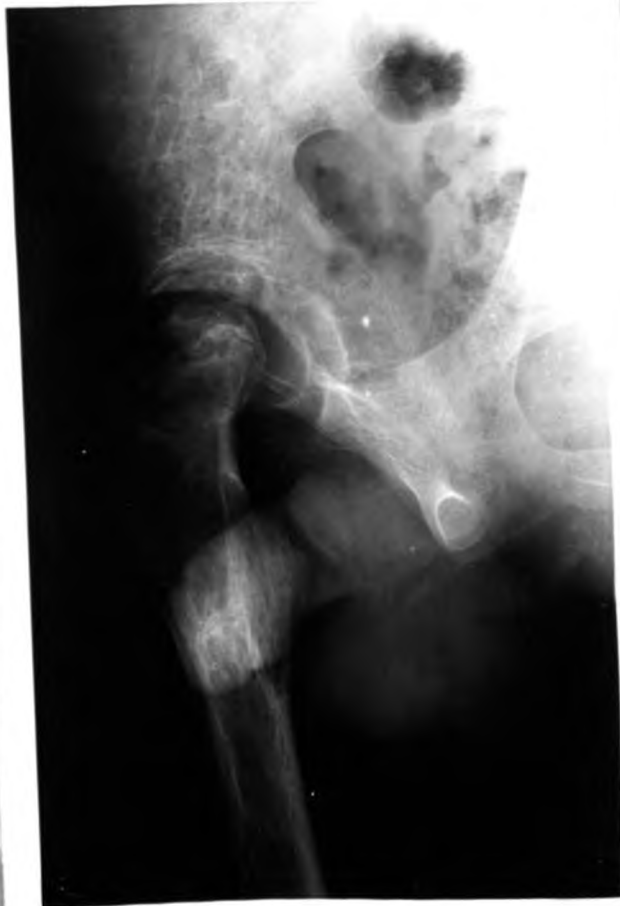
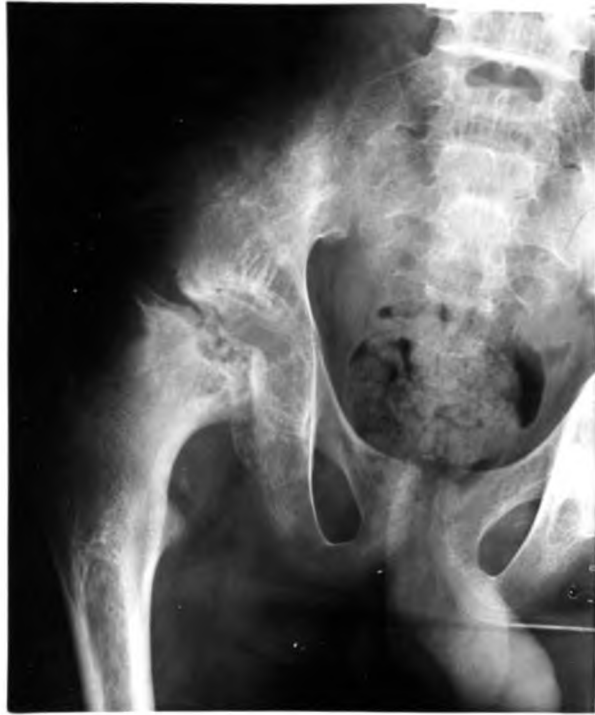


H









REFERENCES

1. Foy H., Kondi A. Timms G.L., Brass W.,  
The variability of sickle cell rates in the tribes  
of Kenya and the Southern Sudan.  
Brit. Med. J. 1:294,1954
2. Betke K., Marti H., Schlicht I.  
Estimation of small percentages of foetal haemoglobin.  
Nature (London) 184:1877, 1959
3. Singer K., Chernoff A.I., Singer L.  
Studies on abnormal haemoglobins, their demonstration  
in sickle cell anaemia and other haematological dis-  
orders by means of the alkali denaturation.  
Blood 6: 413,1951
4. Huntsman R.G., Lehmann H.,  
Treatment of sickle cell disease  
Brit J. Haematol. 28: 437,1974
5. Allison A.C.  
Protection afforded by sickle cell trait against  
subtertian malaria infection  
Brit Med. J 1: 290,1954
6. Jacob G.F.  
A study of the survival rate in sickle cell anaemia  
Brit Med. J 1:738,1957
7. Konotey Ahulu F.I.D.  
Effects of the environment on sickle cell disease  
in West Africa:  
In Abramson H., Bertles J.F., Wethers D. (Eds.)  
Symposium on sickle cell disease, St. Louis,  
C.V. Mosby Co 1973, pp.20-38
8. Njai D., Bwibo N.O., Ogada T.,  
Sickle cell disease in children at Kenyatta National  
Hospital, Paper read at the 23rd Annual Scientific  
Conference E.A. Medical Research Council, February  
1976, Nairobi
9. World Health Organization Scientific Group,  
Technical Report Series; Haemoglobinopathies and  
allied disorders 338 pp.7, 1966, GENEVA.
10. Konotey-Ahulu F.I.D.  
Maintenance of the high sickling rates in Africa:  
The role of Polygamy  
J. Trop. Med. & Hyg. 73: 19, 1970



11. Adelay A., Luzzatto L., Edington G.M.  
Severe malaria infection in sickle cell anaemia:  
Brit Med. J. 2: 445, 1971
12. Eraklis J.A., Kevy S.V., Diamond L.K.  
Hazard of overwhelming infection after splenectomy  
N. Engl. J Med. 276 1225 1967
13. Johnson R.B., Newman S.L., Struth A.G.,  
An abnormality of the alternate pathway of the  
complement activation in sickle cell anaemia  
N. Engl. J. Med. 288: 803 1973
14. Wilson W.A., Hughes G.R.V., Lachmann P.J.  
Deficiency of the factor B of the complement system  
in sickle cell anaemia  
Brit Med. J 1: 367, 1976
15. Robinson M.G., Watson R.J.  
Pneumococcus meningitis in sickle cell anaemia.  
N. Engl. J. Med. 274: 1006, 1966
16. Powars D.R.  
Natural history of sickle cell disease in the first  
ten years  
Seminars in Haematol. 12 (3) July 1975 pp.267
17. Hook E.W., Campbell G.C., Weens H.S., Cooper G.R.  
Salmonella osteomyelitis in patients with sickle  
cell anaemia  
N. Engl. J. Med. 257: (9), 403, 1957.
18. Huckstep R.L.  
Management of osteomyelitis in East Africa  
E.A. Med. J. 45: (7), 429, 1968
19. Barret-Conor E.  
Pneumonia and pulmonary infarction in sickle cell  
anaemia:  
J.A.M.A. 244: (7) 997 1973
20. Barreraz L., Diggs L.W., Bell A.  
Erythrocyte morphology in patients with sickle cell  
anaemia and pulmonary embolism  
J.A.M.A. 203 (8) 569, 1968
21. Vavat M.A., Adolf R.J., Fowler N.O.  
The cardiovascular effects of anaemia  
AM. Heart J. 83: 415, 1972
22. McKusick V.A.,  
The diagnosis of organic mitral stenosis in the presence  
of sickle cell anaemia  
AM. Heart J. 46: 474, 1953

23. Rubler S. Fleischer R.A.  
Sickle cell states and cardiomyopathy, sudden death  
due to pulmonary thrombosis and infarction.  
A.M. J. Cardiol. 19: 867, 1967
24. Phillips J.C., Gerald B.E.,  
The incidence of cholelithiasis in sickle cell disease.  
AM. J. Roentgenol. 113, (i), pp.27, 1971
25. Flye M.W., Silver D.,  
Biliary tract disorders and sickle cell disease  
Surgery: 72 (3), 361 1972
26. Wen Kert A. Robertson B.,  
Natural course in gallbladder disease  
Gastro Enterology: 50: (3), 376 1966
27. Condon P.I., Serjeant G.R.,  
Ocular findings in homozygous sickle cell disease in  
Jamaica. AM. J. Ophthalmol. 73: (4), 533 1972
28. Knap J.  
Isolated macula infarction in homozygous sickle cell  
disease AM. J. Ophthalmol 73: (4), 857, 1972
29. Amaly M.F.  
Ocular manifestations in sickle cell disease  
Arch. Intern. Med. 133: 670, 1974
30. Ching S.M.K., Ralston E.L.  
Necrosis of the femoral head associated with sickle  
cell anaemia.  
J. Bone-Joint Surgery 51-A: 33 1969
31. Bohrer S.P.  
Acute long bone diaphyseal infarction in sickle cell  
disease.  
Brit J. Radiol. 43: 685 1970
32. Gueri M.C., Serjeant G.R.  
Leg ulceration in sickle cell anaemia  
Trop. Geogr. Med. 22: 155 1970
33. Wolfort F.G., Kriezek T.J.,  
Skin ulceration in sickle cell anaemia  
Plast. Reconstr. Surgery 43: 71, 1969
34. Buckler A.E.R.  
Sickle cell disease in pregnant immigrants  
Post Grad. Med. J. 44: 836 1968
35. Apthorp G.H., Measday B., Lehmann H.,  
Pregnancy in sickle cell anaemia  
Lancet 1: 1344, 1963

36. Serjeant G.R.,  
Sickle cell anaemia: Clinical features in adulthood  
and old age  
Symposium on sickle cell anaemia St. Louis  
C.V. Mosby Co. 1973 pp.252
37. White J.G., Heagan B.,  
Gels of normal and sickled haemoglobins a comparative  
study  
J. Exp. Med. 131: 1079, 1970
38. Watson Williams E.J.,  
Folic acid deficiency in sickle cell anaemia  
E.A. Med. J 39: 213 1962
39. Milner P.F., Miller C., Grey R., Seakins M.,  
DeJong W.W., Went L.N.  
Haemoglobin S-O-arab in four Negro families and its  
interaction with haemoglobin S and Hb C.  
N. Engl. J. Med. 283: 1417, 1970
40. Bertles J.F.  
Haemoglobin Interaction and molecular basis of sickling  
Arch. Intern. Med. 133: 538, 1974
41. Serjeant G.R.,  
Leg ulceration in sickle cell anaemia  
Arch. Intern. Med. 133: 690, 1974