

**THE ROLE OF MICTURITION CYSTOURETHROGRAPHY
IN THE DIAGNOSIS OF URINARY TRACT DISEASES IN
CHILDREN AT THE KENYATTA NATIONAL HOSPITAL**

BY

DR. JANE N. GITAU

**A DISSERTATION SUBMITTED IN PART FULFILLMENT FOR THE DEGREE
OF MASTER OF MEDICINE IN DIAGNOSTIC RADIOLOGY,
UNIVERSITY OF NAIROBI**

JUNE 1995



**MEDICAL LIBRARY
UNIVERSITY OF NAIROBI**

DECLARATION

CANDIDATE:

This dissertation is my original work and has not been presented for a degree in any other University.

Signed: *J. Gitau* Date: *23/8/95*

Dr. Jane N. Gitau, MB.Ch.B (NBI)

SUPERVISOR:

This dissertation has been submitted for examination with my approval as a University Supervisor.

Signed: *M.N. Wambugu* Date: *25-8-95*

Dr. (Mrs.) M.N. Wambugu, M.B.Ch.B(Mak), M. Med. (NRB)
Senior Lecturer
Chairman
Department of Diagnostic Radiology
University of Nairobi.

ACKNOWLEDGEMENT

1. First and foremost, I wish to thank my supervisor Dr. (Mrs.) Wambugu whose enormous encouragement and guidance made it possible for this dissertation to be written.
2. I am grateful to the staff and lecturers in the department of diagnostic radiology for their support. Special thanks to Dr. Wambani, for sharing her expertise in Paediatric Radiology.
3. I thank the radiographers at the X-ray department, Keyatta National Hospital whose co-operation was crucial in this study.
4. I am grateful to Mrs. A.M. Symekher for doing a good job of the typing and printing.
5. Last but not least my husband Elijah and our children Lydia, Sheila, Abigael and Angela who created a comfortable atmosphere without which I would not have achieved much. I am very grateful for their enormous support and understanding.

CONTENTS

	<u>Page</u>
DECLARATION	(i)
ACKNOWLEDGEMENT	(ii)
CONTENTS	(iii)
GLOSSARY	(iv)
SUMMARY	1
INTRODUCTION	2
MATERIALS & METHODS	11
MICTURITION CYSTOURETHROGRAPHY BY TRANSURETHRAL CATHETERISATION	12
MICTURITION CYSTOURETHROGRAPHY BY SUPRAPUBIC PUNCTURE	13
RESULTS	15
TABLES	17
BAR CHARTS	20
DISCUSSION	22
RECOMMENDATIONS	50
ILLUSTRATIONS	51
REFERENCES	62
APPENDIX	

GLOSSARY

1. MCU - Micturating Cystourethrogram
2. VCUG - Voiding Cystourethrography
3. PUV - Posterior Urethral Valves
4. VUR - Vesicoureteric Reflux
5. US - Urethral Stricture
6. BNO - Bladder Neck Obstruction
7. NB - Neurogenic Bladder
8. FC - Fistulous communication
9. CA - Congenital anomaly
10. UTI - Urinary tract infection
11. US - Ultrasound
12. IVU - Intravenous urography
13. VATER - This is a mnemonic and includes anomalies of vertebral defect, Anal atresia, Tracheoesophageal fistula with Esophageal atresia, and Radial dysplasia.

SUMMARY

A prospective study of 90 children referred for voiding cystourethrography and the findings are presented.

82 males and 8 females were examined. 58.9% of the patients referred were in the 0-5 year age group and 41.1% in the 6-15 year age group.

67 (74.4%) patients referred had a clinical diagnosis of recurrent urinary tract infection. The most common radiological diagnosis was posterior urethral valves (45.6%) and 51.2% of these children were in the 0-3 years age group. The results are compared with other studies done elsewhere. From these results it came out quite clearly that a diagnosis of posterior urethral valves should always be considered by both the clinician and the radiologist when a child presents with features of UTI or obstructive uropathy. PUV should always be excluded in every male infant, child or young adult who presents with voiding difficulties or unexplained dilatation of the upper urinary tract as may be first seen on an IVU or US.

Of the patients with recurrent urinary tract infection, 17.9% were found to have vesicoureteral reflux.

INTRODUCTION AND LITERATURE REVIEW

The general term cystourethrogram embraces a number of roentgenographic techniques devised for study of the bladder and urethra during micturition. These techniques are especially valuable for demonstration of vesicoureteral reflux, for evaluating abnormalities of the bladder such as diverticula, and for the study of the urethra during micturition. They are used more widely in paediatric uroradiology than in adult uroradiology. A few years ago cine recording (voiding cine cystourethrography) enjoyed quite a vogue, but this technique is rarely used today because of the unacceptably high dosage of radiation delivered to the patient and the relatively poor quality of the cine image as compared to spot films (1).

The technique of voiding cystourethrography (VCUG) combines the advantages of retrograde cystography, micturition cystography and fluoroscopic (image intensification) monitoring of both retrograde filling of the bladder and micturition. Most authors consider it a substantial improvement over older techniques for detection of vesicoureteric reflux and for studying the anatomic and physiologic aspects of voiding, especially as they pertain to the vesical neck and urethra (1). Davis, Lich, Howerton and Joule have shown that a normal excretion urogram does not rule out urinary tract disease in infants and children and state that VCUG is the best method of detecting objective changes in the bladder, neck and urethra, diverticula of the bladder, urethral valves and reflux (2). They express the commonly held view that a voiding cystourethrogram

should be part of the radiological work up in all children with recurrent pyuria.

Increasing experience in adults has shown that it is also of value in this group in the detection of reflux and demonstration of urethral diverticula.

Voiding cystourethrography first came into widespread use about 1958 when image intensification x-ray apparatus with attached cine-roentgenographic equipment became generally available. Subsequently it has gained steadily in popularity and is now a frequently used, routine examination in many centres (1,3,4).

Dr. James Munene in his study on fifty two patients with posterior urethral valves states that the diagnosis is almost always made by micturating cystourethrography (5).. It was the most widely used investigation for diagnosis with cystourethroscopy being used for confirmation as well as for valve resection in 75% of the cases. Recurrent urinary tract infection is a frequent feature found in patients with posterior urethral valves as a result of urinary stasis in the bladder and dilated upper tracts.

Urinary tract infection is the most common abnormality found in the urinary tract in children. At any given moment between 1.2 and 1.6% of school girls have infected urine. In addition between 5 and 10% will have had a urinary tract infection while at school. The condition moreover is as dangerous as it is common (17,18,19,20).

Although it is commonly assumed that UTI commence after children have begun school, actually they commence in infancy, especially in neonates. The data illustrating this have been reported in three large series undertaken in Sweden, Britain and New Zealand (18). In these series it was found that infections are ten times more common in males than in females in the first 30 days of life. The series have also shown that the typical lesions of reflux nephropathy with infection develop in postnatal life and that the vast majority are not congenital or due to other causes.

These infections are extremely difficult to detect clinically prior to the age of one year and even between the ages of one and three years, the symptoms are not localised in the urinary tract. It has now been shown that UTI is the cause of otherwise unexplained fevers in the majority of children under the age of 3 years. If the cause of the fever is not immediately apparent, physicians commonly prescribe antibiotic therapy, thus partially treating the infection without being aware of the source of the infection. It is only after the age of about 5 years that children can refer symptoms to the urinary tract.

Only if physicians are aware of this fact can they diagnose the real problem, request the appropriate radiologic investigations, and demonstrate the progress of the lesion from a normal kidney to one that is clubbed and scarred. Unfortunately, excretory urography is first performed, when the child is able to lead the doctor to suspect UTI, and at this time, there is already scarring

and calyceal clubbing, which may be believed to be congenital.

Blickman et.al. and Friedland also agree in their papers that in many centres VCUG is the initial radiographic procedure for investigation of the urinary tract in children with urinary tract infection. Subsequent imaging of the urinary tract by excretory urography and sonography depends on the result of the VCUG (3,7).

Goldman and Freeman have recommended that an intravenous urogram and a voiding cystourethrogram be done on any child, boy or girl, with first documented urinary tract infection (4). Persistent bacteriuria in the absence of symptoms is also an indication for these studies since many authors have shown that asymptomatic bacteriuria is often associated with significant symptomatic disease later on, and renal damage, if appropriate treatment measures are not taken (4,6,7,12).

The problem of ureteral reflux has become important as the knowledge of the high incidence of urinary tract disease in childhood have become known. It has generally been agreed that in the absence of anomalies of the urinary tract, reflux is abnormal and that the ureterovesical junctions are competent both during and between acts of micturition. If this is so, then it becomes useful to be able to detect reflux in patients with UTI since therapy may be strongly influenced by the presence or absence of reflux.

Most children who develop renal damage (scarring) after UTI have vesico-ureteral reflux. VCUG is therefore usually recommended as the initial radiologic study in children with UTI. However, renal damage may occur also in the absence of reflux. Symptomatic urinary tract infection during childhood occur in 3-5% of girls and 1.2% of boys (14). Renal damage (scarring), also termed reflux nephropathy, develops in 5-15% of these children. The main objective is to identify those at risk of development of renal damage early enough to institute effective preventive measures. Much interest has been focused on defining the optimal radiologic workup (15,16), including new imaging methods like renal sonography and scintigraphy (isotope cystography and renal scintigraphy). The central role of vesicoureteral reflux and intrarenal reflux in the development of renal damage in children with UTI is well recognised, as stressed by Smellie et. al. (17) and Smellie and Normand (18), who have stated that renal damage is almost always associated with vesico-ureteral reflux. It has therefore been suggested that VCUG be the initial radiologic study in children with UTI and that those with reflux should be selected for more thorough workup (3). However, it seems appropriate to consider the risk of developing similar renal damage after UTI in the absence of reflux. Otherwise, the sensitivity and predictive value of such a diagnostic approach cannot be estimated. In a study done by Hellstrom et.al. (6) the frequency of reflux in children with non-obstructive, febrile urinary-tract infection was 32%, which is in agreement with previous studies (19,20). The proportion of children with renal damage was 10 of 84 (12%). Previous studies

have shown renal damage of similar frequency: Winberg et al (20) found 6.4%; Segura et al (21) and Smellie et al (29) found 15%.

Cyclic voiding cystourethrography has been recommended for improved demonstration of reflux from ureters which insert into the urethra (22) and more recently it has been observed that the diagnostic reliability can be enhanced by a second voiding cycle (23, 24).

Isotope techniques for the detection of reflux have recently come into common use. These techniques are excellent for follow up studies in children because the child receives a much lower dose of radiation and the procedure can be performed intravenously, thus avoiding bladder catheterisation (7). Such studies do not show fine detail, hence are not recommended for the first examination, where detailed anatomy and function must be established.

The most common form of congenital distal obstruction in males is posterior urethral valves. While it is possible to see the distended urethra with sonography, the sensitivity and specificity of seeing this portion of a dilated urinary tract is really unknown. When there is distension of the upper urinary tract a VCUG is performed to localize the region of obstruction. It is important to note that the most common presenting symptoms of a patient with posterior urethral valves are inability to void or voiding with a poor or intermittent stream, an abdominal mass, or less frequently but most importantly for the sonographer, ascites. The urinary system decompresses by rupturing at the area of least

resistance - the calyceal fornix - with extravasation of urine into the perirenal space (urinoma), and into the peritoneal cavity (ascites). Therefore, unexplained ascites in the newborn male should be considered secondary to extravasation of urine until proven otherwise (25).

It should be noted that dilatation of the renal collecting system and ureters may be found because of extrinsic pressure on the urinary system. These extrinsic impressions may be secondary to imperforate anus, intersex anomalies, and tumors. Syndromatic causes of dilatation, such as the megacystic - microcolon - malrotation syndrome or the prune belly syndrome, have to be separated from true obstructions. Amongst other causes for obstruction which the VCUG will uncover are urethral diverticula, polyps, urethral strictures and ureterocele.

Michael Zerlin et al in his study on bladder capacity observed that the assessment of the capacity of the bladder to hold urine (or contrast material) is an important aspect of the interpretation of paediatric VCUG and can yield valuable diagnostic information (9). An abnormally large bladder capacity has been associated with an increased frequency of urinary tract infections in children with abnormal voiding patterns, and can be an important indicator of aberrant micturition in children with severe vesico-ureteric reflux. Bladder capacity can also be increased in patients with urinary retention secondary to bladder outlet obstruction, neurogenic dysfunction, or diabetes insipidus. A small capacity

bladder can result from decreased bladder compliance in patients with neurogenic dysfunction or obstructive uropathy, as well as from defunctionalisation of the bladder after complete urinary diversion. Bladder capacity is often temporarily reduced during episodes of acute cystitis. Occasionally, a healthy child with an anatomically and neurologically normal bladder will void after only a very small volume of contrast material has been infused, but the child's bladder will hold a much larger volume when refilled. Recognition that the initial "capacity" is physiologically too small is important, since the sensitivity of VCUG in the detection of VUR is in part related to the volume to which the bladder is filled.

Micturition cystourethrography is also very useful in the investigation of post operative complications of the urinary tract. In the investigation of patients with perforation of the augmented bladder Lebowitz and Braverman in their paper state that cystography with fluoroscopy is the imaging study of choice, and it should be performed immediately and is usually diagnostic (8).

In summary, micturating cystourethrography is indicated for the following purposes:

1. Demonstration of the ability of the bladder to contract.
2. Demonstration of the peripheral control of micturition.
3. Assessment of vesical diverticula and overall marginal outline of the bladder.

4. Investigation of anatomical abnormalities of the bladder neck and urethra.
5. Recognition of vesicoureteric reflux.
6. Investigation of recurrent urinary tract infection.

The examination is contraindicated in the presence of acute infections of the bladder and urethra.

4. Investigation of anatomical abnormalities of the bladder neck and urethra.
5. Recognition of vesicoureteric reflux.
6. Investigation of recurrent urinary tract infection.

The examination is contraindicated in the presence of acute infections of the bladder and urethra.

MATERIALS AND METHODS

The patients recruited were all children referred by Clinicians for micturating cystourethrography either from the ward or the outpatient clinics, upto 15 years of age.

The only contraindication to the examination was the presence of active lower urinary tract infection as shown by pus per urethra. A total of 90 consecutive paediatric patients were investigated over a period of one year. The mode of investigation was by micturating cystourethrography by transurethral catheterisation. In certain cases, for example, in some infants with lower urinary tract obstruction, it was impossible to insert the catheter, hence suprapubic puncture was done. Some patients came with suprapubic catheters inserted by clinicians in the ward as a result of obstruction.

The patients were given an appointment for the examination to be carried out, preferably in the mornings. No special preparation was required.

MICTURITION CYSTOURETHROGRAPHY BY TRANSURETHRAL CATHETERISATION

Requirements:

1. Fluoroscopy table (adjustable) with image intensifier.
2. Size 8F or 5F (for neonates) nasogastric tube.
3. Sterile catheterization tray.
4. Contrast media - water soluble 36% meglumine salt of iodamide (w/v), representing 16.6% iodine, or iodine 166 mg/ml (uromiro 36% from Bracco).
5. Lubricant - K-Y Jelly (from Johnson and Johnson).

The patient was undressed and placed in supine position on the fluoroscopy table. The patient was examined for any frank pus per urethra which was the only contraindication to the examination. A plain film was taken. Under aseptic technique, a lubricated 8F nasogastric tube was inserted through the urethral meatus into the bladder. The nasogastric tube was fixed onto the penis in male infants, and to the thigh in females, using an adhesive tape. Urine in the bladder was drained into a receiver. Dilute contrast media was used. All this was done in the presence of the parent who reassured the child that all was well and the child was relaxed for ease of the examination. Sterile 50mls syringes were filled with contrast media which was then injected slowly into the bladder under screening. Spot films were then taken after or during contrast injection and during voiding. A post micturition film was also be taken.

MICTURITION CYSTOURETHROGRAPHY BY SUPRAPUBIC PUNCTURE

The examination was performed without any premedication or preparation. Suprapubic puncture of the bladder was performed only in patients with a full bladder which was confirmed just prior to the start of the examination by ultrasound. If the bladder is not full the patient was given fluid to drink and waited for about one hour. The patient was placed on a fluoroscopy table. The area between the symphysis pubis and umbilicus was thoroughly disinfected and the bladder was punctured in the midline, 1 and 2 cm above the symphysis pubis, with the needle directed 10 to 15° caudally. A 21-gauge intravenous cannula was used to puncture the bladder and the needle was withdrawn leaving the plastic cannula in the bladder. As soon as there was good urine flow, as much urine as possible was aspirated. The patient was placed in a supine, oblique position with a urinal under the penis. In female patients and very young infants and neonates, an absorbent material was placed between the legs on the examination table.

Contrast was injected slowly under screening until the patient expressed the urge to micturate or started spontaneously to micturate in case of the very young. Spot films were taken as necessary. When the examination was complete the cannula was removed. No antibiotic cover was given after the procedure because the cannulation was done under aseptic conditions.

The information related to the patient was recorded thus:

1. Name, age and the sex of the patient.
2. Inpatient or outpatient number.
3. X-ray department registration number.
4. Clinical history of the disease plus any other associated condition.
5. Clinical diagnosis.
6. Radiological diagnosis.

The films were reported with the help of the supervisor. Results, discussions and conclusions were drawn and radiographs and tables appended as required.

RESULTS

The relevant data from the 90 patients examined were analysed as given in the tables of results and bar charts. Out of the 90 patients investigated 8 were females and 53 (58.9%) fell into the 0-5 year age group (Table 1). 20 patients (22.2%) who were presented for the examination had no history given in the forms except for the working diagnosis.

The most common presenting symptoms and signs in the 0-3 years age group was, failure to thrive, dysuria, abdominal mass and dribbling of urine. Those above 3 years main complaint was dysuria, poor stream, urinary incontinence and loin pain.

A clinical diagnosis of recurrent urinary tract infection was made in 67 (74.4%) of the patients investigated (Table 2).

Radiologically the most frequent diagnosis was posterior urethral valves (Table 3). Vesico - ureteric reflux was diagnosed radiologically in 16.7% and in most cases this was secondary to obstructive uropathy mainly due to posterior urethral valves or urethral stricture. Bladder neck obstruction (3%) and neurogenic bladder (5.6%) was also quite common. 11% of the patients examined were found to be normal.

Most of the patients diagnosed radiologically to have posterior urethral valves were in the 0-3 year age group (51.2%) and less commonly in the 4-6 year age group (29.3%) (Table 4). It is

important to note that 3 patients in the 10-15 year age group had posterior urethral valves although the clinical diagnosis was urethral stricture.

61.1% of patients were referred for micturating cystourethrography as the first radiological examination and majority were found to have obstructive uropathy which predisposed to the recurrent urinary tract infection. The rest of the patients were sent for sonography or excretion urography as the first examination or were sent with two forms for excretion urography and for micturating cystourethrography or for sonography and micturating cystourethrography.

Table 1: MALE TO FEMALE RATIO IN DIFFERENT AGE GROUPS

AGE GROUP	MALE	FEMALE	TOTAL	FREQUENCY (%)
0 - 5 YRS	49	4	53	58.9
6 - 15 "	33	4	37	41.1

Table 2: FREQUENCY DISTRIBUTION OF PRIMARY CLINICAL DIAGNOSIS

CLINICAL DIAGNOSIS	NUMBER OF PATIENTS	FREQUENCY (%)
Urinary Tract Infection	67	74.4
Posterior Urethral valves	43	47.8
Vesico-ureteric Reflux	3	3.3
Urethral stricture	9	10
Fistula	3	3.3
Congenital anomaly	3	3.3
Others	5	5.6

Table 3: FREQUENCY DISTRIBUTION OF RADIOLOGICAL DIAGNOSIS

RADIOLOGICAL DIAGNOSIS	NUMBER OF PATIENTS	FREQUENCY (%)
Posterior urethral valves	41	45.6
Vesico-ureteric reflux	15	16.7
Stricture of Urethra	10	11.1
Bladder neck obstruction	3	3.3
Neurogenic Bladder	5	5.6
Fistulous communication	4	4.4
Congenital anomaly	4	4.4
Others	3	3.3
Normal	10	11.1

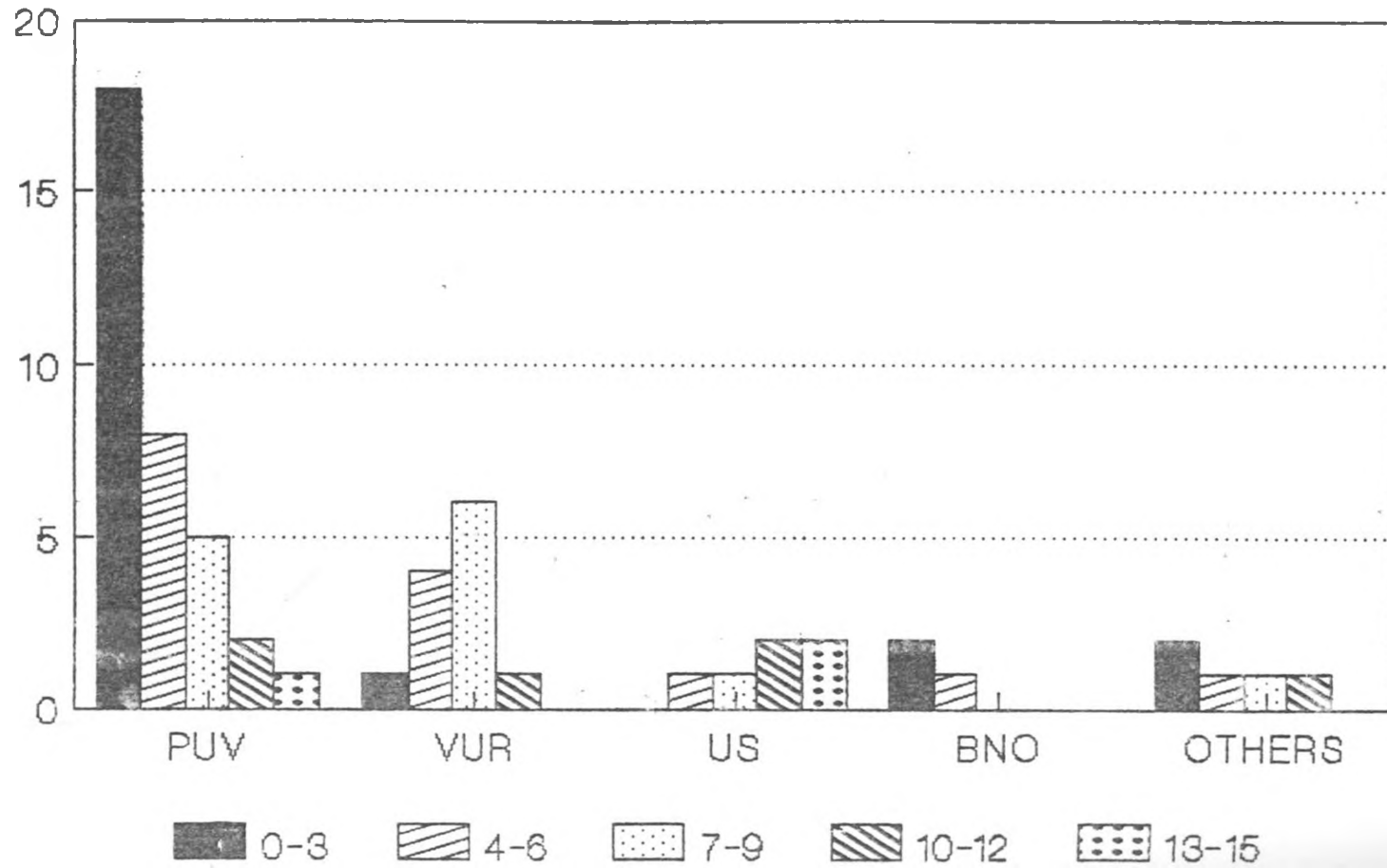
Table 4: FREQUENCY DISTRIBUTION OF PATIENTS WITH PUV VERSUS AGE

AGE	NUMBER OF PATIENTS	FREQUENCY (%)
0 - 3	21	51.2
4 - 6	12	29.3
7 - 9	5	12.2
10 - 12	2	4.9
13 - 15	1	2.4

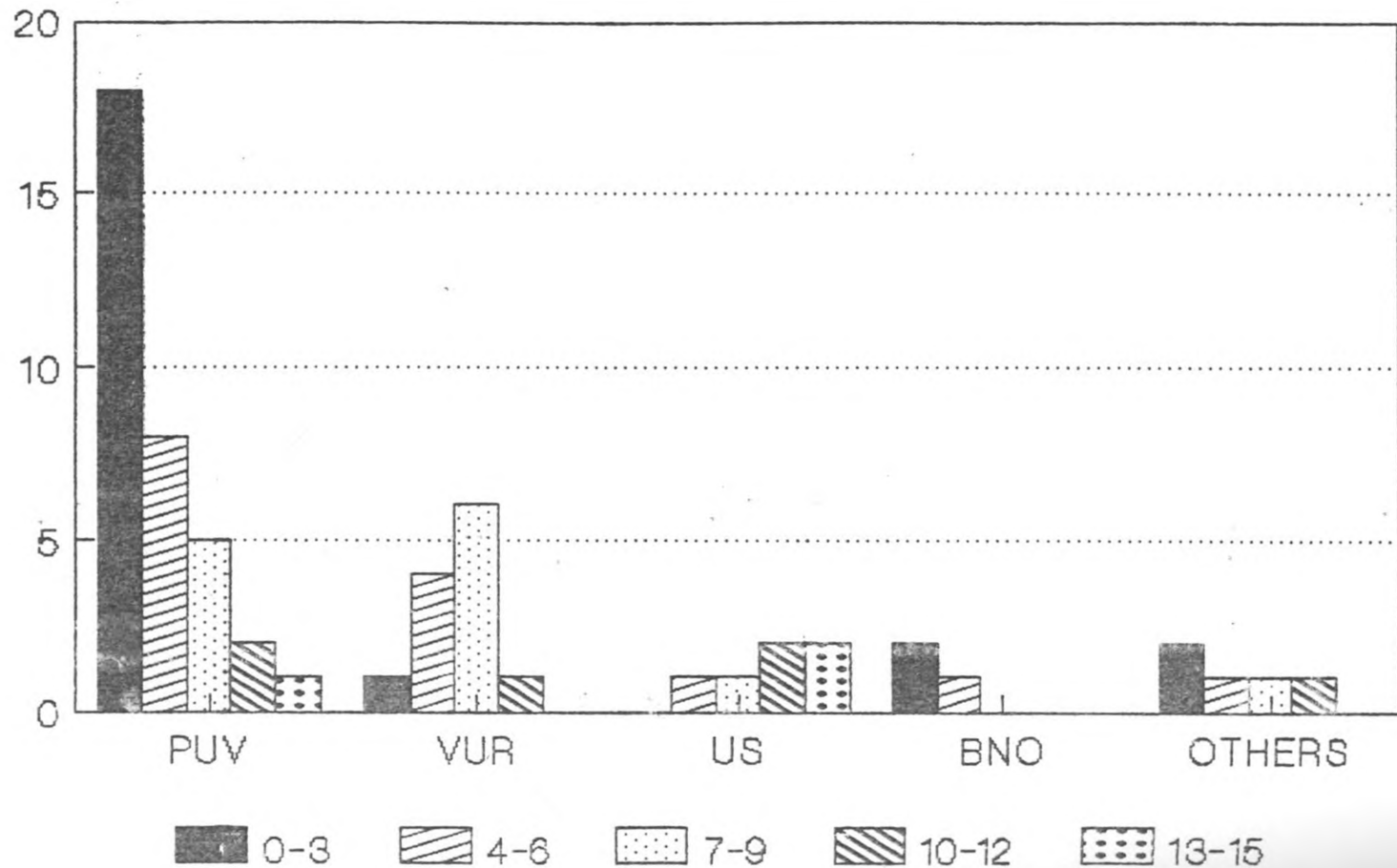
Table 5: RADIOLOGICAL FINDINGS VERSUS AGE IN PATIENTS WITH URINARY TRACT INFECTIONS

	AGE (YEARS)											
	0 - 3		4 - 6		7 - 9		10 - 12		13 - 15		TOTAL	
	NO.	FREQ.	NO.	FREQ.	NO.	FREQ.	NO.	FREQ.	NO.	FREQ.	NO.	FREQ.
PUV	18	26.9	8	11.9	5	7.5	2	2.98	1	1.5	34	50.8
VUR	1	1.5	4	5.97	6	8.95	1	1.5	-	-	12	17.9
URETHRAL STRICTURE	-	-	1	1.5	1	1.5	2	2.98	2	2.98	6	8.96
BLADDER NECK OBSTRU- CTION	2	2.98	1	1.5	-	-	-	-	-	-	3	4.48
OTHERS	2	2.98	1	1.5	1	1.5	1	1.5	-	-	5	7.48
NORMAL	4	5.97	2	3.98	1	1.5	-	-	-	-	7	10.45
TOTAL	27	40.3	17	25.4	14	20.9	6	9	3	4.5	67	100

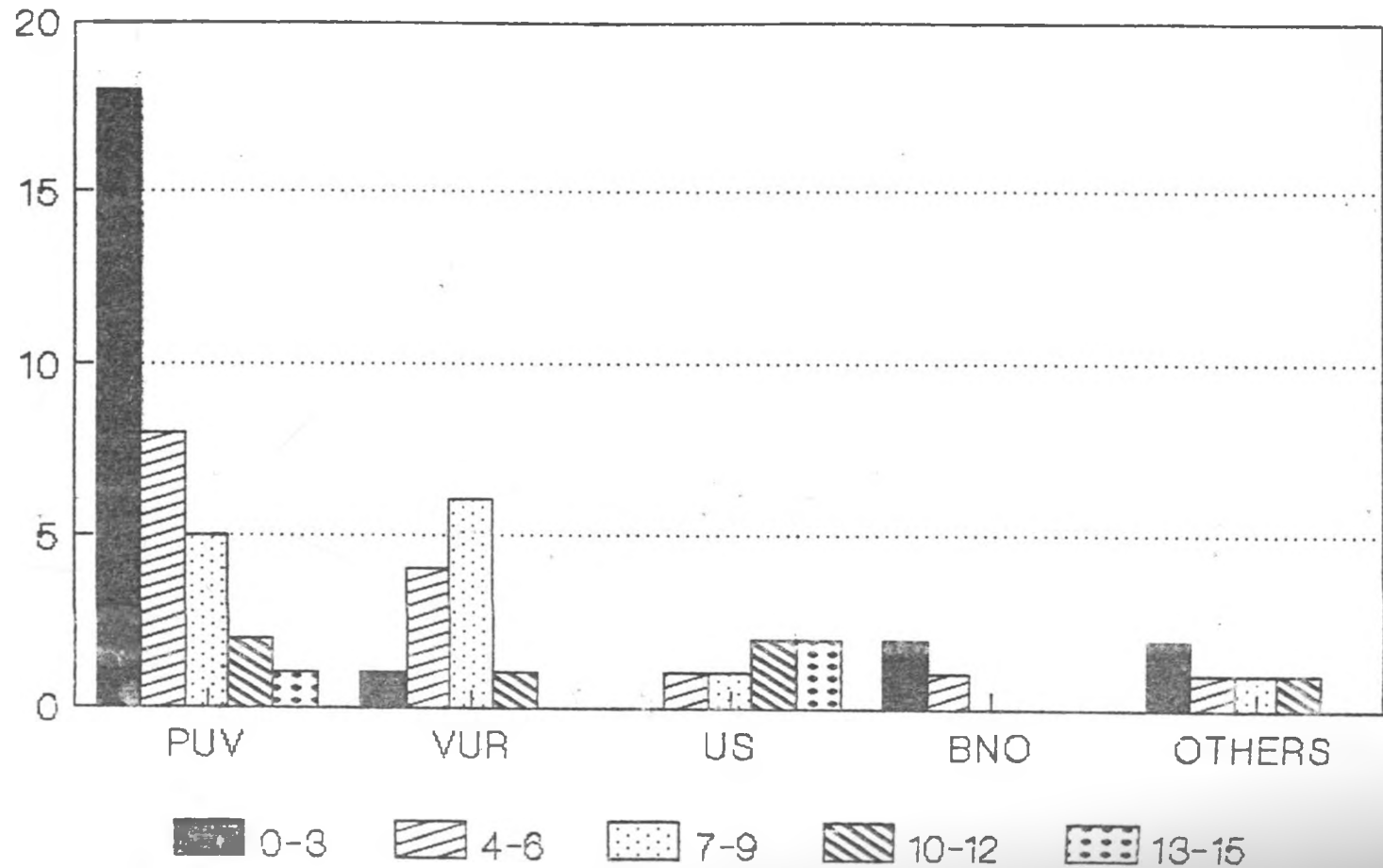
Radiological Diagnosis in patients with U.T.I.



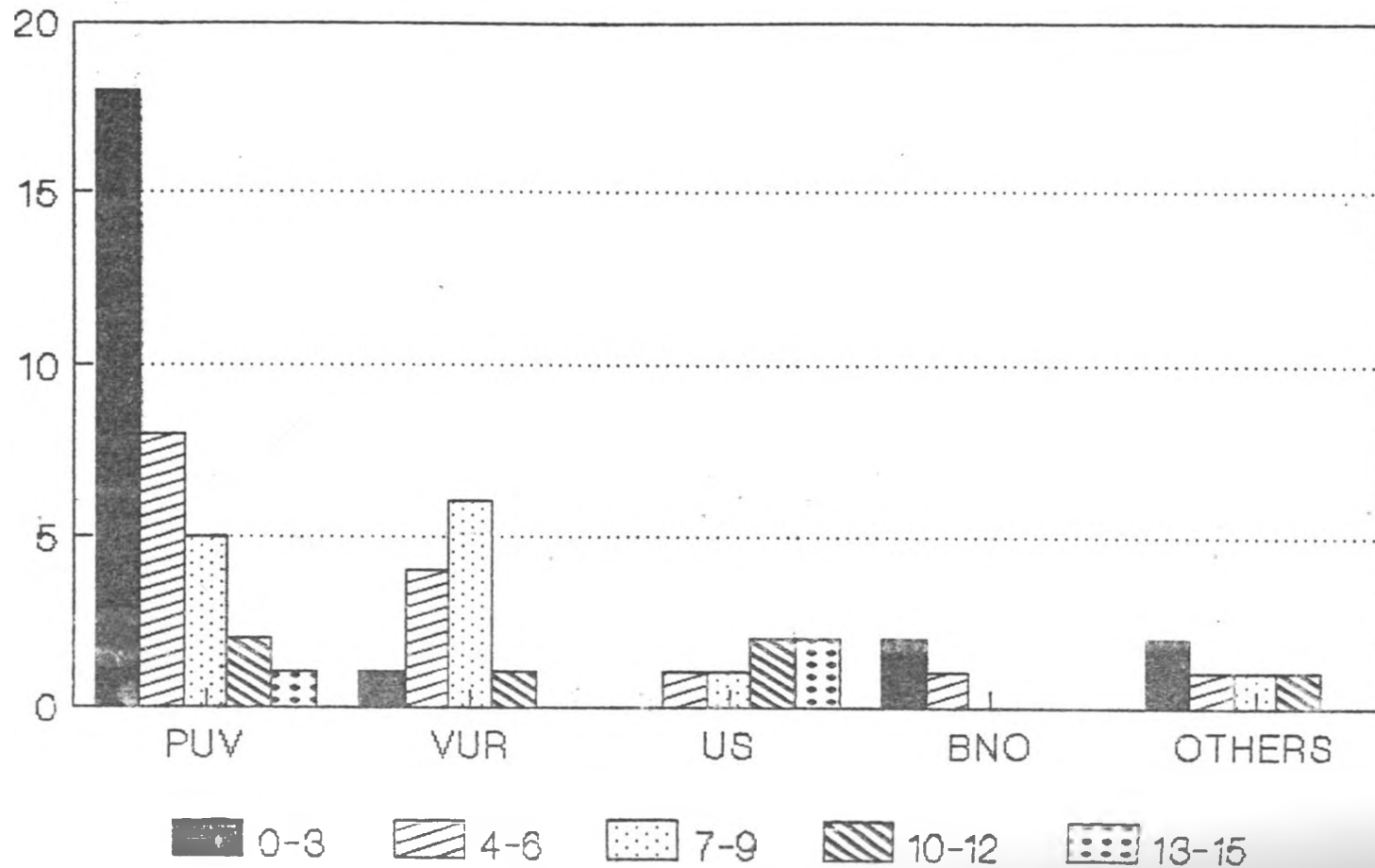
Radiological Diagnosis in patients with U.T.I.



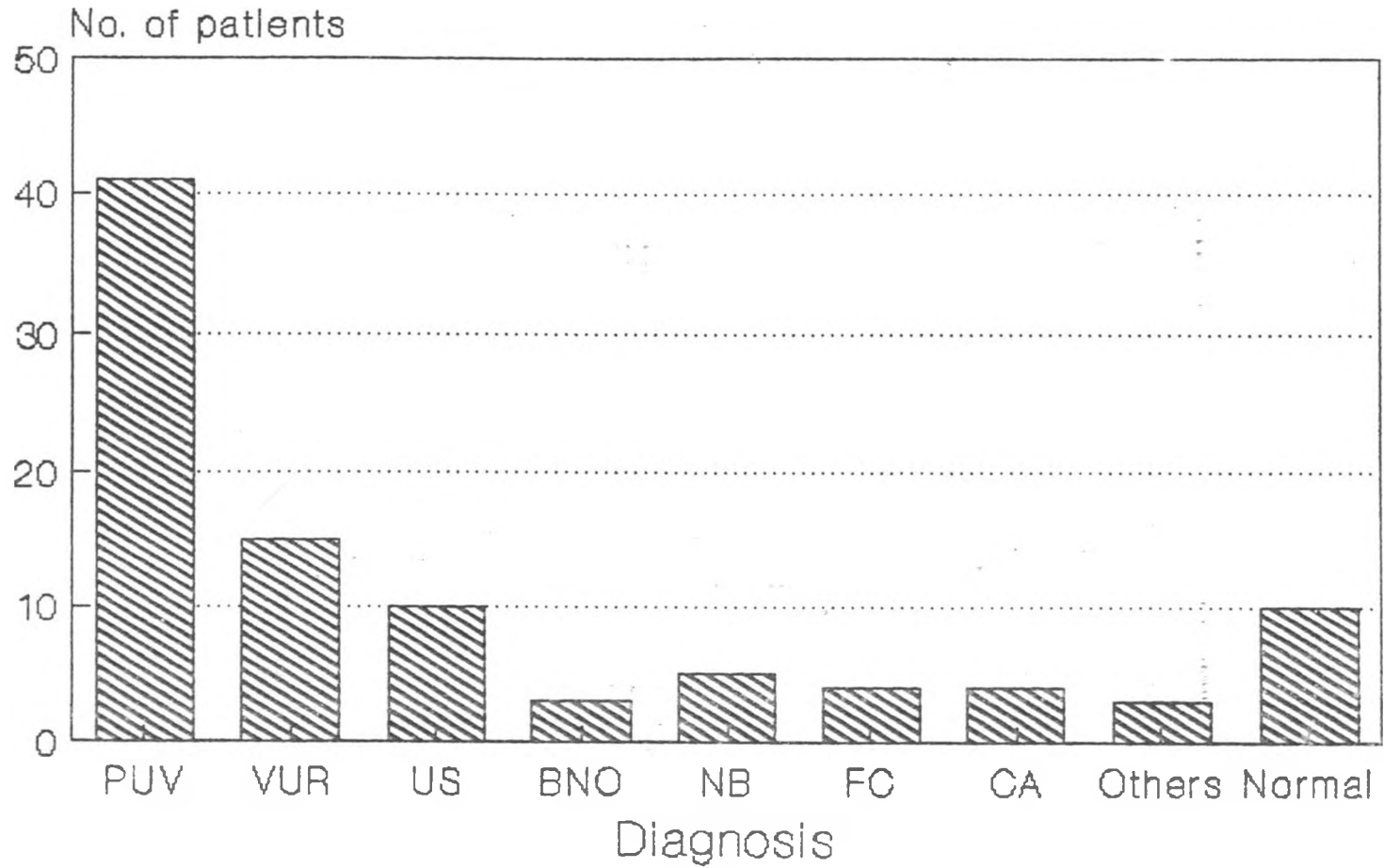
Radiological Diagnosis in patients with U.T.I.



Radiological Diagnosis in patients with U.T.I.



Frequency of Radiological Diagnosis



DISCUSSION

NORMAL ANATOMY OF THE MALE AND FEMALE LOWER URINARY TRACT

Urinary Bladder

The bladder is a hollow, muscular organ which stores the urine. In the empty or contracted condition, it lies in the true pelvis, posterior to the symphysis pubis, from which it is separated by a previscal space. This space is filled with loose connective tissue that allows the filling bladder to move cranial. In the male, the bladder lies anterior to the rectum, seminal vesicles, and ductus deferens. In the female, it is anterior to the uterus and upper vagina. When the bladder is filled, its base becomes a little depressed as the superior surface pushes into the abdominal region.

Internally, there are three openings in the urinary bladder wall, the two ureters and a urethra in the base. These three openings mark the corners of a triangle and delimit an area called the trigone.

The urinary bladder is held loosely in position by true ligaments at its base and vortex and also by folds of the peritoneum which are reflected from the bladder to the wall of the abdomen. The bladder is also enclosed by the loose subserous fascia. In infants, the bladder is an abdominal organ, it does not attain its adult position on the pelvic floor until about the 20th year. As a consequence, anterolateral protrusions of the bladder through the inguinal rings occur with appreciable frequency in normal children under the age of 1 year.

Urethra

The urethra extends from the urinary bladder to the body surface. It differs considerably in males and females.

The female urethra (See diagram 1 and illustration 1)

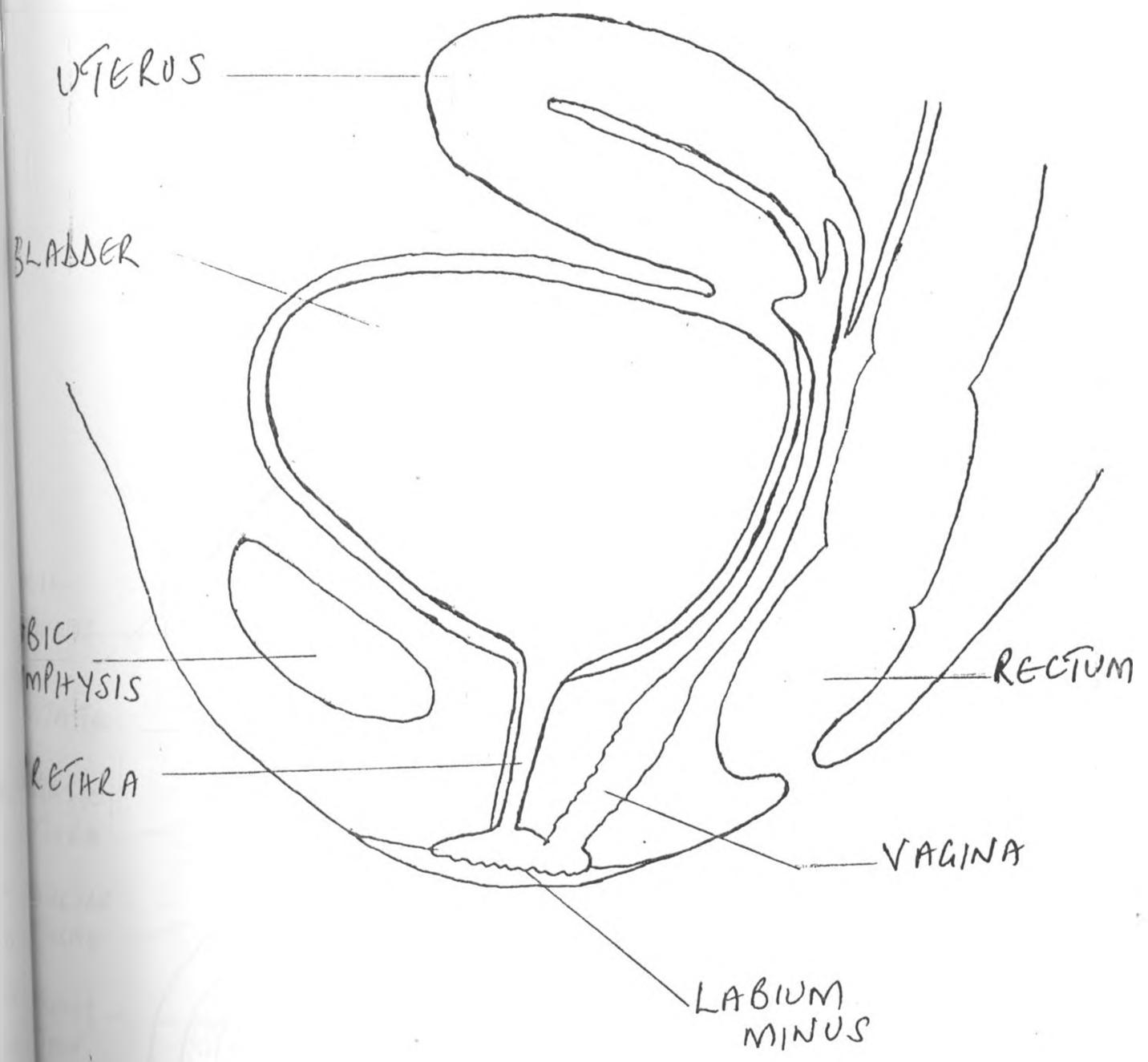
The female urethra is about 4cm (1.5in) long. It is closely applied to the front wall of the vagina and opens just anterior to the vaginal orifice. Its lining is thrown into longitudinal folds. Its mucosa is lined with transitional epithelium near the bladder, which gradually becomes stratified squamous epithelium at its external orifice. There are mucus secreting cells present. Its lamina propria is of loose connective tissue with many elastic fibres. The lamina propria also has an extensive venous plexus, and hence a cavernous or erectile character. The muscular coat consists of circular fibres continuous with those of the bladder. Where the urethra passes through the urogenital diaphragm striated (voluntary) circular muscle forms an external sphincter.

The male urethra (See diagram 2 and illustration 2)

The male urethra is about 20 cm long (8 in). It passes downward from the bladder, then forward for a short distance and finally downwards again. It is divided into two major parts: (1) the posterior urethra, which includes the prostatic and membranous portion, and (2) the anterior urethra, which extends from the urogenital diaphragm to the urethral meatus.

The prostatic urethra is about 3cm in length. It begins at the

DIAGRAM 1



ANATOMY OF THE NORMAL FEMALE URETHRA.

DIAGRAM 2

ANATOMY OF THE NORMAL MALE URETHRA

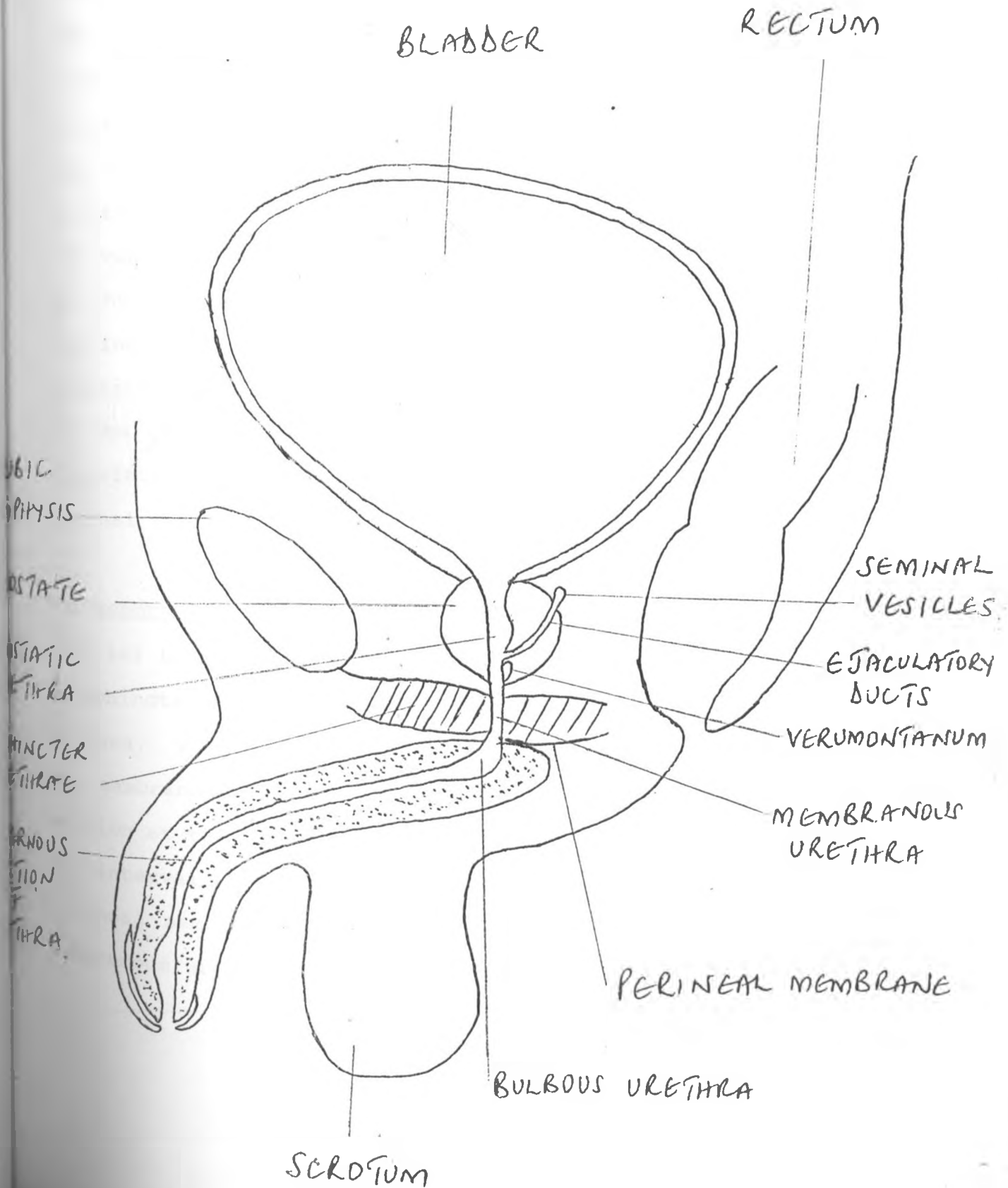
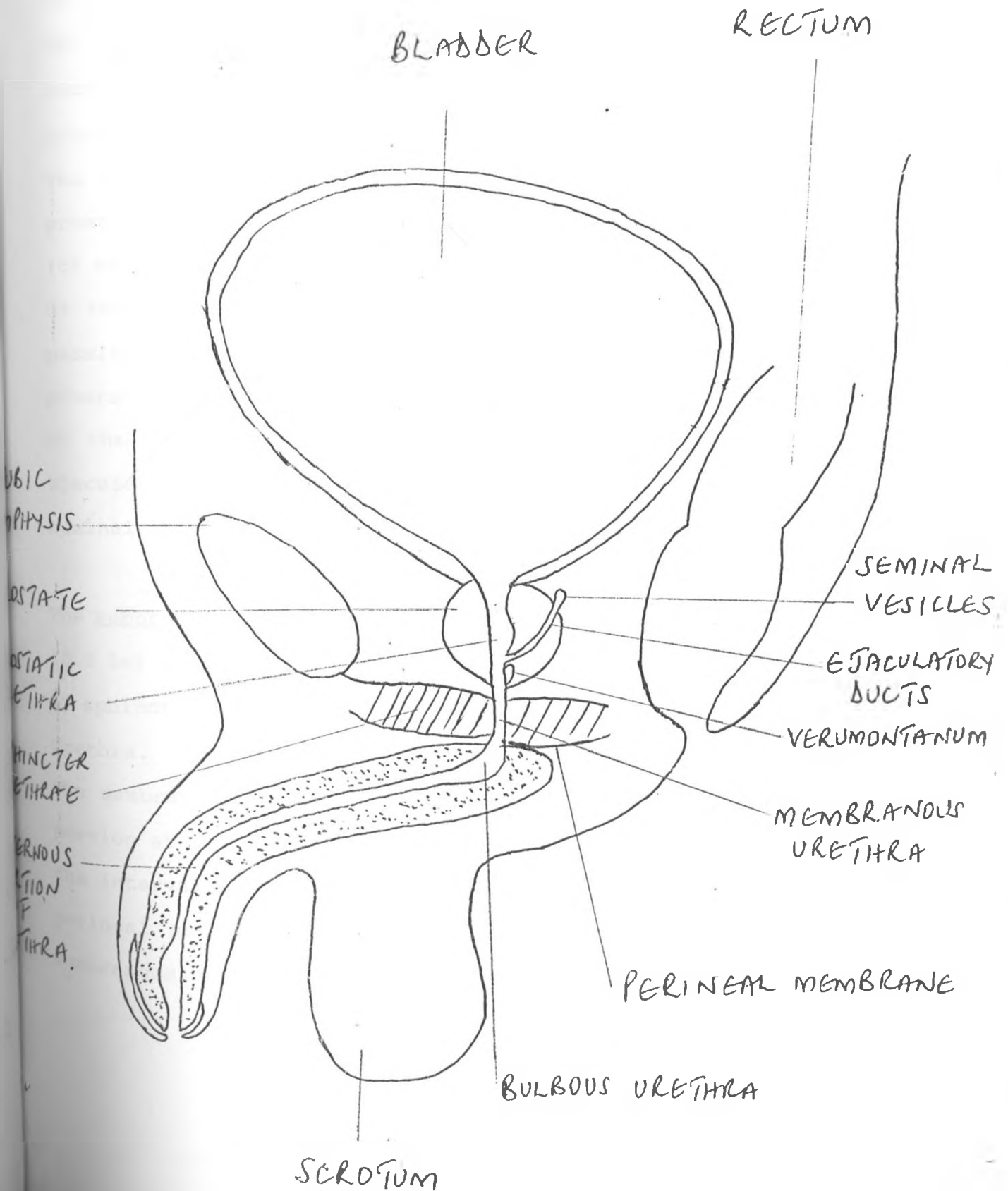


DIAGRAM 2

ANATOMY OF THE NORMAL MALE URETHRA



internal urethral orifice (involuntary internal sphincter) and is continuous with the membranous urethra at the apex of the prostate gland. The prostatic urethra is the most dilatable part of the urethra. From the posterior wall the urethral crest projects into the lumen, giving the latter a semilunar appearance in cross section. The urethral crest is most prominent at the middle of the prostate where the prostatic urethra lumen is widest transversely. The crest becomes indistinct in the upper and lower parts of the prostatic urethra. On its summit, called the colliculus seminalis (or verumontanum), the urethral crest is perforated by the opening of the prostatic utricle. The utricle is a small diverticulum passing upwards in the substance of the median lobe of the prostate. On either side of the opening of the prostatic utricle on the colliculus seminalis is the slit - like orifice of the ejaculatory duct, which conveys the semen and secretions of the seminal vesicles.

The membranous portion. This part of the urethra is about 1 to 2 cm (0.5 in) long. It is surrounded by the striated external sphincter or sphincter urethrae muscle and is the least dilatable part of the urethra. The lumen is stellate in section and the wall is thin. The membranous part of the urethra is continuous with the spongy portion at the lower part of the perineal membrane, which bridges the interval between the pubic rami and the pubic symphysis. The perineal membrane and the sphincter muscle above it anchor the membranous urethra firmly to the bony pelvis.

The penile or spongy portion: This part of the urethra is about 15cm long and comprises a fixed and a free or mobile portion. The fixed portion begins at the lower surface of the perineal membrane within the substance of the bulb of the penis which projects behind the urethra for about 1.5cm. The suspensory ligament of the penis connects that organ to the lower part of the pubic symphysis and the course of the urethra ceases to be fixed in front of this region of attachment. From its entrance into the bulb of the penis until it opens at the end of the penis as the external urethral orifice or meatus, the urethra is closely related to the erectile tissue of the corpus spongiosum and that is why the term "spongy" is used as an alternative to "penile" when this portion of the urethra is described. Throughout most of its course the spongy urethra forms in section a transversely disposed slit, but in the glans and at the external meatus the slit is disposed vertically. The calibre of the urethra is wider in the glans and within the bulb than within the main part of the penis. The dilatation within the glans is known as the fossa navicularis (terminalis) and that within the bulb the intrabulbar fossa. It should be noted that the external urethral orifice is the most constricted part of the whole urethra, so that an instrument that can be passed through this orifice will pass through the remainder of the urethra, provided there are no abnormal constrictions.

Effect of micturition on fundus of bladder, vesical neck, and urethra

At the beginning of micturition the fundus lowers and the vesical neck widens. As a result the vesical neck and prostatic urethra become funnel-shaped, and this may give the impression of shortening of the prostatic urethra. The widening or dilatation of the prostatic urethra may vary with such factors as tonicity (or relaxation) of the external sphincter and whether the patient is voiding freely or against resistance.

In the oblique projection the prostatic urethra appears as a gently curved section with its concavity directed ventrally (anteriorly). Its diameter on the urethrogram depends on the technique used. For example, in VCUG it is well distended owing to the resistance of the external sphincter, whereas in retrograde urethrograms it is usually distended very little. In the mid-portion of the posterior wall of the prostatic urethra, an oval-shaped negative shadow or filling defect (to 1cm in length) is often noted which represents the verumontanum (colliculus seminalis). Occasionally small folds may be seen as linear filling defects arising from the verumontanum, running distally and laterally and terminating in the wall of the membranous urethra. These folds represent the finger-like projections or small ridges seen on cystoscopy and are the posterior urethral valves. These ridges (PUV) are more predominant in the newborn infant and can be the cause of the urinary obstruction if they fail to obliterate.

The membranous urethra is seen as a narrowing of the lumen distal to the verumontanum. Usually this portion is less adequately filled with contrast medium than the prostatic urethra. The diameter of the membranous urethra depends on the relative state of tonicity of the external urethral sphincter; it usually appears wider in the voiding than in the retrograde urethrogram.

The anterior urethra appears as a wide channel on the urethrogram - appreciably wider than would have been thought. The bulbous urethra appears as a wide tube forming a gentle curve between the prostatic urethra and the penoscrotal juncture where the pendulous (penile) urethra begins. The calibre (degree of distension) appears greatest in the retrograde urethrogram, next in the VCUG.

The cystourethrogram in the male child does not differ greatly from that in the adult, except in calibre and length, and except that the fundus of the bladder usually lies on a higher level than in the adult (See illustration 2).

The membranous urethra is seen as a narrowing of the lumen distal to the verumontanum. Usually this portion is less adequately filled with contrast medium than the prostatic urethra. The diameter of the membranous urethra depends on the relative state of tonicity of the external urethral sphincter; it usually appears wider in the voiding than in the retrograde urethrogram.

The anterior urethra appears as a wide channel on the urethrogram - appreciably wider than would have been thought. The bulbous urethra appears as a wide tube forming a gentle curve between the prostatic urethra and the penoscrotal juncture where the pendulous (penile) urethra begins. The calibre (degree of distension) appears greatest in the retrograde urethrogram, next in the VCUG.

The cystourethrogram in the male child does not differ greatly from that in the adult, except in calibre and length, and except that the fundus of the bladder usually lies on a higher level than in the adult (See illustration 2).

DEVELOPMENT OF THE URINARY BLADDER AND URETHRA -

(See diagrams 3 and 4)

The development of the urinary bladder is closely related to the formation of the cloaca. This is a cavity which forms the common opening for the caudal part of the hindgut, the allantois and the mesonephric duct.

The entodermal cloaca is separated from the ectodermal proctodeum by a thin membrane called cloacal membrane. The caudal migration of the urorectal septum divides the cloaca into two parts namely an anterior part called the urogenital sinus, and a posterior part called the rectal canal.

The membrane itself is divided into the urogenital and anal membranes. The perineum is formed at the site of fusion of the urorectal septum with the cloacal membrane. These stages of development precede the formation of the urinary bladder. The urogenital sinus differentiates into two segments:

- a) the vesicourethral canal where the urinary bladder and the upper portion of the urethra are formed, and
- b) the definitive urogenital sinus where the main part of the urethra develops. The division of the two segments is marked by the entry into the bladder of the mesonephric ducts.

The enlargement of the vesicourethral canal incorporates the lower

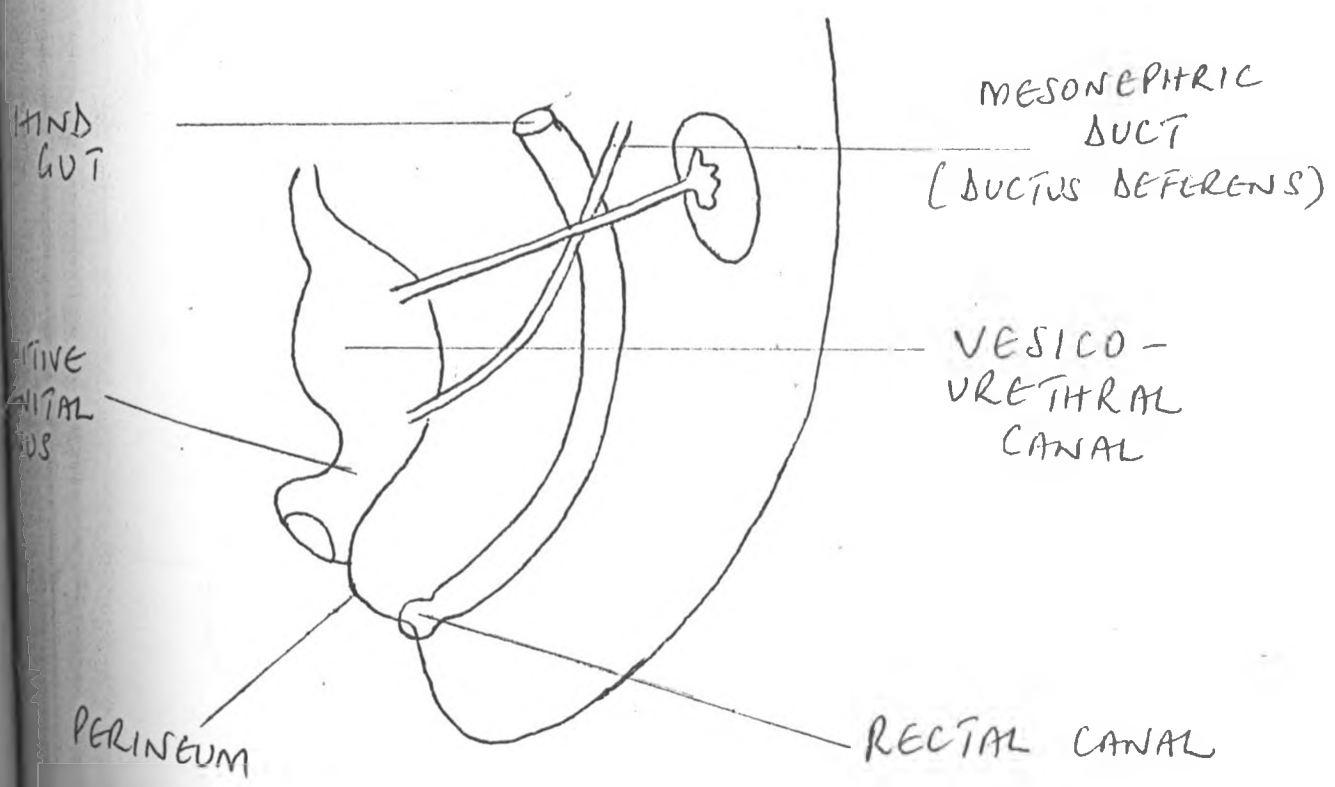
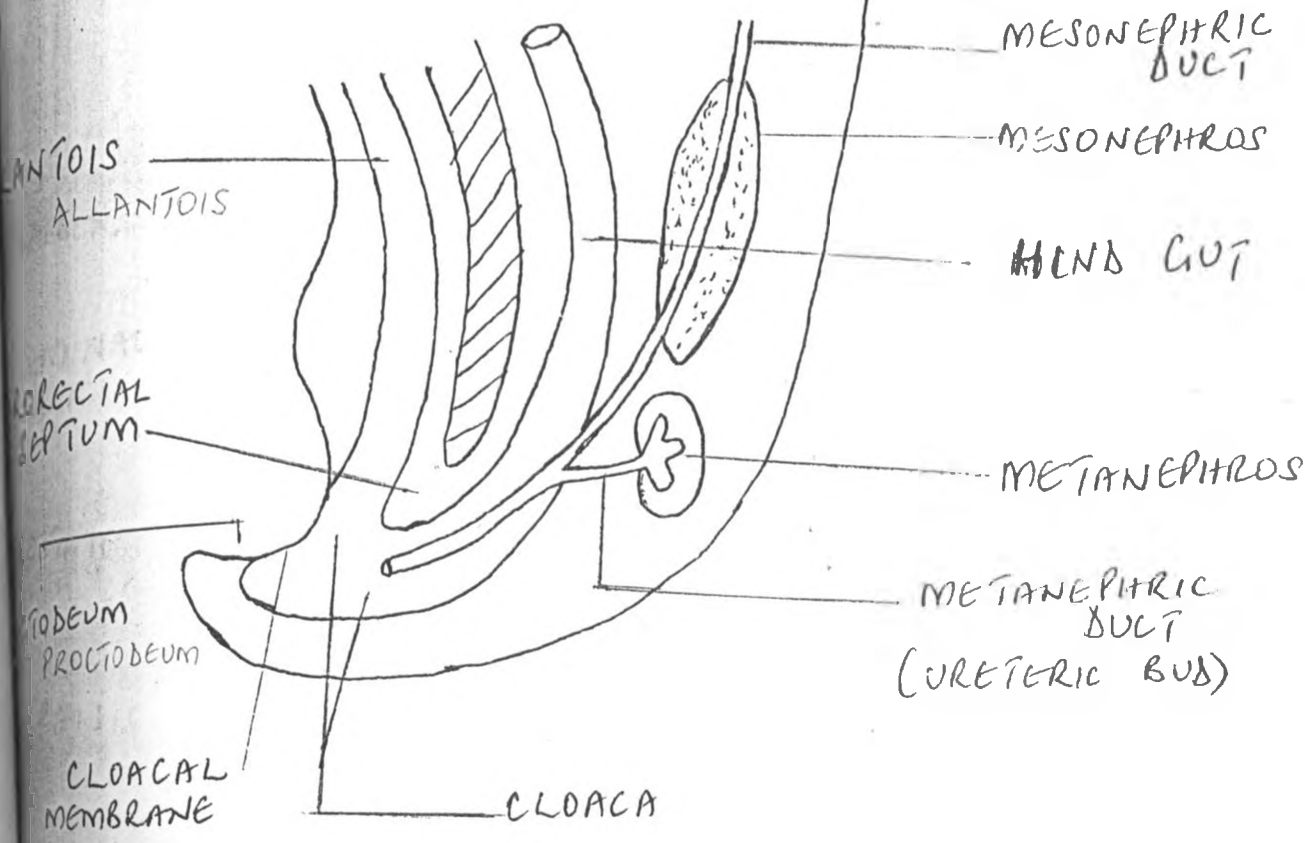
portion of the allantois which at this stage obliterates to form a thick fibrous cord called the urachus. The urachus connects the apex of the bladder to the umbilicus. In post natal life it becomes the median umbilical ligament. With the development of the vesicourethral canal the opening of the mesonephric duct changes in position. At first the mesonephric duct and the ureteric bud on both sides of the cloaca have a common secretory duct. Later the common duct is absorbed and the mesonephric ducts and the ureter open separately. The ureteric orifices move cranially and laterally and the area between them becomes the primitive vesical trigone. As a result the ureters open into the bladder while the mesonephric ducts (ductus deferens) are connected to the urethra.

The mucosa of the bladder develops from the entoderm of the cloaca while the trigone is probably of mesodermal origin. The musculature of the bladder derives from the splanchnic mesoderm. The second segment of the urogenital sinus (definitive urogenital sinus) gives rise to the main part of the urethra and follows a different pattern of development in the two sexes. In the male it divides into the pelvic and penile or phallic portions. The pelvic portion develops into the prostatic urethra and the membranous urethra while the phallic portion gives rise to the penile urethra.

In the female the pelvic and phallic portions form the urethra, part of the vagina and the vestibule.

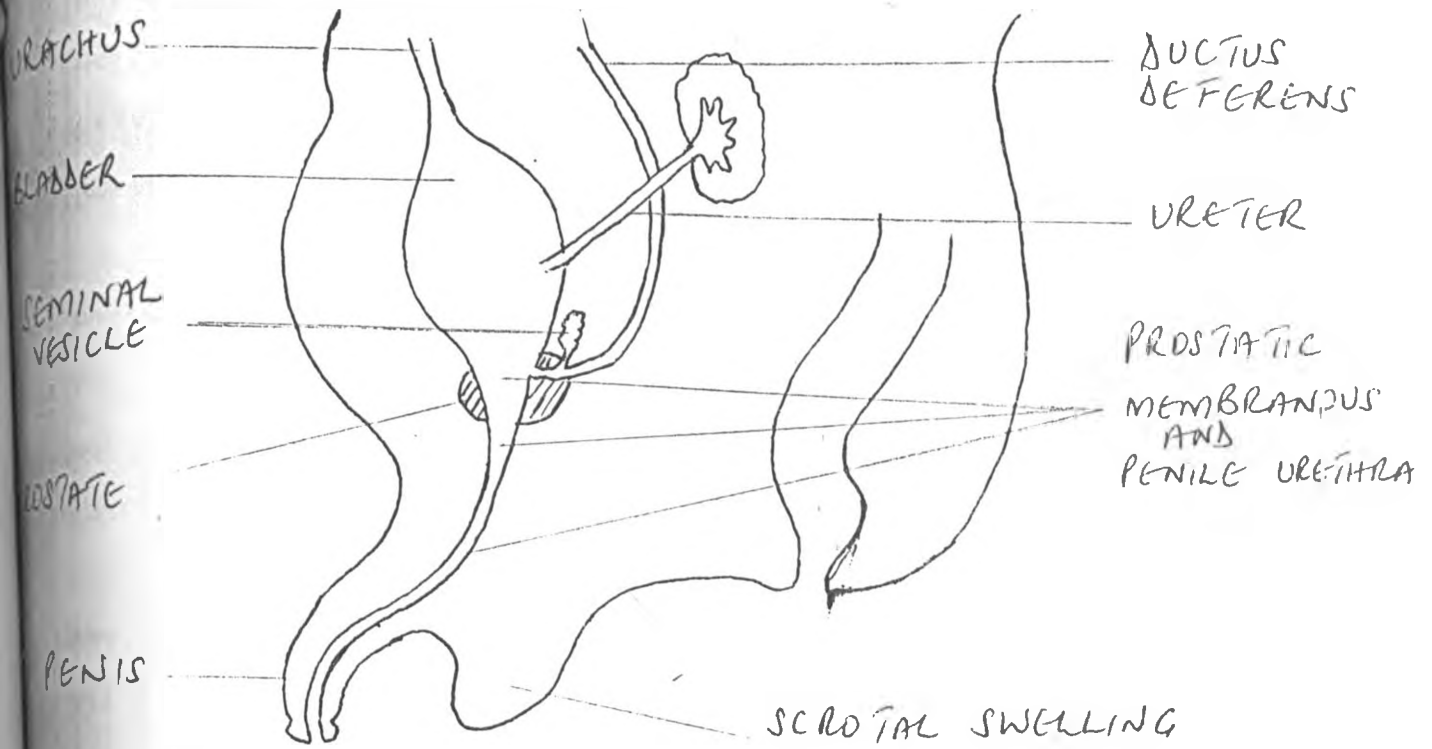
During infancy the bladder is abdominal in position and fusiform in

DIAGRAM 3

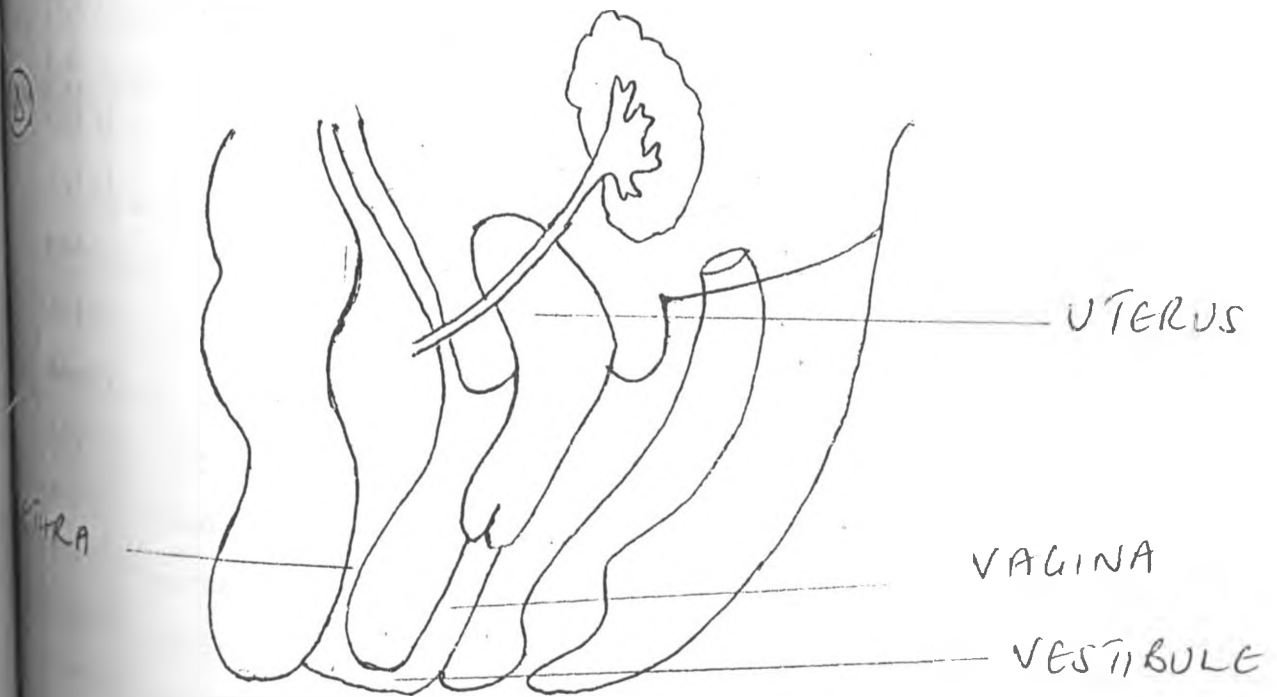


DEVELOPMENT OF THE URINARY BLADDER AND URETHRA SHOWING THE DIVISION OF THE CLOACA AND THE SEPARATION OF THE MESONEPHRIC

(C)



(A)



DEVELOPMENT OF THE UROGENITAL SINUS IN THE MALE (C) AND FEMALE (A)

shape and it is in contact with the anterior abdominal wall. During the sixth year, with the progressive enlargement of the pelvis the bladder becomes intrapelvic and reaches its definitive position shortly after puberty (42).

Posterior urethral valves

Valvular obstruction of the male posterior urethra is a relatively common anomaly and is one of the most important urologic diseases in children. In this series 45.6% of the patients presented for VCUG had posterior urethral valves and it was the commonest abnormality seen. Two main types are recognised; classic posterior urethral valves and posterior urethral membrane (See diagrams 6 and 7). In classic posterior urethral valves (type 1 of Young's classification) (38), two fibroepithelial valve - like folds originate from the lower pole of the verumontanum and extend downward and forward to insert in the wall of the urethra circumferentially below the verumontanum. The two folds fuse anteriorly, leaving a median, more posterior cleft as the only passage for the urine. The verumontanum and its superior and inferior crests and fins are hypertrophied. Posterior urethral membrane (type III of Young's classification) is much less common type of posterior urethral valve. It consists of a membrane attached circumferentially to the wall of the urethra below the verumontanum, usually near the urogenital diaphragm. This membrane varies in appearance from a sheet with a central hole to a greatly redundant "wind sock" with a side hole. The verumontanum and superior and inferior crests are not enlarged. Young also

described a type II posterior urethral valve in which two mucosal folds originating from the superior pole of the verumontanum ascend toward the bladder neck, but this is now believed to be either extremely rare or non-existent (1,26,29). In our series most of the patients had type 1 PUV, only 2 patients had posterior urethral membrane. (See diagram 7).

The posterior urethral valves balloon downward during micturition, obstructing the flow of urine. This causes dilatation of the proximal urethra and secondary changes of varying severity in the bladder and upper tracts (See diagram 5 and illustration 3).

In severe cases, the bladder is markedly hypertrophied and trabeculated. The size of the bladder varies from small to large. Vesicoureteral reflux is present in approximately 40% of patients and is frequently unilateral. This agrees with our series where 34% of patients with PUV had reflux and in other series (24, 25, 27, 28). The ureters are often dilated, elongated and tortuous, and the pelvocalyceal system is variously enlarged. The tortuosity of the ureters is often out of proportion to the urethral dilatation, suggesting an underlying dysgenetic process. The thickness of the renal parenchyma is reduced, sometimes severely. An associated renal dysplasia is common and the affected kidneys may be quite small. Renal function is decreased, often severely and asymmetrically. In patients with unilateral ureteral reflux the parenchymal changes are usually more severe on the side of the reflux than on the nonrefluxing side. Mild cases of

posterior urethral valves are uncommon and are usually discovered in older children.

When posterior urethral valves become manifest in the newborn period, an enlarged abdomen, abdominal mass or masses due to distended bladder, large kidneys, and oliguria or urinary dribbling are common findings. Enlargement of the abdomen may also be due to urine ascites or urinomas caused by extravasation of urine from the bladder or by a calyceal fornix. Sometimes the site of extravasation is not apparent.

Symptoms of posterior urethral valves in infancy and early childhood include urinary tract infection, sepsis, failure to thrive, urinary retention, abdominal pain, vomiting, dribbling of urine, hematuria, palpable kidneys, and signs and symptoms of chronic renal insufficiency. Milder forms of the disease, usually seen in older children, most often manifest with urinary tract infections, enuresis, and voiding dysfunction. An important sign at all ages is a poor urinary stream. In children, this may be difficult to assess due to the wearing of napkins and most infants and older children do not know the difference between a poor stream and a good urinary stream.

In utero, oligohydramnios is common, and secondary changes such as Potter facies, respiratory distress from hypoplastic lungs, pneumothorax, or pneumomediastinum may be the presenting manifestations in the newborn.

posterior urethral valves are uncommon and are usually discovered in older children.

When posterior urethral valves become manifest in the newborn period, an enlarged abdomen, abdominal mass or masses due to distended bladder, large kidneys, and oliguria or urinary dribbling are common findings. Enlargement of the abdomen may also be due to urine ascites or urinomas caused by extravasation of urine from the bladder or by a calyceal fornix. Sometimes the site of extravasation is not apparent.

Symptoms of posterior urethral valves in infancy and early childhood include urinary tract infection, sepsis, failure to thrive, urinary retention, abdominal pain, vomiting, dribbling of urine, hematuria, palpable kidneys, and signs and symptoms of chronic renal insufficiency. Milder forms of the disease, usually seen in older children, most often manifest with urinary tract infections, enuresis, and voiding dysfunction. An important sign at all ages is a poor urinary stream. In children, this may be difficult to assess due to the wearing of napkins and most infants and older children do not know the difference between a poor stream and a good urinary stream.

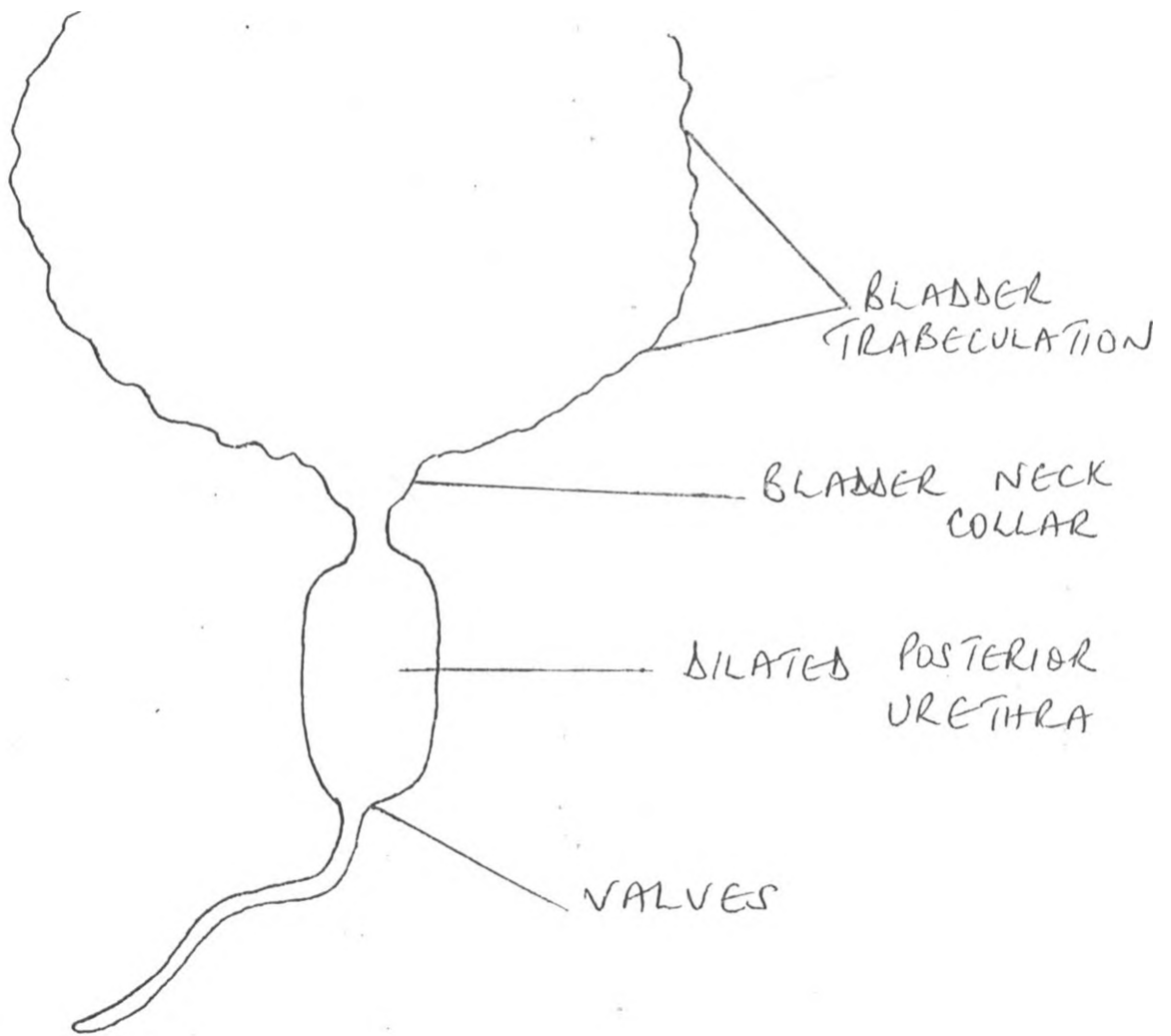
In utero, oligohydramnios is common, and secondary changes such as Potter facies, respiratory distress from hypoplastic lungs, pneumothorax, or pneumomediastinum may be the presenting manifestations in the newborn.

The procedure of choice to demonstrate posterior urethral valves is a voiding cystourethrography. On films exposed during voiding, the posterior urethra is greatly dilated, usually down to the level of the urogenital diaphragm. (See illustrations 3,4,5,6,).

The transition between the dilated posterior urethra and the normal collapsed anterior urethra is quite sharp. The valves themselves may be seen in over penetrated frontal views as two thin radiolucent lines, together with the findings of a prominent verumontanum and prominent urethral crests and fins. A very common finding on the VCUG is a prominent posterior indentation at the level of the bladder neck due to bladder wall hypertrophy and widening of the posterior urethra. Classic posterior urethral valves may not be visible on retrograde urethrography, since the valves are displaced laterally and flattened against the urethral wall by the retrograde flow of the contrast agent. Roentgenographic findings suggesting a type III valve include a sharply defined membrane across the distal half of the posterior urethra with less dilatation of the proximal posterior urethra, and ballooning and herniation of the "wind sock" membrane through the urogenital diaphragm into the bulbar urethra.

Perineal ultrasonography is now increasingly used for the screening of patients suspected to have posterior urethral valves. It however, has not yet replaced MCUG for the diagnosis of PUV as confirmed by a number of authors (29, 30, 31, 34). It is the method of choice when urinary infection contraindicates the

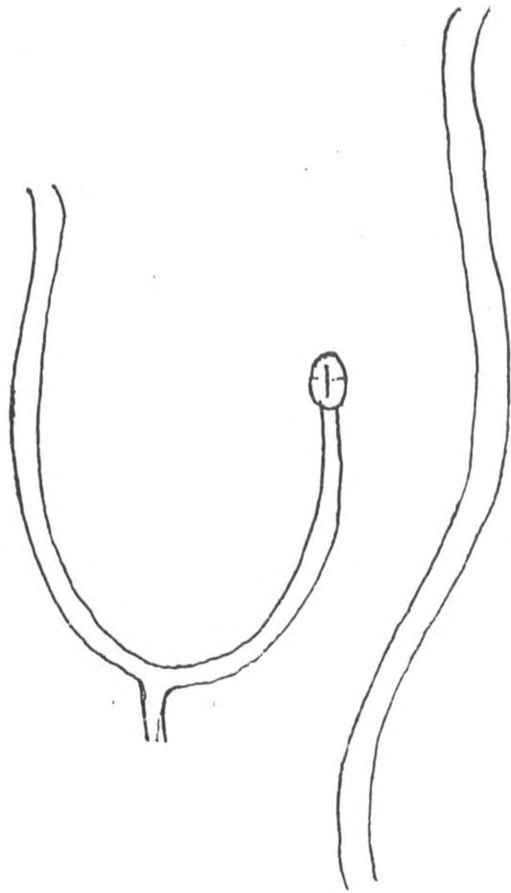
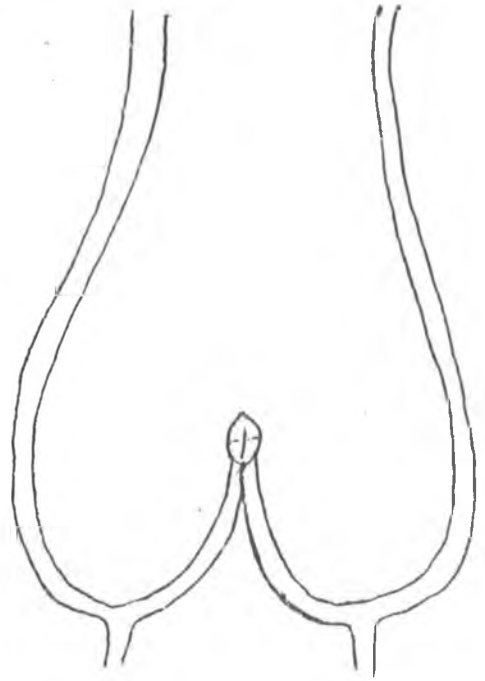
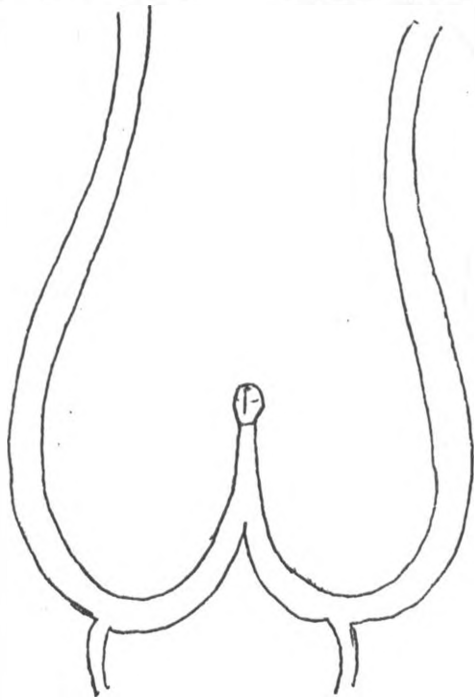
DIAGRAM 5



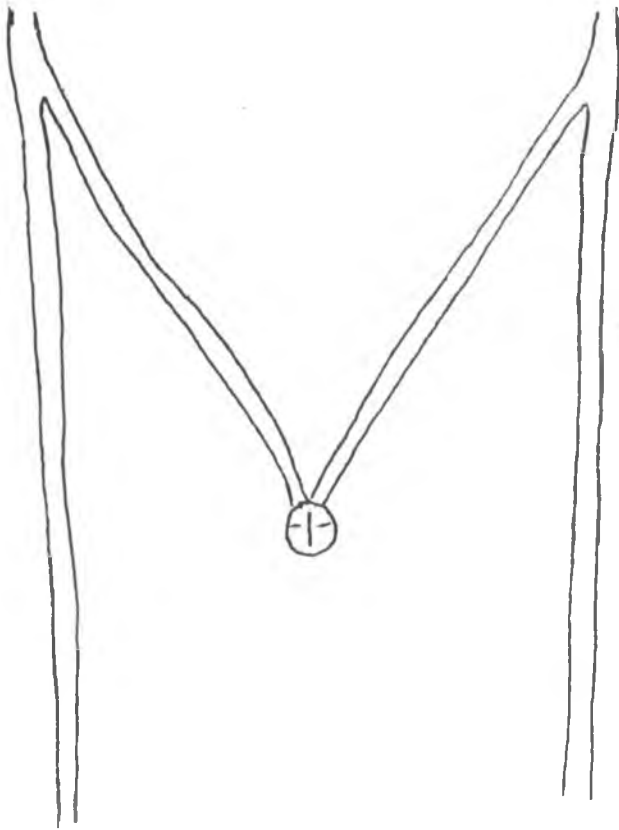CONGENITAL POSTERIOR URETHRAL VALVES
IN A MALE INFANT
DRAWING ILLUSTRATING FINDINGS ON
CYSTOURETHROGRAM.

DIAGRAM 6

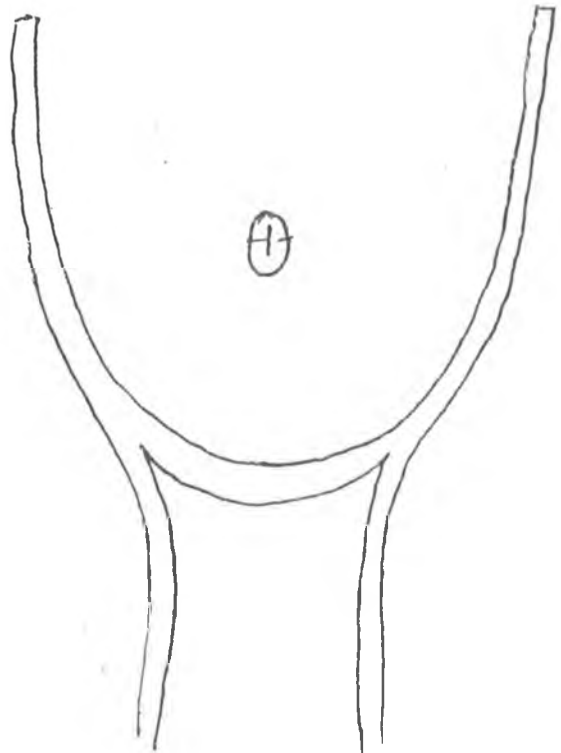
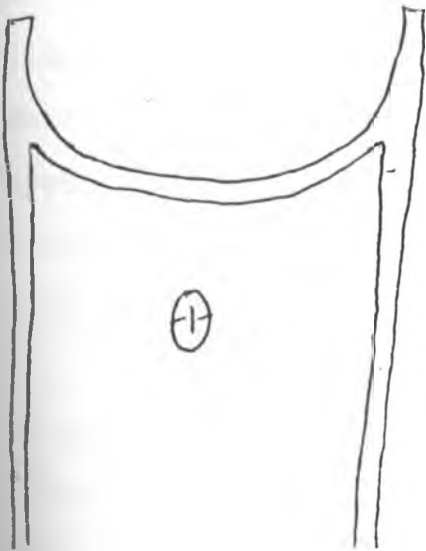
TYPES OF CONGENITAL VALVES OF POSTERIOR URETHRA.



TYPE 1



TYPE II



TYPE III

performance of VCUG. However, after treatment with antibiotics VCUG is done to confirm the diagnosis of posterior urethral valves.

Vesicoureteric reflux and urinary tract infections (See illustrations 7,8,10).

The term vesicoureteral reflux refers to the retrograde passage of contrast material into the ureter during VCUG. The phenomenon is believed to reflect a similar reflux of urine with the bladder at rest or during normal micturition and is regarded by most authorities as always abnormal, even if it occurs in asymptomatic individuals (1,2). Reflux of urine from the bladder into the upper tracts is thought to be potentially harmful because of its relationship to recurrent urinary tract infections and renal scarring (14,17,18,24,25).

The method of choice for demonstrating reflux is VCUG. The procedure may be recorded on "overhead films" or it may be carried out under fluoroscopic guidance with selective spot films or videotape. Simple static cystography is a less reliable method, as reflux may occur only during voiding. Radionuclide cystourethrography entails less radiation to the patient, but the details are poor. The procedure is therefore more suitable in follow-up examinations than in the first study.

In our series the initial VCUG showed reflux in 12 (17.9%) of 67 children with urinary tract infection. This compares favorably with other series (6, 18, 19, 25).

Renal damage was not assessed due to difficulties in follow-up. As the time required for a detectable renal scar to develop usually is several months, and may be upto 2 years for complete development, urography, or renal sonography is usually interpreted as normal in the initial radiologic workup after childhood urinary tract infection. Thus, normal VCUG, in combination with normal urography or sonography does not conclusively prove the patient is free from risk of renal damage. The final outcome in these cases can only be determined by delayed examination of the kidney.

Classification of grades of vesicoureteric reflux adopted by the International Reflux Study Committee are as follows (44) :

N = Normal

Grade I = reflux into ureter only

Grade II = reflux into ureter, pelvis, and calyces. There is no dilation and caliceal fornices are normal.

Grade III = mild or moderate dilation and / or tortuosity of the ureter and moderate dilation of the renal pelvis but little or no blunting of the fornices.

Grade IV = moderate dilation and / or tortuosity of the ureter and moderate dilation of the renal pelvis and calyces.

Grade V = gross dilation and tortuosity of the ureter and gross dilation of the renal pelvis and calyces. Papillary impressions are no longer visible in the majority of calyces. There is complete obliteration of the sharp angle of the fornices, but maintenance of papillary impressions in major calyces.

Most children who develop renal scarring after a UTI have VUR. Two recent articles (6, 32) document, respectively, a 75% and 80% sensitivity of reflux as a marker for renal scarring. In addition, higher grades of reflux are associated with an increase in parenchymal scarring (32). Children younger than 5 years of age are thought to be at greater risk for the development of renal scarring as are older children, so that it is particularly important to identify reflux in younger patients.

VCUG has been used as the standard means of identifying VUR for many years, however, there are variations in procedural technique from centre to centre that may influence the occurrence or demonstration of reflux. These variables include:

- a) catheterisation technique (retrograde vs suprapubic puncture vs intravenous administration of contrast material)
- b) type of catheter
- c) type of contrast material
- d) concentration, volume, and rate at which contrast material is

delivered to the bladder

- e) patient positioning
- f) imaging sequences and
- g) recording methods

Even when identical techniques are used, reflux may vary in severity on sequential examinations performed weeks or months apart, or even from moment to moment. Factors that determine minute-to-minute variability are speculative but may include variations in urine production and flow-rate, changes in intravesical pressure, and muscle tone at the ureterovesical junction. In studies done by Jequier and Jequier and by Paltiel and Rupich (23, 24) on cyclic voiding cystourethrography, it was found that cyclic VCUG increased detection of VUR, which led to a change in clinical treatment. Prone positioning did not enhance detection of VUR to the same degree as did multiple studies performed with the patient supine. Further evaluation of cyclic VCUG is warranted, particularly in the very young child and in other patients at high risk for renal damage secondary to VUR, such as those with myelodysplasia. Children with a history of recurrent UTI and negative results from a VCUG examination, as well as those with a well documented episode of pyelonephritis, might also benefit from a cyclic study. Cyclic radionuclide cystography may prove to be a good alternative to VCUG, as it provides continuous monitoring and substantially decreased gonadal radiation (33).

Urethral stricture (See illustration 11)

Urethral strictures are almost entirely limited to males. They are relatively uncommon but constitute an important and serious problem that is often difficult to treat. The stricture may be congenital or acquired, and the latter may be iatrogenic or secondary to external trauma or infection. Often the cause of the stricture is unknown. In our series 10% of the cases had urethral stricture those aged 10 years and below were due to post-operative complications as after urethroplasty. In the patients aged 10 to 15 years the stricture was usually a sequelae of urethritis.

In general iatrogenic strictures account for the largest number of cases. They may result from urethral instrumentation for diagnostic or therapeutic purposes. Urethral strictures following urethral instrumentations are located predominantly near the penoscrotal junction, an area particularly vulnerable to internal trauma. External trauma is the second most common cause of urethral stricture. Pelvic fractures, penetrating injuries, and falls astride a bicycle bar, a fence, or other object are the most common forms of external trauma. The membranous urethra is the area most often injured, owing to its fixation by the urogenital diaphragm. Strictures from saddle injuries usually are located in the bulbar urethra. Infections are uncommon causes of urethral strictures in children, as opposed to young adults, in whom urethritis due to *Neisseria gonorrhoeal* is an important cause. The strictures due to *Neisseria* predominate in the bulbar urethra and are usually multiple.

Urethral stricture (See illustration 11)

Urethral strictures are almost entirely limited to males. They are relatively uncommon but constitute an important and serious problem that is often difficult to treat. The stricture may be congenital or acquired, and the latter may be iatrogenic or secondary to external trauma or infection. Often the cause of the stricture is unknown. In our series 10% of the cases had urethral stricture those aged 10 years and below were due to post-operative complications as after urethroplasty. In the patients aged 10 to 15 years the stricture was usually a sequelae of urethritis.

In general iatrogenic strictures account for the largest number of cases. They may result from urethral instrumentation for diagnostic or therapeutic purposes. Urethral strictures following urethral instrumentations are located predominantly near the penoscrotal junction, an area particularly vulnerable to internal trauma. External trauma is the second most common cause of urethral stricture. Pelvic fractures, penetrating injuries, and falls astride a bicycle bar, a fence, or other object are the most common forms of external trauma. The membranous urethra is the area most often injured, owing to its fixation by the urogenital diaphragm. Strictures from saddle injuries usually are located in the bulbar urethra. Infections are uncommon causes of urethral strictures in children, as opposed to young adults, in whom urethritis due to *Neisseria gonorrhoeae* is an important cause. The strictures due to *Neisseria* predominate in the bulbar urethra and are usually multiple.

Urethral strictures of unknown cause in symptomatic boys are not rare. They are located most often in the bulbar urethra, and commonly are very short and diaphragm-like (26). They may be the result of unrecognised external trauma, unrecognised urethritis, infected cowper gland ducts, or rupture of one of the cowper duct cysts mentioned above. The possibility of a congenital nature in some cases is not excluded, particularly when there is a family history of the same lesion.

The clinical manifestations of urethral strictures include urinary retention, poor stream, urinary infection, dysuria, painful micturition, hematuria, and recurrent epididymitis. The diagnosis is readily established by voiding cystourethrography when the bladder can be catheterised. Retrograde urethrography is also an excellent method to study strictures of the anterior urethra.

The urethra proximal to the stricture may be dilated. Bladder trabeculation, vesicoureteral reflux, and upper tract dilatation may coexist. In the interpretation of the urethrogram, it is important to remember that normal areas of narrowing at the level of the urogenital diaphragm or narrowing caused by spasm of the bulbocavernosus muscle may simulate a stricture.

Bladder diverticula (See illustration 9)

True bladder diverticular are rare; more common are localised outpouchings of the bladder mucosa through a defect in the muscular coat (pseudo diverticula). As their radiographic features are

Urethral strictures of unknown cause in symptomatic boys are not rare. They are located most often in the bulbar urethra, and commonly are very short and diaphragm-like (26). They may be the result of unrecognised external trauma, unrecognised urethritis, infected cowper gland ducts, or rupture of one of the cowper duct cysts mentioned above. The possibility of a congenital nature in some cases is not excluded, particularly when there is a family history of the same lesion.

The clinical manifestations of urethral strictures include urinary retention, poor stream, urinary infection, dysuria, painful micturition, hematuria, and recurrent epididymitis. The diagnosis is readily established by voiding cystourethrography when the bladder can be catheterised. Retrograde urethrography is also an excellent method to study strictures of the anterior urethra.

The urethra proximal to the stricture may be dilated. Bladder trabeculation, vesicoureteral reflux, and upper tract dilatation may coexist. In the interpretation of the urethrogram, it is important to remember that normal areas of narrowing at the level of the urogenital diaphragm or narrowing caused by spasm of the bulbocavernosus muscle may simulate a stricture.

Bladder diverticula (See illustration 9)

True bladder diverticular are rare; more common are localised outpouchings of the bladder mucosa through a defect in the muscular coat (pseudo diverticula). As their radiographic features are

similar, the generic term diverticula is used for discussion. The neck of the diverticulum varies greatly from a few millimetres in diameter to very large. Bladder diverticula may be primary (idiopathic), secondary, or iatrogenic (post operative), in our series 2 patients had diverticula secondary to PUV. Primary diverticula are the most common. They may originate from a congenital defect or weakness in the bladder musculature (26). They may occur anywhere in the bladder, but very frequently are located just above and lateral to the insertion of the ureter. These periureteral diverticula are also called Hutch diverticular. In our series we saw only one patient with a Hutch diverticula which was unilateral. The ureter enters the bladder near the base of the diverticulum. A large periureteral diverticulum may engulf the ureteral meatus, and the ureter may thus empty into the diverticulum. Hutch diverticula are frequently bilateral. Associated vesicoureteral reflux is present in about half of cases. Multiple bladder diverticula of the primary type may be seen in several syndromes, reflecting a generalised connective tissue disorder. Secondary diverticula are seen mostly in patients with posterior urethral valves or other severe lower urinary tract obstruction and in patients with neurogenic bladder disease (1,2,26). They may occur anywhere but are most common in the periureteral areas. Iatrogenic diverticula are seen most often in the anterior wall of the bladder at the site of a previous vesicotomy or suprapubic drainage catheter, at the ureterovesical junction following ureteral reimplantation, and at the level of the bladder outlet following Y-V plasty of the bladder neck (1,26).

Bladder diverticula may become visible only during voiding when contractions of the bladder force urine into the diverticulum. It is important to note that during VCUg study, a ureterocele may become temporarily averted, simulating a bladder diverticulum. In our series there was one patient with a ureterocele with associated VUR. The ipsilateral kidney was non-functional. (See illustration 10).

Other congenital anomalies

The association of imperforate anus, severe urethral or penile abnormalities, and intrauterine death has recently been reported in radiologic literature (40). Oligohydramnios complicated almost all these pregnancies, but none of the foetuses or neonates had renal agenesis. Although children with imperforate anus generally undergo VCUg to detect rectourinary fistula, reflux, the VCUg may, in children with VATER association, show many other abnormalities. This appears to be true in those children with oesophageal atresia and imperforate anus as shown in a study done by Sandra Fernbach (41).

We had 4 patients with fistulous communication, 3 were males and 2 were associated with an anorectal malformation while one was a post operative complication. The one female child was one month old and had a urethrovaginal fistula whose cause had not yet been established.

Common urethral congenital anomalies such as hypospadias have been

reported in children with VATER association. It remains unclear whether the frequency of hypospadias is increased in this population. Complete urethral duplication is a rare anomaly.

The type of complete duplication seen in the neonate with oesophageal atresia has been variously called an H - type urethroanal fistula or duplication with perineal (hypospadiac) channel (41). The possibility that these multiple anomalies of septation (oesophageal atresia, imperforate anus, duplication of the urethra) may have a common cause, is intriguing but unproved.

RECOMMENDATIONS

1. All the request forms for patients requiring special radiological investigations are countersigned by a radiologist before the patients are given a booking. It is therefore recommended that, in children, referred for excretory urography alone when the diagnosis is primarily urinary tract infection or obstructive uropathy, VCUG should be done as the first radiological investigation, on consultation with the referring clinician. In patients referred for both excretory urography and VCUG, the latter should be done first because if it is done after an IVU, then it is usually difficult to tell whether there is reflux or not.
2. Studies on cyclic VCUG is needed particularly in patients who do not show VUR on the first VCUG but where there is still a high index of suspicion of reflux.
3. Follow up studies are needed to show the incidence of children who develop reflux nephropathy as a sequelae of obstructive uropathy in our set up.

ILLUSTRATION 1

NORMAL FEMALE URETHRA AS SEEN ON VCUG

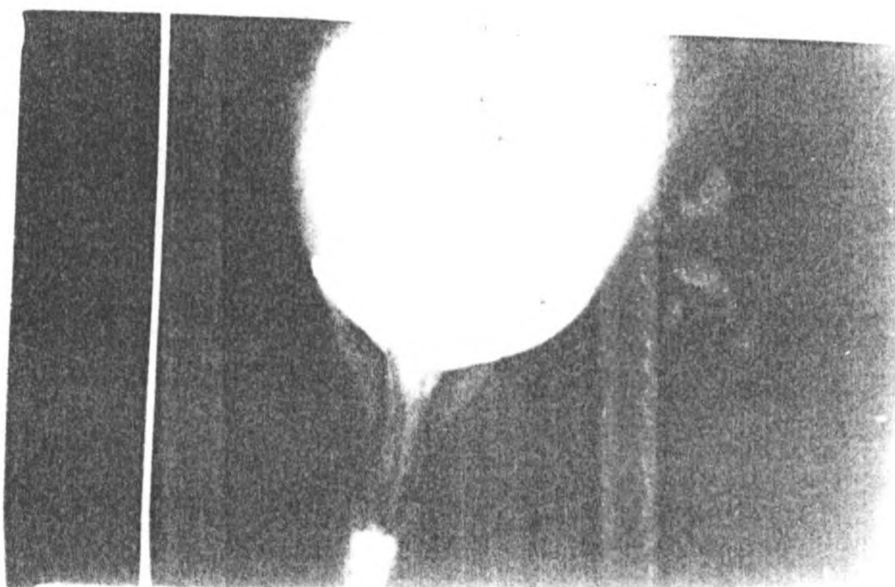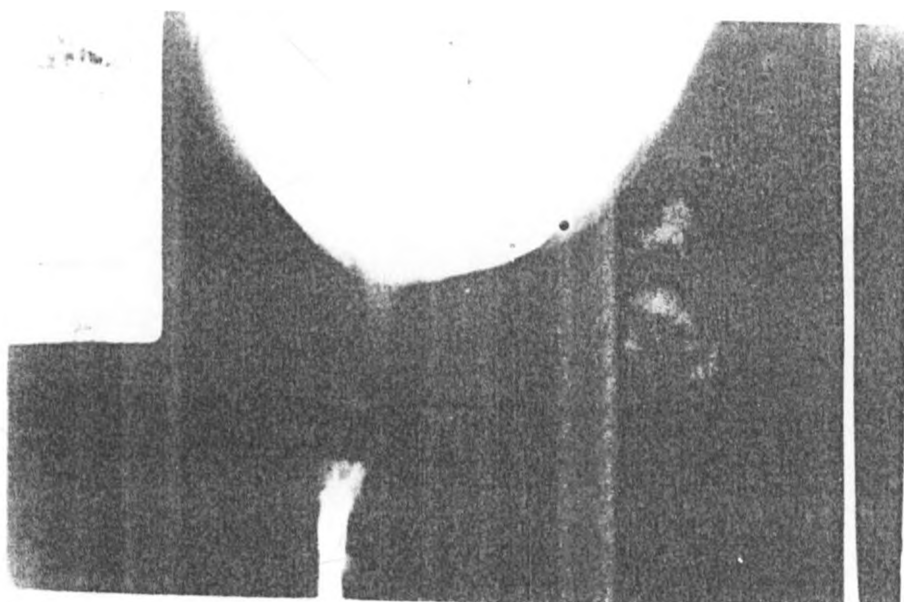


ILLUSTRATION 2

NORMAL MALE URETHRA

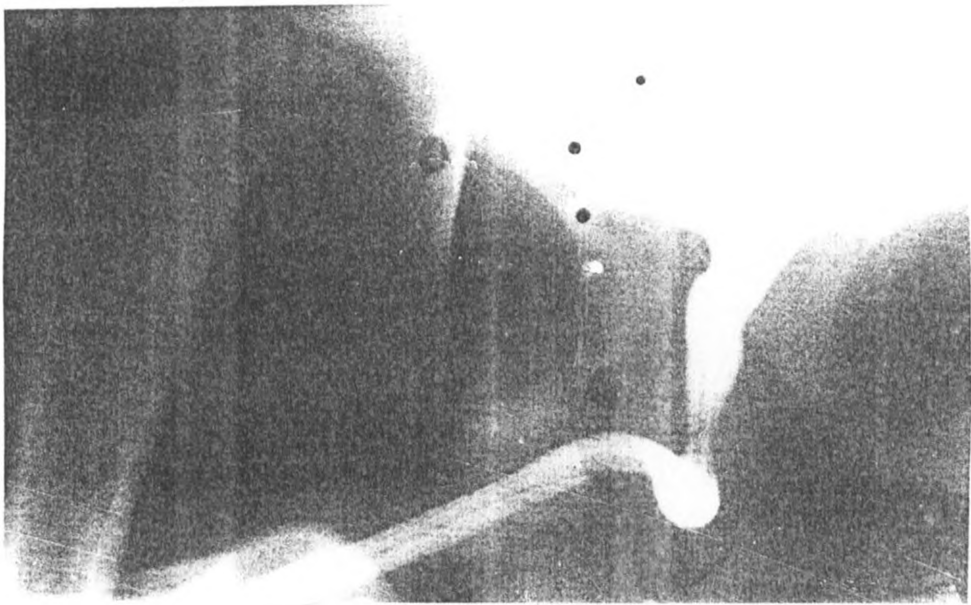


ILLUSTRATION 3

POSTERIOR URETHRAL VALVES

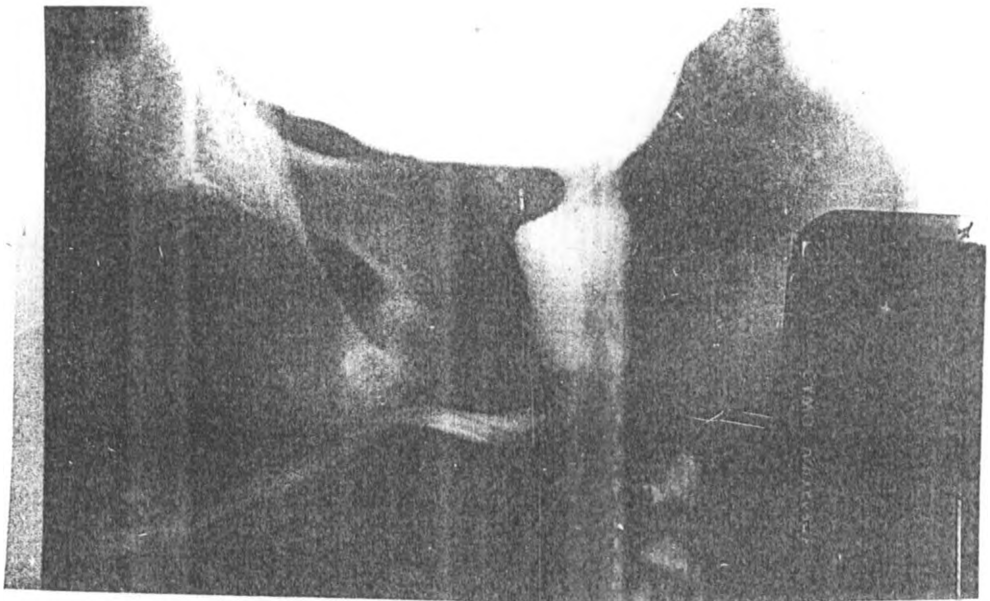


ILLUSTRATION 3

POSTERIOR URETHRAL VALVES

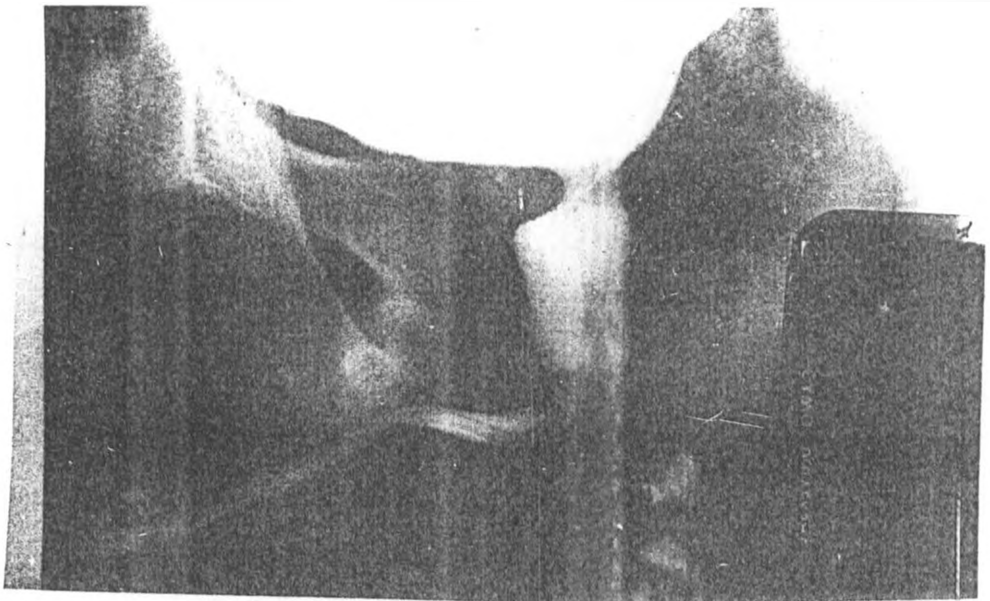


ILLUSTRATION 4

POSTERIOR URETHRAL VALVES WITH BLADDER TRABECULATION

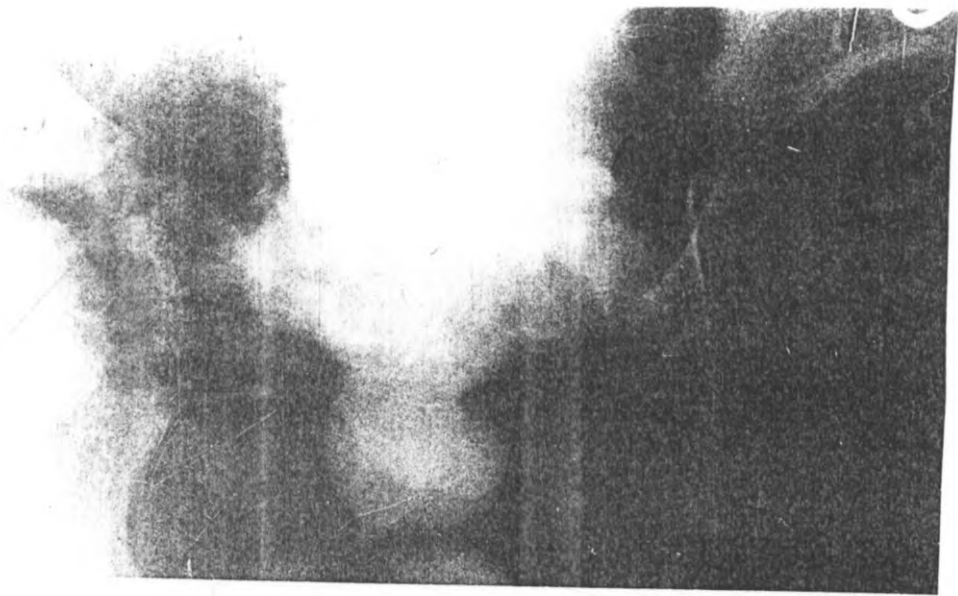


ILLUSTRATION 5

POSTERIOR URETHRAL VALVES WITH UTRICLE

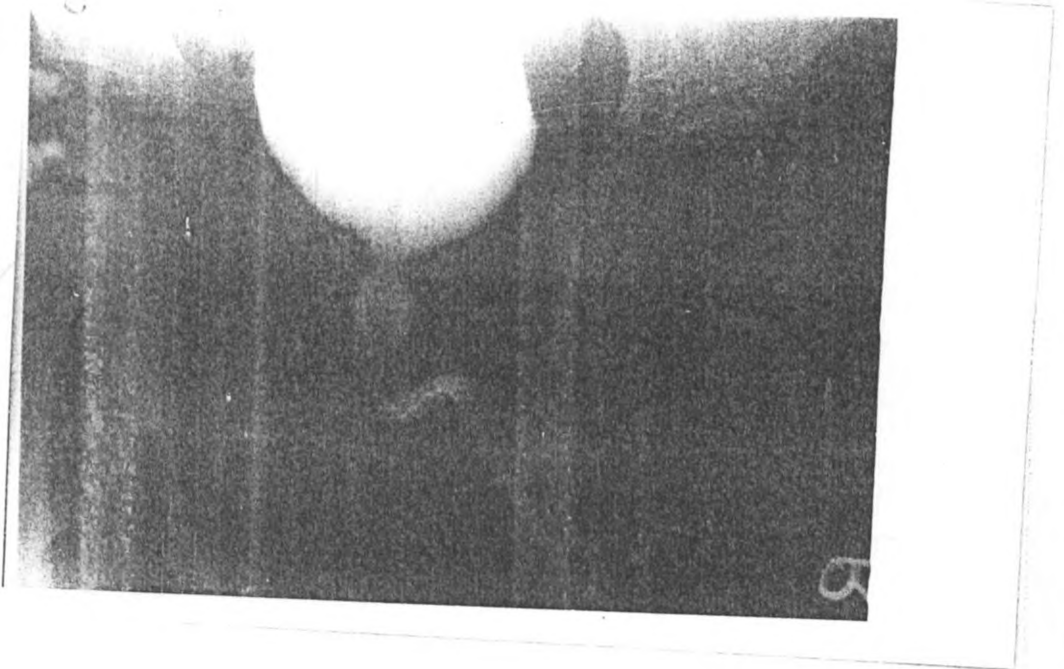


ILLUSTRATION 6

POSTERIOR URETHRAL VALVES WITH URETHRAL STRICTURE IN THE
PENILE URETHRA RESULTING IN POST-STENOTIC DILATATION

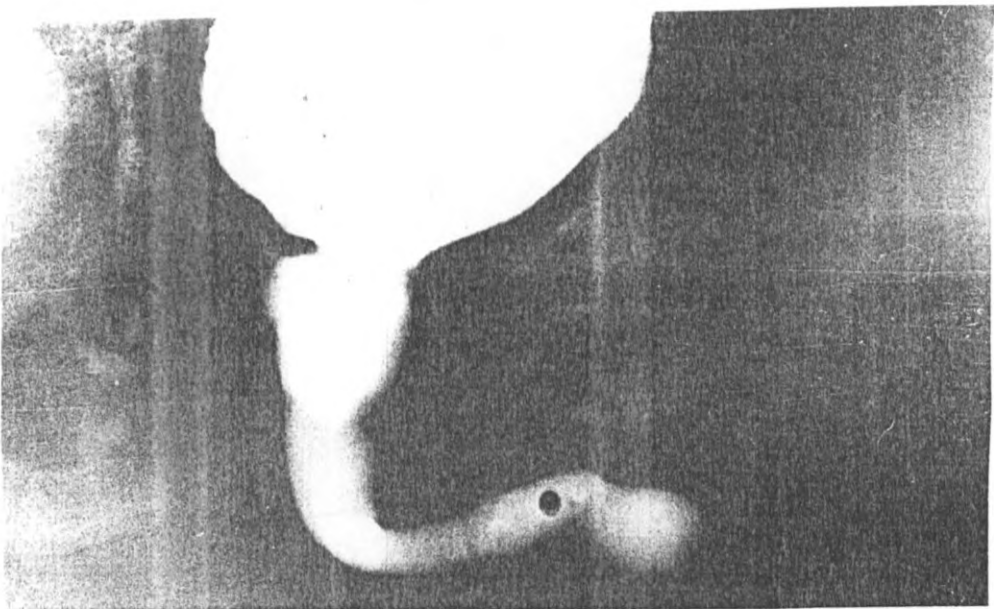


ILLUSTRATION 7

VESICoureTERIC REFLUX GRADE 1

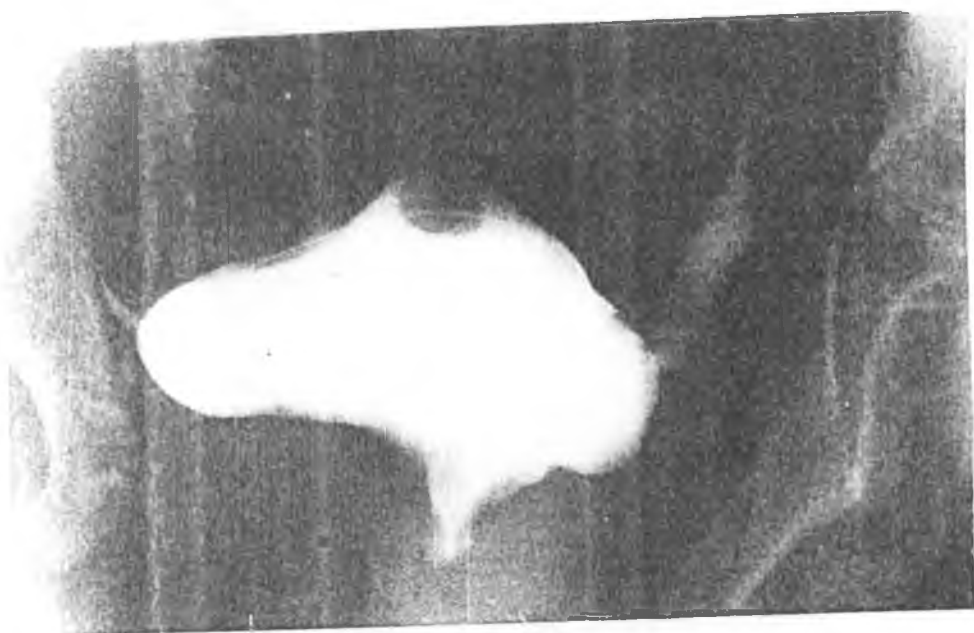


ILLUSTRATION 8

VESICoureTERIC REFLUX GRADE V SECONDARY TO POSTERIOR URETHRAL VALVES

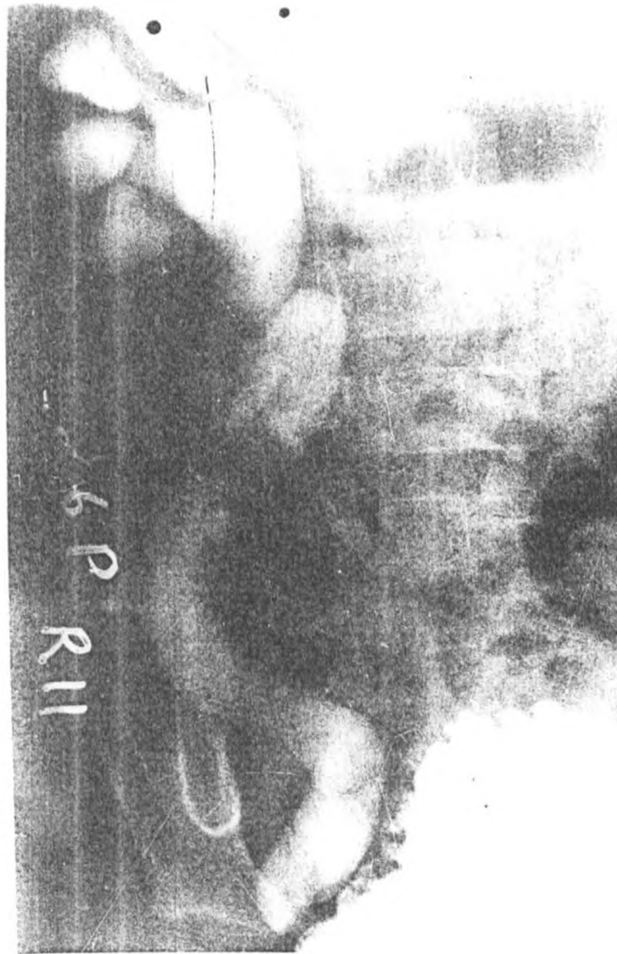

ILLUSTRATION 8

VESICoureteric REFLUX GRADE V SECONDARY TO POSTERIOR URETHRAL VALVES

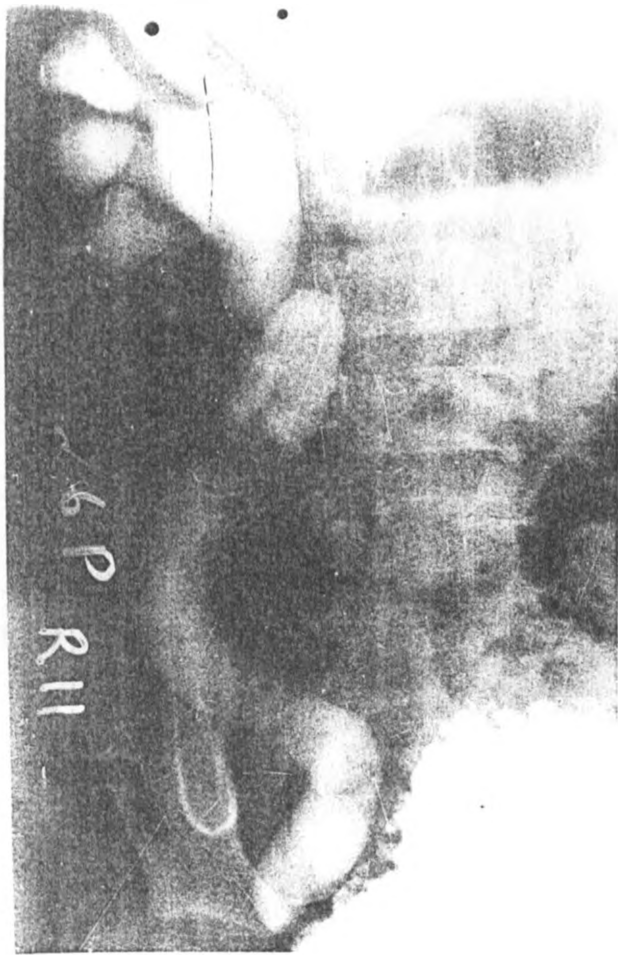


ILLUSTRATION 9

BLADDER DIVERTICULA WITH COARSE BLADDER TRABECULATION

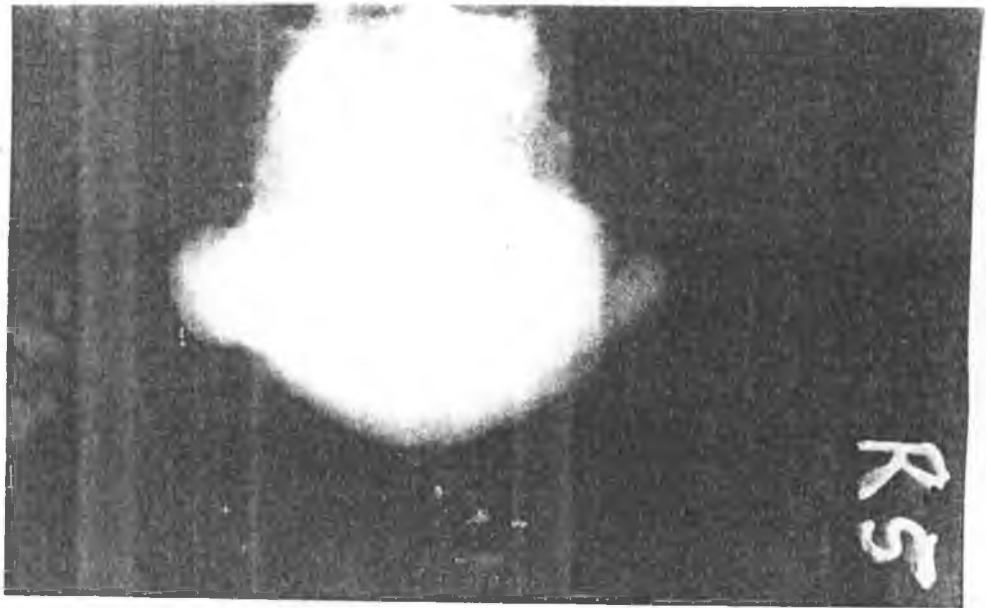


ILLUSTRATION 10

VESICoureTERIC REFLUX SECONDARY TO A URETEROCELE. THE RIGHT KIDNEY WAS NON- FUNCTIONING

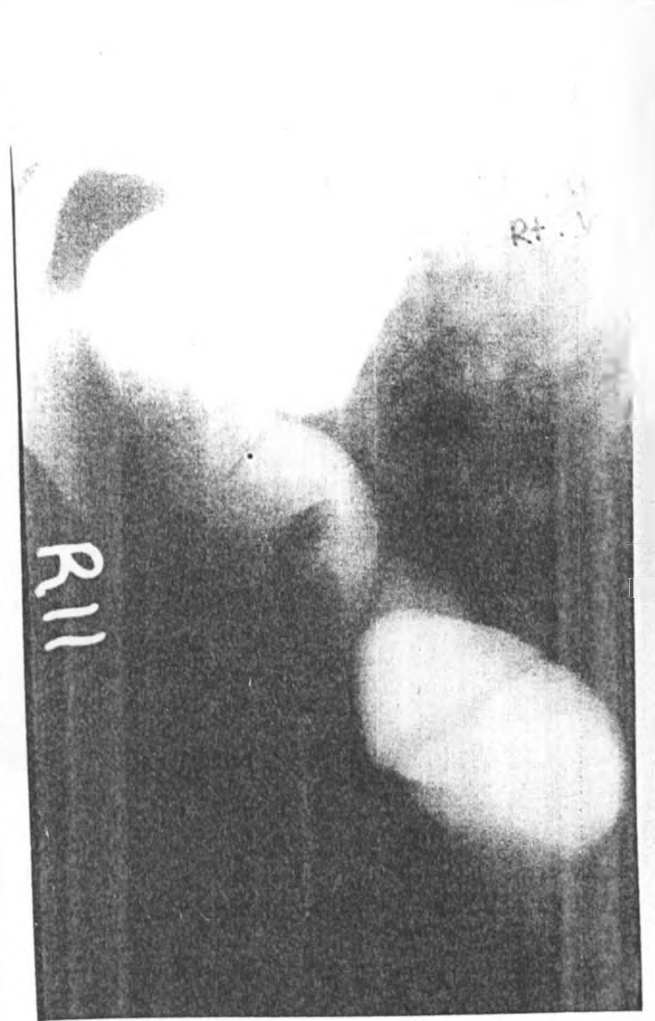
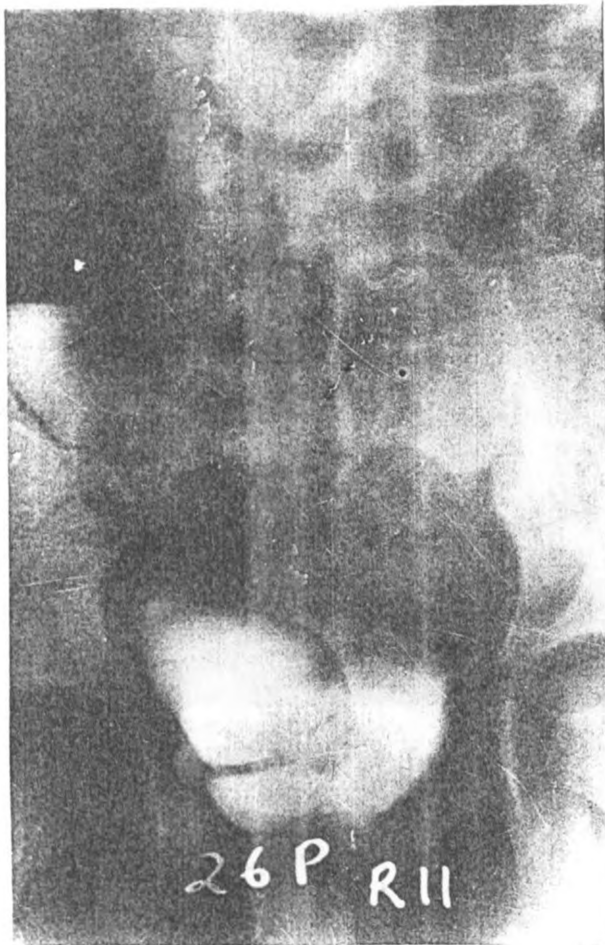
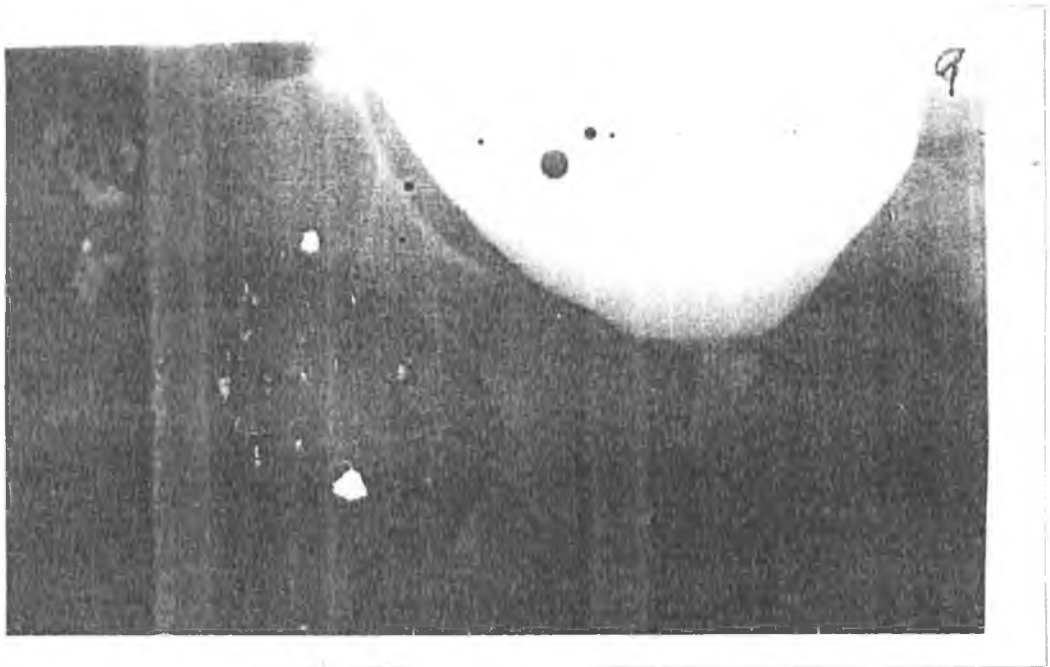


ILLUSTRATION 11

URETHRAL DIVERTICULA



REFERENCES

1. Emmett J.L., Witten D.M.
Clinical Urography, Philadelphia Saunders, 1972.
4th Edition Vol. I, II, III.
2. Davis L.A., Lich R., Howerton L. and Joule W.
The lower urinary tract in infants and children.
Radiology Vol. 77: 445-451, September, 1961.
3. Blickman J.G., Taylor G.A., Lebowitz R.L.
Voiding cystourethrography; the initial radiologic study in
children with urinary tract infection.
Radiology 1985, Vol. 156; pg. 659-662.
4. Harold S., Goldman, Leonard M., Freeman
Radiographic methods of evaluation of the kidneys and urinary
tract.
The paediatric clinics of North America. May 1971 pp 409-433.
5. Munene J.C.
A study of posterior urethral valves, 1980-1989.
M. Med thesis (Surgery) University of Nairobi.
6. Hellstrom et al.
Voiding cystourethrography as a predictor of reflux
nephropathy in children with urinary tract infection.
AJR. April, 1989 Vol. 152: pp. 802-804.
7. Friedland G.
Recurrent urinary tract infections in infants and children.
The radiologic clinics of North America. April 1977, Vol. XV.
No. 1 pp. 19-33.
8. Braverman R.M., Lebowitz R.L.
Perforation of the augmented urinary bladder in 9 children and
adolescents. AJR No. 1991, Vol. 157, No. 5, pp. 1059-1063.
9. Michael Zerlin et al.
Bladder capacity as measured at voiding cystourethrography in
children. Relationships to toilet training and frequency of
micturition.
Radiology, 1993, Vol. 157, No. 3 pp. 803-806.
10. Mohamed S.H.
Suprapubic micturition cystourethrography. Acta Radiologica
1988, Vol. 29; pp. 165-169.
11. Thompson J.W., Radge N.
Method of micturating cystourethrography in children.
J. of Urology; 1968, Vol. 99, pp. 116.

MEDICAL LIBRARY
UNIVERSITY OF NAIROBI

12. Stanley Hellerstein.
Urinary tract infections in children.
Year book Medical Publishers 1982.

13. ICRP 1977a. Recommendations of the International Commission on Radiological Protection. ICRP Publication 26. Annals of the ICRP, 1, (3).

14. Jodal U., Winberg J.
Management of children with unobstructed urinary tract infection.
Paedtr. Nephrol 1987; 1: 647-656.

15. Cavanagh P.M., Sherwood T.
Too many cystograms in the investigation of urinary tract infection in children?
Br. J. Urol. 1988, 55: 217-219.

16. Lebowitz R.L., Mandell J.
Urinary tract infection in children; putting radiology in its place.
Radiology 1987; 165: 1-9.

17. Smellie J.M., Edwards D., Hunter N., Normand I.C.S., Prescod N.
Vesicoureteric reflux and renal scarring.
Kidney Int. 1975; 8: 65-72.

18. Smellie J.M., Normand I.C.S.
Urinary infections in children.
Postgrad. Med. J. 1985, 61: 895-905.

19. Smellie J.M., Hodson C.J., Edwards D., Normand I.C.S.
Clinical and radiological features of urinary tract infection in children.
Br. Med. J., 1964; 2: 1222-1226.

20. Winberg J., Andersen H.J., Bergstrom T., Jacobson B., Larson H., Lincoln K.
Epidemiology of symptomatic urinary tract infection in childhood.
Acta Paedtr, Scand. (Suppl.), 1974; 252: 1-20.

21. Segura J.W., Kelalis P., Stickler G., Burke E.
Urinary tract infection in children; a retrospective study.
J. Urol 1971; 105: 591-593.

22. Wylly J.B., Lebowitz R.L.
Refluxing urethral ectopic ureters; recognition by the cyclic VCUG.
AJR 1984; 142: 1263-1267.

34. Cohen H.L., Susman M., Saller J.O., Glassburg K.I., Shapiro M.A.
Posterior urethral valve; Transperineal US for imaging and diagnosis in male infants.
Radiology 1994; 192: 261.
35. Saxton H.M.
Urodynamics; the appropriate modality for the investigation of frequency, urgency, incontinence and voiding difficulties.
Radiology 1990; 175: 307.
36. Ben-Ami T., Sinai L., Hertz M., Boichis H.
Vesicoureteral reflux in boys; review of 196 cases.
Radiology 1989; 173: 681.
37. Schoeneman M.J., Goldfarb C.R., Ongseng F., Finestone H.
Vesicoureteral reflux in boys.
Radiology 1990; 176: 288.
38. Young H.H., Frontz W.A., Baldwin J.C.
Congenital obstruction of the posterior urethra.
J. Urol. 1919; 3: 289-354.
39. Cass A.S. and Stephens F.D.
Posterior urethral valves; Diagnosis and management.
J. Urol. 1974; 112: 519-525.
40. Hayden S.A., Russ P.D., Pretorius D.H., Manco-Johnson M.L., Clewell W.H.
Posterior urethral obstruction; prenatal sonographic findings and clinical outcome in fourteen cases.
J. Ultrasound Med. 1988; 7: 371-375.
41. Fernbach S.K.
Urethral abnormalities in male neonates with VATER association.
Ajr. Vol. 156, 1991: 137 - 140.
42. Fasana F.
Text Book of Medical Embryology. Normal and Abnormal development, KLB.
43. Hamilton W.J.
Text Book of Human Anatomy, ELBS.
44. International Reflux study in children.
International system of radiographic grading of vesicoureteric reflux.
Paedtr. Radiol. 1985; 15: 105-109.

RADIOLOGICAL DIAGNOSIS OF URINARY TRACT DISEASES IN CHILDREN
KENYATTA NATIONAL HOSPITAL

A referral and teaching hospital)

DATA COLLECTION SHEET

NAME-----
Surname Middle First

DATA:-----CASE NO:-----

AGE:-----SEX:-----

INPATIENT/OUTPATIENT NO:-----

X-RAY DEPARTMENT REGISTRATION NO:-----

- CLINICAL HISTORY:
1. DRIBBLING OF URINE
 2. URINARY INCONTINENCE
 3. POOR STREAM
 4. DYSURIA
 5. LOIN PAIN
 6. RECURRENT UTI
 7. FAILURE TO THRIVE
 8. NAUSEA/VOMITING
 9. OTHERS

- CLINICAL DIAGNOSIS:
1. URINARY TRACT INFECTION
 2. OBSTRUCTIVE UROPATHY e.g. PU VALVES
 3. CONGENITAL ANOMALY
 4. OTHERS

RADIOLOGICAL DIAGNOSIS:-----

1. MCUG

2. ULTRASOUND

3. INTRAVENOUS UROGRAM

Doctor's name:-----

Date:-----Ref No.-----

MEDICAL LIBRARY
UNIVERSITY OF NAIROBI