

# **GLIOMAS: IMMUNOHISTOCHEMICAL GRADING AND CLINICORADIOLOGIC CORRELATIONS AT KENYATTA NATIONAL HOSPITAL**

**A DISSERTATION SUBMITTED IN PART-FULFILMENT FOR THE DEGREE  
OF MASTERS OF MEDICINE (PATHOLOGY) UNIVERSITY OF  
NAIROBI.**

**BY:**

University of NAIROBI Library



0444295 0

**DR MAKAU MBITHI MBChB,  
DEPARTMENT HUMAN PATHOLOGY,  
UNIVERSITY OF NAIROBI**

UNIVERSITY OF NAIROBI  
MEDICAL LIBRARY

i

USE IN THE LIBRARY ONLY


**DECLARATION**

This work is original and has not been submitted for a degree in any other University to the best of my knowledge.

Signed  Date 04/02/2008

This proposal for examination with my approval as a university supervisor.

DR EMILY ROGENA,  
SENIOR LECTURER,  
DEPARTMENT OF HUMAN PATHOLOGY,  
UNIVERSITY OF NAIROBI, P.O.BOX 19676, NAIROBI.

Signed  Date 04/02/08

DR MUSAU C.K,  
LECTURER / NEUROSURGEON,  
DEPARTMENT OF SURGERY,  
UNIVERSITY OF NAIROBI, P.O.BOX 19676, NAIROBI.

SIGNED  Date 04.02.2008

PROFESSOR DAVID GATEI,  
ASSOCIATE PROFESSOR OF PATHOLOGY,  
DEPARTMENT OF HUMAN PATHOLOGY,  
UNIVERSITY OF NAIROBI, P.O.BOX 19676, NAIROBI.

Signed.....Date.....

## DEDICATION

This work is dedicated to my lovely daughter, Natalie Ngina.

## **ACKNOWLEDGEMENTS.**

The Lord has been faithful to me throughout this project and I am very grateful to him.

I wish to extend my sincere gratitude to all who assisted me in many ways towards the completion of this project. My supervisors, Dr Rogena E, Dr Musau C.K and Prof. Gatei D, your input and guidance have been valuable. The technical staff in the department of histopathology University of Nairobi, headed by Ms Sitati S, thank you for your assistance in slides preparation.

The staff of KEMRI histology department, Dr Mutuma G.Z, Shiramba, your assistance in immunohistochemistry made this project a success.

My colleagues in MMED pathology programme, I am grateful for your peer review and encouragement.

Finally I am indebted to Prof Kigundu C, who has been a role model and a source of encouragement throughout my studies.

November 2007.

## TABLE OF CONTENTS

Declaration.....	i
Table of contents.....	ii
Dedication.....	iii
Acknowledgements.....	iv
List of abbreviations.....	v
List of figures, tables and abbreviations.....	vi
1.	
1.0.0 Summary/Abstract.....	1
1.1.0 Introduction.....	3
2.	
2.0.0 Literature Review.....	7
3.	
3.0.0 Rationale.....	14
3.0.1 Main objective.....	15
3.0.2 Specific objectives.....	15
3.0.3 Hypothesis.....	16
3.0.4 Methodology.....	16
Study design.....	16
Sample size.....	17
Inclusion criteria.....	17
Exclusion criteria.....	18
Processing of tissue.....	18
Data collection.....	18
Quality control.....	19
Data analysis.....	19
4. Study results.....	21
5. Discussion.....	37
5.0.1 conclusions.....	54
5.0.2 recommendations.....	55
5.0.3 limitations.....	55
6. References.....	56
7. Appendix I Questionnaire.....	61
Appendix II Immunohistochemistry.....	63
Appendix III Tissue Processing Procedure.....	66

## LIST OF ABBREVIATIONS

<b>KNH</b>	Kenyatta National Hospital
<b>WHO</b>	World Health Organization
<b>H/E</b>	Hematoxylin and Eosin
<b>IHC</b>	Immunohistochemistry
<b>GFAP</b>	Glial fibrillary acid protein
<b>CNS</b>	Central Nervous System
<b>EMA</b>	Epithelial Membrane Antigen
<b>MRI</b>	Magnetic Resonance Imaging
<b>CT SCAN</b>	Computerized Tomography scan
<b>TIA</b>	Transient ischemic attack
<b>ISO</b>	International Standardization Organization
<b>PCNA</b>	Proliferating Cell Nuclear Antigen
<b>MRA</b>	Magnetic Resonance Arteriography
<b>MRV</b>	Magnetic Resonance Venography
<b>PET</b>	Positron Emission Tomography
<b>PSA</b>	Prostatic Specific Antigen.
<b>SPSS</b>	Statistical Package for Social Sciences.
<b>PTAH</b>	PhosphoTangstic Acid Haematoxylin.
<b>SOP</b>	Standard Operating Procedures

## 1.0.0 **SUMMARY**

**Background:** Gliomas are the most common primary central nervous system tumors, accounting for 48% of primary brain neoplasms. These are tumours arising from glial cells in the brain namely astrocytes, oligodendrocytes and ependymal cells all grouped into 24 tumour variants in the World Health Organization 2000 classification<sup>1</sup>

**Broad objective:** To carry out immunohistochemical studies on all gliomas, and classify them according to the WHO grading system 2000 and correlate these with surgical and radiological diagnosis.

**Design:** A retrospective cross-sectional study.

### **Study subjects**

All 102 patients operated on and diagnosed as having gliomas at KNH over a period of five years from January 2002 to December 2006.

**Setting:** Kenyatta National Hospital histopathology laboratory and Kenya Medical Research Institute- Mbagathi Nairobi.

**Methods:** Patients' data and histological reports were analyzed in order to identify those who had been diagnosed to have gliomas. Patients diagnosed with gliomas during the study period were included. A proforma form was used to key in patients' clinical and radiologic information. Histology was done using paraffin embedded blocks, which were retrieved

from the library using the backup reports in the laboratory library. Routine H/E staining was done first, then immunohistochemical markers, glial fibrillary acid protein (GFAP), and Ki67 a cellular proliferative marker for grading.

**Results:** The most prevalent glioma analyzed was grade I (pilocytic) astrocytoma at 25%, followed by glioblastoma multiforme at 17.8%. Majority of the patients were male at 57%. High-grade lesions, grades III and IV gliomas were common among patients above 15 years and also amongst male patients.

Correlations between radiological, surgical and histological diagnosis was very poor at 16%.

All gliomas analyzed were reactive to GFAP and ki67 staining was useful in grading of the tumours and in differentiating low-grade astrocytomas from gliosis. The project was carried out over a period of one year.

**Conclusion:** The use of Immunohistochemistry is useful in the routine histological diagnosis and grading of gliomas at Kenyatta national hospital and the need for complete clinical and radiological detail of the patient is important for correct histological interpretation.

**We recommend** that a standard proforma or request form be developed and adhered to for reporting brain tumours and that GFAP and ki67 Immunohistochemical panels be introduced in the laboratory for diagnosis of gliomas.



## 1.0 INTRODUCTION

Percival Bailey laid down the foundations of modern day neuro-oncology in partnership with Harvey Cushing in 1926 when they published the book entitled '*A Classification of the Tumours of the Glioma group on a Histogenic Basis with a correlated study on prognosis*'. Bailey exhaustively examined and classified a total of 414 cases of gliomas in the Cushing's series classifying them into 13 categories and later into 10 categories<sup>3</sup> over the next 80 years, this classification was to remain unchanged until the year 2000 when World Health Organization reviewed it<sup>1</sup>.

Gliomas arise from glial cells namely astrocytes, oligodendrocytes and ependymal cells. Astrocytes provide nutrition, insulation and structural support for neurons. Oligodendrocytes also provide insulation to nerve axons to facilitate signal transduction while ependymal cells form the lining of the ventricular system.

The annual incidence of tumours of the central nervous system is about 17 per 100,000 persons for intracranial tumours and 2 per 100,000 for intraspinal tumours. Fifty percent of all CNS tumours are primary and 50% metastatic. Central nervous system tumours account for 20% of all childhood cancers, 70% of which arise from the posterior cranial fossa<sup>4</sup>.

There is very little research that has been carried out locally on brain tumours. However, gliomas account for 36-48% of all CNS tumours at KNH as reported by Kibaya G.N and Chumba C.K<sup>26</sup>.

**Table I Global prevalence of intracranial neoplasms<sup>5</sup>**

<b>Tumour type</b>	<b>All ages</b>	<b>&gt;15yrs</b>	<b>&lt;15yrs</b>
Glioblastoma&anaplastic astrocytoma	35%	35%	4%
Astrocytomas	13%	12%	44%
Other neuroepithelial tumours	8%	8%	15%
Meningiomas	17%	25%	3%
Primitive neuroectodermal tumours	3%	2%	24%
Nerve sheath	8%	---	----
Other tumours	16%	18%	10%

The distinction between benign and malignant tumours of the CNS is less defined compared to tumours in other organs. Some glial tumours with histologic features of a benign neoplasm may infiltrate large areas of the brain with serious clinical deficits and unfavourable prognosis<sup>4</sup>.

### **THE WHO CLASSIFICATION OF GLIOMAS.<sup>1</sup>**

#### **(a) ASTROCYTIC TUMOURS.**

i) Diffuse astrocytoma

Variants

1) fibrillary

2) Protoplasmic.

3) Gemistocytic.

ii) Anaplastic astrocytoma.

iii) Glioblastoma.

Variants-

1) Giant cell glioblastoma

2) Gliosarcoma.

iv) Pilocytic astrocytoma.

v) Pleomorphic xanthoastrocytoma.

vi) Subependymal giant cell astrocytoma.

(b) **OLIGODENDROGLIAL TUMOURS.**

- i) Oligodendroglioma
- ii) Anaplastic oligodendroglioma.

(c) **EPENDYMAL TUMOURS.**

- i) Ependymoma
  - Variants: a) cellular.
  - b) Papillary.
  - c) Clear cell.
  - d) Tanacytic.
- ii) Anaplastic ependymoma.
- iii) Myxopapillary ependymoma.
- iv) Subependymoma.

**MIXED GLIOMAS.**

- i) Oligoastrocytoma
- ii) Anaplastic oligoastrocytoma.

**GLIAL TUMOURS OF UNCRETAIN ORIGIN.**

- ◆ Astroblastoma.
- ◆ Gliomatosis cerebri.
- ◆ Chordoid glioma of third ventricle.

**Table II Grading of astrocytic tumours <sup>5</sup>.**

<b>Tumour type</b>	<b>WHO</b>	<b>Kernohan</b>	<b>Ringertz</b>	<b>St Anne/Mayo<sup>6</sup></b>
Pilocytic astrocytoma	I	0	Astrocytoma	1
Diffuse Astrocytomas	II	1	Astrocytoma	2
Anaplastic astrocytoma	III	2	Intermediate astrocytoma	3
Glioblastoma	IV	3&4	Glioblastoma	4

Grade 1 tumours are clinically benign and can be treated surgically. Grade ii, iii and IV tumours are increasingly malignant and require additional therapy (chemo and/ or radiotherapy).

Classification and grading of gliomas are essentially based on subtle microscopic characteristics and this is limited in predicting the outcome of each type of glioma. Glioblastomas account for 50% of all intracranial glial tumours <sup>6</sup>.

**St. Anne/ Mayo grading of diffuse Astrocytomas <sup>6</sup>.**

- a) Nuclear atypia
- b) Mitosis
- c) Capillary endothelial proliferation.
- d) Necrosis.

Each grade scores one point, grade= score +1 maximum 4.

## 2.0.0 LITERATURE REVIEW

### The pathology of gliomas.

Astrocytomas are among the most fibrillar of central nervous system neoplasms. They present a number of difficult problems of recognition. Among the most treacherous is distinguishing low-grade astrocytoma from gliosis.

Astrocytomas as a group tend to be more fibrillar than other gliomas except tanacytic ependymomas and subependymomas. Astrocytomas contain glial fibrillary protein, although the amount is variable. Glial fibrillary protein is the single most important immunohistochemical marker distinguishing astrocytomas from nearly all nonglial neoplasms<sup>7</sup>.

Astrocytomas are a heterogeneous group of neoplasms with numerous subtypes. Because some designations of the subtypes emphasize grading (low-grade, anaplastic, and glioblastoma) while others emphasize structural differences (pilocytic, gemistocytic, and cystic), hence overlap in nomenclature is unavoidable. The most significant structural differences are ones that indicate a different prognosis. These include the pilocytic astrocytoma, which can frequently be cured by surgical removal in a clinically resectable region like cerebellum, and the gemistocytic astrocytoma, which has a poorer prognosis than suggested by standard histologic criteria. Because of their importance to prognosis, these are described individually<sup>8</sup>.

At present, there are conflicts between systems of grading the malignancy of astrocytomas. This review emphasizes features of grading consistent with authoritative texts, the international classification of tumours the World Health Organization, and definitive correlations with prognosis. To avoid confusion, the grade number should state the grading system used. The highest grade identified in the specimen is the one to report, even if this grade does not predominate<sup>1</sup>.

The pilocytic astrocytoma is about the only good news in the astrocytoma series as it has a better prognosis than its diffuse counterparts, especially when it occurs in the cerebellum<sup>7</sup>. To classify the clinical pathologic and therapeutic characteristics that determine prognosis and therapeutic recommendations, a large group of patients with astrocytic cerebellar tumours was reviewed and analyzed by Hayostek C.J et al<sup>9</sup>. They conducted a clinicopathologic analysis of 105 patients with pilocytic astrocytomas and 27 with diffuse variants. Multivariate analysis revealed that the division of pilocytic and diffuse histologic type was the most significant prognostic factor influencing survival. Pilocytic astrocytomas occurred in a young age, were commonly cystic and were completely resectable. This study conducted from 1960 to 1984 concluded that astrocytomas of the cerebellum could be divided into two principal groups, the pilocytic and the diffuse astrocytomas, each of which has distinct, clinical, pathologic and prognostic characteristics. Same findings were reported by Schneider J.H et al<sup>10</sup> and Clarke GB<sup>11</sup>. In

order to distinguish pilocytic astrocytomas from gliosis immunohistochemical staining using glial fibrillary acid protein is done whose positivity confirms an astrocytoma. Unlike cerebellar pilocytic astrocytomas, supratentorial pilocytic astrocytomas are uncommon tumours, the prognosis and management of which have been controversial. Forsyth PA et al retrospectively studied the clinical and pathologic aspects of 51 patients with these tumours. They concluded that supratentorial pilocytic astrocytoma behaves differently from low-grade astrocytomas of the diffuse or fibrillary type in that they have a favourable prognosis. Radiation therapy appears not to be needed for patients undergoing gross total removal. Patients who have biopsy only should receive radiation therapy<sup>12</sup>.

The role of immunohistochemistry and flow cytometric analysis on low-grade astrocytomas is contested as Forsyth et al found that it adds little to clinical decision-making. Cell proliferation markers like ki67 and protoisomerase II would however distinguish gliosis from low-grade tumours<sup>12</sup>.

The radiological findings of low-grade gliomas do not always tally with the histopathological reviews as demonstrated by Coakley KJ et al. Magnetic resonance imaging examinations and histopathological findings in 56 patients with pilocytic astrocytomas were retrospectively reviewed. The tumours occurred at all levels of the central nervous system including the spinal cord. The intracranial tumours were periventricular (73%) or periaqueductal (9%). All tumours were typical pilocytic astrocytomas grade I on the basis of World Health Organization. Despite a well demarcated appearance grossly and on Magnetic resonance imaging, pathologic review

showed that many of these tumours (64%) infiltrated the surrounding parenchyma particularly the white matter. It suffices to mention that great gains in neuroscience have followed the advancement in radiological studies<sup>13</sup>. A review by Vertosick FJ Jr et al suggested that the higher survival of patients with well-differentiated cerebral astrocytomas in adults is the result of early diagnosis afforded by modern brain imaging<sup>14</sup>.

However despite this sophistication in radiography the clinical diagnosis of gliomatosis cerebri remains difficult. Artigas J et al did a clinical and histological review where histology disclosed a diffuse proliferation of glial elements infiltrating normal brain tissue with destruction of myelin sheaths but only slight damage to neurons and axons. Glial fibrillary acid protein showed that most of the neoplastic cells were astrocytic in origin. They also found oligodendroglial and irregular shaped nuclei of unidentified nature. On the basis of the two-stage theory of carcinogenesis (initiation and promotion) it is suggested that this disease might be the result of propagation of initiated glial elements, which have not yet undergone the process of tumour conversion<sup>15</sup>. Kandler RH et al described also four cases of gliomatosis cerebri whereby only one of them a diagnosis was made during life. Radiological investigations including computed tomography and magnetic resonance imaging showed no specific changes in the white matter.

The accurate diagnosis of gemistocytic astrocytomas cannot be over emphasized in that although they are considered as slow growing astrocytomas they often behave aggressively<sup>16</sup>. Krouwer HG et al studied



59 patients with these tumours respectively and found that the presence of at least 20% gemistocytes in a glial neoplasm is a poor prognostic sign irrespective of the pathological background. It is proposed that gemistocytic astrocytoma be classified with anaplastic astrocytoma and treated accordingly<sup>17</sup>.

Other challenging tumours to be diagnosed on light microscopy are the pleomorphic xanthoastrocytomas, which resemble meningeal fibrous histiocytomas and glioblastoma. These tumours require detailed immunohistochemical analysis. Lesions with low mitotic activity and undoubted evidence of glial tissue should be accepted as pleomorphic xanthoastrocytoma as described by grant JW Gallagher PJ. Extensive necrosis in a tumour with glial fibrillary acid protein lipid rich cells indicates a lipidised glioblastoma while positive immunocytochemistry should suggest a fibrous histiocytoma<sup>18</sup>.

Although intracranial neoplasm during the first year of life are not frequently diagnosed, Zuccaro G et al described 40 of them out of a total of 470 brain tumours. The patients presented with non-specific signs and symptoms of the tumours and of these 75% were located at the supratentorial compartment. The most common types were optic chiasm pilocytic astrocytomas, superficial brain astrocytoma and choroid plexus papilloma<sup>19</sup>.

Many ependymomas have a relatively discrete margin with brain, compared with other gliomas. Their cellular conformations vary between fibrillar and epithelial, posing special problems of differentiating from Carcinomas, Meningiomas and other gliomas. These diagnostic problems are resolved with the use of anti-glial fibrillary acid or electron microscopy

features of cilia, basal bodies, cytoplasmic inclusion of microvilli and elongated intercellular junctions, with absence of basement membrane in the parenchyma of ependymomas<sup>7</sup>. Schiffer D et al studied the histologic prognostic factors of ependymoma and found that the number of mitoses is a very important factor in supratentorial cases whereas endothelial proliferation and necrosis are much less important as prognostic factors. Despite the recent advances in immunohistochemistry it is stressed that the diagnosis of mixed glioma or 'oligo ependymoma' should be made with caution<sup>20</sup>.

Kawano N et al described the classical clear cell (oligodendroglioma like) in ependymoma, which was not reactive to Phosphotungstic acid haematoxylin and glial fibrillary acid protein but was confirmed at electron microscopy<sup>21</sup>.

The prognosis of malignant ependymomas is also highly variable as reported by Ross G W and Rubinstein L J. They found no correlation was possible between the tumours histological features, site or likelihood of recurrence. This lack of clinico-histopathological concordance contrasts with the known correlations that exist in astrocytomas<sup>22</sup>.

Oligodendrogliomas represent only 4-7 % of intracranial gliomas but their accurate diagnosis is important. They occur almost exclusively in the Cerebral hemispheres and are most common in adults in middle life. Special diagnostic techniques include touch imprint preparations, electron microscopy and 'immunohistochemistry'. Unfortunately, a review by Burger Pc et al and later Alvord E C Jr shows that there is no specific stain for oligodendrogliomas. Necrosis and the mitotic count are the features that are used to identify the anaplastic oligodendroglioma<sup>22, 23</sup>.

Paulus W and Peiffer J studied the intratumoral histologic heterogeneity of supratentorial gliomas according to the World Health Organization and six histologic features associated with malignancy were evaluated (cellular density, nuclear pleomorphism, necrosis, histologic architecture, vessels and mitoses). Of all gliomas, 48% showed differently typed samples, 82% differently graded samples and 62% benign and malignant grades. These results underscore the importance of extensive tissue sampling<sup>24</sup>.

Kibaya GN did radio-histological correlations of all CNS lesions at Kenyatta National Hospital diagnosed between 1995-1998. He found that gliomas accounted for 36%, meningiomas 14%. Radiological (Computerized Tomography scan) and histological consistency was below 40%<sup>25</sup>. Chumba DK analyzed Central Nervous System tumours also at Kenyatta National Hospital from 2001-2005. He found that gliomas accounted for 48% a figure that was basically the same for meningiomas<sup>26</sup>.

Use of Immunohistochemistry, with the routine histological and radiological findings is of value in making the diagnosis but not done routinely in our set up.

Electron microscopy is also not done routinely aggravating the problem further. As a result of the foregoing, difficult cases of gliomas have been observed and is estimated that they may be about 5-15% of all reported cases.

These difficult cases are commonly associated with the (i) site of the tumor, (ii) Histological subtype, and (iii) histological grade as indicated above in the differentials of the various subtypes.

The future of classification of Central nervous system neoplasm especially pediatrics' ones lies in morphology-based approaches that are based on a "cell of origin" and flexible systems that incorporate the results of immunohistochemical and molecular biology investigations. Burger Pc and Fuller GN acknowledge that the development of improved classifications will depend on reasoned application of newer methodologies to complement the many worthy aspects of present classifications. Careful coordination among clinicians, radiologist and pathologists is necessary to establish the relevance of these findings. Among these are the validity of the primitive neuro-ectodermal tumours, approach to embryonal tumours; the criteria for classification and grading of ependymomas and oligodendrogliomas; and the utility of subdividing cerebellar astrocytomas<sup>27</sup>.

The histopathological diagnosis is the bedrock of modern oncology, and plays a major role in the treatment of many other types of diseases. Errors in these reports can critically affect patient care and may become the subject of great concern. This study will consider how audits in histopathology can provide information about errors and inconsistencies in the diagnosis of surgical specimens. It is emphasized that an accurate histopathological interpretation of gliomas is essential for predicting the recurrence, biological behavior as well as post-operative management modalities.

## **RATIONALE**

Although gliomas have been extensively studied over the last 80 years, malignant variants remain to have one of the highest mortality with median survival of 9-12 months post-diagnosis. Modern clinical practice of neuro-oncology is dependent on accurate tumour classification and no variable predicts prognosis more precisely. Classification therefore, is the basis on which clinicians make critical therapeutic decisions and individualized patient care. We have not been able to describe the patterns of gliomas at our hospital and with this in mind; we wish to do histological classification including appropriate Immunohistochemistry.

This will be vital data for planning better patient management and create a baseline understanding of the patterns of gliomas at our set up.

### **3.0.1 BROAD OBJECTIVES**

- a) To carry out Immunohistochemical studies on all gliomas and classify them according to the World Health Organization grading system 2000.

### **3.0.2 SPECIFIC OBJECTIVES.**

- 1) To determine the prevalence of gliomas in the central nervous system tumours seen at Kenyatta national hospital during the study period.

- 2) To determine the immunohistochemical staining pattern by glial fibrillary acid protein of all gliomas and ki67 on WHO grade I gliomas.
- 3) To correlate the findings of immunohistochemistry with histological diagnosis and clinico-radiologic diagnosis.

### **3.0.3 HYPOTHESIS**

Use of immunohistochemical stains is of value in the routine histologic diagnosis of gliomas at Kenyatta National Hospital.

### **3.0.4 METHODOLOGY**

#### ***Study design***

Retrospective cross-sectional descriptive study.

#### **Study subjects**

All 102 patients operated on and diagnosed as having gliomas at KNH over a period of five years from January 2002 to December 2006.

#### **Identification of Study cases and coding.**

- i) Patients' copies of histology reports, filed in the department of pathology, from January 2002 to December 2006 were retrieved and a search for those reported, as gliomas was done. Patients' data given and the details of the histologic report were recorded in a proforma form.

Appendix 1. Patients' details missing from the laboratory request form were retrieved from the patients' files.

- ii) Specimen delivered to the histopathology department during the study period were identified at the reporting room and recruited into the study.

### ***Sample size***

A total of 102 gliomas were analyzed over the study period. This had been calculated from the formula below where a minimum sample size of 62 samples and a maximum of 245 samples are acceptable.

This is the approximate number of gliomas that were expected to have been operated on over the last five years by December 2006.

$$N = \frac{z^2 p (1-p)}{d^2}$$

Where n= minimum sample size.

P=estimated prevalence of high-grade gliomas~ 80%.

Z=standard normal deviate corresponding to 95%

(C-I =1.96)

D= degree of precision (+/-5-10%).

### ***Inclusion criteria***

- ◆ All reports with a diagnosis of glioma.
- ◆ All request forms delivered to the department with a presumptive diagnosis of glioma during the study period.

### ***Exclusion criteria***

- ◆ Those specimens recorded as gliomas but samples found to be inadequate for immunohistochemical analysis.
- ◆ Cases found to have no blocks for review.

## **DATA COLLECTION**

### ***Processing of the tissue and reporting of the results.***

The researcher retrieved all the reports filled in the department of Pathology diagnosed as gliomas.

The corresponding paraffin blocks were retrieved, sectioned and stained using routine Haematoxylin/Eosin method.

The clinical, radiological and histology diagnosis and classification of the gliomas were entered into the proforma form.

The researcher then examined the slides microscopically with the help of the supervisor and made a diagnosis including World Health Organization classification and selected the IHC panels.

All tumours underwent immunohistochemical staining using Avidin-biotin peroxidase complex method for Glial Fibrillary Acid Protein, then subsequently classified (see appendix ii for procedure).

Final grading was done using markers of cellular proliferation (Ki67).

The staining was done at Kenya Medical Research Institute (KEMRI) laboratories by a technologist trained in immunohistochemistry then read by the researcher together with the pathology supervisors.

The clinico-radiologic correlation was carried out by reviewing the patients' files.



## **Quality control**

This was observed in all stages of tissue processing. Strict adherence to the SOPs was followed in the process and controls were used in immunohistochemistry. Quality checks were done on the stains, sections and fixation techniques. (Appendix II).

## **Data analysis**

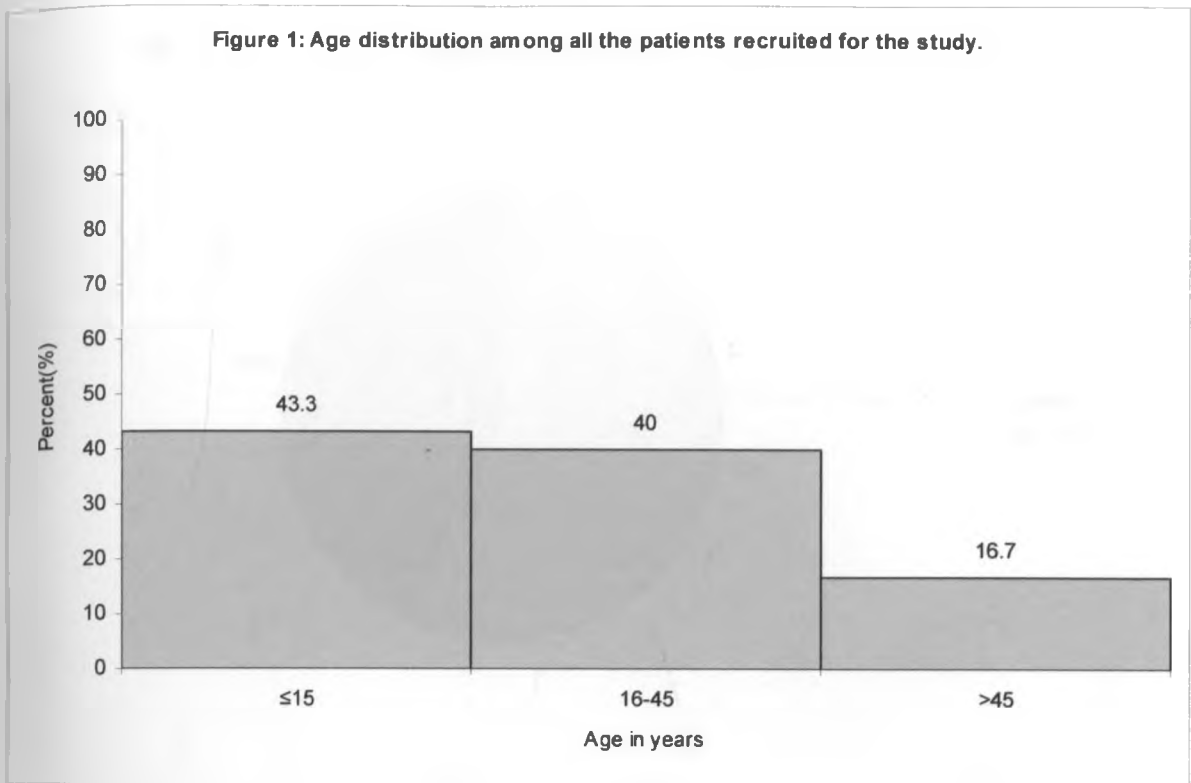
The data from the retrospective results and the request forms was fed into coded proforma sheets that were entered onto a computer database. Computer generated spreadsheets were prepared from the database and then transferred to Statistical Package for Social Sciences (SPSS®) statistical software for analysis. The descriptive summary statistics are presented as proportions and percentages in form of tabulations, charts and graphs using the statistical package (SPSS®).

## **Ethical Issues**

- Authority was sought from the Kenyatta National Hospital ethical and research committee.
- The study was undertaken after formal approval by the committee.
- This study has no adverse effects whatsoever on the health of patients but offers great diagnostic input to their illness.
- Confidentiality of participating subjects was maintained. The name of the subject would only appear on the request form for the purpose of follow-up.
- Any changes in diagnosis were communicated to the neurosurgeon (study supervisor) who would organize appropriate follow-up.

#### 4. RESULTS

- ◆ This descriptive study was conducted between November 2006 and October 2007. The total 102 diagnoses recorded as gliomas were retrieved and analyzed using routine H/E method.
- ◆ Only Sixty-four (63%) of those qualified for immunohistochemistry (glial fibrillary acid protein and ki67).
- ◆ The rest were partly analyzed because the tissue was insufficient, blocks were missing or the blocks contained different tissues other than brain.

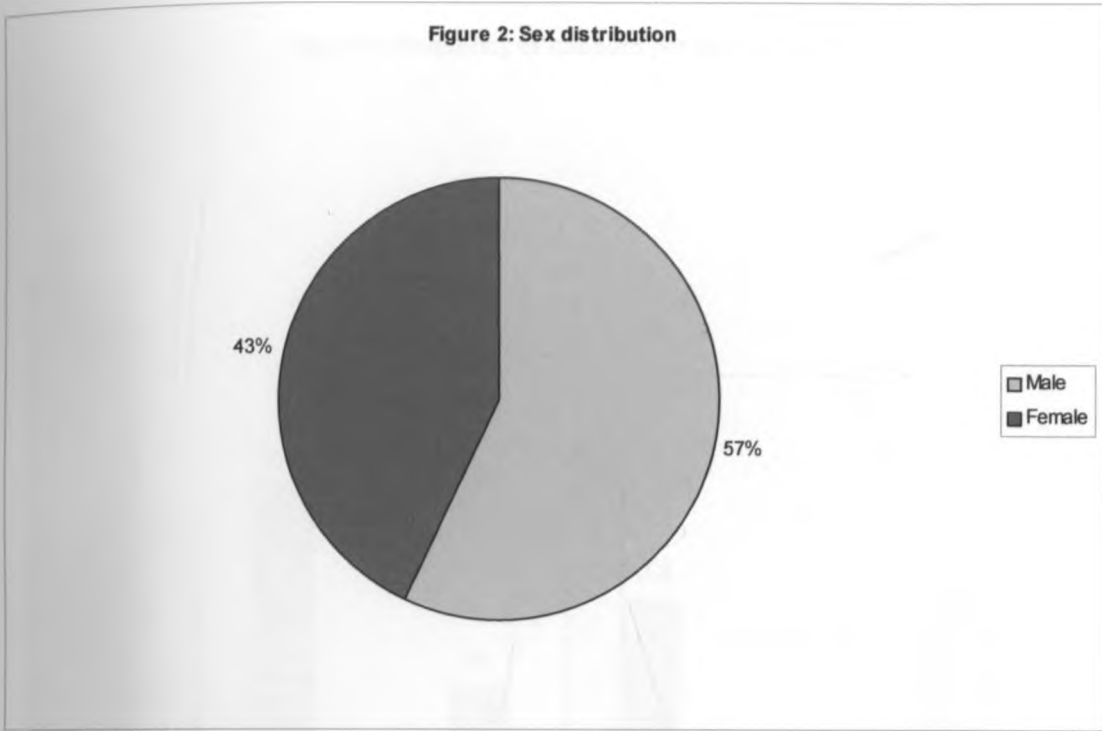


**Figure 1: Age distribution of the patients recruited for the study.**

Majority of the patients operated on were 15 years and below accounting for 43.3%. Those between 16 and 45 years were 40% while 16.7% were patients above 45 years of age.

The youngest was a girl aged seven months while oldest was an 81 year old man.

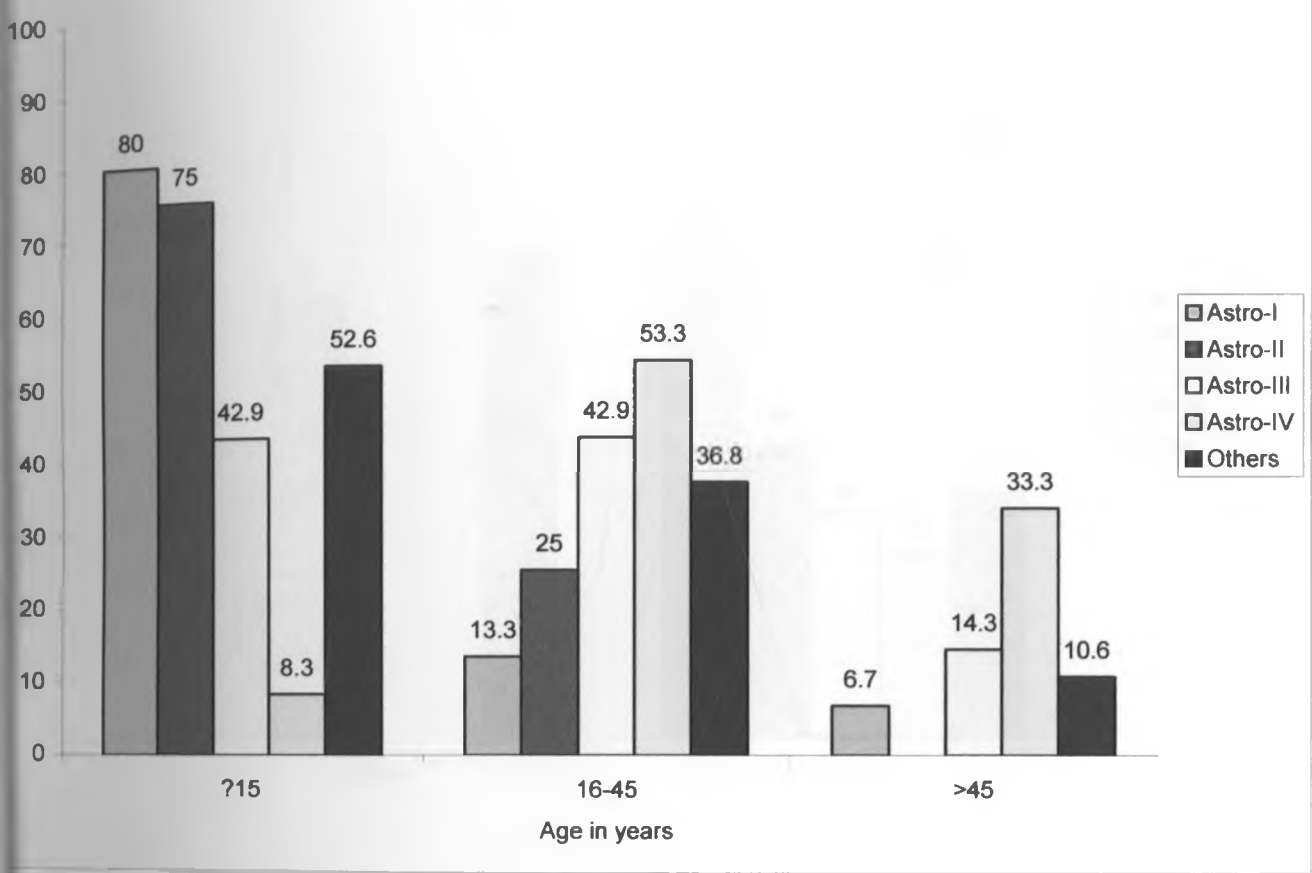
The mean age was 25yrs while the median age 18yrs.



**Figure 2: SEX DISTRIBUTION AMONG STUDY SUBJECTS.**

Majority of the specimen analyzed were from male patients accounting for 57%, while females were 43%. Male to female ratio is 1.3:1.

Figure 3: frequency of tumours per age group.



**Figure 3: Frequency of tumours as per age group.**

Low-grade gliomas were more common among the young than high-grade lesions. Eighty percent of all astrocytomas grade I and 75% of the grade II astrocytomas were amongst the <15yrs while grade IV tumours were only 8.3% in this age group.

Astrocytoma grade IV (GBM) was the commonest tumour in patients above 15yrs contributing to 53.3%.

The group labelled others includes ependymomas, oligodendrogliomas, PNET, and gliosis.

Figure 4: Distribution of the different gliomas by Sex.

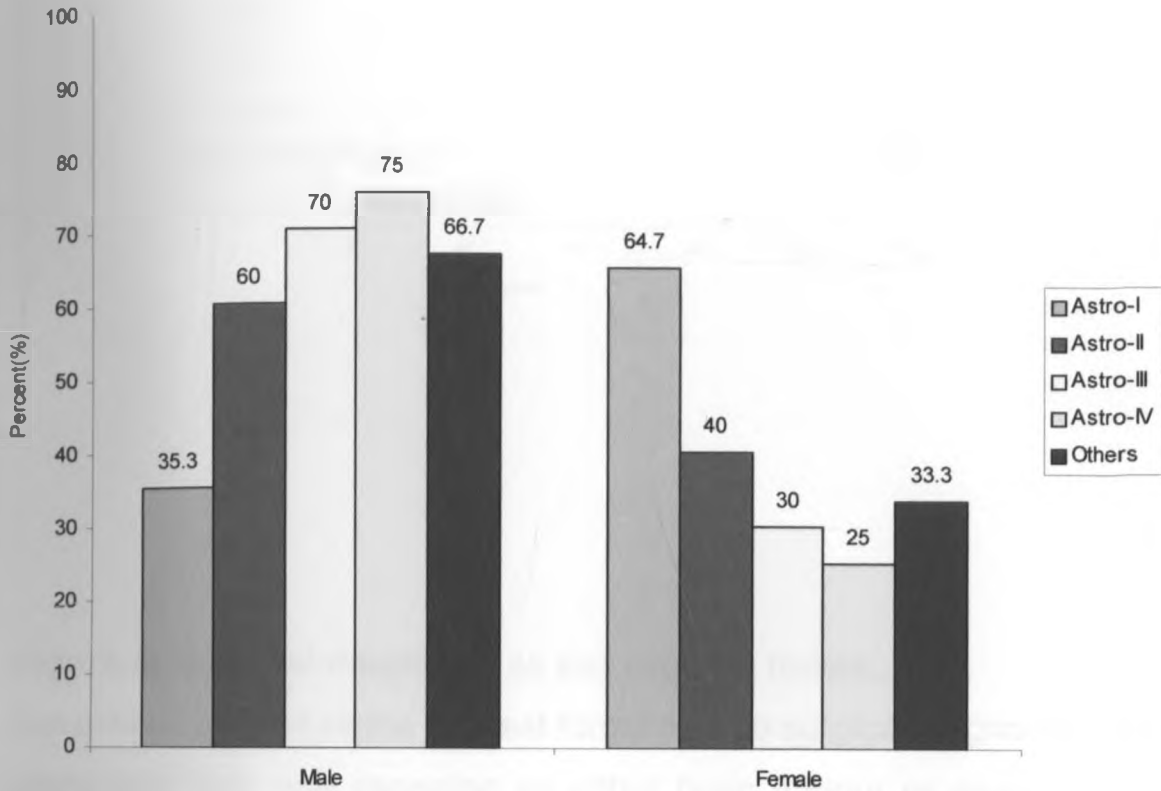
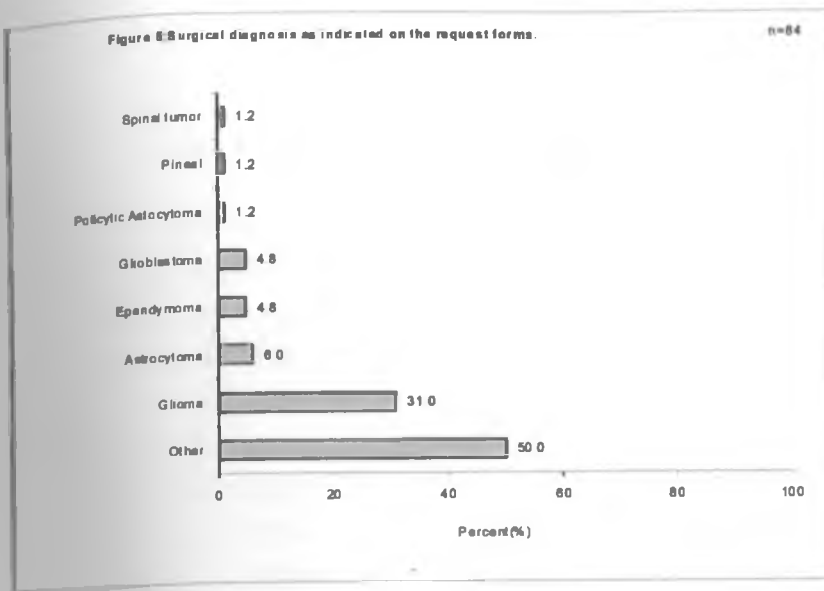


Figure 4: Frequency of tumours among different gender.

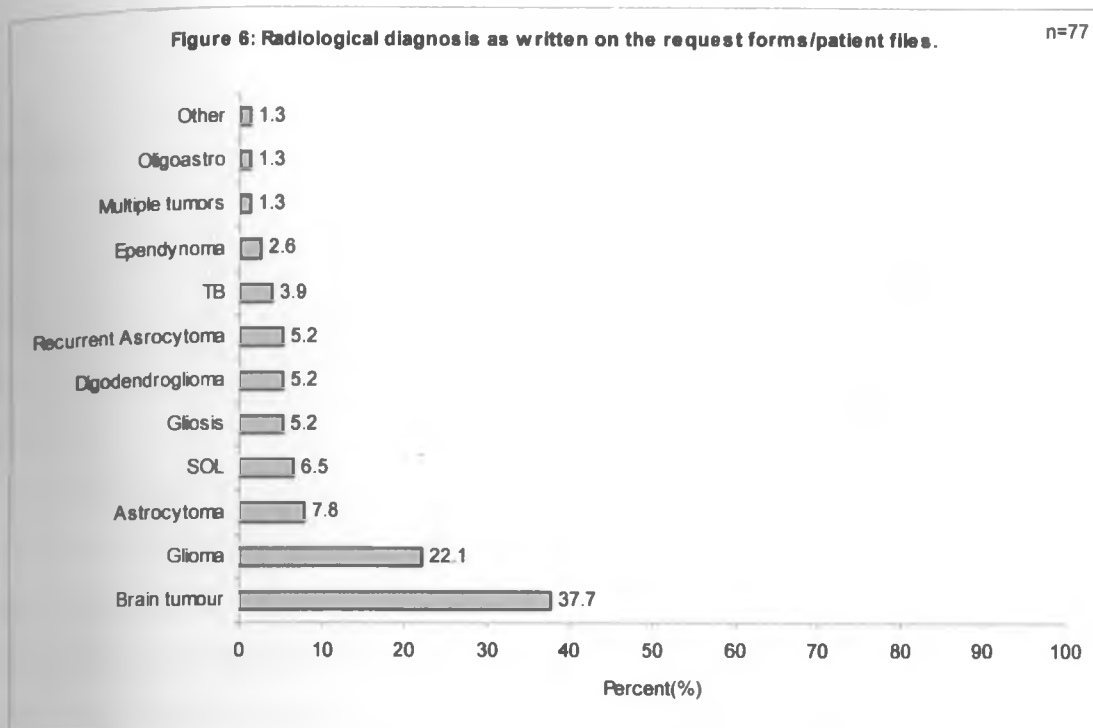
Astrocytoma grade I was more common amongst female (64.7%), while all the other gliomas were more prevalent in males especially grade IV lesions whose frequency was 75% in men.



**Figure 5: Surgical diagnosis as per request forms.**

Seventeen percent of the request forms had no surgical diagnosis indicated while (42) 50% was recorded as either brain tumour or space occupying lesion.

Gliomas were (26) 31%. Other lesions recorded were astrocytoma, ependymoma, GBM, pilocytic astrocytoma and spinal tumour all=19% (16).



**Figure 6: Radiological diagnosis as recorded on patient files.**

Of the 102 patients recruited for this study, 77 (75.5%) had a radiological diagnosis recorded in both the patients' files and request forms.

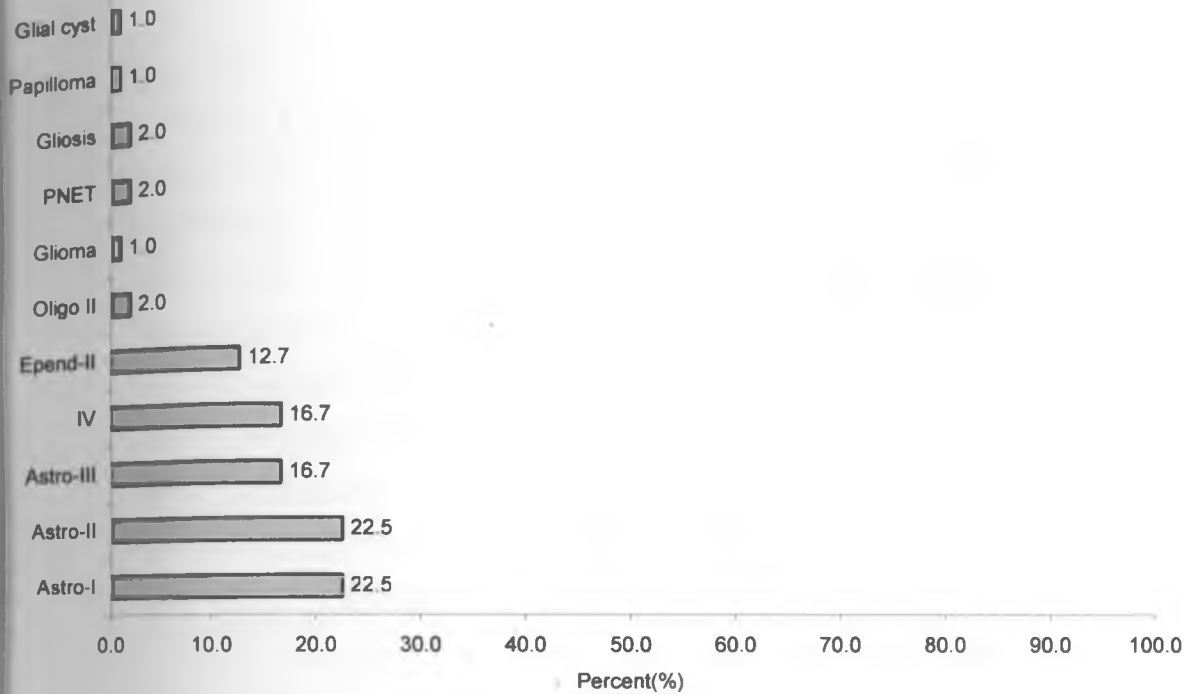
Radiological diagnosis was recorded in only 28.4% (29) of the request forms.

Most common diagnosis was a brain tumour not otherwise specified-37.7% (28), glioma 22.1 % (16) then astrocytoma (6) 7.8%.

The other tumours include SOL, gliosis, oligodendrogloma, TB, ependymoma, multiple tumours all at 32.4% (25).



Figure 7: Previous Histology



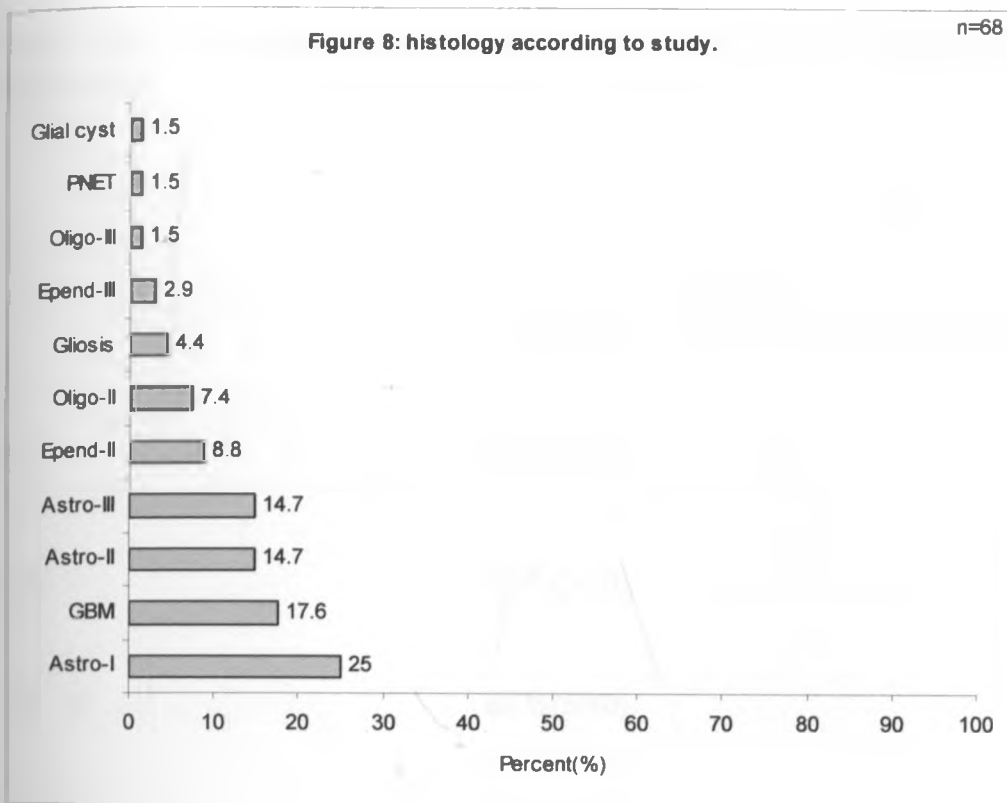
**Figure 7: Previous histological diagnosis as recorded on the request forms.**

Low-grade astrocytomas were most frequent with both grade I & II accounting for 22.5% (23) each.

High-grade astrocytomas were next in prevalence; both grade III & IV at 16.7% (17) each.

Other commoner lesions include ependymomas 12.7% (13).

Oligodendrogliomas, glioma, PNET, gliosis, choroid plexus papilloma and glial cyst all accounted for 9% of gliomas seen.



**Figure 8: final diagnosis after study review.**

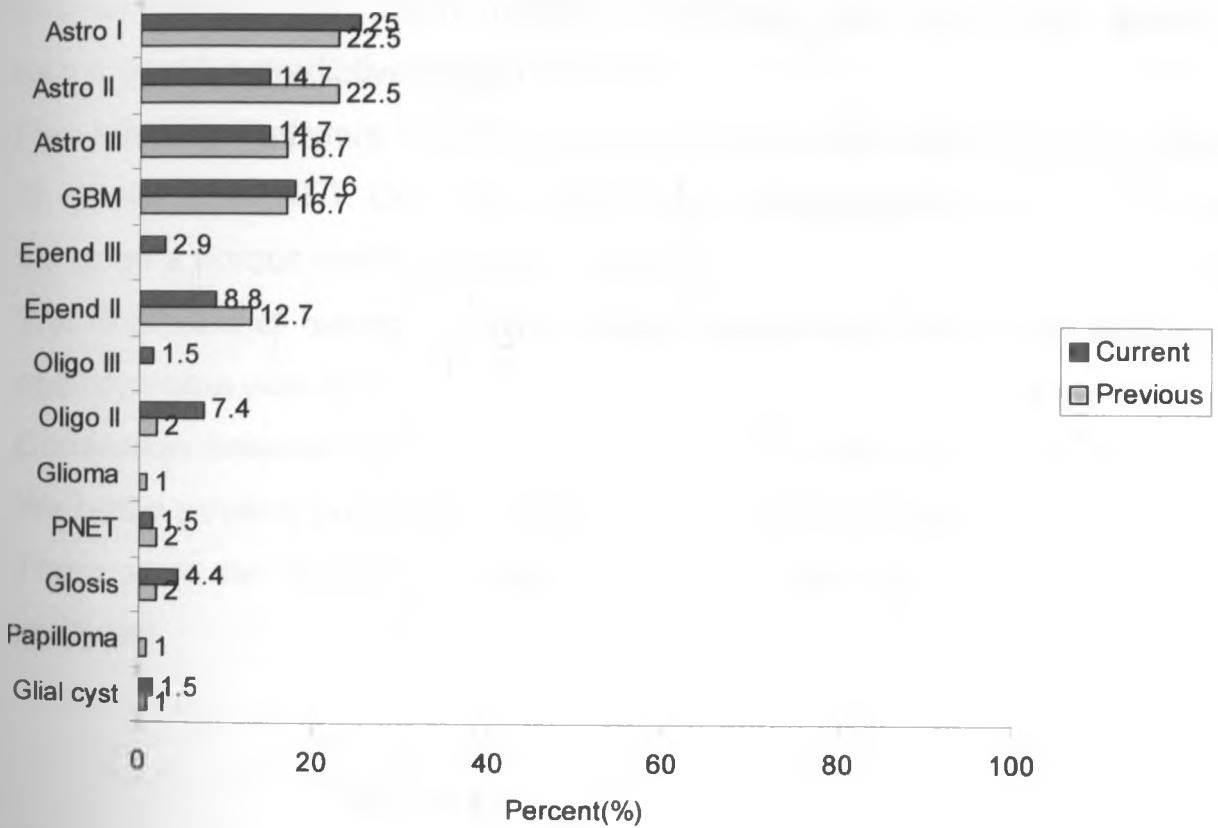
The most prevalent glioma was astrocytoma grade I (pilocytic) 25% (17), grade IV astrocytoma (GBM) at 17.6% (12), grades II & III each accounting for 14.7% (10).

Ependymoma grade II was 8.8% (6) while oligodendroglioma grade II was 7.4% (5). Other tumours were anaplastic oligodendroglioma, anaplastic ependymoma, PNET, gliosis and glial cyst together at 11.8%.

**Table III: correlations between previous and current histological diagnosis.**

Diagnosis	Correct	Positive Predictive Value
Astrocytoma Grade I	58.8 %(10/17)	62.5 %(10/16)
Astrocytoma Grade II	50 %(5/10)	35.7 %(5/14)
Astrocytoma Grade III	60 %(6/10)	50 %(6/12)
Astrocytoma Grade IV	75 %(9/12)	75 %(9/12)
Astrocytoma Grade II	66.7 %(4/6)	44.4 %(4/9)
Astrocytoma Grade III	0 %(0/2)	
Oligodendroglioma Grade II	20 %(1/5)	50 %(1/2)
	0%(0/3)	
	0%(0/1)	

Figure :9 correlation between previous and current diagnosis.



**Table 1/ figure 9: Correlation between previous and current histological diagnosis.**

The tumour that had the highest likelihood of being correctly diagnosed at histology was a grade IV astrocytoma with a positive predictive value of 75%.

The tumour that was easily missed at histology was astrocytoma grade II with a positive predictive value of 35.7%.

Few tumours that were initially missed altogether were ependymoma grade III, gliosis and PNET. One tumour previously diagnosed as a glioma turned out to be a fibrous meningioma on review.

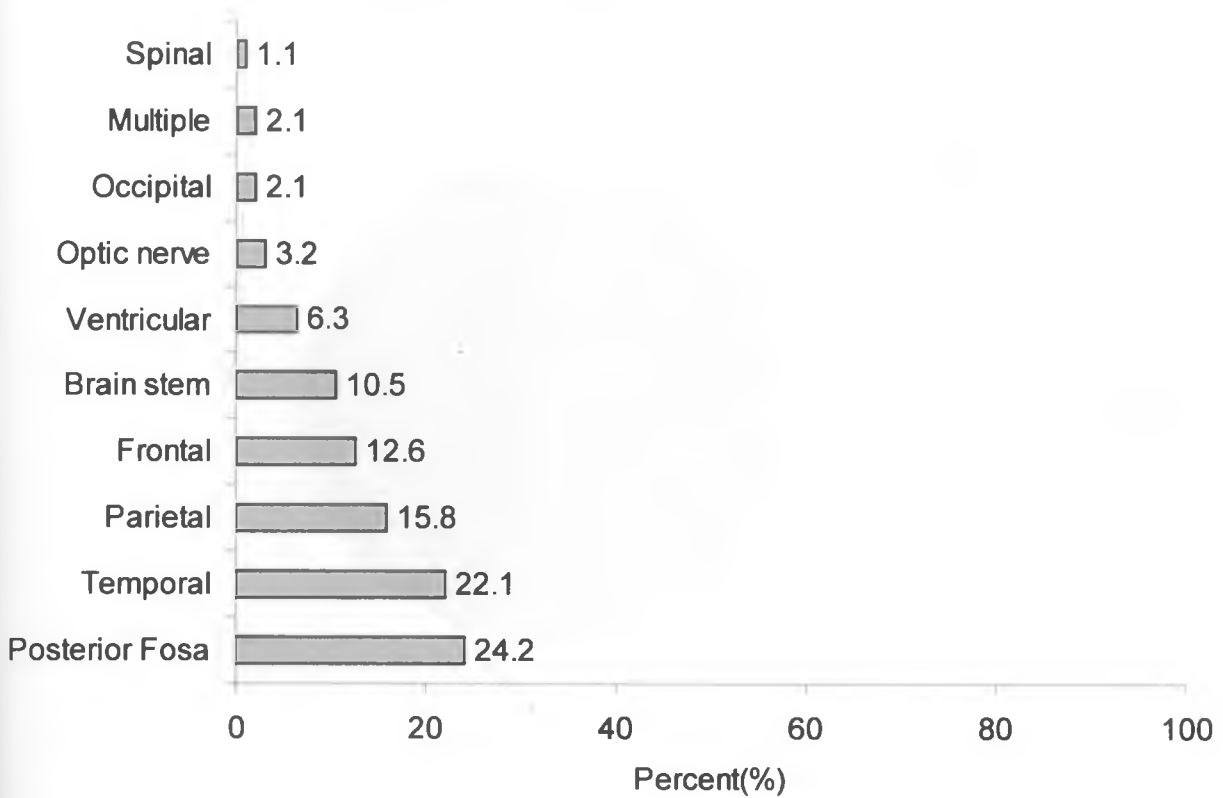
The likelihood of having a correct surgical diagnosis of an astrocytoma or ependymoma was 25%.

Correlation between radiological and histological diagnosis was very poor. We had a positive predictive value of 16% on astrocytomas.

There were no clinical-radiologic correlations amongst all other tumours analyzed.

**Figure 10: Site of lesion**

n=95

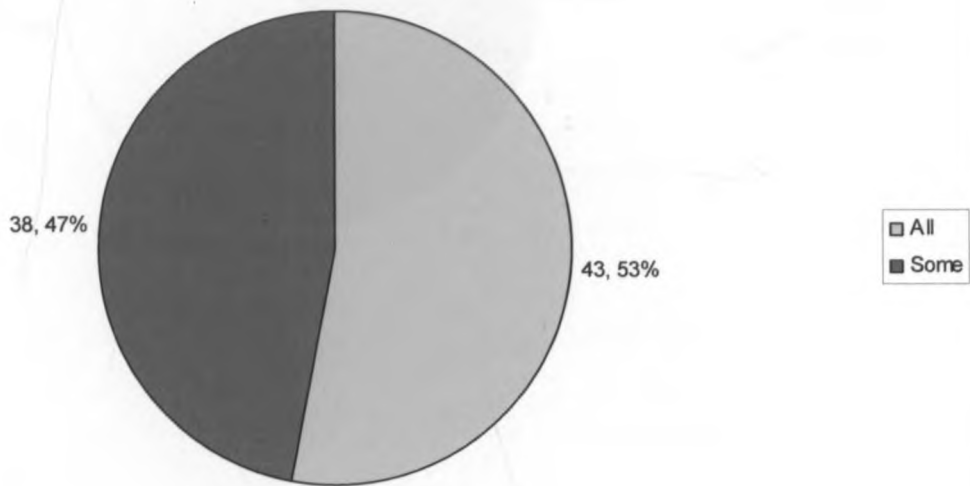


**Figure 10: distribution of tumours by site.**

Majority of the tumours that were operated on were at the posterior cranial fossa-24.2% (23), temporal 22.1% (21), parietal region had 15.8% (15) while the frontal region contributed for 12.6% (12). The brainstem and midbrain contributed a 10.5% (10) while the ventricular was 6.3% (6). One spinal tumour was analyzed (pilocytic) and accounted for 1.1%.

Figure 11: Amount of tissue processed during trimming.

n=81



**Figure 11: amount of tissue processed during trimming at histology.**

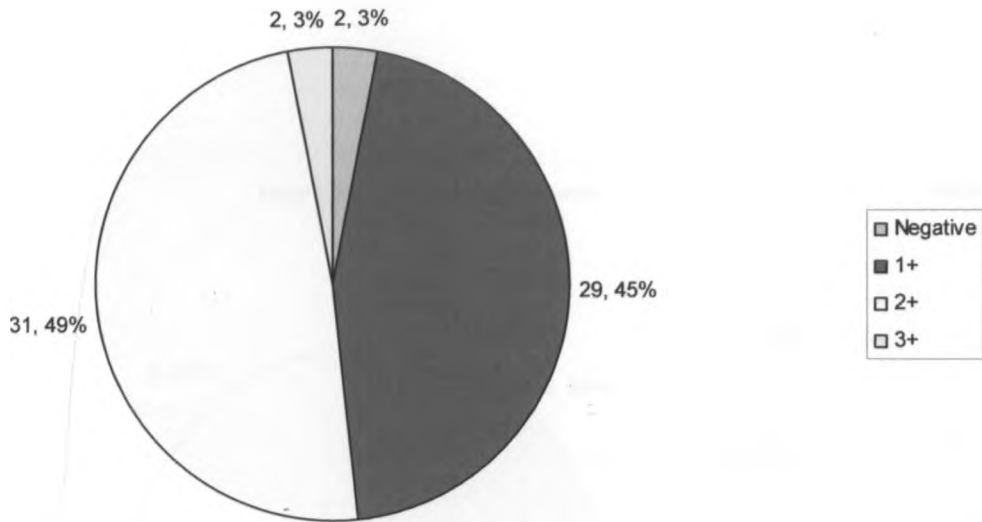
Of the all specimens reviewed, 20.6% were not recorded on amount processed.

All the tissue was processed in 53% while only some was processed in 47%.

Those tissues that were all processed had an average size of 20mm while those that had a part sampled averaged 44mm in diameter.

Figure 12 GFAP staining

n=64



### Figure 12: SHOWS GFAP STAINING PATTERN

GFAP staining was conducted on all gliomas and also on those that were unclassified totaling 64.

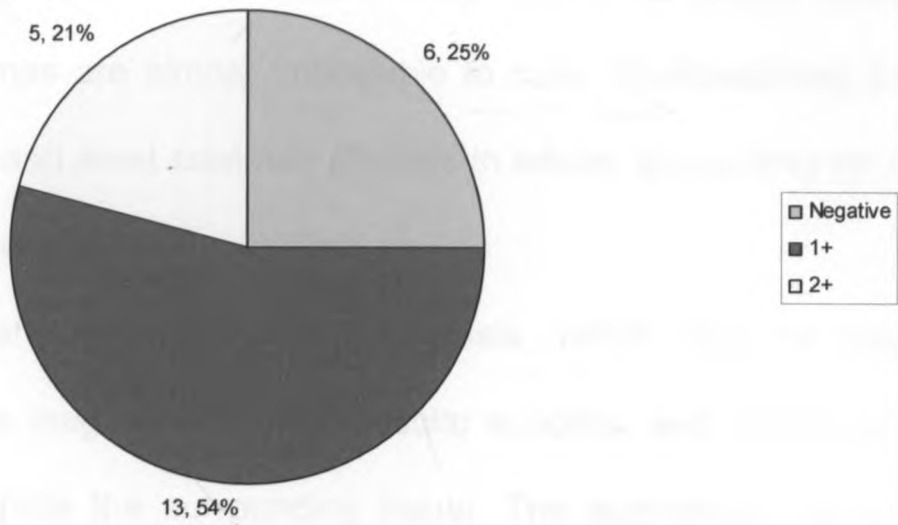
- ❖ 1+ =less than 10% of cells stain positive.
- ❖ 2+ =10-50% of cells stain positive.
- ❖ 3+ =more than 50% of cells stain positive.

Most gliomas exhibited low positivity at 45% and moderate positivity at 49%. High positivity was recorded in only 3% of the gliomas (all were grade II astrocytomas). Negative staining was found in gliosis and PNET.



Figure 13: Ki67 staining patterns.

n=24



**Figure 13: shows Ki67 staining patterns.**

A total of 24 cases underwent ki67 immunostaining. Majority of these were grade I astrocytomas.

Negative staining was recorded in 25% (6) of the cases. All cases of gliosis stained negative, as well as 40% of grade I astrocytoma.

Among the positive cases, 72.2% had a weak reaction (1+), while 27.8% had a moderate reaction (2+).

Eighty three percent (83%) of positive grade I astrocytoma and 75% of positive GBM, had a weak reaction (1+).

## 5. DISCUSSION

Gliomas, the most common primary brain tumors, are considered to arise from the supporting glial cells of the brain or their precursors<sup>27</sup>. Because they generally grow and invade extensively before the patient notes any symptoms, gliomas are almost impossible to cure. Glioblastomas are the most malignant and most common gliomas in adults, accounting for about 50% of all gliomas<sup>28</sup>.

Glioblastomas are distinguished by necrosis, which may be massive centrally or more irregular between vascular supplies, and peripheral cells that diffusely invade the surrounding tissue. The aggressive behavior of these tumors is reflected in their 100% fatality rate within approximately one year even after extensive surgery, radiotherapy, and chemotherapy<sup>2</sup>.

The precise determination of the biological behavior of tumors, as heterogeneous as gliomas is faced with limitations. Firstly, there is limited surgical accessibility and potentially malignant clinical behavior of these tumours. Secondly, because their virtual rate of proliferation may be discordant with the proliferative potential reflected in the histopathological picture, this justifies the continuing attempt at reclassification of these tumors. It is therefore obvious that histological appearance alone may not be adequate to correctly prognosticate the overall behaviour of gliomas.

The present study addresses this issue by using immunohistochemical staining to aid in correct glioma diagnosis <sup>29</sup>.

Gliomas account for 36-48% of all central nervous tumours seen at Kenyatta hospital as reported by Kibaya G.N and Chumba C.K <sup>26</sup>.

Although grade IV astrocytomas are the most common gliomas in literature, we found that they are second in our setup at 17.1% after grade I (pilocytic) lesions, which are 24.3%. This disparity may have arisen since majority of our study subjects were within the first two decades of life, which accounts for 80% of all patients with pilocytic astrocytomas. Similar studies report that comprising 6% of surgically biopsed or excised astrocytic tumours, 70% of pilocytic astrocytomas occur under the age of 20 <sup>30</sup>. They are rare over the age of 50 but may occur in older patients particularly in the cerebral hemispheres. We reported a prevalence of 6.7% among those more than 45 years.

High-grade lesions particularly grade III and IV astrocytomas are reported to peak at the third and fifth decades<sup>27</sup>. A similar picture was reported in our study where grade IV lesions contributed to 53% and 33% among the 16-45 and >45 age groups subsequently.

Grade II lesions (diffuse astrocytomas) usually peak around the third and fourth decades and their distributions is the same among the sexes. This varied much in our review where 75% of all grade II astrocytomas occurred at 15 years or less and 25% between 16-45 years. No diffuse astrocytomas were reported above the age of 45, which is the peak age of high-grade lesions.

Males were slightly more than females in this study at 57% and also bore the burden of the more aggressive tumours grades II, III and IV at 60%, 70% and 75% respectively. The bulk of pilocytic (grade I) astrocytomas were recorded among females at 64.7%. This data is quite similar to that reported by Lois J.W et al who described high-grade lesions as being more in the male population<sup>27</sup>.

The positive predictive value for gliomas reviewed was highest among grade IV lesions being 75% and was lowest among grade II (diffuse astrocytomas) lesions at 35%. On average, the chances of getting a correct histologic diagnosis were 50% without immunohistology. These tallies well with the findings of Coons S.W, et al who described a concordance of 50% among four neuropathologists examining diffuse astrocytomas<sup>30</sup>. The correct pathologic diagnosis of diffuse astrocytomas requires the ability to distinguish astrocytic from oligodendroglial differentiation in histologic sections, a challenging feat even for the most experienced neuropathologist. Interobserver variability in the diagnosis of diffuse gliomas has been high owing to subjective diagnostic criteria,

overlapping morphologic features, and variations in training and practice among pathologists. A select, albeit imperfect, group of molecular and immunohistochemical tests are available to assist in diagnosis of these lesions. Combined loss of chromosomes 1p and 19q is a genetic signature of oligodendrogliomas, whereas gains of chromosome 7 in the setting of intact 1p/19q are more typical of astrocytomas<sup>41</sup>. Unfortunately, we are unable to perform these specialized procedures in our setup hence rely on routine H&E.

The diagnosis of diffuse gliomas still hinges primarily on the histopathologic analysis of H&E-stained slides in most centers especially in the developing world. A shared property of these tumours is the widespread infiltration by individual cells through the CNS parenchyma. Once an infiltrating pattern has been established, tumours are subclassified based on their morphologic features as oligodendroglioma, astrocytoma, or mixed oligoastrocytoma. A grade then is applied to the infiltrating glioma depending on the criteria within each histologic category<sup>30</sup>.

Unfortunately, numerous studies have confirmed the suspicions of pathologists and clinicians that this method lacks a high degree of reproducibility. Of more concern is the inability to reliably distinguish oligodendroglial from astrocytic differentiation in nonclassic or ambiguous gliomas, which account for a surprisingly high percentage of tumours. This is especially true among low and intermediate grade gliomas.

In one study, concordance among experienced neuropathologists was only 50% in classifying and grading oligodendroglioma, astrocytoma, and oligoastrocytoma<sup>31</sup>. correlation improved modestly to 70% after the pathologists reviewed the cases together and discussed diagnostic criteria to facilitate consistency. During our study several pathologists reviewed the slides while any missing clinical and radiologic detail was retrieved and finally immunohistochemistry was performed to confirm the diagnosis.

This review significantly improved the agreement rates amongst the pathologists. Two cases of gliosis had been called gliomas based on increased cellularity but most of the cells were found to be inflammatory cells and reactive astrocytes. Other studies have demonstrated poor intraobserver reproducibility and an unacceptably wide variation in the diagnostic frequency of astrocytoma, oligodendroglioma, and mixed oligoastrocytoma, even among the most experienced of neuropathologists

32

Diagnostic inadequacies have launched numerous investigations of potential genetic and immunohistochemical markers that might distinguish more reliably the two main subtypes of gliomas, thereby simplifying the task of pathologists and restoring confidence among clinicians. Proper classification is more than an academic exercise because prognosis and therapy are guided by diagnosis. Oligodendrogliomas generally have slower growth rates and are associated with a better prognosis than astrocytomas when compared grade for grade, and the presence of an oligodendroglioma component within an infiltrative glioma usually predicts longer survival<sup>33</sup>.

Reproducible classification will become even more critical with the emergence of therapeutic regimens that are directed at specific neoplastic entities and molecular subtypes.

The review of high grade lesions was basically less complex owing to the clear diagnostic criteria of increased mitotic activity, nuclear atypia, vascular proliferation and necrosis with cellular pallisading. Their positive predictive value was 75% compared to 35% for diffuse astrocytomas (see table III).

Even with auxiliary tests, the diagnosis of diffuse gliomas remains a challenge, and the search for more specific and diagnostically useful markers continues. Emerging technologies, like DNA, complementary DNA, and protein microarrays, are demonstrating potential for brain tumor classification and for marker discovery. For example, complementary DNA microarray analysis coupled with computational algorithms has been used to successfully classify high grade gliomas into histologic groups. Moreover, this technique was found to be superior to histologic classification in predicting the prognosis of morphologically ambiguous tumours. Diagnostic microarrays containing a limited number of relevant genes could be designed to classify tumors, predict their clinical behaviour, and rank therapeutic options. Such approaches have already revealed new markers with the potential for diagnostic use that await validation <sup>41</sup>.

The development of therapies targeted at the molecular underpinnings of these diseases ultimately will require a molecular component in the diagnosis of the diffuse gliomas.

Although oligodendrogliomas account for 4-7% of primary brain tumors and 12% to 20% of infiltrating gliomas, our review reported a prevalence of 9.1%. Among these, anaplastic oligodendrogliomas were 1.5%. Their incidence seems to have increased during the past 2 decades, but it remains unclear whether this increase reflects a diagnostic trend among pathologists or a meaningful epidemiologic shift <sup>34</sup>. The previous histological reports in this study actually showed a prevalence of only 2% compared to the review prevalence of 9.1%.

An anaplastic oligodendroglioma had been missed, and this shows the amount of challenge faced when diagnosing these lesions especially where sufficient clinical and radiological detail is not available.

In one of the original classifications of glial neoplasms by Bailey and Cushing and later in the article "Oligodendrogliomas of the Brain" by Bailey and Bucy, a unique cerebral hemispheric tumor of adults with histologic features unlike the other gliomas was described<sup>35</sup>. In these descriptions, oligodendrogliomas contained cells with nuclei that "are almost all perfectly round and of a fairly constant size" and are "surrounded by a ring of cytoplasm which stains very feebly"; they have a "network of fine capillaries" and "are prone to become calcified."

Our current concept of oligodendroglioma retains most of these essential features, yet there is an impression among some authorities that the diagnostic criteria of present day pathologists have expanded to gradually encompass nonconventional morphologic features<sup>36</sup>.

Restricting the diagnosis of oligodendroglioma to morphologically classic lesions that fulfill the original descriptions, would eliminate at least some of the current confusion in neuro-oncology. Nevertheless, these early articles also foreshadowed some of the real diagnostic dilemmas that we continue to encounter: "There are also many cells which appear to be transitions between gigantic oligodendroglia and astrocytes. It is impossible to definitely classify them as belonging in either group. "Practically every stage of gradual transition from typical oligodendroglia to typical astrocytes can be found.



Current diagnosis of oligodendroglioma requires the identification of infiltrating glioma cells that have round, regular, and monotonous nuclei, with little cell-to-cell variability<sup>37</sup>.

As most pathologists are aware, tumour cell cytoplasm tends to swell during routine formalin fixation and paraffin embedding, resulting in cells with well-defined cell membranes, cytoplasm clearing, and a central spherical nucleus a combination that gives rise to the classic “fried egg” cell (also described as “honeycomb” and “woody plant” histologic features by Bailey and Bucy). It should be emphasized that perinuclear cytoplasmic clearing is helpful for establishing the diagnosis of oligodendroglioma but is not a feature that is required, sufficient, or constant.

Grading systems typically have divided oligodendrogliomas into 2, 3, or 4 grades depending on cellularity, cytologic atypia, mitotic activity, vascular proliferation, and necrosis<sup>37</sup>. These criteria for grading are not as clearly defined for oligodendrogliomas as they are for astrocytomas.

The current World Health Organization (WHO 2000) Classification recognizes 2 grades: oligodendroglioma (grade II) and anaplastic oligodendrogliomas (grade III). Grade II tumours vary from low to moderate cellularity. These tumours have a tendency to involve the cerebral cortex, and, as they progress, they often grow in a distinctly nodular pattern. Nodular growth is compatible with a grade II lesion but might represent a transition to a higher grade, especially when the nodules coalesce into regions of confluent hypercellularity. Grade II oligodendrogliomas can show occasional mitotic figures and cytologic atypia, but marked mitotic activity, micro vascular proliferation, or necrosis is consistent with a WHO grade III, anaplastic oligodendroglioma. We described one case of a child with an anaplastic oligodendroglioma in our study, which met all the above criteria.

A recent study of prognostic features in oligodendroglioma identified endothelial hypertrophy, necrosis, and 6 or more mitotic figures per high-power field as significant univariate markers of poor outcome, providing a solid framework for establishing the diagnosis of anaplastic oligodendroglioma (grade III). Previous multivariate analyses have suggested that necrosis is the single most important feature of aggressive clinical behavior<sup>38, 39</sup>.

Pseudopalisading of tumour cells around necrosis is an acceptable finding in anaplastic oligodendroglioma and does not suggest a diagnosis of glioblastoma. In our setup, this remains invaluable diagnostic information since we handle limited amount of brain biopsies. To sum it up, like pornography in the observation of U.S Supreme Court Justice Stewart, the oligodendroglioma is easy to recognize but may be difficult to define<sup>27</sup>.

Normal oligodendroglial cells do not possess cytoplasmic intermediate filaments and do not exhibit GFAP. Nevertheless, immunoreactivity for GFAP may be found in typical oligodendrogliomas in which it has been estimated to occur in over 50% of pure tumors. We reported GFAP reactivity albeit weak reaction in all the oligodendrogliomas reviewed in our study. GFAP reactivity in these tumours appears to be related to several factors. Well-differentiated reactive astrocytes may be scattered throughout in up to 60% of oligodendrogliomas. Alternatively, the tumour may exhibit mini-gemistocytes. Although an interesting and confusing observation, the presence of these tumor cells do not adversely affect clinical prognosis. The origin of the GFAP reactivity appears to have an embryological basis, because human oligodendroglial cells in normal ontogeny may transiently express GFAP immediately before myelinogenesis. Finally, the differential immunohistochemical demonstration of soluble lectins helps to distinguish differentiated from anaplastic oligodendrogliomas.

The grade II tumours elaborated low ki-67 labeling index while the grade III tumour had moderate reaction. Several observers have evaluated nuclear labeling index, as determined by MIB-1 or KI67 staining, to determine its prognostic significance. Anaplastic oligodendrogliomas have higher labeling indices than do well-differentiated oligodendrogliomas; thus, MIB-1 labeling index is associated with tumour grade. Whether the labeling index, independent of histologic grade, is an indicator of prognosis, however, remains more debatable<sup>40</sup>.

The overall incidence of ependymomas in large series has been reported as being 4.7% of all CNS tumours and 9.1% of all gliomas. We reported a similar incidence of 11.7% of all gliomas. None of the ependymomas was reported in the spinal cord although upto 32% of them occur in the spinal cord. Majority of ependymomas are reported in men<sup>27</sup>.

Although often related to ventricular system, ependymomas may occur anywhere in the neuraxis. Commonest intracranial site is the posterior cranial fossa accounting for upto 70%. A small population is entirely intracerebral with no evidence of ventricular continuity<sup>41</sup>.

We reported only 29% of all ependymomas, as being in the posterior cranial fossa and also 29% of all ependymomas were anaplastic while Shaw E.G, Evans R.G, et al reported a range of 7-21% during their review of postoperative radiotherapy of ependymomas in patients<sup>40</sup>.

### **Clinico-Radiologic correlations.**

We reported a very poor concordance between surgical, radiological and histologic diagnosis basically because of the large family of glial tumours. Most radiological-clinical reports recorded general groups like glioma,

astrocytoma or more often brain tumour. This limited the detail required by the pathologist to reach a definitive diagnosis.

We recommend that clear clinical and radiologic detail be availed to the pathologist. Kibaya.G.N described similar findings in 1998 with a concordance of 40% between CT scan and histology results at Kenyatta national hospital.<sup>25</sup> The fact that these finding have maintained a status quo is a sin gue non of unchanging quality in diagnostic medicine.

### **GFAP - GLIAL FIBRILARY ACID PROTEIN.**

GFAP is a 55-kd protein monomer that can form intrachain disulfide cross-links. It is present in astrocytomas and oligodendrogliomas and less so in neurofibromas, medulloblastomas, and ependymomas. Its presence in primitive neuroectodermal tumours underscores the pluripotent differentiation of these tumours. It is believed that GFAP is expressed in cells reacting to their local environment. In fact, the first isolation of GFAP was from a multiple sclerosis plaque, which perhaps represents a reaction to a localized insult. Using antisense oligomers, Weinstein et al, found GFAP to be required for astrocytic reaction to neurons. There may be a coordinated biological interaction between GFAP, vimentin, and S-100.

Recently, the human GFAP gene has been cloned and its chromosomal location identified as 17q21. GFAP has also been found to be expressed in gliomas with low levels of fibronectin gene transcription and expression.

As would have been expected, all gliomas in our study were immunoreactive to GFAP most of which exhibited low to moderate positivity. The three percent of the gliomas that had strong positivity to GFAP were all grade II astrocytomas. Generally, all oligodendrogliomas and ependymomas exhibited low positivity up to 10% of the cells being

reactive which was in keeping with the biology of these tumours because they have less intermediate fibres<sup>40</sup>.

Gliosis and PNET stained negatively thus helping distinguish two cases of gliosis that had been previously reported as diffuse astrocytomas based on their atypical cellularity and reactive astrocytes. This underscores the value of GFAP in the correct diagnosis of gliomas. Unfortunately, none of the glioma markers are sufficiently reliable to be used to grade gliomas, reflect differentiation, or indicate lineage of astrocytomas, oligodendrogliomas, or ependymomas. The lack of specific markers for most CNS tumours reflects their complex heterogeneous biology.

### **Ki67**

The proliferation activity of tumours can also be assessed by means of Ki-67 immunohistochemistry, which is now widely used in clinical pathology and neuropathology diagnostics. Burger and co-workers were the first to show the tight association between Ki-67 immunopositivity and glioma grade in freshly frozen samples of astrocytomas. Weinstein and others have described the prognostic value of immunostaining with MIB-1, an antibody recognizing the Ki-67 antigen in paraffin wax embedded tissue. Based on a large number of studies, the added prognostic information provided by Ki-67 immunostaining is now well established with regard to astrocytic tumours. The latest WHO classification of central nervous system tumours 2007 includes Ki-67 as an additional tool in histological typing and grading, although it cannot be regarded as being entirely prognostic in individual cases<sup>44</sup>.

When considering the usefulness of immunohistochemical tumour proliferation assessment, overlapping Ki-67 indices in different histopathological categories and considerable intratumorous regional variations of proliferation are well known problems. The advantage of Ki-67

comes from its wider coverage of the cell cycle, resulting in higher percentages of positively labeled proliferating cells when compared with proliferating cell nuclear antigen or mitotic indices. This provides a better statistical distinction between different histological grades. At the practical level, another important issue to consider is sampling. Variation in tumour proliferation indices is much smaller when evaluation is systematically performed in the area of highest proliferation. Unfortunately, samples from these tumour areas are not always sent for postoperative diagnostic assessment. Regional intratumorous heterogeneity may result in underestimation of malignancy intraoperatively, irrespective of which method of tumour proliferation assessment is used and this could explain why some of the glioblastomas we stained had a low proliferative index.

Although Burger et al. have found that higher nuclear staining of gliomas with the KI-67 antibody seems to correspond with more malignant histologic appearance and faster growth characteristics<sup>45</sup>, in our study, anaplastic ependymoma and a PNET stained the most owing to lack of necrosis and also they bore a lot of mitoses.

### **Tissue sampling**

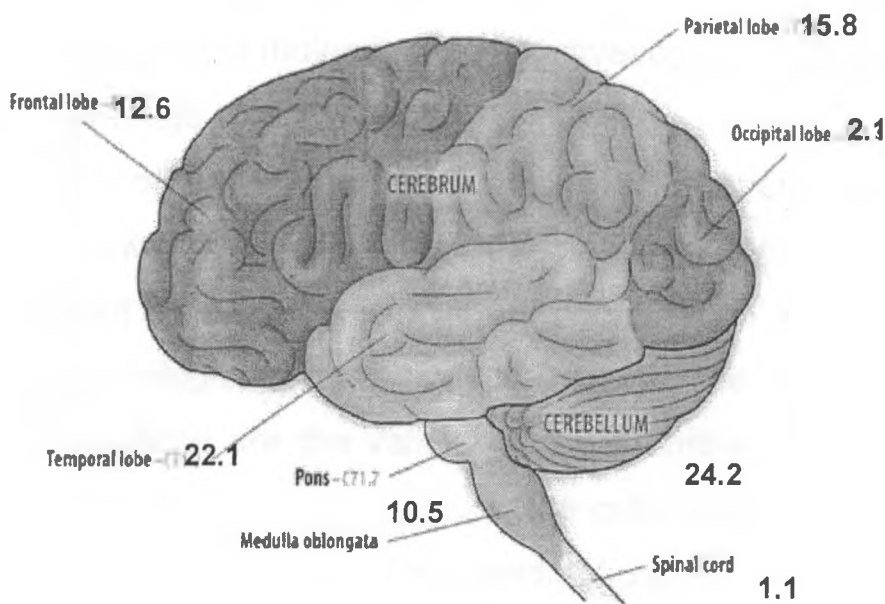
The sizes of the biopsies examined in our study ranged from 3-87mm in diameter. Of all those reviewed, the pathologist trimming never indicated the size of biopsy in 20% of the cases. All the tissue was processed in 53% of the cases, which averaged 20mm diameter while the 47% partly processed biopsies averaged 44mm diameter.

The significance of this was not reviewed in this study; however, inadequate tumour sampling can easily change a diagnosis or grade of gliomas due to their heterogeneity. Paulus W and Peiffer J studied the intratumoral histologic heterogeneity of supratentorial gliomas according to the World Health Organization and six histologic features associated with

malignancy were evaluated (cellular density, nuclear pleomorphism, necrosis, histologic architecture, vessels and mitoses). Of all gliomas 48% showed differently typed samples, 82% differently graded samples and 62% benign and malignant grades. These results underscore the importance of extensive tissue sampling<sup>24</sup>.

Any histologic grading system will suffer if insufficient or unrepresentative biopsy material is submitted for evaluation; this is especially true for gliomas, which have considerable intratumoral heterogeneity. This heterogeneity (reflected in the name given to the most malignant member of the gliomas, glioblastoma multiforme) within a given tumour plagues their evaluation whether by histology, immunochemistry, molecular genetics and troubles clinical evaluation by diagnostic imaging techniques<sup>46</sup>. We recommend that brain biopsy be well sampled and then enough sections processed to achieve good representation on any lesion.

**Figure 14. Site tumour.** This represents the distribution within the brain of the gliomas seen during this study.



Majority of the gliomas studied generally occurred on sites that concur with the available literature. Pilocytic astrocytomas occur mainly in the posterior cranial fossa especially in pediatrics, up to 50%. In our study it was 30%. Other commoner sites for pilocytic are optic nerve 1%, cerebral cortex 20% and spinal 5%. We reported only one spinal pilocytic astrocytoma.

Diffuse, anaplastic astrocytomas as well as glioblastomas all were common in the cerebral hemispheres as expected.



## Future aspects

The future of classification of Central nervous system neoplasm especially pediatrics' ones are evolving from morphology-based approaches to that of a "cell of origin" and flexible systems that incorporate the results of immunohistochemical and molecular biology investigations. Burger PC and Fuller GN acknowledge that

the development of improved classifications will depend on reasoned application of newer methodologies to complement the many worthy aspects of present classifications. Careful coordination among clinicians, radiologist and pathologists is necessary to establish the relevance of these findings. Among these are the validity of the primitive neuro-ectodermal tumours, approach to embryonal tumours; the criteria for classification and grading of ependymomas and oligodendrogliomas; and the utility of subdividing cerebellar astrocytomas<sup>27</sup>.

Just as a correct histopathological diagnosis is crucial in prognosis, what is even more important is susceptibility of some gliomas to chemotherapy. Results are frequently subjective, and there is significant disagreement among neuropathologists. The answer to the question how to best and accurately identify tumours, may be is found in the domain of molecular technology. The challenge for molecular biology is to move the burden of histopathological assessment from classical techniques onto molecular methods. As shown by Nutt *et al*, classification of glioblastomas and nonclassic anaplastic oligodendrogliomas based on gene expression shows a significantly better correlation with survival than histological classification; due to this fact the former method may seem to be more robust<sup>47</sup>.

By studying the specific genetic alterations of a subgroup of more chemosensitive gliomas, their classification can be refined: the loss of the short arm of chromosome 1 has thus been associated with a better prognosis and improved response to chemotherapy <sup>47</sup>.

## 5.0.2. CONCLUSION

- ◆ Majority of the laboratory request forms lack sufficient clinical and radiological data like age, sex, and site of lesion that is useful to ascertain histologic diagnosis.
- ◆ Gliomas were more common in males than females.
- ◆ High-grade lesions were more prevalent among males and also among those >16 years.
- ◆ Most prevalent glioma was grade I astrocytoma followed by grade IV.
- ◆ Clinico Radiologic and histological correlations were very poor.
  
- ◆ All gliomas were immunoreactive to GFAP. This was useful especially in challenging cases like differentiating a meningioma, a PNET and ependymoma.
- ◆ Ki67 is of value in differentiating low-grade tumours from gliosis.
  
- ◆ Clinical and radiologic details are vital for correct diagnosis of brain tumours.
  
- ◆ The bedrock of histological diagnosis is routine H/E microscopy with IHC, flow cytometry and electron microscopy being adjuvant in selected cases.
  
- ◆ Student funding should be provided to ensure that studies are conducted on time and the valuable findings implemented as much as can be practical.

## **5.0.2. Recommendations**

- ◆ A standard laboratory request form should be developed and used in the section of neuropathology.
- ◆ Clinicians should be informed that it is crucial to include patients' clinical and radiological detail on this form (age, sex, and site of lesion, diagnosis, and previous histology results).
- ◆ Immunohistochemical panels for gliomas like GFAP and ki67 should be introduced in laboratory for grading intermediate gliomas and differentiating low-grade tumours from gliosis.

## **5.0.3. Limitations of this study**

This study was expensive and if sponsorship was available, it would have taken shorter time and included more panels for immunochemistry.

Lack of immunohistochemistry at Kenyatta hospital reduces the amount of exposure the student gets during the training period.

The archiving system was not up to date and we missed some blocks from the stores.

## 6. REFFRENCES

1. Kleihues, P, Cavenee, W.B, World Health Organization (WHO) Classification of Tumors: Pathology and Genetics: *Tumors of the nervous system*. Eds. Lyon, France: IARC Press, 2000.
2. Louis, D.N, Holland, E.C and Cairncross, G; Glioma classification-A Molecular appraisal. *Amj of pathol* 159; 3, 2001.
3. Ferguson, S. M.A., and Lesniak, M.S, M.S M.D. Percival Bailey and the Classification of brain tumors. *Neurosurg. Focus* 18 (4): E7, 2005.
4. Robbins and Cotran Pathologic basis of disease 7<sup>th</sup> edn chap 28 PG 1347.
5. Ellison, D, Love, S, Neuropathology. In Chimelli, L, Lowe, 2<sup>nd</sup> edn, Mosby.2004: 35; 623.
6. Altshuler, G, Antonioli, D.A, Diagnostic surgical Pathology. In Sternberg, A.S, 3<sup>d</sup> edn Lippincott Williams and Wilkins, 1999. Chap 10.
7. Hayostek, C, Shaw, E.G, Scheithauer, B.W, et al. Astrocytomas of the cerebellum. A comparative clinicopathologic study of pilocytic and diffuse astrocytomas. *Cancer* 1993; 72:856-869
8. Schneider, J.H. Jr, Raffel, C. McComb, J.G. Benign cerebellar astrocytomas of childhood. *Neurosurgery* 1992; 30:58-62.
9. Clark, G.B, Henry, J.M, McKeever, P.E, Cerebral pilocytic astrocytoma. *Cancer* 1985; 56:1128-1133.

10. **Forsyth, P.A, Shaw, E.G, Scheithauer, B.W, O'Fallon, J.R, et al.** Supratentorial pilocytic astrocytomas. A clinicopathologic, prognostic, and flow cytometric study of 51 patients. *Cancer* 1993 Aug 15; 72(4): 1335-42.
11. **Coakley, K.J, Huston, J, Scheithauer, B.W, et al.** Pilocytic astrocytomas: well-demarcated magnetic resonance appearance despite frequent infiltration histologically. *Mayo Clin. Proc.* 1995; 70:747-751
12. **Vertosick, F.T. Jr, Selker, R.G, Arena, V.C.** Survival of patients with well-differentiated astrocytomas diagnosed in the era of computed tomography. *Neurosurgery* 1991; 28:496-501.
13. **Artigas, J, Cervos-Naavaro, J, Iglesias, J.R, Ebhardt, G.** Gliomatosis cerebri: clinical and histological findings. *Clin Neuropathol* 1985 July- Aug; 4(4): 135-48
14. **Kandler, R.H, Smith, C.M, Broome, J.C, Davies-Jones, G.A.** Gliomatosis cerebri: a clinical, radiological and pathological report of four cases. *Brit. J. Neurosurg* 1991; 5:187-193.
15. **Krouwer, H.G.J, Davis, R.L, Silver, P, Prados, M.** Gemistocytic astrocytomas: a reappraisal. *J. Neurosurg.* 1991; 74:399-406.
16. **Grant, J.W, Gallagher, P.J.** Pleomorphic xanthoastrocytoma. Immunohistochemical methods for differentiation from fibrous histiocytomas with similar morphology. *Am. J. Surg. Pathol.* 1986 May: 10(5): 336-41
17. **Zuccaro, G, Taratuto, A.L, Monges, J.** Intracranial neoplasms during the first year of life. *Surg. Neurol.* 1986 July; 26(1): 29-36
18. **Schiffer, D, Chio, A, Giordana, M.T, et al.** Histologic prognostic factors in ependymoma. *Child. Nerv. Syst.* 1991; 7:177-18220
19. **Kawano, N, Yada, K., Aihara, M, Yagishita, S.** Oligodendroglioma-like cells (clear cells) in ependymoma. *Acat. Neuropathol. (Berl)* 1984; 3:122-127.

20. **Ross, G.W, Rubinstein, L.J.** Lack of histopathological correlation of malignant ependymomas with postoperative survival. *J. Neurosurg.* 1989; 70:31–36
21. **Burger, P.C, Scheithauer, B.W, Vogel, F.S.** *Surgical Pathology of the nervous system and its coverings, 3rd ed.* New York: Churchill Livingstone, 1991.
22. **Alvord, E.C.** Is necrosis helpful in the grading of gliomas? *Editorial opinion. J. Neuropathol. Exp. Neurol.* 1992; 51:127–132
23. **Paulus, W, Peiffer, J.** Intratumoral histologic heterogeneity of gliomas. A quantitative study. *Cancer* 1989; 64:442–447.
24. **Kibaya, G.N.** Radiological and Histologic analysis of intracranial lesions seen at Kenyatta National hospital between 1995-1998. (A thesis conducted as part fulfillment of Mmed in Radiology).
25. **Chumba, D.K,** Histological Classification of meningiomas at KNH 2002-2006. *Mmed-pathology part II* 2006.
26. **J.W. Ironside, T.H.Moss, D.N.Louis et al.** Diagnostic pathology of CNS tumours, 1<sup>st</sup> edn, cap 4 pg 58-89. 2002, Churchill Livingstone.
27. **Suash Sharma, Asis K Karak, Rajvir Singh, VS Mehta, Chitra Sarkar, Horst P Schmitt.** A Correlative Study of Gliomas Using *In Vivo* Bromodeoxyuridine Labeling Index and Computer-aided Malignancy Grading *Pathology Oncology Research Vol 5, No 2, 1999*
28. **Burger PC, Scheithauer BW, Vogel FS.** *Surgical Pathology of the Nervous System and Its Coverings. 4th ed.* New York, NY:Churchill Livingstone; 2002.
29. **Cavenee WK, Furnari FB, Nagane M, et al.** Diffusely infiltrating astrocytomas. In: Kleihues P, Cavenee WK, eds. *Pathology and Genetics of Tumours of the Nervous System. 2<sup>nd</sup> ed.* Lyon, France: IARC Press; 2000:10-21. *World Health Organization Classification of Tumours.*

30. **Coons SW, Johnson PC, Scheithauer BW, et al.** Improving diagnostic accuracy and Interobserver concordance in the classification and grading of primary gliomas. *Cancer.* 1997;79:1381-1393.
31. **Fuller CE, Schmidt RE, Roth KA, et al.** Clinical utility of Fluorescence in situ hybridization (FISH) in morphologically ambiguous gliomas with hybrid oligodendroglial/astrocytic features. *J Neuropathol Exp Neurol.* 2003; 62:1118-1128.
32. **Shaw EG, Scheithauer BW, O'Fallon JR.** Supratentorial Gliomas: a comparative study by grade and histologic type. *J. Neurooncol.* 1997; 31:273-278.
33. Central Brain Tumor Registry of the United States. *Statistical Report: Primary Brain Tumors in the United States, 1995-1999.* Chicago, IL: Central Brain Tumor Registry of the United States; 2002.
34. **Bailey P, Cushing H.** *Tumors of the Glioma Group.* Philadelphia, PA: Lippincott; 1926.
35. **Bailey P, Bucy PC.** Oligodendrogliomas of the brain. *J Pathol Bacteriol.* 1929; 32:735-751.
36. **Reifenberger G, Kros JM, Burger PC, et al.** Oligodendroglioma. In: Kleihues P, Cavenee WK, eds. *Pathology and Genetics of Tumours of the Nervous System.* 2<sup>nd</sup> ed. Lyon, France: IARC Press; 2000:56-61. *World Health Organization Classification of Tumours.*
37. **Mork SJ, Halvorsen TB, Lindegaard KF, et al.** Oligodendroglioma: histologic evaluation and prognosis. *J Neuropathol Exp Neurol.* 1986; 45:65-78.
38. **Burger PC, Rawlings CE, Cox EB, et al.** Clinicopathologic Correlations in the oligodendroglioma. *Cancer.* 1987;59:1345- 1352.
39. **Sandra H. Bigner<sup>2</sup>, B.K. Ahmed Rasheed, Rodney Wiltshire, Roger E. McLendon** neuro-oncology . Morphologic and molecular genetic aspects of oligodendroglial neoplasms<sup>1</sup>*Neuro-Oncology* 1, 52-60, 1999



40. **Rawlings CE, Giangaspero F, Burger PC, et al.** Ependymomas: A Clinicopathologic study. *Surg Neurol*, 1988; 29: 271-281.
41. **Shaw E.G, Evans R.G, Scheithauer B.W, et al.** postoperative Radiotherapy of ependymomas in pediatric and adult patients. *Int. Radiat Oncol Biol Physio*, 1987; 13:1457-1462
42. **Nutt CL, Betensky RA, Brower MA, et al.** YKL-40 is a differential diagnostic marker for histologic subtypes of high-grade gliomas. *Clin Cancer Res*. 2005; 11:2258-2264.
43. **Haapasalo J, Mennander A, Hellen P, et al;** Ki67 immunostaining in frozen sections interpretation of gliomas. *J. clin. pathol*, 2005; 58:263-268.
44. **Burger PC, Shibata T, Kleihues P et al.** 18F-fluoro-2'-deoxyuridine as a tracer of nucleic acid metabolism in brain tumors. *J Neurosurg*. 1990; 72: 110-3.
45. **Janus T.J, Kyritsis A.P, Forman A.D & Levin V.A.** Biology and treatment of gliomas. *Annals of Oncology* 1992; 3: 423-433.
46. **Nutt CL, Mani DR, Betensky RA, Tamayo P, Cairncross JG, Ladd C, Pohl U, Hartmann C, McLaughlin ME, Batchelor TT, Black PM, von Deimling A, Pomeroy SL, Golub TR and Louis DN:** Gene expression-based classification of malignant gliomas correlates better with survival than histological classification. *Cancer Res* 63:1602-1607, 2003.
47. **Ahmed Idbaih<sup>1</sup>, Yannick Marie<sup>2</sup>, Gaëlle Pierron<sup>3</sup>, Caroline Brennetot<sup>1</sup>, Khê Hoang-Xuan<sup>2</sup>, Michèle Kujas<sup>4</sup>.** Two types of chromosome 1p losses with opposite significance in gliomas. *Ann Neurol*. 29 August 2005, vol. 58, p. 483-487.
48. **Daumas-Duport, C, Scheithauer, B, O'Fallon, J, Kelly, P.** Grading of astrocytomas. A simple and reproducible method. *Cancer* 1988; 62: 2152-2165. 210.

7.01. **APPENDIX 1**

**IMMUNOHISTOCHEMICAL GRADING OF GLIOMAS AND CLINICO-RADIOLOGIC CORRELATIONS AT KENYATTA NATIONAL HOSPITAL.**

Proforma form

**Information on request form (part a)**

Accent number: .....

Study Number: .....

Name:..... Age: / \_\_\_\_ / \_\_\_\_ / years.

Sex: 1. Female 2. Male Date: / \_\_\_\_ / \_\_\_\_ / \_\_\_\_ /

I/P NO: \_\_\_\_\_

Occupation: \_\_\_\_\_ (state)

Radiological diagnosis \_\_\_\_\_

Surgical diagnosis \_\_\_\_\_

**Intraoperative information**

Site: (tick)

Spinal ( )

Cerebellopontine angle ( )

Spinal nerve roots ( )

Cauda equina ( )

CNS parenchyma ( )

Frontal \_\_\_\_\_ ( ) \_\_\_\_\_

1. Parietal \_\_\_\_\_ ( ) \_\_\_\_\_

2. Temporal \_\_\_\_\_ ( ) \_\_\_\_\_

3. Posterior cranial fossa \_\_\_\_\_ ( ) \_\_\_\_\_

4. Mid-brain \_\_\_\_\_ ( ) \_\_\_\_\_

Para ventricular ( )

Dural attachment Yes ( ) No ( )

Description of the lesion

**Histological information (part b)**

Tumor size: / \_\_\_\_\_ / mm

Color: \_\_\_\_\_

Consistency: \_\_\_\_\_

Cut surface: \_\_\_\_\_

Amount of tissue processed: \_\_\_\_\_

**HISTOLOGICAL REPORT**

**Immunohistochemistry**

Antibody                      +positive                      ++positive                      +++positive

Glial fibrillary protein: \_\_\_\_\_

Ki67: \_\_\_\_\_

***Diagnosis:*** \_\_\_\_\_

Grade: \_\_\_\_\_

Signature: \_\_\_\_\_

Pathologist \_\_\_\_\_

## 7.01 APPENDIX II

Immunohistochemistry was carried out using Avidin-biotin-peroxidase complex methods on all the slides. The primary antibodies used for this study were Ki-67 (DAKO, 1:1000 dilution) and glial fibrillary protein (GFAP, DAKO, 1:350 dilution). Five-micrometer thick sections from tissue blocks are placed onto 1-lyse coated slides. After air-drying, the tissue sections are deparaffinised and rehydrated before immunostaining. Antigen retrieval is performed by heating tissue sections in a microwave oven before immunostaining. Microwave oven retrieval was performed by continuous heating for 6 minutes at 20% power of 800-watt microwave oven. GFAP does not require antigen retrieval. For all immunostains, endogenous peroxidase activity was blocked by 3% hydrogen peroxide for 5 mins at room temperature. A protein block was also performed according to package instructions. Those slides requiring microwave oven pretreatment received Avidin-biotin blocking agents. All primary antibodies are raised against human antigens. Antibodies were diluted with primary antibody diluent (DAKO), and the presence of relevant antigens was detected with diaminobenzidine (DAB) according to package instructions.

**7.02. Standard operating procedures in immunohistochemistry**  
**Avidin biotin peroxidase method.**

1. Dewax sections and transfer to 100% alcohol.
2. Block endogenous peroxidase with 0.5% hydrogen peroxide in methanol - 30 minutes.
3. Place in tris-saline buffer at 20°C.
4. Treat with 0.05% trypsin in tris-saline buffer containing 0.1% calcium chloride at 37°C (must be accurate). Add the trypsin to the rest after preheating and just before use - 40 minutes.
5. Wash in several changes of tris-saline at 20°C.
6. Treat with P.B.S. containing 1% normal serum (P.B.S./N.S.) from the species the secondary was raised in - 2 x 5 minutes.
7. Treat with specific primary antibody diluted to the order of 1:100 to 1:250 for immunoglobulins or 1:250 to 1:500 for hormones with P.B.S./N.S. - 30 minutes in a damp chamber. It may be necessary to extend this period of incubation to 12-24 hours.
8. Wash in P.B.S./N.S. - 2 x 5 minutes.
9. Treat with secondary antibody (anti-(primary host)-IgG) diluted 1:40 with P.B.S. - 20 minutes.
10. Wash in P.B.S./N.S. - 2 x 5 minutes
11. Treat with peroxidase substrate solution...ethylcarbazole or D.A.B. - 5 minutes.

12. Rinse in distilled water.
13. Stain in Mayer's haematoxylin - 30 seconds.
14. Wash and blue in running water.
15. Mount in glycerine jelly or a suitable aqueous mountant. (For D.A.B. dehydrate in alcohol, clear in xylene or Histo-Clear<sup>®</sup> and mount in D.P.X.).

## CONTROLS

1. Omit the primary antibody by leaving grids in the wash/block solution at step 6, and continuing to step 8. (Checks the secondary and substrate).
2. Replace the primary antibody with another but inappropriate antibody. (Checks the primary).
3. Replace the primary antibody with normal (non-immune) serum obtained from the same animal as the primary. (Checks the primary).
4. Report the slides.

**Table of antibodies that were used.**

<u>Antibody</u>	<u>dilution</u>	<u>immunogen</u>	<u>Host</u>
Glial fibrillary protein1:	1000	bovine	rabbit

Ki 67

Immunohistochemical results were categorized based on number of positively stained slides, <10% +, 10-50% of tumor cells stained positive ++, 50-90% +++, and >90% +++++. Staining intensity was reported as light, moderate or high. Positive results were further evaluated for diffuse staining patterns, and the location of the stain either cytoplasmic or nucleus or cell surface.

## APPENDIX III

---

### 8.0.0 Tissue processing procedure.

Routine tissue processing was done as follows:

- **Fixation**, which starts immediately after surgery and continued after the trimming.
- **Dehydration** using increasing concentrations of alcohol.
- **Clearing** with xylene which is miscible with the embedding material (paraffin)
- **Infiltration** with an embedding material in the study paraffin was used.

An automatic tissue processor does all of the above process.

- **Embedding** was done manually by histotechnician so that tissue oriented properly in the tissue block.
- **Sectioning** was done with a microtome. Sections were floated in warm water to remove wrinkles and picked with a microscope slide. The slide was then kept in warm oven for fifteen minutes for Haematoxylin/Eosin but the step was avoided in Immunohistochemistry because it may damage the antigenic sites and poly-lysine coated slides were used instead.
- **Staining** was done for Haematoxylin/Eosin and immunostaining for Immunohistochemistry.
- **Reporting** of the slides was done by the researcher and confirmed by the supervisors.





**KENYATTA NATIONAL HOSPITAL**

Hospital Rd. along, Ngong Rd.  
P.O. Box 20723, Nairobi.

Tel: 726300-9

Fax: 725272

Telegrams: "MEDSUP", Nairobi.

Email: [KNHplan@Ken.Healthnet.org](mailto:KNHplan@Ken.Healthnet.org)

**Ref: KNH-ERC/ 01/3832**

**Date: 13<sup>th</sup> October 2006**

Dr. Makau Mbithi  
Dept of Human Pathology  
Faculty of Medicine  
University of Nairobi

Dear Dr. Makau,

**RESEARCH PROPOSAL: "IMMUNOHISTOCHEMICAL GRADING OF GLIOMAS AND THEIR CLINICORADIOLOGIC CORRELATIONS AT KNH".**

**(P139/6/2006)**

---

This is to inform you that the Kenyatta National Hospital Ethics and Research Committee has reviewed and **approved** revised version of your above cited research proposal for the period 13<sup>th</sup> October 2006 – 12<sup>th</sup> October 2007.

You will be required to request for a renewal of the approval if you intend to continue with the study beyond the deadline given.

On behalf of the Committee, I wish you fruitful research and look forward to receiving a summary of the research findings upon completion of the study.

This information will form part of database that will be consulted in future when processing related research study so as to minimize chances of study duplication.

Yours sincerely,

**PROF A N GUANTAI**  
**SECRETARY, KNH-ERC**

c.c. Prof. K.M.Bhatt, Chairperson, KNH-ERC  
The Deputy Director CS, KNH  
Dean, Faculty of Medicine, UON  
Chairman, Dept of Human Pathology, UON  
Supervisors: Dr. Emily Rogena, Dept of Human Pathology, UON  
Dr. Musau C. K., Dep. surgery, UON  
Prof D. Gatei, Dept of Human Pathology, UON