

(i)

" THE ROLE OF MYELOGRAPHY

IN

THE MANAGEMENT OF PATIENTS WITH SPINAL PATHOLOGY

AT

KENYATTA NATIONAL HOSPITAL "

A DISSERTATION SUBMITTED IN PART FULFILMENT

FOR THE DEGREE OF MASTER OF MEDICINE IN DIAGNOSTIC RADIOLOGY

UNIVERSITY OF NAIROBI

July, 1989

Dr. Christopher J. Arrumm

University of NAIROBI Library




0324872 1

MEDICAL LIBRARY
UNIVERSITY OF NAIROBI


DECLARATION

CANDIDATE: This Dissertation is my original work and has not been presented for a Degree in any other University.

SIGNED: 

Dr. C.J. ARRUMM M.B. ChB. (Nairobi).

SUPERVISOR: This Dissertation has been submitted for examination with my approval as the University Supervisor.

SIGNED: 

Dr. M.W. WACHIRA M.B.ChB., MMed,
Lecturer,
Department of Diagnostic Radiology,
College of Health Sciences,
University of Nairobi.

CONTENTS PAGE

TITLE & SUBMISSION	(i)
DECLARATION	(ii)
SUMMARY	1
INTRODUCTION	2
MATERIALS AND METHOD	5
RESULTS	9
(a) HISTOGRAM OF AGE & SEX DISTRIBUTION	10
(b) DISTRIBUTION OF COMMON PRESENTING SYMPTOMS	11
(c) MYELOGRAPHIC PATTERN OF SPINAL PATHOLOGY	12
(d) COMPARISON OF CLINICAL, MYELOGRAPHIC AND OPERATIVE FINDINGS IN THE LUMBAR SPINE	13
(e) COMPARISON OF CLINICAL, MYELOGRAPHIC AND OPERATIVE FINDINGS IN THE THORACIC SPINE	14
(f) COMPARISON OF CLINICAL, MYELOGRAPHIC AND OPERATIVE FINDINGS IN THE CERVICAL SPINE	15
(g) ILLUSTRATIONS	16
DISCUSSION	21
CONCLUSIONS	50
RECOMMENDATIONS	51
REFERENCES	53
ACKNOWLEDGEMENTS	57

APPENDIX (i) Data Collection form

SUMMARY

This is a prospective study to try and determine the role of myelography in the management of patients with spinal pathology at the Kenyatta National Hospital, (KNH) Nairobi. 60 patients referred to the X-ray Department, KNH between November 1987 and January 1989 have been included. The study has attempted to correlate the clinical, myelographic and surgical findings in the patients.

The study has shown that patients in the age group 30-39 years were referred more frequently for myelographic examination and that the commonest spinal pathology requiring myelographic examination is prolapsed intervertebral disc in the lumbar spine.

Suggestions have been given at the end of the study as a guideline for future myelographic examinations at KNH.

INTRODUCTION

Diseases of the nervous system may limit themselves to the spinal cord. A significant number of patients presenting with clinical features of spinal pathology are seen at the Kenyatta National Hospital, Nairobi (KNH) - the national referral hospital. Some of these patients require myelographic examination.

Low back pain syndromes with or without sciatica are some of the commonest medical problems. They are responsible for a significant number of working days lost due to ill health (BUIRSK G.). Other patients with spinal pathology may present clinically with paraparesis, quadriparesis, paraplegia, etc.

The early stages of damage to nerve tissue are reversible and some of the function may be regained. Severely damaged neurones do not recover. It is, therefore, most important to diagnose and treat spinal cord compression without delay. The role of the radiologist in the management of these patients is primarily to identify local abnormalities which will be amenable to surgical treatment. The frequent requests for myelographic examination of these patients prompted this study.

In Kenya the two non-invasive methods for investigating spinal pathology (Computerised Tomography "CT" and Magnetic Resonance Imaging "MRI") are not easily accessible to the patient. CT is available in private medical institutions in Kenya. It is not fully utilized because it is expensive to most patients and the

Kenyan doctor community is also still poorly informed about its capabilities. MRI is unavailable in Kenya.

At KNH myelography is the radiological examination of the spine after plain radiography. Myelography has evolved a lot since the technique of negative contrast myelography was pioneered by Dandy (in 1919 and 1925) and Jacobaeus in 1921. (WESTBERG G)

Positive contrast medium myelographic technique was introduced in 1922 by Sicard and Forestier using Lipiodol. In 1944, Ramsey, French and Strain introduced Pantopaque (Myodil) as an improved contrast medium for positive contrast myelography. Due to unsatisfactory results obtained by the above contrast media, water soluble contrast myelographic technique was introduced. The initial water soluble contrast media (Abrodil, Meglumine Iothalamate (Conray 280), and Meglumine Iocarmate (Dimer X)) were all abandoned soon after introduction due to high neurotoxicity and meningeal irritation. Amipaque (Metrizamide) was introduced in 1974 as a watersoluble, non-ionic contrast medium for myelography. It was found to be very unstable in solution and has now been replaced by omnipaque (Iohexol) and Iopamiro (Iopamidol).

In this study all the patients were examined using positive contrast myelographic technique. The study is aimed at:-

- Determining the age and sex distribution of the patients.
- Determining their clinical presentation
- Correlating the patients' clinical findings with the plain X-ray and myelographic findings

- Evaluating the subsequent management of the patients after myelographic diagnosis has been made
- Discussing the relative merits of myelography in the management of the patients and proposing a possible protocol that could be used in the radiological investigation of patients with similar problems in future

MATERIALS AND METHOD

Myelographic examination was done on 60 patients in this study between October 1987 and January 1989. The patients were referred to the X-ray Department from within KNH and other hospitals in Kenya.

Prior to booking any patient for myelography the patient's X-ray request form was scrutinized for details of the clinical presentation, and the plain X-ray films reviewed for the presence of any abnormality. In cases where there was doubt as to whether the examination would be useful in the management of the patient, the clinical details of the patient were discussed with the referring doctor prior to booking.

The referring clinicians were advised to admit the patient's on the eve of the examination in order to:-

- (a) Discuss the examination with the patients and allay their anxiety.
- (b) Ensure proper hydration of the patients so as to minimise chances of adverse reactions to contrast media.

The patients were allowed a light breakfast on the morning of the examination. Examinations were done in the mornings to minimize patient anxiety. No premedication was prescribed.

The radiographic equipment which was used in this study included a standard radiography-fluoroscopy room consisting of:-

- (a) A tilting table able to tilt to 45° (Trendelenberg's position) and 90° (upright).
- (b) Image intensification system.

The myelographic contrast medium was introduced in the sub-arachnoid space via lumbar puncture. Lumbar puncture was done in the X-ray department, with the patient in sitting position or lateral decubitus position.

Lumbar puncture was done using disposable lumbar puncture needle gauge 21 s.w.g. The disposable needles were preferred because:-

- (a) They were sharp and made approach easy.
- (b) The risks of transmission of diseases such as hepatitis and AIDS were reduced.

The puncture was considered successful if the CSF flow obtained was an uninterrupted flow. The contrast medium was then introduced. 58 patients out of the total of 60 patients, were examined using non-ionic water soluble contrast media (IOHEXOL or IOPAMIDOL). The remaining 2 patients were examined using myodil which had been injected by referring clinicians unaware of the availability of the water soluble contrast media.

The majority of the patients in this study were adults and the doses of contrast medium used were:-

(a) IOHEXOL (Omnipaque)

- Lumbar and Thoracic (Lumbar Injection)

(i) 10-15ml of 180mgI/ml concentration

(ii) 8-12ml of 240mgI/ml concentration

- Cervical (Lumbar Injection)

(i) 10-12ml of 240 mgI/ml concentration

(ii) 7-10ml of 300mgI/ml concentration

- Children (over six years old)

(i) 6-12ml of 180mgI/ml concentration

(b) IOPAMIDOL (Iopamiro)

(i) 5-15ml of 200-300mgI/ml concentration

After the injection of contrast medium, the needle was withdrawn and the injection site was sealed and dressed. The following radiographic projections were then done:-

(a) In prone position

- anteroposterior
- right and left obliques
- lateral shoot through

(b) In erect position

- posteroanterior
- right and left obliques
- lateral

The referring clinicians were advised to retain the patients in the ward for 24 hours after myelography. This was done in order to monitor the patients for any adverse reactions to the examination.

The radiographs were discussed with the supervisor of the project and the referring clinician prior to giving the report. The patients were followed up to ascertain the final diagnosis and management.

RESULTS

The results obtained in this study are presented in the form of the following tables 1 - 6.

TABLE 1: HISTOGRAM OF AGE AND SEX DISTRIBUTION

KEY

MALE

FEMALE

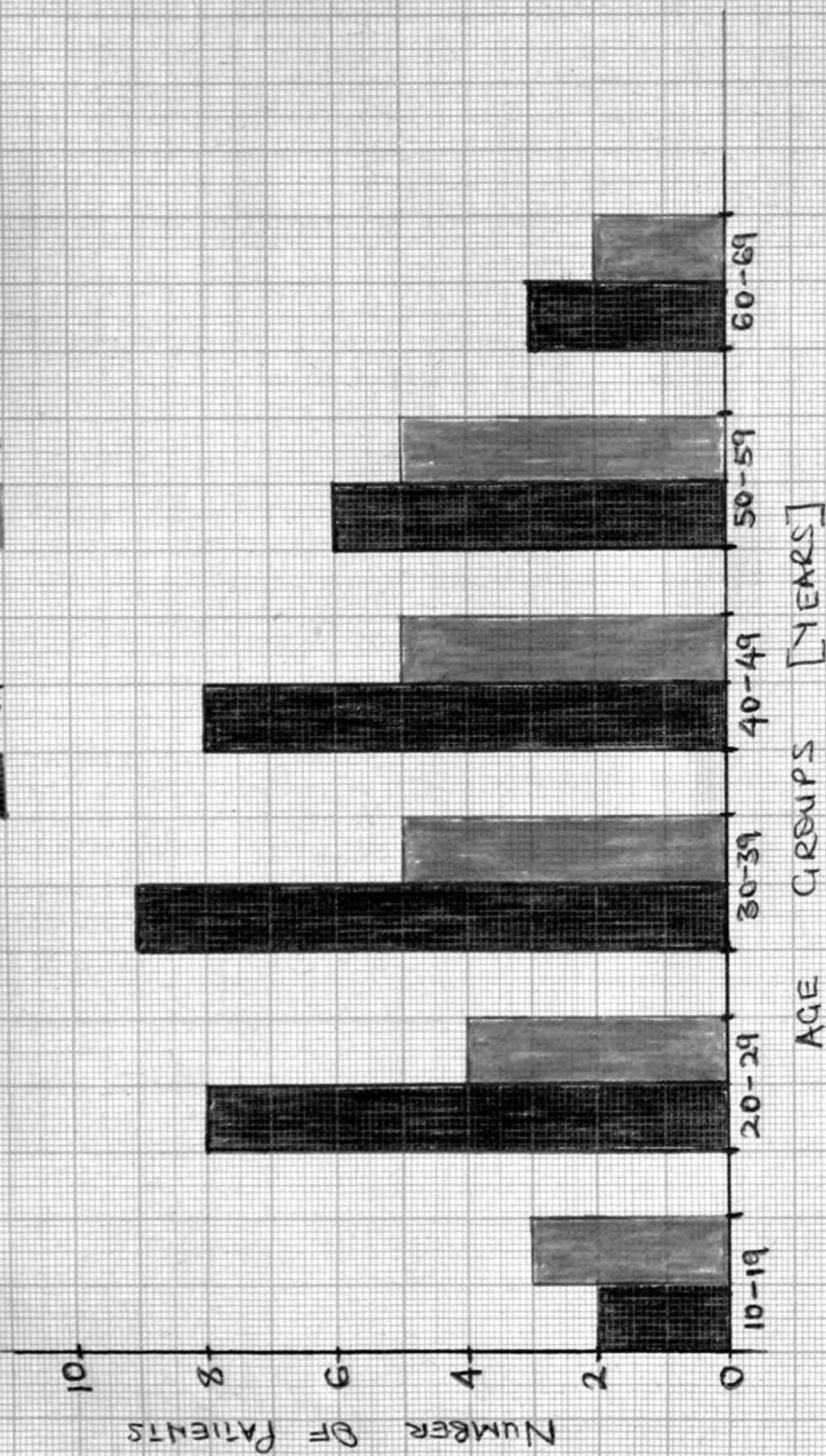


TABLE 2

DISTRIBUTION OF COMMON PRESENTING SYMPTOMS

SYMPTOM	NO OF PATIENTS
Low Back Ache	38
Sciatica	22
Paraparesis	20
Paraplegia	3
Quadriplegia	1
Root pain in upper limbs	6
Sphinteric Incontinence	4

NB: (Some patients presented with more than one symptom)

TABLE 3

MYELOGRAPHIC PATTERN OF SPINAL PATHOLOGY

MYELOGRAPHIC DIAGNOSIS	NUMBER OF PATIENTS
Normal	24
Lumbar Prolapsed Intervertebral Disc	16
Neoplasms	8
Lumbar Spondylosis	7
Cervical Spondylosis	3
Chronic Infection (Granuloma)	1
Syringomyelia	1
Total	60

TABLE 5: COMPARISON OF CLINICAL, MYELOGRAPHIC AND OPERATIVE FINDINGS IN THE THORACIC SPINE

CLINICAL AGNOSIS	NO. OF PATIENTS	MYELOGRAPHIC FINDINGS			OPERATIVE FINDINGS	NO. PATIENTS NOT OPERATED ON
		Normal	Neoplasm	Neoplasm	Other Findings	
Paraparesis	8	6	2	1	-	7
Paraplegia	3	1	2	-	-	3
	11					

TABLE 6: COMPARISON OF CLINICAL, MYELOGRAPHIC AND OPERATIVE FINDINGS
IN THE CERVICAL SPINE

CLINICAL DIAGNOSIS	NO OF PATIENTS	MYELOGRAPHIC FINDINGS			OPERATIVE FINDINGS			NO. OF PATIENTS NOT OPERATED ON
		Normal	Spinal stenosis	Intramedullary tumour	Syringo myelia	Spinal stenosis	other findings	
Quadripareisis	1	-	-	-	1	-	-	1
Heniparesis	1	-	-	1	-	-	-	1
Cervical spinal cord compression	4	4	3	-	-	3	-	1
	6							

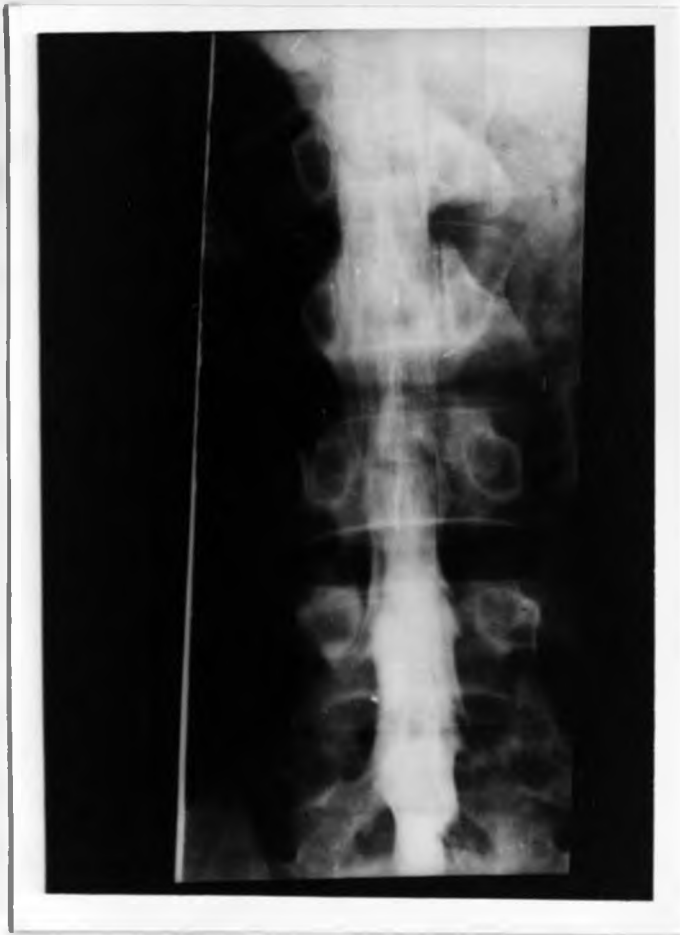

FIGURE 1

DEMONSTRATION OF A NORMAL
LUMBAR RADICULOGAM USING
WATER-SOLUBLE CONTRAST
MEDIUM - ANTEROPOSTERIOR VIEW

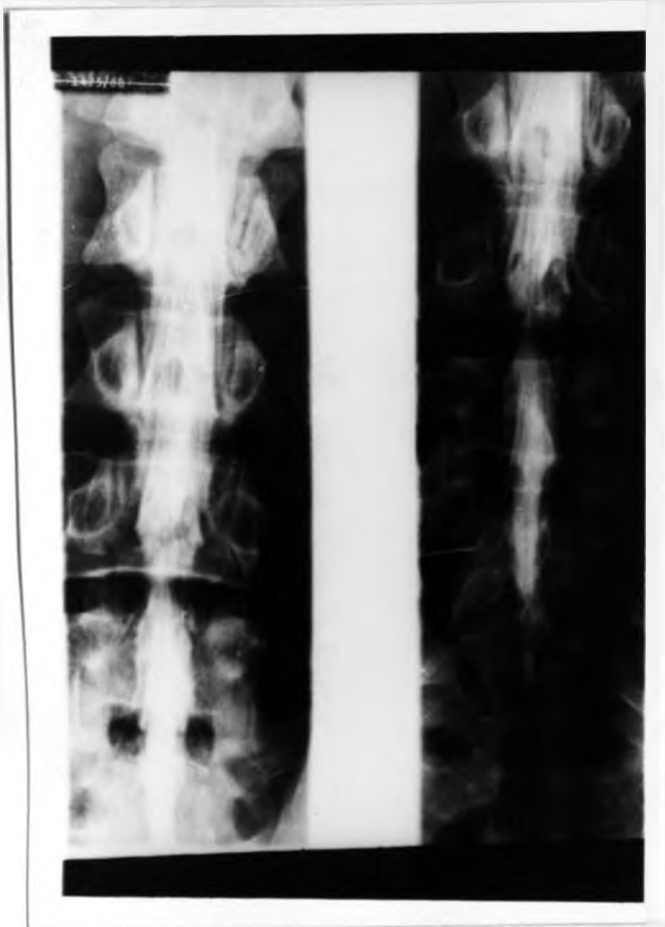

FIGURE 2

LUMBAR RADICULOGAM
ANTERO-POSTERIOR VIEW
DEMONSTRATING A PROLAPSED
INTERVERTEBRAL DISC AT
THE DISC SPACE L4/L5

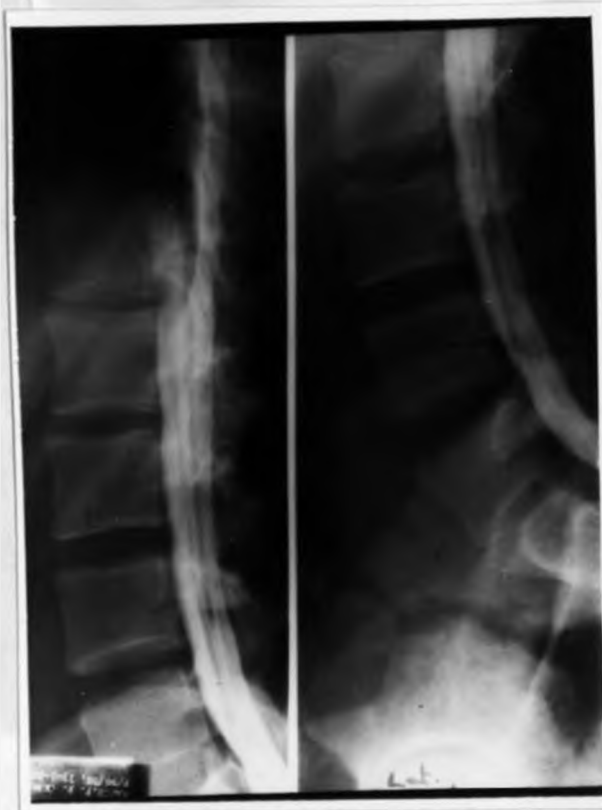

FIGURE 3 (i)

LUMBAR RADICULOGRAM LATERAL HORIZONTAL
VIEW SHOWING NO DEFINITE LESION

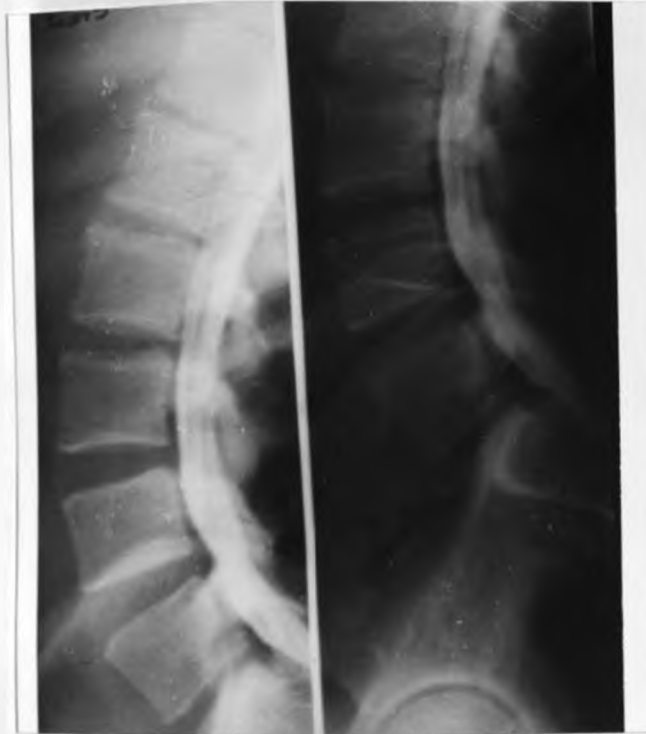

FIGURE 3 (ii)

LUMBAR RADICULOGRAM [SAME PATIENT AS IN 3(i)]
LATERAL ERECT VIEW SHOWING PROLAPSED DISC AT L4/L5

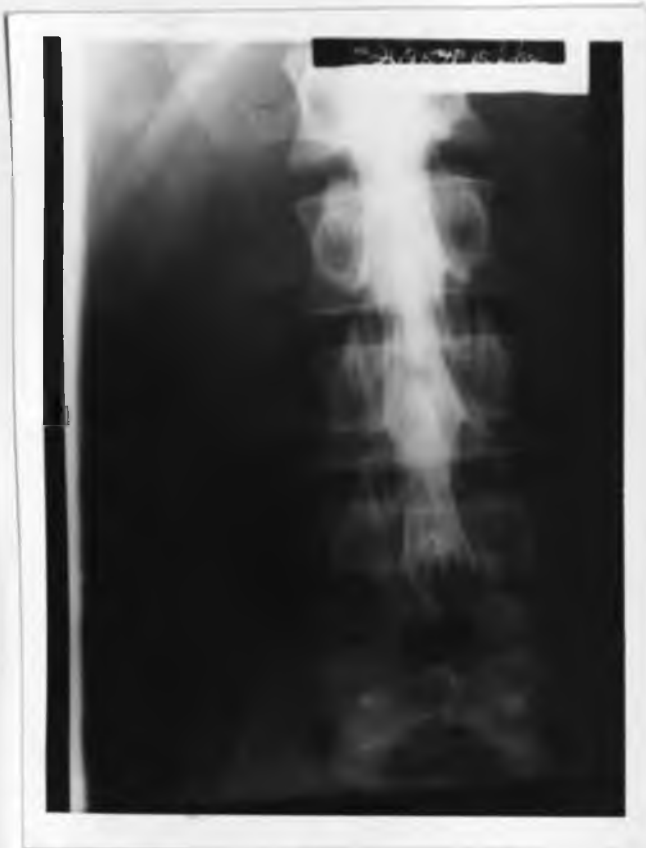

FIGURE 4 (i)

LUMBAR RADICULOGAM ANTEROPOSTERIOR VIEW
DEMONSTRATING A COMPLETE CUT-OFF AT L4/L5 DISC SPACE

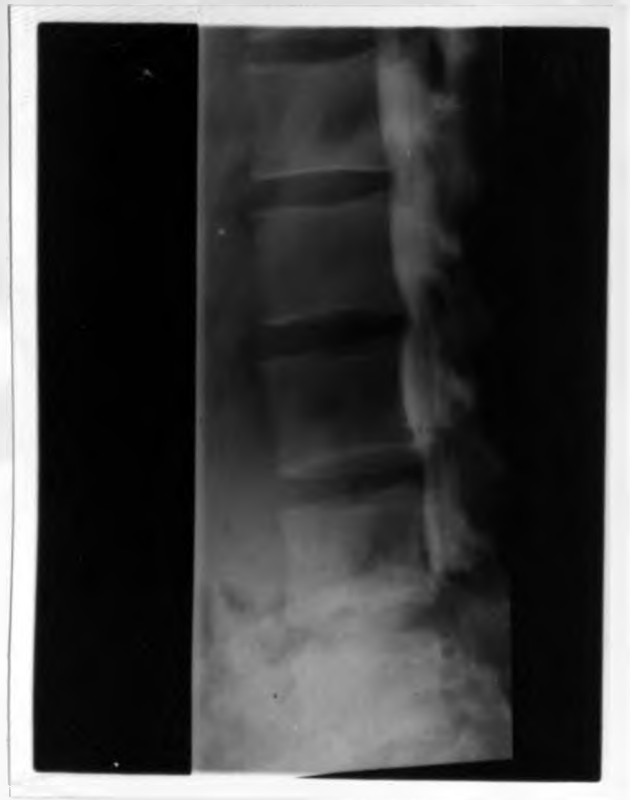

FIGURE 4 (ii)

LUMBAR RADICULOGAM LATERAL VIEW [SAME PATIENT AS IN 4(i)]

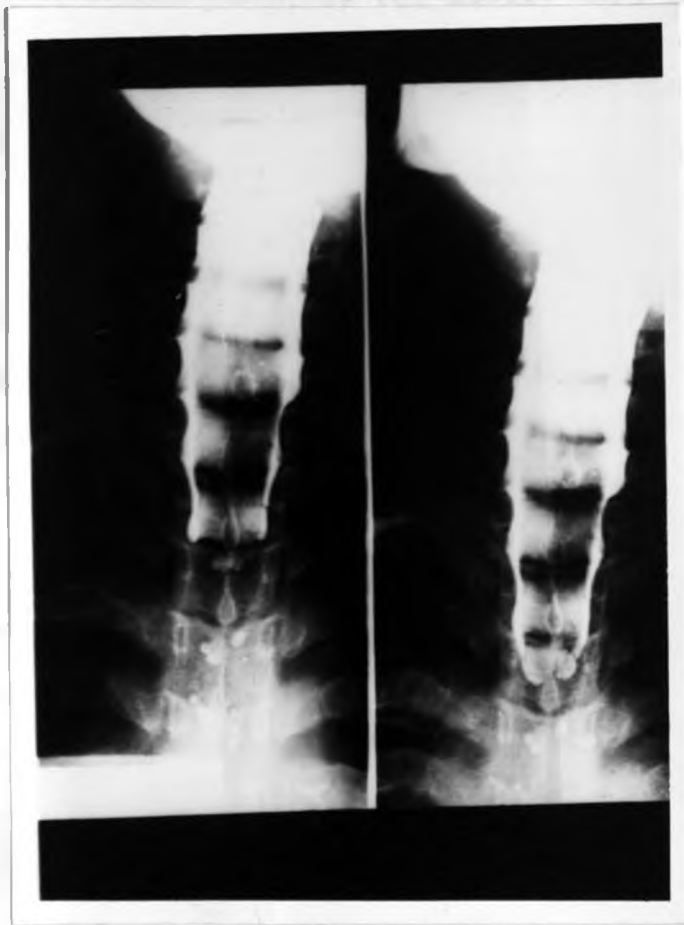

FIGURE 5

CERVICAL SPINE MYELOGRAM USING MYODIL
DEMONSTRATING WIDENING OF THE CERVICAL
CORD AND SPREADING OF THE LATERAL MARGINS

DISCUSSION

In the appraisal of a myelographic study the anatomy of the spinal cord, nerve roots, and subarachnoid spaces is important. In order to differentiate normal variations from minimal pathologic abnormalities it is necessary to carefully analyse:

- (a) The normal dimensions of the spinal cord at all levels.
- (b) The variations in the configuration of the subarachnoid space.
- (c) The size and integrity of the bony canal.

AT KNH prior to 1987 myelographic examinations were performed using myodil as the contrast medium. No previous records or studies are, however, available to indicate details of the incidence and pattern of spinal cord diseases at KNH.

Myelography is the radiological visualization of the spinal cord, cauda equina and the surrounding subarachnoid space. The technique was originally applied to demonstrate complete obstructions in the spinal theca. With improvement of X-ray machines and contrast media, the demand and scope for myelographic examinations became greater.

In this study the method of choice for myelography was by water-soluble contrast media injected via lumbar puncture. 58 patients were examined using water-soluble contrast media. The remaining two had myodil injection due to lack of information of the referring clinicians. Some workers still use iodized oil in

patients whose clinical level of involvement is uncertain or in whom involvement of several levels is expected. These workers argue that since these groups of patients may require detailed myelography of the entire spine, it may be difficult to examine the patients with water soluble contrast medium. This fear has been overcome, however, with more practice and faster examination methods using water soluble contrast media. The newer water-soluble agents have completely replaced myodil for all cauda equina, lumbosacral radiculography, and lumbar myelography. Water soluble media are the contrast media of choice for most dorsal myelography and for cervical myelogram. [WHITEHOUSE G.H. & WORTHINGTON B.S.]

The advantages and disadvantages of the new water soluble media as compared to myodil oil and gas myelography are set in the table below:

Gas	Cheap, low-density, and -irradiation of soft-tissue contrast	Very toxic and slow contrast
Oil	High density and -irradiation of soft-tissue contrast	Slow contrast
Water soluble	High density and -irradiation of soft-tissue contrast	Fast contrast

CONTRAST MEDIUM	ADVANTAGES	DISADVANTAGES
Water-Soluble - Iopamidol - Iohexol	Optimal visualization of spinal cord, cauda equina, nerve roots, subarachnoid space. (Preferred method)	Expensive - cervical myelography is rather difficult
Oil - myodil	Sometimes easier technique. Repeatable after single injection No acute toxicity. Total myelography possible	Poor visualization of nerve roots. Suboptimal visualization of spinal cord and subarachnoid space. Delayed arachnoiditis.
Gas - Air - Oxygen - CO ₂	Cheap. Non-toxic. Good visualization of varying cord size - "collapsing" cord	Nerve roots not seen. Difficult, time consuming technique. Poor radiographic contrast. Rarely used.

TABLE ADAPTED FROM: WHITEHOUSE G.H. & WORTHINGTON B.S.

In this study at myelography, particular attention was paid to defining the location of the lesion and the characteristics of

the lesion. In order to do this it was necessary to consider the characteristics of the normal myelogram first.

In a normal myelogram a striking and constant feature of the thecal column as seen in the anteroposterior view is symmetry. Variations occur in its shape, width and length. There are two main types of column, a cylindrical column of even tubular form, and a much less commonly a ringed column with zones of constriction between the levels at which successive pairs of nerve roots emerge. [BEGG A.C., FAULKNER M.A., MCGEORGE M.]

The width of the thecal column may vary from 30-80% of the interpedicular distance. Its depth may also vary. These variations are not directly related to the sex or build of the patient. Generally the thecal column extends as far down as the second piece of the sacrum. Occasionally it may terminate as high as the inferior margin of the fifth lumbar vertebra. When this occurs the root pouches of the sacral nerves are often large and fill well, and consequently the effects of a protrusion of the lumbosacral disc may still be appreciated. [BEGG A.C., FAULKNER M.A., MCGEORGE M.]

The outline of the root pouches also are usually symmetrical in the normal myelogram. The degree to which the root pouches fill varies considerably. Certain factors affect the filling, of which time, gravity, and the posture of the patient are most important. Thus if the radiological examination is made immediately after the injection of contrast medium only the orifices of the root pouches may be demonstrated. If the examination is

delayed a little the sacral root pouches are usually filled in their entirety. When filled completely, each root pouch shows as a uniformly dense shadow 3 to 4mm wide, passing downward and outwards from the main thecal column. If the layer of contrast medium between the nerve-root and the arachnoid is thin, the root pouch may show in the myelogram as two linear streaks with a clear zone between, representing the nerve root. More frequently where filling is irregular, the opaque medium may appear as a single streak lying medial or lateral to the nerve root. Often, the root pouches do not fill with contrast medium, in which case their orifices are indicated by small projections along the lateral edge of the thecal column. [BEGG A.C., FAULKNER M.A., MCGEORGE M.]

Dorsal and cervical water soluble myelography are simple extensions of the lumbo-sacral myelography. However, special views at exposure are necessary in the cervical spine due to the overlying shoulder joints and the mandibles.

In a myelographic study the lesions may be grouped as extradural, intradural/extramedullary or intramedullary according to their characteristics. In evaluating a myelogram, however, one must always remember that lesions of another kind yield identical patterns in a given location and relationship to the cord and spine. For example, a glioma cannot be differentiated from a syringomyelia, or a peridural tumour from a granuloma in the same site. In such cases, as always, history and clinical examination must be the guide to diagnosis. It should be noted also that at times myelographic features may be atypical e.g.

(a) amorphous images which are pathologically meaningless

(b) patterns from which diagnostic deductions may be

drawn but at operation or necropsy prove to be

mistaken. [LOMBARDI G. & PASSERINI A.]¹

It is necessary to stress that in the majority of cases the diagnosis is not confirmed by the results of the operation or necropsy.

Considering the set up of the disease, it is evident that the clinical picture is not always typical and that the diagnosis is often difficult.

The patients who were operated upon were 20-25 years, 25-30 years and 30-35 years. This can be explained on the basis that the disease is not infrequently associated with intervertebral disc disease.

The following symptoms and signs were observed:

- (1) Prolapsed intervertebral disc and lumbar spondylitis
- (2) Lesions of the lumbar spine
- (3) Lesions of the thoracic spine
- (4) Spondylitis
- (5) Spontaneous fracture of the spinal canal
- (6) Intervertebral disc disease
- (7) Spondylitis
- (8) Cervical spondylitis

AGE AND SEX DISTRIBUTION

60 patients were examined in this study. The age range was 13-65 years. This possibly explains why congenital abnormalities do not feature in the pattern of diseases diagnosed, as the majority of patients were adults with acquired diseases.

The male to female ratio was 1.5:1. Considering the set up of KNH in an urban area where there are more males than females the ratio in the study cannot be said to be true of the whole country.

The commonest age groups afflicted were 20-29 years, 30-39 years and 40-49 years. This can be explained on the basis that the commonest indication for myelography was prolapsed intervertebral disc which also occurs more commonly in those age groups.

The patients' presenting symptoms and myelographic findings are discussed below under the subheadings:

- (a) Presenting symptoms
- (b) Lumbar Prolapsed Intervertebral Discs and Lumbar Spondylosis
- (c) Tumours in the lumbar spine
- (d) Granuloma in the lumbar spine
- (e) Meningioma
- (f) Metastatic Tumours of the spinal canal
- (g) Intramedullary neoplasms
- (h) Syringomyelia
- (i) Cervical spondylosis

(a) PRESENTING SYMPTOMS

The commonest presenting symptom was low backache. In this study 38 patients gave this either as the only complaint or presenting together with other symptoms. Low backache is a symptom in which the clinician often has to depend on the patient's description which may not be altogether accurate.

[HARRISON'S PRINCIPLES OF INTERNAL MEDICINE]

In this study 23 patients with low backache had myelography done on them on the basis of worsening symptomatology, without positive clinical signs.

In 16 of these patients the myelographic examination was normal and the patients were managed conservatively. The myelographic examination therefore did not alter the patient's previous management. It is noted in literature [DILLAN J.B., FRY J., KALTON E.] that 90% of cases of acute back pain need only symptomatic treatment, and only 10% have symptoms or signs of nerve root lesions. Neuroradiological investigation is required only in those patients with persistent back and leg pain unresponsive to proper conservative treatment, and in patients with abnormal neurology [GRAINGER R.G. & ALLISON D.J.].

Since most of these patients with low backache were referred from outpatient clinics, it is necessary to emphasize the need of careful evaluation of the patients. The evaluation should include adequate conservative management prior to requesting for myelography if there are no positive clinical signs.

The other clinical symptoms found in this study included:- sciatica (in 22 patients), paraparesis (in 20 patients), paraplegia (in 3 patients) quadriparesis (in one patient), root pain in upperlimbs (in 6 patients) and sphincteric incontinence (in 4 patients). These symptoms are more indicative of spinal cord or nerve root lesions and most of these patients had abnormalities demonstrated at myelography.

Prior to myelographic examination the patients symptoms must be well defined. The symptoms must also be correlated to the findings on physical examination and plain radiography. This is because several other conditions can present with similar symptomatology but myelography might not be indicated as e.g. in rheumatoid arthritis, collagen vascular diseases, diabetes mellitus e.t.c.

The history of trauma prior to spinal pathology symptomatology especially low backache is of questionable significance as noted by Dillane et al [DILLANE J.B., FRY J., KALTON E.]. The study considered two communities in London (with an upper socio-economic class mainly) and in Merseyside (with a higher manual labour population). The symptomatology of low backache was higher in the London community 57% of the males as compared to 29% of the males in Merseyside.

In this study 7 out of the 60 patients gave a history of trauma prior to the onset of their symptoms. 6 of these patients had myelography done for suspected prolapsed intervertebral discs.

The remaining one patient presented with paraplegia following a bicycle accident. On examination this patient was diagnosed to have a spinal granuloma due to brucellosis. Both this study and the study by Dillane et al therefore indicate that few patients with spinal pathology symptomatology give a history of trauma.

(b) PROLAPSED INTERVERTEBRAL DISCS AND LUMBAR SPONDYLOSIS

The intervertebral discs lie between each two vertebral bodies from cervical vertebral body 2 to sacral vertebra 1. It is composed of fibrocartilage, with a gelatinous central matrix known as the nucleus pulposus. It is firmly attached to adjoining vertebral bodies.

Degeneration of the intervertebral disc complex begins early in life. It is a consequence of a variety of environmental factors as well as normal aging. [Modic M.T. and associates]

The sequelae of disc degeneration remains among the leading causes of functional incapacitation in both sexes and are an all-too-common source of chronic disability in the working years. [Modic M.T. et al] The diagnosis and proper location of the affected disc(s) is important since some of these patients can be effectively managed surgically.

Disc prolapse is the extrusion of the nucleus pulposus into the spinal canal through a laceration of annulus fibrosus. In this study 39 patients were referred for lumbar myelography with clinical diagnosis of prolapsed intervertebral disc. Myelography demonstrated prolapsed intervertebral disc in 16 patients and lumbar spondylosis in 7 patients. Lombardi and Passerini in a retrospective study of 701 patients with degenerative lumbar disease showed that the patients with prolapsed intervertebral disc were 669 and those with lumbar

spondylosis were 32. [Lombardi G. & Passerini A.]²

The results first show that clinically there are more patients with lumbar spinal pathology requiring myelography as compared to the other regions of the spine. Secondly the results show that prolapsed intervertebral disc is the commonest lumbar pathology requiring myelography.

In this study the majority of patients with myelographic diagnosis of prolapsed intervertebral disc either had a posterocentral or posterolateral disc prolapse. The most frequent site of prolapse was the L4/L5 level which is also indicated by Holman C.B. In literature it is noted that most disc prolapses occur backwards.[Duckworth]

The posterior ligament in the midline tends to direct the material posterolaterally where it may press on the nerve root in the foramen, and cause root symptoms and signs. Rarely a true central posterior prolapse may occur causing pressure on the spinal cord or central roots of the cauda equina. In these patients severe paralysis may occur, with disturbed bladder function. [Duckworth T.] Disc prolapse can occur through the endplate into the vertebral body. This may produce acute low back pain and eventually a translucent area close to the disc on X-ray - a so called "Schmorl's Node." Disc prolapse may occasionally be through the anterior portion of the annulus fibrosus.[Holman C.B.]

In this study the age range of patients with myelographic diagnosis of prolapsed intervertebral disc was 19 years - 57 years. The average age was 36.7 years. In literature it is noted that intervertebral disc prolapse tends to occur in the earlier age groups - usually between 30 - 45 years. [Duckworth T.] Prolapsed intervertebral disc also occurs outside these age limits not infrequently.

Myelography on patients with suspected prolapsed intervertebral disc was done both in the prone and erect positions. This is due to the observation that in the erect position compression of the disc will accentuate the herniation, and on the radiograph exposed in this position an anterior thecal deformity will be seen. [Pilling J.R.]

Only 7 out of the patients with myelographic diagnosis of prolapsed intervertebral disc had surgery. The majority being managed conservatively. It is, therefore, not possible in this study to correlate fully the myelographic and operative findings. However, of the 7 patients who were operated on - prolapsed intervertebral disc was confirmed in 6 patients. The other patient had a congenital abnormality of the nerve roots [Figure 4] Pau et al describes similar findings of coiled and elongated nerve roots in patients with cauda equina syndrome. [Pau A. Sehrbunt Viale E., Turtas S., and Viale G.L.]

Cook P.L. and Wise K. in their study and review of literature indicate that the accuracy of water soluble contrast media in diagnosing prolapsed intervertebral disc as correlated with operative findings is 90% or over.

[Cook P.L and Wise K.]

The meaning of lumbar spondylosis is not precise. It is variably referred to by different authors as arthrosis, osteoarthritis, osteophytosis, spondylochondrosis, spondylosis deformans, hypertrophic spondylitis, etc. There is also confusion as to the classification, the way it is formed and the way it acts. The fundamental features of the disease are narrowing of one or more intervertebral discs, formation of osteophytes and protrusion of the discs. [Lombardi G. and Passerini A.]³

Multiple factors are thought to participate in the etiology of disc degeneration including autoimmune, genetic, reabsorption and biochemical. [Modic M.T. et al] Initially narrowing of the disc, osteophytosis and protrusion may appear as isolated, circumscribed lesions. As time goes on, the rate of advance varying with the subject, they tend to spread to the whole spine. [Lombardi G. & Passerini A.]⁴ In this study the age range of patients with lumbar spondylosis was 38-60 years. The average age was 52 years. Lombardi's study showed an average age of 49 years [Lombardi G. & Passerini A.]⁵

Degenerative arthritic changes in the lumbar region offer difficulty in interpretation because the posterior hypertrophic ridging of the margins of the vertebral bodies indent the anterior portions of the thecal sac, at the involved interspaces. These cause extradural deformity similar to that produced by herniated disc. Usually the differentiation can be made on the basis of the bilaterality of the indentation as seen on the anteroposterior projection. The appearance is usually that of an hour glass deformity, with the narrow waist opposite the interspace as a consequence of the ridge having displaced the sac posteriorly [Holman C.B.]

In this study all the patients diagnosed as having lumbar spondylosis were managed conservatively.

(c) TUMOURS IN THE LUMBAR SPINE

In this study 3 patients presented clinically with paraparesis and were investigated for pathology in the lumbar spine. Correlation of clinical, myelographic and histopathological findings diagnosed neurofibromatosis in two of the patients. Both were young males aged 22 years and 25 years respectively. Both had multiple tumours located intradurally and extradurally.

In Lombardi's study 90 neurofibromas were operated on in 87 patients. [Lombardi G. & Passerini A.]⁶

One of the patients had two tumours and another one had three tumours. Of the 90 tumours, 60 were intradural, 25 intraextradural and 5 extradural.

In another study by Epstein, 22 patients with intraspinal neurofibromas were analysed. [Epstein B.S.] Nineteen out of the 22 patients had single tumours. Three patients had multiple tumours.

The two studies therefore indicate multiple tumours of neurofibroma in a patient are less common than single tumour. In Epstein's study the patients with multiple tumours had associated generalized neurofibromatosis.

Lombardi's study notes that neurofibromas may develop at any age. The fifth and sixth decades of life were the periods of highest frequency. The study also showed a predominance of males to females. It also found that the tumours were diffusely distributed along the whole length of the spinal column and showed no preference for any site. [Lombardi G. & Passerini A.]⁶

In one of the two cases of neurofibromatosis in this study a dumb-bell tumour was demonstrated in one patient. Dumb-bell tumours develop asymmetrically. The intraspinal part may be relatively small whereas the extraspinal part may grow to a considerable size. In Lombardi's study dumb-bell tumours were found to be practically associated with bone changes in plain X-rays e.g. widening of intervertebral foramen. The neurological signs may not be in proportion to the bone changes. As a rule, this type of tumour is reported to be limited to one vertebra. [Lombardi G. & Passerini A.]⁶

However, two tumours may reach a large enough size that they erode several pedicles and cause excavation of the posterior surfaces of several vertebral bodies. Neurofibromas may also be found at operation to contain calcification that may not be seen on X-ray.

Neurofibromas are encapsulated tumours, often cystic and usually do not make as deep a depression in the spinal cord as do meningiomas. They are usually attached to the posterior nerve root. They rarely adhere to the dura. At myelography they usually cause definitive arrest in most patients. [Lombardi G. & Passerini A.]⁶

(d) GRANULOMA IN THE LUMBAR SPINE

One case of granuloma in the lumbar region was found in this study. The patient was a male, 37 years of age. He presented at KNH with a history of gradual difficulty in walking and weakness in the lower limbs. The symptoms started about two months after a bicycle accident.

At the time of admission to KNH examination showed that the patient was paraplegic. His sensory level was T12. The clinical diagnosis made was of paraplegia due to cord compression.

The patient's plain X-rays of the lumbar spine showed collapsed vertebrae L1 and L2. There was also a paravertebral mass seen in the region of the L1/L2.

Myelography in this patient demonstrated a complete block at the level of L2 vertebral body. At laminectomy a space occupying lesion was found extramedullary

at the level of L2. The lesion contained caseating material which was diagnosed histologically as abscess due to brucellosis.

Granulomas, whether acute or chronic, may appear as a result of propagation from an adjacent or even from a more remote focus of infection. Transmission is by blood or the lymph. Not infrequently it is difficult to identify the starting lesion.

Chronic granulomas are characterized by pain and later by neurologic signs. They are nearly always diagnosed late or fail to be diagnosed. For this reason the prognosis is poor.

Brucellosis myelopathy is said to occur in about 2% of those with bone brucellosis. [Ganado & Craig]

Cord compressive symptoms are usually due to extradural extension of bony foci, though primary brucellar meningitis has been reported [Cockshott P. & Middlemiss H.]

Tomography and myelography are indicated when the diagnosis is suspected.

(e) MENINGIOMA

One patient in this study had a spinal neoplasm determined histologically as a meningioma. The patient was a female aged 43 years. She presented at KNH with worsening symptoms of pain and weakness in both lower limbs over several months. Physical examination showed that she had spastic paralysis in the lower limbs and a sensory level at T7/T8. A clinical diagnosis of paraparesis due to cord compression was made.

The patient's plain X-rays of the thoracic and lumbar spine were normal. Myelography showed a block at the level of T3 with side tracking of the contrast medium. At surgery an intradural/extramedullary tumour was found. Histology showed the tumour to be a calcified meningioma.

Meningiomas are tumours of adult life. Lombardi and Passerini studied 82 patients with meningioma. [Lombardi G. & Passerini A.]⁶

The average age was found to be 49 years with a range of 13-73 years. The sixth and seventh decades of life showing the highest incidence. The study also indicated a distinct preference for females and a

more pronounced preference for the thoracic portion of the spinal canal.

Epstein studied 26 patients with meningiomas in the spine [Epstein B.S.]

Twenty-one of the patients were over 50 years old. The incidence in women exceeded that in men by 5:1.

By far most meningiomas are situated intradurally and are extramedullary. Occasionally extradural or an extra- and intradural meningioma is found [Brown M.H.]

In the single case in this study the meningioma was found to extend from T2/T3 disc level to lower margin of T3. Lombardi notes that meningiomas are not as a rule very large. [Lombardi G. and Passerini A]⁷

In his study only 4 cases out of 82 had lesions more than 4cm long. Epstein's study notes that the lesions encountered measured from 2x1.5x1cm to 3.5x2x1cm; mostly at the lower range of the scale. [Epstein B.S.]

In the patient in this study, at myelography there was a complete block at T3 level with contrast medium terminating in a cup-like configuration. Epstein's study showed similar result in 12 out of

19 patients. [Epstein B.S.]

In Lombardi's study 76% of the cases had complete blockage. [Lombardi G. & Passerini A.]⁷

Due to this blockage of CSF pathways the tumour is rarely completely demarcated by the contrast medium.

(f) METASTATIC TUMOURS OF THE SPINAL CANAL

Three patients in this study had both plain X-ray and myelographic features of metastatic tumours to the spinal canal. In all the three patients the lesions were extradural myelographically. Two of the patients were males (Ages: 50 years and 60 years respectively) and one was a female aged 65 years. The primary lesion had not been determined in any of the patients

It is noted in literature [Epstein B.S.] that a large number of patients with metastatic tumours to the spine usually have intraspinal extensions from vertebral metastases. This is associated with spinal cord and cauda equina pressure changes. The common primary lesions include Multiple Myeloma and Carcinomas of the breast, lung and prostate.

The thoracic spine is most commonly involved. X-rays show visible bone destruction. Myelographic features include blockages and moderate intrusion into the spinal canal. [Epstein B.S.]

When the clinical and myelographic data do not agree it may be helpful to make a second injection of contrast medium either above or below the obstruction.

Very extensive or multiple lesions contraindicate surgery. [Lombardi G. & Passeriui A.]⁸

Epidural metastases are found in over 75% of cancer patients with myelopathy, and 60% of those with radiculopathy alone. [Dillon W.P.] A patient with cancer and neurologic symptoms of the spinal cord or spinal root injury should, therefore, be quickly studied with myelography, CT-myelography, or MRI.

(g) INTRAMEDULLARY NEOPLASMS

In two patients in this study - one adult (lesion in lower thoracic spine) and one female aged 13 years had myelographic features of intradural neoplasms. The patients are still being investigated and no surgery has been planned yet.

In the patient aged 13 years the clinical presentation was of right hemiparesis. Myelography showed expansion of spinal cord from T3 to C1. Several authors have noted that spinal tumours in children are rare and difficult to diagnose. [Haft et al] & [Nisenson A. & Patterson G.H.] & [Gryspeardt]

(h) SYRINGOMYELIA

One female patient (Age: 19 years) presented clinically with quadriparesis. Plain X-ray showed concavity of the medial surfaces of the cervical spine pedicles and posterior scalloping of the cervical spine vertebral bodies. Myelography showed widening of the cervical cord with spreading of the lateral margins of the column of contrast medium. CT Scan of the head and spine showed hydrocephalus and marked dilatation of the spinal canal. The features were consistent with syringomyelia.

Epstein studied 187 patients with spinal canal mass lesions and encountered 2 cases of cervical syringomyelia.[Epstein B.S.] In one of the cases there was widening of the sagittal diameter of the spinal canal. Myelography on the patient showed widening of the cervical cord and spreading of the lateral margins of the column, indistinguishable from other intramedullary lesions of the same size.

The clinical and symptomatologic features of syringomyelia are fairly well defined. But the pathologic background of the disease is not entirely uniform because there is a wide range of variability of

relationship between its two fundamental components -
glia proliferation and intramedullary cavities.
[Lombardi G. & Passerini A.]⁹

Investigation by myelography and CT would enable the
neuroradiologist to demonstrate the probable causative
pathology in most cases of syringomyelia. These
imaging modalities can also distinguish the distension
of the spinal cord with fluid from distension with
tumour. [Logue V.]

This disease can rule out the presence of other
lesions e.g. tumours.

[i] CERVICAL SPONDYLOSIS

In this study 3 patients were diagnosed myelographically as having cervical stenosis due to spondylotic changes. The diagnosis was confirmed at surgery in all three patients. The patients were aged 36 years, 40 years and 50 years. The youngest patient was a female, and the other two were males.

About 35% of subjects over 50 years are affected with symptomatic cervical spondylosis.[Lombardi G. & Passerini A.]¹⁰ It is also noted in literature [Epstein et al] that "any patient over 30 years of age, no matter what symptoms or signs he presents, is apt to have posterior cervical disc protrusion demonstrated, if he happens to have a myelogram." It is therefore important that radiologists be aware of the lack of specificity of myelography in evaluation of cervical disc or spondylotic root compression. Accurate diagnosis of cervical root neuropathy is actually made on clinical grounds, with confirmation by electromyography in chronic cases. Myelography in this disease can rule out the presence of other lesions e.g. tumours.

The myelographic localisation of spondylotic changes seen in the 3 patients in this study, and the radiological features demonstrated: protrusion of spurs towards the canal or intervertebral foramina and narrowing of the discal interspaces, correspond to the findings by Epstein et al. [Epstein et al]

In his study Epstein notes that protrusion of spurs towards the canal or the intervertebral foramina can be deceptive. However, if there also is developmental narrowing as indicated by diminution of the sagittal diameter, then spurring can become quite significant. Also spondylotic processes affecting the neural arches and articular facets indent the dorsal aspect of the canal and can thereby significantly reduce its transverse diameter, as well as compromise the intervertebral foramina.

CONCLUSIONS

- (1) Spinal pathology was found affecting all age groups including the paediatric age group. At KNH the commonest age group requiring myelographic investigation was the age group 30-39 years.
- (2) The commonest spinal pathology for which patients had myelographic examination was prolapsed intervertebral disc.
- (3) Myelography demonstrated pathological lesions more often in patients with symptoms and signs of spinal pathology than in those with symptoms but no clinical signs.
- (4) Myelography was able to detect space occupying lesions within the spinal canal, localise the lesions and in some cases demonstrate widespread lesions. This was useful in determining whether surgical intervention would be beneficial or not.

RECOMMENDATIONS

In the absence of the newer non-invasive imaging modalities at KNH, use of myelography in the radio-diagnosis of spinal pathology is recommended.

However, myelography is an invasive examination and patient selection must be thorough.

A protocol towards this end is suggested below:

- (a) That the referring clinician should avail to the radiologist detailed clinical data of the patient.
- (b) The referring clinician and the radiologist should review the patient's clinical data and plain films together prior to booking the examination
- (c) Due to the known side effects associated with myelography:
 - The patient's should be admitted on the eve of the examination (for physical and psychological preparation) and be retained in the ward for 24 hours after the examination for observation.
 - Water soluble contrast media be used for examinations at all levels of the spine.

(d) Patients to be examined in both prone and erect positions for lesions in the lumbar spine.

1. [Faded text]

2. [Faded text]

3. [Faded text]

4. [Faded text]

5. [Faded text]

6. [Faded text]

7. [Faded text]

8. [Faded text]

9. [Faded text]

10. [Faded text]

11. [Faded text]

12. [Faded text]

13. [Faded text]

14. [Faded text]

15. [Faded text]

16. [Faded text]

17. [Faded text]

18. [Faded text]

19. [Faded text]

20. [Faded text]

21. [Faded text]

22. [Faded text]

23. [Faded text]

24. [Faded text]

25. [Faded text]

26. [Faded text]

27. [Faded text]

28. [Faded text]

29. [Faded text]

30. [Faded text]

31. [Faded text]

32. [Faded text]

33. [Faded text]

34. [Faded text]

35. [Faded text]

36. [Faded text]

37. [Faded text]

38. [Faded text]

39. [Faded text]

40. [Faded text]

41. [Faded text]

42. [Faded text]

43. [Faded text]

44. [Faded text]

45. [Faded text]

46. [Faded text]

47. [Faded text]

48. [Faded text]

49. [Faded text]

50. [Faded text]

51. [Faded text]

52. [Faded text]

53. [Faded text]

54. [Faded text]

55. [Faded text]

56. [Faded text]

57. [Faded text]

58. [Faded text]

59. [Faded text]

60. [Faded text]

61. [Faded text]

62. [Faded text]

63. [Faded text]

64. [Faded text]

65. [Faded text]

66. [Faded text]

67. [Faded text]

68. [Faded text]

69. [Faded text]

70. [Faded text]

71. [Faded text]

72. [Faded text]

73. [Faded text]

74. [Faded text]

75. [Faded text]

76. [Faded text]

77. [Faded text]

78. [Faded text]

79. [Faded text]

80. [Faded text]

81. [Faded text]

82. [Faded text]

83. [Faded text]

84. [Faded text]

85. [Faded text]

86. [Faded text]

87. [Faded text]

88. [Faded text]

89. [Faded text]

90. [Faded text]

91. [Faded text]

92. [Faded text]

93. [Faded text]

94. [Faded text]

95. [Faded text]

96. [Faded text]

97. [Faded text]

98. [Faded text]

99. [Faded text]

100. [Faded text]

REFERENCES

- (1) Banna M. & Gryspearadt
Intraspinal Tumours in children
Clinical Radiology Vol XXII No 1
Page 17.
- (2) Begg A.C., Faulkner M.A., & McGeorge M.
Myelography in lumbar intervertebral disc
lesions: correlation with operative findings -
British Journal of Surgery 34:141-157.
- (3) Brown M.H.
Intraspinal Meningiomas - Archives of Neurology &
Psychiatry 47:47:271-292
- (4) Buirski G.
The investigation of sciatica and Low Back Pain
Syndrome: current trends - Clinical Radiology
(1987) 38, 151-155.
- (5) Cockshott P. & Middlemiss H.
Clinical Radiology in the Tropics Page 225.
- (6) Cook P.L. & Wise K.
A correlation of the surgical and Radiculographic
Findings in Lumbar Disc Herniation - Clinical
Radiology (1979) 30, 671-682.
- (7) Dillane J.B., Fry, J., & Katton E. (1966)
Acute Back Syndrome: a study from general practice
BMJ ii:82
- (8) Dillon W.P.
Emergency Myelographic Procedures - Diagnostic
Radiology, University of California 1986.
- (9) Duckworth T.
Lecture notes in Orthopaedics and Fractures
Pages 224-225.

- (10) Epstein B.S. & Passafiume A. Spinal Canal Mass Lesions - Radiologic Clinics of North America Vol. IV No 1
- (11) Epstein B.S. et al
Cervical Spinal Stenosis - Radiologic Clinics of North America Vol. XV No 2 August 1977.
- (12) Grainger R.G. & Allison D.J.
Diagnostic Radiology page 1830.
- (13) Gonado & Craig (1958)
Brucellosis myelopathy - Journal of Bone and Joint Surgery 40A, 1380-1387.
- (14) Haft H. & Shenkin H.A.
Spinal Epidural Meningioma - Journal of Neurosurgery 20:801-804 (1963)
- (15) Haft et al (1959)
Spinal Cord Tumours in Children, Paediatrics, 23, 1152-1159
- (16) Harrison's Principles of Internal Medicine
8th Edition
Page 39
- (17) Hofman C.B.
Roentgenologic Diagnosis of Herniated intervertebral Disc - Radiologic Clinics of North America Vol IV No 1.

- (18) Lombardi G. & Passerini A. SPINAL CORD DISEASES
[1] pages 7-8 (1964)
[2] page 2
[3] Page 119
[4] page 120
[5] Pages 120&133
[6] pages 59-63
[7] page 65
[8] page 93
[9] page 157
[10] pages 119-125
- (19) Logue V.
14th Crookshank Lecture
Clinical Radiology Vol. 22 No 1
- (20) Modic M.T. et al (1988)
Imaging of Degenerative Disc Disease
Radiology (1988) 168:177-186.
- (21) Nisenson A. & Patterson G.H. (1945)
Spinal Cord Tumours in Children:
A study of three cases of ependymoma - Journal
of Paediatrics 27, 397-406.
- (22) Pau A., Sehrbundt Viale E., Turtas S., & Viale G.L.
Redundant Nerve Roots of Cauda Equina
Surgical Neurology 16:245-250, October 1981.
- (23) Pilling J.R.
Water soluble Radiculography in the Erect Posture:
A Clinico-radiological study - Clinical Radiology
(1979) 30, 665-670.

(24) Westberg G.
Gas Myelography and Percutaneous Puncture in
the Diagnosis of Spinal Cord Cysts - Acta
Radiologica, Supplementum 252 (1966).

(25) Whitehouse G.H. & Worthington B.S.
Techniques in Diagnostic Radiology
pages 264 - 280.

A C K N O W L E D G E M E N T S

I would like to thank:-

1. DR. M.W. WACHIRA, M.B.Ch.B, M.Med
who was my Supervisor during this dissertation
for the guidance that he offered me.
2. The Office of The President through the Department
of Defence for the financial assistance that was
granted to me to enable the study to be carried
out.
3. The staff in the X-ray Department at Kenyatta
National Hospital for the assistance and patience
that they accorded me.
4. - Miss Millicent Karue for her fine typing.
5. My wife Alice and our two daughters Gloria and
Christina for being very understanding during the
the period of study.

DATA COLLECTION FORM

1. NAME OF PATIENT:

(Last Name) (Other Names)

2. PLACE OF EXAMINATION (Hospital):

3. HOSPITAL NUMBER(S)

4. X - RAY NUMBER(S)

5. DATE OF EXAMINATION:

6. CENTRE (Hospital/Ward/Clinic) FROM WHICH PATIENT IS REFERRED:

7. PATIENT'S CLINICAL PRESENTATION:
(a) AGE -----
(b) SEX -----

7 (c) SYMPTOMS + THEIR DURATION:

(d) CLINICAL SIGNS:

(e) CLINICAL DIAGNOSIS:

8. PLAIN X - RAY REPORT:

9. MYELOGRAPHY (OR RADICULOGRAPHY) REPORT:

10. PATIENT'S FOLLOW UP REPORTS:

(a) POST MYELOGRAPHIC MANAGEMENT

(i) Surgical Operation

(ii) Other forms of management if surgical not done:

10 (b) Findings at Operations:

(c) Histological Report:

