

CRYPTORCHIDISM

( A STUDY OF 200 CASES AT KENYATTA NATIONAL  
HOSPITAL (K.N.H.) )

BY

DR. CHAIRMAN NYAMBUYI (M.B.B.S.)

SUBMITTED AS DISSERTATION IN PART FULFILMENT  
FOR THE DEGREE OF MASTER OF MEDICINE (SURGERY)  
PART II

JULY 1985.

UNIVERSITY OF NAIROBI  
LIBRARY

University of NAIROBI Library



0390373 9

DECLARATION

CANDIDATE

This dissertation is my original work and has not been presented for a degree in any other University.

  
DR. CHAIMAN NYAMBUYI, M.B.B.S.

SUPERVISOR

This dissertation has been submitted for examination with my approval as University Supervisor.

  
PROF. J.M. KYAMBI

## CONTENTS

1	Acknowledgement	-----	(i)
2	Aim of study	-----	(ii)
3	Summary	-----	1
4	Review of Literature	-----	4
5	Materials and Methods	-----	7
6	Results	-----	9
7	Discussion	-----	40
8	Recommendation	-----	55
9	Conclusion	-----	56
10	References	-----	58
11	Appendix	-----	65

+  
ACKNOWLEDGEMENT

I would like to thank Prof. J.M. Kyambi for his encouragement, support, guidance and constructive criticism of the manuscript.

Many thanks also go to Mrs. L.N. Mwombe and Mrs. M.N. Kiarie for their superb and invaluable secretarial work.

Aim of the Study

- (i) To show that the number of patients seen with cryptorchidism has been increasing year by year.
- (ii) To find out if the time for surgery has reduced to the optimum time i.e., 2-5 years. If not make recommendations.
- (iii) To show the incidence of various types of cryptorchidism, namely intra-abdominal canalicular, extra-calicular, and ectopic, unilateral and bilateral types.
- (iv) To show the incidence of hernia, torsion and hydrocele association with cryptorchism.
- (v) To show the types of orchidopexy operations done, the number of patients that had a single stage orchidopexy and a two stage orchidopexy.
- (vi) To show the number of orchidectomies done and why they were done.
- (vii) To highlight the findings at operation.
- (viii) To show the number of complications that occurred in treatment of these cases.

- (ix) To show the incidence of palpable and impalpable cryptorchid testes .
- (x) To highlight the presenting symptoms and signs and the investigations done.
- (xi) To show the final position of the testis in the follow-up cases.
- (xii) To show the comparison of cryptorchid testis and a healthy testis in unilateral cryptorchidism.
- (xiii) To show the distribution of these patients according to the provinces.
- (xiv) Finally to show the period of hospitalisation of these cases.

### SUMMARY

A cryptorchid testis is a relatively common problem of the male sex.

In the years 1975 to 1984 a total of two hundred (200) cases of cryptorchid testes were seen and treated in Kenyatta National Hospital (K.N.H.). The two hundred patients had a total of two hundred and sixty three (263) improperly descended testes.

The main symptom was absence of the testicle from the scrotum. This was present in all the two hundred patients. This symptom was followed by the presence of a swelling in 123 (61.5%) cases and then pain in 91 (45.5%) cases.

The condition was unilateral in one hundred and thirty six (136) (68%), bilateral in sixty four (64) (32%), right sided in sixty three (63) (46.32%) left sided in seventy three (73) (53.68%), twenty eight (28) (10.64%) testes were intra-abdominal, eight (8) 3.04% were at the internal inguinal ring, a hundred and forty (140) (53.3%) were in the mid inguinal canal, thirty-seven (37) 14.06% at the external inguinal ring, forty-four (44) 16.7% at the superficial inguinal pouch, five (5) (1.0%) at the pubic region, one (1) (0.38%) at the penile base. No testis was in the femoral or perineal region.

Two (2) nonunion of testis and epididymis were found at surgery.

Clinically eighty-nine (89) (33.84%) patients were associated with an open processus vaginalis, two (0.76%) patients were associated with torsion, seven (7) (2.66%) patients were associated with hydrocele, Four (4) (1.52%) patients had hypospadias, one (1) patient had Noonan's syndrome, one (1) patient had prune belly syndrome. In one hundred and two (102) (38.78%) cases the testicle was palpable.

One (1) patient (0.5%) had intravenous urogram which was normal. Two patients (1%) had buccal smear done. No burr bodies were seen. Two patients (1%) had chromosomal studies which showed a normal male karyotype 46xy. Fourteen (14) patients (7%) had biopsy and histology done.

Two hundred and fourteen (214) (81.33%) had a single stage orchidopexy, thirty-five (35) (13.3%) patients had a two stage orchidopexy. Fourteen (14) (5.2%) patients had orchidectomy.

In two hundred and twenty-six (226) (85.92%) cases the length of the vas deferens was adequate. In thirty-seven (37) (14.08%) cases the length of the vas deferens was inadequate.

In thirty-two (32) (12.16%) patients the testicle was atrophic. In eighty-six (86) (32.69%) patients the testicle was smaller than the opposite side. In one hundred and forty-five (145) (55.15%) patients the testicle was normal.



In one hundred and sixty-three (163) (16.98%) the processus vaginalis was patent. In one hundred (100) (38.2%) cases no hernial sac was found.

In two hundred and seventeen (217) (82.52%) the entrance to the scrotum was completely obliterated by fibrous tissue. In forty-six (46) (17.48%) it was normal.

One hundred and sixty-five (165) (82.5%) patients had dartous pouch technique type of orchidopexy. Eight (8) (4%) patients had Keetley-Torek operation, two patients (1%) had Ombredanne Operation and in twenty-five (25) (12.5%) it was not specified what type of the orchidopexy was done.

Finally in the follow-up cases the testicle was in the scrotum in one hundred and sixty (160) (80%) and at the upper part of the scrotum in twenty-six (26) (13%).

RIVIEW OF LITIRATUR F

John Hunter 1786<sup>34</sup> described the earliest account of undescended testis which found in the abdomen of a seven month fetal life and in the scrotum at 9 months.

In 1899 Bevan<sup>26</sup> described the operation for undescended testicle and congenital hernia. In 1926 Bevan advised suturing the testis to the bottom of the scrotum.

Keetley (1894<sup>7</sup>) and Torek (1909<sup>6</sup>) described the Keetley-Torek operation which embedded the testis into the thigh temporarily then brought back into the scrotum after 3 to 6 months.

Ombredanne (1910)<sup>34</sup> described an operation in which the undescended testis was replaced in the opposite compartment of the scrotum.

Denis Browne (1933)<sup>11</sup> discarded the natural canal and formed a new canal in front of the pectineal fascia.

In 1945 Bishop P.M.F.<sup>19</sup> described clinical endocrinology versus the management of the undescended testicle.

Cooper E.R.A. (1929)<sup>40</sup>, and Sohval A.R.<sup>17</sup> (1954) showed the histology of the retained testis at different ages and its comparison with the scrotal testis.

Hansen (1949) showed that treated or untreated the fertility is identical in unilateral retention of testis. Bilateral cryptorchism if untreated led to sterility.

Scorer C.G. (1957)<sup>16</sup> wrote the treatment of undescended testis and Witherington R. (1970)<sup>17</sup> described the management of the undescended testis.

Stephen R.A. (1958)<sup>2</sup> described the malignant testicular tumours.

Benson and Lofti (1967)<sup>5</sup> described the Dartous Pouch Technique.

Chambless W.H. (1961)<sup>19</sup> and A.K. Henry<sup>19</sup> (1963) and Witherington<sup>17</sup> (1984) described the use of the midline preperitoneal approach to undescended testis and inguinal and femoral hernia repair.

Kiesewetter W.B. (1969)<sup>24</sup> studied the histologic changes in the testis following the anatomically successful orchidopexy.

Persky L. 1971<sup>30</sup> and Firor H.V.<sup>31</sup> 1971 described the two stage orchidopexy.

Hinman F. Jr<sup>41</sup> 1955 described the optimum times for orchidopexy in cryptorchism.

Ehrlich R.M. (1969)<sup>14</sup> et al described the effects of gonadotrophin in cryptorchism.

Reigler H.C. (1972)<sup>20</sup> described the torsion of intra-abdominal testis.

Fowler R. and Stephens F.D.<sup>17</sup> (1963) described the role of testicular vascular anatomy in the salvage of high testes.

## MATERIALS AND METHODS.

An analysis of clinical records of two hundred (200) patients seen and treated at Kenyatta National Hospital (KNH) between 1975 and 1984, in whom a diagnosis of cryptorchid testis was made. A proforma into which to transfer the information from these records was made (see appendix 1). Kenyatta National Hospital (KNH) is the national referral and the teaching Hospital of Faculty of Medicine, University of Nairobi, Kenya.

The analysis included the clinical presentation of these patients in terms of the age, sex, birth weight, full term or premature the province where the patient came from, symptoms and signs. The aim here was to highlight the commonest and the most persistent presenting features. The history and the physical findings as recorded in the patients file were studied and the information transferred to the proforma.

An analysis of the investigations was also made. This included data on haemogram, urea and electrolytes, urine analysis, culture and sensitivity, stool examination for ova and cysts as routine investigations and intravenous urogram buccal smear. Chromosomal studies, biopsy as special investigations. Other investigations were liver function and tests and electrocardiography.

All the patients had haemogram, urea and electrolytes, plus urine analysis done. Sixteen (16) patients had urine culture and

sensitivity done. Two (2) patients had their stools examined for ova and cysts. The aim here was to rule out parasitic infestation. One patient had liver function tests done. These investigations were aimed at assessing the patient's fitness for surgery.

One (1) patient had intravenous urogram done. This was aimed at ruling out other anomalies that may be present in the genito-urinary tract in association with the undescended testicles.

Two (2) patients had chromosomal karyotyping studies carried out to find out if they had a normal male karyotype 46xy.

One (1) patient had electrocardiography done for an associated heart lesion.

Fourteen (14) patients had biopsy and histology done. These were done to see the histological state of the testis.

A review was made of the follow-up of cases as seen in the clinic after surgery. This was to determine what percentage had their testicles completely descended into the scrotum and the percentage that still had their testicles undescended at the upper part of the scrotum.

Lastly a review of the number of days these patients stayed in the hospital was done.

RESULTS

A) Sex (200 cases)

All the two hundred (200) (100%) patients were males.

B) Age (200 cases)

The age of the patients ranged from 0 years to 35 years.

In the age group 0-3 years there were 34 (17%) Patients

In age group 4-6 years there were 54 (27%) patients.

In the age group 7-9 years there were 52 (27%) patients.

In the age group 10-12 years there were 31 (15.5%) patients

In the age group 13-15 years there were 14 (7%) patients

In the age group above 15 years there were 15 (7.5%) patients.

The peak incidence was between 4-9 years.

(See Table 1 Chart 1A)

The yearly distribution of patients is shown on Chart 1B.

C) Symptoms.

Cryptorchidism is a congenital condition which means the duration of symptoms is from birth.

91 (45.5%) patients presented with pain.

35 (17.5%) patients presented with chronic discomfort.

123 (61.5%) patients presented with swelling.

200 (100%) patients complained of the absence of the testicle.

In 145 (72%) patients the history was given by the father.

In 190 (95%) patients the history was given by the mother

In 4 (2%) patients the history was given by the patient himself.

(See Table 2 Chart 2)

AGE GROUPS IN YEARS	1975	1976	1977	1978	1979	1980	1981	1982	1983	1984	Total	Per cent
0 - 3	0	1	0	1	7	3	4	5	7	6	34	17%
4 - 6	1	0	1	1	5	18	5	3	7	13	54	27%
7 - 9	1	4	1	10	6	5	1	5	9	10	52	26%
10 - 12	0	2	1	2	1	7	1	2	7	8	31	15.5%
13 - 15	0	1	1	0	0	2	1	1	1	7	14	7%
Above 15	0	0	0	1	2	3	0	2	1	6	15	7.5%
total per year	2	8	4	15	21	32	12	18	32	50	200	100%

Table 1. Age groups and yearly distribution of patients



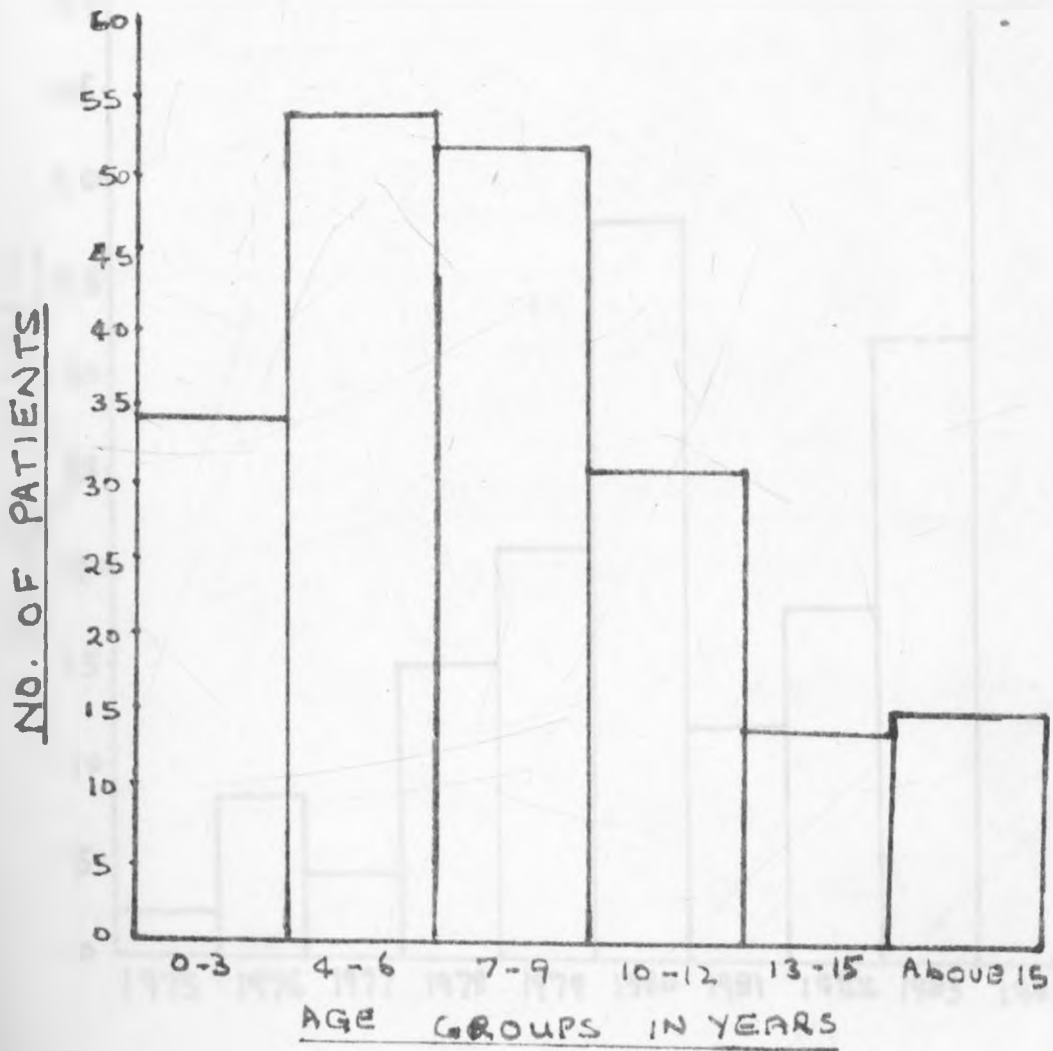


CHART 1A AGE DISTRIBUTION

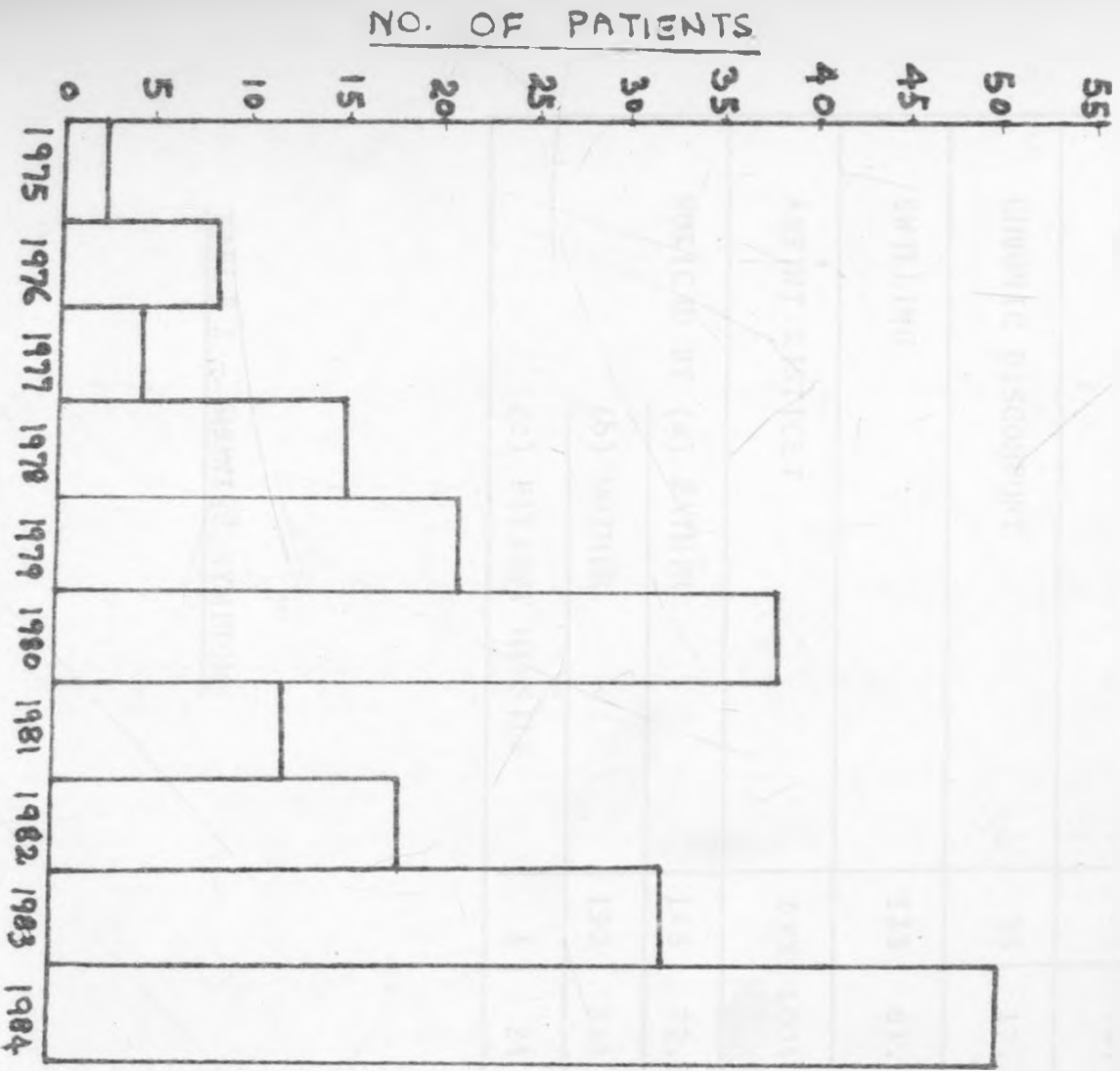


CHART 1B - YEARLY DISTRIBUTION

SYMPTOM	NO	PERCENT
PAIN	91	45.5%
CHRONIC DISCOMFORT	35	17.5%
SWELLING	123	61.5%
ABSENT TESTICLES	200	100%
NOTICED BY (a) FATHER	145	72.5%
(b) MOTHER	190	95%
(c) PATIENT HIMSELF	4	2%

TABLE 2 - SHOWING SYMPTOMS

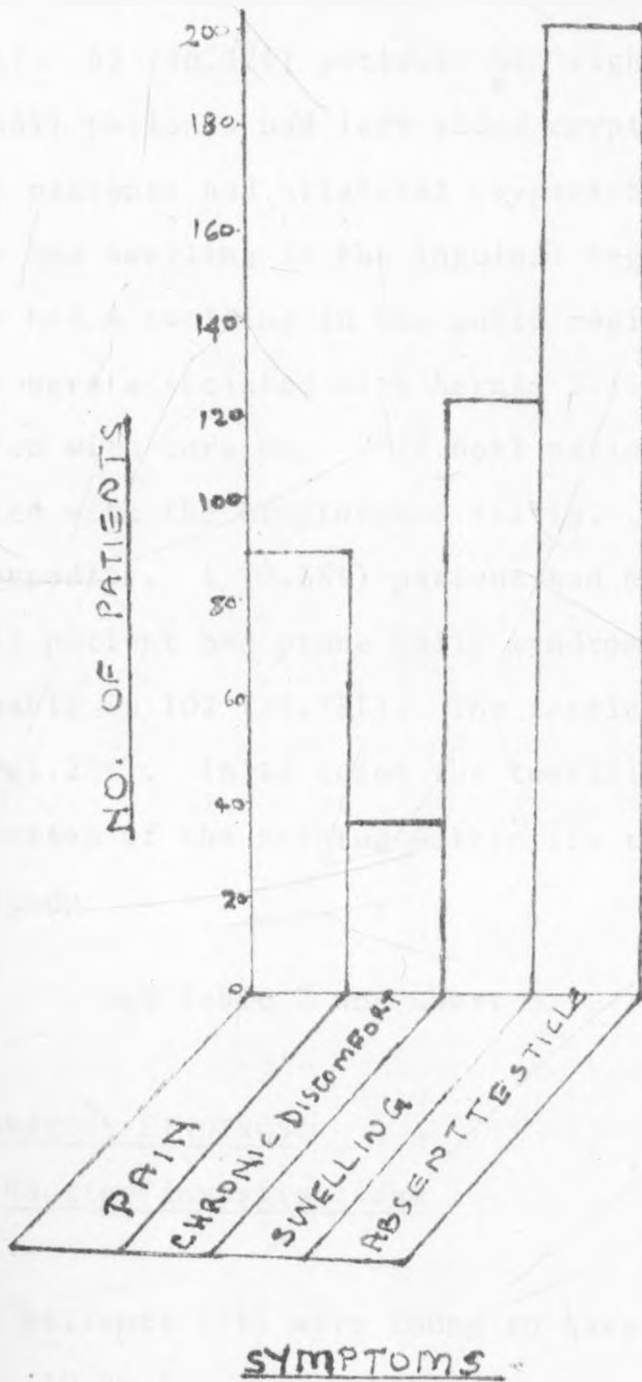


CHART 2 - THE DISTRIBUTION OF SYMPTOMS.

(D) PHYSICAL EXAMINATION FINDINGS

Empty small scrotum was the commonest finding 263 (100%) patients. This was followed by unilateral cryptorchism 136 (68%). 63 (46.32%) patients had right sided cryptorchidism. 73 (53.68%) patients had left sided cryptorchidism. 64 (32%) patients had bilateral cryptorchidism. 144 (54.75%) patients had swelling in the inguinal region. 7 (2.66%) patients had a swelling in the pubic region. 89 (33.84%) patients were associated with hernia 2 (0.76%) patients were associated with torsion. 7 (2.66%) patients had hydrocele associated with the cryptorchid testis. 4 (1.52%) patients had hypospadias. 1 (0.38%) patient had Noonans svndrome. 1 (0.38%) patient had prune belly syndrome. The testicle was palpable in 102 (38.78%). The testicle was not palpable in 161 (61.22%). In 12 cases the testicle was milked down to the bottom of the scrotum-Retractile testis not included in the study.

See Table 3 and Chart 3.

(I) LABORATORY FINDINGS.

(A) Routine investigations

Two patients (1%) were found to have haemoglobin less than 10 gm %

No patient showed abnormalities in the urea and electrolytes.

No patient showed sugar or albumin in the urine.

Sixteen (16) (8%) had positive urine culture.

The organisms were sensitive to Nalidix acid.

Two patients (1%) had stools positive for ova and  
cysts.

Only one (1) (0.5%) patient had liver function tests  
done. These were normal.

(B) Special Investigations

One (1) (0.5%) patient had intravenous urogram done. It  
showed no urinary tract anomalies.

Two (2) (1%) patients had buccal smear done. No burr  
bodies were seen.

Two (2) (1%) patients had chromosomal karyotyping studies  
done. A normal male karyotype 46xy was seen.

Fourteen (14) (7%) patients had biopsy and histology  
done. Three of the fourteen patients the histology  
showed testicular tissue with normal spermatogenesis.  
Eleven of the fourteen patients the histology showed  
fibrous tissue without testicular tissue.

	SIGNS	NO	PER CENT
1	EMPTY SMALL SCROTUM	263	100%
2	UNILATERAL CRYPTORCHISM	136	68%
3	(A) RIGHT SIDED CRYPTORCHISM	63	46.32%
4	(B) LEFT SIDED CRYPTORCHISM	73	53.68%
5	BILATERAL CRYPTORCHISM	64	32%
6	SWELLING IN (a) INGUINAL REGION	144	54.75%
7	(b) PUBIC REGION	7	2.66%
8	(c) PERINEAL REGION	-	-
9	(d) FEMORAL REGION	-	-
10	ASSOCIATED WITH HERNIA	89	33.84%
11	ASSOCIATED WITH TORSION	2	0.76%
12	ASSOCIATED WITH HYDROCELE	7	2.66%
13	ASSOCIATED WITH HYPOSPADIAS	4	1.52%
14	ASSOCIATED WITH NOONAN'S SYNDROME	1	0.38%
15	ASSOCIATED WITH KLINEFELTER SYNDROME	1	0.38%
16	TESTICLES (a) PALPABLE	102	38.78%
17	(b) IMPALPABLE	161	61.22%
18	(c) MILKED OUT OR DOWN	12	

TABLE - 3 SIGNS ON PHYSICAL EXAMINATION

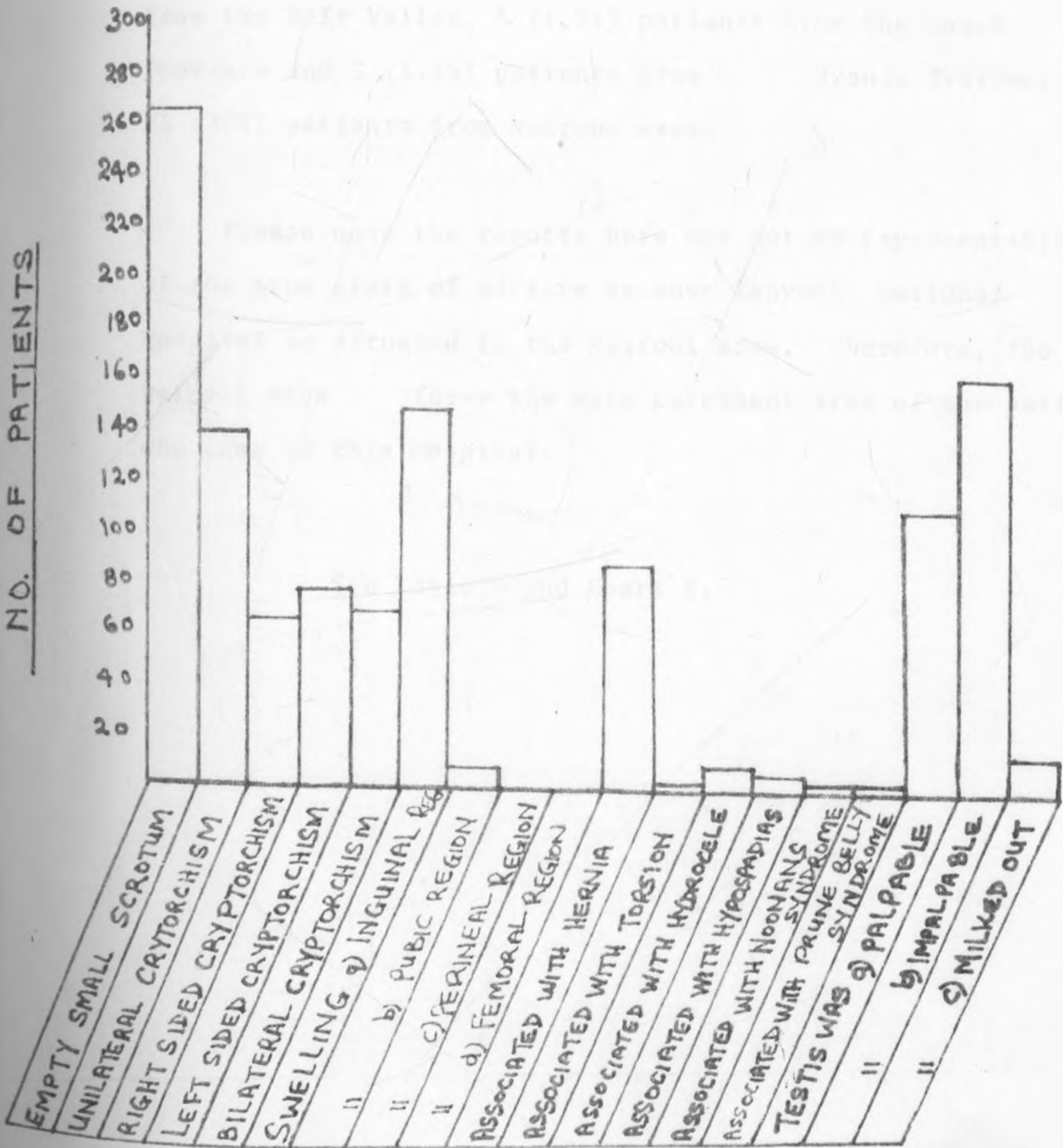


CHART-3 - SIGNS OF PHYSICAL EXAMINATION



(f) Results of the patients.

Distribution according to their provinces showed that there were 40 (20%) patients from the Central Province, 29 (14.5) patients from the Eastern Province, 44 (22%) patients from the Western Province, one (0.5%) patient from the Rift Valley, 3 (1.5%) patients from the Coast Province and 5 (2.5%) patients from Nyanza Province, 78 (39%) patients from Nairobi area.

Please note the results here may not be representative of the true state of affairs because Kenyatta National Hospital is situated in the Nairobi area. Therefore, the Nairobi area forms the main catchment area of the patients who come to this Hospital.

See Table 4 and Chart 4.

CENTRAL PROVINCE	40	
EASTERN PROVINCE	29	
WESTERN PROVINCE	44	
RIFT VALLEY PROVINCE	1	
COAST PROVINCE	3	
NYANZA PROVINCE	5	
NAIROBI AREA	78	

TABLE 4 PROVINCIAL DISTRIBUTION OF THE PATIENTS

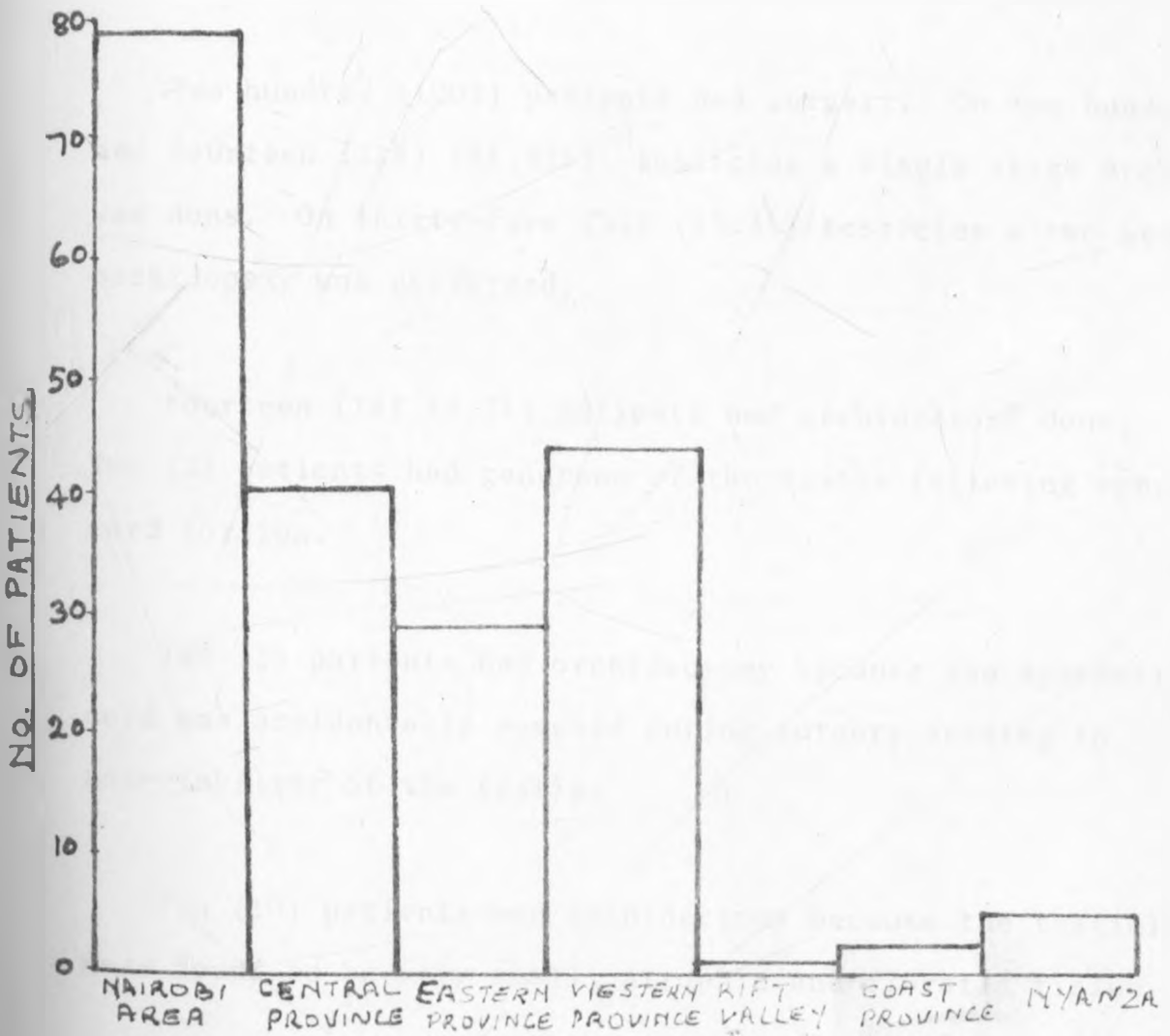


CHART 4 - THE PROVINCIAL DISTRIBUTION OF PATIENTS

G) Results of Treatment

Two (2) (0.76%) patients were observed for spontaneous descent. It did not occur.

Two (2) (0.76%) patients with unilateral cryptorchism were put on hormonal therapy. The testicle did not descend into the scrotum.

Two hundred (100%) patients had surgery. On two hundred and fourteen (214) (81.33%) testicles a single stage orchidopexy was done. On thirty-five (35) (13.3%) testicles a two stage orchidopexy was performed.

Fourteen (14) (5.2%) patients had orchidectomy done. Two (2) patients had gangrene of the testis following spermatic cord torsion.

Two (2) patients had orchidectomy because the spermatic cord was accidentally severed during surgery leading to non-viability of the testis.

Ten (10) patients had orchidectomy because the testicles were found to be very small, atrophic and fibrotic tissue.

see Table 5 Chart 5.

1	SPONTANEOUS DISCONT	2	0.76%
2	HORMONAL THERAPY	2	0.76%
3	ORCHIDOPEXY (a) SINGLE STAGE	214	81.33%
	(b) TWO STAGE	35	13.3%
4	ORCHIDECTOMY	14	5.2%

TABLE 5      SHOWING THE MANAGEMENT




CHART-5 THE MANAGEMENT

H) The Types of Orchidopexy Operation Done

One hundred and sixty-five (165) (82.5%) patients had the Dartous Fouch Technique performed on them.

Eight (8) (4%) patients had the Keetley-Torek Operation.

Two (2) (1%) patients had the Ombredanne Operation.

Twenty-five (25) (12.5%) patients the type of Orchidopexy operation done was not specified.

(Seen Table 6, Chart 6.)

All the 200 patients had the inguinal incision approach.

	NO	%
DARTOUS TOUCH TECHNIQUE	165	82.5%
KIFTLEY-TORIK OPERATION	8	4%
OMBR EDANN I O I IRATION	2	1%
UNSPECIFIED TYPE	25	12.5%

TABEL 6 TYPE OF ORCHIDOPHY  
OPERATIONS DONE.






CHART 6 - TYPE OF ORCHIDOPEXY OPERATION

(I) Results of the findings at operation were as follows:-

28 (10.64%) testicles were intra abdominal.

8 (3.04%) testicles were at the internal ring.

140 (53.3%) testicles were in midinguinal region  
approximately.

37 (14.06%) testes were at the external inguinal  
ring.

44 (16.7%) testes were in the superficial inguinal  
pouch.

5 (1.9%) testes were in the pubic region.

1 (0.38%) testis was at the penile region.

No testes were found in the femoral or perineal  
region.

In 2 testes there was nonunion of the testis with  
the epididymis.

The length of the vas deferens was adequate in 226  
(85.92%) cases. It was short in 37 (14.08%) cases.

The length of the spermatic blood vessels was adequate  
in 196 (74.52%) and inadequate in 67 (25.48%) cases.

Condition of the testes was as follows:-

32 (12.6%) testicles showed atrophic changes.

86 (32.69%) testicles were smaller.

145 (55.15%) testicles were normal in size.

The open processus vaginalis was present in 163 (61.98%) testicular operation. This was dissected out, ligated and divided.

In a 100 (38.02%) testicular operation the hernial sac was absent.

In 217 (82.52%) testicular operations the entrance to the scrotum (the third ring of McGregor) was covered by fibrous tissue.

In 46 (17.48%) operations the entrance to the scrotum was normal.

See Tables 7A to 7F and Chart 7.

J) Results of the follow-up cases

45 (27.5%) patients complained of pain that came on and off on the scar of operation.

21 (10.5%) patients developed a swelling on the operation site.

5 patients had keloids developing on the scar.

8 patients had hypertrophic scar.

5 patients had swelling as a result of operation wound infection.

3 patients developed hernia.

TABLE 7 A-F FINDINGS AT OPERATION

7A. POSITION OF TESTIS

10

	POSITION OF TESTICLE	NO	PERCENT
1	INTRA-ABDOMINAL	28	10.64%
2	AT INTERNAL RING	8	3.04%
3	MID INGUINAL CANAL (APPROXIMATELY)	140	53.3%
4	AT EXTERNAL INGUINAL RING	37	14.06
5	AT SUPERFICIAL INGUINAL FOULC	44	16.7%
6	AT PUBIC REGION	5	1.9%
7	AT FEMORAL REGION	0	-
8	AT PERINEAL REGION	0	-
9	PHENILI	1	0.38%
10	NONUNION OF TESTIS+EPIDIDYMIS	2	

7B. LENGTH OF VAS DEFERENS

11

	LENGTH	NO.	PERCENT
1	ADEQUATE	226	85.92%
2	INADEQUATE (SHORT)	37	14.08%

7C. LENGTH OF SPERMATIC VESSELS

12

	LENGTH	NO	PERCENT
1	ADEQUATE	196	74.52%
2	INADEQUATE (SHORT)	67	25.48%

7D. CONDITION OF TESTIS

13

	CONDITION	NO.	PERCENT
1	ATROPHIC	32	12.16%
2	SMALL	86	32.69%
3	NORMAL SIZE	145	55.15%

7E. OPEN PROCESSUS VAGINALIS

14

		NO.	PERCENT
1	PRESENT	163	61.98%
2	ABSENT	100	38.02%

7F. INTRANEURAL TO THE SCROTUM

15

		NO.	PERCENT
1	COVERED BY FIBROUS TISSUE	217	82.52%
2	NORMAL	46	17.48%

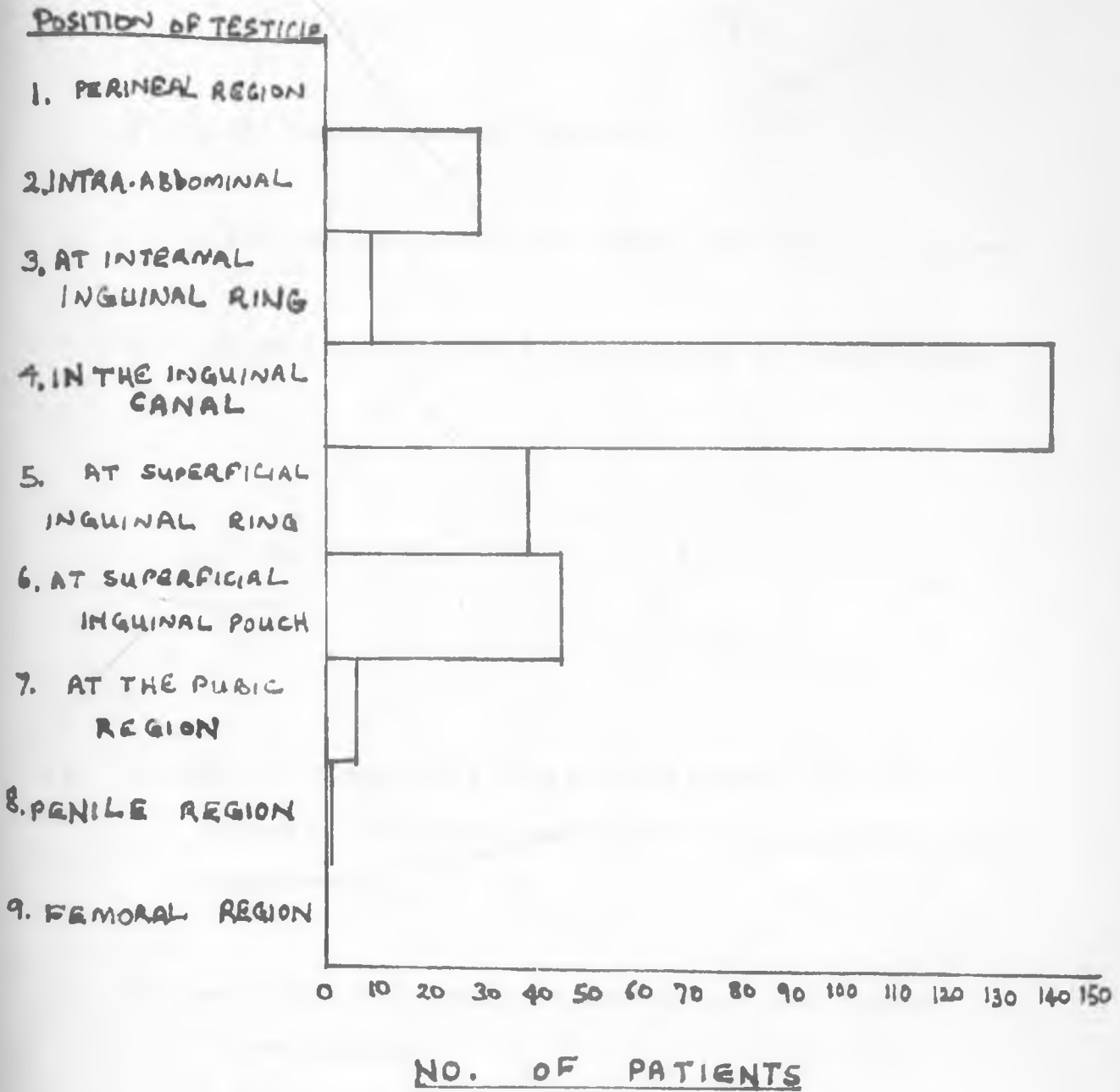


CHART 7 FINDINGS AT OPERATION

Only 5 (2.5%) patients had post-operative wound infection.

18 (6.8%) testes became atrophic.

26 (9.8%) testes were at the upper part of the scrotum.

160 (60.8%) testes were at the bottom of the scrotum.

See Table 8, Chart 8

(K) Results of Comparing a Cryptorchid testis with its normally descended counterpart in unilateral cases showed that,

(1) In 92 (67.64%) patients the size of the testis was smaller.

In 36 (26.40%) patients the testis size was the same.

(2) In 93 (68.45%) patients the testis was longer in shape.

In 35 (25.73%) patients the shape of the testis was the same as the counterpart.

	NO	PERCENT
1. PAIN	45	27.5%
2. Swelling	21	10.5%
3. INFECTION (i) OF WOUND	5	2.5%
(ii) ORCHITIS	0	0
(iii) EPIDIDYMO-ORCHITIS	0	0
4) ATROPHY OF TESTIS	18	6.8%

Table 8 - COMPLICATIONS



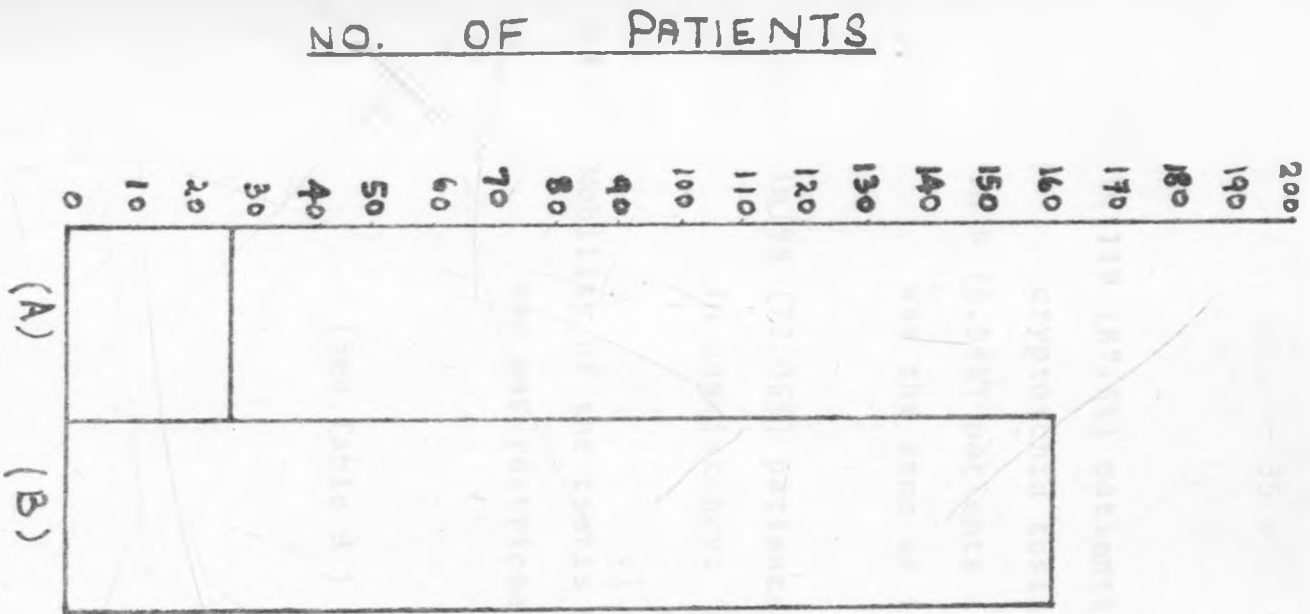


CHART 8 -

THE FINAL RESULTS OF

ORCHIDOPEXY AT FOLLOW-UP CLINIC

- (A) TESTIS STILL UNDESCENDED - AT THE UPPER PART OF THE SCROTUM.
- (B) TESTIS COMPLETELY DESCENDED INTO THE SCROTUM.

(3) In 119 (87.5%) patients the position of the cryptorchid testis was higher.

In 9 (6.54%) patients the position of the testis was the same as the counterpart.

(4) In 98 (72.05%) patients the testis was softer in consistency.

(5) Mobility of the testis with regard to the scrotal sac was restricted in 121 (88.96%) cases.

(See Table 9 )

17

1	SIZE	(a) SMALLER	92	67.64%
		(b) SAME	36	26.4%
2	SHAPE	(a) LONGER	93	68.45%
		(b) SAME	35	25.73%
3	POSITION	(a) HIGHER	119	87.5%
		(b) SAME	9	6.54%
4	CONSISTENCY	(a) FIRM	28	20.58%
		(b) SOFTER	98	72.05%
5	Mobility with Regard to the Scrotal Sac, Restricted in		121	88.96%

TABLE 9 - COMPARISON BETWEEN THE CRYPTORCHID TESTIS AND ITS NORMALLY DISCENDED COUNTERPART IN UNILATERAL CASES.

L) Results of the Period of Hospitalisation were as follows:-

1. 98 (49%) patients stayed in the hospital for 5 days and less.
- 2) 54 (27%) patients stayed in the hospital for 5 to 10 days.
- 3) 20 (10%) patients stayed in the hospital for 10 to 15 days.
- 4) 12 (6%) patients stayed in the hospital for 15 to 20 days.
- 5) 5 (2.5%) patients stayed for 20 to 25 days.
- 6) 3 (1.5%) patients stayed for 25 to 30 days.
- 7) 3 (1.5%) patients stayed for 30 to 35 days.
- 8) 1 (0.5%) patients stayed for days between 35 to 40 days.

The patients who stayed shortest stayed for 2 days and the one that stayed longest stayed for 39 days.

(See Table 10, Chart 9)

The majority of the patients 152 (76%) stayed in hospital for less than 10 days.

NO. OF DAYS	NO. OF PATIENTS	PERCENT
0 - 5	98	49%
5 - 10	54	27%
10 - 15	20	10%
15 - 20	12	6%
20 - 25	5	2.5%
25 - 30	3	1.5%
30 - 35	3	1.5%
35 - 40	1	0.5%

TABLE 10. PERIOD OF HOSPITALISATION

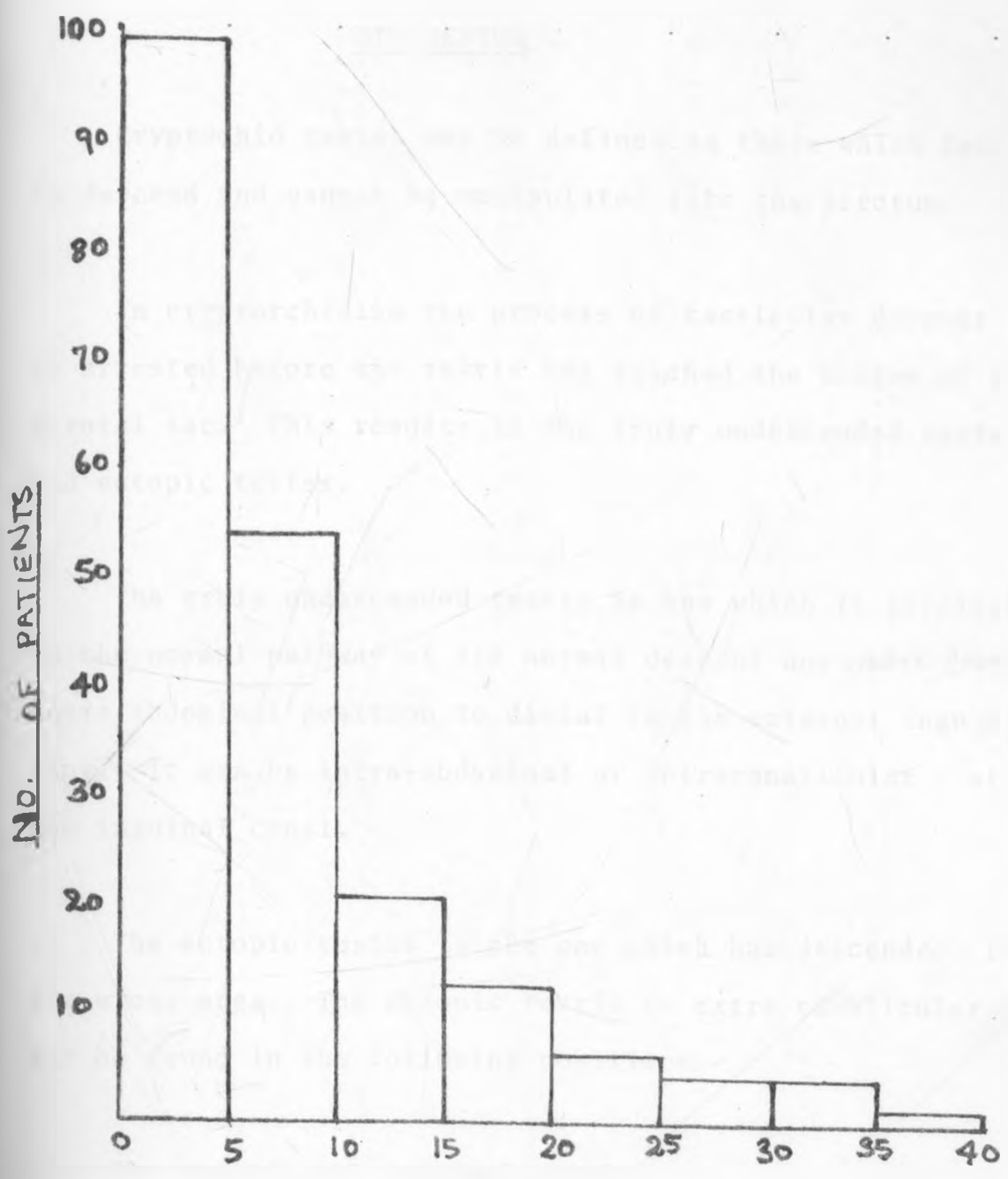


CHART 9 - PERIOD OF HOSPITALISATION IN DAYS

## DISCUSSION

Cryptochid testes may be defined as those which fail to descend and cannot be manipulated into the scrotum.

In cryptorchidism the process of testicular descent is arrested before the testis has reached the bottom of the scrotal sac. This results in the truly undescended testes and ectopic testes.

The truly undescended testis is one which is arrested in the normal pathway of its normal descent any *where* from intra abdominal position to distal to the external inguinal ring. It can be intra-abdominal or intracanalicular - within the inguinal canal.

The ectopic testis is the one which has descended into the wrong area. The ectopic testis is extra canalicular and may be found in the following positions:-

The superficial inguinal pouch.

The interstitial ectopic testis lying on the aponeurosis of the external oblique muscle.

The pubopenile ectopic testis which is lying on dorsal base of the penis.

The perineal testis, which lies in the perineum affixed by attachments near the Ischial Spine.

The femoral canal ectopic testis which is lying in the femoral triangle.

### Embryology

The fetal testis arises as an outgrowth of the urogenital ridge by the sixth week of gestation.

By the twelfth (12th) week the fetal testis is situated at the internal inguinal ring.

The initial phase of descent, the transabdominal migration, is produced by differential growth of the foetus rather than migration per se.

Distally the developing testis is connected to the inguinal region by a column of mesenchyme - the gubernaculum, which passes through the already developed inguinal canal and into the scrotum.

Further descent occurs after seven (7) months of intra-uterine life. Generally by the end of the 8th month the testes have reached the scrotum (Shapiro and Bodai).



The incidence of cryptorchidism varies with the age of the babies. It is highest in the premature newborn infants 21%, followed by the full term newborn infants 2.7% - 4% and at one year of age it is 0.2% (Scorer).

In adult it varied from 0.3% (Bishop) to 0.8% (Scorer and Farrington).

Any testicle that has not spontaneously descended by the end of one year may be assumed unlikely to descend. Only rarely does spontaneous descent occur after one year.

Testicular descent is arrested in 1 to 7% of the males (Campbell and Harrison).

The retractile testis did not form part of this study because there is no indication for orchidopexy in retractile testes.

The undescended testis may be located intra-abdominally, in the inguinal canal or in the ectopic position.

The intra-abdominal testis is impalpable all the time.

The inguinal canal testis may be palpable sometimes.

The ectopic testis is palpable all the time.

In the series studied of the imperfectly descended testes the following were found. The total number of cases was

200. Total number of undescended testes were 263.

There were 136 (68%) unilateral cases. This compares well with the 60% in the series of Dougall and Maclean and 75% in the series by Shapiro and Bodai. This was about two and half times the bilateral cases.

There were 63 (46.32%) right sided testicles and 73 (53.68%) left sided testicles undescended. This compares well with the series of Campbell and Harrison which gives the side incidence of the right and left as being about equal.

There were 64 (32%) bilateral cases. This compares well with series by Dougall and Maclean of 40% cases with bilateral maldescent.

There were 83 (33.84%) undescended testes associated with hernia clinically.

Two undescended testes were associated with torsion. Seven cases were associated with hydrocele. There were four (4) associated with hypospadias. There was one case associated with Noonan's Syndrome and one case associated with Prune belly syndrome.

The testis was in the pubic region in 7 cases (2.66%) and in the inguinal region in 144 (54.75%) cases.

The testicle was impalpable in 16 (61.22%) undescended testicle, compared with 18 (57.7%) cases of Kodwawwala.

#### Aetiology of Testicular Maldescent.

Several theories have been advanced but the causes of maldescent remain unclear, Shapiro, et al. and Campbell, et al.<sup>4</sup>.

Normal testicular descent depends on several known factors and either one or more of them may be operative in any particular case. The factors are (1) a normal hypothalamic-pituitary-testicular axis, (2) a normal testicular production of androgen, (3) adequate end-organ utilisation of androgen, (4) a normal gubernaculum (5) a normal intra-abdominal pressure, (6) spermatic vessels of adequate length, (7) a vas deferens of adequate length, (8) absence of blockage within the inguinal canal, (9) a genetic factor may play a role since undescended testis is both familiar and inherited.

In this series there were 37 (14.08%) short vas deferens.

The length of the spermatic vessels was inadequate (Short in 67 (25.48%).

In 2 (1%) cases there was nonunion of the testis and the epididymis.

The entrance to the scrotum also known as the 3rd ring of McGregor was covered by fibrous tissue which partially or completely shut it off from the scrotal sac in 217(82.52%).

In 8 families the condition affected more than one child. In one family the father had had undescended testis treated and his two sons had testicular maldescent. Here it appears hereditary in this family.

Abnormal intra-abdominal pressure may be operative in the one case of prune belly syndrome.

The end-organ utilisation may have been at fault in the two (2) case of non-fusion of the testis with the epididymis. And currently the concept of end-organ failure best accounts for unilateral cryptorchism 136(68%) (Witherington)<sup>18</sup>.

In bilateral cryptorchism a defect in the hypothalamic-pituitary-testicular axis may explain it better.

### Pathology of Cryptorchidism

#### Surgical findings.

Undescended testis is highly associated with congenital hernia, usually the indirect type, due to failure of processus vaginalis to close.

In this series there were 162 (61.98%) patent hernial sacs. This compares well with 18 (66%) hernia association in the series by Kodwawwala.

The testis was intra-abdominal in 28 (10.64%) cases compared with Dougall and Maclean<sup>8</sup>.

The testes was in the inguinal canal in 185 (70.3%) cases compared with 70% in Campbell<sup>14</sup> and 80% in the series by Flach given by Selwyn.<sup>10</sup>

Two cases were associated with torsion of the spermatic cord. In two cases there was nonfusion of testis with the epididymis.

Seven cases were associated with hydrocele.

The vas deferens was inadequate in length in 37 (14.08%) cases.

The spermatic vessels were inadequate in length in 67 (25.48%)

This shows the spermatic vessels are commonly short compared to the vas deferens.

The third inguinal ring of McGregor, that is the entrance to the scrotum, was shut off in 217 (82.52%) cases.

The testis was atrophic in 32 (12.16%) cases.

Testis was smaller in 86. (32.69%).

The histology of 14 (7%) cases that had biopsy done showed that 3 out of 14 had normal testicular tissue with normal spermatogenesis. Eleven (11) out of fourteen testes showed fibrous tissue without testicular tissue.

The testicular morphological changes start from 5 years onwards in cryptorchism. Below 5 years the histological appearance of the cryptorchid testis and the scrotal testis are identical (COOPER ARE<sup>40</sup> AND SAHVAL).<sup>16</sup>

In these series none of the cryptorchid testis presented with malignancy. Many workers agreed that the incidence of testicular malignancy is quite high, 1.500 cases of cryptorchidism by Manson Brown<sup>31</sup>. A probability of a malignancy developing in an undescended testis is 20 to 50 times greater than in a normally located scrotal testis was given by Johnson, Woodhead, et al.<sup>12</sup>

In East Africa testicular tumours are not very common. The testicular tumour seen often is the Burkitts Lymphoma affecting the testis (OWOR). Seminomas, teratocarcinoma, and teratomas are rare.

The fertility is affected in cryptorchid testis. The unilateral cases of undescended testis are about 35% - 60% fertile.

Bilateral cases are almost 100% sterile unless treatment is instituted in good time.

#### Diagnosis of Cryptorchism.

The diagnosis rested largely on palpation and a history of absence of a testicle from the scrotum. The testis was palpable in 102 (38.78%) and impalpable in 161 (61.22%). The testes were found in intra-abdominal location are non palpable testes, extra-canalicular testes are always palpable. Intra-canalicular testes are sometimes palpable. Rule out orchidectomy.

#### Laboratory data and other findings

In one patient intravenous urogram was done to rule out associated urinary tract anomalies. No anomaly was found. Shapiro and Bodai<sup>4</sup> give the incidence of urinary tract anomalies in cryptorchism as 3 - 20%.

**TWO** patients had haemoglobin less than 10gm%

Sixteen (16) (8%) had a positive urine culture and sensitivity. I. Coli organisms were grown sensitive to Nalidix acid.

Two patients had ova and cysts in their stools.

In two patients (1%) buccal smear was done and no burr bodies were found.

Two patients had chromosomal studies. It revealed a normal male Karyotype 46xy.

The aim here was to rule out intersex.

The histology was abnormal in eleven (11) cases. It showed fibrous tissue without testicular tissue.

#### The Management of Cryptorchid testis

Two (0.76%) patients were put on a trial for spontaneous descent. Both patients were above seven years of age. Spontaneous descent did not occur.

Two (0.76%) patients were put on a hormonal therapy using a short course regimen of 10,000 i.u. of chorion gonadotrophin hormone administered intramuscularly in 3 equal doses on alternate days. The testes did not descent into the scrotum. Both cases were unilateral cryptorchidism.

Good hormonal therapy results are obtained in bilateral cases and between 2-5 years of age (Ehrlich, Lattimer, Dougherty and et al)<sup>13</sup>.



All the 200 (100%) patients had surgery.

214 (81.33%) testicles had a single stage orchidopexy.

35 (13.3%) testicles had a two stage orchidopexy.

14 (5.2%) testicles were done orchidectomy for various reasons among them tiny atrophic testis, torsion of testis with gangrene and accidentally severed spermatic vessels and cord-leading to gangrene of testis.

Surgery here is aimed at:

1. maximizing fertility potential
- 2) preventing diminished testicular hormone production,
- 3) minimizing the occurrence of germ cell tumours of the testis,
- 4) correcting associated hernia,
- 5) preventing torsion,
- 6) minimizing potential trauma to the testis,
- 7) correcting associated hydrocele,
- 8) achieving a cosmetic result,
- 9) arraying the patient's psychological feelings.

In unilateral cases done orchidopexy before 5 years of age, fertility potential increases to 100% (Karcher)<sup>31</sup>

In bilateral cases the chances of sterility are high. The fertility potential rises from near 0 to 50% in those done

orchidopexy before the age of 5 years (Charny)<sup>17</sup>.

The testicular hormone production is improved as the testis is placed into the scrotum which has ideal temperature compared to those intra-abdominally where the temperature is 2.2°C. higher and in the inguinal canal where the temperature is 0.9°C. higher.

The placement of the testicle in the scrotum makes it easily accessible to palpation and in the event of tumour developing it will easily be discovered. Testicular tumours are known to have occurred 10 to 18 years following a successful orchidopexy (O'Donnell and Jaffer)<sup>39</sup>.

Hernia when associated with an undescended testicle is an indication for doing orchidopexy early. The hernia can easily cause strangulation (Gonzales)<sup>32</sup>. 89 (33.84%) herniae were seen in this series.

Torsion of spermatic cord occurs quite often. In this series there were 2 torsions (Reigler)<sup>19</sup>.

Trauma will result in the damage of the undescended testis in an abnormal position. Orchidopexy offers protection.

A testicle well placed in the scrotum is safe.

The psychological feelings of absent testicle or empty scrotum are arrayed with orchidopexy.

### Timing for Orchidopexy

The following periods are recommended by different workers:

- 1) Three weeks to 52 weeks (Scorer)<sup>15</sup>.
- 2) Nine to eleven years (Gross<sup>27</sup> and Brown)<sup>31</sup>.
- 3) Most clinicians suggest that the optimum time for orchidopexy is prior to five (5) years of age (Johnson)<sup>28</sup>.

In this series the majority of the patients 140 (70%) were seen and treated between 0 - 9 years. The peak was between 4-9 years.

### Types Orchidopexy Employed.

Three types of orchidopexy operations were used in this series. The dartous pouch technique<sup>5</sup> was used in 165 (82.5%) patients and is the one recommended by many workers these days. It has good success rates.

The Keetley<sup>7</sup> Torek Operation<sup>6</sup> was used in 8 (4.0%) cases. The disadvantage here is that its a two stage operation and tension at the first operation could impair blood supply to the testis. Hence atrophy of testis could result.

Ombredanne operation<sup>33</sup> was used in only two (2) (1%) cases.

In 25 (12.5%) cases the type of orchidopexy used was not specified.

The final result of orchidopexy depends on whether the basic principles advanced by Bevan at the turn of the century were observed. These are (1) mobilisation of the testis so that it is free from tension, 2) sufficient dissection to obtain adequate length of spermatic vessels for placement of the testicle into the scrotum, 3) Retention of the testicle in the scrotum, and (4) repair of the associated hernia.

In all these 200 patients the inguinal approach was used.

The final result of orchidopexy is judged by

- 1) the size of the testis
- 2) the consistency of the testis.
- 3) the final position of the testis.

In this series the size of the testis was the same in 36 (26.4%) cases.

The consistency was the same in 28 (20.53%) cases.

The testis was at the bottom of the scrotum in 160 (60.8%) cases and at the upper end of the scrotum in 26 (9.8%) cases. Here the result was 60.8% satisfactory compared with 70% in Brown's series.

The complications that occurred during the management of these patients were wound infection 5 (2.5%) cases. Atrophy

of the testis 18 (9.8%), retraction of the gonad 26 (9.8%) cases, recurrent hernia 3 (1.8%), damage to the vas deferens 2 (0.7%).

### Prognosis

The prognosis is considered from two important aspects.

- 1) Future fertility and,
- 2) Future malignant change.

### Future fertility

A) Bilateral undescended abdominal or inguinal testes do not produce spermatozoa and if the defect persists after puberty the patient will be sterile.

B) In unilateral undescended testes fertility is identical in the treated and untreated cases.

C) Ectopic testes - these are usually well developed. If they are placed in the scrotum before puberty the patient will probably be fertile.

### Malignancy

Malignancy in non-descent testes is roughly 1:500 (Brown)<sup>31</sup> It is less common in patients done orchidopexy before the age of 5 years.

The majority of the tumours after orchidopexy were seen in those who were operated on after the age of 6 years. (Johnson and Woodhead, et al.)<sup>12</sup>.

Recommendations for the clinician

- 1) Orchidopexy be done or performed prior to the age of 5 years and not after the age of 10 years.
- 2) Strong consideration be given to performing an orchidectomy in patients with unilateral cryptorchism diagnosed after 10 years.
- 3) Careful periodic examination of both scrotal compartments be made mandatory in all patients with cryptorchism treated either by orchidopexy, hormonal therapy or orchidectomy.
- 4) Biopsy should be done routinely in the older children specifically to search for carcinoma in situ.

Recommendations for the patients

- 1) Teach all men aged 20 to 50 years to self examine their testes periodically.

Recommendations for the parents.

- 1) All parents be made aware that cryptorchidism is treatable and that they should not hide children who suffer from this condition.
- 2) The parents should be advised to seek medical treatment for their children who suffer from cryptorchism at an

early age, preferably before the age of 5 years.

- 3) Parents should be made aware of the low fertility rate of cryptorchid testes.
- 4) They should also be made aware of the high probability of a neoplasm developing in an undescended testis.

### Conclusion

Orchidopexy is the cornerstone of therapy for cryptorchidism and is currently believed it should be done before the age of 5 years when the testicular morphology begins to change.

The undescended testis is placed into the scrotum surgically for the following reasons:-

- 1) to repair an accompanying hernia,
- 2) to prevent torsion of the spermatic cord,
- 3) to assure the greatest possibility of fertility especially in bilateral cases.
- 4) to prevent trauma which may damage the testes,
- 5) to achieve cosmesis,
- 6) to permit easy palpatory examination of the testis so that malignancy can be discovered early.
- 7) to ~~array~~ allay the psychological anxieties in the parents and the patient as well.
- 8) to correct associated hydrocele.

9. And testicular function to be assessed in the follow-up cases after orchidopexy by doing sperm count and testosterone in the serum estimation. Serum testosterone increases after human chorionic gonadotrophin challenge.



REFERENCES

1. Yusuf · Kodwawwala,  
Imperfectly descended testicle - A review.  
Fast African Medical Journal Volume 42 No. 7  
July 1965.
  
2. Stephen, R.A.  
Malignant testicular tumours.  
Ann. Roy. Coll. Surg. of England.  
23: 71, 1958.
  
3. Malik,  
Tumours of male genitalia - Khartoum, East  
African Medical Journal, Volume 56, page 229, 1979
  
4. Stephen R. Shapiro, Balazs Imre Bodai.  
Current concepts of the undescended testis.  
Surgery gynaecology and obstetrics.  
147: 617-625, 1978.
  
5. Benson and Lofti.  
The Dartous Pouch Technique.  
Surgery 62: 967, 1967.
  
6. Terek, F.  
Technique of orchiopexy  
New York Journal of Medicine.  
90: 948, 1908.

7. Keetley, C.B.

Temporary fixation of testis to thigh - a series of 25 cases of undescended testes.

Lancet 2: 29, 1905

8. Dougall, A.J. Maclean, N., Wilkinson, A.W.

Histology of the undescended testis at operation.

Lancet 1: 771 - 289, 1971.

9. Robert Flinn. and Lowell R. King.

Experiences with the midline Trans-abdominal approach in orchiopexy.

Surgery, Gynaecology and Obstetrics.

133: 285-289, 1971

10. Selwyn, B., Levitt, J., Stanley, J., Kogan, M., et al.

The impalpable testis - A rational approach to management.

Journal of Urology, 120: 515. 1978.

11. Denis Browne, M.B., Sydney,

Some anatomical points in the operation for undescended testicle. Lancet 1: 460, 1933.

12. Douglas E. Johnson, Captain USAF.

David M. Woodhead, Major MC.

Donald R. Fohl Captain USAF.

Jack R. Robinson Col. USAF.

Cryptorchism and testicular tumorigenesis.

Surgery 63: 919 - 921; 1968

13. Richard M. Ihrlich, Phillip Tomashefsky, Louis J. Dougherty,  
John K. Lattimer.

Effects of gonadotrophin in cryptorchism.

Journal of Urology 102: 793-795; 1969

14. Campbell, F.M. and Harrison.

Improperly descended testis

Urology Vol. 2 page 1628-1644; 1970

15. Scorer, C.G.

Treatment of undescended testis

Lancet 2: 1123; 1957.

16. Sohval, A.R.

Histopathology of cryptorchism - compared scrotal  
and undescended testes.

American Journal of Medicine. 16: 345-346, 1954.

17. Charny, C.W.

The spermatogenic potential of the undescended testes  
before and after treatment.

Journal of Urology 83: 697, 1960.

18. Roy Witherington.

Cryptorchism and approaches to its surgical management.  
Surgical clinics of North America.

Vol. 64: No. 2 April 1984

19. Reigler, H.C.  
Torsion of intra-abdominal testis  
Surgical clinics of North America.  
Vol. 52: 371, 1972.
  
20. Whitaker, R.H.  
Management of the undescended testis.  
Br. J. Hosp. Med. 4: 25, 1970
  
21. Martin, D.C.  
Malignancy in the cryptorchid testis.  
Urology clinics of North America 9: 371, 1982.
  
22. Prentiss, R.J., Weickgenant, C.J., Moses, J.J., et al.  
Undescended testis: surgical anatomy of spermatic  
vessels, spermatic surgical triangles and lateral  
spermatic ligament.  
Journal of Urology 83: 686, 1960.
  
23. KieseWetter, W.B., Shull, W.R. and Feherman, H.G.  
Histologic changes in the testis following the  
the anatomically successful orchiopexy.  
J. Pediatric Surg. 4: 59, 1969
  
24. Scorer, C.G. and Farrington, G.H.  
Congenital deformities of the testis and epididymis.  
New York, Appleton - Century-Crofts, 1972.

25. Bevan, A.D.

Operation for undescended testicle and congenital hernia.

JAMA. 33: 773, 1989.

26. Robinson, J.N. and Engle.

Some observation on cryptorchid testis.

J. Urology 71: 726, 1954.

27. Gross, R. E. and Replogle, R.L.

Treatment of the undescended testis, opinions gained from 1767 operations.

Postgrad. Medicine 34: 266, 1963

28. Johnson, J.H.,

The undescended testis.

Arch. Dis. Child. 40 113, 1965

29. Persky, L. et Albert, D.J.,

Staged Orchiopexy.

Surg. Gynae and Obst. 132: 434, 1971.

30. Firor, H.V.

Two stage orchiopexy.

Arch. Surg. 102: 598-599, 1971

31. Manson Brown J.J.

Undescended Testes.

Surgery of childhood edited by J.J. Manson Brown.

Page 1135, 1962

32. Edmond T. Gonzales, Jr.  
Orchidopexy and herniorrhaphy  
Urologic Surgery, 2nd edition edited by James F. Glenn.  
Chapter 58: pages 808.
33. Paediatric Surgery 2nd Edition, Volume 2, 1972.  
Edited by Mustard W.T.  
Ravitch, M.M. and Welch, I.J. et al,  
Pages 1292-1310
- 35: Raphael Owor.  
Epidemiology of cancer in East Africa.  
Postgraduate Doctor. The Journal of prevention,  
diagnosis and treatment.  
Vol. 7, No. 1, page 19, January 1985.
36. Lattimer, J.K.  
The optimum time to operate for cryptorchidism.  
Paediatrics 53: 96, 1974.
37. Fonkalsrud, I.W.  
Current concepts in the management of the undescended  
testicle.  
Surgical clinics of North America. Vol. 50: 847, 1970.
38. Scorer, C.G.  
The descent of the testis. Arch. Dis Child. 39:  
605, 1964.

39. Jaffer, D.J. and O'Donnell, K.T.

Testicular Tumour 18 years following orchiopexy.  
J. Urol. 104: 878, 1970.

40. Cooper, F.R.A.

The histology of retained testes in human subject  
at different ages and its comparison with scrotal  
testes. J. Anat. 64: 5, 1929.

41. Hinman, F.Jr.

Optimum times for orchiopexy in cryptorchidism.  
Fertil. Steril. 6; 206, 1955.

42. Sohval, A.R.

Testicular dysgenesis as an aetiologic factor in  
cryptorchidism. J. Urol. 1954- 72: 693.

Appendix 1 (i)

Date of Admission

CRYPTORCHISM

Date of Discharge.

Name                      Age                      Sex                      Province

Premature                      Birth weight

Fullterm

Medical History

Onset of Illness.

Symptoms

- a) Pain
- b) Chronic Discomfort
- c) Swelling
- d) Absent of testicle noticed by:
  - a) mother
  - b) father
  - c) patient himself.

Signs of Physical Examination

- a) small empty scrotum
- b) unilateral cryptorchism.
  - i) Right side cryptorchism
  - ii) Left side cryptorchism.
- c) bilateral cryptorchism
- d) swelling in:
  - i) inguinal region
  - ii) pubic region
  - iii) perineal region
  - iv) femoral region
  - v) penile region.



Appendix 1 (ii)

Association with hernia.

Association with torsion

Association with hydrocele

Association with hypospadias.

Association with other syndromes.

Testicle(s) was      a) palpable  
   b) impalpable  
   c) milked out.

Investigations

A) Routine Investigations.

- 1) Haemogram
- 2) Area/electrolytes
- 3) Mid-stream urine check for
  - a) sugar
  - b) albumia
  - c) culture and sensitivity.
- 4) Stool for ova + cyst.
- 5) Liver function tests.

B) Special Investigations.

- 1) Intravenous urogram.
- 2) Buccal smear
- 3) Chromosomal Karyotyping.
- 4) Biopsy and Histology.

Appendix 1 (iii)

Treatment

1. Spontaneous Descent
2. Hormonal therapy
3. Orchiopexy
  - a) single stage
  - b) two stage.
4. Findings at operation
  - a) position of testis
  - b) length of vas deferens
  - c) length of spermatic vessels
  - d) condition of the testis
    - i) soft or firm
    - ii) atrophic
  - e) hernial sac or open processus vaginalis
    - i) present
    - ii) absent
  - f) entrance to the scrotum
    - i) covered by fibrous tissue
    - ii) patent.
- 5) Orchiectomy
6. Final position of testis
  - a) undescended - at upper end of scrotum
  - b) descended into scrotum.

