

2

A REVIEW OF THE FIRST CT SCANS OF THE  
HEAD IN PATIENTS REFERRED FROM  
KENYATTA NATIONAL HOSPITAL.

A dissertation submitted in part-fulfilment for the  
degree of Master of Medicine (Diagnostic Radiology),  
University of Nairobi.

by

DR. I.C. STREHLAU, M.B., Ch.B.

MAY, 1988.




MEDICAL LIBRARY  
UNIVERSITY OF NAIROBI

DECLARATION

This dissertation is my original work and has not been presented for a degree in any other University.


Signed: \_\_\_\_\_



DR. I.C. STREHLAU, M.B.Ch.B.

This dissertation has been submitted for examination with my approval as a University Supervisor.

Signed: \_\_\_\_\_



DR. N.E. ADAMALI, MBBS, DMRD, FRCR.

TABLE OF CONTENTS

	<u>Page</u>
SUMMARY .. .. .	1
INTRODUCTION .. .. .	3
OBJECTIVES .. .. .	7
MATERIALS AND METHODS .. .. .	8
RESULTS .. .. .	14
Tables I - VII .. .. .	19 - 25
Figures 1 - 15 .. .. .	41 - 56
Table VIII .. .. .	61
Table IX .. .. .	64
DISCUSSION .. .. .	65
CONCLUSION .. .. .	90
REFERENCES .. .. .	91
ACKNOWLEDGEMENTS .. .. .	103

*Arthrography*

**MEDICAL LIBRARY  
UNIVERSITY OF NAIROBI**

## SUMMARY

A total of 109 patients with CT scans of the head from Kenyatta National Hospital were reviewed. Twenty eight per cent of the patients were children under 10 years of age; the majority of whom had a CT diagnosis of primary brain tumour. Primary brain tumours were the commonest intracranial lesions observed and accounted for 87%. The next common intracranial lesion was haemorrhage following trauma. Hydrocephalus was found in 19% of patients (70% were secondary to obstructing masses, 10% due to brain atrophy, 10% due to aqueductal stenosis and in 10% no demonstrable cause was shown).

90% of patients had a provisional diagnosis of space occupying lesion and headache was the most frequent presenting symptom (53%).

The accuracy of CT scanning as a screening technique was found to be 100% (there were no false negatives although the follow-up period was short). By comparison, the diagnostic accuracy for plain skull radiography was found to be 49%, air encephalography/ventriculography 83% and angiography 69%. The diagnostic accuracy of CT for specific lesions e.g., traumatic haemorrhages, hydrocephalus, CSF cysts was found to be high and less for other lesions e.g., abscesses, tumours.

A large number of patients were operated upon without invasive contrast studies e.g., angiography

(66%). Hospital stay after CT was done and before definitive treatment commenced was found to be shorter (average 17.6 days) than hospital stay before CT was done (average 27.5 days).

[Faint, illegible text block]

[Faint, illegible text block]

## INTRODUCTION

### Historical Note

The idea of matrix representation to visualize inaccessible structures has been used in fields as diverse as electron microscopy, radio-astronomy and radio-isotope brain scanning (4).

In January, 1961, Oldendorf, a practicing Neurologist, described an experimental system which, in theory, he thought ought to be able to produce a cross-sectional display of "radio-density discontinuities" within the cranium (3,4). Unfortunately, the idea was not developed and remained in abeyance until Hounsfield, using x-rays, independently developed a usable diagnostic system in 1972 (3,7,32). This investigation is regarded by many people as the greatest step forward in radiology since the discovery of x-rays by Roentgen in 1895. It resulted in the 1979 Nobel prize for Medicine being awarded jointly to Hounsfield and Cormack (35,55).

Computerized Tomography (CT) is an easily accomplished, non-invasive, rapid examination where small differences in tissue attenuation not recorded by conventional radiography can be shown (8,35). Since the introduction of CT Scanning, there has been a remarkable revolution in the medical treatment of patients. Many patients have

been saved or their quality of life improved as a result of the accurate diagnosis provided by CT (29).

Overwhelming success has been seen in its application to neuroradiology (8,9,47,50) for example, in the detection of atrophic processes, both primary and secondary tumours, vascular lesions including haemorrhage and infarction, infective processes, developmental anomalies and degenerative diseases. In psychiatry, computerized tomography has been used to rule out underlying organic disease.

Delineation of the normal brain scan has been of greatest value to the clinician and patient by minimizing the need for hospitalization and more invasive or hazardous procedures. Fewer pneumoencephalograms and radionuclide brain scans are being performed and **the percentage** of negative cerebral arteriograms has been sharply reduced. In two studies (8) and (23), since the introduction of this technique, air studies have diminished by 66%, cerebroangiographic procedures by 34% and radionuclide brain scans by 29%. Another study (62) estimated a possible savings of US \$2,000,000 per year per CT unit (as quoted in 1975). These predictions were based on savings in hospital days and diagnostic procedures, the estimated

savings were validated by statistics in pneumo-encephalography but not with angiography. These investigations remain necessary in certain patients and the space and equipment (and to some degree personnel) must be maintained at high costs.

Computerized tomography has, also, played a major role in neuroradiology in lesions of the spine e.g., trauma, disc prolapse, anatomical defects, tumours, spinal stenosis and infections. There are over 200 indications for CT Scanning in other parts of the body. One important aspect is the **detection** of lymph node enlargement and tumour recurrence in the abdomen, thorax and axillae when not demonstrated by other radiological methods including conventional tomography, lymphography and arteriography. This information has proved invaluable for radiotherapy, chemotherapy or surgery in these patients (23,35).

The future is expected to bring the development of methods of obtaining useful images of the heart and of visualizing the coronary arteries. Aside from the imaging advantages provided, the role of computerized tomography in planning and performing interventional procedures is now recognized. It is the most accurate method for **guiding** procedures to obtain cytolo-

gical, histological or bacteriological specimens and for performing a variety of therapeutic procedures (29).

The evolution and refinement of CT equipment has been as remarkable as the development of patient diagnosis. Initially, a 5 minute translate-rotate system was used (4,32). Currently, standard units in radiological practice are 3rd and 4th generation scanners with scan times of less than 5 seconds. All modern systems are more reliable than the earlier equipment. The contrast and spatial resolution of these systems are in the range of 0.5% and less than 1 mm respectively. The sophistication of the computer programmes that aid in the diagnosis is, also, remarkable. There are now programmes for three-dimensional reconstructions, quantitation of blood flow, determination of organ volume, longitudinal scans (Scoutview, Deltaview, Synerview and Topogram) and even triangulation programmes for performing percutaneous biopsy procedures.

These foregoing facts point out the advantages of computerized axial tomography; the only disadvantages being the enormous costs of purchase, installation and maintenance. This brings out the cost benefit dilemma that contributed to the undertaking of this study.

## OBJECTIVES

1. To evaluate the type of patients referred for CT Scanning from Kenyatta National Hospital (KNH) and whether the referrals were justified.
2. To assess the diagnostic accuracy of CT Scanning compared to other radiological investigations done.
3. To determine whether the presence of CT Scanning has had any influence in reducing the number of carotid angiograms, air encephalograms or ventriculograms required.
4. To ascertain whether CT Scanning has any influence on patient hospital stay and, therefore, cost to the hospital.
5. If results suggest that CT Scanning is a useful investigation in terms of diagnostic accuracy, reducing time and cost of diagnosis evaluation in these patients (thereby reducing morbidity), then this study may be used to influence any future proposals for the installation of a CT Scanner at Kenyatta National Hospital.

## MATERIALS AND METHODS

There are three CT Scanning units currently available in Nairobi in the private sector, namely at the M.P. Shah Hospital, Aga Khan Hospital and at the Nairobi Hospital. Presently, patients from KNH are referred to the first two hospitals where reduced fees are offered to them. Some patients have been scanned free of charge out of academic interest after consulting with the attending physicians. In this study, all the patients were referred by the attending physicians and although many patients were recommended to undergo the examination, some were unable to raise the necessary funds to have the scans done. The hospital authority has undertaken to pay the costs in certain special cases where the neuro-physician or neurosurgeon has made a written request.

A study was carried out on a total of 109 patients who were referred for CT of the head over a 10 month period beginning March, 1987. A large part of the study was prospective but a few cases were done retrospectively since the installation of the first CT Scanner in May, 1986.

It was not possible to include all the patients referred for head CT in the study as some of the files were not traceable and a few did not have a

report of the CT findings.

There were a total of 107 in-patients and two out-patients.

The data includes:-

- demographic data e.g., sex, age
- where referred **from initially** (if not KNH)
- clinical features including duration
- provisional diagnosis
- other radiological investigations done and findings
- CT Scan findings
- length of hospital stay (before CT Scan, after CT Scan and before definitive treatment commenced)
- management and outcome
- final diagnosis (either histopathology or post-mortem examination)

### CT Scanning Equipment

The CT Scanners used in this study are third generation Siemens (Somatom C-R) units.

The Somatom CR works according to the fan-beam principle with rotating detectors and pulsed X-ray radiation. The principle is particularly suitable for the construction of fast scanners; even at low dose, images with high resolution can be achieved. In computed tomography, the x-ray

output is collimated to a very narrow beam and after passing through the patient, it is partially absorbed and the remaining photons of the x-ray beam fall on a rotating detector instead of x-ray film. The detector response is directly related to the number of photons impinging on it and so to tissue density since a greater proportion of x-ray photons passing through dense tissues are absorbed than are absorbed by the less dense tissues. When they strike the detector the x-ray photons are converted to scintillations which can be quantified and recorded digitally. The information is fed into a computer which produces different readings as the x-ray beam is traversed around the subject. The digital readings can be presented as a numerical read out representing the absorption in each tiny segment of the section traversed. This information can, also, be presented in analogue form as a two dimensional display of the matrix on a screen where each numerical value is represented by a single picture element (pixel). Image reconstruction and storage in the Somatom-CR takes place in a 256 x 256 matrix. On the other hand, the image is displayed in a 512 x 512 image matrix. The number of measuring channels in the asymmetric fan amounts to 384.

Technical Data

Measuring System

Scan field : 48 cm diameter  
Slice thickness : 3 slice thickness  
selectable: 2, 4 and  
8 mm

X-ray System

X-ray generator : high frequency generator  
with computer controlled  
regulation and parameter  
selection  
Pulse duration : 2 and 4 ms  
Pulse frequency : maximum 110 pulses/s  
Constant voltage : 125 kV  
mAs : 170-670 mAs

Scan Data

Slices per scan : 1  
Measuring times : 3 sec., 5 sec., 6 sec.,  
depending on the programme  
Fastest scan sequence : up to 8.5 scans per minute

Image Reconstruction and Display

Image reconstruction time: 6-9 secs. for standard  
scans  
CT value scale : -1000 to +3071 HU  
(Hounsfield Units)

Routine cuts were taken starting at the base of the skull through the posterior fossa and sella region at 4 mm intervals and then 8 mm intervals through the remainder of the brain. The tube was angled 0-25° depending on the position of the head. Intravenous contrast material (1 ml/kg of sodium meglumine diatrizoate 60% or meglumine iodamide 300) was generally used in patients suspected of having tumours, vascular malformation, inflammation etc. It was generally not used in patients with trauma and in some cases of infarction. Restless patients were sedated. There were facilities for obtaining coronal and sagittal sections by computer reconstruction of the axial slices. Permanent records of the images were obtained on single emulsion x-ray films. Some of the images were stored on floppy discs.

### Radiation Risk

In modern CT systems, the x-ray tube revolves around ~~the~~ patient and exposes an extremely narrow field which reduces scattered radiation. At a constant voltage of 125 kV, the absorbed dose is a function of mAs product and the number of projections in each scan. At 125 kV and 230 mAs, the maximum skin dose is 125mGY (1.25 rad) with the Somatom-CR, and this value is independent of exposure, number of projections and thickness of slice.

Some of the difficult (non-specific) cases were discussed with other senior radiologists in the department when the films were available. This was especially true of the cases where definitive radiological diagnosis could not be made and, also, in cases where the CT diagnosis differed with the findings at surgery or histopathology.

Follow-up information was obtained on all patients until the end of the study period. This included cases where scans were reported as normal. If no pathology was revealed on further investigation and follow-up in the normal scans, it was assumed that the CT scan diagnosis was correct.

Some of the patients were scanned more than once for follow-up of the progress of a lesion and for diagnosis of post-operative complications.

There were no medico-legal considerations as the study involved merely a collection of data for an investigation that exposed a patient to a permitted dose of radiation.

The results were presented in a tabular form, commentary and some cases were documented by photographs.

## R E S U L T S

### General Characteristics

A total of 109 patients were studied. All the patients were studied for a new neurological or neurosurgical problem; except for a known case of medulloblastoma who underwent CT to monitor recurrence of tumour.

Sixty four cases were males and 45 cases were females.

The age distribution is presented in Table I. Twenty eight per cent of the cases were children aged 0 - 10 years; the youngest patient being 5 months of age.

Table II shows the areas where the patients were initially referred from. A large number of patients (38%), as expected, were from around the Nairobi area i.e., some from out-patient clinics and the majority admitted from casualty or out-patient clinics.

Forty seven per cent were patients referred to KNH from Government hospitals in other parts of the country. Another 15% were cases referred to KNH by private doctors, clinics and hospitals. ~~On referral for~~ CT, most patients had a provisional

diagnosis of space occupying lesion (89.9%).

Headache was the commonest presenting symptom and was seen in 53% of patients (see Table III). The next most common symptom encountered was weakness of the upper and lower limbs, mainly hemiparesis, found in 40%. Other fairly common symptoms were impaired vision (18%), vomiting (22%), mental changes (18%) and convulsions/twitching (21%). Cerebellar signs were encountered in 16% of patients. Other signs encountered are shown in Table IV.

The majority of patients had symptoms for a duration of 1 week - 1 month (29%) and >1 month - 6 months (30%) (see Table V).

Several patients had more than one type of lesion demonstrated on CT Scanning. However, 40% of patients in the study had a CT diagnosis of primary brain tumour (see Table VI). The next frequent diagnosis was haemorrhage; subdural haematomas accounting for 14%, extradural haematomas 3% and intracerebral haemorrhage 1%. Brain atrophy was found in 6% of cases and hydrocephalus was found in 19% of patients. Seventy per cent of hydrocephalus was found to be secondary to obstructing masses, 10% due to brain atrophy, 10% due to Aqueductal Stenosis and 10% showed no demonstrable lesion.

Fourteen per cent of CT Scans done did not demonstrate an intracranial lesion and were reported as normal. On follow-up, 2 cases were confirmed as suffering from SSPE (Subacute sclerosing panencephalitis) from measles anti-body titres and 3 patients were thought to be psychiatric cases. Sixty seven per cent of the patients with normal scans improved with physiotherapy. Neither further investigation in hospital nor the subsequent course of their illness revealed a structural brain lesion and, therefore, it was assumed that the diagnosis was correct.

All the scans done were technically satisfactory.

Three cases were listed as unknown in the Table and are discussed separately here:-

#### Unknown I (D.W.)

A 12 year old male patient presented with a 4 month history of left hemiparesis and right VII, VIII and IX cranial nerve palsies. Skull X-ray was normal. Both carotid and vertebral angiograms were done and were normal apart from a rapid circulation time. CT scan revealed a hyperdense area in the brainstem and a bleed was queried in the report. The neurosurgeons thought it was a brainstem tumour and decided it was inoperable. The patient passed away one week after the scan was done and no post-mortem study was

done.

#### Unknown II (L.A.)

A 19 year old female patient presented with a one year history of right sided weakness. Carotid angiogram done was initially reported as normal. Retrospectively, after CT Scanning was done, some radiologists felt there was elevation of the middle cerebral artery on the side not done (left) with crowding of vessels in the temporal area.

CT showed a large area of low attenuation in the left temporoparietal region, with associated compression of the left lateral ventricle and minimal shift of midline. After contrast, there was an area of rim enhancement. Several differential diagnosis were made which included cerebral abscess with marked oedema, glioma and hydatid cyst (as the patient came from an area where the disease is prevalent). The patient passed after while still in the ward before surgery was done. No post-mortem study was requested.

#### Unknown III (K.W.)

A 11 year old male patient was referred with a 2 month history of vomiting, twitching starting on the right side of the body and abnormal behaviour. The skull X-ray showed no abnormality. CT

revealed an isodense mass just to the left of the midline, in the region of the thalamus, indenting upon the lateral ventricle and showing displacement of vessels. No abnormal vascularity or enhancement was demonstrated. Ventriculography was suggested but not done. Instead, carotid angiography was done and reported as normal. The patient was still awaiting biopsy at the end of the study period.


AGE	NO.	%
0 - 10 yrs.	31	28
11 - 20 yrs.	14	13
21 - 30 yrs.	18	17
31 - 40 yrs.	17	16
41 - 50 yrs.	9	8
51 - 60 yrs.	6	5
61 - 70 yrs.	7	6
>70 yrs.	7	6
TOTAL	109	~ 100

TABLE I: AGE DISTRIBUTION OF PATIENTS

AREA REFERRED FROM	NO. OF CASES	%
NAIROBI AREA	41	38
CENTRAL PROVINCE	15	14
WESTERN PROVINCE	3	3
NYANZA PROVINCE	5	5
EASTERN PROVINCE	12	11
NORTH EASTERN PROVINCE	3	3
RIFT VALLEY PROVINCE	10	9
COAST PROVINCE	4	4
PRIVATE CLINICS/HOSPITALS	16	15
TOTAL	109	~100

TABLE II: AREA PATIENTS ORIGINALLY REFERRED FROM

SYMPTOM	NO. OF CASES	%
Headache	58	53
Impaired vision	20	18
Diplopia	8	7
Vomiting	24	22
Dizziness	10	9
Mental changes	20	18
Convulsions/twitching	23	21
Weakness upper/lower limbs	44	40
Impaired speech	9	8
Impaired hearing	2	2
Dysphagia	3	3
Nasal obstruction	1	1
Difficulty in breathing	2	2
Excessive bleeding	1	1
Increasing size of head	2	2
Endocrine manifestations	3	3

TABLE III: SYMPTOMS OF PATIENTS THAT UNDERWENT CT

SIGN	NO. OF CASES	%
Papilloedema/optic atrophy	17	16
Mental changes	20	18
Proptosis	3	3
Dysarthria	2	2
Aphasia	7	6
Weakness of limbs	44	40
Cranial n. palsies	9	8
Cerebellar signs	17	16
Altered state of consciousness	6	6
Fever	2	2
Irritability/bulging fontanellies	1	1
Hydrocephalus	2	2
Failure to thrive	1	1
Excessive bleeding	1	1
Endocrine manifestations	3	3

TABLE IV: SIGNS OF PATIENTS THAT UNDERWENT CT

TIME	NO. OF CASES	%
1 week	14	13
1 week - 1 month	32	29
>1 month - 6 months	33	30
6 months - 1 year	12	11
1 - 2 years	9	8
> 2 years	8	7
Unknown	1	1

TABLE V: DURATION OF SYMPTOMS

Diagnosis on CT	No. of cases	On Operation/Histology				Diagnostic accuracy %
		No. of cases confirmed	Correct diagnosis	False positive	False negative	
Primary tumour	44	23	20	3	0	87
Metastasis/extension	1	1	1	0	0	100
Subdural haematoma	15	12	12	0	0	100
Extradural haematoma	3	3	3	0	0	100
Cerebral oedema	2	-	-	-	-	-
Intracerebral haemorrhage	1	-	-	-	-	-
Cerebral infarction	4	-	-	-	-	-
A.V. Malformation	2	2	2	0	0	100
Aneurysm	1	1	1	0	0	100
Brain atrophy	7	-	-	-	-	-
*Hydrocephalus	4	3	3	0	0	100
Abscesses	3	2	1	1	0	50
Tuberculomas	1	1	1	0	0	100
Parasitic cysts (Hydatid)	1	1	1	0	0	100
Encephalocele	1	1	1	0	0	100
CSF cysts	2	1	1	0	0	100
Unknown	3	-	-	-	-	-
Normal	15	-	-	-	-	-

\*Does not include hydrocephalus due to obstructing masses or atrophy.

TABLE VI: CT DIAGNOSIS AND DIAGNOSTIC ACCURACY

DIAGNOSIS ON CT	HISTOLOGICAL CONFIRMATION		TOTAL NO. OF CASES	%
	OBTAINED	NOT OBTAINED		
*Glioma	7	11	18	43
Medulloblastoma	1	2	3	7
Meningioma	5	3	8	19
Cranio-pharyngioma	0	3	3	7
Pituitary tumour	1	5	6	14
Pinealoma	0	2	2	5
**Epidermoid cyst	1	0	1	2
Metastatic/extension	1	0	1	2
T O T A L	16	26	42	100

\*Glioma - On histology 4 were confirmed as astrocytomas, 3 as ependymomas

\*\*On CT - Cranio-pharyngioma was queried. Histology showed simple epidermoid cyst.

TABLE VII: ANALYSIS OF THE HISTOLOGICAL TYPES OF TUMOURS CONSTITUTING THE TOTAL SERIES

MEDICAL LIBRARY  
UNIVERSITY OF NAIROBI

Histological confirmation was obtained in 16 of the 42 patients with intracranial tumour (38%). (See Table VII). The false positive cases were not included.

In the remaining 26 patients the diagnosis is supported by the lesion characteristics such as site, density, enhancement with intravenous contrast medium, the subsequent clinical course or correlation with complementary investigations. In these patients no histology was obtained because 13 patients were still waiting to undergo surgery; 2 patients refused surgery, 5 tumours were inaccessible to surgery in the present hospital set-up, 1 patient died shortly after inserting a VP shunt and before biopsy taken in the second stage of the operation; one patient was pregnant and, therefore, unable to undergo surgery.

One patient was in poor general condition (semi-comatose) for over 6 months and, therefore, unable to withstand general anaesthesia; 3 biopsy specimens were either destroyed during preparation for histology or lost.

#### PRIMARY BRAIN TUMOURS

Tumours were revealed as areas of either increased or decreased tissue density, or a combination of the two when compared with the density of normal brain or isodense with normal brain tissue. Displacement, distortion or involvement

of major structures such as the ventricles were also, recognized. Some of the tumours exhibited perifocal oedema demonstrated as areas of reduced density clearly distinguishable against the grey substance.

### Astrocytomas

In the 4 patients with histologically proven astrocytoma, an abnormality was seen in all cases. The scans showed a varied density picture, 2 cases showed mixed density masses, one being ill-defined and the other well defined in outline. One case demonstrated a low density mass and the other was an isodense lesion. In three of the cases, the tumour mass caused significant obstructive hydrocephalus. In all the cases, there appeared to be slight enhancement in the higher density areas with no accumulation in the low density areas.

The tumours did not demonstrate a significant degree of perifocal oedema. In one of the scans, areas of calcification were noted within the mass.

Two of the astrocytomas were supratentorial in location while the other two were cerebellar astrocytomas. The astrocytomas were not graded histologically.

### Ependymomas

The tumours in the three cases were large increased density lesions. Two were found in children and one in a young adult of 25 years. One tumour showed small areas of calcification and in another there was evidence of breakdown. All the tumours caused some degree of hydrocephalus. Periventricular oedema was noted in one case. There was some enhancement with intravenous contrast material in all cases. Two of the patients had carotid angiography done; one was reported as normal and the other showed evidence of hydrocephalus.

### Medulloblastomas

There was only one case of histologically proven medulloblastoma in this study. This was in a child who was being investigated for recurrence and had destruction of the lumbar spine probably as a result of metastatic spread. The scan showed an ~~irregular~~ mixed density lesion in the cerebellum showing specks of calcification within it. There was dilatation of all the ventricles but no significant mass effect seen. IV Contrast did not show significant accumulation in the tumour areas.

### Meningiomas

There were 5 cases of histologically proven

meningioma that were situated at different sites; petrous apex, posterior fossa, anterior fossa and the tentorium. All the meningiomas in this study displayed sharply delineated hyperdense areas with one tumour having hypodense areas within it probably due to necrosis and breakdown because no enhancement occurred with IV contrast in these areas. Two of the tumours had a surrounding area of moderate oedema. One meningioma had areas of calcification within it.

All the tumours accumulated contrast medium intensely and homogeneously apart from the tumour with hypodense areas within it. Carotid angiography studies had been done in two of the patients, one showing a large vascular tumour with displacement of vessels while the other investigation had been reported as normal two years previously but the films could not be traced. One of the tumours showed sarcomatous change on histology. Post-operatively, the patient received radiotherapy and follow-up brain scans showed no recurrence at least six months after surgery.

### Craniopharyngiomas

There were no histologically proven cases of craniopharyngioma though there were 3 suspected cases as seen on CT. These cases were all observed in children under 10 years of age. Plain Skull

X-ray in one case showed destruction of the pituitary fossa with suprasellar calcification; one case showed sutural diastasis and another case was normal.

Carotid angiography was not done in any of the cases. CT showed well-defined mixed density masses arising in the midline around the suprasellar region. One case, was mainly cystic measuring 12 H.U. Two cases showed no enhancement with contrast while one enhanced after intravenous contrast. Two of the cases caused obstruction of CSF flow with resultant hydrocephalus.

#### Pituitary tumours

In the single case of histologically proven pituitary adenoma (chromophobic), the tumour mass was rounded, slightly hyperdense and well demarcated. Enhancement of the density of the tumour tissue after the administration of I.V. Contrast was seen. There were probably 3 cases of microadenomas that were not detected on CT scanning, but had clinical features of prolactin-secreting adenomas.

#### Pinealoma

There were no histologically proven cases of a pineal tumour but there was a suspected case in a 6 year old female child that had a low density

lesion around the pineal gland causing obstruction at the level of the Aqueduct. The parents of the child refused to give consent for the operation and the child was discharged.

The other case was a 13 year old female also, with obstructive hydrocephalus due to a hyperdense midline tumour in the region of the pineal gland. There was increased uptake with contrast medium.

#### Epidermoid cyst

There was a histologically proven case that initially was thought to be a craniopharyngioma on CT Scanning. The lesion was a well-defined, cystic area arising from the suprasellar region. It appeared to be obstructing the 3rd ventricle with resultant dilatation of the lateral ventricles. There was no enhancement after administration of I.V. Contrast material. The patient was a 7 year old male.

#### Extension/Metastasis

CT Scanning was done in a patient who had enucleation of one eye due to proven retinoblastoma four months previously. A well-defined soft tissue mass was seen around the lateral rectus muscle in the remaining eye, with an intracranial extension.

There was no evidence of any bone involvement. Some enhancement was seen after contrast administration.

### Subdural Haematomas

Fifteen cases of subdural haematoma were diagnosed, twelve were confirmed at surgery and in three, the neurosurgeons felt the patients could be discharged on dexamethasone as the haematomas were very small and caused no significant shift of the mid-line structures. These cases were to be followed up in the neurosurgical clinic.

These subdural haematomas can be divided into 3 distinct groups according to the density of the material in the subdural space:-

- (a) Haematomas with absorption values greater than normal brain were seen as white peripheral bands capping the cortex and with displacement of the midline structure to the contralateral side. The density of the peripheral bands in patients with acute lesions corresponded to that of clotted blood. Nine patients fell into this group.
- (b) Haematomas with absorption values lower than normal brain were seen as low-density peripheral bands with some mid-

line displacement. Four patients fell into this category.

- (c) In one patient a scan was obtained in which the subdural haematoma was not seen as a clear-cut density difference between itself and the underlying brain but a marked midline structure displacement to one side was noted. There was no history of previous trauma in this case and the findings were confusing. Carotid angiography demonstrated the subdural haematoma and the diagnosis was clinched.

There was a definite history of trauma in 80% of cases.

### Extradural Haematoma

Three patients with extradural haematomas were confirmed at surgery. The outstanding feature seen on the scans was a peripheral, inwardly convex, high density lesion with a contralateral displacement of the midline structures.

Two of the cases had evidence of a skull fracture both on plain radiography and, also, on CT.

### Cerebral Oedema

There were 2 cases of cerebral oedema as reported on CT. Both had a history of previous trauma. One case was a false positive as the patient clearly had a subdural haematoma demonstrated by carotid angiography. The other case showed as a diffuse area of low density on one side of the brain.

### Intracerebral Haemorrhage

One case was found showing a sharply demarcated area of high density measuring 55 H.U. in the temporo-parietal region, surrounded by low density oedema. There was a mild degree of shift of the midline. After contrast, no abnormal vascularity or enhancement was shown. The patient was a known hypertensive.

### Cerebral Infarction

There were 4 suspected cases of cerebral infarction showing low density areas. One case was a 34 year old female, who had delivered three weeks prior to the sudden onset of hemiplegia and aphasia. CT demonstrated a large low density area in the parietal region with compression of the lateral ventricles and shift of the midline. This was thought to be a case of cerebral embolism following deep venous thrombosis post-partum.

The patient subsequently did very well on physiotherapy. In two of the cases, there were dilated cisterns and CSF spaces probably due to cerebral atrophy as a result of infarction. None of the cases showed enhancement after administration of I.V. contrast material.

#### A.V. Malformations

Two cases were found in this study. In one, a carotid angiogram showed an arterio-venous malformation in the region of the petrous bone. CT revealed a posterior fossa tumour mass extending into the neck and causing extensive bone erosion that enhanced with administration of I.V. contrast medium. A differential diagnosis of haemangioblastoma was, also, considered. Surgical exploration confirmed a very vascular angiomatous malformation. The patient underwent radiotherapy with a view to sclerose the malformation. In the second case, there was a serpentine area in one of the cerebral hemispheres showing enhancement after contrast. No mass effect was seen. However, a mild degree of dilatation of one of the lateral ventricles was seen, suggesting mild cerebral atrophy. Carotid angiography showed apparent non-filling of the anterior cerebral artery beyond a certain point with an avascular area in the temporal region. There was, also,

early filling of the deep venous system.

### Aneurysms

An angiographically proven case of aneurysm of the posterior communicating artery was picked up initially on CT. The patient had a 4 month history of ptosis of the right eye. CT Scanning revealed an approximately 1cm, rounded dense area in the right parasellar region adjacent to the cavernous sinus that had circular enhancement with I.V. contrast. Carotid angiography confirmed the presence of the aneurysm and was well demonstrated in the oblique views.

### Hydrocephalus

This was demonstrated as ventricular dilatation on CT examination. There were four cases of communicating hydrocephalus; two were secondary to brain atrophy and **no demonstrable cause was** shown in the other two. In these cases, there was symmetrical dilatation of all the ventricles.

Most of the cases were due to obstruction 80% (non-communicating hydrocephalus). Most of the patients were children and had tumour masses causing obstruction.

There were 2 cases of Aqueductal stenosis showing selective dilatation of the third and lateral ventricles only.

### CSF Cysts

There were two cases; one was thought to be an arachnoid cyst and the other a porencephalic cyst. The arachnoid cyst appeared as a well-defined rounded CSF density area in the posterior fossa on CT Scanning. There were associated dilatations of the third ventricles and body of the lateral ventricles. On exploration, a large cyst with clear fluid was found in the midline communicating with the fourth ventricle. This was excised and the neurosurgeons thought it was a Dandy Walker cyst. However, there were no features on CT Scanning to suggest a dysplastic cerebellum.

In the patient with a porencephalic cyst, there was mild dilatation of the left frontal horn with an associated fluid density area communicating with it. The patient was a known severe hypertensive due to bilateral artery stenosis and the lesion was thought to be post-infarctive.

### Brain Atrophy

Changes attributable to cerebral atrophy

were seen in CT scans of 7 patients. Dilated lateral ventricles of varying degree were seen in all cases. In addition the scans showed widening of the sylvian and interhemispherical fissures, as well as the cerebral sulci high up in the cerebral hemispheres in cases of generalized brain atrophy. Two cases were due to generalized brain atrophy in elderly patients; one showing very extensive atrophy and the other showed more atrophy in one temporal lobe causing a more dilated temporal horn on the same side. One case showed ~~more~~ prominent frontal lobe sulci, the other case showed atrophy of the cerebellar hemispheres. Both these were seen in young adults. Three cases of cerebral atrophy as a result of infarction were seen, the cause of which was unknown.

## INFECTIONS

### Abscess

There was a single case of histologically proven abscess. In this case, there were multiple abscesses, seen in the frontal and parietal regions. The child had been previously treated for meningitis. The abscesses some of which were multilocular showed as areas of low density. After injection of intravenous contrast medium, the abscess capsules showed as thin-walled regular rings of enhancement.

### Tuberculoma

Three patients with tuberculoma were seen in this study. Only one was diagnosed correctly on CT, the others were thought to be brain tumours but on histology proved to be tuberculous lesions. In the correctly diagnosed tuberculomata, these were seen as two small, rounded, dense areas in the midbrain and occipital areas. Both showed ring enhancement after contrast. There was no mass effect and no ventricular dilatation.

The other lesions that appeared similar to tumour masses were larger but well defined mixed density lesions, both arising from the posterior fossa. They caused mass effect and minimal dilatation of the ventricles. There was some enhancement with contrast. One of the large masses had areas of calcification within it. There was a significant decrease in size of the lesions on CT Scanning in one case after 7 weeks of medical treatment.

### Hydatid Cyst

There was a single case of hydatid disease with a positive serological test (Casoni). A large round cyst was seen in the anterior cranial fossa measuring 6 x 5.5 cm. The cyst was largely of

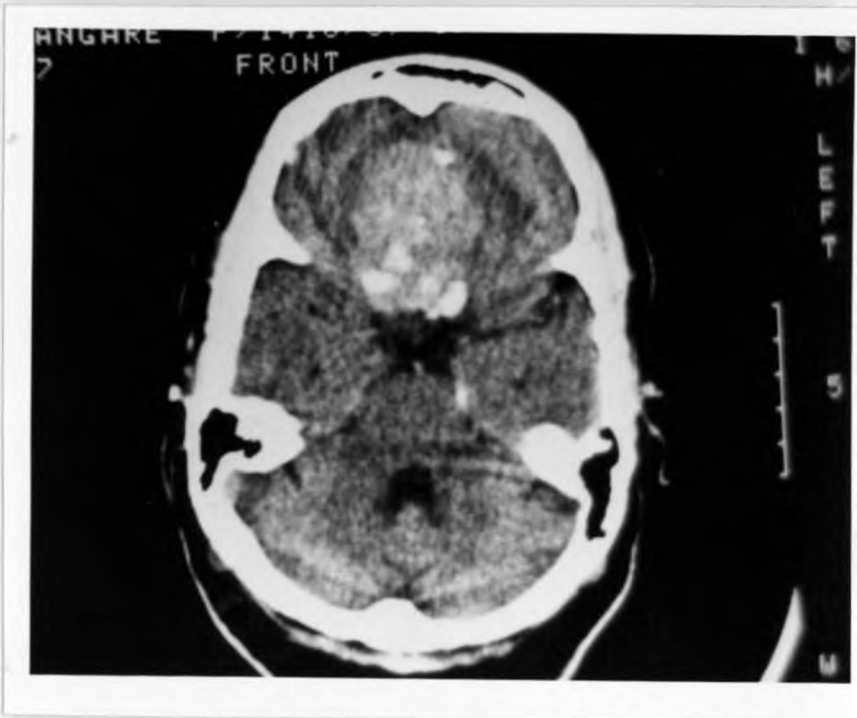water density but there was a higher density area causing a level probably due to debris and daughter cystercerciae. This higher density material moved with changing position of the head of the patient. The large size of the cyst caused mass effect and ventricular dilatation. Calcification was demonstrated within the wall of the cyst.

## MISCELLANEOUS

### Encephalocele

A single case of frontoethmoidal encephalocele was identified. A soft tissue density mass was seen in the nasal cavity and was more prominent on one side. The surrounding cerebral tissue appeared normal. On sagittal reconstruction done through the midline, there was a bony defect in the anterior cranial fossa, through which the mass in the nasal cavity appeared to communicate. The basal cisterns and ventricular system appeared normal.

The following are photographs to illustrate some of the pathology encountered in this study.



**Figure 1:** A patient with a 5 year history of convulsions and failing vision of the left eye was admitted 4 years ago for carotid angiography and was later discharged on grounds that the examination was normal. CT Scanning revealed a large oval-shaped hyperdense mass with flakes of calcification within it in the anterior fossa, that enhanced with IV contrast administration. Histology - meningioma.

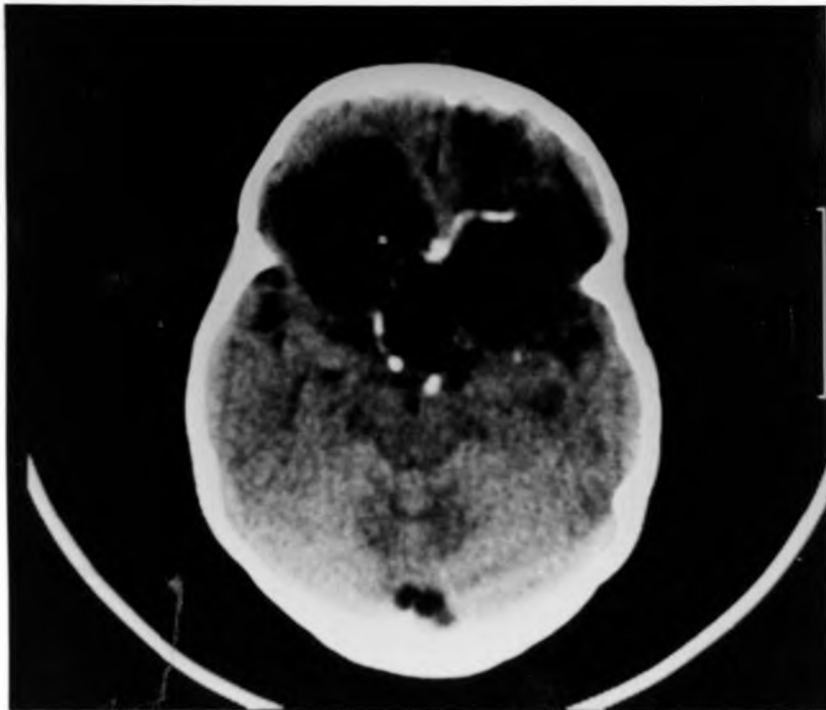
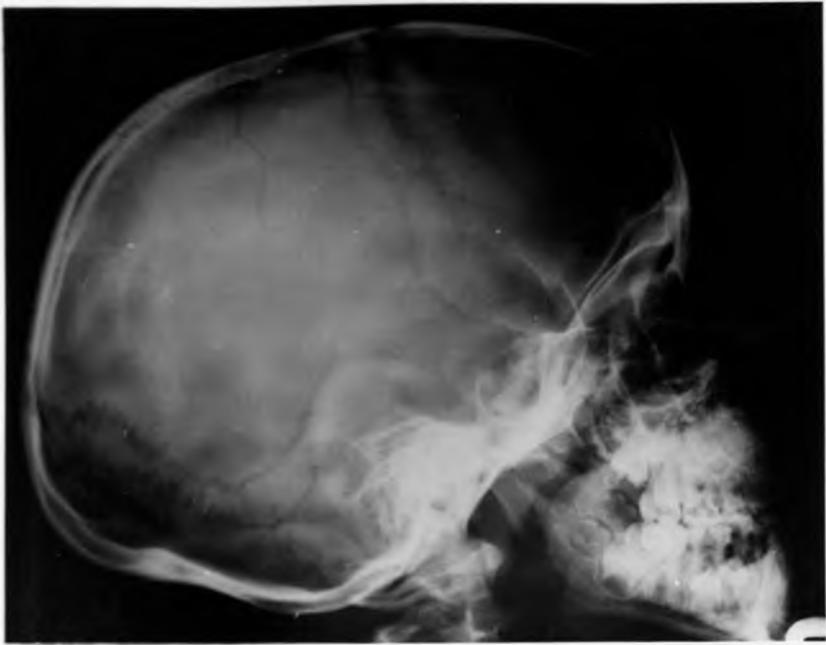
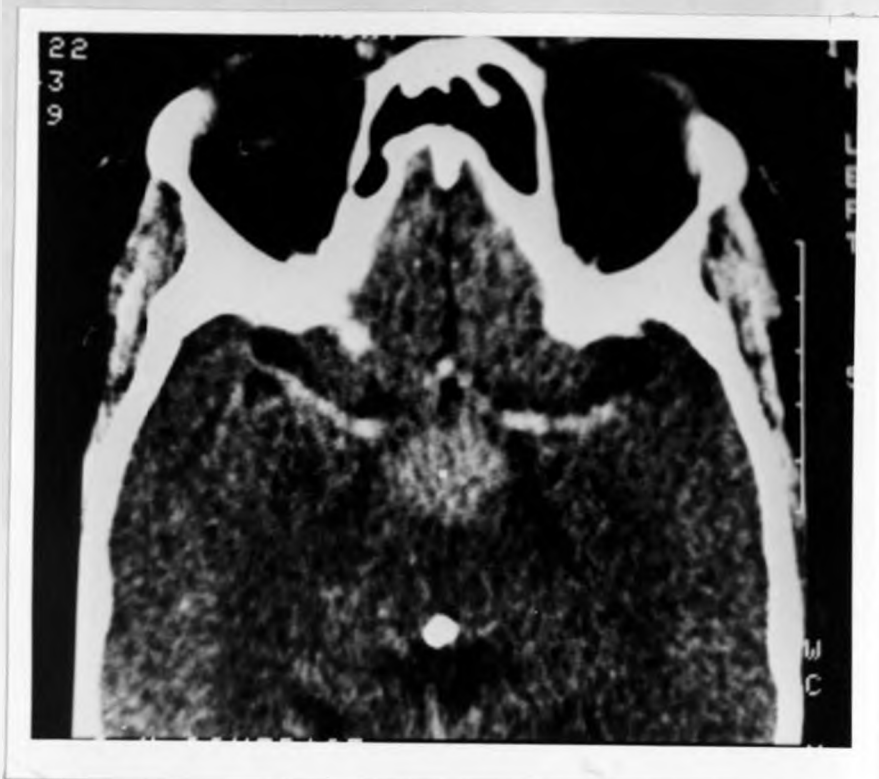
Figure 2: Plain skull film shows sellar calcification in a 6 year old female child with craniopharyngioma. CT revealed a large cystic mass in sellar region extending anteriorly with calcification within it.

DEPT. OF DIAGNOSTIC RADIOLOGY  
University of Nairobi  
Kenyatta National Hospital



**Figure 3:** A 31 year old male presenting with a 3 year old history of increasing size, severe headaches, impotence and 2 year old features of diabetes mellitus. Plain skull x-rays showed prominent paranasal sinuses. X-rays of the hands and feet appeared normal. CT Scanning revealed an isodense mass measuring 2 x 1.5 cm. lying superiorly and behind the posterior clinoids, showing uniform enhancement. Histology was not confirmed as towards the end of the study period, the patient went into ketoacidotic coma. The patient was thought to have acromegaly.

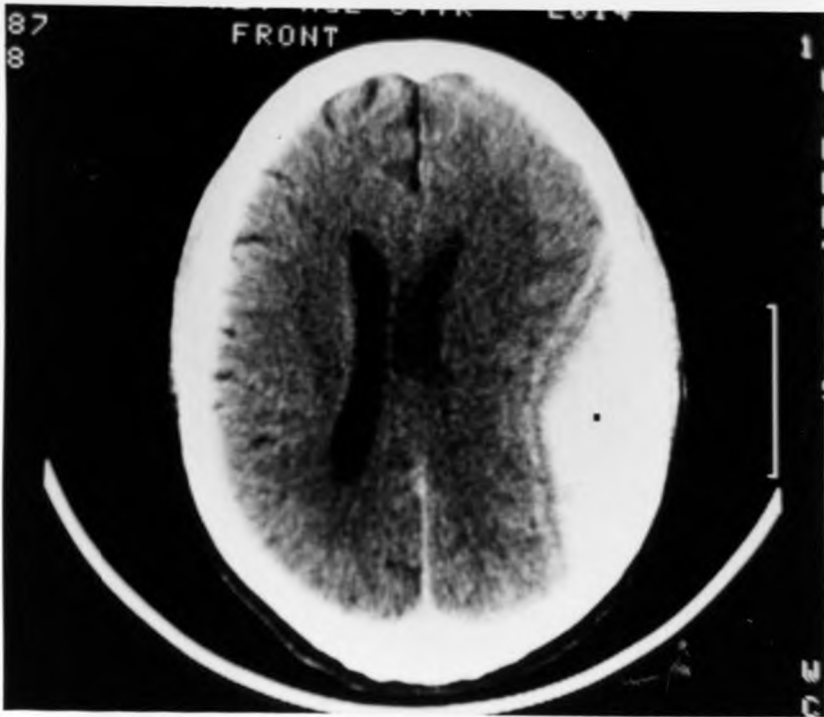
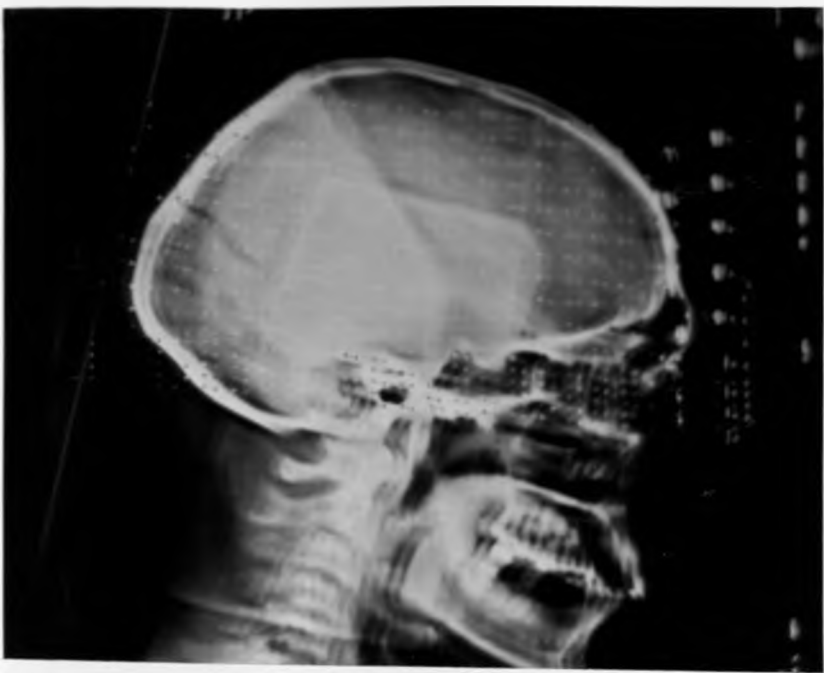


Figure 4: Patient with history of trauma with transient loss of consciousness and weakness of right side. Plain skull radiography revealed fracture in left parieto-occipital region. CT Scanning revealed large biconvex area of high density in the same region with shift of midline structures to the right - epidural haematoma.

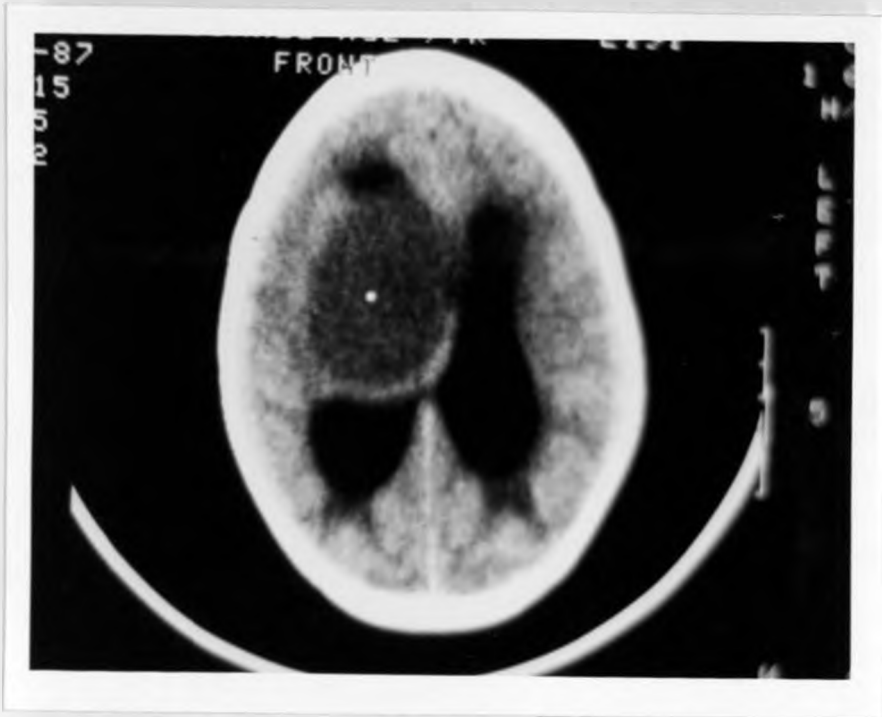


Figure 5: Large well-defined cystic lesion measuring 6.5 x 4.8 x 5.3 cm. obstructing the 3rd ventricle with resultant dilatation of the lateral ventricles. There was no enhancement after contrast administration.

Histology - simple epidermoid cyst.

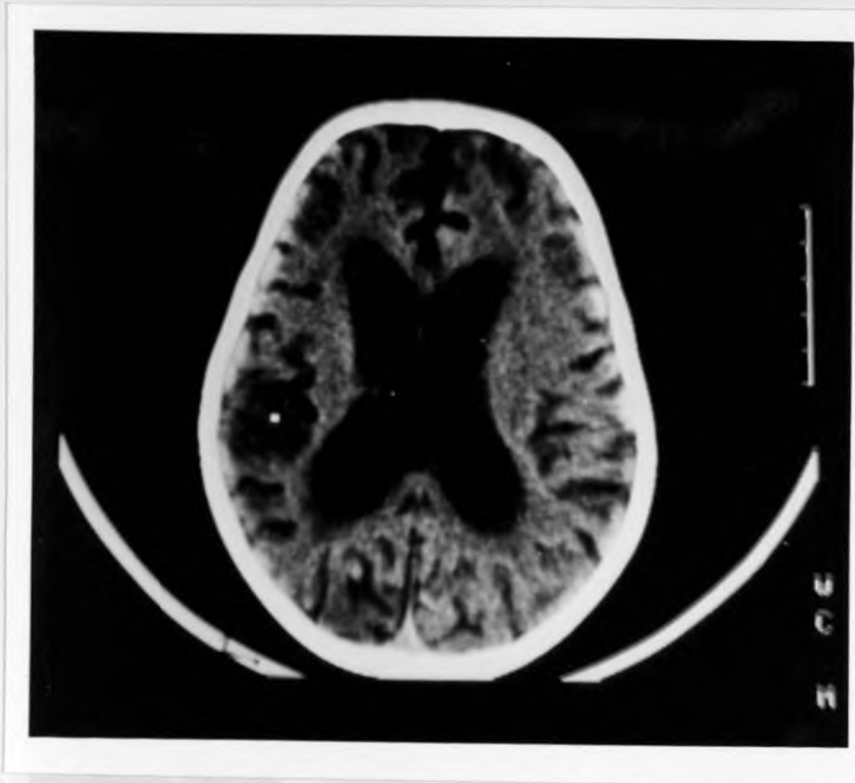


Figure 6: A 2½ year old child with weakness more on left side and aphasia for 2 months. CT Scanning revealed dilatation of the sulci, fissures, cisterns and ventricles suggestive of brain atrophy. There are areas of brain infarcts mainly in the right parietal lobe. Thought to be post-encephalitic brain atrophy with infarcts.

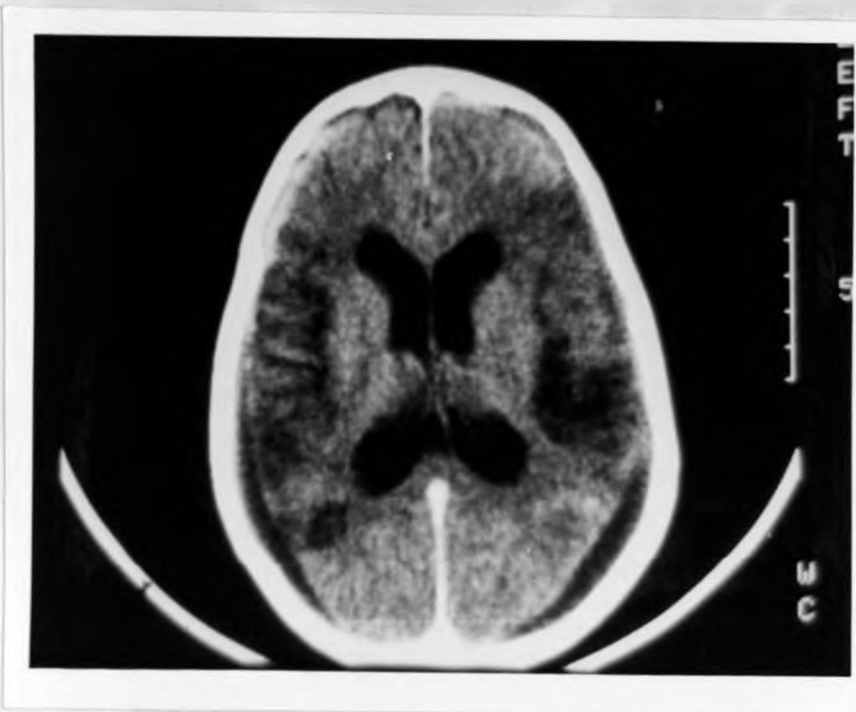


Figure 7: A 8 year old patient presenting with a 3 day history of headache, convulsions and bleeding excessively from the gums. CT Scanning showed cisternal and ventricular dilatation with no midline shift due to brain atrophy. Low density areas were seen in the parietal lobes due to infarction. Bilateral chronic subdural haematomas are seen. Patient was later diagnosed as having Von Willebrand's disease on coagulation screening.

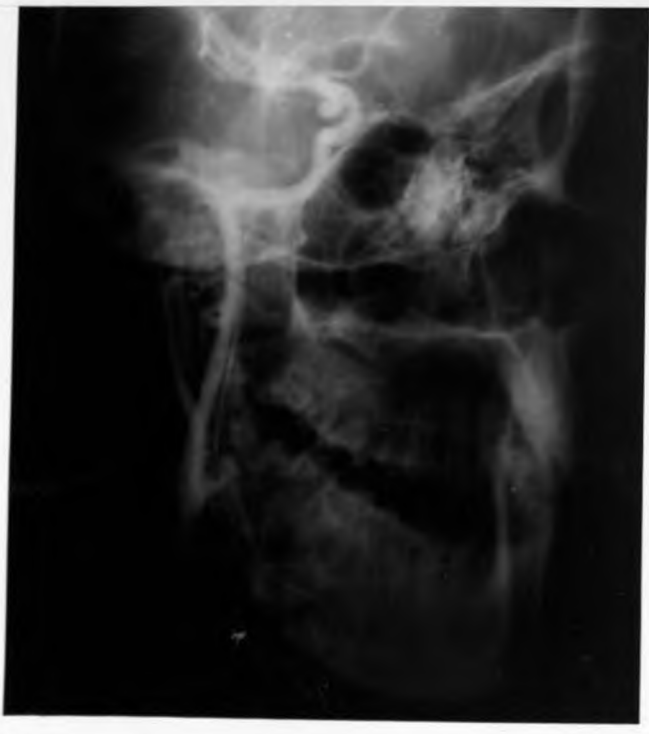
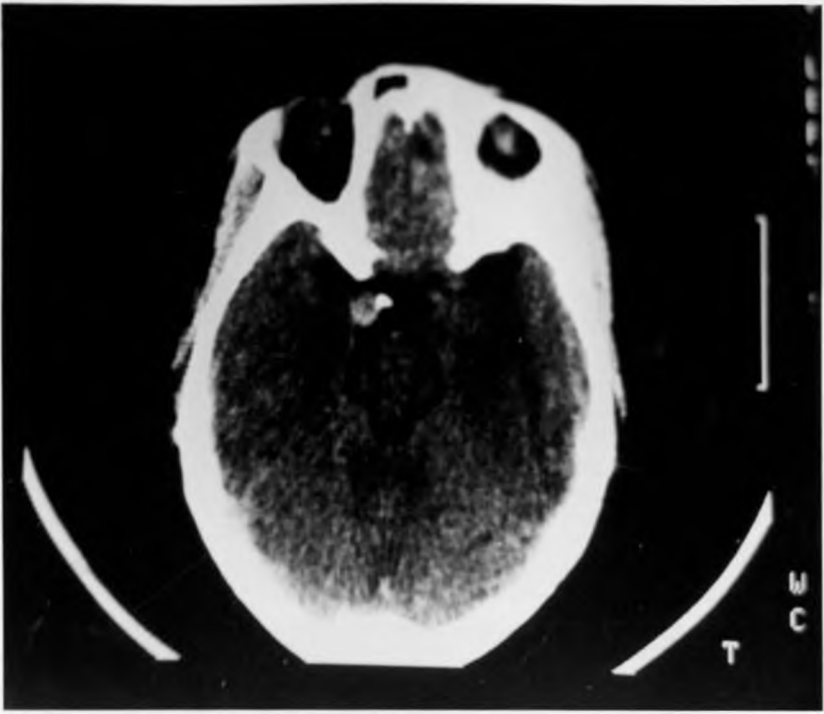
Figure 8: Patient had a 4 month history of ptosis of right eye. CT Scanning revealed a 1 cm. hyperdense area in right parasellar region with circular enhancement adjacent to cavernous sinus. Carotid angiography (oblique views) demonstrate an aneurysm of the right posterior communicating artery well.

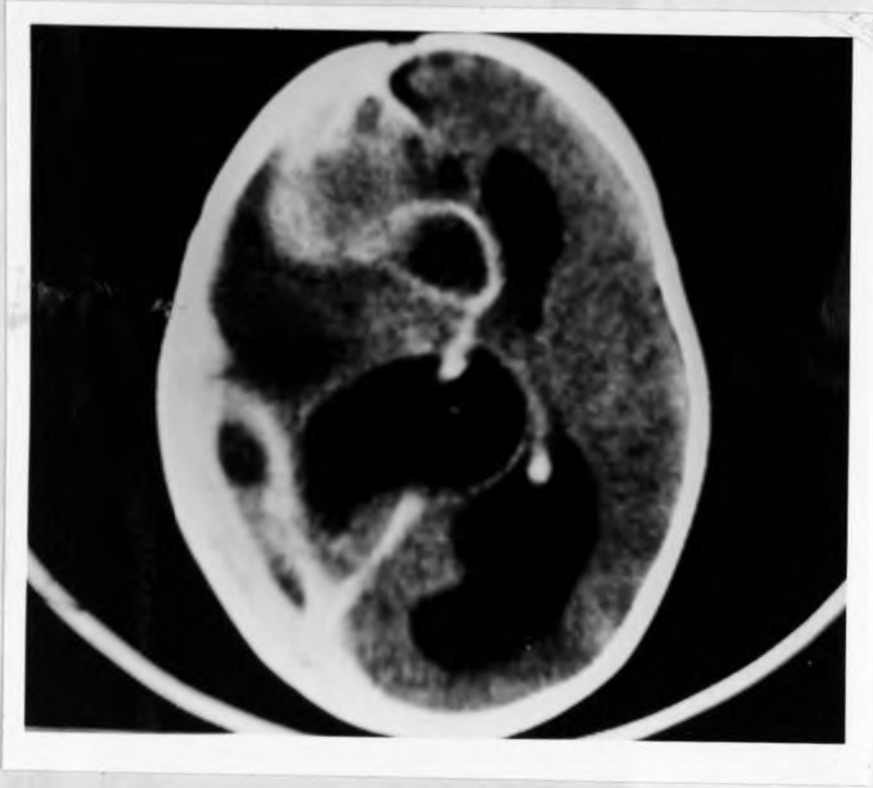
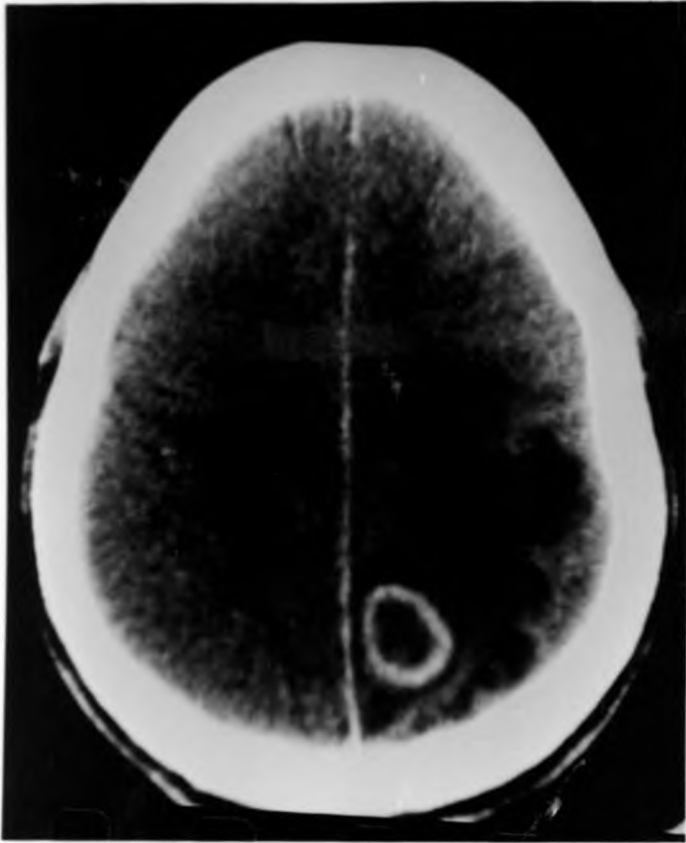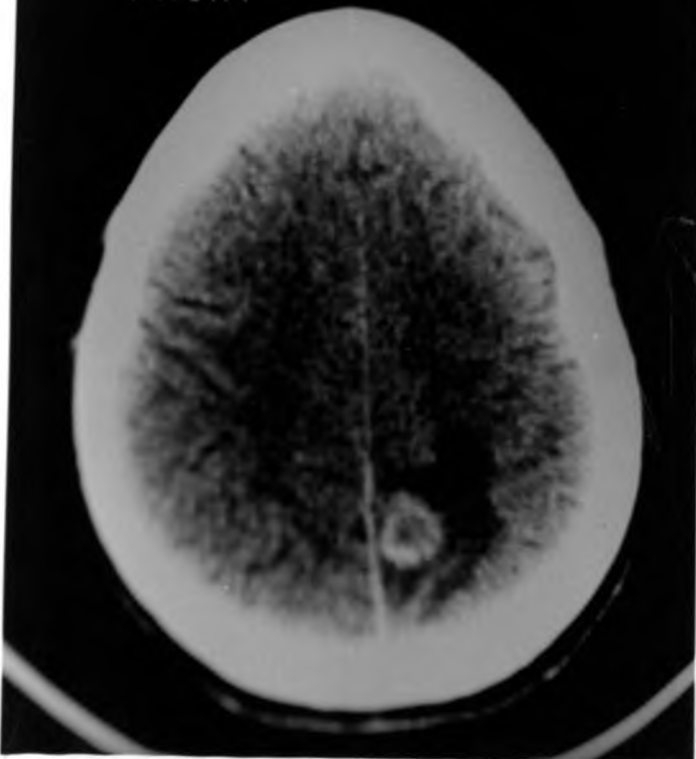


Figure 9: A 7 month old child with a 3 week history of irritability, fever and vomiting. The child was treated for meningitis without any improvement. CT showed multiple areas of low attenuation with surrounding rims of high attenuation that enhanced following contrast injection. Multiple abscesses were drained on craniotomy.



Before  
treatment

AGE 20YR  
FRONT 1963



After  
treatment

Figure 10

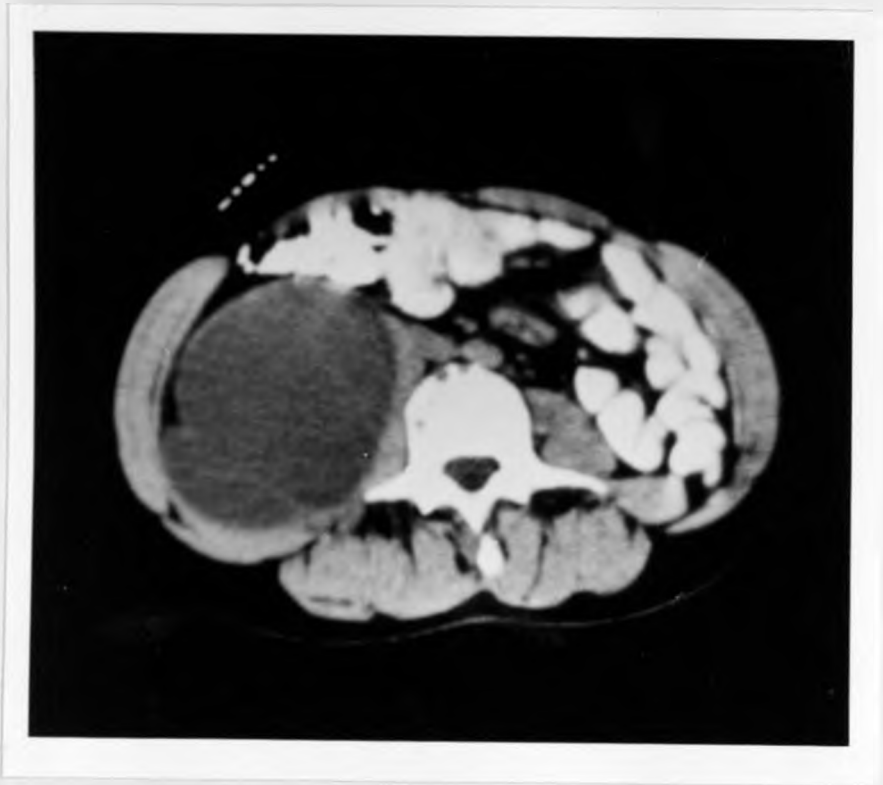


Figure 10: A young man presented with a 3 month history of convulsions and a 2 week history of headache, vomiting, visual disturbance and weakness. Skull and Chest X-ray were normal. A radiograph of the thoracolumbar spine revealed a paravertebral soft tissue mass. CT Scanning of the head revealed two rounded hyperdense areas with rim enhancement (only one shown in the photographs). After 7 weeks of antituberculous therapy, the lesion seen in the left posterior region shows a decrease in size. CT Scanning of the abdomen shows a large psoas abscess on the right side causing erosions of the vertebral body.

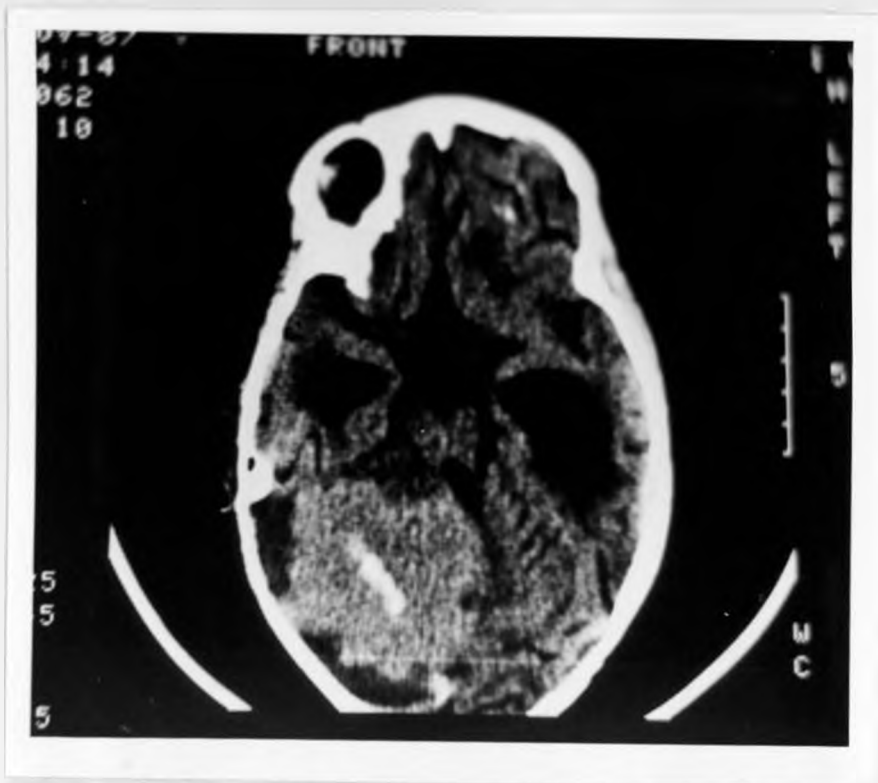

Figure 11: A 9 year old male patient with a 1 year old history of headaches, progressive enlargement of head, loss of vision and weakness. He had cervical lymphadenopathy with a positive Mantoux test and, therefore, was started on antituberculous therapy. CT Scanning showed a large well defined mass in the posterior fossa compressing the 4th ventricle with resultant dilatation of the 3rd and lateral ventricles. An area of calcification is seen within it. A diagnosis of medulloblastoma was entertained but on craniotomy cheesy material was found and confirmed to be tuberculous on histology.

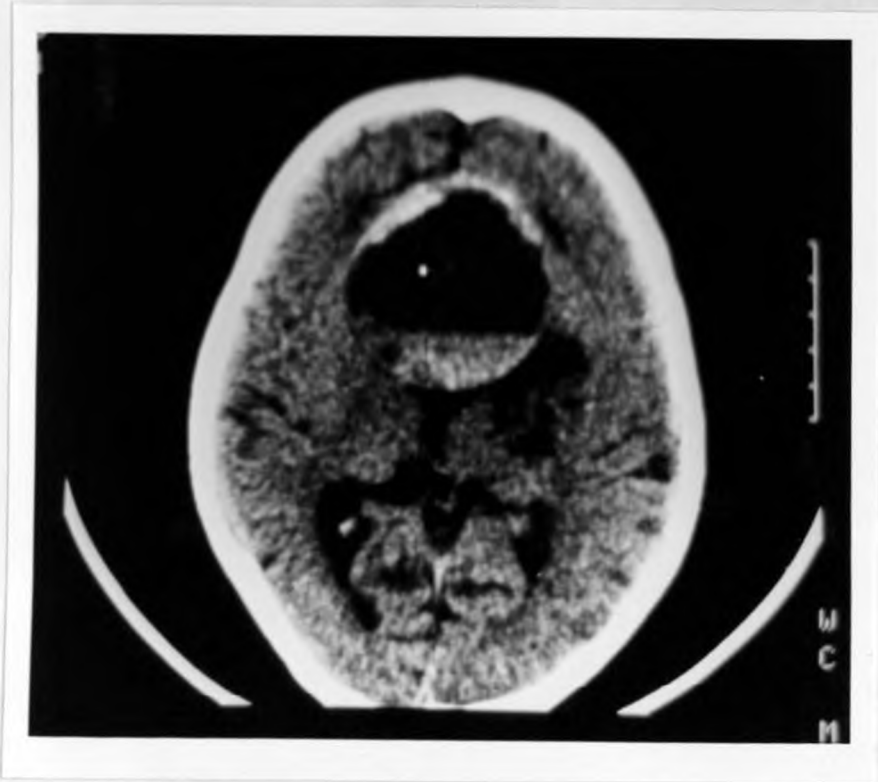

Figure 12: A 8 year old Turkana boy presented with bilateral proptosis and blindness for an unknown duration of time. Carotid angiography showed grossly displaced vessels with no pathological circulation. CT Scanning revealed a large rounded cystic structure with a fluid level that changed with position of the head. They cyst has a surrounding rim of calcification.

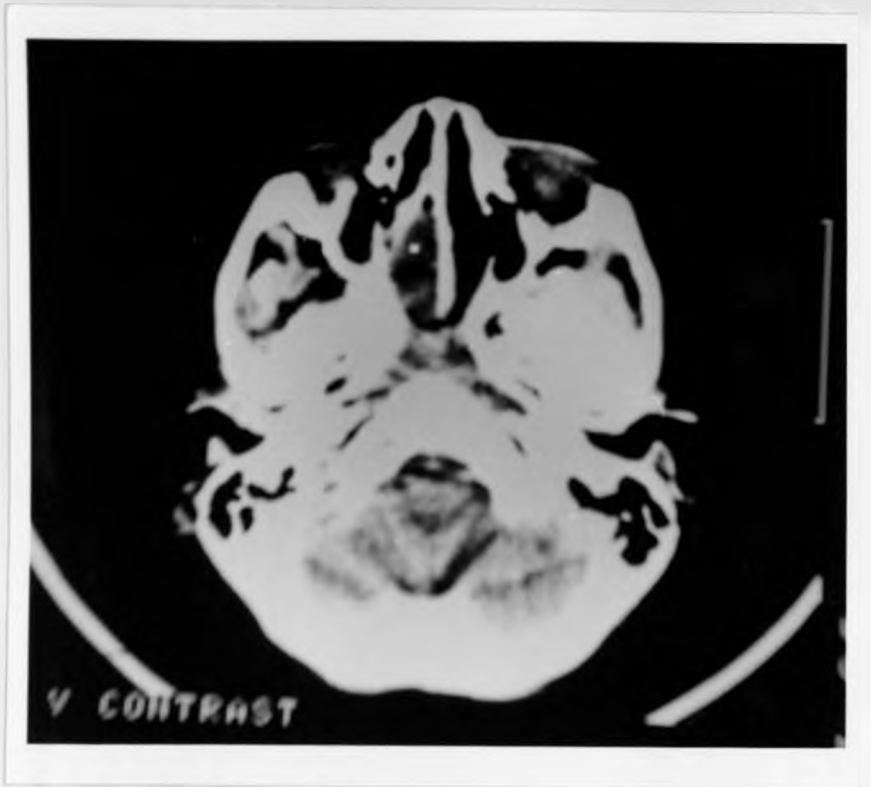


Figure 13: A 7 year old child presented with headache, convulsions and nasal blockage for 2 years. CT Scanning showed a soft tissue density mass in the right nasal cavity. On sagittal reconstruction (not shown), a bone defect was seen in the anterior cranial fossa, through which the mass in the nasal cavity appears to communicate. Biopsy was taken and histology showed brain tissue - encephalocele.

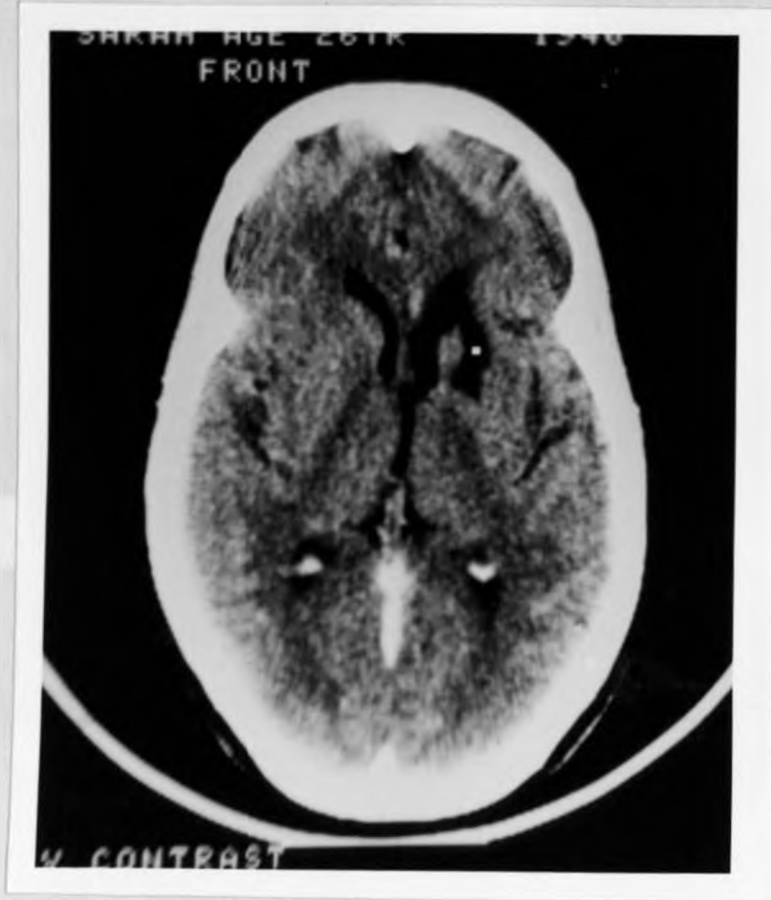


Figure 14: The patient presented with a 4 day history of severe headache, vomiting and diminished vision. CT Scanning showed a dilated left frontal horn with an associated low density area communicating with it. Patient was a known severe hypertensive and it was thought to be suggestive of post-infarction porencephalic cyst in that basal ganglia region.

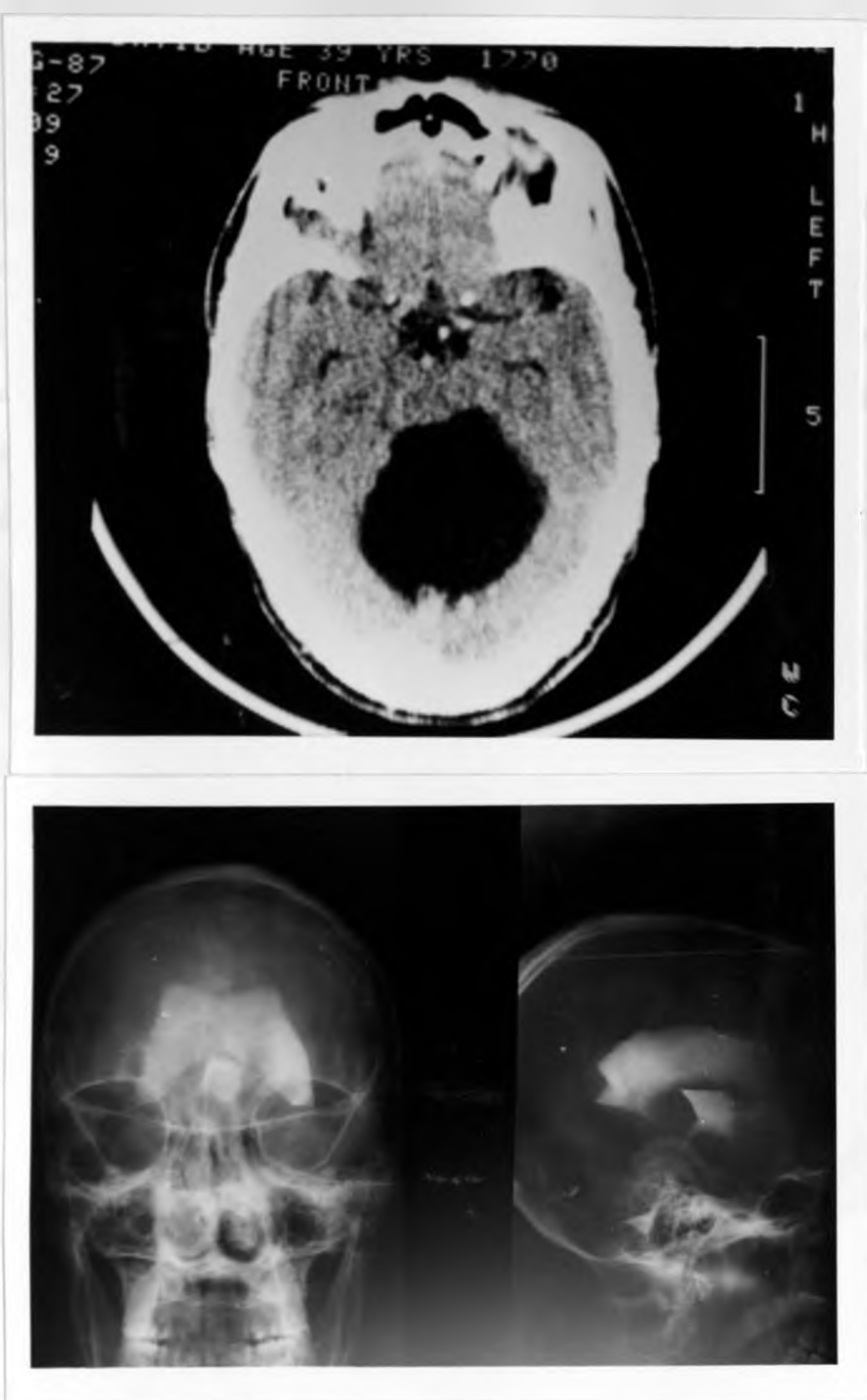


Figure 15: A 39 year old patient presented with a 7 year old history of vertigo, unsteady gait and otorrhoea and a 8 month old history of left sided weakness, blurring of vision and headache. CT Scanning revealed a large well-defined CSF density area in the posterior fossa that appeared to be a dilated 4th ventricle

with associated dilatations of the 3rd and lateral ventricles. Ventriculography showed dilatation of 3rd and lateral ventricles. On exploration, a large cyst with clear CSF was found in the midline communicating with the 4th ventricle - Subarachnoid cyst. The cyst was excised and patient did well post-operatively.

The diagnosis of a large subarachnoid cyst communicating with the 4th ventricle was made on the basis of the ventriculogram and the clinical picture. The patient had a long history of headache, vomiting, and papilloedema. The diagnosis was confirmed by the ventriculogram which showed dilatation of the 3rd and lateral ventricles and a large cyst communicating with the 4th ventricle. The cyst was excised and the patient did well post-operatively.

- 57 -

## DIAGNOSTIC ACCURACY

Table VI shows the diagnostic accuracy of CT for some of the intracranial lesions detected. The diagnostic accuracy for primary brain tumours was 87%. In all cases, there was a detectable structural lesion but there were false positives in 3 cases. In two cases, a diagnosis of primary brain tumour was made on CT but at surgery caseous material was found. Histology confirmed the presence of granulomatous tissue consistent with tuberculoma. The third case on CT showed a left parietal hyperdense mass with surrounding marked oedema and shift of the midline. There was rim (ring) enhancement with the administration of IV Contrast material. A diagnosis of primary brain tumour, abscess was made. Burr hole biopsy was done and features of cerebral haemorrhage or infarction seen on histology.

The diagnostic accuracy of CT for abscesses was 50% and this may not be statistically significant because there were only two proven cases; one being a true positive as pus was drained on craniotomy and histology, also, showed features of chronic abscess formation. The other case was a 10 year old boy whose CT scan showed a rounded hypodense mass lesion in the right parietal lobe causing displacement and dilatation of the ventricles. The mass had a dense rim around it

that enhanced with IV contrast medium administration. A diagnosis of brain abscess was made. However, on craniotomy, no pus was drained and a cystic mass found. The neurosurgeons thought that this may have been a cystic glioma. Microscopy of the aspirated fluid revealed only a few lymphocytes.

Diagnostic accuracy for extension of tumour, traumatic haematomas, angiomatous malformations, hydrocephalus and CSF cysts, tuberculomas, hydatid cyst and encephalocele was found to be 100% as there were no false positives or negatives in the confirmed cases.

Carotid and vertebral angiography was performed only in 27% of the patients. Air encephalography or ventriculogram done in 6%. Plain X-rays films of the skull were done in 82% of the cases. (See Table VII).

The diagnostic accuracy for plain skull X-rays was found to be 49%. Skull X-rays were considered diagnostic if they showed evidence of raised intracranial pressure i.e., erosion of the posterior clinoids, enlargement of the sella, sutural diastasis, increased convolutional markings in adults or pathological calcification. Pneumoencephalography or ventriculography was considered diagnostic if there was evidence of

a space occupying lesion causing distortion of the ventricles or recesses or showed evidence of hydrocephalus. The Diagnostic accuracy was found to be 83% for pneumoencephalography/ventriculography. Carotid or vertebral angiography was considered diagnostic when the tumour was localized and pathological circulation shown. Angiography was, also, considered diagnostic when there was a mass effect, stretching and displacement of cerebral vessels and evidence of hydrocephalus. The diagnostic accuracy of angiography was found to be 69%.

If the diagnostic accuracies of the conventional methods for investigation of neurological problems are considered in this manner, i.e., as screening methods, then the diagnostic accuracy of computerized tomography may be said to be 100% in this study for detecting pathological intracranial lesions.

An abnormal brain parenchymal structure was obtained in all the scans with pathological lesions. There were no reported cases of false negatives as all patients who were followed-up showed no obvious abnormality on further investigation. However, CT has an overall diagnostic accuracy of 94% for detecting specific types of lesions.

INVESTIGATION	TRUE		FALSE		TOTAL DONE	DIAG- NOSTIC ACCURA- CY
	+VE	-VE	+VE	-VE		
Skull X-ray (plain)	30	14	0	45	89	49%
Air encephalo- gram/ventri- culogram	4	1	0	1	6	83%
Carotid/ vertebral angiogram	19	1	1	8	29	69%

TABLE VIII: DIAGNOSTIC ACCURACIES OF OTHER RADIO-  
LOGICAL INVESTIGATIONS

$$\begin{aligned} \text{The Overall diagnostic accuracy of CT} &= \frac{\text{Total of correct diagnosis}}{\text{Total no. of patients examined}} \\ &= \frac{62}{66} \\ &= 94\% \end{aligned}$$

False negatives = 0%

False positives = 9.8%

## HOSPITAL STAY

There were only 75 patients included in the study to ascertain whether CT had any influence on patient hospital stay. This was because 18 patients were still waiting to undergo surgery for a definite intracranial lesion shown on CT; 10 patients had already had CT Scanning done prior to admission, 4 patients died before treatment commenced and 2 patients were out-patients.

It was found that approximately a third of patients stayed for 0-7 days, another third for more than 7 days to 1 month and another third stayed for more than 1 month to 6 months in the hospital before CT was done. However, a majority of patients (61%) had definitive treatment commenced after CT Scanning had been done in less than 7 days. Only 7% stayed for longer than 1 month. Definitive treatment meant that either surgery had been done, medical treatment, physiotherapy or radiotherapy commenced or that the patient had been discharged and was to be followed up. (See Table IX).

## MANAGEMENT AND OUTCOME

Thirty nine per cent of patients underwent surgery. Of these, the majority of patients, 72% did well post-operatively and either remained

the same i.e., the condition did not deteriorate or improve with physiotherapy. Seven per cent of the patients who had surgery appeared to get worse, 12% died post-operatively either from complications of anaesthesia and surgery or in the immediate post-operative period from infection. The condition of 9% of patients remained unknown as it was not possible to trace the files.

Seventeen per cent of patients were still waiting to have surgery at the end of the study period. This can be attributable to the shortage of neurosurgical staff and facilities the hospital lacks at certain periods.

Two patients had inaccessible tumours and, therefore, surgery was not possible. Fourteen per cent ~~were~~ put on medication without surgery, 7% underwent radiotherapy and the majority of patients 89% had some form of physiotherapy.

Time period	Hospital stay before CT done		Hospital stay after CT done and before definitive management commenced	
	No. of cases	%	No. of cases	%
0 - 7 days	26	34.7	46	61.3
7 days - 1 month	23	30.7	16	21.3
1 month - 6 months	26	34.7	13	17.3
6 months - 1 year	0	0	0	0
TOTAL	75	100	75	100

TABLE IX: EFFECT OF CT ON HOSPITAL STAY

Average (mean) no. of hospital days before CT done

$$= \frac{2064}{75} = 27.5 \text{ days.}$$

Average (mean) no. of hospital days after CT done and before definitive management commenced

$$= \frac{1319}{75} = 17.6 \text{ days.}$$

## DISCUSSION

Computerized tomography is a relatively recent invention, and its short history coincides with a worldwide concern about health care costs and risks (25). Cost effectiveness attempts to assure that disease is treated with the most effective means available at the same time minimizing the cost of such treatment (59). This method involves such factors as the impact of CT on the existing health care system, health outcome of patients, and reduction of hospital occupancy (59).

CT Scanning clearly possesses very considerable advantages; being neither uncomfortable nor hazardous. Risks are associated mainly with the use of contrast media, general anaesthetic or sedation if required, while risks due to radiation are minimal. CT can readily be used for outpatients and may enhance the length and quality of patient survival time by allowing appropriate therapy to be initiated sooner (8, 28). A positive diagnosis can be obtained in a very high percentage of patients as it records much more definite and detailed information than can be obtained from other screening procedures. Furthermore, many patients do not require subsequent contrast radiology, either because a firm diagnosis can be made on the basis of the CT scan or the surgeon is provided with sufficient information to proceed to craniotomy (8, 9, 57). The surgeon will, however, often need to know the source and extent of the blood supply before embarking upon craniotomy, and at

present this can only be clearly shown by angiography (4).

It has been found that the basic elements of the neurodiagnostic procedure have not been altered by the advent of CT and a searching history and neurologic examination are still being routinely performed, although the emphasis has shifted somewhat among other neurological tests since utilization of CT (3, 8, 23, 35). The number of plain skull films done in this study was high (82%). It is still being used as a screening test and some authors have questioned the value of the plain film in neurological cases due to its low diagnostic value (16, 56). In this study, the diagnostic accuracy was found to be only 49%. The low yield from plain skull X-ray films is confirmed in this study and by Sage et al (57). Thus when CT is available, the request for plain skull X-ray becomes unnecessary. Carotid and vertebral angiography was done only in 27% of cases. Studies to outline the ventricular system were done in only 6% of patients although the diagnostic accuracy was high (83%). A large number of patients (66%) in this study were operated on without angiography or pneumoencephalography/ventriculography. Therefore, it can be stated that since the introduction of CT, the need for other invasive and hazardous procedures has declined to a certain extent.

In other studies, the use of cerebral angiography was least affected by the advent of CT Scanning despite the higher risk factors, costs and the necessity for hospitalization. The use of angiography decreased by 15-65%, pneumoencephalography by 40-90%, radionuclide scanning by 29% (8, 23, 64). In one study by Wortzman et al (64), 170 air studies and 170 angiographic procedures were made unnecessary in the 444 patients reviewed. Admission was not necessary in 58% of the outpatients examined and the hospital stay was shortened significantly for in-patients. Larson et al (37) did a retrospective study of patients undergoing angiography either before a CT Scanner became available, after installation of CT or one year after CT became available. He found that since the availability of CT, a progressive decrease in the proportion of angiograms that are normal has occurred (from 36% to 16%) and that patients being evaluated for mass lesions accounted for the decrease. Angiography formerly done in many patients with convulsive disorders or with presenile dementia has been nearly eliminated and is, also, rarely used in cases of head trauma (8). Before CT, air encephalography was the only method available for establishing the diagnosis of cerebral atrophy (5, 28). The number of electroencephalograms (EEG) performed was found to increase slightly (15-20%) in proportion to the expanding patient population and it was thought that the neurologist considers EEG a source of essential data that cannot be derived by any other means (8, 9).

Comparison of the CT Scanner with scintigraphy, angiography and pneumoencephalography is difficult since each aims to answer somewhat different questions. Pneumoencephalography identifies tumours indirectly by their effect on the ventricular system and subarachnoid space and only occasionally provides a specific diagnosis. It is particularly valuable for identifying neoplasms in the posterior fossa and perisellar regions, two areas where CT has limitations (28).

Angiography may reveal a tumour directly by the presence of abnormal vasculature or indirectly by the displacement of vessels and such anatomical details may be of great value to the surgeon.

Angiography, also, permits estimation of ventricular size, may give evidence of infarction and is the only available method of showing most of the disease of blood vessels (28).

In CT Scanning, a positive diagnosis can be obtained in a very high percentage of patients as it records much more definite and detailed information than can be obtained from other screening procedures. Work done by Evens (24) and others (5, 28) obtained a diagnostic accuracy of approximately 95% in the early days of CT Scanning. The false positive and false negative cases were found to be nearly equally divided in most series. In this study,

an overall diagnostic accuracy of 100% was obtained as a screening test. A pathological lesion was demonstrated in all positive cases and there were no false negatives on follow up. However, the total diagnostic accuracy in differentiation of specific conditions was found to be 94%. This was because some of the abscesses or tuberculomas were mistaken for tumours and vice versa. Some lesions do not conform to characteristic features and, therefore, all the possibilities should be considered when reporting on head scans.

One study by Ambrose et al (5) reported a diagnostic accuracy of 89% for supratentorial tumours and 80.3% for infratentorial tumours. The diagnostic accuracy for cerebrovascular accidents, atrophy or abscess was found to be 92.3%. In another study by Mori et al (45), findings on cranial computed tomography were correlated with autopsy findings to determine CT reliability. When only scans of good quality were considered, there were no false positive cases. The number of false negatives (34%) varied directly with lesion size and a detection threshold for CT found in the range of 0.5-1.5 cm. The study was performed using at first, the 1st generation scanners and later some cases were performed on 2nd generation scanners. There has been a great improvement since then in image quality. Then, a 80 x 80 matrix system was used; in this study a 256 x 256

matrix is used and, therefore, better results are obtained.

Some of the limitations of CT in the diagnosis of neurologic disease are reported by Davis et al (21). Problem areas include small lesions less than 1.5 cm, lesions obscured by adjoining structures, small vascular structures, some isodense subdural haematomas and misinterpretation due to technical errors. Knowledge and use of the clinical presentation, the performance of other complementary diagnostic procedures, repeat CT Scans tailored to the region of interest, and repeat serial scans may assist in reaching the proper diagnosis and diminishing potential errors.

Published studies indicate a diagnosis of normal in 10 - 40% of CT examinations of the head (23, 48, 7). This compares similarly with a figure of 14% found in this study. Although, radionuclide scanning for the brain was not available during the study period, in most literature a much higher percentage of approximately 90% are found to be normal (23, 8, 9).

Brant-Zawadzki et al (33) compared Magnetic Resonance Imaging (MRI) and CT and concluded that MRI is a more sensitive diagnostic study and is the optimal neuroradiological screening procedure. In addition to its better soft tissue contrast resolution, MRI dose not expose the patient to any form of

ionizing radiation nor does it require the use of IV contrast material; it is truly non-invasive. Perhaps if MRI were available, some of the "negative" CT scans would reveal pathology on MRI.

### Hospital Stay

Sixty one per cent of patients in this study stayed in hospital for less than 7 days before either surgery was done; the patient put on medication; physiotherapy or radiotherapy given or discharged after CT Scanning had been done. Patients stayed in hospital for comparatively longer periods without any definitive treatment when they had not undergone CT Scanning due to a lack of definitive diagnosis. The average number of hospital days a patient spent before CT Scanning had been done and before definitive management commenced is shorter by approximately 10 days. These figures suggest that the use of CT Scanning decreases the length of hospital stay presumably by arriving at a useful diagnosis much earlier than having to wait for other less accurate, more time-consuming and hazardous investigations. This is comparable to other studies e.g., by Bahr et al (6) and Larson et al (36) where hospital stay and cost were reduced in patients after CT was in use. Another study by Newton et al (49) similarly found the average pre-operative length of hospital stay decreased with the advent of CT.

## Primary Brain Tumours

The majority (40%) of the patients in the study had a diagnosis of primary brain tumour on CT examination while in other studies (48, 27, 52) the most common intracranial lesion was haemorrhage as a result of trauma. In this study, traumatic haemorrhage accounted for the third commonest intracranial lesion found on CT, the second being hydrocephalus. Hydrocephalus was found to be **common because both communicating and non-communicating** types of hydrocephalus were considered here.

The incidence of primary brain tumours is high in this study probably because 28% were children below the age of 10 and brain tumours are commoner in children (46). The occurrence of primary brain tumour has two age peaks: one in childhood, when infratentorial lesions (medulloblastoma, ependymoma, cerebellar astrocytoma and brainstem glioma) are the most common, and a second occurs around the age of 50, when supratentorial lesions (glioma, metastasis, meningioma) predominate (46).

There is no doubt that computed tomography scanning is the technique of choice for the investigation of intracranial tumours (63). In a cooperative study by five university centres, sponsored by the National Cancer Institute in the USA, the usefulness of computed tomography compared with conventional skull

radiography, radionuclide brain scanning, and neuroangiography was assessed (10). The study showed that the use of contrast-enhanced computed tomography can reveal upto 98% of all intracranial neoplasms and can specifically identify approximately 90%. The introduction of CT Scanning has been shown to be cost-effective, reducing the total cost for the diagnosis of intracranial tumours by 25% (10).

The main drawback of the CT technique in this study is that benign granulomas have been indistinguishable from primary brain tumours and abscesses. Several studies (3, 31, 55) have experienced this similar problem and, therefore, in countries where granulomatous disease is prevalent caution must be exercised when interpreting the scans.

The majority of primary brain tumours (43%) were thought to be gliomas although only slightly more than half were confirmed on histology. Meningiomas were the second commonest tumours (19%), followed by pituitary tumours (14%). Most of the pituitary tumours were not confirmed histologically and, therefore, may not be a true representation of the tumour types encountered. The results are in accordance with those reported by Ambrose et al (5),

New et al (48) and Zimmerman, 1971 (58) in the European and North American Studies.

Billinqhust (14), also, found that gliomas constituted 54% of intracranial primary tumours at Mulago Hospital in Uganda. However, other studies e.g., a study done by Froman & Lipschitz on tumours of the CNS among the Bantu population in Transvaal, South Africa (27) reported a higher incidence of meningiomas as compared to gliomas. A similar study by Adeku & Jonata in Ibadan, Nigeria, found meningiomas to constitute 26.7% of all intracranial primary neoplasms (2). Dr. Onyango-Akena reviewing 105 patients referred to Kenyatta National Hospital, X-ray Department for carotid angiography in one year found 5 meningiomas out of 17 intracranial neoplasms which gives a figure of 33% (50). No detailed study with histological confirmation has been done on primary brain tumours at Kenyatta National Hospital and both this study and Dr. Onyango-Akena's constitute too small a patient population to be of much significance.

### Gliomas

Amongst tumours, gliomas were found to be the commonest (43%) and the patterns conformed to those described in literature (5, 18, 46, 48, 52, 58). At least some degree of enhancement occurred in all cases. Some tumours had areas of calcification within

them. One of the patients had carotid angiography done which was reported as normal. Gliomas are rarely missed on CT Scanning, even without the use of contrast medium. This is in contrast to cerebral angiography and radioisotope scanning, both of which are not uncommonly negative or equivocal in the presence of extensive, low-grade, infiltrating tumours (58).

### Meningiomas

These were the second most common brain tumours and the majority, 4 out of 5 cases were supratentorial. This is comparable with studies where 90% of meningiomas are supratentorial (18, 58). All the tumours were found in adults. Plain Skull X-rays did not reveal calcification in any of the cases though there were signs of raised intracranial pressure in some. The meningiomas showed as well-delineated hyperdense areas that accumulated contrast medium intensely. In two cases, specks of calcification were revealed on CT Scanning. The only patient who had carotid angiography films available, demonstrated a large vascular tumour with displacement of the major vessels. Imalingat (6) found that 77% of patients with meningioma had abnormal plain film findings and tumour calcification was noted in 21% of the cases. On carotid angiography, a definitive diagnosis of a meningioma was made in 75% while a diagnosis of space-occupying lesion was made in 25%.

Not a single carotid angiogram was reported as normal.

### Medulloblastomas

In this study, the one histologically proven case was in a child being investigated for recurrence. The child had collapse of one of the lumbar vertebrae probably from metastasis. Medulloblastoma are said to be particularly likely to metastasize both upwards and downwards via the CSF (58).

### Craniopharyngioma

All the cases in the study were seen in children under 10 years of age as mentioned in literature elsewhere (17, 39, 58). Rarely does it occur in adults. Suprasellar calcification was well demonstrated in one of the cases on plain skull X-rays. CT demonstrated mixed density masses arising in the midline, partly cystic with enhancement in two-thirds of the cases. Calcification was noted in 66%. It calcifies in about 80% of children and in about 40% of adults (17). Craniopharyngioma may on occasion be of uniformly high density on CT. This usually indicates a solid tumour, but it may rarely prove to be a cyst with high density contents. When a craniopharyngioma enhances uniformly on CT, it may be difficult to distinguish from a chromophobe adenoma or giant aneurysm (17).

## Pituitary Tumour

There was a single case of histologically proven pituitary adenoma (chromophobe) that was rounded, well demarcated, hyperdense, and enhanced with IV contrast in the sellar region. 3 cases were probably microadenoma, not identifiable on CT with features of hyperprolactinaemia.

These microadenomas were probably beyond the resolving power of the 3rd generation unit. The advent of the 4th generation scanners together with the use of narrow collimators using 1, 1.5 or 2 mm sections and overlap if necessary, has resulted in considerably improved resolution in the study of small sellar and suprasellar lesions (58). In a study by Davis et al (20) a significant number of patients with proven microadenoma were not recognized on CT alone, even with high-resolution direct coronal imaging. Focal hypodense lesions, sellar floor erosion, infundibulum displacement, gland height greater than 8 mm and an abnormal diaphragma sellae configuration are neither sensitive nor specific findings of microadenoma.

CT Scanning has, also, been of great value in the follow-up of patients with brain tumours following surgery, irradiation and chemotherapy. In a study by Marks and Gado (42), lesion size regressed

after treatment in 62%, stabilized in 29% and progressed in 9%. CT findings correlated with the clinical course in 93% of cases. After a mean follow up of 10 months, 73% of tumours persisted, 20% disappeared and 7% recurred. The authors describe hydrocephalus in approximately 24% of patients following surgery and irradiation. CT can, also, detect radiation induced necrosis and oedema.

### Cerebral Trauma

Computed tomography is generally accepted as being the method of choice for investigating non-penetrating injuries of the head. No other method is as safe, quick or accurate (41, 63).

Traumatic haemorrhage accounted for the second most common intracranial lesion detected on CT Scanning. 80% of the subdural haematomas had a definite history of trauma. The subdural haematomas were seen as peripheral crescentic bands of blood encapsulating a portion of the cerebral hemisphere. They were either hyperdense, hypodense or isodense depending on the chronicity of the bleed. The extradural haematomas were seen as peripheral, biconvex and demarcated by either sutures or the edge of the stripped dura. Two-thirds of the cases had skull fractures. The case of cerebral oedema showed as a diffuse area of low density on one side of the brain.

The features of head trauma in this study are similar to what is described in literature (22, 41, 43, 65). All epidural haematomas, a number of large intracerebral haematomas and large subdural haematomas are life-threatening focal mass lesions often amenable to surgical correction. Prior to CT, radiologic evaluation of head trauma was directed toward detection of these mass lesions. By circumventing the delays and risks encountered with arteriography, CT permits more rapid and accurate identification of these lesions. Also, the general condition of the entire brain can be assessed. The patient can be taken from the CT scanner to the neurosurgical operating room, and definitive surgery can be performed (63).

Most of the patients who underwent surgery survived in this study; only two patients died, with subdural haematomas, one in whom surgery was delayed and another who underwent 2 separate evacuations and repair of the dura before he died. This corresponds well with the 100% post-operative survival seen in the study by Zimmerman for epidural haematomas, and 36% surgical mortality for acute subdural haematomas (65).

In one study by Lipper et al (41), in order to determine the prognostic significance of CT findings in head injury, retrospective analysis was

performed in 128 randomly selected severe head injury patients managed with a standardized protocol. The correct prediction rate of outcome using the proposed scale for CT findings alone was found to be 69.7% but when CT findings were combined with the Glasgow Coma Scale, the score rate was increased to 75.8%.

### Intracerebral Haemorrhage

A single case of intracerebral haemorrhage showed as a sharply demarcated area of high density in the temporo-parietal region surrounded by low density oedema in a known hypertensive. Spontaneous haematomas are commonest in hypertensive, elderly patients and are probably due to rupture of a small atheromatous vessel (58). Because of the clear distinction between the high attenuation of extravasated blood and that of the surrounding brain, CT Scanning is by far the most accurate radiological method for demonstrating these lesions (58).

CT and cerebral angiography evaluated subarachnoid haemorrhage in 68 consecutive patients. In a study by Lilieqvist and Lindquist (40), it was found that CT should be the first radiographic diagnostic study if performed within two days of onset of bleeding. In this way, cisternal blood

distribution and locus of possible intracerebral haematoma help to predict the site of the ruptured aneurysm and vessel of origin. This allows selective angiography. Follow-up CT allows evaluation of cerebral ischaemia and differentiation of repeat haemorrhage from cerebral infarction.

### Infarction

There were four cases of infarction seen as low density areas that did not enhance with contrast. CT is the appropriate initial examination in cerebral infarction both because of the high yield of useful information and, also, because of the increased risk of carotid angiography in patients with stroke in progress (15). In 75% of cases of ischaemia, the CT scan will show an irregular, area of low attenuation corresponding to a recognizable vascular territory. In the remaining 25% the infarcted area initially remains isodense with surrounding brain; only follow up scans will demonstrate that infarction has occurred (15). One case showed a moderate mass effect which compares with the finding of 10 - 20% showing mass effect during the initial 1 - 2 weeks, which then disappears (19). Atrophy with local reduction of the volume of brain tissue, widening of adjacent cortical sulci and enlargement of neighbouring parts of cerebral ventricles are common

sequelae of cerebral infarction and was seen in two of the cases (15, 19).

### A-V Malformations

One arterio-venous malformation in the study was revealed as a posterior fossa tumour mass extending into the neck and causing extensive bone erosion that enhanced with IV contrast administration. The second case showed as an enhancing supratentorial area in one of the cerebral hemispheres. They were both intact and showed no mass effect. Although the diagnosis of angioma may be certain on a CT scan, most of these cases will require angiography before surgery in order to define the exact anatomy of the feeding vessels and draining veins (53, 58). Kramer and Wing as described in (15) have reported on an angiographically "occult" arteriovenous malformation detected by CT. The arterial supply may be obliterated in these lesions, and angiography may only show a mass lesion.

### Aneurysms

In this study there was a single case of aneurysm of the posterior communicating artery confirmed by carotid angiography. CT should be the initial examination in suspected subarachnoid haemorrhage from

rupture of an aneurysm. Spinal tap, which may be misleading or noninformative, and in addition carries a definite complication rate, should be assigned a less important role in the workup of subarachnoid haemorrhage. In further workup, angiography will give important supplementary information on critical points such as the exact size of an aneurysm, the location of its neck, the anatomy of neighbouring vessels, arterial spasm, and multiplicity of aneurysms.

In one study by Larson et al (36), additional use of CT resulted in little demonstrable improvement in the case of patients with cerebrovascular disease but did increase the cost of evaluation; while with brain tumours CT was found to improve care while not increasing cost.

### CSF Cysts

Computed tomography is the method of choice for the evaluation of cerebral atrophy and determination of the size of the ventricular system (63). The arachnoid cyst in this study was a well-defined rounded CSF density area in the posterior fossa on CT Scanning. According to a study by Vaquero et al (60), primary arachnoid cysts of the posterior fossa

are uncommon. The patient in the study with an arachnoid cyst had hydrocephalus with headache, nausea and vomiting with gait disturbance. Similar findings were observed in (60) with the authors concluding that CT was the best method for diagnosis and location of the site of the cyst and for observing the post-operative evolution.

There was mild dilatation of one of the frontal horns with an associated fluid density area communicating with it in the patient with a porencephalic cyst. It was thought to be as a result of atrophy following infarction as a result of severe hypertension. In a study by Kolawale et al (34) of twenty-six cases of porencephalic cysts, he found that the cysts were all non-enhancing, discreet, and low attenuation areas within the brain. Fifty per cent of the cysts were associated with cerebral atrophy; hemiatrophic or generalized types. Hydrocephalus was a feature in 34.6%; all in the multifocal types, and in cases which were associated with subarachnoid cysts. Mass effect was seen in only three cases, two of which were associated with subarachnoid cysts. The aetiological basis could not be determined in most cases.

## INFECTIONS

### Abscess

There was a single case of histologically proven abscess that consisted of multiple, multilocular areas of low density with rim enhancement after IV contrast. Aspiration of the abscesses was done and the patient improved both clinically and on follow-up scans. Plain X-ray radiography did not reveal any abnormality. Carotid angiography was not done. The features agree with the findings of other authors (18, 52, 54, 58). Angiography and isotope scanning are positive in only 90% of patients with brain abscess (54). They do not indicate the exact nature, stage nor precise anatomical site of the abscess. In contrast, CT is 100% positive, gives accurate localization and determines the presence of daughter cysts and abscesses at other sites. It allows for serial examinations at short intervals, to gauge the correct time for surgical intervention, i.e., in following the evolution of an abscess from a cerebritis to cavitation with capsule formation. The timing of the surgical intervention is important, as surgery prior to the development of a capsule is generally not advised. Surgery requires:

- (a) early and accurate identification of the abscess capsule
- (b) accurate anatomical localisation of the abscess
- (c) identification of multiple loculations and multiplicity of lesions (54).

## Tuberculoma

In one case, the tuberculous lesions showed as small, rounded dense areas showing ring enhancement after contrast administration.

This case was associated with a psoas abscess in the abdomen and showed considerable improvement on anti - TB therapy on follow-up scans. Two of the irregular lesions were probably as a result of small tubercles coalescing to form a larger lesion and did not demonstrate the typical features of tuberculomata as described in other studies (13, 31, 62). Calcification is described in 1-6% of intracranial tuberculomas (58, 62). A study by Whelan and Stern (62) has stated that tuberculomas are solitary in about 66% of cases and that infratentorial lesions are slightly more common than supratentorial lesions, especially in children, which differs with another study by Price and Danziger (53) that states that about 60% of tuberculomas are multiple and supratentorial. Two out of three patients had solitary lesions and two of the lesions were infratentorial, one in an adult and the other in a child. It is submitted that in some instances a tuberculoma can confidently be diagnosed as such on CT appearances and in others it must rank high in any differential diagnosis of mass lesion with ring enhancement (61). Some studies (61, 62) found most of the lesions approximately isodense with normal brain substance surrounded by a ring of intense contrast enhancement. The ring

tends to be unbroken and usually of uniform thickness. It may be smooth or irregular in outline. Although there are several differential diagnosis, the two most likely to be considered in the differential diagnosis are neoplasm either primary or secondary and pyogenic abscess (61). In this study, two cases of tuberculoma were mistaken for brain tumours. Other studies (13, 31) have described appearances as seen in the two cases of tuberculomas mistaken for tumours, i.e., of large irregular masses which enhance with contrast and a suggestion that the mass is made up of multiple small rings and discs coalescing to produce the irregular contour of the mass was made.

Although a definite diagnosis is often not possible on CT, the method is of value in determining the number, location and extent of lesions and, also, for follow-up after treatment.

### Hydatid Cyst

Hydatid cysts can occur anywhere within the brain, but the middle cerebral artery territory is most frequently involved, especially the parietal lobe (12). Most cysts are supratentorial (12). In this study, the single case of hydatid cyst was found in the anterior cranial fossa. Nearly half

present in childhood (12) as in the case found which occurred in a 8 year old child. The signs and symptoms are those of raised intracranial pressure; specific neurologic signs are less frequent, but reduced visual acuity and severe papilloedema are common (12). The child in the study presented with blindness and proptosis. Serologic tests are usually negative (12), presumably because cysts are protected by the skull and are intact, but in this study the patient had a positive Casoni test.

Plain films of the skull may show erosion of the posterior clinoid processes, unilateral skull enlargement, and separation of the sutures in young adults (12). Plain Skull X-ray showed erosion of the posterior clinoid processes and gross distortion of vessels on carotid angiography in this study. The patient had a well-defined round structure of fluid density with no rim enhancement. Within the cyst was higher density material causing a fluid level that moved with changing position of the head. There was evidence of calcification in the capsule. The large size of the cyst caused mass effect and ventricular dilatation.

CT shows a well defined round or oval cystic structure of cerebrospinal fluid density (12). Rim enhancement is infrequent but intravenous contrast material may minimally increase the attenuation value of cyst fluid (12). There is no surrounding

oedema, unlike abscesses or cystic tumours, but there is considerable mass effect and there may be hydrocephalus (12). Calcification occurs in less than 1% of cysts (12). Cysts as small as 1 cm in diameter could be demonstrated in another study by Haertel et al (30).

### Encephalocele

A case of frontoethmoidal encephalocele was detected showing a soft tissue density mass in the nasal cavity and a bony defect in the anterior cranial fossa through which the mass arising from the anterior cerebrum communicated with the nasal cavity. The contribution of CT is to show basal bone defects and to indicate the nature of the herniated structures and their relationship to adjacent portions of the brain if surgical correction is contemplated and to demonstrate commonly associated abnormalities such as hydrocephalus (58).

## CONCLUSION

CT of the head is a unique radiological method of diagnosis that has found more widespread application in neurodiagnosis as experience in its clinical usage increases.

The overall detection rate of intracranial lesions is high and, therefore, a good screening method. It achieves a higher overall diagnostic accuracy of 94% in this study. This is compared with a diagnostic accuracy of 49% obtained in plain skull radiography, 83% in studies outlining the ventricular system and 69% in angiography.

The need of invasive contrast studies e.g., angiography and pneumoencephalography appears to have decreased and a large number of patients (66%) were operated on without their use. These studies are, also, more uncomfortable, hazardous and cannot be used on out-patients.

The availability of CT has, also, significantly decreased the length of hospital stay because a definite course of management can be taken once an accurate diagnosis has been made.

In conclusion, the benefits of CT Scanning appear to outweigh the disadvantages of cost.

## REFERENCES

1. Abrams H.L., McNeil B.J.  
Computerized Tomography: Cost and Efficacy  
Implications.  
Am J. Roent. 131: 81-87, 1978.
2. Adeku E.L., Jonata.  
Intracranial masses in Ibadan.  
West African Medical Journal Vol. 16: 31, 1967.
3. Ambrose J.  
Computerized transverse axial scanning (tomography):  
(2) Clinical application.  
Br. J. Rad. 46: 1023-1047, 1973.
4. Ambrose J.  
Computerized X-ray scanning of the brain.  
Journal of Neurosurgery 40: 679-695, 1974.
5. Ambrose J., Gooding M.R., Richardson A.E.  
An assessment of the accuracy of CT Scanning in  
the diagnosis of intracranial tumour.  
Brain 98: 569-582, 1975.
6. Bahr A.L., Hodges F.J.  
Efficacy of computerized tomography of the head  
in changing patient care and health costs; a  
retrospective study.  
Am. J. Roent. 131: 45-49, 1978.

7. Baker H.L. Jr., Campbell, Houser, Reese.  
Early experience with the EMI Scanner for study  
of the brain.  
Radiology 116: 327-333, 1975.
8. Baker H.L. Jr.,  
The impact of computerized tomography on neuro-  
radiologic practice.  
Radiology 116: 637-640, 1975.
9. Baker H.L. Jr.  
Computed tomography and neuroradiology: a fortunate  
primary union.  
American journal of Roent. 127: 101-110, 1976.
10. Baker H.L. et al.  
National Cancer Institute study evaluation of  
computed tomography in the diagnosis of intra-  
cranial neoplasms. I, Overall results.  
Radiology 136: 91-96, 1980.
11. Barrington N.A., Lewtas N.A.  
Indications for contrast medium enhancement in CT  
of the brain.  
Clin. Rad. 28: 535-537, 1977.
12. Beggs. I.  
The radiology of hydatid disease.  
Am. J. Roent. 145(3): 639-648, 1985.

MEDICAL LIBRARY  
UNIVERSITY OF NAIROBI

13. Bhargawa S., Tandon P.N.  
Intracranial tuberculomas: a CT Study.  
British Journal of Radiology 53: 935-945 (1980).
14. Billingham J.R.  
Intracranial SOL in African patients at  
Mulago Hospital, Kampala.  
East African Medical Journal 43: 385, 1966.
15. Braham.  
Computerized tomography diagnosis of cerebro-  
vascular disorders: a review.  
Computerized tomography, 2: 173-181.
16. Bull J.W., Zilka K.J.  
Rationalizing requests for X-ray films in  
neurology.  
British Medical Journal 1968, 4: 569.
17. Chambers A. et al.  
Suprasellar Masses.  
Seminars in Roentology April, 1984: 84-90.
18. Davis D.O., Pressman P.D.  
Computerized tomography of the brain.  
Radiological Clinics of North America 12: 297-313, 1974.

19. Davis K.R. et al.  
Cerebral infarction diagnosis by CT. Analysis  
and evaluation of findings.  
American Journal of Roent. 124: 643-660, 1975.
  
20. Davis P.C. et al.  
Prolactin - secreting pituitary adenomas: in-  
accuracy of high resolution CT imaging.  
American Journal of Roent. 144(1): 151-6, 1985.
  
21. Davis K.R. et al.  
Some limitations of computed tomography in the  
diagnosis of neurological disease.  
American Journal of Roent. 127: 111-123, 1976.
  
22. Drayer B.P., Rosenbaum A.E.  
Brain oedema defined by cranial computed  
tomography.  
Journal of Computerized assisted tomography 3:  
317-323, 1979.
  
23. Evens R.G.  
New frontier for radiology: computed tomography.  
American Journal of Roent. 126: 1117-1129, 1976.

24. Evens R.G., Jost R.G.  
Economic analysis of computed tomography radio-  
logical units.  
American Journal of Roent. 127: 191-198, 1976.
25. Evens R.G. et al.  
National CT use and radiation exposure,  
United States 1983.  
American Journal of Roent. 144: 1077-1081, 1985.
26. Fineberg H.V. et al.  
Computerized axial tomography, effects of diag-  
nostic and therapeutic plans.  
JAMA 238: 224-227, 1977.
27. Froman R., Lipschitz.  
Demography of tumours of the CNS among the Bantu  
population of the Transvaal, South Africa.  
Journal of Neurosurgery 32: 660-770, 1970.
28. Gawler J. et al.  
Computer assisted tomography: its place in  
investigations of suspected intracranial tumours.  
Lancet II (1974): 419-423.
29. Haaga J., Alfidi R.  
Computed tomography of the whole body.  
1983.

30. Haertel, Fretz, Fuchs.  
CT in the diagnosis of echinococcosis.  
Radiology 138: 533, 1981 (Abstract).
31. Hirsch L.F. et al.  
Intracranial tuberculomas and the CAT scan.  
Acta neurochirurgica 45: 155-161, 1978.
32. Hounsfield G.M.  
Computerized transverse axial scanning (tomography). (I) Description of a system.  
British Journal of Radiology 46: 1016-1022, 1973.
33. Jewel K.L.  
Sensitivity of MRI vs. CT for neuroimaging  
(letter).  
American Journal of Roent. 144(6): 1319-20, 1985.
34. Kolawole T.M. et al.  
Forencephaly: computed tomography (CT) scan  
findings.  
Computerized Radiology 11(1): 53-8, 1987.
35. Kreel, L.  
Computerized tomography using the EMI general  
purpose scanner.  
British Journal of Radiology 50: 2-14.

36. Larson E.B. et al.  
Computed tomography in patients with cerebrovascular disease: impact of a new technology in patient care.  
American Journal of Roent. 131: 35-40 (1979).
37. Larson E.B. et al.  
Impact of CT on utilization of cerebral angiograms.  
American Journal of Roent. 129: 1-4, 1977.
38. Larson E.B. et al.  
Diagnostic evaluation of headache: Impact of computerized tomography and cost effectiveness.  
Journal of the American Medical Association 243: 359-362, 1980.
39. Leeds N.E., Naidich T.P.  
Computerized tomography in the diagnosis of sella and parasellar lesions.  
Seminars in Roentology 1977; 12: 121-135.
40. Liliequist B., Lindqvist M.  
Computed tomography in the evaluation of subarachnoid haemorrhage.  
Acta Radiological (Diagn.) 21: 327-331, 1981.

41. Lipper M.H. et al.  
Computed tomography in the prediction of  
outcome in head injury.  
American Journal of Roent. 144(3): 483-6, 1985.
42. Marks, Gado.  
Serial computed tomography of primary brain  
tumours following surgery, irradiation and  
chemotherapy.  
Radiology 125: 119-125.
43. Merino-de Villasante, Taveras.  
Computerized tomography in acute head trauma.  
American Journal of Roent. 126: 765-778.
44. McNeil B.J. et al.  
Utilization of CT of the head in a tertiary  
care hospital.  
Radiology 139: 113-118, 1981.
45. Mori H. et al.  
Reliability of CT: correlation with neuro-  
pathological findings.  
American Journal of Roent. 128: 795-8.
46. Naidich T., Simmerman R.  
Primary brain tumours in children.  
Seminars in Roent. April 1984: 100-114.

47. New P.F.J. et al.  
Computerized tomography with the EMI scanner.  
Radiology 110: 109-122, 1974.
48. New P.F.J. et al.  
CT with the EMI scanner in the diagnosis of  
primary and metastatic intracranial neoplasms.  
Radiology 114: 75-89, 1975.
49. Newton D.R. et al.  
Economic impact of CT Scanning on the evaluation  
of pituitary adenomas.  
American Journal of Roent. 140: 573-576, 1983.
50. Onyango-Akena.  
Review of carotid angiography at KNH.  
(1981) M. Med. dissertation.
51. Operating instructions for the SOMATOM CR - Siemens.
52. Paxton R., Ambrose, J.  
The EMI Scanner: a brief review of the first  
650 patients.  
British journal of Radiology 47: 530-565, 1974.

53. Pressman B.D., Kirkwood J.R., Davis D.O.  
Computerized transverse tomography of vascular lesions of the brain. I. Arteriovenous malformation. II Aneurysms.  
American Journal of Roent. 124: 208-214, 215-219, 1975.
54. Price, Danziger.  
The role of computerized tomography in the diagnosis and management of intracranial abscess.  
Clinical Radiology 29: 571-577, 1978.
55. Price, Danziger.  
Computed tomography in cranial tuberculosis.  
American Journal of Roent. 130: 769-771, 1978.
56. Radue E.W., Du Boulay G.  
The contribution of plain X-ray in the management of posterior fossa in the CT era.  
Neuroradiology 16: 512-513, 1978.
57. Sage M.R., Wilson B.C., Benness G.T.  
Diagnostic and therapeutic impact of CT in patients with malignant brain tumours.  
Medical Journal of Australia 2: 493-496, 1980.

58. Sutton.  
Textbook of Radiology and Medical Imaging.  
Churchill Livingstone Fourth Edition: 1598-1630.
59. Swartz R. et al.  
Computed tomography: the cost benefit dilemma.  
Radiology 125(1): 251-3, 1977.
60. Vaquero J. et al.  
Arachnoid cysts of the posterior fossa (letter).  
Radiology 143: 301, 1982.
61. Welchman J.M.  
CT of intracranial tuberculomata.  
Clinical Radiology 30: 567-573, 1979.
62. Whelan, Stern.  
Intracranial Tuberculoma.  
Radiology 138: 75-81.
63. WHO Scientific Group: The future use of new  
imaging technologies in developing countries.  
Series No. 723.
64. Wortzman G., Holgate R.C., Morgan P.P.  
Cranial computed tomography: an evaluation of  
cost effectiveness.  
Radiology 117: 75-77, 1975.

65. Zimmerman R.A. et al.

Cranial computed tomography in diagnosis and management of acute head trauma.

American Journal of Roent. 131: 27-34, 1978.

66. Imalingat.

The clinical and radiological features of intracranial meningiomas.

(1985) M. Med. Dissertation.

## ACKNOWLEDGEMENTS

I would like to thank all the people who contributed towards the preparation of this dissertation:-

1. For guidance and help, I am indebted to Dr. Adamali, who was my supervisor.
2. For secretarial skills, the patience of Miss Mary Okoth in spite of all the work she had.
3. For photographic work, Mr. Caleb Oloo.
4. Finally, of course, I am very appreciative of the support, patience and encouragement of my husband, Dr. Vincent Orinda and my two young children, Peter and Akinyi who probably did not get as much time and attention as they needed.

MEDICAL LIBRARY  
UNIVERSITY OF NAIROBI