

THE PATTERN OF CT-SCAN FINDINGS IN BLACK STROKE PATIENTS
AS SEEN AT TWO IMAGING CENTRES IN NAIROBI

DISSERTATION SUBMITTED IN PART FULFILMENT FOR THE DEGREE OF MASTER
OF MEDICINE IN DIAGNOSTIC RADIOLOGY OF THE UNIVERSITY OF NAIROBI

BY

DR. JAMES K. THIRINGI MB.ChB. (Nbi)

UNIVERSITY OF NAIROBI
MEDICAL LIBRARY

2006

USE IN THE LIBRARY

University of NAIROBI Library




0393152 4

DECLARATION

Candidate:

This dissertation is my original work and has not been presented for a degree in any other university.

Signed 

DR. JAMES THIRINGI MB.ChB (Nrb)

Supervisor:

This dissertation has been submitted for examination with my approval.

Signed 

DR. N. M. KIMANI MB.ChB (Nrb)

MMED Diagnostic Radiology (Nrb)

Lecturer

Department of Medical Imaging and Radiation Medicine

University of Nairobi

USE IN THE LIBRARY ONLY

DEDICATION

This work is dedicated to the late Mrs. Jerioth Nyagura Ndirangu, who suffered a major infarctive stroke in September 2001 and immediately lost consciousness. A CT scan of her brain done four hours later was normal. Unfortunately, she never regained consciousness and died two weeks later. She was 86 and had lived a full and fruitful life.

ACKNOWLEDGEMENT

This study has been made possible with the assistance of a number of persons to whom I would like to express my sincere gratitude.

I am indebted to my supervisor, Dr. N.M. Kimani for his continued guidance, suggestions, comments and encouragement throughout the period of this study.

I would also like to thank Dr. B. Mugi of Kenyatta National Hospital for her painstaking review of the proposal and for her invaluable encouragement.

Dr. N. Adamali and Dr. A. Odhiambo were very kind in allowing me to conduct the study at their private imaging centers. I am very grateful to you.

This study would not have been possible without the very diligent and enthusiastic assistance I received from Mr. Richard Odoyo, the CT radiographer at MP Shah Hospital. Mr. Mohammed Hussein at Plaza Imaging Services was similarly helpful.

I would also like to appreciate the very able input by Miss Alice Lakati into the data management and analysis process.

Finally, I owe special thanks to my wife, Jennifer, for her encouragement and moral support.

Thank you all and may God richly bless you.

CONTENTS

Abbreviations-----	5
Abstract-----	6
Introduction-----	8
Literature Review-----	9
The Role of Computed Tomography	11
Cerebral Vascular Territories and Stroke	15
Pathology and CT appearances of Stroke	20
Ischaemic Stroke	20
Intracerebral Haemorrhage	24
Subarachnoid Haemorrhage	27
Objectives-----	29
Study Justification-----	30
Research Question-----	31
Methodology-----	32
Study Area	32
Study Population	32
Study Design	32
Sample Size	32
Sampling Method	32
Inclusion/Exclusion Criteria	33
Materials and Procedures	33
Data Analysis	34
Study Limitations	34
Ethical Considerations	35
Results-----	36
Discussion-----	49
Conclusions-----	60
Recommendations-----	61
References-----	62
Appendices-----	66

ABBREVIATIONS

ACA	- Anterior Cerebral Artery
ACoA	- Anterior Communicating Artery
AVM	- Arteriovenous Malformation
BA	- Basilar Artery
CT	- Computed Tomography
CECT	- Contrast Enhanced CT
ECASS	- European Co-operative Acute Stroke Study
GM	- Grey Matter
HU	- Hounsfield Units
ICA	- Internal Carotid Artery
ICeH	- Intracerebral Haemorrhage
ICH	- Intracranial Haemorrhage
LACI	- Lacunar Infarct
MCA	- Middle Cerebral Artery
MRI	- Magnetic Resonance Imaging
NECT	- Non-Enhanced CT
NH	- Nairobi Hospital
NINDS	- National Institute of Neurological Disorders and Stroke
PACI	- Partial Anterior Circulation Infarct
PCA	- Posterior Cerebral Artery
PICA	- Posterior Inferior Cerebella Artery
PIS	- Plaza Imaging Solutions
POCI	- Posterior Circulation Infarct
rt-PA	- recombinant Tissue Plasminogen Activator
SAH	- Subarachnoid Haemorrhage
SCA	- Superior Cerebella Artery
SDH	- Subdural Haemorrhage
TACI	- Total Anterior Circulation Infarct
WM	- White Matter

ABSTRACT

Introduction

Stroke lesions are known to show significant racial and regional variations. Several workers in Africa have found haemorrhagic stroke to make up a much larger proportion of stroke lesions than that reported in the West. The purpose of this study was to describe stroke patterns in Blacks in Nairobi from a radiological perspective using the imaging modality of CT.

Objective

The aim of this study was to determine the pattern of CT scan findings in black adult stroke patients seen at two imaging centers in Nairobi with particular reference to the proportions of haemorrhagic and ischaemic lesions.

Study design

This was a descriptive prospective study.

Methods

The brain CT scans of 112 consecutive patients with a clinical diagnosis of stroke done between July and December 2005 in two imaging centers in Nairobi were reviewed. Clinical information provided on the requisition forms was also recorded. The CT scans were evaluated to determine the frequency of infarctive and haemorrhagic lesions as well as their locations, sizes and local anatomical effects. The frequency of non-stroke lesions in these patients was also documented. Correlation was made of the patients' age, sex, and known medical conditions with the topographic findings on CT.

Results

There were 53 (47.3%) male and 59 (52.7%) female patients scanned. The age range was from 16 to 100 years. The mean age for stroke was 61.6 years. The 51 - 60 years and 61 - 70 years age brackets had the highest rates of stroke with 30.1% of patients each. Patients below age 50 years constituted 20.4% while those above age 65 years constituted 47.3%.

Stroke was radiologically confirmed in 84% (94) of patients. Nine examinations showed no abnormality on CT. In another nine, disorders other than stroke were found. Of the 94 patients with radiologically confirmed stroke, 68.1% (64) had infarctions, 30.9% (29) had parenchymal haemorrhages and 1.1% (one) had subarachnoid haemorrhage. The non-stroke disorders found were six subdural haematomas, two high grade gliomas and one case of cerebritis.

Conclusion

The rate of haemorrhagic type of stroke in black adult patients as seen at the two imaging centers in Nairobi is 30.9%. This is about twice that stated by most authors for the largely Caucasian population in the Europe and America. However, it is significantly lower than that demonstrated by earlier studies in Africa which suggested a rate above 50%. The findings of this study concur with those of a similar prospective study done in Zimbabwe in 1986.

INTRODUCTION

Stroke is a clinical syndrome which describes a sudden neurological deficit of presumed vascular origin that lasts more than 24 hours or results in death¹. This clinical term encompasses cerebral infarction, intracerebral haemorrhage (ICeH), subarachnoid haemorrhage (SAH) and cerebral venous occlusion. In the Western world the first two entities constitute 80% and 15% of strokes respectively, while SAH contributes 5%². Cerebral Venous and dural sinus occlusions, while often presenting with acute neurological deterioration, are a rare cause of stroke and make up less than 1% of the total; they will not be specifically addressed in this study. Subdural (SDH) and extradural haematomas are usually a result of trauma and are not part of the stroke syndrome.

The diagnosis of acute stroke is based primarily on the clinical observation of an acute neurological deficit and the exclusion of other diagnostic possibilities by CT-scanning and where necessary, metabolic tests. In specific situations MRI may be done.

The nature of stroke lesions is known to show significant racial and regional variations. A number of studies in Africa have reported much higher rates of haemorrhagic stroke than the 15%² quoted above for Western populations. Some West African countries have reported rates as high as 60%. Here in Kenya, no study has been done to specifically determine the relative frequency of the two main types of stroke. The distinction has direct impact on patient management particularly with regard to the use of thrombolytic therapy in infarctive stroke. It also has implications in the preemptive management of patients at risk for stroke. This is particularly important in the debate on the widespread use of daily antiplatelet medications like aspirin to prevent thrombotic stroke in hypertensives and diabetics. In populations where this type of stroke is far commoner than the haemorrhagic type such interventions are readily justified. However, if infarctive stroke is indeed not common in black Africa such therapy may be called into question. It is, however, quite unclear whether this is indeed the case.

Studies done in Ghana, Nigeria, Zimbabwe and South Africa have yielded widely differing results. It is my hope that this study will contribute some Kenyan data to this debate and that as more studies are done, more replicable results will emerge. This study describes the pattern of stroke lesions in Black adults in Nairobi from a radiological perspective using the imaging modality of CT.

LITERATURE REVIEW

Stroke is the third commonest cause of death in developed countries and a leading cause of long term disability. It has an incidence rate of 1-2:1000⁵. In recent years morbidity and mortality from stroke in the West has declined, largely due to improved management of underlying risk factors⁵. In contrast, here in Africa, the stroke burden is on the increase⁶.

The incidence of stroke is higher in Blacks than in other races⁷. Both the severity and mortality of stroke are also greater in Blacks⁸. The reasons are thought to include: the more frequent occurrence of haemorrhagic stroke in Blacks³; the higher frequency of hypertension and diabetes among Blacks globally⁹; the lower mean incomes of Blacks and the fact that Blacks tend to present later after the stroke thus worsening the prognosis.

In the West, ischaemic stroke has been found to account for about 80% of strokes while haemorrhagic stroke occurs in only about 15% and SAH in the remaining 5%¹¹. Several authors working in Africa have found the proportion of haemorrhagic stroke in Black Africans to be significantly higher. Some have also found the mean and peak ages for stroke to be significantly lower than those in the West and those stated in the WHO global statistics¹². Of all patients in the WHO multi-centre stroke registry 54% were aged above 64 years¹³. In the UK and USA, majority of deaths from CVA occur after the age of 74 years¹². In both countries 85% of the population is below 65, so the population structure alone would not account for the disparity in the peak age for stroke with African countries.

Analysis of stroke statistics for Africa is complicated by widely differing diagnostic protocols and a paucity of community based studies. Most estimates available are based on hospital data.

In South Africa stroke causes eight to ten percent of all deaths. The age-standardized mortality rate is about 1.5/1000 population¹⁴. Hoffmann¹⁵, in a 6 year study involving the University of Natal and the Durban Stroke Registry recorded 1260 cases from a catchment area of 8 million (KwaZulu-Natal). Young stroke patients (15 – 49 years) comprised 25.4% (320) of cases.

In Zimbabwe, Matenga et al.¹⁶ recorded a total of 113 admissions for stroke into the two teaching hospitals in Harare over a 6 month period. He conducted a prospective CT study of 100 of these Black patients and found that 29% had haemorrhages and 62% had infarcts. 2% had SAH and 7%

had non-stroke lesions. The mean age for stroke was 52 years. 39% were below age 50 and only 28% were above age 65.

In Tanzania, Matuja et al⁶ recorded 299 admissions for stroke at the Muhimbili Medical Center in Dar es Salaam over a 12 month period. He found the mean age of stroke patients to be 51 years. Only 26% were aged above 64. This was a prospective clinical study.

In Nigeria, Nwosu et al.¹⁷ recorded 240 admissions for stroke into the University of Nigeria Teaching Hospital in Enugu over a 33 month period. He found that 27.9% (67) were aged between 16 and 45 years. The rate of haemorrhagic stroke in this group of young stroke patients was 17.9% while the rates of infarctive stroke and SAH were 65.7% and 11.9% respectively.

Wirendu et al.¹⁸, in a study of 1086 autopsies of stroke patients in Ghana found 54% (586) to be haemorrhagic and 37% (397) to be infarctive. Seven percent (76) had SAH. The peak age for haemorrhagic stroke was 50-59 years, for infarcts 60-69 years and that for all stroke 50-59 years. 56% of patients were below age 60.

Nyame et al.¹⁹, in a retrospective study of 1003 Ghanaian patients found that of the 907 with proven stroke on CT, 60% (547) had haemorrhages while 40% (360) had infarcts. The mean age of stroke patients was 54 years.

Here in Kenya, morbidity associated with stroke is just as prevalent and is often personally devastating and costly. Behemuka²⁰ recorded 207 stroke admissions at the Kenyatta National Hospital (KNH) in Nairobi between 1975 and 1979.

In the same hospital, Kwasa²¹ found that of 4704 admissions to the medical wards between January 1986 and January 1987, 1084 (23%) were neurological and of these 193 (18%) had stroke. He then conducted a clinical study on 72 of the stroke patients in which he found the mean age for stroke to be 52 years. The peak age bracket was 51 – 60 years with 23.6%, followed by the 61 – 70 years bracket with 20.8%. Only 38% were aged above 60. CT findings were not included in this study.

The Role of Computed Tomography

CT has remained the accepted workhorse in stroke due to a number of advantages: widespread availability compared to other advanced modalities; cost effectiveness; reliability in detecting ICeH and SAH; high sensitivity in distinguishing haemorrhagic from non-haemorrhagic stroke and its speed and simplicity. MRI is more likely than CT to reveal silent lesions and cortical lacunar infarcts (lacunae), and also to allow the viability of ischaemic tissue to be assessed³. In the first 24 hours of stroke, special MR sequences such as Diffusion-Weighted imaging are superior to CT in picking infarcts⁴. While MRI is playing an increasing role in stroke diagnosis it is not cost-effective in the developing world and CT continues to dominate the scene.

The role of CT in stroke imaging is four-fold:

1. To confirm the diagnosis and detect stroke mimics.

Clinical diagnosis alone is inaccurate in about 13% of patients admitted to stroke units²². This is because occasionally, lesions such as tumours, subdural haematomas (SDH) and cerebral abscesses present with sudden onset of focal neurological deficit thus mimicking stroke on a clinical level. Confusion may also arise at the level of image interpretation. On CT images, infarcts may be mimicked by²³ tumours, particularly gliomas; cerebritis and encephalitis as well as by early multifocal leukoencephalopathy. Where CT appearances are equivocal, clinical history, vascular territories, relative amounts of vasogenic oedema and follow-up imaging are often helpful adjuvants in diagnosis.

Strokes often affect the cortex and spare the underlying white matter while tumours preferentially involve white matter often sparing the cortex. A full thickness lesion suggests stroke. Extensive white matter oedema without cortical involvement suggests tumour or infection². In ischaemic stroke, brain oedema increases in the first week, persists in the second and then regresses. Persistence or increasing oedema beyond that period suggests a non-stroke diagnosis². Strokes are typically wedge shaped or serpentine (gyriform) and follow a typical vascular distribution while tumours may be round, lobulated or infiltrating and not confined to a specific vascular territory.

Tumours, especially metastatic lesions of malignant melanoma, can cause ICeH and be indistinguishable from non-neoplastic bleeds²³. Neoplastic haemorrhage is suggested by a more complex structure, extensive vasogenic oedema in the acute phase and the presence of enhancing

areas not adjacent to the clot. Haemorrhagic AVMs, unlike haemorrhagic tumours (except for metastasis), are often multiple and show a relative lack of oedema.

Nyame et al.¹⁹, in a retrospective study of 1003 Ghanaian patients clinically diagnosed to have stroke found that 5.6% (56) had an entirely normal CT (unlikely to have been due to early scanning in the particular set up), and 4% (40) had disorders other than stroke (DOS). In the later category were ten subdural haematomas (SDH), eight cerebral abscess, four meningiomas and eighteen other unspecified brain tumours. Matenga et al.¹⁶, found that of 100 Zimbabwean patients with clinical stroke DOS were found in seven: SDH in four, tumours in two and cysticercosis in one.

2. To Select Patients Suitable for Thrombolysis

The ability to rapidly and accurately depict the location and extent of acute brain ischaemia has gained major importance in the last decade, largely due to the findings of two large American and European stroke studies known respectively as the NINDS²⁴ and ECASS²⁵ studies. These studies showed that thrombolytic therapy with rt-PA offered substantial benefits to selected patients with ischaemic stroke if administered within 3 to 6 hours. On the other hand, this therapy carries a significant risk of detrimental secondary haemorrhage and cerebral oedema. In this context CT is invaluable, firstly, to exclude primary ICH and secondly, to aid selection in those with infarcts. One of the problems encountered is that many patients (25% in one study) awoke with stroke symptoms with no indication of the time of onset. The dating of infarcts by CT is unreliable²⁶.

In the NINDS study, the CT criterion predictive of therapeutic benefit was the presence of a parenchymal hypoattenuation of 33% or less of the MCA territory²⁴. Patients with no hypoattenuation on early CT showed no benefit from thrombolysis. Those with lesions larger than 33% of MCA territory were at increased risk of haemorrhagic complications²⁷.

3. To give Prognostic Information

The topography of stroke is of key prognostic value. The clinical outcome is closely tied to the size and location of a haematoma or infarct and these cannot be accurately mapped without imaging. Haemorrhagic stroke, in general, bears a worse prognosis than the ischaemic stroke⁵. ICeH is fatal in about 75% of patients⁵ and the CT topography of the lesion enables the clinician to give a more

accurate prognosis to the family. Supratentorial haematomas that are over 5cm in their largest diameter have a poor prognosis. Pontine haematomas over 3cm in diameter are usually fatal⁵.

Cerebellar haematomas are unique in that immediate surgical evacuation in those over 3cm in diameter is often helpful. Those less than 1cm in size are managed conservatively while those measuring 1 – 3cm are evacuated if consciousness is significantly impaired⁵.

Involvement of the MCA territory is a poor prognostic marker. Infarcts with the hypodensity covering over 50% of the MCA territory are associated with 85% mortality²⁸. Death is usually due to severe brain oedema. The involvement of multiple vascular territories is another poor prognostic marker.

The presence of hypoattenuating brain tissue at CT within the first 6 hours of stroke is associated with larger volume infarcts, a less favourable clinical course and a high risk of secondary cerebral haemorrhage and death. Less severe strokes are associated with delay in appearance of the ischaemic lesion on CT. A normal early CT indicates less severe disease²⁹. Frank hypodensity of the lentiform nucleus on early CT is strongly associated with later haemorrhagic transformation of the infarct³⁰.

Bamford et al.³¹ described the natural history of cerebral infarction in 543 British patients based on four topographical subgroups and a four year follow-up. Their key findings are summarized below:

- (a) Total anterior circulation infarcts (TACI) – constituted 17% of infarcts. These included both cortical and subcortical involvement of the MCA (with or without the ACA) territories. This group had a negligible chance of a good functional outcome and mortality was high, especially from transtentorial herniation. Stroke recurred in 6% within a year.
- (b) Partial anterior circulation infarcts (PACI) – constituted 34% of infarcts. These were the more restricted and predominantly cortical infarcts, including isolated ACA infarcts. No direct neurological deaths occurred in this group. Stroke recurrence was high at 17% within a year and occurred early.
- (c) Posterior circulation infarcts (POCI) – constituted 24% infarcts. These were lesions in the vertebrobasilar territory: brainstem, cerebellum and occipital lobes. They had the best chance of a good functional outcome. A few died early, presumably due to

brainstem dysfunction. The recurrence rate of stroke was high at 20% within a year, but occurred later in that period.

- (d) Lacunar infarcts (LACI) – constituted 25% of infarcts. These were small infarcts in the territory of the deep perforating arteries. A large proportion of patients remained substantially handicapped. They were not associated with any direct neurological deaths. They had a low recurrence rate of stroke at 9% within a year.

There are extensive collateral channels around the brainstem and the vascular anatomy here is variable making it difficult to correlate the areas of infarction with occlusion of specific vessels. Because of this Bamford³¹ grouped the infarcts associated with the brainstem, cerebellum and occipital lobes together.

4. To Detect Early Complications of Stroke

Common early complications include frank haemorrhagic transformation of infarcts and raised intracranial pressure with cerebral herniation. The former occurs in 15-20% of MCA occlusions commonly in the basal ganglia and the cortex³².

Cerebral Vascular Territories and Stroke

There is considerable variation in the locations of the boundaries of the various vascular territories. The boundaries themselves are not rigid but show some dynamism dependent on haemodynamic conditions. These conditions affect flow in the leptomeningeal anastomoses that connect the larger arterial territories³³.

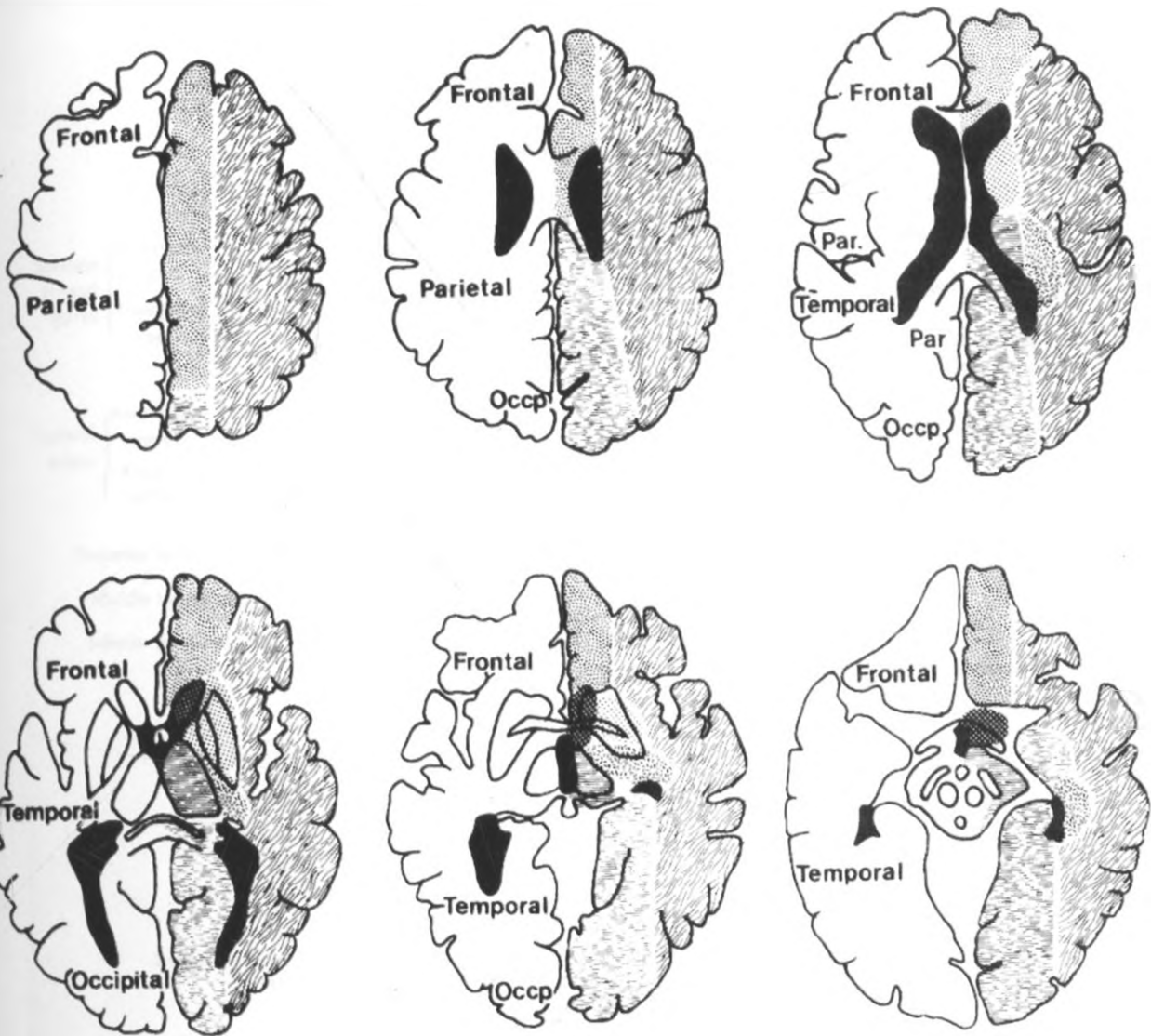
The anterior cerebral artery (ACA) and the middle cerebral artery (MCA) are often referred to as the anterior or 'carotid' circulation and are the terminal branches of the internal carotid artery (ICA). Both give lenticulostriate arteries to the basal ganglia and internal capsule. The posterior cerebral artery (PCA) and Basilar Artery (BA) are the key components of the posterior or 'vertebrobasilar' circulation. These together with the Posterior Communicating Artery (PCoA) give thalamoperforating branches to the midbrain, thalamus and posterior limb of the internal capsule.








The Middle Cerebral artery (MCA)

This artery typically supplies the following: most of the lateral hemisphere (sensorimotor except leg and foot area); the anterior temporal lobe and the lentiform nucleus (almost always) through lenticulostriate branches. The caudate nucleus and deep frontal white matter is variably supplied, complementary with the ACA contribution. It also supplies the genu of the internal capsule through the "artery of cerebral haemorrhage".

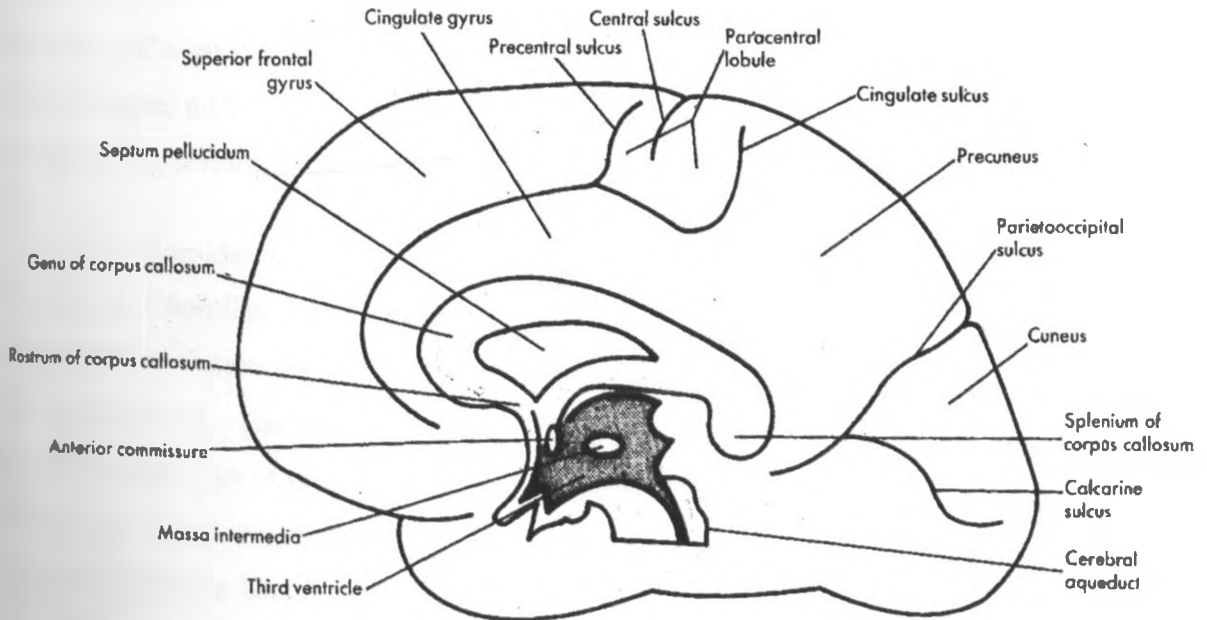
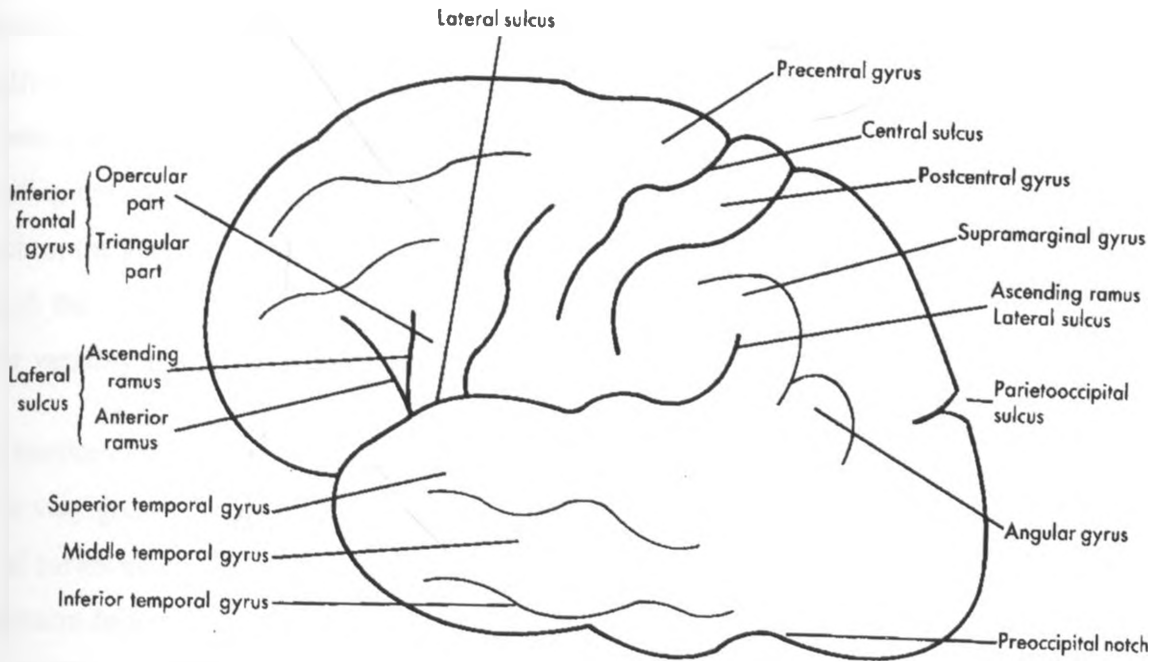
Over 75% of all strokes occur in the MCA territory². If the entire MCA is involved, the basal ganglia, the deep cerebral white matter and much of the hemispheric cortex are affected. The infarct shows as a wedge shaped area from the lateral ventricle to the brain surface. MCA infarcts sometimes involve only the anterior or posterior division. The lentiform nucleus may be spared if occlusion occurs distal to the MCA bifurcation.

Axial line diagrams showing the cerebral vascular territories³⁴



- | | | | |
|---|--------------------------------|---|---------------------------------|
|  | Anterior Cerebral Artery |  | Posterior Cerebral Artery |
|  | Anterior Cerebral Artery, deep |  | Posterior Cerebral Artery, deep |
|  | Middle Cerebral Artery |  | Anterior Choroidal Artery |
|  | Middle Cerebral Artery, deep | | |

Line diagrams showing the main gyri and sulci of the brain³⁵



The Anterior Cerebral Artery (ACA)

This artery is smaller than the MCA. It supplies the medial aspect of the frontal and parietal lobes up to the parieto-occipital sulcus. In two-thirds of people the ACA/PCA boundary is on the convexity in this sulcus or along the superior parietal lobule. The middle of the orbitofrontal gyrus usually demarcates the inferior border with the MCA. The ACA also supplies the following regions: a thin strip of the adjacent superolateral hemispheric surface (the anterior two-thirds only, including the leg and foot sensorimotor areas); the septum pellucidum through pericallosal branches; the anterior two-thirds of the corpus callosum; the anterior limb of the internal capsule through the recurrent artery of Heubner and the caudate nucleus together with the deep frontal white matter variably and complementary to the MCA contribution.

ACA territory infarcts are relatively rare as embolism into this artery is less likely and collateral flow is very good. Isolated ACA infarcts constitute 0.6% of all infarcts³⁶. They typically involve a strip of cortex along the anterior aspect of the inter-hemispheric fissure. The commonest cause is focal spasm following SAH.

The Posterior Cerebral Artery (PCA)

This is the terminal branch of the Basilar artery and typically supplies: the posterior 1/3 of the cerebral convexity, particularly the occipital lobe; the inferior temporal lobe; part of the posterior limb of the internal capsule (complementary to the Anterior Choroidal Artery) and part of the thalamus. PCA infarcts are second in frequency to MCA ones². The common sites are the calcarine cortex, thalami, midbrain and the posterior limb of the internal capsule. The PCA passes just above the edge of the tentorium cerebelli and may be compressed when intracranial pressure is elevated.

The Choroidal Arteries

The Anterior Choroidal Artery (AChA) is given off the Internal Carotid above the Posterior Communicating Artery (PCoA) origin. The medial and lateral Posterior Choroidal Arteries (PChA) arise from the PCA. The territories of the PChAs are complementary to those of the AChA which typically include: part of the posterior limb and genu of the internal capsule; the medial globus pallidus and the optic tract; the uncus of the temporal lobe and the Amygdaloid nucleus and the choroid plexus of the lateral ventricle.

The Basilar Artery (BA)

This artery is formed at the ponto-medullary junction by the union of the two Vertebral Arteries. It gives perforators that supply the pons, midbrain and posteroinferior part of the thalamus. Occlusion related to the BA may occur in 3 ways:

- i. Occlusion of the short perforators only leading to infarcts in the pons and midbrain.
- ii. BA Thrombosis – this causes patchy multi-focal infarcts in the territories of the Anterior Inferior Cerebellar Arteries (AICA), Superior Cerebellar Arteries (SCA) and the PCA.
- iii. Distal BA occlusion leading to the “Top of the Basilar Syndrome” with lesions in the pons and midbrain (BA); the thalami and posterior limb of internal capsule (PCA); the occipital lobe and the posterior temporal lobe (PCA). The combination of infratentorial, thalamic and occipital infarcts is highly suggestive of this syndrome. The BA may appear unusually dense on CT.

The Superior Cerebellar Artery (SCA)

This artery branches off the BA just below the tentorium. It supplies the entire superior surface of the cerebellar hemispheres, the superior vermis and most of the deep cerebellar white matter. SCA lesions affect the superior cerebellum, the ipsilateral vermis and varying amounts of cerebellar white matter.

The Anterior Inferior Cerebellar Artery (AICA)

This is the first branch of the BA. Of the cerebellar arteries it covers the smallest territory. It has a reciprocal supply with PICA and supplies the flocculus, the anterior (petrosal) surface of the cerebellum and the middle cerebellar peduncle. It also supplies part of the pons and in some cases part of the medulla. Isolated AICA infarcts are uncommon and typically occur in diabetic and hypertensive patients with atherosclerotic vascular disease (ASVD). They show as focal lesions in the brachium pontis or curvilinear infarcts along the petrosal surface of the cerebellum.

The Posterior Inferior Cerebellar Artery (PICA)

This artery branches off the Vertebral Artery at the level of the medulla. It supplies the posteroinferior cerebellum, the cerebellar tonsil, inferior vermis and often, the posterolateral medulla. PICA infarcts tend to spare the deep cerebellar white matter and dentate nucleus as these are supplied primarily by the SCA.

Pathology and CT appearances of stroke

Ischaemic Stroke

The two main causes of primary cerebral ischaemia are atherothrombosis and embolism². Emboli may originate from the heart, particularly in patients with atrial fibrillation or myocardial infarction, or from a larger proximal artery most commonly from an ulcerated plaque at the carotid bifurcation. Multiple infarcts in different arterial territories suggest a cardiac source of emboli.

In young patients carotid artery dissection and vasculitis are additional causes of ischaemic stroke. Other causes of vascular narrowing include vasospasm (secondary to SAH or infection), fibromuscular dysplasia of the cervical ICA and tumour encasement of vessels (pituitary adenoma, carcinoma of the PNS). Vascular occlusion may also occur in hypercoagulable states. Ischaemic stroke occurs as a complication of sickle cell disease in 6 - 9% of cases³⁷. Infection with the HIV virus is an important cause of ischaemic stroke in young and middle aged patients. Mochan et al.³⁸, in South Africa studied 35 such patients and found that 94% (33) had infarctions while 6% (2) had haemorrhages. He also found that coagulopathies and meningitis played an important role.

The cerebral arteries can be occluded at 3 sites. The first is at the terminal branches - leading to cortical infarcts. The second is at the deep perforating vessels - leading to lacunar infarcts (small infarcts in the basal ganglia and capsular region). This usually follows microvascular hyaline degeneration of the long perforating arteries in elderly, hypertensive or diabetic patients. The third is at the main trunk - leading to infarction of an entire vascular territory. When leptomeningeal collaterals are adequate, the cortex may be spared leaving a large striatocapsular infarct.

The cerebral microvasculature offers relative protection to some regions while leaving others comparatively vulnerable. The subcortical white matter and the extreme and external capsules have dual or even triple interdigitating supply. The cortex has short arterioles from a single source. The thalamus, basal ganglia and centrum semiovale have large long single source vessels which are susceptible to hypertensive, diabetic and atherosclerotic damage.

Arterial perfusion is lowest in the watershed areas (areas between the capillary beds of the major cerebral arteries) because of arteriolar arborization. These areas are the first to suffer ischaemia and infarction in the event of generalized hypoperfusion usually due to haemodynamic disturbances.

This leads to Hypoxic Ischaemic Encephalopathy (HIE). Watershed infarcts may be linear or wedge shaped. A low density band is seen on CT most commonly at the parieto-occipital confluence of the ACA, MCA and PCA. The basal ganglia are also a common site.

Stroke progresses from ischaemia to actual infarction. Most ischaemic strokes consist initially of a small central region of complete ischaemia - where cells are damaged irretrievably unless perfusion is quickly re-established - surrounded by a region of reduced perfusion, the penumbra. The cells in the penumbra are kept viable by collateral flow but remain at risk of irreversible injury. Current salvage therapies aim to rescue these cells³⁹.

CT Findings in Infarction

CT findings in acute cerebral ischaemia evolve over time. The time divisions that follow are variable and are modified from Anne Osborne's Diagnostic Neuroradiology².

(a) Hyperacute infarct: first 6 – 12 hours

Hypoperfusion leads to failure of the sodium pump causing intracellular sodium accumulation. Water shifts into the cells and the neurons swell. Cytotoxic oedema predominates in this stage and it mainly affects the grey matter diminishing its contrast with adjacent white matter. This loss of anatomical margins explains some of the early CT signs. CT at this stage may be normal in 50 – 60% of patients⁴⁰ but may otherwise show some of the subtle signs of early ischaemia outlined below.

(b) Acute infarct: 12 – 24 hours

Ischaemic damage to the endothelial lining of capillaries leads to breakdown of the blood-brain barrier. Intravascular fluid leaks into the extracellular space producing vasogenic oedema that spreads in the white matter. This peaks at 24 – 48 hours. In addition to the earlier signs, CT at this time may show hypoattenuation of the basal ganglia and sulcal effacement.

(c) Early subacute: 2 – 3 days

Most large vessel infarcts are visible on non-enhanced CT (NECT) as wedge shaped hypodense areas involving both gray and white matter in a typical vascular distribution. Mass effect increases. Haemorrhagic transformation may occur, commonly in cortical or basal ganglia infarcts.

(d) Subacute: 4 – 7 days

Gyral or patchy enhancement is seen on contrast enhanced CT (CECT). Sometimes, this is present from day 3. Enhancement persists for up to 8 – 10 weeks. Mass effect and oedema persist during this period.

(e) Late subacute: 1 – 8 weeks

Contrast enhancement persists. Mass effect diminishes after 7 – 10 days.

(f) Chronic: 2 months to years

A focal well delineated low attenuation area may be seen whose radiodensity approaches that of CSF. Encephalomalacia with volume loss occurs. Adjacent sulci may be prominent and the ipsilateral ventricle may enlarge due to focal atrophy.

Very rarely dystrophic calcification may occur.

The subtle signs of early cerebral ischaemia are:

i. A hyperdense MCA

This is caused by fresh thrombus in the horizontal M1 segment of this artery. It is the earliest detectable change on CT and can be seen from the onset of the ictus. It is seen in 25% of all acute infarcts and 35 – 50% of MCA territory infarcts⁴¹. It is an unfavourable sign correlating with large infarcts and worse patient outcome. Heavily calcified MCAs can mimic this sign but are usually bilateral. On the other hand a mildly hyperattenuating MCA may reflect the normal slight hyperdensity of intravascular blood to brain and not thrombosis.

ii. Obscuration of the outline of the lentiform nucleus

This may be visible within an hour⁴². It reflects cytotoxic oedema. A change in water content of 1.5% corresponds to a 4HU change in CT number and is visually detectable⁴².

iii. The Insular Ribbon Sign

Loss of the grey/white matter interface along the lateral insula. This region, composed of the island of Reil, the extreme capsule and the claustrum is furthest from the ACA and PCA collaterals in MCA infarction. In one study this sign was present in 23 of 27 MCA infarctions⁴³.

iv. Effacement of grey white matter junction along the cortex.

v. Subtle effacement of cortical sulci. This may be seen from about three hours⁴².

vi. Subtle hypoattenuation of the white matter

This may be present within an hour of ictus and may be seen in up to 60% of cases at six hours⁴². Hypoattenuation may be defined as a visible decrease in radiodensity of brain tissue compared with that in other portions of the same anatomic structure or its contralateral counterpart.

Early ischaemic changes on CT are easily overlooked. The CT scans of the patients entered into the ECASS study (n = 786) underwent a second review by experts which showed that initial “on-site” interpretation had overlooked an early infarct in 11% of patients²⁵. Matenga et al.¹⁶, in Zimbabwe found that of 62 patients with infarcts 19% (12) did not have the lesions detected on the initial CT. A normal CT finding in a patient with acute stroke may be explained by the following²⁹: focal brain ischaemia above the critical level of structural integrity; an early stage of ischaemic oedema causing hypoattenuation below contrast resolution; ischaemia mainly confined to white matter and location of a lesion near the skull base where beam hardening artifacts impair recognition. Lacunar infarcts may also be a cause. Due to their small size most true lacunar infarcts are not picked by CT².

In a study of 31 patients with infarcts scanned within 24 hours of ictus (mean 8 hours) the CT and MR detection rates were 58% and 82% respectively⁴⁰. On follow-up scans at 7-10 days both modalities detected 88% of subacute infarcts. In this series the distribution of the infarcts was thirteen cortical, eight subcortical, seven combined and three in the posterior fossa. Nine lesions were under 2cm; four over 5cm and eight were in between. In a similar study of 44 patients with infarcts imaged within 8 hours of ictus the sensitivity of unenhanced CT was 55% while that of perfusion CT was 76%⁴⁴. Small infarcts in eight patients – mean size 1.47cm - were missed on both modalities. Dynamic perfusion CT was performed at the level of the basal ganglia with the gantry perpendicular to the posterior part of the superior sagittal sinus. Contrast used was 40ml of LOCM 300 given at 8ml/s. Images were taken at 1/sec for 40s with a 4s delay. This mode of imaging improves early infarct detection but is not currently in use in Kenya.

Lacunar infarcts account for 15% – 25% of all strokes⁴⁵. They are small deep cerebral infarcts typically located in the basal ganglia and thalamus. They are often multiple and are due to embolic, atheromatous or thrombotic lesions in the long single penetrating arterioles that supply the deep cerebral grey matter. In a study of 1003 patients by CT in Ghana, Nyame et al.¹⁹ found no lacunar

infarcts and concluded that the resolution of their CT was not adequate to pick them. MRI is better at picking lacunae.

Contrast enhancement is common in subacute infarcts and reflects blood-brain barrier disruption initially, and then neovascularity associated with repair subsequently. It can persist for up to 12 weeks²³ and may be cortical, central, patchy and sometimes dense. Its diagnostic value is limited due to non-specificity.

Venous infarcts are often haemorrhagic and primarily affect white matter. CT may show patchy foci of oedema and petechial haemorrhages within the first two days. Signs of dural sinus occlusion like a hyperdense clot in a dural sinus (commonly the superior sagittal or transverse sinuses) or the empty delta sign may also be present. Haemorrhagic transformation of arterial infarcts tends to occur later than in venous ones but still within the first 2 weeks and is probably due to reperfusion. It is often seen in the basal ganglia and the cortex²³.

Intracerebral Haemorrhage (ICeH)

The commonest non-traumatic cause of ICeH is hypertensive arteriopathy causing rupture of a small perforating vessel⁴⁶. This accounts for 40-60% of ICeH. The preferential sites are the penetrating branches of the MCA and the basilar artery. Nearly two-thirds of spontaneous ICeH are in the basal ganglia. The sites commonly affected² are the putamen and external capsule in 60 – 65% of cases; the thalamus in 15 – 25%; the pons in 5 – 10%; the cerebellum in 2 – 5% and the subcortical white matter in 1 – 2%. Large haematomas often extend beyond the putamen to include the globus pallidus and internal capsule. Not infrequently, large basal ganglia haemorrhages may also extend into the ventricles or Sylvian fissure. Clot dissection into the ventricular system occurs in half the cases of hypertensive ICeH and is associated with a poor prognosis especially when the 4th ventricle is involved⁴⁷. Cerebellar bleeds typically originate near the dentate nucleus along perforating branches of the SCA or PICA. The midbrain, medulla and spinal cord are rarely involved in hypertensive ICH.

Wirendu¹⁸, in a study of 1086 autopsies on stroke mortalities in Ghana, found 71% of the haemorrhages to be intracerebral, 6% pontine, 5% cerebellar and 6% to involve multiple sites. SAH constituted 12% of intracranial haemorrhage.

Amyloid angiopathy is a common cause of ICeH in the elderly normotensive patient and accounts for 15-25% of ICeH². The haemorrhages are characteristically multiple, spare the basal ganglia and brainstem and are usually located at the corticomedullary junction. In the young, AVMs, cavernous angiomas and substance abuse are the commoner causes of bleeds. AVMs account for 10-15% of all ICeH². Unexplained ICH in a normotensive young adult is often caused by an AVM. When repeated haemorrhage occurs into an AVM the appearance may resemble a neoplasm. Venous angiomas rarely bleed and telangiectasie are usually small and clinically silent. Very occasionally, aneurysm rupture can cause ICeH without SAH. Street drugs like cocaine may induce an acute hypertensive episode that results in ICeH (1 - 2% of cases). The location of bleeds is similar to that of hypertensive ICeH in the elderly.

Rarer causes of ICeH are coagulopathies (<1% of cases), vasculitis, venous infarcts, haemorrhagic transformation of arterial infarcts and herpes encephalitis. Haemorrhages from malignancy related coagulopathy (usually associated with leukaemias and chemotherapy) show no unique imaging features. They tend to be supratentorial and intraparenchymal. Intratumoral haemorrhage is associated with high grade astrocytomas, very vascular tumours and necrotic tumours such as pituitary adenomas. Metastatic lesions from kidneys and lungs, as well as choriocarcinoma and melanoma also tend to bleed.

About 25% of patients die within the first 48 hours of ICeH⁴⁷. Delayed neurological deterioration occurs in a small percentage usually due to rapid clot expansion with secondary brain herniation. In patients with persistent hypertension, delayed re-bleeds may occur.

Haemorrhagic infarctions are nearly always the haemorrhagic transformation of initially ischaemic lesions, usually following arterial embolism. It is thought to occur when the emboli are lysed and damaged endothelium is reperfused. It may range from petechial haemorrhages to frank parenchymal haematomas. Common sites are the basal ganglia and the cortex.

CT Findings in ICeH

CT is highly sensitive (nearly 100%) and specific in detecting acute ICeH⁴⁸. Demonstration of the clot depends on its location, volume and density. The CT density of the haematoma depends on the initial haemoglobin content, dilution by extracellular fluid, partial volume effects, windowing and

most importantly the age of the clot. A high haematocrit carries a higher concentration of the protein 'globin' giving a higher mass density and greater attenuation of X-rays. Clot densities are described in relation to that of brain tissue which measures 30 – 45HU. (White matter measures 30 – 35HU and Grey matter 36 – 46HU).

(a) Hyperacute haemorrhage: first 6 hours

Acute haemorrhage is hyperdense to brain measuring about 55 – 80HU but may reach 100HU. The clot retracts packing the RBCs to a haematocrit of 70 – 90%. There is a linear relationship between the CT attenuation and the haematocrit. If the haematocrit is low (20% or less), it may be isodense to brain⁴⁹. Isodense haematomas may also occur with a haemoglobin concentration of 8g/dl⁵⁰. A rarer cause of isodense acute clots is failure of clot retraction due to coagulopathies. Fluid – fluid levels may be seen in such clots. A hyperacute clot is usually rounded, homogenous and has little or no oedema around it. A fine low density rim that may be seen around it is usually caused by clot retraction. Rapid bleeding may cause a clot with an unretracted semi-liquid center which on CT appears as a hypodense area within the generally hyperdense haematoma (the swirl sign).

(b) Acute haemorrhage: 7 - 72 hours

The clot remains hyperdense with a haematocrit up to 90%. Oedema surrounding the clot is pronounced and progresses for 24 to 48 hours. This is usually vasogenic oedema in the surrounding white matter.

(c) Subacute haemorrhage: 4 days – 4 weeks

The haematoma becomes less radiodense from the periphery towards the centre and eventually becomes about isodense to brain. This may take between one and six weeks. The attenuation decreases on average 1.5HU daily⁵¹.

Oedema slowly subsides. Mass effect diminishes.

A perivascular inflammatory reaction occurs in the brain tissue surrounding the clot. In addition, proliferating capillaries at the clot's periphery initially have a deficient blood brain barrier and so subacute haemorrhages sometimes show peripheral enhancement on CECT⁵².

(d) Chronic haemorrhage: over 4 weeks

In the early chronic phase vascular proliferation encroaches on the clot, reducing its size. The clot is hypodense to brain and may be isodense to CSF. Due to this, establishing the diagnosis of an old haemorrhage by CT in a previously unscanned patient is not possible, as it may resemble an old infarct²³. MRI can differentiate the two.

There is no oedema present.

In the late chronic stages collapsed slit-like lesions or cavities are seen in about 25%, low attenuation foci in 37% and calcifications in 10%. No identifiable residual abnormality is seen in the remaining 27% on CT⁵³. Residual lesions are commonly in the region of the putamen and external capsule.

Ring enhancement may persist to the 6th month⁵⁴.

Any areas of high attenuation are likely to be due to re-bleeding.

Re-bleeding outside an organized haematoma can resemble tumoral haemorrhage while re-bleeding within it may produce a target sign on CECT. Where IVH has occurred, blood may adhere to the ependyma or the choroid plexus or sink into the horns (usually the occipital) leading to a fluid level. Small clots near the calvarium or skull base are difficult to detect. A wider window width of between 150 – 250HU helps separate small peripheral clots from dense overlying bone.

The CT finding of multiple peripherally located haemorrhages of different ages in an elderly normotensive strongly suggests cerebral amyloid angiopathy⁵⁵. Haemorrhagic infarctions are seen on CT in 5 – 15% of all stroke cases⁵⁶. In large infarcts the rate is about 25%. Autopsy studies show a much higher occurrence rate. Most are identified 24 – 48 hours after the ischaemic event³² as high density foci within previously ischaemic areas. They are virtually always associated with mass effect². Delayed cortical haemorrhagic infarctions can also develop if collateral pial supply increases after oedema and mass effect diminish.

Subarachnoid Haemorrhage (SAH)

Spontaneous SAH is due to a ruptured arterial aneurysm in 70 – 80% of patients and an AVM in about 10%²³. AVMs are more commonly associated with ICeH. Very rarely intracranial tumours such as pituitary adenomas can bleed into the subarachnoid space. In the remaining cases no underlying cause is found. Most aneurysms are located on or close to the circle of Willis. Ninety

percent are in anterior (carotid) circulation and 10 % in the posterior (vertebrobasilar) circulation. The Anterior and Posterior Communicating Arteries each bear about a third of all cerebral aneurysms, while the MCA bears 20% and the Basilar Artery bifurcation 5%²³.

CT Findings in SAH

The typical signs of sudden severe headache, neck stiffness and photophobia usually allow a clinical diagnosis. CT is positive in over 90% of cases if the scan is carried out within a few days of the haemorrhage²³. Detection is high within 4 – 5 days of onset²⁸. The hallmark of recent SAH is increased density of the CSF spaces. Blood is most commonly seen in the basal cisterns and Sylvian fissures but the entire subarachnoid space may be involved sometimes with reflux into the ventricular system. In some cases the blood may clot around a ruptured aneurysm. When the cerebral convexities are involved, subarachnoid blood along the falx and paramedian sulci gives a high density 'feathered' appearance in the interhemispheric fissure.

Blood in the Sylvian fissure may be due to an aneurysm in the ipsilateral ICA, PCoA or the MCA. Focal inter-hemispheric blood is usually due to an ACoA aneurysm. Blood in the 4th ventricle is often caused by a PICA lesion. CT reflects relative densities and because of this conditions that cause overall low density in the brain parenchyma such as diffuse cerebral oedema may mimic SAH. Ninety percent of extravasated blood in SAH is cleared within 1 week and by this time only half of all SAHs remain detectable⁵⁷. SAH visualized on CT more than 1 week after the initial haemorrhage suggests rebleeding.

CT may also show two important complications of SAH, hydrocephalus and ischaemic infarction secondary to vasospasm. The hydrocephalus is usually the communicating type and it is very common to see mild dilation of ventricles, particularly the temporal horns within a few hours of the bleeding. It usually resolves over several days. Ischaemic infarction is not rare and usually occurs between four and eleven days after the SAH²³. It is commoner with large amounts of subarachnoid blood.

OBJECTIVES

Broad Objective

The main objective of this study was to determine the pattern of CT-scan findings in black adult stroke patients seen at two imaging centers in Nairobi.

Specific Objectives

The key specific objective was to determine the proportions of the two main types of stroke, namely haemorrhagic and ischaemic stroke in the patients studied. The study also aimed at documenting the age and sex distribution of the stroke patients seen as well as determining the anatomical location and estimated size of stroke lesions. Finally, the study sought to ascertain the frequency of detection of stroke mimics.

JUSTIFICATION

This study has not been carried out in Kenya before. A clinical study done by Kwasa²¹ at the Kenyatta National Hospital in 1987 did not incorporate the use of CT. Owino-Musa⁵⁸, in 1993 carried out another clinical study at the same hospital but this was restricted to young stroke patients aged below 45 years. Of the 41 patients he studied only half had a CT scan of the head and the details of stroke topography were not specifically studied.

Knowledge of the CT topography of stroke is important because it correlates closely with outcome and impacts the therapeutic decision making process. CT offers a simple and widely applicable method of classifying stroke. A classification based on pathophysiology requires extensive and costly investigation and may be inconclusive in up to 40% of patients⁵⁹. The other main method of investigating stroke, MRI, while offering certain key diagnostic advantages, is not cost effective in the developing world.

Due to the prevalence of haemorrhagic strokes among blacks, great caution needs to be exercised in the use of anticoagulants and thrombolytics before haemorrhage is excluded as the cause of stroke. This is particularly important in places where CT scans are not available and treatment is given empirically. This study has shown what proportion of stroke is haemorrhagic among black patients seen at two imaging centers in Nairobi. It has also shown, quite unfortunately, that the proportion of patients who obtain a CT-scan early enough to be considered for thrombolytic therapy where this may be indicated is extremely low. In fact, none of the stroke patients seen at the two study centers met the time criteria for thrombolytic therapy. This shows that a lot needs to be done to get stroke patients to hospitals and CT-scan rooms faster. Thirdly, due to the key prognostic significance of the size and location of a stroke lesion, the study has described the pattern of lesions encountered.

One other important aim of this study was to show whether stroke mimics – particularly the treatable ones – were commonly encountered in the study population. This was indeed found to be the case and calls for the urgent use of CT in all stroke patients to exclude such mimics.

RESEARCH QUESTION

Is intracerebral haemorrhage more common than cerebral infarction among black stroke patients seen at the two imaging centers in Nairobi?

METHODOLOGY

Study Area

This study was conducted at the CT-Scan units of two centers concurrently, namely, MP Shah Hospital, Nairobi (MPS) and Plaza Imaging Services, Nairobi (PIS).

The CT-scanner at Kenyatta National Hospital which is the university teaching hospital was not functional during the study period and this center was not included in the study.

Study Population

This consisted of patients who had been seen by their respective doctors, a clinical diagnosis of a recent stroke made and the patient referred for a CT-scan of the head to one of the centers listed under study area above, within the period of the study.

Study Duration

The study ran from July to December 2005.

Study Design

This was a descriptive prospective study.

Sample Size

This was determined using Fisher's formula⁶⁰.

$$n = Z^2 P (1-P) / d^2$$

Where, n = sample size;

Z = standard normal deviate value corresponding to 95% confidence level (=1.96).

P = estimated proportion of stroke patients with haemorrhagic lesions. The Zimbabwean value was used, therefore P = 29%¹⁶

d = degree of precision set at 10%

$$n = 1.96^2 \times 0.29 \times 0.71 / 0.1^2 = 80 \text{ patients.}$$

This figure was regarded as a minimum sample size and was exceeded during the study duration.

The actual number of patients studied was 112.

Sampling Method

Every patient from the study population above who presented to either of the two centers for CT scanning during the study period was recruited into the study.

Inclusion and Exclusion Criteria

All patients aged 15 years or older with a clinical diagnosis of stroke, and in whom the ictus had occurred within the preceding two weeks were recruited. (Within this duration infarction and haemorrhage can be reliably differentiated on CT images). Patients with known non-stroke neurological disorders or Head Injury were excluded from the study.

Materials and Procedures

The patients hospital number, X-ray number, age, sex, race, time of ictus, date of scan and concise relevant clinical history were obtained at the time of the scan from the clinicians request form, the patient or the accompanying nurse or relative. Where clarification was necessary the patient's file, which was usually brought to the CT room, was perused and when necessary the primary clinician was consulted. The above information was recorded on the data collection sheet by the principal investigator.

The types of CT scanners at the two centers that were used were a Siemens Somatom ART Model 06207059 Conventional Scanner at MPS and a Phillips Tomoscan CXIQ 3rd generation Spiral scanner at PIS. Both centers followed a similar imaging protocol which may be summarized thus: the patient lies supine on the CT couch and the head is immobilized with restraining devices; a scanogram is performed and used to plan the examination; scans are performed from the base of the skull to the vertex parallel to the canthomeatal line using a KiloVoltage of about 120KVp. The slice thickness used was 5mm and 10mm in the posterior fossa and supratentorial regions respectively. Contiguous slices were used.

Intravenous contrast media was not routinely administered in stroke imaging in these centers. It was given – about 40-50ml of a low osmolar contrast media containing 300mg Iodine/ml (LOCM 300) - in specific situations such as when a non-stroke diagnosis was suspected, particularly tumour or infective lesions; in subacute infarcts and in suspected vascular malformations. Window level and width were optimized to allow clear differentiation of gray and white matter so as to pick any early changes of infarction. A window width of about 80HU and window level of about 40HU was most commonly used.

The images were studied on the monitor and recorded on film. The interpretation of images was done with the help of consultant radiologists at the two centers and whenever possible were reviewed with the University Supervisor. The findings sought were as per the outlines under “CT findings” in the literature review above. These were reflected in the data collection sheet. The evaluation of lesion size was non-quantitative: relative estimates of size were made by measuring the maximum diameter of the lesion and then the largest diameter obtainable perpendicular to the first, in the same CT section. Lesions were then grouped into three sizes: less than 20mm, 20 – 50mm and over 50mm.

Data Management and Analysis

The data collection form was pre-tested over a two week period at the MP Shah hospital. Appropriate adjustments were made before commencement of the study. All data was recorded on a separate data collection sheet (appendix 1) for each patient. It was then entered into the computer software SPSS 11.5 (Statistical Package for Social Sciences). Data cleaning was done by running frequencies and errors corrected.

Statistical analysis was carried out. Categorical values were calculated in terms of proportions. Continuous variables were analysed using measures of central tendency. Confidence intervals were calculated using the 95% confidence levels. Where correlations were made, for example, between ‘age’ and ‘type of stroke’ or between ‘presence of hypertension’ and ‘type of stroke’, the Chi-Square test was used to test for association. Statistical significance was assessed at alpha level $\alpha = 0.05$. Fisher’s exact test was used to determine association between the presence of diabetes and the type of stroke lesion suffered. This test was used because the low cell count invalidated Pearson’s Chi-Square test. The test was carried out using Epi-Info software.

Study Limitations

Due to logistical and time constraints this study lacks correlation with the patient’s neurological symptomatology and clinical progression. Firstly, quantification of the neurological deficit by a recognized clinical neurological scoring scale and assessment of the various risk factors would necessitate an expansion of the study in terms of personnel and diagnostic work up which is not feasible at the moment. Secondly, the clinical studies by Kwasa²¹ and Owino-Musa⁵⁸ at KNH referred to earlier have already addressed these issues.

In the occasional case where CT-scan was performed within 24 hours of ictus and was normal despite clinical suspicion of ischaemic stroke, confirmation by other modalities or by a follow-up CT was not performed. This was due to financial limitations.

This study may have failed to sample patients with mild stroke who were not referred for CT scanning. On the other extreme, some patients with severe strokes may have died before they could be referred for imaging. Some also may not have sought medical help at all. All these factors introduce bias.

Some stroke patients, particularly those admitted in public hospitals may not have afforded CT-scanning at the private centers where the study was done and were therefore not sampled. Since stroke is thought to be more common and more severe in the lower socio-economic groups⁶¹, this is likely to have introduced a degree of selection bias.

Ethical Considerations

Before commencement of this study, the research proposal was submitted to the Kenyatta National Hospital Ethical and Research Committee and written approval was obtained. Copies of the research proposal were then submitted to the two research centers before commencement of the study. Both centers gave a verbal approval.

Patients' names were not used in this study in order to maintain confidentiality. Only the examination ordered by the primary doctor was performed. This was explained to the patient when consent was obtained. No additional investigation was requested by the author; therefore, the patient incurred no extra danger or expense. Patient contact with the author was limited to the time of the scan. Data collection took place in the radiology unit and patients were not bothered further after leaving the unit.

The results of this study will be delivered to the Kenyatta National Hospital Ethical and Research Committee to assist them form a database for future study and reference and to facilitate any possible improvements in patient management.

RESULTS

The CT-scans of 112 patients with a clinical diagnosis of stroke seen at two centers between July and December 2005 were studied. Stroke was radiologically confirmed in 94 (84%) patients. Nine examinations showed no abnormality on CT. In another nine, disorders other than stroke (DOS) were found. Of the 94 patients with radiologically confirmed stroke 64 (68.1%) had infarctions, 29 (30.9%) had parenchyma haemorrhages and one (1.1%) had subarachnoid haemorrhage.

Demographic Characteristics

The mean age for stroke was 61.6 years (95% CI 57.7 – 63.6). The 51 - 60 years and 61 – 70 years age brackets had the highest rates of stroke with 28 (30.1%) patients each. No significant difference ($\chi^2 = 0.009$; 1df; $P > 0.05$ [0.93]) was observed in the type of stroke suffered and the age group of the patient. The average age of patients with haemorrhagic stroke was 57.6 years (95%CI 53.2 – 62.1) while that of those with infarctive stroke was 62.0 years (95%CI 58.2 – 65.9).

Nineteen (20.4%) patients were below age 50 years and 44 (47.3%) were above age 65 years.

There were 53 (47.3%) males and 59 (52.7%) females. The age range was from 25 to 100 years for males and 16 to 90 years for females. The mean age for stroke was the same in both sexes at 61 years. No significant difference ($\chi^2 = 0.733$; 1df; $P > 0.05$ [0.93]) was observed in the type of stroke suffered and the sex of the patient.

All the 112 patients included in this study were Blacks. In the course of the study six non-blacks were encountered including four Asians and two Caucasians. Since this was a study in Blacks these six were excluded from the study.

Clinical Presentation

This was analysed from information given in the radiology request form and was not independently assessed. Of the patients with confirmed stroke hemiparesis was the commonest clinical sign, being recorded in 31 (33.3%) cases. Hemiplegia and alterations in consciousness were each recorded in 12 (12.9%) patients. Speech defects were the presenting sign in four patients. The request forms of 34 (36.6%) patients did not indicate any clinical sign but merely stated a diagnosis of stroke.

Known Medical Conditions

Like the clinical presentation, this was recorded from the radiology request forms. Hypertension was the commonest known medical condition in the stroke patients. It was recorded in 41 (44.1%) patients. Diabetes mellitus was recorded in 15 (16.1%) patients. The two conditions above occurred together in 10 (8.9%) patients. An increased likelihood of infarctive type of stroke was positively correlated (Fisher's Exact test = 5.01; 1df; $P < 0.05$ [0.032]) with diabetes, though weakly so. Of the 15 patients with diabetes 93.3% (14) had infarctions whereas only 64.1% (50) of those without known diabetes had infarctions. There was no significant statistical association ($\chi^2 = 3.825$; 2df; $P > 0.05$ [0.148]) between the presence of hypertension and the type of stroke suffered.

One young patient aged 16 years had rheumatic heart disease and suffered an infarctive stroke. Two patients had a previous stroke in the remote past. HIV infection was only recorded in one patient whose CT scan showed signs of cerebritis and no stroke lesion. No cases with known coagulopathies or sickle cell disease were encountered.

Duration between time of stroke occurrence and CT scanning

It was noted that in one third of cases (38) the radiology request form was not dated and gave no indication when the stroke occurred. However, it was possible to establish an estimated duration in 100 of the 112 patients from the persons accompanying the patient. Thirty-seven (37%) patients were scanned within 24 hours of the ictus. However, no patient was ascertained to have been scanned within the first six hours. This is also in keeping with the fact that no scan had the subtle features of early infarction. One 80 year old female who presented with hemiparesis and was thought to have been scanned within the first six hours had a normal scan. Unfortunately, follow-up imaging was not performed on her to exclude infarction.

The total number of patients scanned within 48 and 72 hours of ictus was 57 (57%) and 70 (70%) respectively. Of the remaining patients, 14 were scanned by the seventh day and 11 in the second week. The study excluded patients presenting for scanning after 14 days.

Haemorrhagic Stroke

As noted above, 29 (30.9%) patients had parenchymal haemorrhage. The middle cerebral artery (MCA) territory was by far the most commonly affected accounting for 79.3% (23) of all bleeds. The PCA territory was the primary site of haemorrhage in three patients and the ACA in two. One 46 year old hypertensive male patient had multiple arterial territories involved. He had a bleed in right MCA/ACA watershed area and another in the left MCA territory of the temporal lobe.

The basal ganglia were the most commonly affected parenchymal site with 37.9% (11) of all the haemorrhages. The parietal lobe was next with 27.6% (8) followed by the thalamus with 10.3%. The pons and the frontal lobe were affected in 6.9% each. Only two patients had the temporal and occipital lobes as the primary site of haemorrhage. No cerebellar bleed was encountered. Right sided bleeds occurred in 16 (55.2%) patients and left sided ones in 12 (41.4%). One patient had bilateral bleeds as noted above. Of the lesions in the cerebral lobes, nine (60%) occurred at the gray/white matter junction while the remaining six (40%) were restricted to the subcortical white matter.

All the bleeds encountered were hyperdense to gray matter. The range of CT density measurements was from 60 to 82HU with an average of 75.3HU. Intraventricular haemorrhage occurred in nine (31%) patients most of whom had basal ganglia bleeds. Of the 13 patients with both hypertension and ICeH, four (30.8%) had clot dissection into the ventricular system. One of these involved the fourth ventricle. Mass effect and oedema around the bleed were very common, each occurring in 89.0% of bleeds.

The bleeds ranged in size from 12 to 82mm in their maximum diameter with an average of 45.3mm (95% CI 38.2 – 52.4). The mean of the second diameters, measured perpendicular to the first, was 26.6mm. This was less than two-thirds that of the average of the first diameters showing that most bleeds were elongated or oval rather than rounded. Bleeds were classified into three categories – small, medium and large - based on size and their distribution across four age brackets is tabulated below. Small bleeds were those less than 20mm in largest diameter. Slightly over half the bleeds were medium sized measuring between 21 and 50mm. Over a third (11) of all bleeds were large, measuring over 50mm in largest diameter. It was noted that nine of these involved the basal ganglia and parietal lobe while the temporal and occipital lobes had one each. An analysis of the size of

bleed against age of the patient showed poor correlation ($r < 0.5$). Bleeds did not get predictably bigger as patient age increased.

Table showing Sizes of Bleeds across Age Brackets

		Age				Total
		< 50 yrs	51 – 60 yrs	61 – 70 yrs	> 71 yrs	
Size of Bleed	0-20mm	0	1	2	0	3 (10.3%)
	21-50mm	3	6	4	2	15 (51.7%)
	>50mm	5	4	1	1	11 (37.9%)
Total		8	11	7	3	29 (100%)

Infarctive Stroke

The rate of infarctive stroke in this study was 68.1% (64). Over half, or 54.7% (35) of all infarctions involved the parietal lobe. The basal ganglia region was the next commonest site with 17 (26.6%) patients. Frontal, occipital and temporal lobe infarctions occurred in five, three and two patients respectively. One patient had a pontine, and another, a cerebellar infarct. One of the patients with an occipital infarct also had a thalamic as well as a cerebellar lesion. A patient with a very extensive parietal region infarct also showed a contralateral frontal lobe infarct. This was thought to be due to mass effect with pressure on the ACA. Curiously, 62.5% (40) of infarctions were left sided. Of the infarcts involving the cerebral lobes, 82.2% (37) involved both the cortex and the white matter while the rest were subcortical.

Lacunar infarcts or small infarcts in the deep perforating arteries were found in 20.3% (13) of patients. Only five patients had infarctions involving the vertebrobasilar circulation. The remaining 71.8% (46) of patients had infarctions involving the carotid circulation. Half of these (23) were extensive involving over a third of the middle cerebral artery territory, and therefore predictive of a poor outcome³¹. The other half consisted of more restricted infarcts.

Multiple infarcts were found in seven patients. Four of these were found to each have two lacunar infarcts in the basal ganglia. In one of them the lacunae were bilateral. The other three patients each

had two larger lobar infarcts and in two of them the infarcts were bilateral. No special characteristics were noted in these patients. Four were hypertensive and one diabetic.

The mean of the maximum diameters of all the infarcts was 51.1mm (95% CI 42.3 – 60.0). The smallest measured 6mm and the largest 132mm. The infarcts were further grouped into three sizes as outlined for haemorrhages above and their distribution across the age groups is tabulated below. Just like for haemorrhages no statistical correlation ($r < 0.5$) was found between size of lesion and patient age. Overall, infarcts were significantly larger than bleeds as evident from the mean diameters. More infarcts fell into the “over 50mm” (42.2%) category than in either of the smaller two categories.

Table showing Sizes of Infarcts across Age Brackets

		Age				Total
		< 50 yrs	51 – 60 yrs	61 – 70 yrs	> 71yrs	
Size of Infarct	0-20mm	0	6	4	5	15 (23.4%)
	21-50mm	3	4	9	6	22 (34.4%)
	>50mm	8	7	8	4	27 (42.2%)
Total		11	17	21	15	64 (100%)

The CT density measurements were taken for all infarcts. They ranged from 10 – 29HU with a mean of 18HU (95% CI 17.2 – 19.3). In general, older infarcts were observed to have lower densities than more recent ones but this was not statistically analysed. Nearly half or 46.9% (30) of all infarcts caused mass effect on the brain. Five (7.8%) were haemorrhagic. Only 10 (15.6%) of the patients with infarctions were given intravenous contrast media. Enhancement was demonstrated in seven.

One 60 year old comatose male patient scanned four days after ictus was found to have a mixed type of stroke. He had a right basal ganglia bleed measuring 12mm in size which had dissected into the lateral ventricle. His second lesion was a right parietal infarct measuring 25mm in size. No known medical conditions were elicited from his history.

Disorders Other Than Stroke (DOS)

These were detected in 8.0% (nine) of the patients scanned. The commonest disorder encountered was subdural haematoma. This was seen in six patients. Two others had CT appearances consistent with high grade gliomas. Cerebritis was diagnosed in one patient.

Illustrations

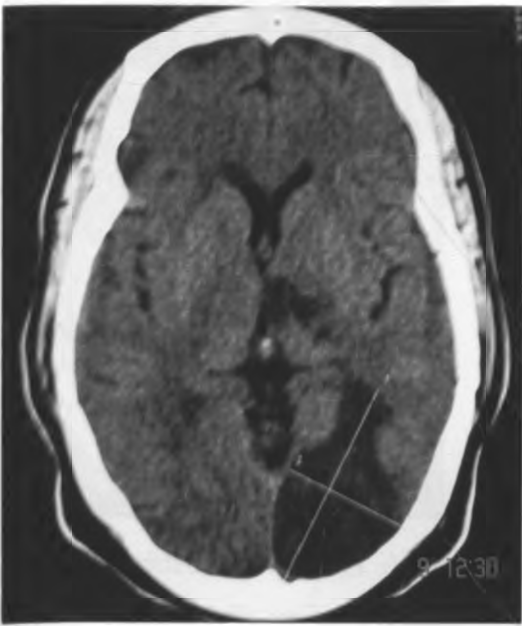


Fig 1a: NECT of a 40 year old female patient who presented with right sided hemiparesis and loss of vision in the right eye. The scan was done about 36 hours after ictus. It shows well-margined hypodense lesions in the left occipital lobe and the left thalamus consistent with infarctions in the left PCA territory. The occipital infarct measured 57 by 38mm.

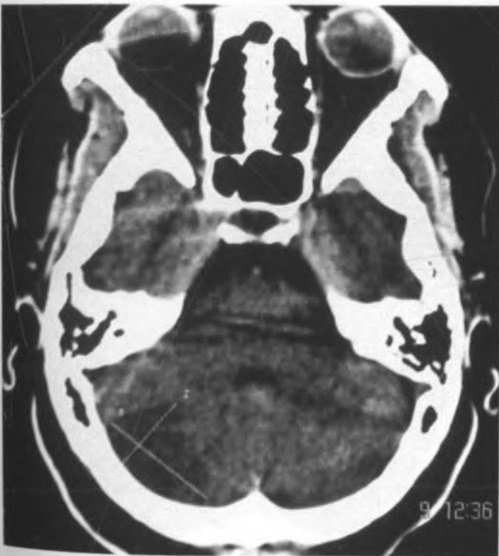

Fig 1b: Same patient as in Fig 1a above. The patient had a second lesion in the right cerebella hemisphere consistent with an infarct in the PICA territory. It measured 29 by 24 mm. Due to the multiplicity of lesions echocardiography was advised to exclude a cardiac source of emboli.

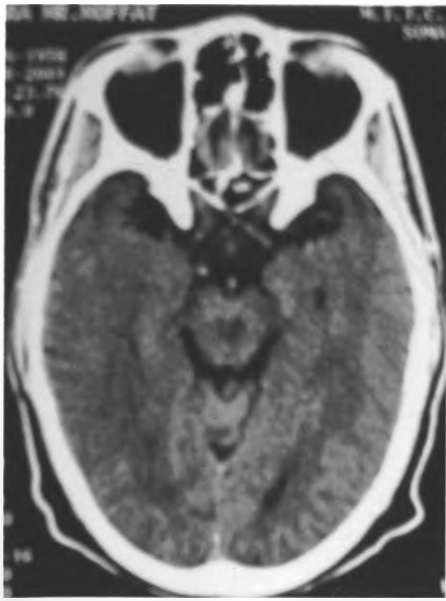


Fig 2: CECT of a 58 year old male patient who presented with right sided hemiparesis. A non-enhancing hypodense lesion is seen in the midbrain consistent with an infarct. It is centrally located but the left side is more affected.

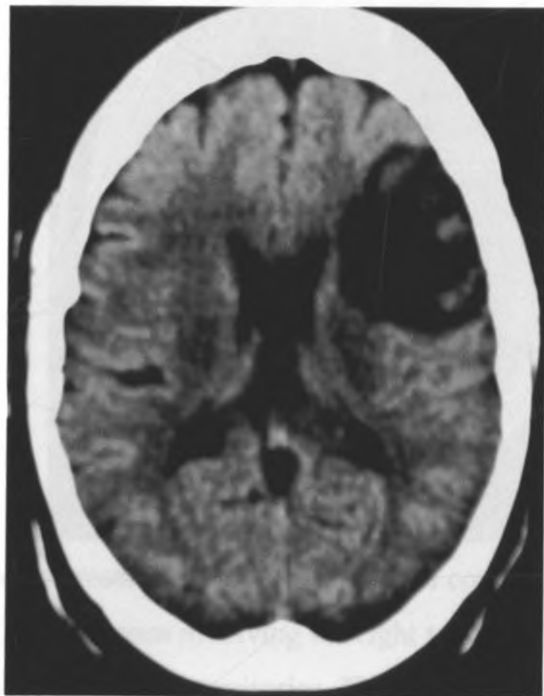
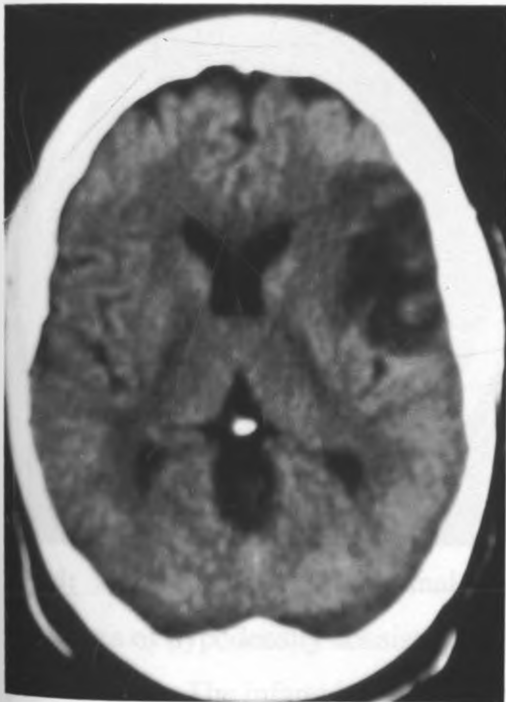


Fig 3: NECT in a 69 year old male patient with right sided weakness. A wedge shaped hypodense area involving both gray and white matter is seen typical of an infarct in the MCA territory of the frontal lobe.

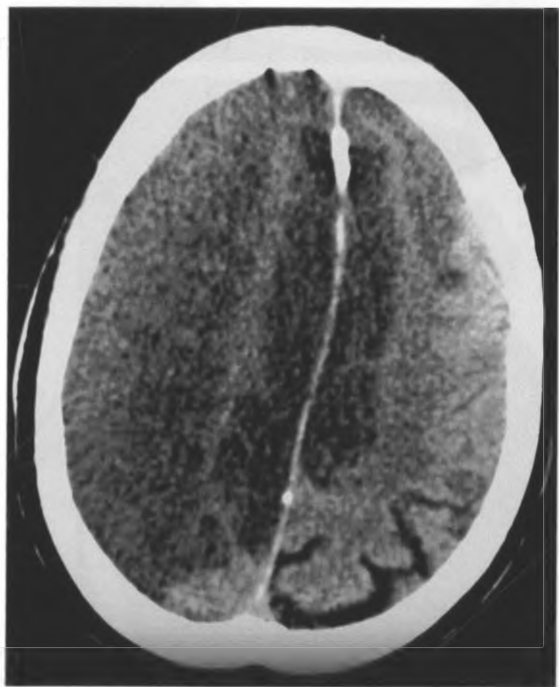
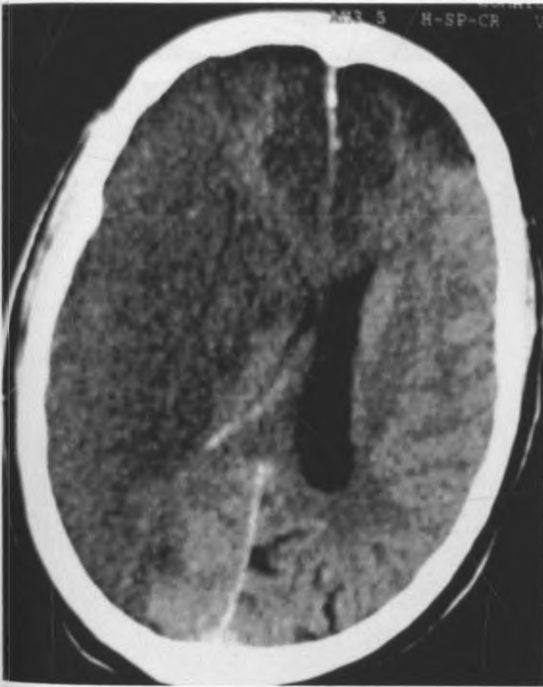
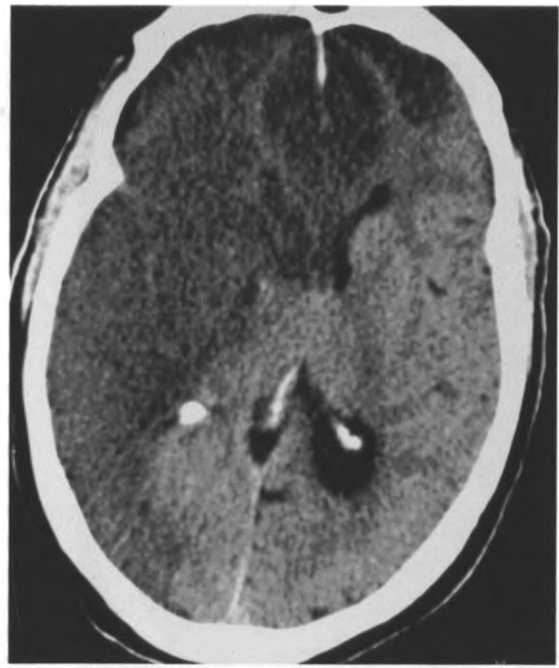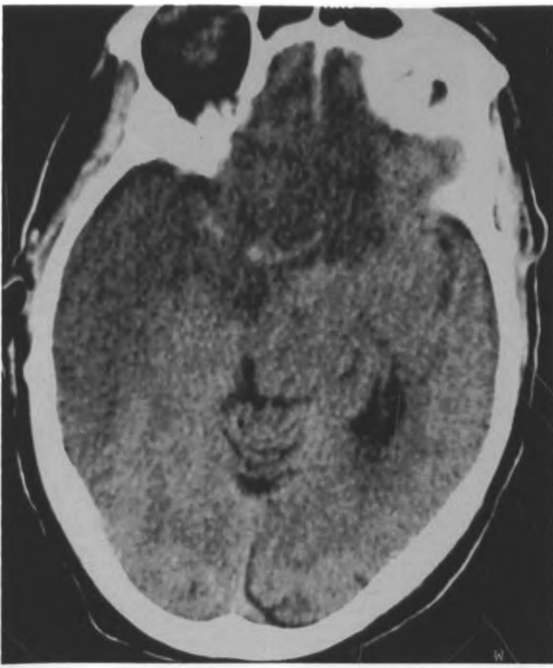Fig 4: NECT in a 100 year old male patient who presented with sudden loss of consciousness. A large area of hypodensity consistent with an infarct is seen involving the right temporal, frontal and parietal lobes. The infarct involves both the MCA and ACA territories. There is marked mass effect evidenced by a shift of the midline to the left and effacement of the right lateral ventricle. The ACA territory on the left side is also infarcted possibly as a secondary effect following pressure on this artery from the subfalcine herniation.

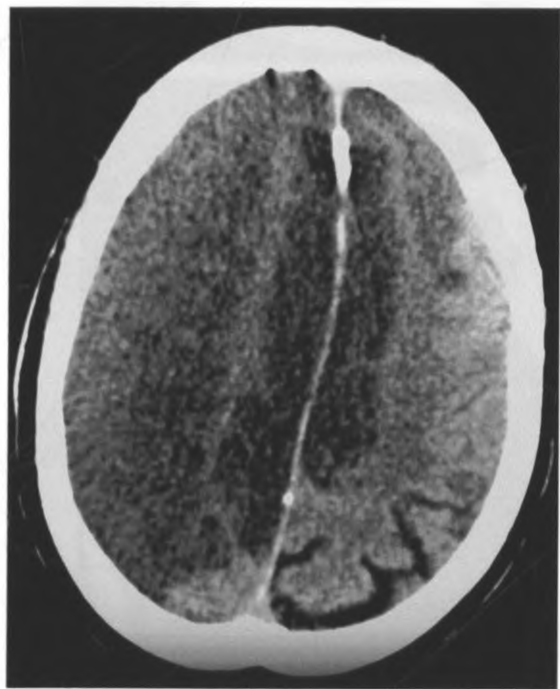
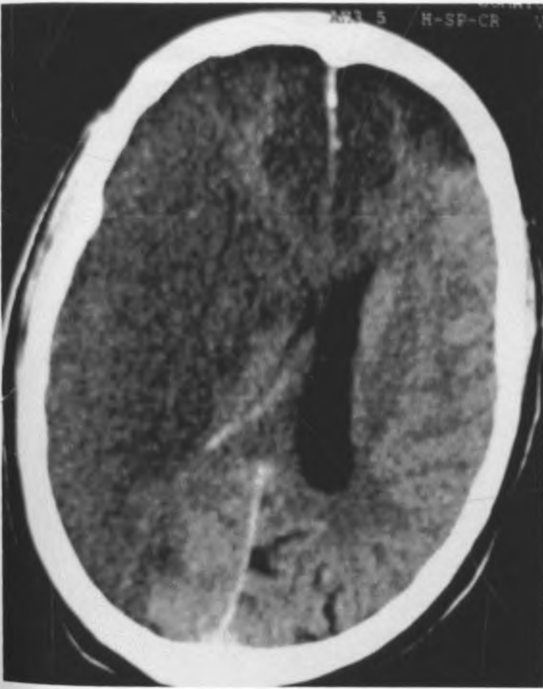
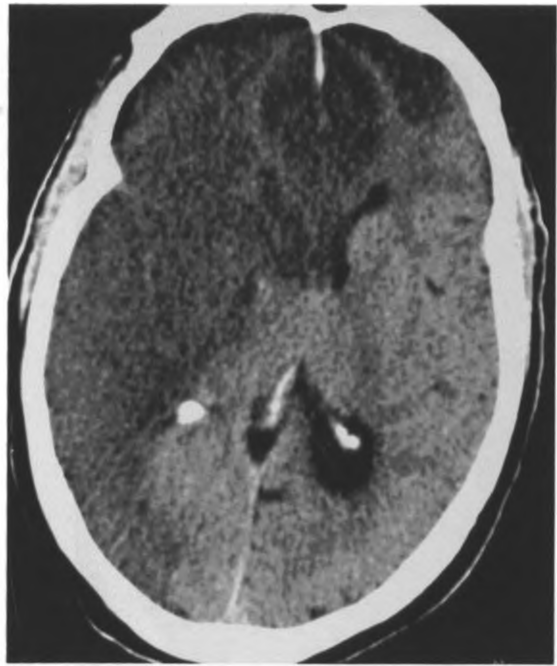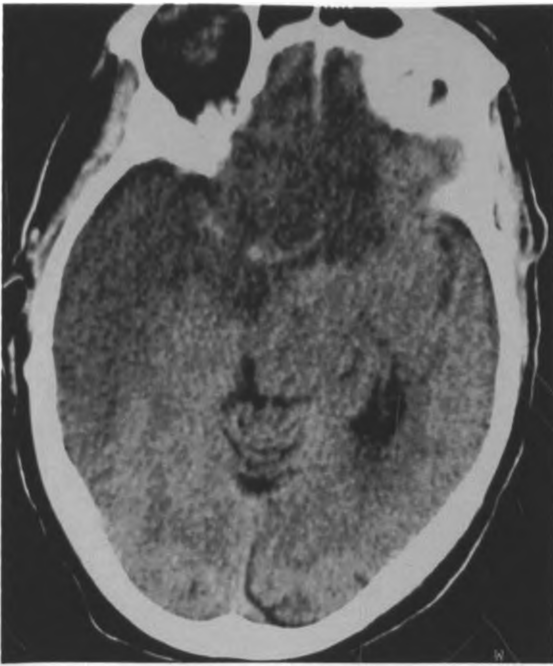Fig 4: NECT in a 100 year old male patient who presented with sudden loss of consciousness. A large area of hypodensity consistent with an infarct is seen involving the right temporal, frontal and parietal lobes. The infarct involves both the MCA and ACA territories. There is marked mass effect evidenced by a shift of the midline to the left and effacement of the right lateral ventricle. The ACA territory on the left side is also infarcted possibly as a secondary effect following pressure on this artery from the subfalcine herniation.

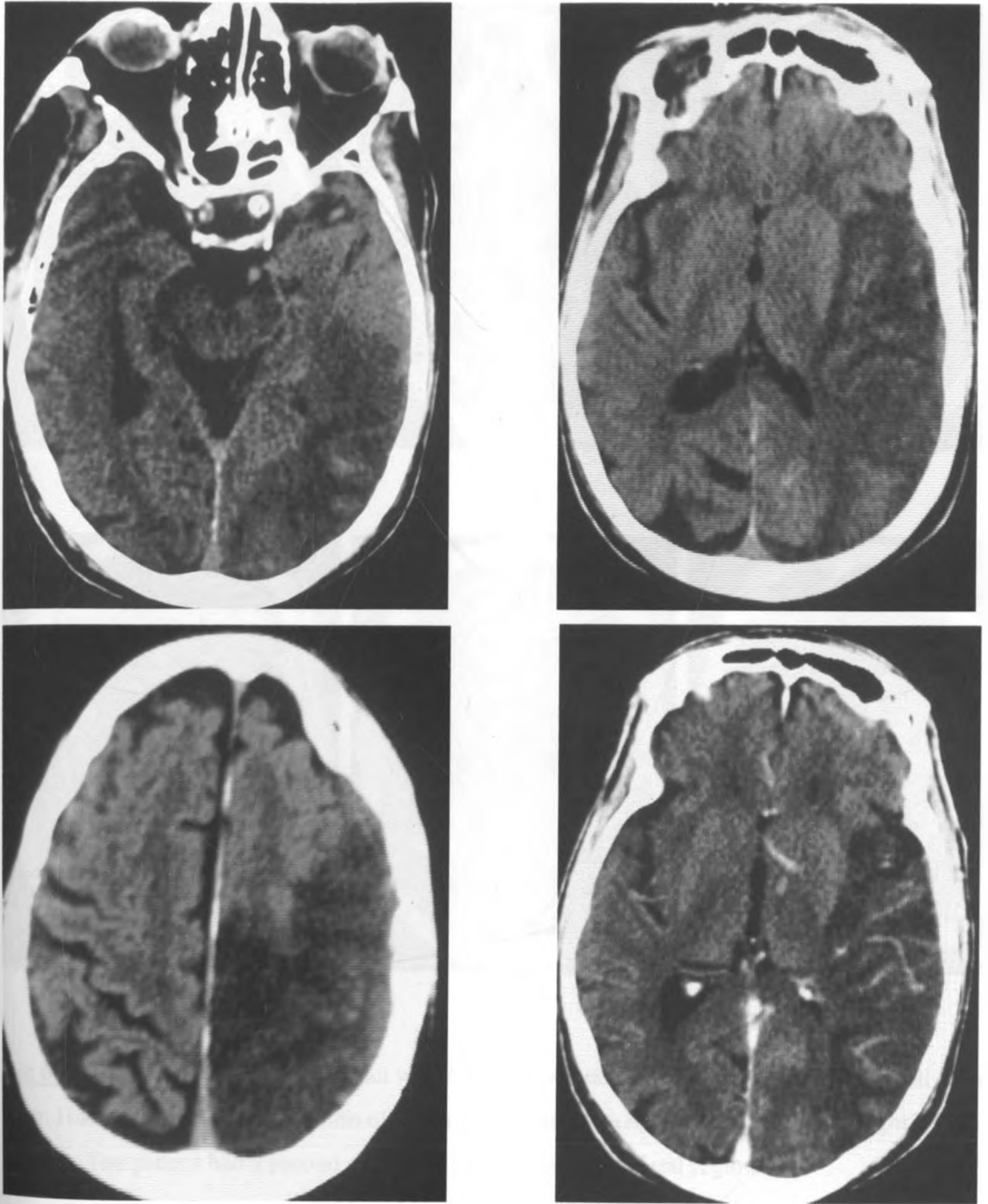


Fig 5: NECT and CECT in a 90 year old male with partial loss of vision and right hemiparesis, both of sudden onset. A large infarct involving the left temporal, parietal and occipital lobes is seen. The last image demonstrates the typical gyral enhancement seen in subacute infarcts.

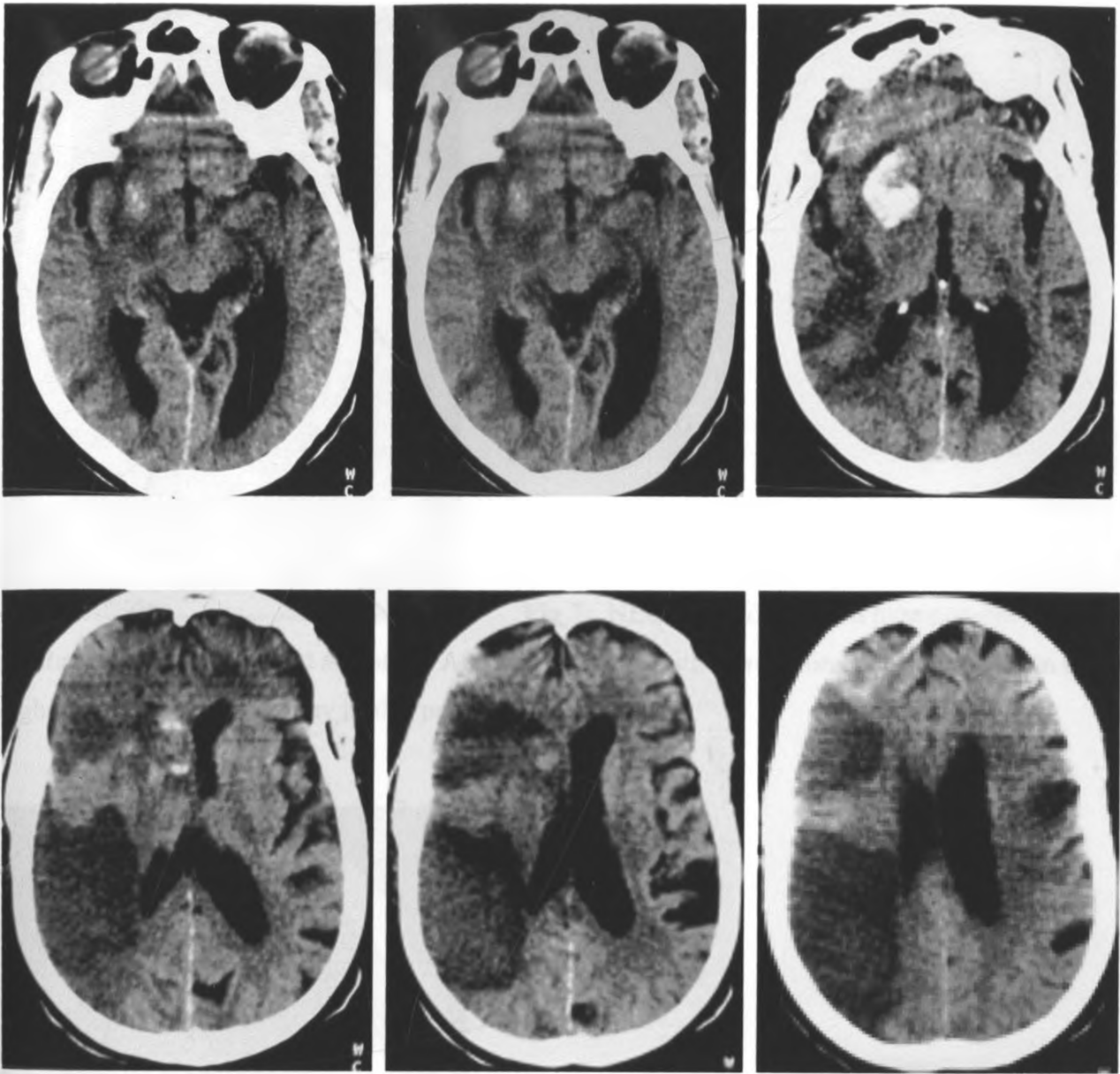


Fig 6: NECT in a 79 year old woman with left hemiparesis. A large right temporoparietal infarct is seen. Haemorrhagic transformation of the infarct is seen as a hyperdense clot in the right basal ganglia. The patient had a second smaller infarct in the left parietal region.

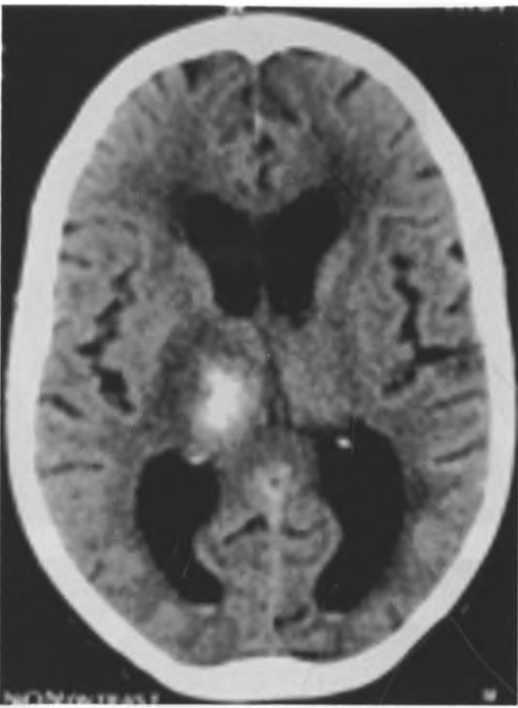


Fig 7: NECT in a 63 year old hypertensive male with left hemiparesis and altered sensation. A hyperdense clot with surrounding oedema is seen in the right thalamus. Brain atrophy is also present.

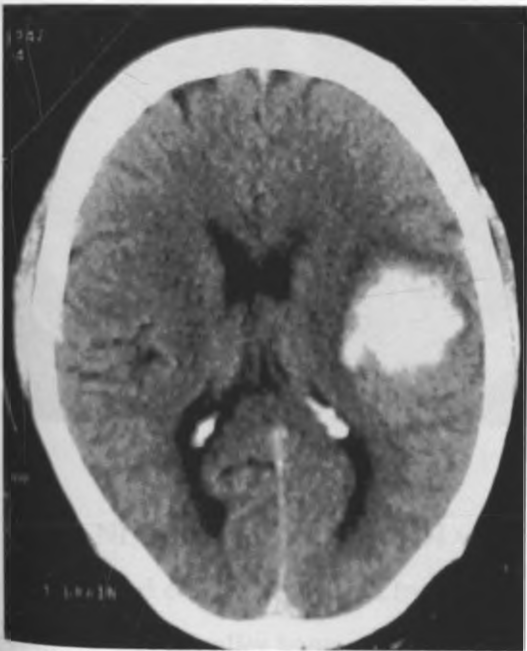

Fig 8: NECT showing a hyperdense acute haemorrhage in the left MCA territory. It is surrounded by an area of hypodensity consistent with oedema. Mass effect is minimal. This patient was scanned two days after ictus and had right sided hemiplegia.

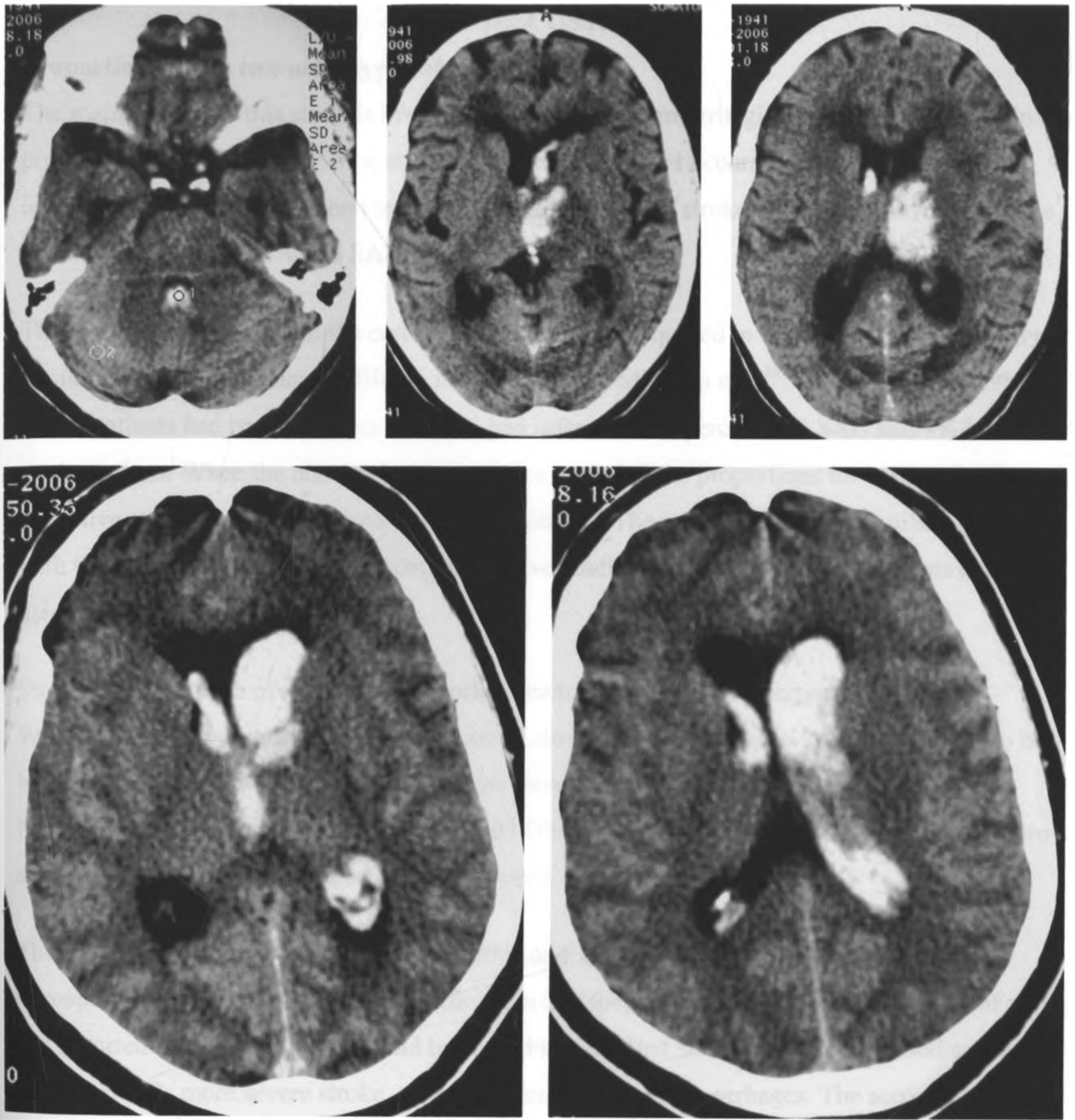

Fig 9: NECT in a hypertensive 64 year old female patient who presented with right hemiparesis and reduced consciousness. A hyperdense haematoma is seen in the right basal ganglia. The second scan shows a smaller haematoma in the left basal ganglia as well. Both haemorrhages have dissected into the ventricular system. Hyperdense blood is seen in both lateral ventricles and in the third and fourth ventricles.

DISCUSSION

Proportions of the two main types of stroke

The main finding of this study is that the proportions of haemorrhagic and infarctive stroke in the population studied were 30.9% and 68.1% respectively. SAH occurred in 1.1%. In the West, infarctive stroke has been found to account for about 80% of strokes while haemorrhagic stroke occurs in only about 15% and SAH in the remaining 5%¹.

The rate for bleeds found in the current study is twice that quoted in the West. This rate is very similar to that reported among Blacks in Zimbabwe by Matenga et al¹⁶. They found that 29% of stroke patients had haemorrhages and 62% had infarcts. Two percent had SAH and 7% had non-stroke lesions. When the non-stroke lesions were excluded the proportions for haemorrhagic and infarctive strokes were 31.2% and 66.7% respectively. The current study had significant similarities with the Zimbabwean one. Both were prospective studies involving about 100 patients examined using CT.

Studies in other parts of Africa have reported much higher rates for haemorrhagic stroke.

Wirendu et al.¹⁸ in a study of 1086 autopsies of stroke patients in Ghana found 54% (586) to be haemorrhagic and 37% (397) to be infarctive. Seven percent (76) had SAH.

Nyame et al.¹⁹ in a retrospective study of 1003 Ghanaian patients found that of the 907 with proven stroke on CT, 60% (547) had haemorrhages while 40% (360) had infarcts.

These two Ghanaian studies were done in 2001 and 1998 respectively. While both were retrospective studies they are quite significant in that they involved a fairly large number of patients and reported similar findings. It could be argued that the first study was autopsy based and so was biased towards more severe stroke - and therefore, towards haemorrhages. The second study, however, was a review of CT images and unlikely to have been similarly biased. The rate for haemorrhagic stroke in this second study was 60%. This is four times that quoted in Western studies and twice that found in my study as well as in the Zimbabwean one. This huge disparity remains unexplained.

Most of the African stroke studies found in the literature were based on clinical rather than radiological findings and do not help bridge this gap. These include studies from Nigeria, Tanzania

and Kenya. One CT based study by Nwosu et al¹⁷ of 240 stroke patients at the University of Nigeria Teaching Hospital found the rate of haemorrhagic stroke to be 17.9%. Their rates of infarctive stroke and SAH were 65.7% and 11.9% respectively. This study, however, was restricted to young stroke patients aged below 45 years and is therefore not suited for comparison with those discussed above.

In conclusion, my study has lent some credence to the often held belief that the rate of haemorrhagic stroke in black Africa is not as high as has been previously thought³. However it was a small study and larger studies in this region may be needed to resolve this question.

Demographic Characteristics

The mean age for stroke in this study was 61.6 years. The incidence of stroke peaked in the sixth and seventh decades of life. Patients under age 50 years constituted 20.4% of stroke cases. Those above age 64 constituted 47.3%.

In 1986, Kwasa²¹ conducted a clinical stroke study of 72 patients at the Kenyatta National hospital in Nairobi. He found a mean age for stroke of 52 years. Stroke incidence peaked in the sixth decade followed closely by the seventh. Patients aged above age 60 years constituted 38%. In Zimbabwe, Matenga et al¹⁶ found a mean age for stroke of 52 years. Patients below age 50 constituted 39%. Only 28% were above age 65 years. In Tanzania, Matuja et al⁶ found the mean age of stroke patients to be 51 years. Only 26% were aged above 64 years. In Ghana, Wirendu et al¹⁸ found that stroke incidence peaked in the 6th decade. Patients below age 60 years constituted 56%. Again in Ghana, Nyame et al¹⁹ reported a mean age in stroke patients of 54 years. In South Africa, Hoffmann¹⁵, in a 6 year study involving the University of Natal and the Durban Stroke Registry found that young patients (15 – 49 years) comprised 25.4% of stroke cases.

The mean age for stroke found in this study is about a decade higher than reported in the foregoing African studies. This study also found stroke to be as common in the 7th decade as in the sixth, whereas the other studies all placed the peak in the sixth decade. One of the reasons for this may be related to the fact that this study was conducted in private medical facilities rather than the national hospital. These facilities tend to be more expensive and this creates a bias towards the more well-off and urbanized portion of the population. It is probable that urbanization may skew stroke

demographics towards a Western pattern. Urbanised populations have better access to health care and risk factors for stroke particularly hypertension may be better controlled in this subgroup. This notion is further supported by the fact that the proportion of young stroke patients in my study is similar to that reported by Hoffman¹⁵ in South Africa. The South African population is on the whole more urbanized than that in much of the rest of Africa.

The findings of this study are in agreement with the other African studies when compared with Western statistics. The African studies cited above show that stroke affects younger people in Africa than it does in the West. Of all patients in the WHO multi-centre stroke registry 54% were aged above 64 years¹³. In the UK and USA, majority of deaths from CVA occur after the age of 74 years¹². In these two countries 85% of the population is below age 65 years, so the population structure alone would not account for the disparity in the peak age for stroke with African countries.

In conclusion, this study, while supporting the idea that the African stroke population is younger than the Western one also suggests that the peak age for stroke may be shifting towards a higher age group. My postulation is that this may be due to better control of such risk factors as hypertension in our population. It is acknowledged, however, that this may only be true for patients able to afford imaging at the private centers where the study was conducted.

Parenchymal Haemorrhage

By far the arterial territory most often affected by haemorrhagic stroke was the MCA territory with 79.3% of bleeds. The basal ganglia were the single most common site of bleeds. Haemorrhages sited away from the deep nuclei most commonly occurred at the gray white matter junction. Intraventricular extension of haemorrhages was common occurring in 31.0% of cases. While majority of bleeds were medium sized over a third were large, measuring over 50 mm in diameter, and so likely to be associated with a poor prognosis⁵. Lesions were not observed to become predictably larger as patient age increased.

The various African studies mentioned earlier did not dwell on the topographical details of stroke lesions after they were classified into haemorrhagic or infarctive types. One exception is the Ghanaian autopsy-based study by Wirendu¹⁸. He found 71% of haemorrhages to be intracerebral, 6% pontine, 5% cerebellar and 6% to involve multiple sites. SAH constituted 12% of intracranial

haemorrhage. Many studies done in the West have gone into similar detail. A few pertinent findings from the literature are stated for comparison with my findings.

It is a well established fact that over 75% of all strokes involve the MCA territory². It has also been shown that nearly two-thirds of spontaneous intracerebral haemorrhages occur in the basal ganglia². Certain findings are said to be poor prognostic markers. Haemorrhages over 5cm in largest diameter are known to have a very poor prognosis⁵. Franke⁴⁷ found that clot dissection into the ventricular system occurs in half the cases of hypertensive ICeH and is associated with a poor prognosis especially when the 4th ventricle is involved.

It has been stated that amyloid angiopathy is a common cause of ICeH in the elderly normotensive patient and accounts for 15-25% of ICeH². The haemorrhages are characteristically multiple, spare the basal ganglia and brainstem and are usually located at the corticomedullary junction.

The findings of this study with regard to the anatomical distribution of haemorrhages are very similar to those found in Ghana and in Western literature. The MCA territory and particularly the basal ganglia had the highest haemorrhage rates in all the studies I came across. Some important differences found in this study, however, are worthy of mention. One concerns bleeds attributed to amyloid angiopathy. Haemorrhages are put in this category if they are multiple and occur at the corticomedullary junction in an elderly normotensive patient. Using these criteria no patient in my study can be classified as such. The one patient who had multiple bleeds was aged only 46 years and one of his bleeds was entirely subcortical. While nine patients were found to have bleeds centered at the corticomedullary junction, only three of these were normotensive. Two of these were aged 60 years and the third 65 years. This finding is in contrast to Osborne's² where 15 – 25% of ICeH was attributed to amyloid angiopathy.

The second difference is a less significant one. This study found clot dissection into the ventricular system to occur in 30.0% of all patients and 30.8% of hypertensive patients. Franke⁴⁷ found a rate of 50.0% in hypertensive ICeH. This difference is probably not large as the numbers involved are small. However, if the finding were to be borne out by larger studies it would be quite significant. This is because of the bad prognostic impact intraventricular extension has on cerebral bleeds.

ICeH is said to be fatal in about 75% of patients⁵ and the CT topography of the lesion enables the clinician to give a more accurate prognosis to the family. From this standpoint at least two-thirds of the patients studied would have been put in a poor prognostic category. Half of these had bleeds measuring in excess of 50mm in size while the other half had associated intraventricular haemorrhage. An overlap of the two prognostic markers occurred in three patients. Another poor prognostic marker was noted in four other patients. These demonstrated midline shift on their scans despite having haemorrhages below 50mm in size. One patient was found to have a 20mm pontine bleed. Large pontine bleeds are often fatal⁵.

In conclusion, the CT topography of haemorrhagic stroke as found in this study does not differ significantly with that found in other parts of the world except perhaps in the rarity of bleeds that may be attributed to amyloid angiopathy. Larger studies are needed to confirm or refute this finding. Secondly, the common prognostic markers found in stroke literature are readily picked on CT scan exams in this set up. It is advisable for radiologists to routinely state the presence or otherwise of these prognostic markers so that clinicians can factor them in when briefing the families of stroke patients.

Infarctive Stroke

In this study the rate of infarctive stroke was 68.1%. The basal ganglia and the parietal lobe were by far the commonest sites affected. Together they accounted for about 80% of all infarctions. This finding is consistent with the well established fact that over 75% of all strokes occur in the MCA territory². When the entire MCA is involved as was often the case the basal ganglia, the deep cerebral white matter and much of the hemispheric cortex are affected. Extensive MCA infarcts were often found to have the typical wedge shape extending from the lateral ventricle to the brain surface.

A method of classifying infarcts that was first suggested by Bamford in 1991 was used for ease of description. Bamford et al³¹ described the incidence and natural history of cerebral infarction in 543 British patients based on four topographical subgroups and a four year follow-up. Their key findings are summarized below:

- 1) Total anterior circulation infarcts (TACI) – constituted 17% of infarcts. These were patients with both cortical and subcortical involvement of the MCA/ACA territories. They had a negligible chance of a good functional outcome and mortality was high.

- 2) Partial anterior circulation infarcts (PACI) – constituted 34% of infarcts. These had more restricted and predominantly cortical infarcts. No direct neurological deaths occurred. Stroke recurrence was high at 17% within a year and occurred early.
- 3) Posterior circulation infarcts (POCI) – constituted 24% infarcts. Vertebrobasilar territory infarcts had the best chance of a good functional outcome though a few died early, presumably due to brainstem dysfunction. Recurrence rate was high at 20% within a year, but occurred later in that period.
- 4) Lacunar infarcts (LACI) – constituted 25% of infarcts. These were small infarcts in the territory of the deep perforating arteries. A large proportion of these patients remained substantially handicapped but no direct neurological deaths occurred. The recurrence rate was low at 9% within a year.

This classification was adopted due to its simplicity and prognostic significance even though clinical outcomes were not a part of the current study. The incidence rates found in my study were 35.9% each for total and partial anterior circulation infarcts, 7.8% for posterior circulation infarcts and 20.3% for lacunar infarcts. The incidence rates for categories two and four compare very well with those reported by Bamford. A marked difference however is observed in the other two categories. Total anterior circulation infarcts were twice as common in the current study while vertebrobasilar infarcts were remarkably low.

There is no obvious explanation for this difference. Early mortality would not account for the low number of POCI recorded as the same effect would then be reflected in the TACI group. It is also not plausible that the POCI were small and did not present for scanning since lacunar infarcts are even smaller and were recorded in large numbers. One other possibility is that during data collection some POCI were erroneously recorded as LACI or PACI. This however is very unlikely as the only regions where such confusion may arise are the thalamus and the posterior limb of the internal capsule. The number of infarcts restricted to these regions would not account for the difference and certainly would not explain the paucity of posterior fossa lesions.

In the absence of other plausible explanations, one may suggest from the foregoing that in the Nairobi study population TACI are commoner and POCI rarer than in Bamford's British study group. This is indeed a possibility as one review article³ does list four authors who found the

severity of stroke to be greater in blacks than in other races. A relatively higher incidence of TACI over POCI would be in keeping with this as TACI strokes are generally far more serious. It is acknowledged in all this however, that Bamford's was a much larger study involving 543 patients and therefore of greater statistical power.

The relatively large number of lacunar infarcts picked in this study is of special interest. These lesions are typically located in the basal ganglia and thalamus. They are often multiple and are due to embolic, atheromatous or thrombotic lesions in the long single penetrating arterioles that supply the deep cerebral grey matter. They were found to make up 20.3% of infarcts. This finding concurs not only with Bamford³¹ but also with Regli⁴⁵ who in a review of lacunar infarcts as seen on MRI found them to account for 15% – 25% of all strokes. This is in sharp contrast to the findings of a study of 1003 patients by CT in Ghana in 1998. In that study Nyame et al.¹⁹ found no lacunar infarcts and concluded that the resolution of their CT was not adequate to pick them. The improved resolution of the scanners used in Nairobi may indeed account for this difference.

That many lacunar infarcts were picked is also significant for a second reason. It is often argued that the reason Africa reports a larger proportion of haemorrhages than the West is that we tend to scan only the more severely affected stroke patients. While lacunar infarcts can cause major neurological deficits more often than not, clinical symptoms are not marked. The rate of haemorrhagic stroke in this study was twice that reported in the West; yet the rate for lacunar infarcts was similar to that quoted for Western populations.

Frank haemorrhagic infarctions were encountered in 7.8% of infarcts. Matthew⁵⁶ has stated that on CT these are usually seen in 5 – 15% of all stroke cases. In large infarcts a rate of about 25% is quoted⁵⁶. Autopsy studies show a much higher occurrence rate. Most are identified 24 – 48 hours after the ischaemic event³² as high density foci within previously ischaemic areas. They are virtually always associated with mass effect². This later finding was observed in the cases encountered in this study.

One key aim in the management of infarctive stroke is the prompt identification of lesions that may be amenable to thrombolytic therapy. The guidelines applied are derived from the NINDS²⁴ and ECASS²⁵ studies. These studies showed that thrombolytic therapy with rt-PA offered substantial

benefits to selected patients with ischaemic stroke if administered within 3 to 6 hours. In the NINDS study, the CT criterion predictive of therapeutic benefit was the presence of a parenchymal hypoattenuation of 33% or less of the MCA territory²⁴. Patients with no hypoattenuation on early CT showed no benefit from thrombolysis. Those with lesions larger than 33% of MCA territory were at increased risk of haemorrhagic complications. Sadly, in this study no patient met these criteria. This was because of long delays between the occurrence of stroke and the time a CT scan is performed.

In conclusion, this study shows that infarctive stroke, just like in the West, is the commonest type of stroke in the population studied. The findings also suggest that large anterior circulation infarcts are more common in this population than in the West. While only a small proportion of patients in the West qualify for thrombolytic therapy, in this region it is almost non-existent. This is primarily a public health problem that needs to be addressed through increased awareness by both medical personnel and the public. There is also an urgent need to improve emergency services so that stroke patients can reach hospitals faster. For the whole exercise to succeed however, CT scanners, thrombolytic agents and personnel trained in their use must all be widely available in the country. The problem is therefore a socioeconomic and political one. It is important however, to begin to improve on current practice and the well equipped private hospitals in Nairobi should probably lead the way.

Subarachnoid Haemorrhage (SAH)

Only one patient (1.1%) had SAH. The diagnosis of SAH in this case had already been made clinically. This particular case showed one of the most important complications of SAH, namely an infarct in the territory of one ACA thought to be due to associated spasm of this artery. This interesting image unfortunately was not recorded as a digital camera was not available at the time. Isolated ACA infarcts are otherwise very rare occurring in only 0.6% of all infarcts³⁶. This is because embolism into this artery is rare and collateral flow is very good. The infarct seen in this case was typical involving a strip of cortex along the anterior aspect of the inter-hemispheric fissure.

That only one case of SAH was recorded is not surprising. In Zimbabwe, Matenga¹⁶ found SAH in only two of 113 patients with clinical stroke. In the West SAH is said to account for 5% of all strokes¹¹. Wirendu et al¹⁸ in a study of 1086 autopsies of stroke patients in Ghana found 7% to have

SAH. One study in Nigeria by Nwosu et al¹⁷ recorded a significantly higher rate for SAH of 11.9% but this was among a select group of young stroke patients aged 16 – 45 years.

During the course of the study there was no requisition form seen with a clinical diagnosis of SAH in which the CT scan turned out to be normal. It is therefore not likely that some SAH cases were missed because the scan was performed late when the increased density in the basal cisterns would have cleared. This study suggests that the rate of SAH in the study population is low. Perhaps the main underlying risk factor, cerebral aneurysms, is less common in this population than in the West.

The Normal Scans

There were nine (8%) normal scans recorded in this study. As noted earlier no patient was scanned within six hours of ictus. This is the period when the sensitivity of CT for infarcts is lowest. CT at this stage may indeed be normal in 50 – 60% of patients⁴⁰. Thirty-seven patients were scanned within the first 24 hours. It is possible that even within this time some infarcts may have been missed and the scans reported as normal.

In a study of 31 patients with infarcts scanned within 24 hours of ictus (mean 8 hours) the CT and MR detection rates were 58% and 82% respectively⁴⁰. On follow-up scans at 7-10 days both modalities detected 88% of subacute infarcts. In a similar study of 44 patients with infarcts imaged within 8 hours of ictus the sensitivity of NECT was 55% while that of perfusion CT was 76%⁴⁴.

Small infarcts in eight patients – mean size 1.47cm - were missed on both modalities.

Matenga et al.¹⁶, in Zimbabwe found that of 62 patients with infarcts 19% (12) did not have the lesions detected on CT. Nyame et al.¹⁹, in a retrospective study of 1003 Ghanaian patients clinically diagnosed to have stroke found that 5.6% (56) had an entirely normal CT.

Infarcts may be missed where ischaemia is above the critical level of structural integrity or where the resultant hypoattenuation is below the level of contrast resolution²⁹. Scans may also have been reported as normal because the subtle signs of early ischaemic change, though present, were overlooked. The CT scans of the patients entered into the ECASS study (n = 786) underwent a second review by experts which showed that initial “on-site” interpretation had overlooked an early infarct in 11% of patients²⁵.

The proportion of normal scans in this study compares well with the findings from Zimbabwe and Ghana. That only 8% of scans were normal however suggests a high detection rate of stroke by CT when compared with the Western studies mentioned above. This is most likely because many patients in this region are scanned after long delays when the changes of ischaemia are advanced. Unfortunately, follow up scans were not obtained in any of the nine patients with normal scans. It is possible – but unlikely considering the delays encountered before scanning – that some of them may have shown infarctive lesions not visible on the earlier scans. Where normal scans are encountered in the clinical setting of stroke post-contrast scans should be obtained to exclude space occupying lesions. If these too are normal and clinical suspicion of stroke is high the referring clinicians should be advised on the need for follow up scans.

Disorders Other Than Stroke (DOS)

These were detected in nine (8.0%) patients. Six had subdural haematomas. Two had high grade gliomas. One had cerebritis. Nyame et al¹⁹ in a retrospective CT-based study of 1003 Ghanaian patients clinically diagnosed to have stroke found that 4% (40) had disorders other than stroke (DOS). In this group were ten subdural haematomas (SDH), eight cerebral abscess, four meningiomas and eighteen other unspecified brain tumours. Matenga et al¹⁶ found that of 100 Zimbabwean patients with a clinical diagnosis of stroke DOS were found in seven: SDH in four, tumours in two and cysticercosis in one.

The diagnosis of stroke based on clinical findings alone has been found to be inaccurate in about 13% of patients admitted to stroke units²². This is because occasionally, lesions such as tumours, subdural haematomas (SDH) and cerebral abscesses present with sudden onset of focal neurological deficit thus mimicking stroke on a clinical level.

The rate of detection of DOS in this study compares well with the rates quoted in the three studies mentioned above. This suggests that the accuracy observed in the clinical diagnosis of stroke in the patients studied is as good as that in the other regions. The stroke mimics diagnosed are also very similar and show SDH to be the commonest stroke mimic.

In conclusion, a significant number of stroke mimics were discovered on CT scanning. This is particularly important because unlike stroke which is usually managed conservatively, the three

types of mimics encountered require specific interventions that may radically alter the outcome. SDH in particular can be rapidly fatal as it is often associated with marked mass effect. Urgent surgical evacuation of the haematoma may therefore be lifesaving. For this reason patients with a clinical diagnosis of stroke should all have emergency CT scans to exclude treatable stroke mimics.

CONCLUSIONS

The rate of haemorrhagic type of stroke in black adult stroke patients seen at the two study centers in Nairobi is 30.9%. This is about twice that stated by most authors for the largely Caucasian population in Europe and America. However, it is significantly less than that demonstrated by earlier studies in Africa which suggested a rate above 50%. The findings of this study concur with those of a similar prospective study done in Zimbabwe in 1986.

The mean age for stroke in this study was 61.6 years. The incidence of stroke peaked in the sixth and seventh decades of life. Patients below age 50 years constituted 20.4% while those above age 65 years constituted 47.3%. There were no significant differences found between males and females with regard to the number affected, their age distribution or the type of stroke lesion suffered.

Over three-quarters of all stroke lesions were located in the middle cerebral artery territory. The basal ganglia were the commonest sites of haemorrhagic lesions while the parietal lobes were the commonest sites of infarctive ones. Posterior fossa lesions were the rarest of all. The mean diameter for haemorrhages was 45.3mm while that for infarcts was 51.1mm. Overall, 40.1% of all lesions were large and measured over 50mm in diameter.

The frequency of stroke mimics was 8%. Subdural haematomas were the commonest entity found to be misdiagnosed as stroke. Considering that another 8% of patients had normal CT scans, it is likely that there were other stroke mimics not picked by this diagnostic test.

RECOMMENDATIONS

All patients in whom a clinical diagnosis of stroke is made should have an urgent brain CT-scan to exclude treatable stroke mimics, particularly subdural haematoma and cerebritis.

Where lateralizing signs are present in stroke patients, clinicians should indicate the side affected so that radiologists can more confidently pick subtle signs of early infarction.

Patients who are scanned early – particularly in the first 12 hours after ictus – and are found to have normal CT-scans should have follow up scans to exclude previously occult infarcts. This should only apply to those in whom clinical suspicion for stroke is high. To facilitate this, the request form should always indicate the time when stroke occurred.

Stroke patients who get to hospital within three to six hours of ictus need to be scanned urgently, specifically to determine if they meet the criteria for thrombolysis. This treatment should be availed for the few who do. Medical personnel need to be sensitized to regard hyperacute infarcts as “brain attacks” amenable to salvage therapy in the same way that “heart attacks” are.

Radiologists should routinely report the dimensions, specific locations and associated complications seen with stroke lesions to aid clinicians in prognostication and planning of management.

When the appearance of a brain infarct shows atypical features, for example, being restricted to white matter or associated with mass effect out of proportion to its size intravenous contrast should be given to help differentiate it from a tumour or infective lesion.

A larger study in older black patients involving imaging and clinical correlation is needed to determine if bleeds attributable to amyloid angiopathy are indeed rare in this region.

Given the very large variations in the rates of the two main stroke types emerging from studies in different parts of Africa it is suggested that experts from several African countries come together and design a harmonized study protocol on stroke so that outcomes from different regions can be comparable in real terms.

REFERENCES:

1. Warlow CP, et al. *Stroke: A practical guide to management*. Oxford: Blackwell Scientific; 1996.
2. Osborne Anne G. *Diagnostic Neuroradiology*. St. Louis: Mosby; 1994.
3. Imam I. Stroke, a review with an African perspective. *Annals of Tropical Medicine and Parasitology* 2002; **96**: 435-445.
4. Mullins Mark E, et al. CT and conventional and D-W MR in acute stroke: Study in 691 patients at presentation to the emergency department. *Radiology* 2002; **224**: 353-360.
5. Fauci A, et al. *Harrison's Principles of Internal Medicine*. 14th.Ed. New York: McGraw-Hill; 1998.
6. Matuja William BP. Strokes among African people in Dar es Salaam, Tanzania. *Medicom* 1987; **9**: 197-201.
7. Stewart JA, et al. Ethnic differences in incidence of stroke: prospective study with stroke register. *BMJ* 1999; **318**: 967-971.
8. Jones MR, et al. Racial variation in initial stroke severity. *Stroke* 2000; **31**: 563-567.
9. Hajat C. Cerebrovascular risk factors and stroke subtypes; differences between ethnic groups. *Stroke* 2001; **32**: 37-42.
10. Broderick JP, et al. The risk of subarachnoid and intracerebral haemorrhages in Blacks as compared with Whites. *NEJM* 1992; **326**: 733-736.
11. Mohr JP, et al. The Harvard co-operative stroke registry: a prospective registry. *Neurology* 1978; **28**: 754-762.
12. WHO. World health annual statistics. Geneva: WHO; 1995.
13. Hatano S. Experience from a multi-centre stroke register: a preliminary report. *Bull. WHO* 1976; **54**: 541-542.
14. Fritz V. Stroke therapy clinical guideline – S. African Medical Ass. *South African Medical Journal* 2000; **90**: 276-306.
15. Hoffmann Michael. Stroke in the young in South Africa – An analysis of 320 patients. *South African Medical Journal* 2000; **90**: 1226-1237.
16. Matenga J, Kitai I, Levy L. Stroke among black people in Harare, Zimbabwe: results of CT and associated risk factors. *BMJ* 1986; **292**: 1649-1651.

17. Nwosu CM, Nwabueze AC, Ikeh VO. Stroke at the prime of life: A study of Nigerian Africans between the ages of 16 and 45 years. *East African Medical Journal* 1992; **69**: 384-390.
18. Wirendu EK, Nyame PK. Stroke related mortality at Korlu Bu Teaching Hospital, Accra, Ghana. *East African Medical Journal* 2001; **78**: 180-184.
19. Nyame PK, Jumah KB, Adjei S. Computerised Tomographic Scan of the head in evaluation of stroke in Ghanaians. *East African Medical Journal* 1998; **75**: 637-639.
20. Behemuka M. CVA in 207 Kenyans; General peculiarities and prognosis of stroke in an urban medical centre. *EAMJ* 1985; **62**:315-321.
21. Kwasa Thomas. A study of clinical and lab features in stroke patients at KNH. MMed. Dissertation; 1987.
22. Shuaib A. The impact of MRI on management of acute ischaemic stroke. *Neurology* 1992; **42**: 816-818.
23. Grainger RG, Allison D. Eds. Diagnostic Radiology, A textbook of medical imaging. 4th edition. London, Churchill Livingstone; 2002.
24. NINDS rt-PA Stroke Study Group. Rt-PA for acute ischaemic stroke. *NEJM* 1995; **333**:1581-1587.
25. Hacke W, Kaste M. IV thrombolysis with rt-PA for acute hemispheric stroke: The European Co-operative Acute Stroke Study. *JAMA* 1995; **274**: 1017-1025.
26. Chodosh EH, et al. Silent strokes in the NINCDS stroke data bank. *Neurology* 1998; **38**: 1674-1675.
27. Russell J Eric. Diagnosis of hyperacute infarct with CT: key to improved clinical outcome after IV thrombolysis. *Radiology* 1997; **205**: 315- 318.
28. Dahnert Wolfgang. *Radiology Review Manual*, 5th Ed. Philadelphia: Lippincott Williams and Wilkins; 2003.
29. Rudiger von Kummer, Bourguain H, et al. Early prediction of irreversible brain damage after ischaemic stroke at CT. *Radiology* 2001; **219**: 95-100.
30. Pessin MS. Haemorrhagic infarction: guilty by association? *AJNR* 1991; **12**: 1123-1126.
31. Bamford J, Sandercock P, et al. Classification and natural history of clinically identifiable subtypes of cerebral infarction. *Lancet* 1991; **337**: 1521-1526.

32. Bozzao L. Early angiographic and CT findings in the distribution of the MCA. *AJNR* 1991; **12**: 1115-1121.
33. Van der Zwan A. Variability of the major cerebral arteries. *Journal of Neurosurgery* 1992; **77**: 927-940.
34. Gonzalez C, et al. *Head and Spine Imaging*. New York: Churchill Livingstone; 1985.
35. Hagga John R, Lanzieri Charles F. *Computed Tomography and Magnetic Resonance Imaging of the Whole Body*. 3rd Ed., St. Louis: Mosby Year Book; 1994.
36. Kazui S. Angiographic evaluation of brain infarction limited to the ACA territory. *Stroke* 1993; **24**: 549-553.
37. Wang Z, et al. Investigation of stroke in sickle cell disease by MR spectroscopy. *Neuroradiology* 1992; **35**: 57-65.
38. Mochan Andre, Modi Mala, Modi Girish. Stroke in Black South African HIV – Positive Patients; a prospective analysis. *Stroke* 2003; **34**: 10-15.
39. Beauchamp NJ, Bryan NR. Acute cerebral ischaemic infarction: a pathophysiologic review and radiological perspective. *AJR* 1998; **171**: 73-83.
40. Bryan RN. Diagnosis of acute cerebral infarction: comparison of CT and MR imaging. *AJNR* 1991; **12**: 611-620.
41. Leys D, Pruvo JP. Prevalence and significance of hyperdense MCA in acute stroke. *Stroke* 1992; **23**: 317-324.
42. Tomura N, et al. Early CT findings in cerebral infarction: obscuration of the lentiform nucleus. *Radiology* 1988; **168**: 463-467.
43. Truwit CL, et al. Loss of the insular ribbon: another early CT sign of acute MCA infarction. *Radiology* 1990; **176**: 801-806.
44. Kloska SP, et al. Acute stroke assessment with CT: do we need multimodal evaluation? *Radiology* 2004; **233**: 79-86.
45. Regli L. MRI in small deep cerebral infarcts. *Archives of Neurology* 1993; **50**: 175-180.
46. Bozzola FG. Epidemiology of Intracranial haemorrhage. *Neuroimaging Clin. N. America* 1992; **2**: 1-10.
47. Franke CL. Prognostic factors in patients with intracerebral haematoma. *Journal of Neurology, Neurosurgery & Psychiatry* 1992; **55**: 653-657.

48. Vuadens P, Bogousslavsky J. Diagnosis as a guide to stroke therapy. *Lancet* 1998; **352** (suppl. 3): 5-9.
49. Gaskill-Shipley M. Routine CT evaluation of acute stroke. *Neuroimaging Clin. North America* 1999; **9**: 411-464.
50. Byoko OB. CECT of acute isodense subdural haematomas. *AJNR* 1991; **12**: 341-343.
51. Cohen WA. CT of intracranial haemorrhage. *Neuroimaging Clin. N. America* 1992; **2**: 75-87.
52. Lee YY, et al. Organised intracerebral haematoma with acute haemorrhage: CT patterns and pathological correlations. *AJNR* 1986; **7**: 409-416.
53. Kreel L, et al. The radiological (CT) and clinical sequelae of primary intracerebral haemorrhage. *British Journ. Radiology* **64**: 1096-1100.
54. Zimmerman RD. Ring blush associated with intracerebral haemorrhage. *Radiology* 1997; **122**: 707-711.
55. Wakai S. Lobar intracerebral haemorrhage. *Journal of Neurosurgery* 1992; **76**: 231-238.
56. Matthews VP. ICH in occlusive vascular disease. *Neuroimaging Clin. North America* 1992; **2**: 221-233.
57. Van Gijn J, et al. The time course of aneurysmal haemorrhage on CT. *Neuroradiology* 1982; **23**: 153.
58. Owino-Musa. Stroke in the Young at KNH. MMed. Dissertation; 1993.
59. Sacco RL, et al. Infarcts of undetermined cause: the NINDS Stroke Data Bank. *Ann. of Neurology* 1989; **25**: 382-390.
60. Fisher AA, et al. Handbook for Family Planning Operations Research Design, 2nd edition. Population Council; 1991.
61. Zabsonre P, et al. Risk and severity factors in CVA in West African Blacks of Burkina Faso. *Medecine Tropicale* 1997; **57**: 147-152.

Appendix 1:

Data Collection Sheet

Patient's study No..... Centre..... X-ray no.....

Age..... Sex: 01: Male 02: Female.

Date of Scan..... Request form Dated:

Estimated Ictus to Scan Interval.....

Race 01- Black 02 - Other

Known Medical Conditions 01 – Hypertension 02 – Diabetes 03 – Coagulopathy
04 – HIV infection 05 – Sickle Cell Disease 06 – Previous stroke
07 – Other (specify).....

Presentation 01 - Hemiplegia 02 - Hemiparesis 03 – Speech defects
04 - Altered Consciousness 05 - Other (Specify).....

CT FINDINGS

1. Normal scan

2. Parenchymal haemorrhage

2.1 Site: 01 - Basal ganglia 02 - Thalamus
03 - Pons 04 - Cerebellum
05 – Frontal lobe 06 – Parietal lobe
07 – Temporal lobe 08 – Occipital lobe
09 - Multiple sites 10 – Other (specify)

2.2 For lesions in the lobes:

01 - Subcortical WM 02 - GM/WM junction

2.3 Side affected: 01 – Right 02 - Left

2.4 Max. Diameter in mm.....2nd.Diameter in mm..... (Perpendicular to the max.)

2.5 CT Density in HU.....

2.6 Appearance of Clot: 01 - Hyperdense 02 - Isodense 03 - Hypodense

2.7 Intraventricular haemorrhage: 01 - Present 02 - Absent.

2.8 Oedema: 01 – Present 02 – Absent

2.9 Mass effect / Sulci Effaced: 01 – Present 02 – Absent

2.10 Arterial Territory: 01- ACA 02- MCA 03- PCA 04- Other.....

3. Subtle signs of infarction

3.1 Side affected: 01 – Right 02 - Left

3.2 Sign: 01 - Hyperdense MCA 02 - Obscured lentiform nucleus
03 - Insular ribbon sign 04 - Loss of G/W matter differentiation
05 - Subtle WM Hypodensity 06 - Subtle Sulcal Effacement

4. Frank Infarction

4.1 Side affected: 01 – Right 02 - Left

4.2 Type: 01: TACI – cortical + subcortical infarct MCA area +/- ACA area
02: PACI – more restricted predominantly cortical infarct incl. isolated ACA infarct
03: POCI – posterior circulation infarct: brainstem, cerebellum, occipital lobes
04: LACI – lacunar infarct – small infarct in area of deep perforating arteries

4.3 Max diameter in mm.....2nd.diameter in mm..... (Perpendicular to the max)

4.4 If MCA territory: 01 - less than 1/3 of MCA territory 02 - more than 1/3 of MCA territory

4.5 CT density of infarct in HU.....

4.6 Oedema 01 - Present 02 - Absent

4.7 Mass effect 01 - Present 02 - Absent

- 4.8 Was IV contrast given? 01 - Yes 02 - No
- 4.9 If yes, enhancement related to infarct: 01 - Present 02 - Absent
- 4.10 Is the infarct haemorrhagic? 01 - Yes 02 - No
- 4.11 Anatomical Site: 01 – B/Ganglia 02 – Frontal 03- Parietal 04 – Occipital
 05 – Temporal 06 – Brainstem 07 – Cerebellum 08 – Other.....
- 4.12 For Lobar Infarcts: 01 – Cortical 02 – Subcortical WM 03 - Combined

SAH

- 5.1 Does the Request Form indicate a clinical suspicion of SAH? 01 - Yes 02 - No
- 5.2 Site of increased density: 01 - Basal cisterns 02 - Sylvian fissures 03 - Along the Falx
- 5.3 Reflux into ventricular system 01 - Present 02 - Absent
- 5.4 If “ictus to scan” interval > 1 week, is there a re-bleed? 01 - Yes 02 - No
- 5.5 Associated Hydrocephalus 01 – Present 02 – Absent
- 5.6 Associated Infarction: 01 – Present 02 – Absent Site:

Disorder other than Stroke (DOS)

- 01 - Tumour 02 - SDH
 03 - Abscess 04 - Other (Specify).....
-

General comment.....

.....

.....

.....

Consent Form (English)

My name is Dr J. K. Thiringi, a Master of Medicine student in Diagnostic Radiology, University of Nairobi. I am conducting a study on Stroke and would wish to recruit you to participate. The information you will give and the examination findings will be handled with complete confidentiality and your name will not be recorded.

Your doctor has ordered a CT scan of your brain. The procedure may be compared to taking advanced X-ray pictures and is safe and painless. No additional procedures will be performed on you. I will need to record your age, any known medical conditions, your main neurological symptoms and the date your stroke occurred.

The results of the study will be used to improve the management of stroke. Please note that you are not obliged to participate and you have a right to decline and still proceed with your examination as requested by your doctor.

Thank you for your cooperation

If you accept to participate, please sign below

Signature..... Date.....

I certify that the patient has understood and consented to participate in the study.

Dr. J. Thiringi.Date.....

Consent Form (Kiswahili)

Kibali Cha Kuhusika Katika Utafiti

Jina langu ni Daktari J. K. Thiringi kutoka Chuo Kikuu cha Nairobi. Ninafanya utafiti kuhusu magonjwa ya kufungana au kupasuka kwa misisi ya ubongo kwa kutumia mbinu ya picha ya X-ray utakayofanyiwa inayoitwa CT Scan. Picha hii imeamrisha na daktari wako na haina uwezo wa kukudhuru wala uchungu wowote.

Habari utakayotoa au ile itakayopatikana kukuhusu, itakuwa siri ya kutumika katika utafiti pekee. Jina lako halitajumulishwa.

Ripoti ya yale yatakayopatikana kwako na lolote lile litakalokusaidia litatumwa kwa daktari wako.

Utafiti huu utasaidia katika kurekebisha na kuendelea matibabu ya magonjwa ya sehemu ya misisi ya ubongo.

Tafadhali kumbuka unashiriki kwa hiari yako.

Kama unakubali kushiriki tafadhali weka sahihi yako hapa chini.

Sahihi..... Tarehe.....

Ninathibitisha kuwa muhusika ameelewa na kukubali kushiriki kwa utafiti huu.

Daktari J.K. Thiringi..... Tarehe.....

UNIVERSITY OF NAIROBI
MEDICAL LIBRARY