

ACHALASIA CARDIA AND OTHER BENIGN LESIONS OF THE OESOPHAGUS

AS SEEN AT KENYATTA NATIONAL HOSPITAL BETWEEN 1974 AND 1988

- A CLINICOPATHOLOGIC STUDY.

AN UNDERTAKING PRESENTED IN PARTIAL FULFILMENT FOR

THE DEGREE OF MASTER OF MEDICINE IN SURGERY.

BY DR. C.S.MOTAZE

SUPERVISED BY PROFESSOR P.A.ODHIAMBO, DEPARTMENT OF SURGERY

COLLEGE OF HEALTH SCIENCES, UNIVERSITY OF NAIROBI, 1988.

University of NAIROBI Library




0390022 2

UNIVERSITY OF NAIROBI
LIBRARY

DECLARATION.

I swear on oath that this work is my original work and that to the best of my knowledge this work has never been presented for a similar or higher degree in this University or elsewhere.


Signed 

Date...02/2/89...

Dr. Christopher Sinju MOTAZE

M.D YAOUNDE (CAMEROON)

I hereby certify that this work has been carried out under my supervision and I have found it satisfactory enough to be submitted.

Signed 

Date...02/2/89...

Prof. P.A.ODHIAMBO MB. B.CH, FRCS

Professor of surgery , consultant surgeon,

Cardiovascular and Thoracic surgery.

University of Nairobi &

Kenyatta National Hospital.

TABLE OF CONTENTS.

(i)	DECLARATION
(ii)	TABLE OF CONTENTS
(iii)	DEDICATION
(iv)	ACKNOWLEDGEMENT
(v)	SUMMARY

CHAPTERS:PAGE:

I.	GENERAL INTRODUCTION	1
	+ AIMS AND OBJECTIVES	4
II.	REVIEW OF LITERATURE	5
III.	MATERIALS AND METHODS	38
IV.	RESULTS	41
V.	DISCUSSION + COMMENTS	69
VI	APPENDICES	
	- Bibliography.	78
	- Questionnaire	91

DEDICATION

I am very delighted to dedicate this work to my daughter
NGOANDONG who has suffered from my absence, the result of a quest
for higher skills. May this be an inspiration to her, her mother,
her brothers and sisters to vie for greater heights.

ACKNOWLEDGEMENTS.

I wish to express my sincere gratitude to my supervisor Prof. P.A.OGHIAMBO for the keen interest he showed not only to this work but for my personal welfare. This human touch has really been the true inspiration.

My gratitude goes, untainted to the entire Cardiothoracic team messers B.O.OTSYULA , J.K.N.KARIUKI and all the rest of that unit for being so different from the rest.

I cannot forget my colleagues who have given me the push to carry on to the finish, by their constant reminder, interest and other contribution.

Patients are not forgotten especially for being patient and tolerant to me. I still remember how often you talked of your "hearts".

To Suzanne Thuo and Grace Kagwaine my grateful thanks for transforming my horrible handwritting to readable print.

My heartfelt gratitude go to my wife Dorothy Telelen for accepting the burden of my absence and for assuming so efficiently and nobly the position of head of the family for all these years and for the periods I shall be drawn from home by my responsibility to patients. Your sponsorship and sacrifices have been my strength out here.

SUMMARY.

Achalasia cardia is an age old problem. The original description dates back to the 17th century. The basic pathology is a neuromuscular failure resulting in the absence of lower oesophageal sphincter relaxation in the face of an advancing bolus. Several workers have tried to locate the lesion in the neuro-muscular axis. Opinions differ as to the level though myenteric plexuses have been shown to have reduced, degenerate or absent ganglion cells.

The clinical presentation is variable. The classical paradoxical dysphagia is not always seen. This variation notwithstanding our treatment of choice has been the classical or modified Heller's oesophagomyotomy.

During the period 1974 to 1987 a total of 107 cases were seen at Kenyatta National Hospital. This gives an average of seven cases per year. The clinical presentation, methods of management and the outcome of treatment is the object of this work. Achalasia accounted for 43% benign lesion treated over the period under study. The male/female ratio was 1:1 contrary to other workers (2,40). The triad of dysphagia, regurgitation and weight loss were the only consistent symptoms. Other symptoms were described. In the absence of manometry Barium swallow and clinical evaluation still remained valuable diagnostic tools.

Despite the advanced stage at which the patients presented the result of treatment was satisfactory. 63% had very good to excellent result at myotomy with pre or post operative dilatation.

Evidence of carcinoma was found in 4 cases, accounts for 3.74%: 2 at endoscopic biopsy and two from resected lower oesophageal segments.

Achalasia cardia is thus a not uncommon problem in our environment. Its malignant potential is unquestionable. Oesophagomyotomy is so far the best treatment and should be performed as a primary therapy unless conditions warrant its postponement.

We hope the aspects of the problem which have not been studied will form the basic of further work as soon as the facilities become available to us.

CHAPTER ONE.INTRODUCTION:

Achalasia of the oesophagus is a neuromuscular disorder resulting from motor failure at the lower end of the oesophagus or the gastro-oesophageal junction. The clinical effect is failure of the gastroesophageal junction to relax in the face of an advancing bolus. This gives rise to a symptom complex.

As early as 1674 Willis made the first original description of this disease and much to his credit that description is still adequate, complete and upto date. He did not give a name to this classical and historical description and it was only in 1913 that Hertz coined the term achalasia meaning failure of relaxation.

That year saw the advent of the first successful operative technique of oesophagomyotomy performed by Ernest Heller. This inaugural technique consisted of two longitudinal incisions through the muscles of the lower oesophagus down to but sparing the mucosa. In the same year a modification using one anterior myotomy was introduced by ZAAIJER. Both have been put to test by pressure measurements (12) and show satisfactory reduction in sphincter pressure. The classical Heller's myotomy is however attended by higher

incidence of spontaneous reflux and has all been abandoned for the Zaaier's technique. This modified Heller's myotomy is the operation of choice for the non-complicated cases of achalasia.

Individual modifications exist and are practised according to the whims of the surgeons. These include varying the approach (thoracic or abdominal), excision of abundant redundant muscle, performing anti-reflux procedures, varying the length of the incision. these variations have raised their own dust of controversies.

The aetiology of cancers is still largely unknown but the role of certain lesions or the contribution of certain factors is fairly common knowledge. Studying these conditions and factors gives us the hope of finding the track that leads to the much sought for link.

It has been known for long that environment contributes to 90% of all cancers, prominent among these factors are dietary factors which are thought to be responsible for as much as 35% (4) Beaumont more than 150 years ago stipulated that diets may have something to do with cancer and diseases of the digestive system (4) . Recently Burkitt and Trowel (1975) worked extensively on refined carbohydrate foods and the implications of dietary fibers intake to high incidence of colonic cancer, coronary heart disease, obesity, diabetes mellitus, hypertension and hiatus hernia. The latter three

have other diseases as their sequelae. The list in this hypothesis cannot be said to be exhaustive. Achalasia and other lesions have had dietary factors implicated, though not proved, in their pathogenesis.

There is an abundance of literature on achalasia cardia or cardiospasm mainly on aspects of management and complications. Very little is available on aetiological factors and though extensively documented elsewhere almost no work has been done locally.

AIMS AND OBJECTIVES.

Achalasia cardia is a world wide problem and the abundance of literature on the modalities of treatment attest to the fact that as well as being prevalent no cure has yet been found.

Our records indicate that cases have been documented as far back as 1971. Yet apart from a preliminary study (Kamdar et al 1986) (40), no other work has been published on this subject in Kenyatta National Hospital.

The aim of this work is not only to fill this gap but to carry out an exhaustive and detailed study of the cases of achalasia as seen at Kenyatta National Hospital within the last 15 years (1974-1987). In this light the following was undertaken:-

- 1) A review of all the files of patients treated so far for achalasia to determine their clinical pattern of presentation here; the attitudes of management, complications, and other significant findings.
- 2) A scrutiny of files of patients treated for benign dysphagia.
- 3) An examination of files of patients treated for malignant stenosis. This was mainly to look for indices of premalignant lesions that might have signalled themselves earlier.

I. ANATOMY

1.1. Developmental

The oesophagus develops from the 6th pharyngeal arch during the 3rd week of gestation (20-23 days) within the primitive pharynx. This primitive pharynx results from the differentiation of the part of the yolk sac underlying the embryonic disc, ventral to the neural folds and groove. As the embryonic disc folds the root of this cranial end of yolk sac invaginates into the developing head to form the foregut.

The cranial end of this foregut is at first blind, being separated from the stomodeum or oral cavity by the oropharyngeal membrane. The caudal end is also blind but the pharyngo-tracheal groove appears in the posterior wall. With the elongation of the neck, the descent of heart and lungs into the chest, the caudal end of the foregut elongates rapidly (22-23 day) to form the primitive oesophagus distal to the pharyngo-tracheal groove.

Also from the anterior wall the laryngo-tracheal groove develops. This will form the larynx; trachea and respiratory system.

The primitive oesophagus has a dorsal meso-oesophagus attaching it to the posterior wall. This meso-oesophagus with the surrounding mesenchyme contribute to the formation of the mediastinum. Anteriorly it is separated from the trachea by a tracheo-oesophageal septum.

The musculature is formed by surrounding mesenchyme while the entoderm within the tube gives rise to the stratified squamous epithelium. By the 8th week the epithelial lining proliferates to occlude the lumen but will usually breakdown to give a patent lumen. Incomplete resorption of these epithelial masses is responsible for the presence of webs and diaphragms while non-resorptions or failure of recanalisation of the lumen results in atresia.

1.2. Structural

The oesophagus has an inner epithelial, a submucosa and an outer muscular layers.

The muscular layer is striated at the upper one-quarter section but smooth below this. The point of transition is vague though situated at about the level of the aortic arch. Some skeletal fibres have been found in the lower oesophagus.

The external longitudinal and inner circular (muscular) fibres of the upper part are attached by the crico-oesophageal tendon to the back of the lamina of the cricoid cartilage. The oesopharyngeal fibres of inferior constrictors of the pharynx act as a sphincter to the oesophageal inlet.

At the lower end no anatomical sphincter exists and the gastro-oesophageal sphincter is purely physiological. Its components are:-

1. The circular muscle fibres which cover the entire oesophagus (the longitudinal are deficient in the lower half).
2. The crura of the diaphragm though they do not contract.
3. Length of abdominal oesophagus.
4. Valve-like flaps of the mucosa maintained by contraction of the muscularis mucosae.
5. Circular muscles at the cardia forming a sling around the oesophagus.

All these maintain the closure of the oesophagus to stomach contents. Contributory are the angle of His and the intra-abdominal pressure.

1.3 Macroscopic Anatomy (surgical anatomy)

The oesophagus extends from the level of the cricoid cartilage corresponding to the 6th cervical vertebra to the cardiac opening of the stomach. It pierces the diaphragm at the level of the eleventh or twelfth thoracic vertebrae. Though it begins at the lower end of the pharynx, in exploration (endoscopy) the measurements are made from the upper incisors (see figs. 1 and 2).

In the standing position the adult length is 25-30 cm. It is 2 times as long as the trachea and in the female it is 1-2 cm shorter.

For purely descriptive purposes it is divided into three main parts: see fig. 1 and 2.

- i. Cervical oesophagus it is one-fifth of the total length.
- ii. Thoracic oesophagus.
- iii. Abdominal oesophagus.

The diameter varies from 1 cm in the upper segment to 2 or 3 cm in the lower segment.

1.3.1 Impression and Constrictions: The following structures adjacent to the oesophagus leave indentations which can be visualized in radiology. The arch of the aorta, the left atrium, left main bronchus and left pulmonary artery, and the descending aorta just above the diaphragm.

There are three main points of constrictions: cricopharyngeal sphincter which is 15 cm from the incisors the level of the left main bronchus and the diaphragmatic hiatus.

1.3.2 The cervical oesophagus: Related anteriorly to the trachea and recurrent laryngeal nerves in the groove; posteriorly to the longus colli and vertebral column; laterally to the lobes of the thyroid gland and the carotid sheath. Here it is a mid-line structure though slightly to the left projecting from behind the trachea. Thus the best approach could be through the left side, the right is adopted though but for purely safety reasons (fewer blood vessels).

1.3.3 The thoracic oesophagus: It is still a median structure though not midline. It constantly changes direction. It lies in the posterior mediastrium behind the trachea and then behind the pericardium to which it is applied and which separates it from the left atrium.

In the upper part of the chest the oesophagus leaves the midline and curves slightly to the right until it reaches the arch of aorta, past which it lies in front of but posteriorly to the carina, closer to the left main bronchus with a sleeve of pericardium separating them.

At the level of the left main bronchus it begins to deviate again to the left until it pierces the diaphragm after which it takes a sharper further turn.

In the posterior mediastinum it thus lies in a tunnel that leads from the chest to the neck allowing passage of air and fluid in cases of oesophageal perforation. Between it and the vertebral column is a space filled with pleura between which layers the blood vessels from the aorta reach the oesophagus. This space is visible on lateral view radiographs.

1.3.4 The abdominal oesophagus: As it pierces the diaphragm it continues its left-ward turn till it joins the lesser curvature of the stomach forming the gastrooesophageal or cardio-oesophageal junction. It is still closely related to the vagi, the left one anterior to it while the right one is posterior. It is only partially covered by peritoneum.

1.3.5 Blood supply to the oesophagus: The blood supply is segmented. The cervical or upper third is supplied mainly by the inferior thyroids, occasionally from the ascending pharyngeal artery and branches from the common carotids. The thoracic segment receives its blood supply mainly from the bronchial arteries, from direct branches from the aorta, and from the right intercostals in about 20% of cases. Other rare sources include internal mammary, costocervical trunk and very rarely the subclavian. The subdiaphragmatic portion receives blood from multiple sources: The left inferior phrenic, left gastric and occasionally from an accessory left hepatic artery which derives from the splenic artery or the coeliac axis.

The oesophagus between the jugular notch and aortic arch is relatively avascular.

The venous drainage follows the arteries except that there is a rich network of anastomosis between the portal system (via the oesophageal and gastric veins) and the systemic or caval veins via the azygos. According to Lieberman the anastomosis occurs in the lamina propria within the submucosa and on the outer surface of the junctional

regions (35), although Sir Walker who first described transection and devascularisation as treatment for varices had claimed the bleeding was at the level of the gastroesophageal junction. Both agree however that the bleeding is subepithelial and only lateral wall erosion will lead to exteriorized hemorrhage.

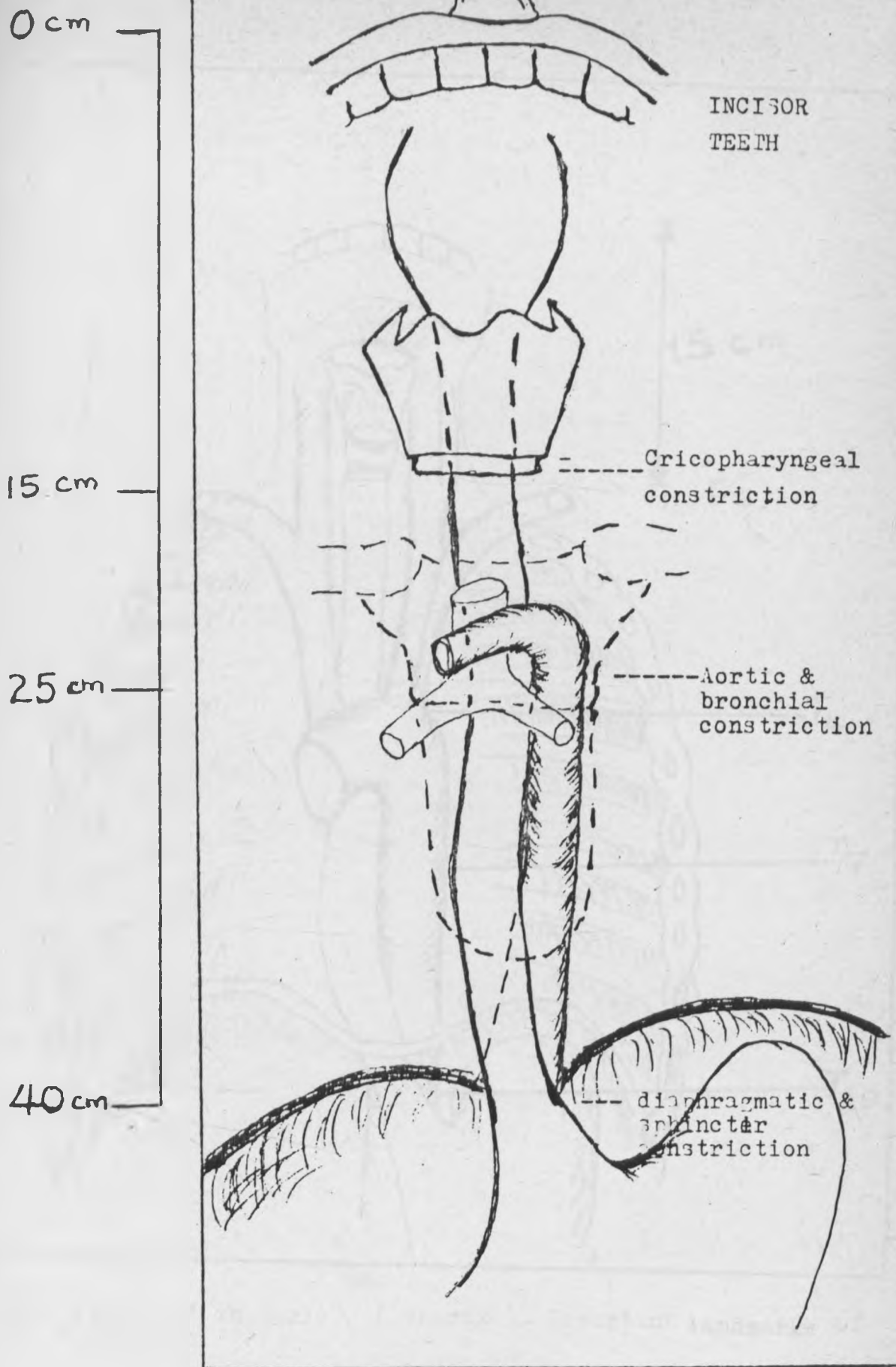


Fig.1 Adapted from BAILEY & LOVE and Cahier d' anatomie
(Thorax). Important relations of the oesophagus

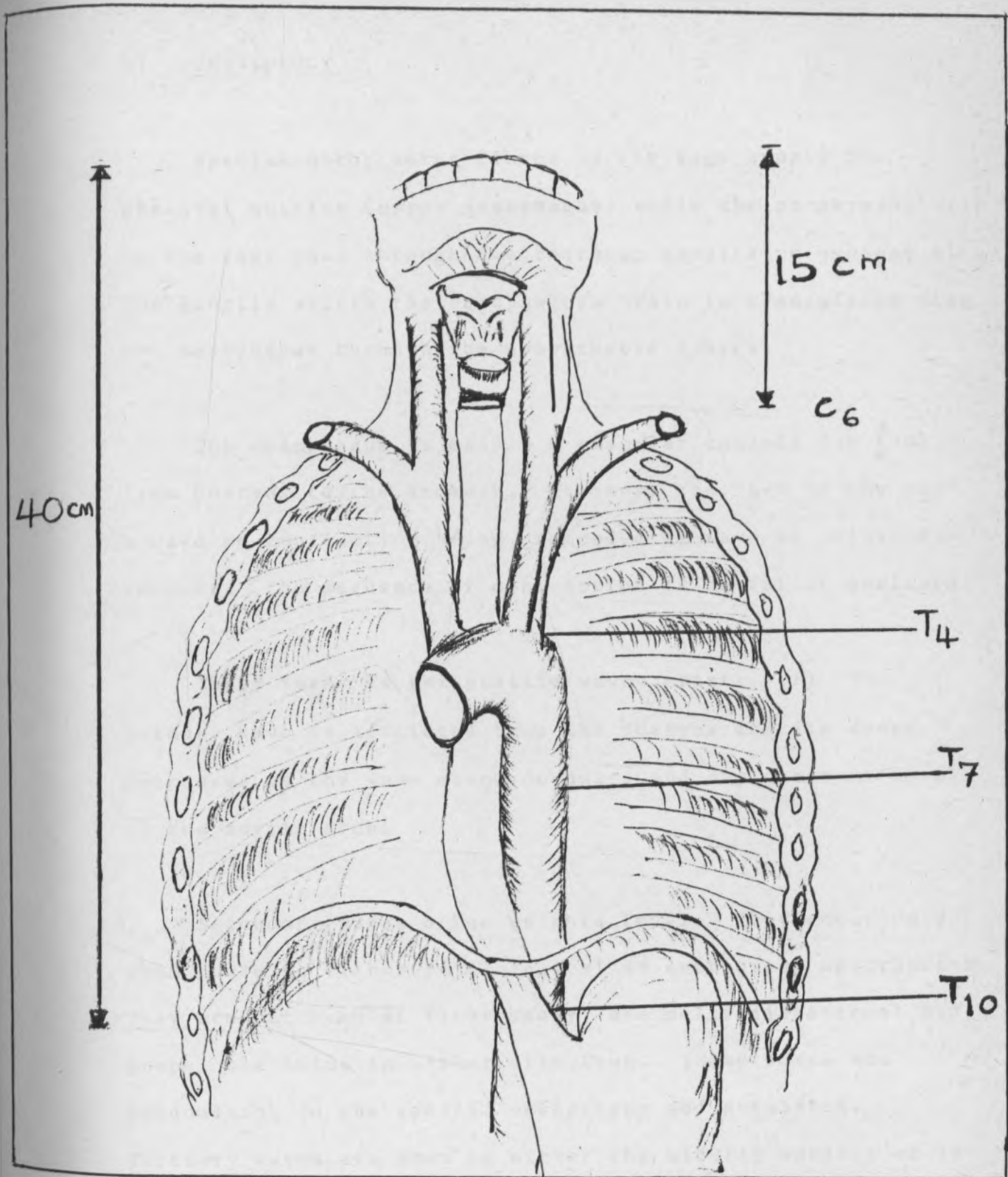


Fig. 2 From Cahier d' anatomie (thorax). Important landmarks of the Oesophagus.

II PHYSIOLOGY

Special motor nerve fibres in the vagi supply the skeletal muscles (upper oesophagus) while the parasympathetic in the vagi pass through the thoracic ganglia to synapse with the ganglia within the oesophagus. Pain is transmitted from the oesophagus through the sympathetic fibres.

The oesophagus is mainly a muscular conduit for food from pharynx to the stomach. It obeys the "Law of the gut": a wave of contraction being preceded by wave of relaxation in front. The sequence of contraction is aboral or analward.

Three forms of peristaltic waves exist. (i) The primary wave is initiated from the pharynx and its speed decreases as the wave moves downward and may cease at level of the aortic arch.

Secondary waves arise at this level. They occur only when there is either physiological or mechanical obstruction. They are not seen at fluoroscopy, are multi-directional and propel the bolus in either direction. These waves are predominant in the spastic oesophagus and achalasia. Tertiary waves are seen in either the elderly subject or in cardiospasm.

The intra-oesophageal pressure is high at the level of the crico-pharyngeus and decreases downwards, only to rise sharply at the diaphragmatic hiatus and gastro-oesophageal junction. Manometric studies are used to detect the abnormalities that arise in certain pathologies (see fig 3).

The intraluminal surface (epithelial) is usually alkaline and pH studies are thus indicated occasionally.

The change from oesophageal squamous epithelium to gastric columnar makes an important junction whose position will be of important in certain affections.

PATHOLOGY.

Achalasia of the oesophagus, otherwise called achalasia cardia, mega-oesophagus or cardiospasm is a neuro-motor disorder resulting in a functional obstruction at or near the oesophago-gastric junction with consequent dilatation at or near the thoracic oesophagus. Dilatation may involve the entire oesophagus except the abnormal distal segment.

The initial description of the disease was made by Willis (1674), without giving it any name but the term was coined independently by Hertz in 1913 and 1915 by Sir Authur Hurst (62). Since then the word 'achalasia' has been used interchangeably with 'cardiospasm' though the disorder is both motor failure of oesophagus and failure of relaxation of the sphincter at the gastroesophageal junction.

Though there is general agreement on terminology concepts about pathology are divergent and have equally evolved. It was initially felt the disorder was merely due to absent ganglion cells.

Current concepts would rather ascribe to denervation. There may be a complete loss of myenteric ganglion cells but degeneration has been found in some of the specimens studied in some series such as those by Adams and coworkers (1).

Misiewicz also performed pharmacologic and histologic studies on strips of muscle obtained at surgery (47). They noted loss of B-adrenergic inhibition activity which mediates relaxation of muscles. Ganglion cells were either absent or abnormal.

Some authors have suggested that the primary disorder is in the preganglionic neuron but this has not found universal acceptance (15).

The aetiology of achalasia thus remains largely unknown though a number of conditions are closely related to it. Almost anything including psychiatry has been ascribed to it.

Age: achalasia has shown itself to be no respecter of age. Cases have been reported in neonates and children. Judson has found literature reports which include as much as 5% children and infants as young as 2 weeks of age (38). The peak incidence lies between the 2nd and 4th decades.

There also tends to be a familial tendency specially in the paediatric type. This infant incidence makes achalasia a worthwhile differential of regurgitation, failure to thrive, and recurrent respiratory tract infections in infants and children.

Sex: Achalasia has been known in Western Countries to affect females predominantly with a ratio of 2:1 over the male but Kamdar et al (40) as well as Adebo et al (2) have shown a reversal to a male predominance with ratios of 3:2 and 2:2.1 respectively.

Other factors: Some reports have suggested that chest trauma may be a factor in the development of achalasia. Others have incriminated the vegetative nervous system, and experimental destruction of the dorsal motor nucleus of the vagus and cervical vagotomy have produced in the rats oesophageal dilation similar to the human achalasia (1,12). A decrease in the number of ganglion cells in the dorsal motor nucleus of the vagus has been noted. Attempts have been made to incriminate neuropathies such as Raynaud's disease and diabetes. Kamdar and co-workers reported the case of a patient who developed symptoms after cervical sympathectomy for Raynaud's phenomenon. Heller's operation cured her of dysphagia but her Raynaud's disease persisted.

Chaga's disease, prevalent on a large scale in South America, is capable of producing oesophageal disease virtually identical to achalasia with both manometric and roentgenographic findings. Here, however, there are associated dilatations of the colon, ureters and other viscera. As such, most of the cases of achalasia reported from South America are actually cases of Chaga's disease.

There is not enough evidence that cases reported elsewhere in the world result from T.Cruzi, the pathogen of Chaga's disease.

Biopsy results as reported by Adedo et al, 1980 are indeed interesting. It is surprising, he says, that biopsies from myotomy cases rarely showed absence of ganglia. Rather a common finding was evidence of inflammatory changes. Could these be signs that their series of achalasia was of an acquired immune disorder?. It should be very interesting to find out. Were it so, achalasia would be on a highly endemic scale in filarial zones.

FILARIASIS.

The findings of filarial fibrosis does not make the picture clearer. Adebo et al report one case in their series (2). If filaria were as strong an aetiological agent then much of West Africa should present a higher incidence of achalasia.

CLINICAL PICTURE.

The age and sex incidence have already been discussed. The onset of symptoms may be insidious or sudden following a trauma, be it psychic or physical (56).

Patients would normally talk of food sticking to their throats and many would try to adjust their diet. Classically the problems start more with liquids but could progress to solids.

Pain, an infrequent symptom, is usually restroternal, epigastric or referred and would be precipitated by cold or hot foods as well as hurried meals. It is an early symptom if it occurs. It is now thought to be due recovery ischemia (44).

Regurgitation may be the bell-ringer occurring most often on recumbency. It could be spontaneous. The taste would vary from normal to sour as the disease progresses; it could even be frankly foul-smelling.

Hemorrhage is a sign of alarm as it could point to the presence of neoplasm (56). Otherwise it is usually due to oesophagitis.

Other not uncommon symptoms include parotitis, vitamin B deficiency as well as inanition (17,56).

Respiratory symptoms may be secondary to regurgitation and aspiration (17,56). Pneumonitis is the result and could also be seen in consumers of tea and home-brewed liquor (17,18,48,49). More typical are inhalation pneumonitis but rare manifestations have been described (7,56). These include hemoptysis, bronchiectasis, lung abscess and asthmatic attacks (56); and rarely signs of respiratory tract obstruction presenting as stridor (7,8,30,37-49).

Achalasia may reveal itself through hematemesis consequent upon oesophagitis or from associated carcinoma which may be coincidental. In this case the carcinoma usually arises just proximal to the end of dilatation.

Not unusually an enlarged cervical oesophagus causing superior vena cava obstruction may be the warning sign. Slowness at eating has been noticed and this is accompanied by intake of copious amount of fluid "water escort" (56). Certain manoeuvres are adopted to assist the increasingly dilated flaccid oesophagus. These include the valsalva manoeuvre.

These attempts by patients to solve their own problems are in a way responsible for their reporting late for medical and surgical attention.

INVESTIGATIVE STUDIES:

Whereas history may be very contributory to the diagnosis of achalasia the physical examination offers very little.

1. Reontgenographic Studies. They show a lot of consistency and correlate well with fluoroscopic, endoscopic and clinical stages of the disease.

Osler-Spencer defines three stages of the disease (56).

- a) Early stages with mild dilatation.

- b) Diffusely dilated stage with much regurgitation.
- c) Decompensated stage with the dilated oesophagus assuming even a sigmoid appearance. Much food can be retrained here and the patient shows wasting despite a "lot of food in him".

2. Fluoroscopy will demonstrate vigorous though disorganized oesophageal contractions in the lower oesophagus. The picture is that of a tapered-end cigar or pencil. It is to be noted that contractions diminish with progression of the disease culminating in the total abolition of peristalsis. In the latter stage fluid level could be noted in the oesophagus on Barium swallow and even on plain chest x-rays.

Ladapo 1978 (43) basing his studies on chest x-rays, barium swallows and fluoroscopy describes three stages.

- i. Patient with dilatation less than 4 cm diameter.
- ii. Fusiform dilatation of between 4 and 6 cm diameter.
- iii. Dilatation of more than 6 cm, the oesophagus being tortuous and or sigmoid.

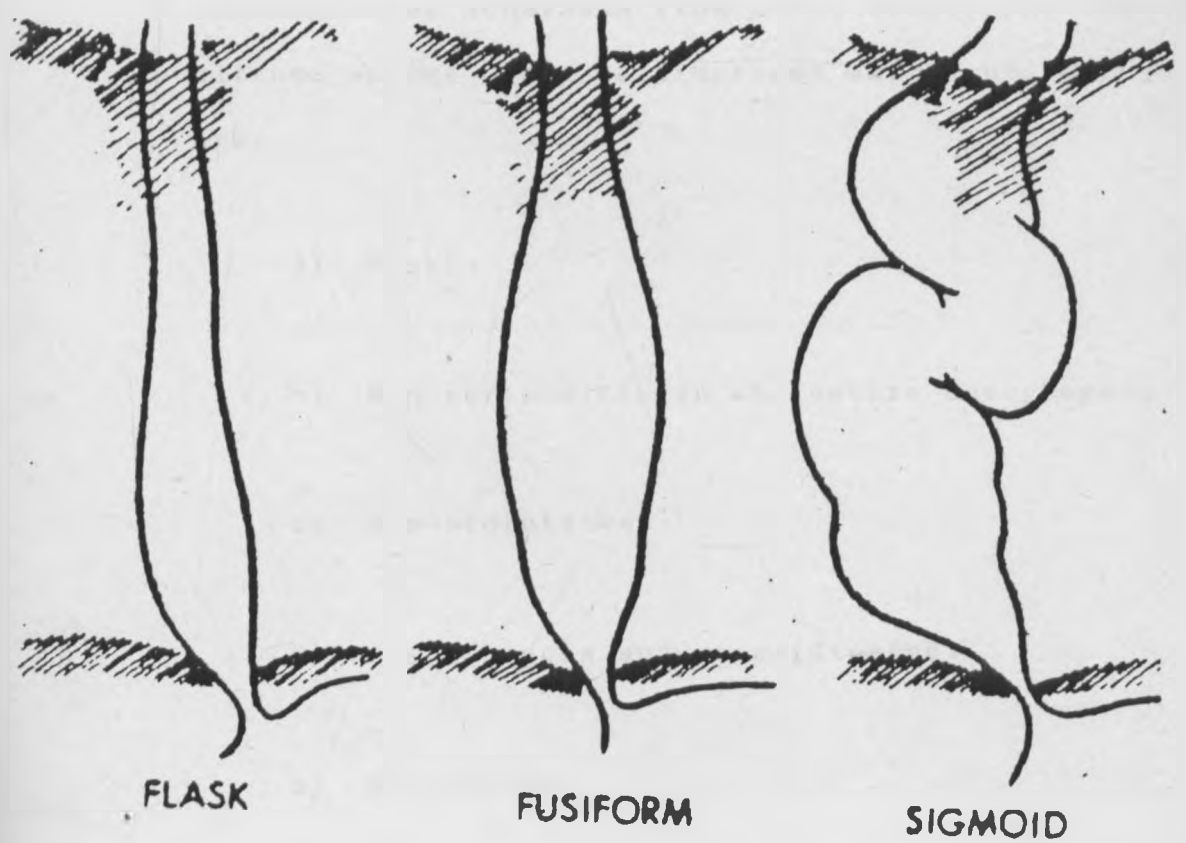


FIGURE 3

Gross forms of achalasia: flask, fusiform, sigmoid. These are equivalents of stages I, II and III respectively.

Adopted from POSTLETHWAITE R.W. Surgery of the Oesophagus

This staging correlates well with that of Osler-Spencer.

3. These roentgenographic studies are complemented by manometry. This has become the most valuable diagnostic tool and is particularly helpful in the early stages to distinguished achalasia from other conditions such as diffuse spasms where contractions may be present but are:

- a) Feeble
- b) Non-peristaltic in the entire oesophagus.
- c) Non-propulsive.
- d) Simultaneous and uncoordinated.
- e) Repetitive.

Inspite of these the primary (peristaltic) waves are absent. The pharyngo-oesophageal sphincter is normal. The pressure in the gastro-oesophageal junction is noted to be higher than normal and relaxation on swallowing is absent or incomplete.

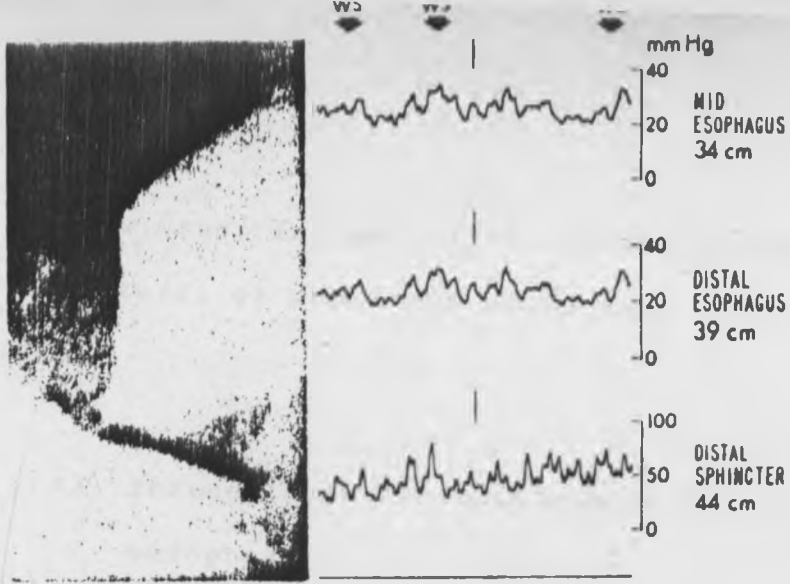
4. Recently bathanecol given subcutaneously has been found to produce powerful, sustained, painful contractions denoting autonomic denervation of the oesophagus (60). This reaction is not present in normal individuals (see fig 4).

All these are reversed or improved on forceful dilatation or following Heller's myotomy.

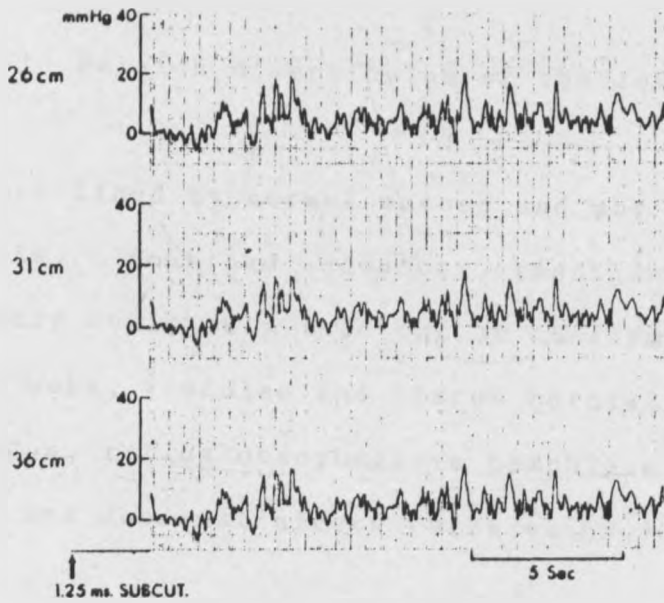
Manometry would be necessary to differentiate affections clinically and radiologically mimicking achalasia. Even then endoscopy may still have to be resorted to, to rule out any associated lesions such as scleroderma, carcinoma of the infiltrating type, diffuse spasm and even benign strictures. It is mandatory in patients with short history of achalasia, suspected stricture or who have had haemorrhage (56).

5. Endoscopy still has its limitations. It may be negative in the early stage of the disease and the characteristic rosette of mucosa may mislead the inexperienced. As the disease advances much retained material may cause poor visualization.

The tortuous nature of the oesophagus in late stages makes visualization poor, even if one uses a fibroptic type of endoscope.



Achalasia. There is a positive resting pressure in both middle and distal esophagus, and a high resting sphincter pressure with absence of relaxation.



Achalasia. Methacholine injection causes a higher mean resting pressure and repetitive contractions.

Fig. 4 Adopted from surgery of the oesophagus by

POSTLETHWAIT, R.V.

Yet a few other lesions have roentgenographic and manometric features of achalasia which even the endoscopist may miss:-

- i) Pedunculated fibrolipomas of the lower oesophagus.
- ii) Intramural leiomyomas of the lower oesophagus and
- iii) Pulsion diverticulum of the lower oesophagus.

These are lined by normal mucosa and may coexist with achalasia. Combined endoscopy, roentgenography and manometry could help rule out or confirm other lesions such as webs, fistulas and hiatus hernia, Barret oesophagus, reflux oesophagitis pemphigus vulgaris, gastric and duodenal ulcers (9,21,44,63,70).

Achalasia cardia should be differentiated from other achalasia of the oesophagus, such as:

1. Upper oesophageal sphincter dysfunction or cricopharyngeal achalasia involving mainly the upper third of the oesophagus.

2. Diffuse oesophageal spasms involving the lower two-thirds of the oesophagus. The contractions are of high-amplitude, repetitive, non-peristaltic, often sustained, and are seen in about 10% of wet swallows. Features suggestive of achalasia are seen only in 30 % of cases.

24 hours - pH studies: These are not useful because lactic acid obtained from fermentation of food residues and after treatment could be resulting from reflux and we have no way of differentiating acid from fermentation and acid refluxed from the stomach (44,51).

MANAGEMENT.

According to Oslen and Payne (56) the obstructive symptoms of achalasia are due solely to the failure of the lower oesophageal sphincter to relax in response to swallowing and unfortunately we are not capable of restoring the normal motor function. The whole object of our treatment efforts would be directed at weakening this sphincter i.e. relieving the functional obstruction.

While there is agreement on this broad principle there has been a lot of controversy on exactly what should be done and how it should be done. All sphincter-destroying procedures bear the inherent risk of causing reflux, ulceration, hemorrhage and fibrotic strictures (cicatrical changes).

Non Surgical Approaches to Management.

Psychotherapy has been tried by those who felt achalasia was a psychiatric disorder (5,12). This was woefully disappointing. Belladonna derivatives were tried without success. Nitrites or nitroglycerin may be used but only in the early stage as palliation (11,15,44,53).

1. Non Operative.

Mechanical dilatation of the lower sphincter has been in use since Thomas Willis (1674) first described the disease (2,12,62). Benefits from ordinary bouginage are temporary or transient because they leave the unrelaxing or hypertensive sphincter intact. Expanding dilators actually are needed to tear or disrupt the muscles of the sphincter (2,12,23,41)

Russel (12,23,41) is said to have developed the first expanding dilator in 1898. Most dilators are expanded by air or water and varying pressures are used as is necessary. Pressure is carefully controlled (41,45,60,71). Slight pain and bleeding are usually noted. Complications here include mediastinitis and rupture. Strack (41,48) used metal dilators which were placed endoscopically. The results are usually good. In the series reported of 15 children by Tachovsky, Lynn and Ellis (71) the longest symptom free period was 3 years and all the children eventually required surgery. Thus surgery remains the method of choice in young subjects. Mayo Clinic (4148,62) reported in 1867 good to excellent results of 60-70%. Each patient received a maximum of 8 dilatations (60).

If there is agreement on the fact that the solution to the motility disorder is to split the lower sphincter, how to do it remains very much controversial. For some authors the split should cover the entire segment where there should be smooth muscles (17,22,49,53,62,64). For others the splitting of a few millimeters distal to the sphincter is all that matters (40,13,24). For Way Lawrence 1 cm into the gastric fundus is enough (76). The total length of the incision is variable. Most authors would prefer a 7-10 cm incision that runs from the inferior pulmonary vein to the gastric cardia.

For Way (76) 10-12 cm incision is required and for ADEBO (2) 6-12 cm is the required length.

Currently when people refer to the above procedure as Heller's oesophagomyotomy they are actually referring to a modified Heller's procedure (49,32,78,39,11,50,77). Ellis et al (23) think either the median incision or the original bilateral incisions both lead to the loss of obstruction and thus the goal is achieved. Nemir and Frobes (52) feel the modified (median incision) procedure is beset with fewer problems.

In few instances other procedures may be applied. Such is the case of extreme fibrosis where the oesophagus might need to be reconstructed, replaced or by-passed (7,80,79,10,50,64).

Anti-reflux procedures are not routine but where the natural anti reflux mechanisms were already faulty or were destroyed at surgery they have to be undertaken. These are needed in the case of replacement and/or oesophagectomy done either for associated carcinoma or for extremely fibrotic lower oesophagus, or occasionally redundant tortuous oesophagus.

The Heller's operation or its modified version usually achieves between 85-95% success. The failures or recurrent dysphagia may be due to one of the following:

- i. Inadequate myotomy
- ii. Extensive paralysis of the body of the oesophagus.
- iii. Gastro-oesophageal incompetence often due to overzealous operation.
- iv. Stricture secondary to reflux oesophagitis.
- v Development of carcinoma.

RELATIONSHIP OF ACHALASIA TO CARCINOMA.

Though the aetiology of achalasia remains in dispute the complications find a more clinically convenient unanimity. Besides oesophagitis, aspiration, regurgitation and respiratory complications, carcinoma is an awesome possible complication.

Different incidences have been reported. Cases have been reported where achalasia were found in association with multiple malignancies. Barour et al report a case of squamous cell and adenoid cystic carcinoma(7). The presence of the adenoid is attributed to chance finding but squamous cell carcinoma may be due to dysplasia. The incidence of carcinoma on achalasia of the oesophagus is put at between 1 and 10% (7,11,20,30,32,39,41,78).

The pathogenesis is not very clear but it could be reasoned that achalasia (with or without reflux) will lead to obstruction and/or reflux oesophagitis. The obstruction allows for longer periods of contact between the mucosa and possible carcinogens; or in the case of reflux either the chronic irritation predisposes the mucosal cells to malignant change or brings them into contact with bile and other gastro-intestinal secretions that may be carcinogenic (7,9,12,32).

OESOPHAGITIS AND BARRET OESOPHAGUS.

I. Barret oesophagus. The original Barret's description was for a mediastinal stomach due to a short oesophagus (70). Barret felt continuous acidity from stomach led to chronic irritation of the oesophageal mucosa. It is now felt it is the end stage of oesophagitis as cases of longstanding reflux have shown the lower oesophagus lined by gastric mucosa which is columnar in type (3,9,28,63,69,70).

The malignant potential of Barret's oesphagus is an established fact. It ranges from 0.01 to 0.66% in various series (9,58,63,69,70). Cases followed up endoscopically show progressive epithelial metaplasia to frank mitotic figures increase. Others think it is simply part of generalised metaplasia (16).

OESOPHAGITIS OF VARIOUS AETIOLOGIES.

These aetiologies include hiatus hernia, caustic ingestion, burns, drug induced and/or chronic ingestion of beverages and alcohol. It is now generally felt any chronic irritation is likely to cause dysplasia and thus has a malignant potential (7).

In this light the malignant potential of achalasia motility disorders, amyloid disease, Crohn's disease, pemphigus vulgaris, ingestion of hot beverage and/or alcohol can be explained (23,33,37,58,66).

MENETRIER DISEASE: This is a giant mucosal hypertrophy involving mainly the stomach and lower oesophagus. This affection is premalignant. 0-5% of adenocarcinomas of the stomach and oesophagus arise from these lesions. Diagnosis

Diagnosis is based on endoscopy and biopsy which shows giant hypertrophy of gastric mucosa. It is very difficult to distinguish from malignancy and some authors have proposed radiotherapy and steroids administration as a protocol for treatment (66).

Many other benign lesion exist but some could merely be precursors of others. Diffuse spasms and vigorous achalasia are thought to be precursors of true achalasia; per se they do not have any malignant potential. They may be associated with other gastrointestinal tract disorders such as gallstones, peptic ulcers, pancreatitis, hiatus hernia and diverticulosis.

Hypertensive sphincters, (upper or lower) would normally coexist with achalasia and other motor disorders. Hypotensive lower oesophageal shpincter will present as reflux and its consequences will be those of reflux oesophagitis. The presentation of scleroderma is similar.

CHAPTER THREE

MATERIALS AND METHODS.

This study has been largely retrospective, the source of the material being the files and records of patients as found in the hospital records department, theatre recordings and files in the surgical and medical wards. We looked into the files of patients diagnosed both as dysphagia, carcinoma or other oesophageal and digestive system diseases. These mainly provided sideline information and facts.

The main emphasis was on achalasia, patients with which diagnosis received more attention and all the necessary facts were collected onto the data sheet.

Twenty patients were seen during their hospital stay. This number was rather small and so they were merged with the retrospective cases for analysis. This prospective group did not give as much information as initially thought. The issue of missing files is still an acute problem as quite a number could not be traced. Also most of the x-ray (contrast studies) were not available for comment in this study.

The diagnostic criteria included the clinical symptom complex, roentgenographic findings and confirmation at surgery. The most useful were barium swallow, endoscopy and surgical confirmation.

Data on each patient included identification, mode of presentation, duration of symptoms, essential clinical features, preadmission procedures and other investigations; chest roentgenographies were part of barium swallow. The latter and fluoroscopic assessment of motility formed the cornerstone of diagnosis. Staging was done in some patients prior to surgery but only at surgery in the rest. Endoscopy was performed in a few patients. Dysphagia was staged but not found to be reliable as patients often tended to exaggerate their symptoms to win sympathy.

Information on each patient was collected onto the prepared data sheet for analysis.

Manometry and 24 hr acid (pH) studies would have been useful but are not currently done at this centre. Perhaps the huge number of patients labelled as "Dysphagia of undiagnosed or unknown aetiology" could have provided more cases to this sample lot of achalasia

Those who refused surgery, were lost to follow up or died before surgery, were included for analysis to provide information on aspects of this diseases other than the technique and result of surgery.

Biopsy results were not always handy. Often lack of facility for processing these specimens discouraged many surgeons so much so that they (biopsies) were not always taken either at endoscopy or at surgery. This was also responsible for our abandoning an important part of this work which invloved examining specimens of the lower oesophagus, excised due to cancer, for evidence of achalasia in an attempt to determine the link between these cases of malignancy and achalasia.

Analysis of data is depicted on the tables recorded and described from those not published here.

Our records are compared with those published elsewhere if those aspects have been studied.

TABLE 1.

AGE/SEX DISTRIBUTION OF PATIENTS.

AGE GROUP (RANGE) IN YEARS.	0-10		11-20		21-30		31-40		41-50		51-60		61-70		ABOVE 70		NOT STATED		TOTAL.
	M	F	M	F	M	F	M	F	M	F	M	F	M	F	M	F	M	F	
NUMBER OF PATIENTS	5	7	11	13	12	11	7	6	9	7	2	7	4	1	2	0	2	1	107
TOTAL	12		24		23		13		16		9		5		2		3		107
CUMULATIVE TOTAL	12		36		59		72		88		97		102		104		107		107
PERCENTAGE	11.2		22.4		21.5		12.1		15		8.4		4.7		1.9		2.8		100%
CUMULATIVE PERCENTAGE	11.2		33.6		55.1		67.2		82.2		90.6		95.3		97.2		100		100%

The mean age of the patients in this series was 32 (31.9) years with the youngest being two babies of 2 months of age and the oldest being 75 years. The Male/female ration was 1:1.

FIGURE 5

AGE/SEX DISTRIBUTION OF PATIENTS

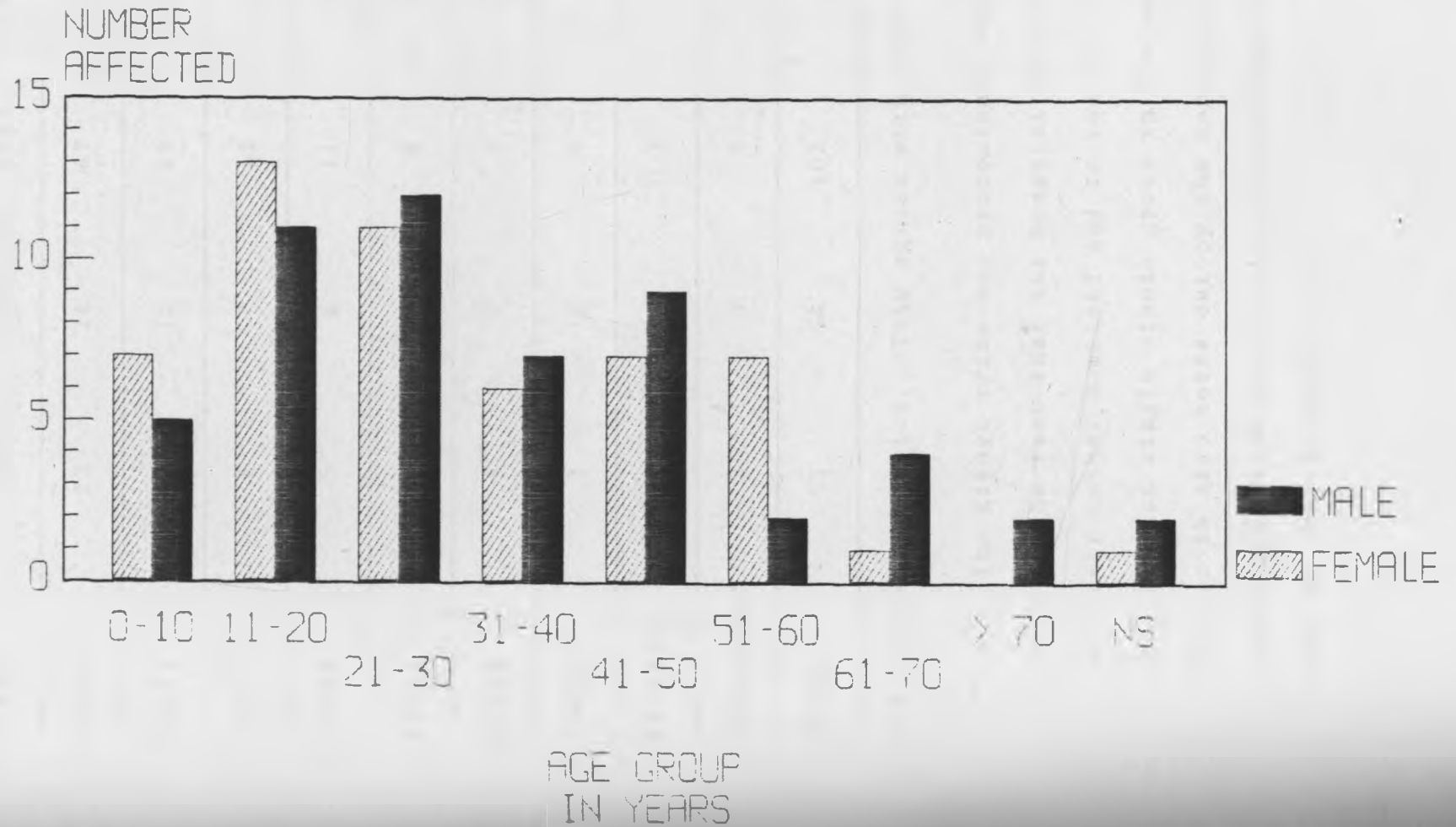


TABLE 2: DISTRIBUTIONS OF PATIENTS ACCORDING TO TRIBAL ORIGINS.

TRIBE	MALES	FEMALES	TOTAL	%
KIKUYU	23	24	47	43.90
KAMBA	4	10	14	13.08
LUO	6	7	13	12.14
LUHYA	5	6	11	10.28
KISII	4	2	6	5.61
OTHER	4	2	6	5.61
SOMALIS	3	1	4	3.78
KALENJIN	1	2	3	2.80
FOREIGNERS	3	0	3	2.80
TOTAL	53	54	107	100

The sex ratio was 1:1. This agrees with most recent studies.

The Kikuyu tribe was predominant but this may be due more to the fact that the hospital is situated in the heart of their tribal homeland and to the fact that they are also the largest single ethnic group in the country. The distance factor is also borne out by the Kambas being the next largest group (UKAMBANI being only a few kilometres away from Nairobi and of easy access.

TABLE 3

CLINICAL PRESENTATION OF THE 107 PATIENTS

	SYMPTOM	FREQUENCY	PERCENTAGE.
1.	DYSPHAGIA	98	91.59
2.	REGURGITATION	66	61.68
3.	WEIGHT LOSS	47	43.90
4.	CHEST PAINS	31	28.97
5.	EPIGASTRIC PAINS	26	24.30
6.	CHRONIC COUGH AND FEVER	13	12.15
7.	ANAEMIA	11	10.3
8.	FAILURE TO THRIVE	7	6.5
9.	RESPIRATORY DISTRESS	3	2.8
10.	ASTHMA	2	1.87
11.	STRIDOR	2	1.87
12.	VOICE CHANGE	2	1.87
13.	HEMATEMESIS	2	1.87
14.	MELENA STOOLS	2	1.87
TOTAL		107	100

In babies and infants regurgitation was the most common symptom (100%) while in adults the symptom of dysphagia was predominant 92%. Chest and epigastric pains, (retrosternal) ranked quite high in the list. These pains have always been felt to be due to reflux oesophagitis, chest infection or spasm. More recent work now points to a poor blood supply especially recovery of perfusion after spasm, a clinical situation akin to angina pectoris.

The characteristics of dysphagia in the 98 patients were as follows:-

- i. Dysphagia to both solids and fluids 47 (47.96%)
- ii. Dysphagia to solids only 36 (36.7%)
- iii. Dysphagia to fluids only 2 (2.04%)
- iv. Dysphagia progressed from liquids to both 3 (3.06%)
- v. Dysphagia progressed from solids only to both 10 (10.2%)

FIGURE 6

CLINICAL PRESENTATION
OF THE 107 PATIENTS

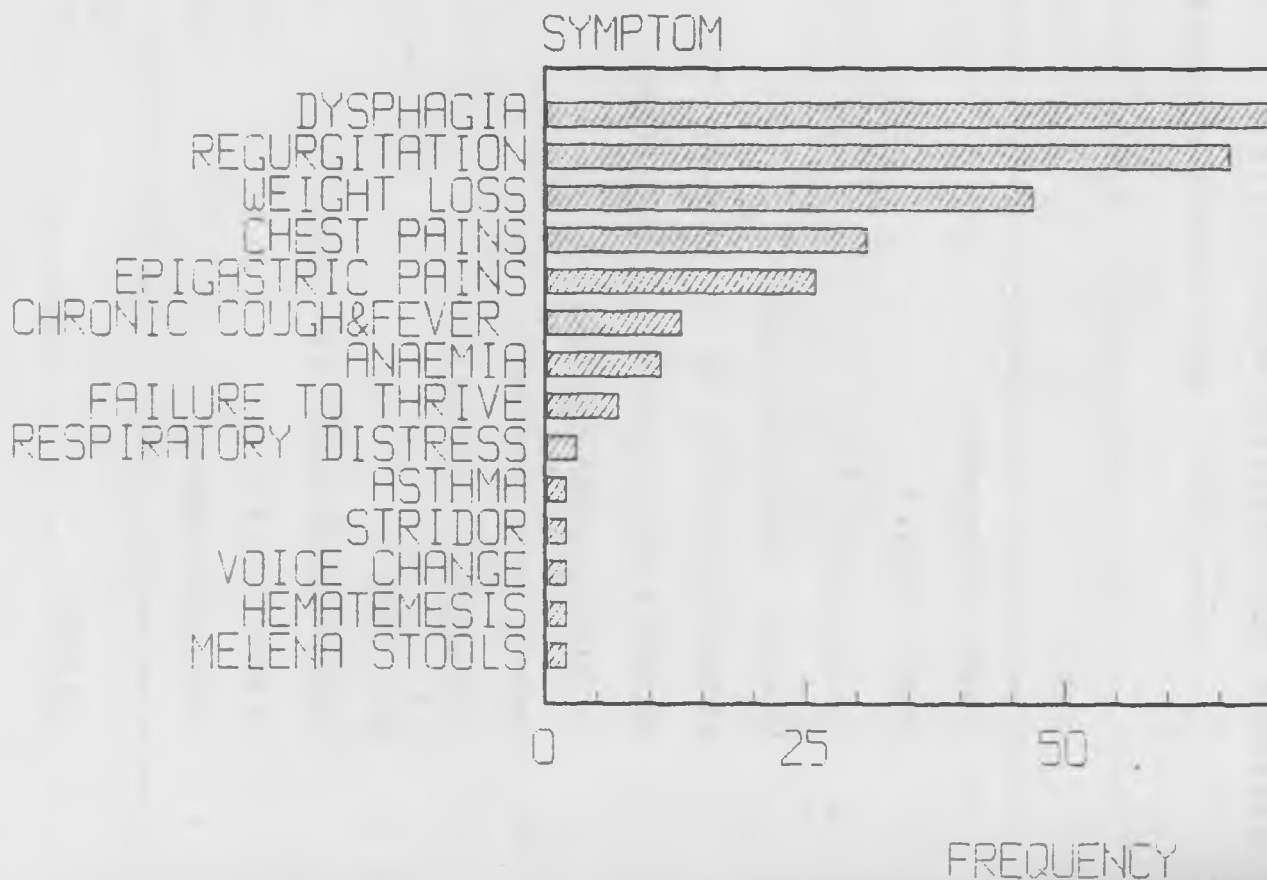


TABLE 4.

SOME COMMON CAUSES OF BENIGN DYSPHAGIA AS SEEN AT KNH BETWEEN 1974-1987.

AETIOLOGY	NO. OF CASES	PERCENTAGE
1. ACHALASIS CARDIA	107	45.53
2. OESOPHAGITIS	28	11.91
3. BENIGN OESOPHAGEAL STRICTURE	19	8.1
4. FISTULAE	18	7.66
5. EXTRAMURAL COMPRESSION **	10	4.26
6. MALLORY WEIZ SYNDROME	10	4.26
7. PHARYNGO-OESOPHAGITIS	8	3.4
8. NEUROPATHLES (INCLUDING DIABETIC)***	8	3.4
9. LARYNGEAL NODULES (2) AND POLYPS (4)	6	2.6
10. PLUMMER VINSON SYNDROME	6	2.6
11. SCLERODERMA	5	2.1
12. HIATUS HERNIA	5	2.1
13. BARRET OESOPHAGUS	5	2.1
TOTAL	235	100

-* Oesophagitis here denotes oesophagitis per se. Reflux traumatic or intubation oesophagitis and Barret's oesophagus are considered differently.

** Extramural compression resulted from causes such as goitres (2), lung fibrosis, Aortic aneurysm, lateral (ectopic) cervical thyroid, congestive cardiac failure and enlarged mediastinal nodes.

*** Neuropathies include diabetes mellitus; hemiplegia with paralysis of VIII, IX, XII cranial nerves; Raynaud's phenomenon and

FIGURE 7

COMMON CAUSES OF BENIGN
AS SEEN AT KN

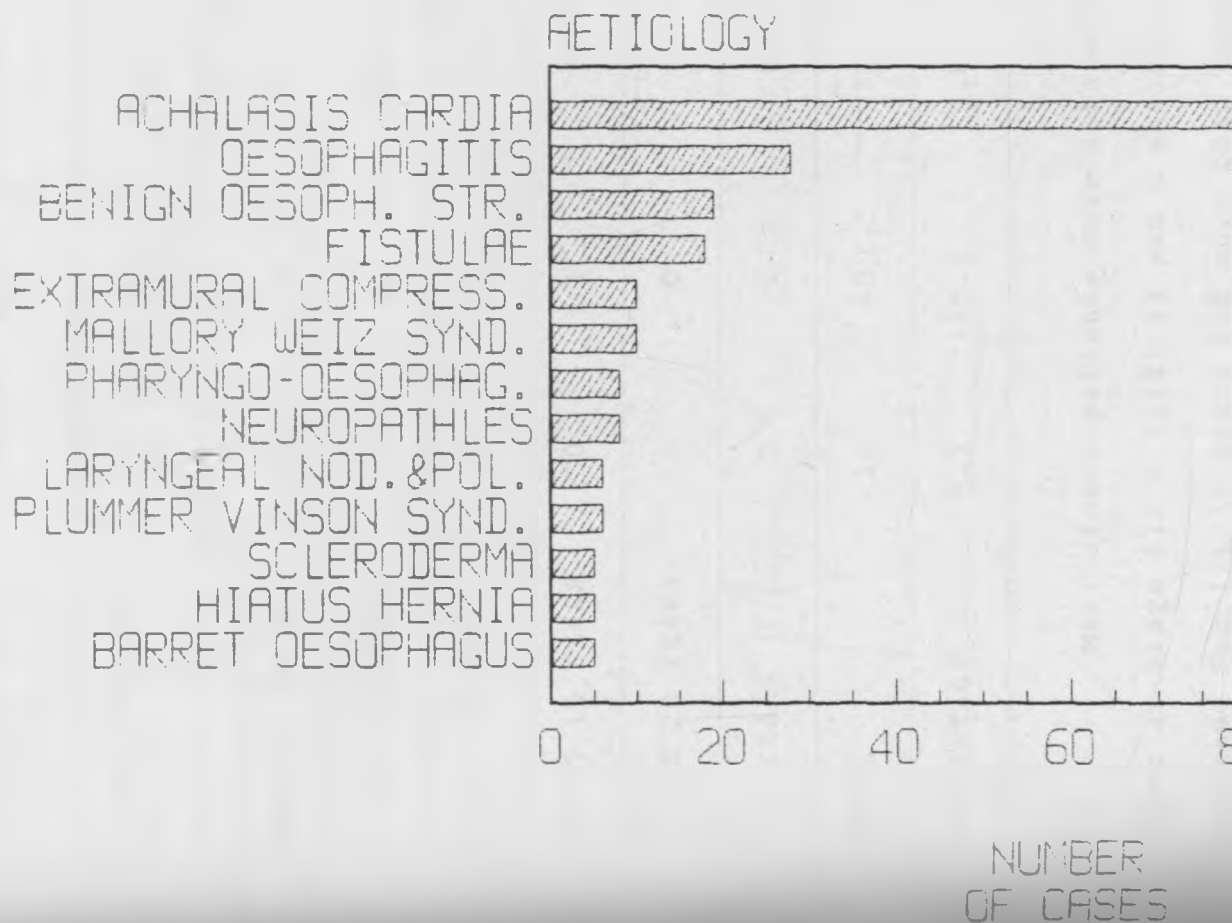


TABLE 5a: PATIENTS DISTRIBUTION ACCORDING TO DURATION OF SYMPTOMS IN RELATION TO STAGE OF DISEASE .

DURATION OF SYMPTOMS	STAGE I	STAGE II	STAGE III	STAGE III B OR IV	TOTAL
UNDER SIX (6) MONTHS	3	6	3	0	12
>6 MONTHS BUT BELOW 1 YEAR	0	2	1	1	4
1 TO 5 YEARS	7	25	22	13	67
5 TO 10 YEARS	0	9	6	5	20
10 TO 15 YEARS	0	1	1	0	2
15 TO 20 YEARS	0	0	0	1	1
>20 YEARS	0	0	0	1	1
TOTAL	10	43	33	21	107
PERCENTAGE	9.3	40.2	30.8	19.7	100

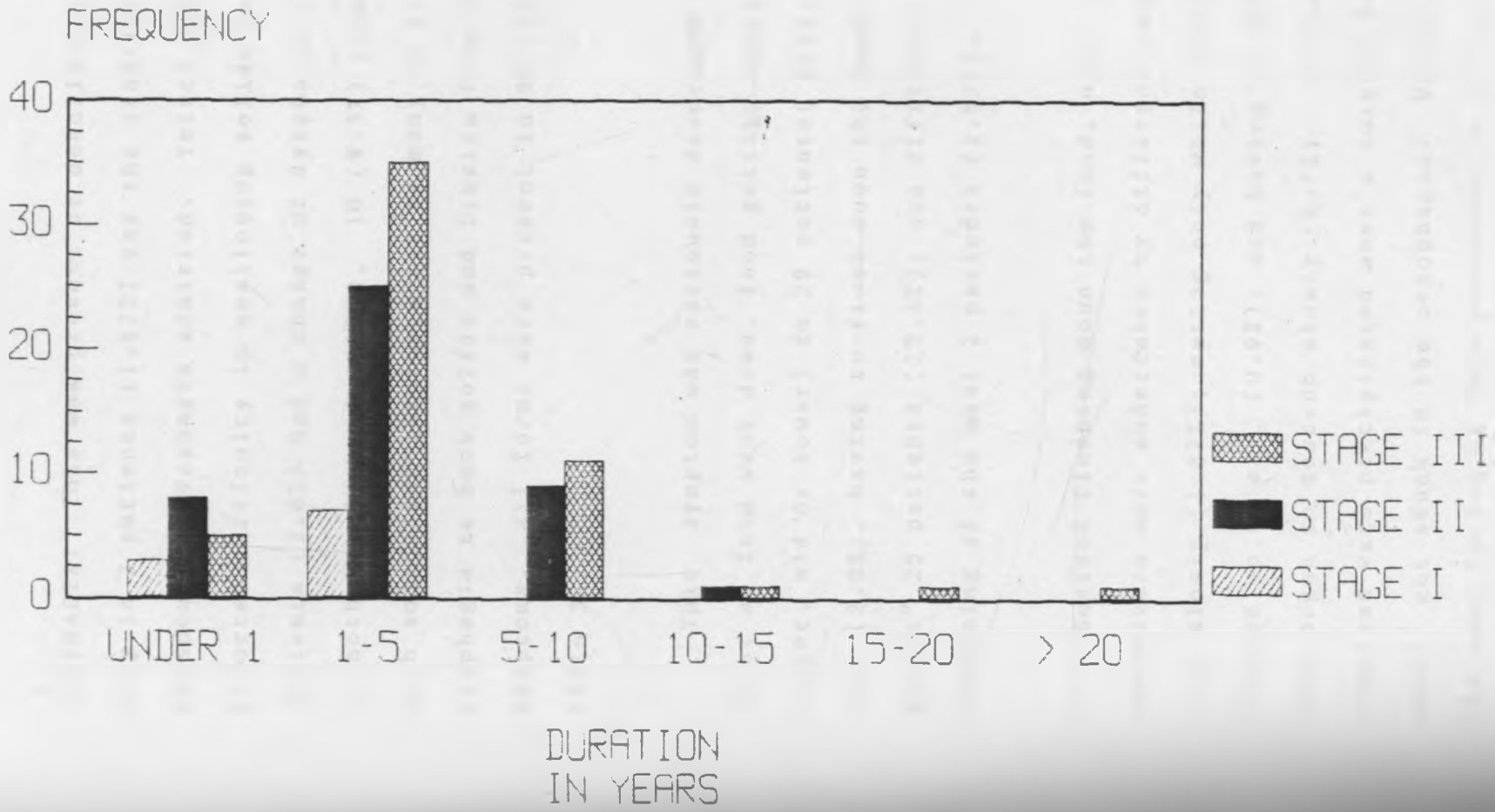
Most of our patients were seen at stages II and III (most at stage III & III B) 43 and a majority had had their symptoms for 1 to 5 years and more than three-quarters having had them for between one to ten years. This lateness should reflect on the outcome of treatment. Yet 59% of those operated obtained extremely encouraging results (very good to excellent) (2).

TABLE 5b

CLASSIFICATION ACCORDING TO DURATION OF SYMPTOMS AND STAGES OF DISEASES.

	STAGE I	STAGE II	STAGE III	TOTAL
UNDER 1 YEAR	3	8	5	16
1-5 YEARS	7	25	35	67*
5-10 YEARS	0	9	11	20
10-15 YEARS	0	1	1	2
15-20 YEARS	0	0	1	1
ABOVE 20 YEARS	0	0	1	1
	10	43	54*	107
PERCENTAGE	9.3	40.2	50.5	100%

FIGURE 8
DURATION OF SYMPTOMS



CLINICAL PRESENTATIONS (SYMPTOMS AND SIGNS).

DYSPHAGIA: This was present or described in several forms. Only in 2 patients (1.87%) was the classical symptom of paradoxical dysphagia admitted. Thirty six patients (33.6%) reported difficulty in swallowing solids only. Three patients (2.8%) had a change of dysphagia from liquids only to both liquids and solids, 10 (9.3%) from solids only to both solids and liquids while as many as 47 (43.9%) reported dysphagia to both solids and liquids from the start of symptoms. All forms were present in 98 cases (91.59%). See table 3.

This symptom was variously described as pain in the chest as food went down, food getting stuck in the chest (upper, mid or lower) in 29 patients (27%), slow passage of food (2.8%), having to flush down the food or provide "water escort" 25 patients (23.4%); and difficulty only at the beginning of the meal 2 patients (1.87%).

Besides flushing down the food, other interesting manoeuvres were undertaken by different patients: eating very slowly (1.87%); eating only while standing (2.8%), being propped up to eat, (0.9%), and having to belch before the food began to descend slowly (4.7%). In one case the symptoms were precipitated when a foreign body (a piece of meat) got stuck in the oesophagus. We did not come across the description of this presentation in our reading.

GRADING OF DYSPHAGIA.

In Grade I the patients eat but occasionally food gets stuck in the throat or chest.

Grade II patients eat soft food but live mostly on liquids or fluids.

Grade III patients can take only liquids.

Grade IV patients find it difficult taking even liquids but still retain some even if very little.

Grade V complete obstruction. This grading is more appropriate in carcinoma but we have applied this to our achalasia patients (60). The patients are distributed as shown. (Grade 0 denotes no dysphagia).

TABLE 6

GRADE	NO. OF PATIENTS	PERCENTAGE
GRADE I	18	16.8
GRADE II	42	39.3
GRADE III	30	28
GRADE IV	17	15.9
GRADE V	0	0
TOTAL	107	100

It will be noted that the bulk of the patient were 1 grade II and III. This means that they came in with fairl

REGURGITATION. This symptom was common among infants and babies (100%) and in adults this always accompanied dysphagia and this more than dysphagia led to consultation. In other words it was less tolerated than dysphagia per se. This symptom was present in 66 cases; in three adults this was only noted at night or whenever the subject was lying prone.

OTHER SYMPTOMS: Besides dysphagia 91.59% and regurgitation 61.9%, the other most prevalent symptom was weight loss 43.9%. This particular symptom of weight loss in babies and infants 6.5% was described as failure to thrive. This triad of dysphagia regurgitations and weight loss is considered diagnostic until proved otherwise. This symptom complex together with the radiographic and/or endoscopic findings are the hallmark of diagnosis (Adebo et al, 1980). Other symptoms present to a significant degree were: chest pain 29%, epigastric pains 24.3%, and chronic cough and/or signs of chest infection 12.1%. Others included anemia 10.3%, failure to thrive, "asthma, stridor, voice change, hematemesis, and melena stool 1.9%. Respiratory distress was the presenting symptom in three children (2.8%) while one patient's case was signaled by foul breath.

ASSOCIATED PROBLEMS/PATHOLOGIES: One patient had pulmonary tuberculosis as well as diabetes mellitus, two had achalasia and pulmonary tuberculosis and three had achalasia and diabetes mellitus.

Incidental findings were para-umbilical hernia 1 patient, poliomyelitis 1 patient, hypertension 2 patients, bronchiectasis 1 patient, peptic stricture 11 patients and pleural adhesion displacing oesophagus 2 patients.

Ten patients (9.3%) had previously been diagnosed and actively treated as duodenal ulcer cases and two of which had even undergone vagotomy and drainage. It is surprising the diagnosis of achalasia was not made during these two operations. May be the disease developed subsequently.

At surgery two patients were found to have entirely different pathologies, the one having a hiatus hernia while the other proved to be purely a case of reflux oesophagitis per se.

On the average there were 2-3 presenting symptoms per patient, 14 presenting one symptom only and up to 4 having five symptoms each.

TABLE 7.

For those who received treatment the interval between admission and surgery was short.

Under 1 month	60 patients.
1 to 6 months	33 patients.
6 months to 1 year	5 patients.
Beyond 1 year	2 patients.

Several factors are responsible for some patients staying for up to six months or more before surgery. These include breakdown of facilities, anemia and metabolic disorders or concurrent diseases.

OTHER PARAMETERS: Of the 107 analysed files, 93 were Christians, 9 Muslims and 5 Atheists. Sixty of the patients were married, 28 were single, 6 were either widows or widowers, 12 were children and there was one catholic reverend sister.

Seventeen admitted to taking alcohol only, 5 to tobacco smoking only, while 39 admitted to both smoking and alcohol intake. Forty six however denied smoking or taking alcohol.

INVESTIGATIONS:

Endoscopic findings. Most endoscopies did not reveal any abnormal mucosa. The result of endoscopic findings are shown in tables 8 and 9 .

Though biopsies were taken in 36 of the 68 endoscopies results were available only in 15 patients. Most of the others could not be traced. Of these only two revealed carcinoma while the rest showed normal mucosa with inflammatory cells, Barret's oesophagus, leukoplakia 1, gastritis 5, multiple ulcerations 2.

Barium meal/swallow. This was the most frequently used investigative procedure. It was carried out in 94 of our patients (87.9%) and only in 2 patients were the findings doubtful.

TABLE 8: SHOWING FINDINGS AT ENDOSCOPY.

FINDINGS	NUMBER
1. NORMAL MUCOSA + POOL OF FLUID/FOOD (4)	23
2. INFLAMED/PALE MUCOSA	20
3. SUSPICIOUS MUCOSA	3
4. DILATED LUMEN	24
5. NODULES AND POLYPS	6
6. BLEEDING VARICES	1
7. TIGHT BUT NEGOCIABLE CARDIA	30
8. COMPLETELY TIGHT CARDIA ADMITTING ONLY A SLIM STORZ SCOPE	1

TABLE 9: SHOWING HISTOLOGICAL FINDINGS OF 36 BIOPSIES TAKEN AT ENDOSCOPY.

RESULT	NO. OF CASES
BENIGN POLYPS	4
NON-SPECIFIC INFLAMMATORY CHANGES	6
BARRET OESOPHAGUS	3
MULTIPLE ULCERATION (NON-SPECIFIC)	2
CARCINOMA OESOPHAGEAL MUCOSA	2
LEUKOPLAKIA	2
SCLERODERMA	1
NO RESULTS	16

Plain x-ray: This was contributory only in four patients (3.7%). Often they added very little to the clinical diagnosis. Air-fluid levels were not seen in any of our patients. In these four the enlarged mediastinum gave the impression of aortic aneurysm and it needed an angiogram and an ECG in each case to rule out cardiopathy.

Of all the cases clinically diagnosed as achalasia only two were found at surgery to have different pathologies. Five patients were not confirmed as they were lost to follow up and two were deferred because of pregnancy.

Muscle strips obtained at myotomy or resected with specimens (lower third of oesophagus) were also found to have the following:-

TABLE 10: SHOWING RESULTS OF OESOPHAGEAL WALL (MUSCLE) BIOPSY.

RESULT	NO
ABSENCE OF GANGLIA	25*
FEW GANGLIA	14*
INFLAMMATORY CHANGES	10
CARCINOMA	2
NO RESULTS	17
TOTAL	68

*Thus only 39 cases were histologically confirmed for achalasia. This do not include the two cases of carcinoma whose muscle strips showed scanty ganglia.

PRE-ADMISSION PROCEDURES: These were reported as endoscopic dilatations or previous myotomy by abdominal approach. Otherwise the distribution was as shown on table 11 below,

TABLE 11: SHOWING MULTIPLICITY OF PRE-ADMISSION PROCEDURES:

NUMBER OF OPERATIONS PER PATIENT	NUMBER OF PATIENTS
NO OPERATIONS	88
1 OPERATION	13
2 OPERATION	5
3 OPERATION	1

88 patients had no surgery prior to admission. 13 had one operation each, 5 had 2 operation each 1 had 3 operations.

HELLER'S OESOPHAGOMYOTOMY.

From our analysis we noted that of the 107 patients three did not have any form of therapy, three declined surgery but accepted endoscopic dilatation, and one patient aspirated at intubation and when fully recovered then refused surgery and was lost to follow-up. Of the 100 patients who consented to surgery.

4 patients had dilatation only, then were lost to follow up.

2 patients had their oesophagomyotomy converted to gastro-oesophagectomy and anastomosis.

10 patient under went preoperative dilatation attempts before myotomy was resorted to.

21 patients underwent postoperative dilatation 10 of which had one session each, 1 had three sessions, and 2 had as many as 4 sessions each.

63 had Heller's modified myotomy only.

APPROACH.

1 patient had two abdominal approach of oesophagomyotomy and never improved. He was finally relieved by thoracic oesophagomyotomy.

4 patients had each undergone myotomy by abdominal approach. These were also finally relieved by thoracic approach.

No patient had an abdominal approach subsequent to the thoracic approach.

27 patients had only abdominal approach of Heller's operation; 71 had Heller's operation via thoracic approach in 10 of which an antireflux procedure was performed. Five of the ten had had previous myotomies by the abdominal approach.

Four cases proved particularly difficult to manage: One was abandoned when the muscle could not be resected from the mucosa. In one the peptic stricture was so tight and the patient so wasted a feeding gastrostomy was performed.

In 2 of the patients the oesophagus were resected and gastro-oesophageal anastomosis performed. Both had adenocarcinoma of the lower oesophagus.

LENGTH OF INSISION: The longest incision obtainable from our records is 16 cm and the shortest 3 cm with the average being 10.1 cm. The incision was carried into the stomach fundus over 1.9 cm on the average. The information about the total length of the incision was available for 44 patients. In 34 files only was the length of incision distal to the cardio-oesophageal junction given.

As mentioned elsewhere the majority of the patients seen were with stage II or stage III disease. It is encouraging however to note that up to 59% obtained very good to excellent results. Almost all of those with poor or failed procedure (18 out of 20) were again in stage III and IIIB.

Seven patients were not operated despite well established diagnosis. The reasons for this included: pregnancy 2 patients, refused surgery 1 patient, absconded 1 patient, managed conservatively 2 patients, lost to follow up (after endoscopy) before definitive surgery 1 patient.

FOLLOW UP: Postoperatively we evaluated our patients on the triad indices of swallowing, roentgenographic evidence (barium swallow) and weight gain. The overall result was denoted as:-

RX if no therapy was administered

R0 if procedure failed and required repeat or change.

R1 if symptoms persisted and required palliative procedure.

R2 if few symptoms requiring only vigorous medical management persisted.

R3 if good enough to rely on dietary and other type of advice.

R4 excellent result presenting no symptoms at all.

The distribution of patients according to outcome of treatment is shown on table 12 below.

THICKNESS OF MUSCLE: The thinnest recorded hypertrophy was 1.5 cm and the thickest 4 cm giving an average of 2.67 cm.

OUTCOME OF SURGERY.

TABLE 12 SHOWING OUTCOME OF TREATMENT ON 100 OPEARATED PATIENTS.

QUALITY OF RESULTS		STAGE I	STAGE II	STAGE III	STAGE IIIB	TOTAL
R4	EXCELLENT	6	18	3	1	28
R3	VERY GOOD	1	9	14	7	31
R2	GOOD	1	10	5	5	21
R1	POOR	1	1	6	4	12
R0	FAILED					
	PROCEDURE	0	0	5	3	8
RX	NO SURGERY OR					
	OPERATION					
	DEFERRED	1	5	0	1	7
TOTAL		10	43	33	21	107

FIGURE 9

SHOWING OUTCOME OF TREATMENT
ON 100 OPERATED PATIENTS

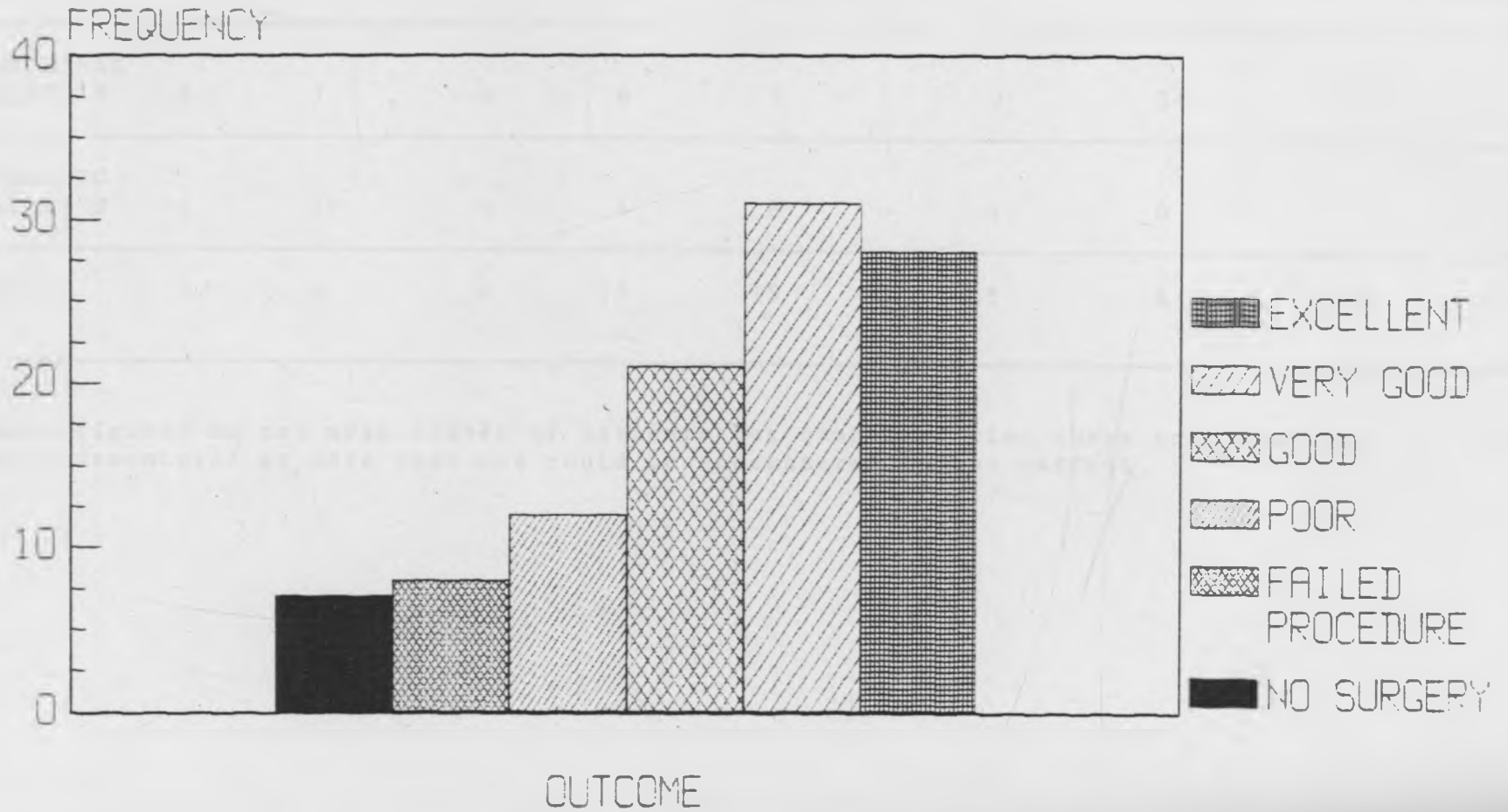



TABLE 13: COMPLICATION OF OPERATIVE MANAGEMENT

	WOUND SEPSIS	FAILED PROCEDURE	REFLUX	STRICTURE	PERFORATION MUCOSAL	EMPHYEMA	PERITONITIS	PNEUMONIA	HIATUS HERNIA	
ABNOMINAL HELLER'S	3	7	4	8	7	0	3+	3	2	37
THORACIC HELLER'S	1	1+	4	4	8	1	0	1	1	21
TOTAL	4	8	8	12	15	1	3	4	3	58

These figures do not mean number of patients but number of time these complications were encountered as more than one could be encountered in one patient.

FIGURE 10

COMPLICATIONS OF OPERATIVE MANAGEMENT



In the early postoperative period success was based on symptoms and clinical signs. Ideally the patients were expected to have a barium swallow before discharge. This was often abandoned due to frequent breakdown of facilities. This however was expected to be done by the 1st postoperative visit to the out patient clinic. This was not always done due to the same reason given above. Sixty patients were seen during the few postoperative months up to 9 months only, 17 were seen for about 1 year, 5 were seen over a period of two years, 1 for three years, 2 for four years, 1 for seven years and only 1 seen over ten years period.

Complications of the operations are shown on table 13 (fig 10) for both abdominal and thoracic approaches.

The rest were never seen after discharge. Most were lost to follow up after the first visit to the clinic and may be continued at their district hospital if symptoms were mild.

Aetiologic factors:

Incidence: The exact incidence has varied widely even within the same region. The exact local incidence is still unknown due to insufficient reporting and diagnosis. Of the benign dysphagia traced over the period of study achalasia accounted for 43%. This is just indicative of the magnitude of the problem.

Age and Sex incidence: Thiolding (1921) found that males developed symptoms between the ages of 30 and 40 while female developed theirs much earlier (20 to 30 years of age). There is said to be a slight male predominance.

More than 50% of our cases were under 50 years. Our youngest patients were 2 months old while the oldest were 74 and 75 years old. Newborn cases have been reported by other authors: Vinson 1945, Howard 1953 (48,71), Judson 1975 (11), and Asch et al 1979, reported achalasia in a 3 month old baby (5). This compares well with our series where 2 patients were operated at 2 months of age. Similarly Payne et al obtained 18.5% under three months. Several other series have been reported (54,55,56,57).

The sex ratio has been variable. Some authors give a Male:Female ratio of between 2:1 and 3:1. In our own series the sex ration was 1:1 but in the earlier age groups (below 30 years) females predominate while above this age males predominate. An earlier report had however reported 3:2 (40), similar to Ellis et al who gave a female predominance of 3:2 (25). But later publications by Ellis, Rai, Robin and Moore gave a 1:1 ratio (57).

We did not find any familial tendency in our series though this is widely reported (Kelpatrick and Miles, 1972, Nagler et al, 1963, Cloud et al 1966; Westley et al 1975, and Dayalan et al 1972) (14,38,48,61,71,73). The role of other aetiological factors is less clear.

Neuropathies: We found quite a number of neuro-pathies associated with achalasia. There were 4 cases of diabetes, 1 case of Raynaud's phenomenon and one patient presented with paralysis of VIII, IX,X,XII cranial nerves; one cases was reported following head injury.

Other agents like alcohol, smoking, cold foods, toxins and parasites and even trauma have been implicated but the distribution of our patients did not point to any conclusive effect.

SYMPTOMS: The paradoxical dysphagia has hardly been observed (only two of our patients admitted to this dysphagia to liquid and not be solids). But most authors hardly pay much attention to this "discrepancy". So much is the symptom merely passed off as dysphagia that its nature is given little importance.

The issue of duration is more intriguing. The declared "start of symptoms" is rather the moment when the symptoms become very bothersome. There has been controversy regarding the cause of retrosternal pains. While many thought it was due to spasm recent work seems to indicate this is due to ischemia resulting from delayed recovery of anoxia the consequence of precarious blood supply (15,35,33).

Weight loss was noted in 43.9% of our patients (47/107) and this may be due to fear of dysphagia, chronic blood loss from resultant oesophagitis and regurgitation. The latter was present in 61.7% of our patients.

Many authors place their faith on the triad symptoms of dysphagia, regurgitation and weight loss (20,57). With combined roentgenographic findings the diagnosis is accurate to a high degree (56,17,43) but occasionally these symptoms are reproduced in malignancy and other lesions and only upper gastrointestinal tract endoscopy helps to differentiate these conditions (16,39,78). In the absence of manometric studies we were left only with surgery as a means of confirming our diagnosis.

Despite the "relatively short" duration of symptoms declared by our patients the stage of disease was fairly advanced in most of them: 40.2% in stage II and 50.5% in stage III. This was surprisingly higher than reported in most series (2,23,64,51,24,57,25,33).

We however encountered some symptoms which have not been reported in the literature. These included: patients having to be propped up or stand up to facilitate swallowing, eating very slowly, belching before food passed into the stomach and initial dysphagia only (at start of meal only). If we had any doubt about the absence of classical dysphagia the fact that most patients needed to flush down their food or "provide water escort" should dispel them.

It is gratifying to note that despite the large number of patients arriving in stages II and III the outcome of treatment was not as disappointing as expected. This compares well with other series (24,51,57). Our methods of treatment like those of other authors varied. Like Von Mikuliez (1904) it was necessary to do an occasional gastrostomy but without retrograde dilatation. Our dilatations were done with metallic storz dilators. This procedure was mainly to provide temporary palliative relief or to relieve residual symptoms after the operative procedures. Notably this was applied to pregnant patients who had to undergo surgery after delivery. We do not believe

in this as a definitive measure. The force (pressure) needed to overcome neurogenic or muscular obstruction is too high to be innocuous. Extremes of fibrosis may require resection and anastomosis or reconstruction (46,57,55,67).

Our main option of definitive treatment was cardio-oesophagomyotomy not as practised by Ernest Heller in 1913, but as modified by A.Zaaijer. The classical Heller's procedure was practised only in two patients due to extensive fibrosis from previous myotomies.

Complications were unrelated to the method or approach. The most frequent complications were those of failure to relieve symptoms, reflux and mucosal perforation: Persistence of symptoms is thought to be due to oesophagitis, or concomittant hiatus hernia. Failure of Heller's operation may be due to inadequate myotomy incision (2,24,57,25) or too advanced oesophagitis or gastroesophageal sphincter incompetence resulting from overzealous myotomy.

Certain issues have always been the object of controversies as far as management of achalasia is concerned. Approach has always raised much dispute. We feel the thoracic route still remains the best as it helps us to assess properly the entire subaortic oesophagus which is the site of so much pathology. Moreover in the absence of manometry it is essential to perform an extensive myotomy.

Malignancy in achalasia is commonest in the middle third and this cannot be assessed from below. Because of this possibility of malignant change, and even the co-incidental presence of malignancy, endoscopy becomes a mandatory preoperative investigative procedure.

There is not much agreement on the length of the extramucosal myotomy incision. In most series the average of 6-10 cm is reported (24,51,57) but extensive incision up to the inferior pulmonary vein or Aortic arch may help relieve generalised spasm missed in the absence of manometric studies. The length of incision into the stomach however provokes more controversies. While we advocate a few millimetres it has been argued that persistence of dysphagia may be due to inadequate incision of lower oesophageal sphincter (2,11,24,48,51,52,57,64,71). We believe this distance distal to the spincter is enough to relieve symptoms without disturbing the hiatus.

Kramer, Harrison and Donaldson feel achalasia is a transition stage to diffuse spasms hence the need for lengthy myotomy (12,15,23).

One issue over which a lot of ink has flowed is whether all oesophagomyotomies should be accompanied by antireflux procedures. In our series this was not practised routinely and only in 10 patients were they resorted to.

This procedure had consideration only in advanced stages (2) or in cases where the hiatus had been disturbed by previous manoeuvres or concurrent hiatus hernia. The great authorities on achalasia and hiatus hernia, do not quite agree on the need for antireflux procedure. Ellis and associates (24,25,57) feel this should be done to prevent reflux oesophagitis. Others like Bersley (67) feel the hiatus has to be dissected well to achieve a good myotomy and hence an obligatory antireflux procedure. Ellis and Coworkers (67) feel a precise myotomy is all that is required and that antireflux procedures may even lead to obstruction. They claim to have 92% success at primary repair with only 3% reflux. On the contrary Belsey reported 67% success at primary repair with 22% reflux and when they combined myotomy and fundoplication no reflux was observed in 116 patients. Murray (1980) advised complementary funduplications in those cases which have a high risk of developing reflux and in those which were already complicated by reflux (51). Muscle biopsy offered gratifying confirmation though the absence of results tainted this joy. A large number was noted to have just inflammatory changes (10 cases) or reduced ganglia (14 patients).

Reoperation has been noted to have poor results. Those undergoing reoperation were mainly those who had had Heller's operation via the abdominal approach (6 patients) and those in whom the diagnosis had been inadequate or mistaken (2 patients). Contrary to the report by Ellis, Crozier and

Walkins (24) all our repeat operations by thoracic approach yielded good result. Previous dilatation is known to affect the outcome of myotomy and we strongly feel such patients may have traumatic oesophagitis which can be vigorously treated medically. Our results confirm the findings of others (2,11,52,57,64).

Complications were more common with the abdominal approach. Sepsis was more common but incidence of mucosal perforation seemed to be equal by both ways.

A few cases (5 patients) where postoperative Barium swallows were done showed oesophagus reduced in size but never returned to original dimension. This compares with other reported series (2,53).

COMMENT:

Despite the problems of oesophagomyotomy there is no suitable alternative and modified Heller's operation still offers the best treatment of achalasia at whatever stage the patient is first seen.

With manometry, pH studies and endoscopy well applied our results should be much improved and we should diagnose more patients early enough to give the best results.

Though there were only four cases (3.7%) of carcinoma the mucosal changes were enough to convince us that achalasia remains a potentially malignant condition. This percentage (3.7%) compares well with world wide figures of 3-10%. These patients require continuous endoscopic follow as myotomy does not halt the process of malignant change.

REFERENCES

1. ADAMS C.W.M., BARIN R.H.F. AND TRDUNCE JR.
Ganglion cells in Achalasia of the Cardia. Virchow's
Archives (Pathological Anatomy) No. 372 pp 75-79, 1976.
2. ADEBO et al.
oesophagomyotomy for achalasia of the oesophagus. Experience
at University College Ibadan
East African Med. Journal Vol.57 No.6, 1980
3. ALLISON P.R.
Hiatus Hernia, Annals of surgery Vol.178 p. 223, September
1973.
4. ANDERSON J.W.
Fibers and Health. American Journal of Gastroenterology.
Vol.81 No.10 1986.
5. ASCH M.J.
Oesophageal achalasia, diagnosis and cardiomyotomy in newborn
infants. J.Ped. Surg. 9(6) 911-2, 1974.
6. BARNES L.M. et al.
Pemphigus vulgaris involving the oesophagus Dig. I Sci Vol.32
No.6 June 1987.

7. BAROUR SIGUGEIRSSON et al.
Acute thoracic inlet obstruction in achalasia with adenoid cystic and squamous cell carcinoma. The Ann. Thorac. Surg. Vol.40 No.5 516-518, Nov. 1985.
8. BELLO L.T. et al.
Achalasia (cardiospasm), report of a case with extreme and unusual manifestation. Ann Internal Med.32: 1184,1950.
9. BRAND D.L.: YLVISAKER J.J. GELFAN DM AND POPE C.E.I.
Regression of columnar oesophageal epithelium (BARRETT) after antireflux surgery. New England J.Med.302, 844-5, 1980.
10. BUNTAN W.L., PAYNE W.S. AND LYNN H.B.
Oesophageal reconstructions for benign diseases; a long term appraisal. Ann Surg. 46: 76,1980.
11. CARTER R. AND BREWER L.A.
Achalasia and oesophageal carcinoma. Studies in early diagnosis for improved surgical management. Annals of surg.130: 114, 1975.
12. CASSELLS R.R., BROWN A.C., SAYRE C.P. AND ELLIS F.H.
Achalasia of the oesophagus, Pathologic and aetiologicial considerations. Ann. Surg.110: 474; 1964.

13. COHEN S.C., LI. T.C., AND PETRO R.
An ecologic study on diet and cancer in china. Natural cancer institute monograph (In press 1987.)
14. CLOUD D.T., WHITE R.F., LINKER I.M. AND TAYLOR L.C.
Surgical treatment of achalasia in children J.Ped. Surg.112; 137, 1966.
15. COHEN S.C.
Motor disorders of the oesophagus. N.Engl. J.Med.301: 184-192, 1979.
16. COOPER B.T.
Barret oesophagus and colon cancer. Lancet November 1978 (p. 1084)
17. DAVEY
Companion to surgery in Africa. 2nd edition edited by Adelola. Churchill livingstone chapter 20.
18. DENT R.I
Proposed joint survey of gastrointestinal cancer. American J. Gastroenterol Vol. 82, 74. 1987.
19. DOHERTZ D.P.O. et al
The place of surgery in the management of amyloid disease. Br. J. Surg. Vol.74 No.2. February 1987.

- 20 DOLMANS WMV, I.MBAGA AND D. MWAKYISA.
Evaluation of 140 proximal G.I. Endoscopies East Afr. Med. Journal vol. 56 No.12, 1979.
21. EASTRIDGE, PATE AND MANN.
Lower Esophageal Ring. Experience in treatment of 88 patients. The Annals of Thoracic Surgery Vol.37 No.2 Feb. 1984 pp 103-107.
22. ELLIS, HAROLD.
Clinical Anatomy 6th edition Blackwell Scientific Publications Oxford 1976 pp 44-49.
23. ELLIS F.H. et al.
Oesophagectomy for oesophageal achalasia. Experimental, Clinical and Manometric aspects. Ann. Surg. 166: 640, 1967.
24. ELLIS F.H., CROZIER R. AND ALTON WATKINS.
Operation for Oesophageal achalasia; Results of Oesophagomyotomy without antireflux operation. J. Thoracic Cardiovascular Surg. Vol.88 No.3 pp 344-51 Spet. 1984.
- 25 ELLIS F.H., CROZIER R.E., AND GIBB S.P.
Reoperative achalasia surgery. J. thoracic surgery. Vol.90 No. 5 pp 859-865, 1986.

26. FASANA F.
Textbook of Medical Embryology (Normal and abnormal development) chapters 17 and 20. pp 185-191 and 221-234.
Kenya Literature Bureau. 1980.
27. GATEI D.G., ODHIAMBO P.A., MURUKA F.J.
Retrospective Study of Cancer of the Oesophagus in Kenya.
Cancer research No.303 Vol.8 Feb. 1978.
28. GILLEN P., KELLING P. AND BYRNE HENNESSY..
Invariable consequence of Reflux. Br. J. Surg. Vol.74 p 774.
1987.
29. GRAYRILU D.
Aspects of Oesophageal Surgery. Current problems in Surgery.
12(10): 29-34. 1975.
30. GUSTRA P.E., KILLORAN P.J. AND WASGATT W.N.
Acute stridor in achalasia of the oesophagus. American J.
Gastroenterol 60: 160, 1973.
31. GUYTON A.C.
Disorders of swallowing and of the oesophagus. Medical
physiology. 6th edition. W.B. Saunders & Co. Philadelphia.
Chapter 60 p. 827.
32. HANKINS JR. AND MCLANGLIN J.G.
The association of carcinoma of oesophagus and achalasia. J.
Thoracic and Cardiovascular surgery 69: 355, 1975.

33. HAINSWORTH J.P.
The danger of home brewing, oesophageal rupture. Br.J.
Surg. Vol.74 No.2 Feb. 1987.
34. HENDERSON R.D.
Dysphagia complicating hiatus hernia repair. J. Thorac.
Cardiovasc. Su g. Vol.88 No.6, 1984.
35. HOSKIN S.W. AND JOHNSTON A.G.
What happens to oesophageal varice after transection and
devascularisation. Surgery Vol.101 No.5. 1987.
36. JARMO A., SALO AND Kai V.ALA-Kulju.
Congenital cyst in adults. The annal of thoracic surg.
Vol.44 No.2, Aug. 1987.
37. JEFFREY et al.
Airway burns following aspiration of microwave heated tea.
Chest Vol.90 No.4 pp 621-627, oct. 1986.
38. JUDSON G. RANDOLP.
Achalasia of the oesophagus. In peadiatric surgery, edited
by Mark Ravitch J.M. publication. Chicago, 1979 Vol pp
489-490.
- 39 JUST-VIERA J.O. AND HAIGHT L.
Achalasia and carcinoma of the oesophagus. Surgery gynecol.
obst. 128: 1081, 9169.

40. KAMDAR H.H., ODHIAMBO P.A., KARIUKI J.N. AND OTSYULA B.O.
Achalasia of the oesophagus. Proceedings of the association of surgeons of East Africa, 1986 pp 87-88.
41. KERR R.M., OTT D.J., Wu W.C. AND WART B.W.
Pneumatic dilatation as a method after myotomy Amer J. Gastroenterol Vol.82. Jan 1987.
42. KING D.M. AND STRICKLAND B.
An unusual cause of acute thoracic inlet obstruction Br. J. Radiol 52: 910, 1979.
43. LADAPO F.
The radiology of achalasia of the oesophagus. J.Nig Med. Association 8: 207, 1978.
44. MACKENZIE et al.
Oesophageal Ischemia in Motility Disorders associated with chest pain. The Lancet No. 8511 pp 592-596 10th Sept. 1988.
45. McLEAN R.D.W., STEWARD C.J. AND WHYTE D.G.C.
Acute Thoracic inlet obstruction in achalasia of the oesophagus. Thorax 36: 456, 1976.
46. MERCER C.D. AND LUCIUS D.H.
Surgical Management of peptic oesophageal stricture, 20 years experience. J. Thorac cardiovasc surg. Vol.88 No.6, 1984.

47. MISIEWICS J.J., WALKER S.L., ANTHONY P.P. AND GUMMA J.W.P.
Achalasia of the cardiac. Pharmacology and Histopathology of
isolated cardiac sphincter muscle from patients with and
without achalasia Q.J. Med. 149: 17-30, 1969.
48. MOAZAM F. AND RODGERS B.M.
Infantile achalasia. Brief clinical report. J. Thoracic
and cardiovasc. Surgery 72(5) 809, 1976.
50. MULLEN D.C., YOUNG W.G. Jnr. AND SEALLY W.C.
Results of 20 years experience with oesophageal replacement
for benign disorders. Ann Thoracic surgery. 5: 481, 1968.
51. MURRAY et al
Selective application of fundoplication in achalasia. The
annals of Thoracic surgery Vol.37 No.3 March 1984.
52. NEMIR P. AND FROBES A.S.
The modified Heller's operation for achalasia of the
oesophagus. Surg. Clin. North America 42: 1407, 1962.
53. NEMIR P. WALLACE AND FALLAHNEDAEL M.
Diagnosis and management of Benign diseases of the
oesophagus. Curr Probl in surgery. Year Medical
Publications, 1975.

54. OHSHIWA H, YANG H., BOURGADE, CHEN J. AND BORSHI.

A correlative study in urinary excretion of Nitroso compounds and oesophageal and liver cancer mortality in China. Natural Cancer Monograph (in press 1987).

55. ORRINGER M.B.

Transhiatal oesophagectomy for benign disease. J. Thoracic. Cardisvasc surgery Vol.90 No.3 pp 649-655 Nov. 1985.

56. OSLEN A.M. AND PAYNE W.S.

Motor disorders of deglutition. Ann thoracic surgery Vol.40 No.5 pp 516-518 Nov. 1985.

57. PAI G.P., ELLIS R.G., RUBIN J.W AND MOORE H.V.

Two decades of experience with modified Heller's myotomy for achalasia, review of 36 cases. Current surgery Vol.44 No.1 Jan/Feb., 1987.

58. PASCAL R. AND CLEARFIELD H.R.

Macroepidermoid (adenosquamous) carcinoma arising in Barret oesophagus. Dig. Di Sci. Vol.32 No.4, 1987.

59. PAYNE W.S. AND ELLIS F.H.

Aesophagus and Diaphragmatic Hernias. Motility disturbances. Principles of Surgery, Schwartz 4th 90. Vol.2 Chapter 25 pp 1068-74.

60. POSTLETHWAIT R.W.

Neurogenic disturbances. Chapter 3. Surgery of the oesophagus. 1st edition appletin - century grafts. New York. 1983.

61. POWEL R.W.

In swenson's ped. surgery edited by Roffenspergy 4th edition. Chapter 66/67 pp 495-501. Appleton-Century Grafts N.Y.

62. ROTH J.L.A.

Achalasia and other motor disorders. In gastroenterology. Ed.H. Bochus. W.B.S. Company p 183, 1974.

63. SARR M.G., HAMILTON S.R. AND MARRONE G.C.

Barret oesophagis. It's association with adenocarcinoma in patients with symptoms of gastroesophageal reflux. AM. J. Surg. 149: 187, 1985.

64. SARYANNIS C. AND MULLARD K.S.

Oesophageal myotomy for achalasia of the cardia. Thorax 30: 539, 1975.

65. SCHWARTZ S.I. AND STORER E.

Dysphagia, manigestation of gastrointestinal disease. Principles of surgery. 4th edition Vol.2, pp 1027-1028. McGrawhill Book Company.

66. SIMON J.N.L. et al.
Menetrier's diseases and gastric carcinoma. Journal R.C.S.
Edinburgh Vol.32 No.3 June 1987.
67. SKINNER D.B.
Myotomy and achalasia. Editorial. The annals of Thoracic
surg. Vol.37 No.3 March 1984.
68. SMART H.L. et al.
Twenty-four hour oesophageal acidity in achalasia before and
after pneumatic dilatation. GUT Vol.28 No.7, July 1987.
69. SMITH R.R.L., BOITNOTT, HAMILTON S.R. AND ROGERS E.L.
The spectrum of carcinoma arising in Barret Oesophagus.
Clinicopathologic study of 26 patients. The American Journal
of Pathology Vol.8 No. , 1984.
70. STARNES V.A., ALTINS R.B., BALINGER S.F., AND SAWYERS J.L.
Barret oesophagus, a surgical entity. Current surgery
Jan/Feb Vol.42 No.1, 1985.
71. TACHOVSKY et al.
The surgical approach to oesophageal achalasia in children.
J.Ped. Surgery 3(2) 226, 1968.

72. TAM B.J.K. AND DIAMANT.

Assessment of the neural effect in a dog with Idiopathic megaoesophagus. Dip. D.Sci, Vol.32 No.4 p 70, 1987.

73. VAUDHAN W., HURT J. AND WILLIAMS L.

Familial achalasia and pulmonary complications in children. J. Ped. Surg. 1: 407, 1973.

74. WANKYA B.M. et al.

Upper G.I. Ednsopic experience at K.N.H. East Africa Med. Journal Vol.56 No.12 December, 1979.

75. WATEL C. AND CAHIL.

The right approach to carcinoma of the cardia and lower oesophagus. Annals of the R.C.S. of England. Vol.69 pp 214-216, 1987.

76. WAY L.W.

Oesoophagus and Diaphram. In current sugical diagnosis and treatment Chapter 21. Medical publication Losaltl, california.

77. WYATT G.M. et al.
The malignant potential of crohn's disease. Ann. R.C.S.
Engl. Vol.69, 1987.
78. WYCHULLIS A.R., WODLAM G.L. AND ANDERSON H.A.
Achalasia and carcinoma of the oesophagus J. American Medical
Association, 215: 1638, 1971.
79. YUDIN S.S.
The sugical construction of 80 cases of artificial
oesophagus. Gynecol. obstet., 78, 561, 1944.
80. ZHANG KAI AND YANG-YIHUA.
Use of pericled omentum in oesophagastic anastomosis.
Analysis of 100 cases. Ann R.C.S. England Vol.69: 209-211,
1987.

QUESTIONNAIRE FOR COLLECTION OF DATA

ON

BENIGN LESIONS OF THE OESOPHAGUS AT KENYATTA NATIONAL HOSPITAL
AND THEIR RELATIONSHIP TO ESOPHAGEAL MALIGNANCIES

Type of
Form

A- retrospective

B- prospective

1. IDENTIFICATION

(a) NAME OF PATIENT

. CHRISTIAN OR FOREIGN (ACQUIRED.)

. PERSONAL NAME

. SURNAME(FAMILY NAME)

(b) Age
IN YEARS

(c) SEX

M

F

(d) MARITAL STATUS

SINGLE

MARRIED

WIDOW/WIDOWER

DIVORCED

MONOGAMIST

POLYGAMIST

(e) (e) NUMBER OF CHILDREN

Females

Males

Total

(f) RELIGIOUS FAITH

ATHEIST

CHRISTIAN

MUSLI.

HINDU

OTHERS (SPECIFY)

(g) PROFESSION

EMPLOYED BY CORPORATE BODY

SELF EMPLOYED

UNEMPLOYED

RETIRED

PLANTER

PASTURAL

BUSINESS(SSE)

(h) AREA OF ORIGIN

PRCVINCE

DISTRICT

URBAN

RURAL

2. SOCIAL HABITS

(a) TYPE OF FOOD STUFF CONSTITUTING BULK OF DIET

HIGH CEREAL

TUBERS

HIGH FIBER

PROTEINACEOUS

SPICY

DO YOU TAKE MOST OF YOUR FOOD

COLD

HOT

SMOKED - DRIED?

YES

NO

(b) TOBACCO HABITS

SMOKER

SNOFFERS(SNIFFERS)

CHEWERS

(a) ALCOHOLIC HABITS

NON	MILD	MODERATE	HEAVY

?BIEER

-LOCAL LIQUOR

-LOCAL BREW

3. PRESENTING SYMPTOMS

(a)

	DYSPHAGIA
	REGURGITATION
	SIALORHOEA
	CHEST PAINS
	WEIGHT LOSS
	LUMP IN CHEST
	SHORTNESS OF BREATH
	CHANGE OF VOICE
	OTHERS

(b) DURATION OF MAIN SYMPTOM

1. BEFORE ADMISSION
2. BEFORE SURGERY

	YEARS	MONTHS	WEEKS	DAYS
1				
2				

(c) SIGNIFICANT PAST HISTORY

	CHEMICAL BURNS - INGESION
	SCALD (INHALATION BURNS)
1	CHRONIC ALCOHOL INGESION (1. BIEER 2. SPIRITS 3. LOCAL BREW)
2	
3	
	CHRONIC PHARYNGITIS

(d) CONDITION AT VISIT (CONSULTATION)

- UNCLEAR SYMPTOMATOLOGY
- SIGNIFICANT SYMPTOMATOLOGY
- DIAGNOSTIC SYMPTOMATOLOGY
- UNQUESTIONABLE

(e) CONDITION AT ADMISSION

- FAIR
- MODERATELY WASTED/DEHYDRATED
- SEVERELY WASTED/DEHYDRATED
- URAEMIC

4. IMPORTANT G.I.T. DISEASE CONDITIONS

1	ESOPHAGITIS
2	CARCINOMA OF STOMACH/CARDIA
3	PLUMMER VINSON - (PATTERSON-KELLY) SYNDROME
4	ACHALASIA CARDIA
5	ATROPHIC GASTRITIS
6	DIVERTICULOSIS OF OESOPHAGUS
7	BURNS (CHEMICAL, SCALDS) (ACCIDENTAL ₁ , VOLUNTARY ₂)
8	PEURTZ - JEUGERS
9	POST RADIATION LESION
10	AMYLOIDOSIS
11	SARCOIDOSIS
12	LEUOLOPLAKIA

5. ASSOCIATED LESIONS/MALIGNANCIES

1
2
3
4
5

6. NUMBER OF SURGICAL PROCEDURES

(A) BEFORE ADMISSION

1	2	3	4	5
---	---	---	---	---

(B) WHILE AT KNH

1	2	3	4	5
---	---	---	---	---

7. CLINICAL STAGING BEFORE DEFINITIVE/PALLIATIVE SURGERY

I	II	III	IV
---	----	-----	----

8. INVESTIGATION

- a) BARIUM MEAL
- BARIUM SWALLOW

ENDOSCOPY

NORMAL

INFLAMMATION

TYPICAL

ENDOSCOPIC BIOPSY

SUSPICIOUS

NO

YES

b) ANAEMIA

MICROCYTIC

NORMOCYTIC

MACROCYTIC

NORMOCHROMIC

HYPOCHROMIC

Hb

T.R.B.C.

JAUNDIC

THROMBOCYTOPENIA

NEUTROPENIC

LEUCOCYTOSIS

P.T.I.

LAB FINDINGS (ALSO EXPRESSED AS % OF NORMAL) U/E

- BUN
- CREATININE
- CLEARANCE OF CREATININE
- BILIRUBINE
- SERUM LIPIDS
- SERUM PROTEINS
- PHOSPHATES
- CHLORIDE
- BICARBONATE
- SODIUM
- POTASSIUM
- CALCIUM

9. HISTOPATHOLOGY

NEGATIVE

POSITIVE

? DUKES CLASSIFICATION.

10. SURGICAL PROCEDURES

o INVESTIGATIVE

ENDOSCOPY

EXFOLIATIVE CYTOLOGY

BIOPSY

- o PALLIATIVE
- o TEMPORARY
- o CURATIVE

DETAIL OF PROCEDURE

11. IN THIS PATIENT IS THERE AN OBVIOUS LINK BETWEEN BENIGN AND MALIGN LESION?

NO

PROBABLE

CERTAIN