

**DISSERTATION**

**OCULAR MANIFESTATIONS OF SICKLE CELL DISEASE AT THE  
UNIVERSITY TEACHING HOSPITAL, LUSAKA, ZAMBIA**

**DR. BWALYA WILLARD MUMBI**

**H58/69898/11**

**A DISSERTATION SUBMITTED IN PARTIAL FULFILLMENT FOR THE  
AWARD OF DEGREE OF MASTERS IN MEDICINE (OPHTHALMOLOGY),  
UNIVERSITY OF NAIROBI**

**2014**

## **DECLARATION**

I declare that this thesis is my original work and has not been presented for the award of a degree in any other university.

Signed: \_\_\_\_\_

Date: \_\_\_\_\_

**Dr. Bwalya Willard Mumbi**

## APPROVAL

This dissertation has been submitted for examination with the approval of the following supervisors:

**Prof. Jefitha Karimurio, MB.CHB, M.MED (Nairobi), MSC-CEH (London), FEACO, PhD (Melbourne)**

Department of Ophthalmology, University Of Nairobi

Signed:  Date: 29/05/2014

**Dr. Lucy Njambi, MB.CHB, M.MED (Nairobi), FEACO.**

Lecturer, Department Of Ophthalmology, University Of Nairobi

Signed: \_\_\_\_\_ Date: \_\_\_\_\_

**Dr. Grace Chipalo-Mutati, BSc.HB, MBCHB (UNZA), MRCOPHTH, FRCS (Edinburgh), MSc (CEH),**

Consultant Ophthalmologist, Head of Eye Unit, University Teaching Hospital (UTH)  
Lusaka, Zambia

Signed: \_\_\_\_\_ Date: \_\_\_\_\_

## **DEDICATION**

This study is dedicated to my wife Sepiso, and my children Chengelo and Naleli for their support and encouragement.

## TABLE OF CONTENTS

DECLARATION .....	ii
APPROVAL .....	iii
DEDICATION .....	iv
LIST OF TABLES .....	vii
LIST OF FIGURES .....	viii
LIST OF ACRONYMS AND ABBREVIATIONS .....	ix
ACKNOWLEDGEMENT .....	x
ABSTRACT.....	xi
1.0 INTRODUCTION .....	1
1.1 Sickle cell disease.....	1
1.2 Historical Perspective.....	1
2.0 LITERATURE REVIEW .....	2
2.1 Epidemiology of SCD .....	2
2.2 Systemic Manifestation .....	3
2.3 Ocular Manifestation of SCD.....	4
2.3.1 Visual Acuity .....	4
2.3.2 Orbital Compression Syndrome .....	5
2.3.3 Conjunctiva.....	5
2.3.4 Iris atrophy and depigmentation .....	5
2.3.5 IOP.....	6
2.3.6 Nonproliferative Retinal Changes .....	6
2.3.7 Proliferative Sickle Retinopathy.....	8
3.0 JUSTIFICATION .....	11
4.0 OBJECTIVES .....	12
4.1 General Objective .....	12
4.2 Specific objectives .....	12

5.0 METHODOLOGY .....	12
5.1 Study area.....	12
5.2 Study period .....	14
5.3 Study Design .....	14
5.4 Study Population .....	15
5.5 Sampling Technique.....	15
5.6 Inclusion criteria:.....	16
5.7 Exclusion criteria: .....	16
5.8 Data Collection and Management .....	16
5.8.1 Data Collection Procedure.....	16
5.8.2 Data Analysis.....	17
5.9 Ethical Considerations.....	18
5.9.1 Confidentiality .....	18
5.9.2 Ethical Approval.....	18
6.0 RESULTS .....	19
7.0 DISCUSSION .....	32
7.1 CONCLUSION .....	36
7.2 RECOMMENDATIONS .....	37
7.3 LIMITATIONS OF THE STUDY .....	37
REFERENCES .....	38
APPENDICES .....	42
APPENDIX I: QUESTIONNAIRE .....	42
APPENDIX II: PARTICIPANT INFORMATION FORM.....	46
APPENDIX III: CONSENT FORM .....	51
APPENDIX IV: ASSENT FORM FOR CHILDREN/DEPENDENTS. ....	53
APPENDIX V: ETHICS APPROVAL LETTERS .....	56

## **LIST OF TABLES**

Table 1: Characteristics of the study participants .....	19
Table 2: Tribe of parents.....	21
Table 3: Total number of admissions.....	22
Table 4: Systemic Severity – Admissions per year of life.....	22
Table 5: Systemic History - Reasons for Admission.....	23
Table 6: Ocular History .....	24
Table 7: Visual Acuity in the affected eye.....	25
Table 8: Conjunctiva findings.....	25
Table 9: Fundus examination findings.....	26
Table 10: Univariate analysis on factors influencing ocular presence among the sickle cell patients .....	28

## **LIST OF FIGURES**

Figure 1: Flow diagram showing response rate of the study participants.....	19
Figure 2: Region of the parents.....	20
Figure 3: Prevalence of ocular manifestation of sickle cell disease .....	27



## **LIST OF ACRONYMS AND ABBREVIATIONS**

CRAO	Central Retinal Artery Occlusion
CRVO	Central Retinal Vein Occlusion
FLA	Fluorescein Angiography
HBSC	Haemoglobin SC
HbSS	Haemoglobin SS
IOP	Intraocular Pressure
OCT	Optic Coherent Topography
PSR	Proliferative Sickle Retinopathy
RBC	Red Blood Cell
SCA	Sickle Cell Anaemia
SCD	Sickle Cell Disease
UON	University of Nairobi
UTH	University Teaching Hospital
WHO	World Health Organization

## **ACKNOWLEDGEMENT**

I would like to express my sincere gratitude to my supervisors: Prof. Karimurio, Dr. Njambi and Dr. Mutati for their guidance in this study.

I would also like to thank Dr. Hamankwa Mantina of University Teaching Hospital, Haematology Department for his dedication and help that he offered me.

I am grateful to Light For The World for their financial support to conduct this study.

Last but not the least, I am also grateful to the lecturers, my fellow residents and the staff from Department of Ophthalmology, University of Nairobi. Not forgetting my statistician, Mr. Gabriel Otieno, who tirelessly worked with me to the completion of the study.

## **ABSTRACT**

**Background:** Sickle cell disease (SCD) is an autosomal recessive haemoglobinopathy occurring due to a defect in the beta chain of the haemoglobin molecule. Its effects on the eye have been reported in the adnexa, anterior and posterior segments. An overall sickling prevalence in Zambia varies between 4.5-16.8% in a population of 13 million people but ocular manifestations have not been documented.

**Objective:** To assess the pattern of ocular manifestations in sickle cell disease patients at the University Teaching Hospital (UTH), Lusaka, Zambia.

**Study design:** Hospital- based prospective consecutive case series.

**Setting:** Hospital wards and haematology clinic.

**Methodology:** All patients aged between 6 to 61years reporting for routine follow up in the haematology clinic and those admitted in medical wards during the period of the study were examined. A questionnaire was administered to extract information from patients reporting to the health facility. Examination of the eyes was done using slit lamp biomicroscope. The posterior segment was examined with an indirect ophthalmoscope and slit lamp biomicroscope.

**Results:** Ocular abnormalities were found in 69.15% of the 94 subjects studied. All had HbSS with a female to male ratio of 1.8:1. Blindness was found in 1.09% of eyes examined, and was due to retinal detachment. Anterior segment findings included: conjunctival sickle sign 38 (40.43%); jaundice 18 (19.35%), iris atrophy 2 (2.13%); and cataract 2 (2.13%). Posterior segment findings included: vessel tortuosity 41 (44.09%); black sun burst 4 (4.30%); angioid streak 1 (1.08%); schisis 1 cavity2 (2.15%); macular hole1 (1.08%); epiretinal membranes membranes1 (1.08%). Retinal detachment was found in 1 (1.08%) patient. There was statistically significant association of ocular manifestation with age above 26 years ( $p=0.013$ ).

**Conclusion:** HBSS was the only genotype of SCD in this study. People originating from the Northern and Eastern regions had the highest prevalence of SCD. With regard to ocular manifestations of SCD, the prevalence was high but most of the manifestations were not causing visual impairment. Both men and women were equally affected. The prevalence increased with age.

## **1.0 INTRODUCTION**

### **1.1 Sickle cell disease**

Sickle haemoglobinopathies occur due to abnormality in the beta chain of the hemoglobin molecule.<sup>1</sup> SCD indicates the presence of genotypes that contain one sickle gene, with HbS making up at least half the hemoglobin. A number of sickle genotypes have been documented, and these include the following: HbSS disease or sickle cell anemia; HbS/b-0 thalassaemia which is double heterozygote for HbS and b-0 thalassaemia; HbSC disease a double heterozygote for HbS and HbC commonly found in West Africa.<sup>2</sup>

HbSS is the most common subtype occurring worldwide. It consists of two copies of  $\beta$ -globin S mutation. This is an autosomal recessive disease caused by the substitution of valine for glutamic acid at position 6 of the beta polypeptide chain of hemoglobin. The second subtype of SCD common in Africa is compound heterozygosity consisting of beta S and beta C globins.<sup>3,4</sup> This is due to the inheritance of HbS from one parent and another HbC, from the other parent.

A deficiency in the rate of synthesis of the  $\beta$ -globin chain results in a thalassaemia. This occurs when HbS combine with this chain resulting in S $\beta$  thalassaemia (S $\beta$ ).<sup>5</sup>

The polymerisation of deoxygenated HbS makes red blood cells less pliable and deforms some of them, and these stiff cells cannot easily negotiate capillary beds, resulting in premature destruction (haemolysis) and blockage of blood flow (vaso-occlusion). These two mechanisms result in a plethora of clinical manifestations.<sup>6</sup> The chief manifestations are chronic haemolytic anemia and vaso-occlusive crises that produce severe pain as well as long-term and widespread organ damage.

Sickle cell disease literally affects every aspect of the eye. Its effects have been documented in eye adnexa, anterior and posterior segments.<sup>1</sup>

### **1.2 Historical Perspective**

Africans have known of the disease for generations, and it has been traced back as far as 1670 in Ghana. It was first reported in the United States in 1910 by Herrick on a dental student from Grenada named Noel. He had recurrent pain, anaemia and sickled appearance of the red blood cells.<sup>2</sup> In 1949, Neel demonstrated that sickle cell anemia

was transmitted as a recessive gene, and the same year Pauling and associates noted that sickle hemoglobin and normal hemoglobin demonstrated a different electrophoretic mobility.<sup>1</sup>

## **2.0 LITERATURE REVIEW**

### **2.1 Epidemiology of SCD**

SCD occurs in regions of the world where malaria is or was previously common. Individuals in these areas have a fitness benefit in carrying only a single sickle-cell gene (sickle cell trait).<sup>7</sup> These areas include: Africa; Mediterranean Europe; Middle East; some regions of India; the Caribbean; South and Central America.

In Africa, the HbS gene frequency is 10-30% and about 200,000 new cases of sickle cell disease (SCD) occur each year. The incidence of SCD in other parts of the world is increasing due to population migration.<sup>8,9</sup>

In the United States of America, SCD affects > 70,000 African-Americans and 1 in 375 newborn.<sup>9</sup> In the United Kingdom, it affects 1 in 2,400 live births across ethnic groups, and > 12,000 individuals are living with SCD.<sup>8</sup>

An overall sickling prevalence of 10.4% was found in over 4,000 selected subjects in a study done in Lusaka, Zambia. However, this varied from 4.5% to 16.8% in different tribal groups.<sup>11</sup>

Earlier studies done in a 1969 survey of some 10,000 blood samples found 187 cases diagnosed with HbSS, most of them in infants. However, no haemoglobin C and no  $\beta$ -thalassaemia were found. Haemoglobin H disease and other evidence for  $\alpha$ -thalassaemia were found.<sup>12</sup>

Patients with SCD are now living much longer than in the past. Deaths occurring due to SCD globally were previously very high. From the 1960s, multiple researchers have reported an almost total absence of HbSS among samples of African adults.

A study done by Barclay in a Zambian mining town between 1969-1971 showed excess mortality rates of 60% by age 12 years.<sup>12</sup>

However, in the recent past, some studies are suggesting that survival might be improving. For example, in a study conducted in Lusaka, Zambia, Athale and Chintu reported that the case-fatality rate among children with HbSS who were admitted to the University Teaching Hospital decreased from 18.6% in 1970 to 6.6% during 1987–1989.<sup>13</sup> A recent WHO progress report noted a decline in under-5 mortality in sub-Saharan Africa by 28% since 1990.<sup>14</sup>

## **2.2 Systemic Manifestation**

The homozygous state (HbSS) has more severe systemic manifestation while the heterozygous state (HbSC) disease and sickle cell  $\beta$ -thalassaemia are milder.<sup>15</sup>

Although hematologic changes indicative of SCD are evident as early as the age of 10 weeks, symptoms usually do not develop until the age of 6-12 months. This is because of high levels of circulating fetal hemoglobin. At the age of 3 months, adult hemoglobin (HbA) usually gains prominence.<sup>2</sup>

The physiological changes in RBCs result in a disease with the following cardinal signs: (1) haemolytic anemia; (2) painful vaso-occlusive crisis; and (3) multiple organ damage from microinfarcts, including heart, skeleton, spleen, and central nervous system.<sup>2</sup>

Chronic haemolytic anaemia is one of the hallmarks of the disease. This occurs as a result of the premature destruction of sickle erythrocytes which have a mean life span of 17 days. The anaemia is exacerbated by a number of several events such as aplastic crises, acute splenic sequestrations, chronic renal disease, bone marrow necrosis, deficiency of folate and iron.<sup>10</sup>

Painful vaso-occlusive crisis is the most common and hallmark of the disease. This result from complex interactions between endothelium, plasma factors, leukocytes and rigid red cells leading to the obstruction of blood vessels. The hypoxia which results leads to tissue necrosis and local pain.<sup>15</sup>

This can manifest in any part of the body, but is more common in long bones, chest, abdomen and brain. This phenomenon is precipitated by cold weather, dehydration and infections.

Multiple organ damage from microinfarcts may result in disastrous acute events. This can involve: neurological, hepatobiliary, genitourinary and cardiac complications resulting in death.

Abdi Daher et al, in hospital-based study done in Kenya, found pain (83.5%) to be the most common.<sup>16</sup> In Ghana, Osafo-Kwaako et al, found that the prevalence of PSR in HbSS subjects increased with increasing systemic severity of the disease. For HbSC, it was however found that PSR increased with moderate increase in systemic severity. It was also observed that adults with HbSS and HbSC who had more than 0.6 hospital admissions per year of life were at increased risk of developing PSR.<sup>17</sup>

### **2.3 Ocular Manifestation of SCD**

Sickle cell ocular abnormalities are caused by intravascular sickling, haemolysis, haemostasis, and thrombosis.<sup>18</sup>

#### **2.3.1 Visual Acuity**

Van Meurs in Curacao, found visual impairment in sickle cell disease to occur more commonly in one eye. Bilateral visual loss was not common. He reported 6% severe unilateral visual loss in HbSC and 1% severe bilateral visual loss.<sup>19</sup>

Abdi Daher et al, in a hospital-based study done in Kenya in 101 patients found no visual loss.<sup>16</sup> In Accra, Ghana, Osafo-Kwaako et al reported 2.5% of patient eyes in a study of 114 HbSS and 87 HbSC patients had visual impairment, half of which had severe visual impairment or blindness.<sup>17</sup> However, most of the eyes had normal vision (99.1% of HbSS and 95.3% of HbSC eyes).

### **2.3.2 Orbital Compression Syndrome**

This consists of fever, headache, orbital swelling, and optic nerve dysfunction. The most common cause is due to orbital bone marrow infarctions and palpebral lid swelling.<sup>15</sup>

In a report of five cases and review of literature, Anuradha Ganesh et al, found infarction of orbital bones during vaso-occlusive crises in sickle cell disease. This presents acutely with a rapidly progressive periorbital swelling. Haematomas frequently complicating the condition and, along with the inflammatory swelling. The 5 patients (4 with HbSS and 1 with sickle cell- $\beta$ -thalassaemia) aged 6-15 years had a history of multiple admissions for vaso-occlusive crises. The periorbital swelling spread to the orbit in 4 cases and resulted in proptosis, restriction of ocular motility and visual impairment.<sup>20</sup>

### **2.3.3 Conjunctiva**

The conjunctiva may reveal multiple short comma-shaped capillary segments that often appear isolated from the vascular network because the afferent and efferent lumens are empty. These transient sites of tightly clumped intravascular erythrocytes are found on the bulbar conjunctiva.<sup>15</sup>

The conjunctival sickle sign was seen significantly more often in patients with HbSS disease (70%) than in patients with HbSC (34%) or sickle thalassaemia (17%) disease in a study done in USA by Clarkson.<sup>1</sup> In Ghanaian patients, conjunctival vessel signs were found in 53%. This had approximately equal prevalence amongst HbSS and HbSC patients.<sup>17</sup> Abdi Daher et al in Kenya observed it in 87% of HbSS patients.<sup>16</sup>

### **2.3.4 Iris atrophy and depigmentation**

Iris atrophy and depigmentation in SCD patients is believed to be due to the vaso-occlusive process and is also closely associated with PSR in the same eye.<sup>35</sup> Osafo-Kwaako et al in Ghana observed that eyes with iris atrophy were 1.8 times more likely to have PSR. Iris atrophy and depigmentation was 3 times more prevalent with HbSC than HbSS patients.<sup>17</sup>



### **2.3.5 IOP**

Sickling of HbS cells is favoured by the relatively deoxygenated conditions in the anterior chamber. The deformed, sickled and less pliable cells are unable to negotiate the trabecular meshwork leading to increased intraocular pressure.<sup>16</sup> SCD patients with hyphaema present an important ocular emergency, which usually occurs as a result of trauma or surgery. Red blood cells tend to sickle and obstruct the flow of aqueous humour as a result of low pH and partial pressure of oxygen.<sup>16</sup>

Individuals with sickle cell disease are prone to neovascular glaucoma. Ischaemia occurring due to blood vessels obstruction by sickled red blood cells may lead to neovascularisation in trabecular meshwork and iris. This can eventually lead to anterior chamber outflow tract obstruction causing raised intraocular pressure.<sup>22</sup>

In a Nigerian study, George IO, found glaucoma in 1.1% of the cases studied.<sup>23</sup> Osafo-Kwaako et al found 1.7% had IOP more than 21mmHg in subjects who were not known glaucoma patients and had no optic disc signs of glaucoma.<sup>17</sup> However, Abdi Daher et al found normal IOPs in all the patients examined.<sup>16</sup>

### **2.3.6 Nonproliferative Retinal Changes**

The nonproliferative ocular signs occurring as a result of SCD are varied. They include: venous tortuosity, silver wire arterioles, salmon patch hemorrhages (oval pale retinal hemorrhages), intraretinal hemorrhages, black sunbursts, macular arteriole occlusions, retinal vein occlusions, angioid streaks, and dark without pressure.<sup>24</sup> Retinal vein occlusions although rare can be severe resulting in loss of vision.

Vessel involvement at the posterior pole in sickle cell disease presents a spectrum ranging from central retinal artery occlusion, major branch occlusion, minor branch occlusion, to perimacular capillary drop-out and formation of perifoveal avascular zones.<sup>25</sup>

Central retinal artery occlusion or its major branches in sickle cell disease may occur spontaneously.<sup>26</sup> This leads to a pale, hazy, oedematous retina giving a cherry red spot or a black spot in blacks.<sup>17</sup> A case of multiple vascular occlusions of both larger and smaller sized retinal arterioles occurring simultaneously in a patient with sickle cell

haemoglobin C disease (SC) has been described by Chopdar in a 22 year old West Indian man. This occurrence is however uncommon.<sup>27</sup>

Vessel tortuosity is a common finding on the fundus. Kaimbo et al in a study of 66 Congolese children aged between 1 and 18 years found retinal vascular tortuosity (29%), dilatation (26%) and AV crossing (29%).<sup>28</sup> Tortuosity of major retinal vessels was found in 13.8% of patients with HbSS disease in a Nigerian study.<sup>23</sup>

Salmon-patch hemorrhages are superficial intraretinal hemorrhages. They are usually seen in the mid periphery of the retina adjacent to a retinal arteriole. They usually resolve without sequelae. Salmon patch retinal haemorrhages were observed in 6.4% of Nigerian HbSS subjects.<sup>29</sup>

The schisis cavity is a space caused by the disappearance of the intraretinal hemorrhage.

The black sunburst consists of round chorioretinal scars usually located in the equatorial fundus. This is histologically due to focal hypertrophy, hyperplasia and migration of RPE cells. They are usually round or ovoid, and are characteristically located in the equatorial fundus. They usually have stellate or spiculate borders and are frequently associated with refractile yellowish granules. Their configurations range from tiny pigmented spots to large multi-spiculated scars. Because of their characteristic peripheral location, these lesions usually do not interfere with vision.<sup>30, 17, 31</sup>

In a prospective study of 38 patients by Asdourian G, et al, three patients developed black sunbursts during a period of 6 to 24 months follow up. The lesions occurred in the fundus periphery.<sup>31</sup>

The black sunburst sign was reported by Osafo-kwaako in 21.2% of HbSC and 5.0% HbSS of the patients.<sup>17</sup>

Angioid streaks are a characteristic retinal pattern of pigmented 'fissures' radiating from the disc, lying deep to the retinal vessels and caused by breaks in the elastic lamina of Bruch's membrane.<sup>32</sup> Vascular impairment of the choriocapillaris with

resulting damage to Bruch's membrane has been previously suggested as a cause of angioid streaks.<sup>33</sup>

Detailed ophthalmological assessments made on 242 patients with HbSS disease attending the sickle cell clinic at the University Hospital of the West Indies and a group of peripheral sickle cell Clinics detected angioid streaks in 21 patients (11 male, 10 female), with ages ranging from 30 to 63 years.<sup>32</sup> Osafo-Kwaako et al in Ghana found angioid streaks in 5.3% of HbSS and 6.9% of HbSC subjects examined.<sup>17</sup>

### **2.3.7 Proliferative Sickle Retinopathy**

Proliferative retinopathy (PSR) involves the growth of abnormal vascular fronds that place patients at risk of vitreous hemorrhage and retinal detachment. The initiating event in the pathogenesis of proliferative disease is thought to be peripheral retinal arteriolar occlusions. Local ischemia from repeated episodes of arteriolar closure is presumed to trigger angiogenesis through the production of endogenous vascular growth factors, such as vascular endothelial growth factor and basic fibroblast growth factor.<sup>23</sup>

In 1971, Goldberg proposed a classification of proliferative sickle retinopathy into the following 5 stages: Peripheral arteriolar occlusions; arteriolar-venular anastomosis; seafan neovascularisation; vitreous hemorrhage and retinal detachment.<sup>1</sup>

PSR is most frequent in patients with HbSC but also can be present in patients with hemoglobin S-thalassaemia disease, and HbSS.<sup>34</sup> This is because Spontaneous regression (auto-infarction) of the new vessel proliferations is more common in HbSS than in HbSC patients. Severe vaso-occlusion in HbSS leads to the dead retina not being able to trigger angiogenesis through the release of vascular endothelial growth factors.<sup>35</sup> A study done by Condon PI ,et al on “Behaviour of untreated proliferative sickle retinopathy” showed that auto infarction closes the feeding vessels of PSR lesions without the complications associated with photocoagulation. Spontaneous regression was present on initial examination in 49% of eyes with PSR initially and developed in further 39% eyes of follow up during the study. Although development of PSR was more common in sickle cell-haemoglobin C (SC) disease, auto infarction

appeared to occur more commonly in homozygous sickle cell (SS) disease. Blindness related to PSR occurred in (12%) eyes.<sup>36</sup>

Frequency of PSR tends to increase with age. Although peripheral vaso-occlusion may be observed as early as 20 months of age, clinically detectable retinal disease is found most commonly between 15 and 30 years of age.<sup>34, 37, 38</sup>

In a Jamaican cohort study, involving 59 of the 74 (80%) children with HbSS disease and 37 of the 54 (69%) children with HbSC disease, aged 5-7.5 years, proliferative retinopathy was not identified.<sup>39</sup>

In another Jamaican cohort study of sickle cell disease done among 389 children aged 5-13 years, Peripheral retinal vessel closure was present in approximately 50% of children with HbSS and HbSC genotypes at age 6 years and increased to affect 90% of children by age 12 years. Proliferative retinopathy was rare, occurring only once in an 8-year-old boy with HbSC disease.<sup>40</sup>

The highest proportion of patients with PSR occur in the 30-39 year age group.<sup>41</sup>

However, though rare, vitreous haemorrhage has been known to occur below the age of 20 years. Children with SCD should, from about the age of 10 years, be referred for at least every two years for dilated binocular indirect ophthalmoscopy preferably with fluorescein angiography if such facilities are available, so that neovascular lesions can be treated before blinding sequelae occur. When an individual reaches the age of 20, the examination should be increased to yearly examinations.<sup>34</sup>

The prevalence of PSR among SCD in different countries has shown a wide range of variation: Jamaica 24%,<sup>42</sup> United States of America 18%,<sup>43</sup> Ghana 12.9%,<sup>17</sup> Togo 9.4%<sup>44</sup> Nigeria 5.6%,<sup>45</sup> Saudi Arabia 1.6%,<sup>46</sup> and in Kenya 1%.<sup>16</sup>

The prevalence of PSR for HbSS found in literature search was lower than that of HbSC. It was 12% in HbSS and 36% in HbSC of Jamaican patients<sup>42</sup>; in the United States of America ,11% of HbSS and 45% of HbSC patients;<sup>43</sup> 3.5% in HbSS compared with 31.4% in HbSC in Ghana;<sup>17</sup> 1% in Kenya of HbSS<sup>16</sup>; 50% of HbSC in Curacao Islands.<sup>19</sup>

Van Meurs found vitreous haemorrhage in 18% and 8% had retinal detachment, all these patients had HbSC.<sup>19</sup> Obikili et al in Nigeria, found 3.8% of vitreous

haemorrhage and no retinal detachment among HbSS subjects.<sup>29</sup> Osafo-Kwaako et al in Ghana found vitreous haemorrhage in 1.8% of HbSS and 3.4% of HbSC subjects examined. Retinal detachment was found in 0.9% of HbSS and 1.1% of HbSC subjects.<sup>17</sup> Abdi Daher et al in Kenya, found no case of vitreous haemorrhage or retinal detachment.<sup>16</sup>

The formation of epiretinal membranes are thought to result from disruption of the internal limiting membrane by posterior vitreous detachment (PVD). This provides access for glial cells which migrate through breaks in that membrane and proliferate on the retinal surface.<sup>49</sup> The PSR, the extent of involvement of PSR, and vitreous haemorrhage all constitute risk factors for the formation of epiretinal membranes.<sup>48</sup>

Moriarty et al, in Jamaican study indicated that SCD may be one of the causes of epiretinal membranes. Epiretinal membranes at the macula were seen in 4% of the eyes of 355 patients with HbSS disease and HbSC disease under the age of 60 years.<sup>48</sup>

The goal of treatment of PSR is to eliminate existing neovascularisation and, thus to eliminate the sequelae of PSR.<sup>30</sup> Although more than 60% of neovascularisation undergo spontaneous regression,<sup>49</sup> vitreous haemorrhage and retinal detachment still occur. Most should therefore be treated. Indications for treatment include: bilateral retinopathy; large and elevated sea fans; rapid growth of a sea fan; evidence of vitreous haemorrhage; and visual loss in one eye due to proliferative disease.<sup>50</sup>

Modalities to treat proliferative sickle retinopathy include: laser retinal photocoagulation, retinal cryotherapy, and vitrectomy/membranectomy.

Various methods of laser photocoagulation effectively induce regression of peripheral neovascularisation. Scatter laser photocoagulation of areas that surround sea-fan proliferation and associated areas of ischemic retina induces regression of these lesions.<sup>51</sup>

Peripheral retinal cryotherapy is used if media opacities prevent photocoagulation.

Surgical procedures (vitrectomy/membranectomy) may be performed to treat retinal detachments, non-clearing vitreous hemorrhage, and epiretinal membranes.<sup>30, 17</sup>

### **3.0 JUSTIFICATION**

Although prevalence of sickle cell disease is high in the country, there is no study done to determine ocular manifestations.

The World Health Organization (WHO) at its 56<sup>th</sup> session in 2006 recommended that SCD be acknowledged as a public health issue and emphasized the urgent need to establish simple cost effective strategies to reduce the morbidity and mortality associated with SCD in countries most affected with SCD.<sup>52</sup>

A number of interventions have thus been promoted, such as public health programs including: newborn screening, health education, and immunization. This has resulted in increased life-expectancy. Hence, more patients with SCD are living into adulthood. Mortality attributable to sickle cell disease has decreased and the mean age of death is increasing.<sup>17, 53</sup>

The increase in life expectancy may lead to increased number of patients with visual impairment. As a result of this, eye care providers will be faced with a burden of a unique challenge of managing these patients.

The information obtained will thus be useful in highlighting the magnitude and pattern of ocular features of sickle cell disease patients in Lusaka, Zambia. Therefore, this will assist in setting up of an appropriate screening protocol and follow-up. It will also foster a multidisciplinary approach in the management of sickle cell disease patients involving pediatricians, physicians, ophthalmologists and other allied health workers.

## **4.0 OBJECTIVES**

### **4.1 General Objective**

To assess the pattern of ocular manifestations in sickle cell disease patients at the University Teaching Hospital (UTH), Lusaka, Zambia.

### **4.2 Specific objectives**

1. To establish the prevalence of ocular morbidity among sickle cell disease patients at haematology clinic and wards of UTH.
2. To determine the association of ocular manifestation of sickle cell disease with age, sex, genotype and systemic severity.

## **5.0 METHODOLOGY**

### **5.1 Study area**

The University Teaching Hospital is a public institution located in, Lusaka, Zambia. Zambia is a Southern Africa country bordered by Tanzania, Malawi, Mozambique, Zimbabwe, Botswana, Namibia, Angola and The Democratic Republic of Congo (Figure 1). Zambia's population is about 13 million according to the 2010 population census.

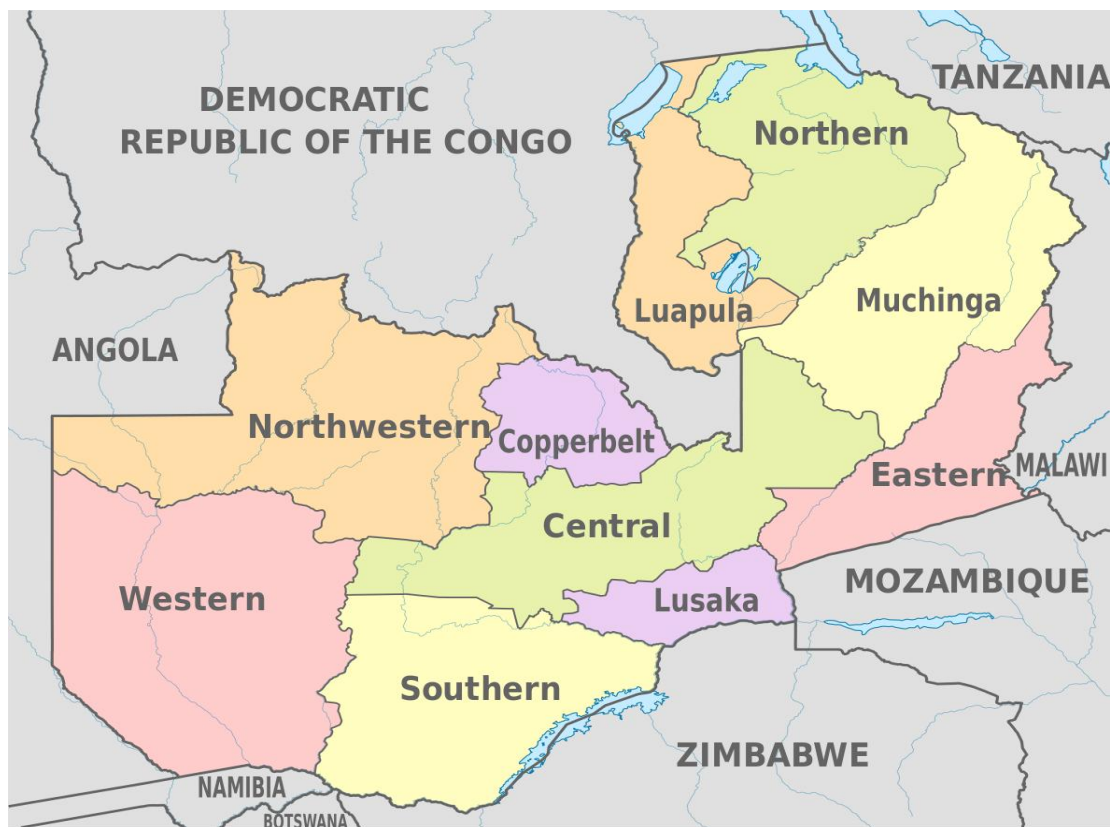Although more than 73 languages are spoken in the country, English is the official language.

The country is divided into ten 10 provinces. Lusaka province, hosts the main referral hospital, the University Teaching Hospital.

The haematology clinic is located within the hospital. Patients coming for routine follow up for SCD are seen every Friday in the haematology clinic located in Clinic 3, first floor of the University Teaching hospital. Children with severe events and illness from SCD are admitted in the haematology ward in the paediatrics section and adults are admitted in the adult medical wards.

Patients first register with the clerk on their appointed date and hospital records are retrieved thereafter. They are then seen by the nurse who takes vital signs such as temperature, blood pressure and pulse. The patients are then seen by the

haematologist who assesses for any severe events. Counseling is offered to the patient by the attending haematologist on the disease. Depending on the well being of the patient, he/she is either admitted to control any severe event or is given another follow up date if there is no severe event.



**Figure 1: Map of Zambia**



## 5.2 Study period

The study was conducted from October 2013 to February 2014.

Activities	JAN 2013	FEB 2013	MAR 2013	APR 2013	MAY 2013	JUN 2013	AUG 2013	SEP 2013	OCT 2013	NOV 2013	DEC 2013	JAN 2014	FEB 2014
Proposal development													
Research and Ethical Committee approval													
Data collection													
Data analysis													
Report writing													
Dissemination of findings													

**Figure 2: Gantt chart for the work plan.**

## 5.3 Study Design

This was a hospital-based consecutive case series.

#### 5.4 Study Population

Sickle cell disease patients attending the haematology clinic, and those admitted to the paediatric haematology ward and medical wards.

Using sample size calculation for a single cross-sectional survey:

$$n = \frac{1.96^2 * P_{\text{exp}}(1-P_{\text{exp}})}{d^2}$$

Where:  $n$  = required sample size  
 $P_{\text{exp}}$  = expected prevalence  
 $d$  = desired absolute precision 54

Given that  $P_{\text{exp}} = 0.34$  (*George IO et al*)<sup>23</sup>, it therefore follows that  $(1 - P_{\text{exp}}) = (1 - 0.34) = 0.66$ . We let the desired absolute precision ( $d$ ) to be 10%.

The required sample size is given by

$$n = \frac{1.96^2 \times 0.34 \times 0.66}{0.1^2} = 86$$

The estimated sample size of 86 was expanded to 96 to allow for 10% possible non respondent. The prevalence for ocular manifestations of 34% used to calculate the sample size was obtained from a Nigerian study<sup>23</sup>. This was the closest similar study done in our region. There were no similar studies done in the Southern African region. In East Africa, a similar study done by Abdi Daher Saher et al,<sup>16</sup> did not indicate the prevalence of ocular manifestations.

#### 5.5 Sampling Technique

All eligible patients who reported for routine follow-up for sickle cell disease at the haematology clinic and those admitted in the paediatric haematology ward and adult medical wards at UTH were examined for ocular manifestations of SCD.

### **5.6 Inclusion criteria:**

Patients diagnosed with SCD and confirmed by Hb electrophoresis were included in the study.

### **5.7 Exclusion criteria:**

Patients aged 5 years and below were excluded because of special resources for examination and the expected difficulties in examining this age group.

## **5.8 Data Collection and Management**

### **5.8.1 Data Collection Procedure**

With the help of trained research assistant, the study was explained to the patients. They were then given the information form (Appendix II) detailing the study. Those who agreed to be part of the study were given the consent/assent form to sign which was also signed by the principal investigator.

Once the study participant had consented, a structured questionnaire (Appendix I) and hospital records were then used in extracting demographic data and history of the presenting complaints. Visual acuity was then taken using the Snellen chart and Illiterate E chart. Refraction was done to get Best Corrected Visual Acuity (BCVA) in the eye clinic for the patients with poor vision.

Tonometry was carried out with a Carl Zeiss slit lamp biomicroscope by applanation tonometry using tetracaine eye drops and fluorescent strips. In those patients where it was not possible to take IOP with the slit lamp, a portable Pulsair IntelliPuff Tonometer (Keeler Instruments, Inc.) was used to take IOP. Anterior segment examination was carried out with a Carl Zeiss slit lamp biomicroscope. It was performed to establish the presence or absence of signs due to sickle cell disease in conjunctiva, cornea, anterior chamber, pupil, iris, lens and anterior chamber.

Posterior segment was assessed as follows: both pupils were dilated with 0.5% tropicamide eye drops to view the fundus. Examination of the fundus was then performed with an indirect ophthalmoscope using a Volk 20 diopter lens. A detailed examination was done using a Volk 90 diopter lens coupled with a Carl Zeiss slit lamp biomicroscope.

Fundus photo documentation was done in selected cases.

Pretesting of the questionnaires was done to ensure validity. The research assistant was trained on data collection prior to the start of the study. Data on demographic and number of hospital admissions was extracted from hospital records and compared with that obtained from interviewing the patients. This was done to validate the information obtained.

### **5.8.2 Data Analysis**

The collected data were cleaned and entered in a computer's Microsoft excel data base. It was then exported to STATA version 12 (Stata Corp, College Station, Texas) for analysis.

Ocular manifestation was defined as the presence of the following: conjunctiva sign, jaundice, iris atrophy, cataract; Vessel tortuosity; salmon patch haemorrhage; black sunburst; angioid streak; schisis cavity; macular hole; epiretinal membrane; disc sign and retinal detachment.<sup>1, 17, 28.</sup>

Systemic severity was taken as the number of admissions divided by the age to get the numbers per year of life.<sup>17</sup>

All the analyses were performed using STATA, Version 12 (Stata Corp, College Station, Texas). Descriptive statistics such as frequency, percentage, mean, standard deviation was used to summarize and describe the data.

Stepwise logistic regression was done to assess individual independent variables in relation to ocular manifestations of sickle cell disease. All significant variables were included in the final multivariable logistic model. A p-value of 0.05 was used for all significance tests.

## **5.9 Ethical Considerations**

### **5.9.1 Confidentiality**

The files for patients containing confidential information were not photocopied nor were names of the patients or clinicians recorded. The information on the questionnaire was accessible only to the investigators and the statistician. All information collected on the patients was considered confidential and treated as such. Patients with treatable ocular manifestations were offered appropriate treatment. Informed consent (Appendix III), Assent form for minors (Appendix IV) was obtained from patients who were recruited in the study. They were also availed with an information form (Appendix II) explaining the study and the procedure to be done.

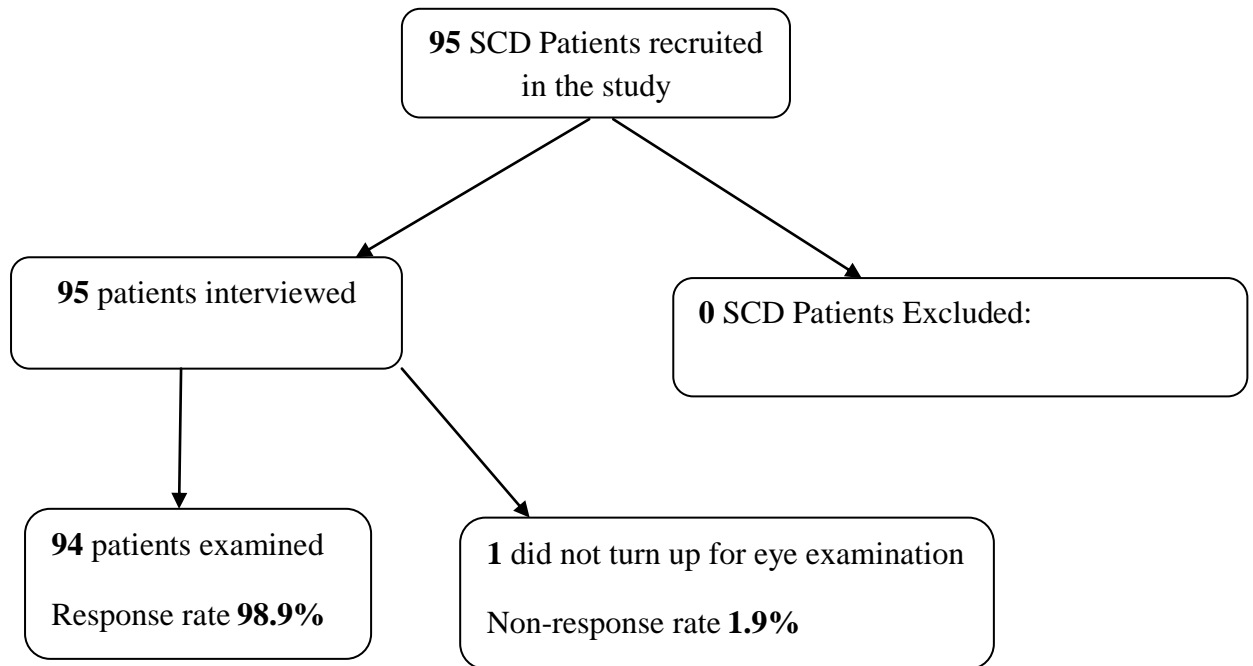
### **5.9.2 Ethical Approval**

The proposal was submitted to the University Of Zambia Biomedical Research Ethics Committee and KNH/UON ethics committee for approval.

Permission letter to carry out the study was obtained from UTH.

## 6.0 RESULTS

The flow chart below shows that there was a response rate of 98.9% out of the 95 patients recruited in the study.



**Figure 1: Flow diagram showing response rate of the study participants.**

Table 1 below shows that ages of the participants ranged from 6 years to 61 years old. Majority were in the age groups of 6 – 15 years (52.13 %). The mean age of the respondents was 18 years [95% CI: 16 - 20; SD: 10.43] and the median age was 14 years [95% CI: 12-19 years] Females were the majority.

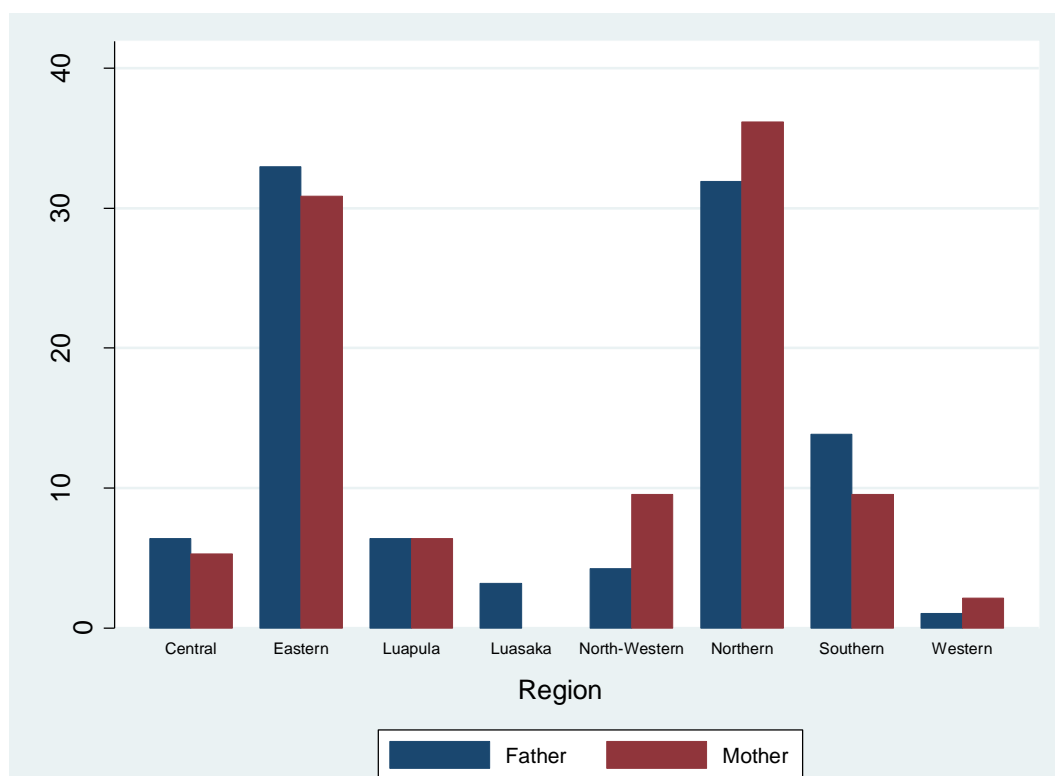
**Table 1: Characteristics of the study participants**

Characteristics n=94	n (%)
<b>Age-groups</b>	
6 – 15 years	49 (52.13%)
16 – 25 years	26 (27.66%)
26 – 35 years	12 (12.77%)
Above 36 years	7 (7.45%)
<b>Gender</b>	
Female	61 (64.89%)
Male	33 (35.11%)

Figure 2 shows that the majority of the respondents' fathers (32.98%) come from Eastern region and Northern (31.91%) and the least come from Western region (1.06%). There was no respondent from the Copperbelt region.

The majority of the respondents' mothers (36.17%) came from Northern followed by Eastern (30.85%) and the least (2.13%) came from Western. No respondents' mothers came from Lusaka and Copperbelt regions.

23.40% of the respondents had their both parents coming from Northern Province followed by 19.15% parents coming from Eastern province.



**Figure 2: Region of the parents**

Table 2 shows most respondents (24.47%) had their father coming from the Bemba tribe followed by Chewa and Tonga tribes (12.77%).

Highest respondents (31.19%) had their mothers coming from the Bemba tribe.

The majority (15.96%) of the respondents tend to have both parents coming from the Bemba tribe followed by Chewa (6.38%) and then Tonga (5.32%).

**Table 2: Tribe of parents**

<b>Tribe (father)</b>	<b>n (%)</b>	<b>Tribe (mother)</b>	<b>n (%)</b>
Bemba	23 (24.47%)	Bemba	30 (31.91%)
Chewa	12 (12.77%)		
Tonga	12 (12.77%)	Nsenga	11 (11.70%)
Nsenga	8 (8.51%)		
		Tonga	9 (9.57%)
Tumbuka	7 (7.45%)		
Mambwe	5 (5.32%)	Chewa	8 (8.51%)
Namwanga	5 (5.32%)		
Ngoni	4 (4.26%)	Kaonde	6 (6.38%)
Soli	4 (4.26%)	Mambwe	5 (5.32%)
Lenje	3 (3.19%)	Ngoni	5 (5.32%)
		Kunda	3 (3.19%)
Others	14 (14.89%)	Others	17 (18.09%)

Others – tribe of father included: Aushi (1), Ila (1), Kaonde (1), Kunda (1), Luvale (1), Swaka (1), Lala (2), Lunda (2), Mbunda (1).

Others – tribe mother include: Aushi (1), Bisa (2), Chokwe (1), Kaonde-Ila (1), Lala (2), Lenje (2), Lozi (2), Lunda (1), Luvale (1), Namwanga (2) and Tumbuka (2)



In table 3, majority of the respondents (72.34%) had 0-10 number of admissions while the least number of admissions (1.06%) was between 21 -30.

**Table 3: Total number of admissions**

<b>Total Number of Admissions, n=94</b>	<b>n (%)</b>
No of admissions	
0 – 10	68 (72.34%)
11 – 20	20 (21.28%)
21 – 30	1 (1.06%)
31 and above	5 (5.32%)

The number of hospital admissions per year of life was used to calculate the severity of disease. This was done by dividing number of admissions by age of the subject.<sup>17</sup> Most (44.68%) of the subjects had between 0 and 0.3 admissions per year of life (Table 4).

**Table 4: Systemic Severity – Admissions per year of life**

<b>Admissions per year of life n=94</b>	<b>n (%)</b>
Number of Admissions	
0 – 0.3	42 (44.68%)
0.4 – 0.7	34 (36.17%)
0.8 – 1.0	8 (8.51%)
Above 1.1	10 (10.64%)

The findings in Table 5 shows that painful crises were the most common reason for admissions (82.98%) among the respondents followed by severe anaemia (68.09%).

**Table 5: Systemic History - Reasons for Admission**

Reasons for Admission n=94	n (%)
*Painful crises	78 (82.98%)
Severe anaemia	64 (68.09%)
Febrile illness	53 (56.38%)
Stroke	5 (5.32%)
Others+	18 (19.15%)

\*Painful crises included: abdominal pain, chest pain, bone pain & ear pain.

+Other reasons for admission included headache (4), meningitis (2), priapism (2), body swelling (1), nose bleeding (1), swelling of eyes (1), leg ulcers (1), pneumonia (1), rheumatic heart disease (1), swollen arm (1), and trauma (1)

Table 6 shows that the commonest presenting complaint was colour change of eyes (51.06%) followed by difficulty seeing (24.47%).

**Table 6: Ocular History**

<b>Variable</b>	<b>n (%)</b>
Difficulty in seeing, n=94 people	
Yes	23 (24.47%)
No	71 (75.53%)
Eye with difficulties, n=23 people	
Left eye only	2 (8.70%)
Right eye only	2 (8.70%)
Both eyes	19 (82.61%)
Pain in the eyes, n=94 people	
Yes	12 (12.77%)
No	82 (87.23%)
Painful eye, n=12 people	
RE only	1 (8.33%)
Both eyes	11 (91.67%)
Any colour change, n=94 people	
Yes	48 (51.06%)
No	46 (48.94%)
What colour n=48 people	
Red	1 (2.08%)
Yellow	46 (95.83%)
Brown	1 (2.08%)
Eye with colour change n=48 people	
Both	48 (100.00%)

### **Visual acuity**

Table 7 shows that most respondents 90(95.65%) had normal vision. The prevalence of blindness was 1(1.06%).

**Table 7: Visual Acuity in the affected eye**

<b>Visual acuity n=94 people</b>	<b>n (%)</b>
Normal vision	90 (95.74%)
Visual Impairment	3 (3.19%)
Severe visual impairment	0
Blind	1 (1.06 %)

**Clinical examination findings**

As shown in Table 8, conjunctival sickle sign was present in 40.43% of the patients. Most of the respondents (80.85%) had no jaundice at the time of examination.

**Table 8: Conjunctiva findings**

<b>Findings , n=94</b>	<b>n (%)</b>
Normal	56 (59.57%)
Conjunctival sickle sign	38 (40.43%)
Jaundice	
Yes	18 (19.35%)
No	76 (80.85%)

Concerning other anterior segment findings, 1(1.06%) patient had an irregular pupil due to posterior synechia. Two (2.13%) patients had iris atrophy. Two (2.13%) patients had cataracts; 1 was a child with retinal detachment while the other was an adult who had a posterior sub-capsular cataract.

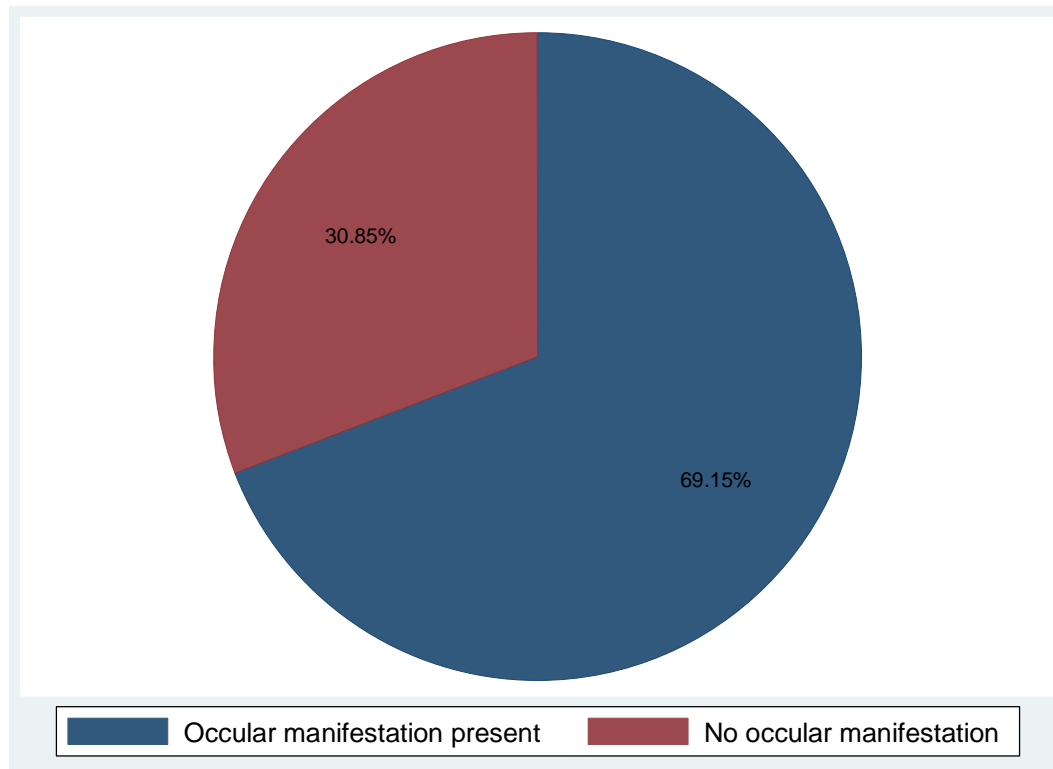
Table 9 shows that 56.38% of the patients examined had fundus findings. 3.18% were vision threatening, these included: macular hole (1.06%), epiretinal membrane (1.06%) and retinal detachment (1.06%). The overall prevalence of vision threatening ocular manifestations of SCD in this study was 5.31% when cataract as a cause was included.

**Table 9: Fundus examination findings**

<b>Fundus sign, n=94</b>	<b>n (%)</b>
<b>Non-Proliferative fundus signs</b>	
Vessel tortuosity	41 (43.62 %)
Salmon patch haemorrhage	1 (1.06%)
Black sun burst	4 (4.26%)
Angiod streak	1 (1.06%)
Schisis cavity	2 (2.13%)
Macular hole	1 (1.06%)
Epiretinal membranes	1 (1.06%)
Hair Pin at Disc (Disc sign)	1 (1.06%)
<b>Proliferative fundus signs</b>	
Retinal detachment	1 (1.06%)
<b>Normal</b>	<b>41 (43.62%)</b>

### **Prevalence of ocular manifestations**

Figure 3 shows that 69.15% (95%CI: 58.78-78.27) of our respondents had ocular manifestations of SCD



**Figure 3: Prevalence of ocular manifestation of sickle cell disease**

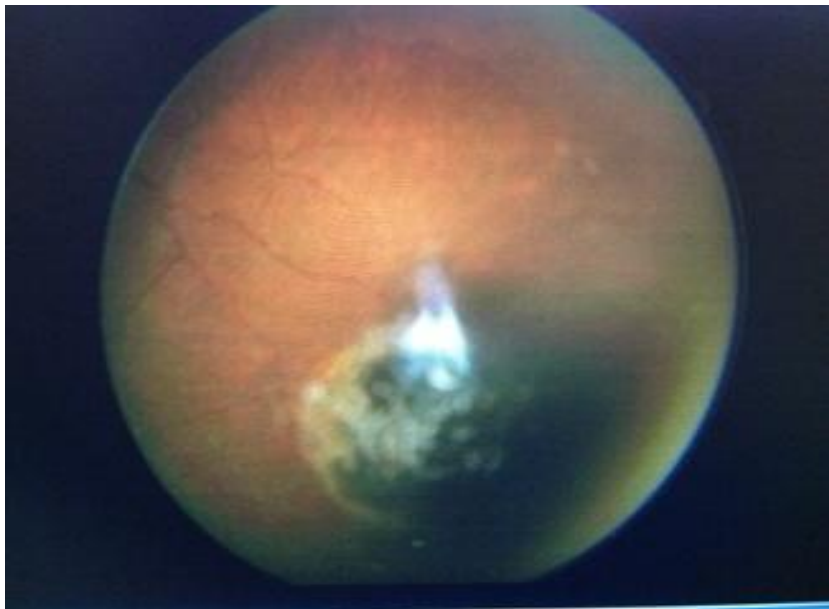
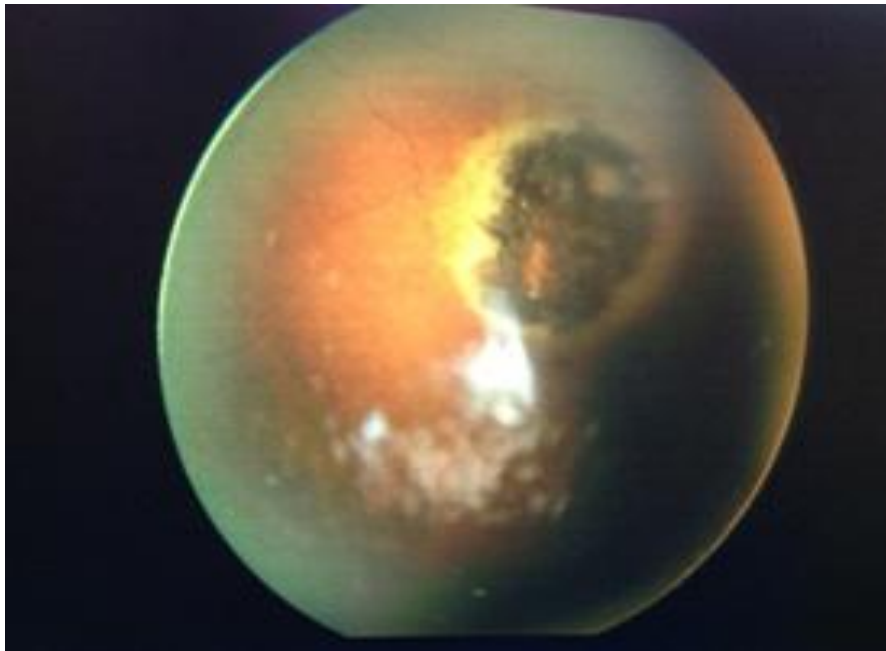
The Univariate analysis in Table 10 shows that only age had statistically significant association with ocular manifestation. The age groups with significant findings were 26 – 35 years and above 36 years.

There was no statistically significant association between gender, severity and the ocular manifestation ( $p>0.05$ ).

**Table 10: Univariate analysis on factors influencing ocular presence among the sickle cell patients**

Factor	Ocular Manifestation (n=94)			
	N	n (%)	OR (95% CI)	p-value
<b>Gender</b>				
Male	33	23 (69.70%)	<b>1.00 (Ref)</b>	
Female	61	42 (68.85%)	1.04 [0.42-2.61]	0.933
<b>Age-groups</b>				
6 – 15 years	49	39 (79.59%)	<b>1.0 (Ref)</b>	
16 – 25 years	26	20 (76.92%)	0.85 [0.27-2.69]	0.788
26 – 35 years	12	5 (41.67%)	0.18 [0.05-0.70]	0.013
Above 36 years	7	1 (14.29%)	0.04 [0.005-0.40]	0.006
<b>Severity</b>				
0 – 0.3	42	30 (71.43%)	<b>1.0 (Ref)</b>	
0.4 – 0.7	34	23 (67.65%)	0.84 [0.31-2.23]	0.721
0.8 – 1.0	8	5 (62.50%)	0.67 [0.14-3.24]	0.615
Above 1.1	10	7 (70.00%)	0.93 [0.21-4.22]	0.929

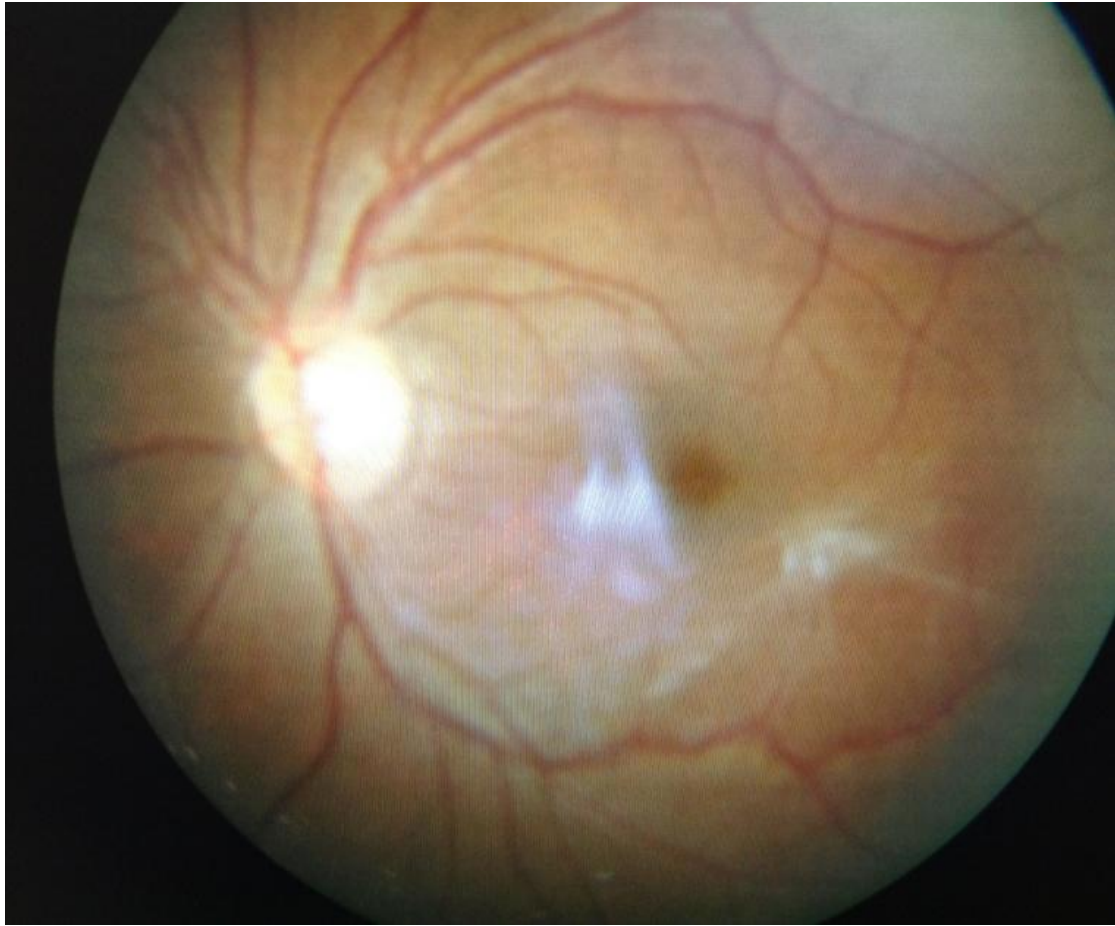
Black sunburst in a 24 year old male, about 1.5DD in size. Lesion located infero-temporal, 3DD away from macular and did not affect vision.



**PHOTO 1**

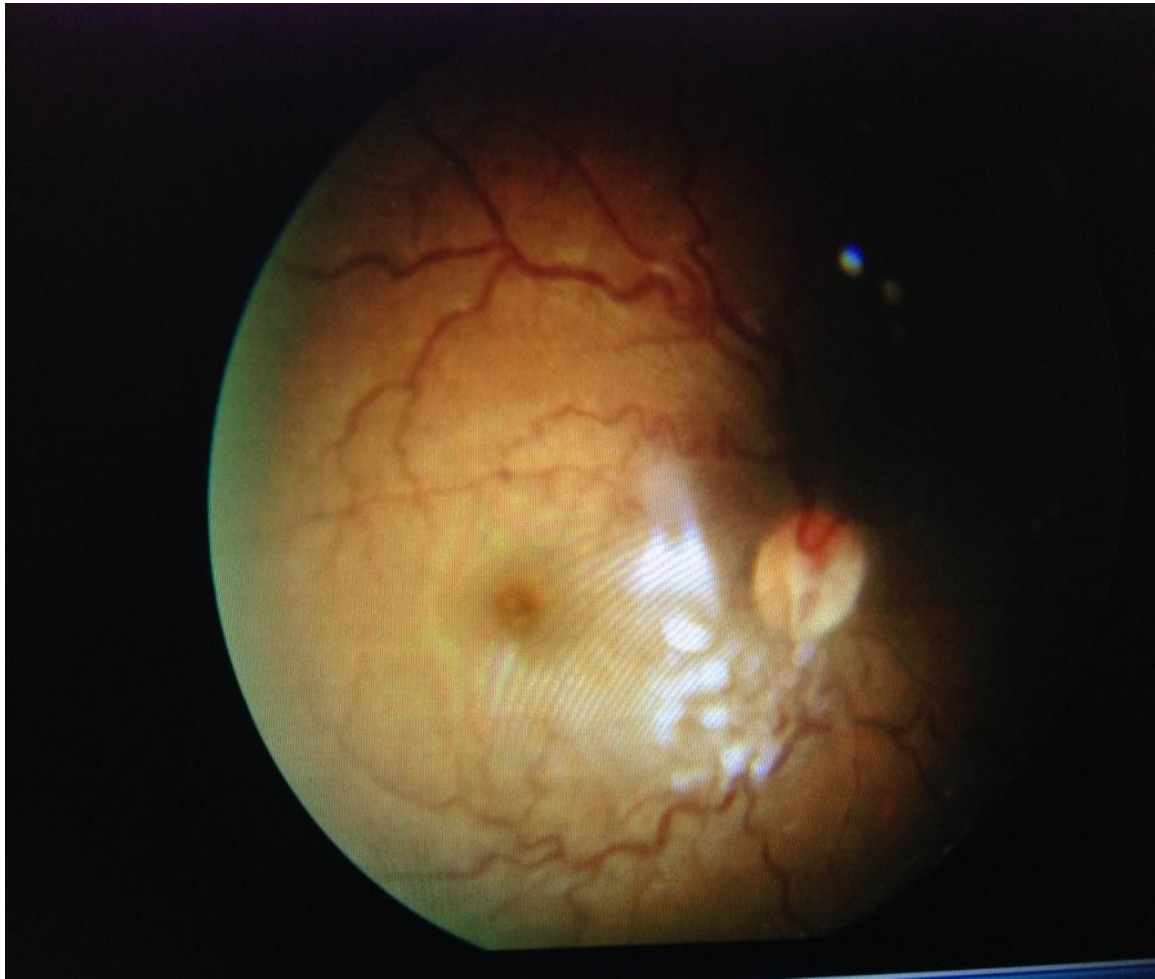

Epiretinal membranes 1 DD in a 32 year old female patient. Vision was not affected.



**PHOTO 2**

Tortuous retinal vessels in a 26 year old female patient.



**PHOTO 3**

## 7.0 DISCUSSION

This study revealed that ocular manifestations of SCD were common among patients at the University Teaching Hospital, in Lusaka, Zambia.

Only one genotype of SCD, HbSS and this finding was similar to what Ashworth TG et al found in a 1969 survey done in Zambia. Unlike in West Africa no HbSC was found in the survey<sup>11</sup>. Abdi et al, in East Africa also found HbSS only.<sup>16</sup>

The prevalence of 69.15% reported in this study was comparable to previous studies done before, which showed a prevalence range of 34-90%.<sup>23, 28, 55</sup> This variation has been as a result of a number of reasons: different age groups have been studied in various studies, for example, Kaimbo et al in Democratic Republic of Congo studied only children up to age of 18 years. In our study, the respondents were much older ranging from 6 to 61 years old. In addition, different methodologies applied in data collection such as the use of optic coherent tomography (OCT) and fluorescein angiography (FLA) to detect ocular manifestations such as maculopathies and retina ischaemia of which could have been missed in our study as we did not use these equipments. Therefore, the prevalence could have been higher than what was reported in this study if OCT and FLA had been used. The prevalence for visually threatening ocular manifestations was 5.31%. This included: retinal detachment, cataract, epiretinal membrane and macular hole.

With regard to increase in ocular manifestation of SCD, the results of this study are comparable to findings of other studies conducted in Africa. They show an increase in life expectancy among SCD. In a 1969-1971 study by Barclay, he found more than 60% of patients not surviving beyond age of 12 years.<sup>12</sup> An improvement in the care of SCD patients probably explains the increased life expectancy. Currently, patients are routinely followed up and those with severe disease are treated accordingly hence the reduction in mortality.

Our findings revealed that age had a statistically significant association with occurrence of ocular manifestations of SCD owing to the fact that the age of the patient was an indicator of the duration of disease. There is a higher likelihood of

finding ocular manifestations in older patient than in the younger patients. These findings are comparable to other findings reported.<sup>34, 40, 41</sup> Age was a direct indicator of duration of disease.

The majority of the patients examined during this study were females (64.89%) and the female to male ratio of 1.8:1. However, there was no association of sex to ocular manifestations. These findings were similar to other studies done in East and West Africa<sup>16, 17</sup> where it was reported that more females attended routine medical follow-up visits in our study. Most of the children were brought to the clinic by their female care-givers. This could be explained by the traditional practice of females being compliant to follow-up as compared to their male counterparts. Other studies have shown no gender difference in prevalence of SCD.<sup>56</sup>

Majority of the respondents (23.40%) had both their parents with origins of Northern Province followed by 19.15% parents coming from Eastern province. The least affected region was Western Province. There were no patients coming from Copperbelt province. The Bemba tribe had the highest number of respondents affected (15.96%) followed by the Chewa and then Tonga tribes. No previous studies have been done before in the country to compare with. The Bemba tribe who had the highest prevalence originates from the Northern province. This explains why Northern Province had the highest prevalence of SCD.

On systemic severity of disease of sickle cell, total number of admissions and number of admissions per year of life due to sickle cell crisis was used to ascertain systemic severity<sup>17</sup>. Only one study was found in literature that studied systemic severity. The majority of the respondents 68(72.34%) had less than 10 admissions. 5.32% of the subjects studied had the highest number of admissions, a total of more than 31 admissions. The number of admissions per year of life was used to assess the systemic severity. However, in this study, there was no significant influence of systemic severity of sickle cell disease on ocular manifestations ( $p= 0.615$ ). This is contrary to what one would expect. SCD is a systemic disease; the more severe the disease is the more end organ damage one would expect including damage to ocular structures. The fact that these findings are different from what is expected justifies the need for another study.

Among ocular complaints, the commonest reported symptom was eye discoloration reported by 51.06% of the respondents. Of these, 46 (95.83%) reported yellowing of eyes. Yellowing of eyes explains the presence of jaundice resulting from haemolysis due to the haemolytic crisis common in HbSS. This can also be explained by the commonest reason of hospital admission being severe anaemia. The results are similar to the findings reported in East Africa.<sup>16</sup> On examination, jaundice was found in 18(19.35%) of the 94 patients examined in the study. This was lower than that reported by patients' symptoms. This marked difference could be explained by the fact that subjects responded yes to having yellowness of eyes even though they did not have the symptom at the time they were seen but had the symptom in the past. Akinsola FB. Et al in Nigeria reported 50.50% presence of jaundice among patients enrolled.<sup>37</sup>

Visual acuity findings were similar to other findings reported.<sup>16, 17, 19</sup> Majority (95.65%) of the patients had normal best corrected visual acuity (BCVA) according to WHO classification. Three (3.26%) of patients had visual impairment of which one patient had pale discs and the other had posterior sub capsular cataract and the third patient had a macular hole. Only one (1.06%) was blind. The patient had old retinal detachment.

Conjunctival findings found in this study consisted of conjunctival sickle sign and jaundice. The conjunctival sign consisted of tortuous vessels and comma shaped vessels.<sup>15</sup> 40.43% of the patients in this study had conjunctival sign. Different prevalence in different studies have been found; ranging from 32 – 87%. Kaimbo et al in Central Africa found 32%; Osafo- kwako et al in Ghana found 53% ; Clarkson J. found 70%; Abdi et al in Kenya found 87%.<sup>28, 17, 1, 16.</sup>

Only two (2.13%) patients had iris atrophy. This is comparable to the reported findings by Osafo-Kwako et al of 3.5% of HbSS patients among Ghanaian subjects.<sup>17</sup> There was no rubeosis and iris depigmentation among the patients enrolled. 2.13% of the patients enrolled had cataracts. One was a 6 year old child with retinal detachment in one eye and the other was a 61 year old man with bilateral posterior sub capsular cataract.

All the patients seen had intra-ocular pressures of less than 21mmHg. This is similar to the findings in Kenya among patients with HbSS.<sup>16</sup> This does not however mean that there is less glaucoma in SCD patients, probably this is because the patients with HbSS studied tend to be younger. Only one patient in our study was aged above 40 years. Higher intra-ocular pressures have commonly been reported in patients with HbSC.<sup>17</sup>

Retinal vessel tortuosity was found among 44.09% of the enrolled subjects. Tortuosity of vessels has been reported among patients with HbSS ranging from 6% to as high as over 50 % of the subjects.<sup>16, 17, 23, 28, 36</sup> The variable prevalence of retina vessel tortuosity is as a result of differences in populations studied that differed in age groups and subjective interpretations of vessel tortuosity by different researchers.

Black sunburst was the second commonest posterior segment finding. This was reported in 4.403% of the subjects. Black sunbursts tend to occur commonly in subjects with HbSC. All our subjects in this study had HbSS. Our findings are similar to others reported in West Africa, 5.0%.<sup>17</sup>

Angioid streaks were reported in 2.15% of the subjects enrolled. This is slightly lower than that found in Jamaican patients by Hamilton AM. Et al of 8.68%.<sup>32</sup> The variation can be due to missed diagnosis of early angioid streaks on fundoscopy as the best way to diagnose angioid streaks is by using fundus fluorescein angiography where they appear as window defects. In this study, fluorescein angiography was not done.

Salmon patch haemorrhage was reported in one (1.08%) patient who was 20 year old. The patch was small and located in superior nasal aspect of the retina. The patient was advised for frequent ophthalmological reviews. This prevalence found was less than that the 6.4% reported by Obikili et al in Nigeria among patients with HbSS.

Schisis cavity was found only in one patient (1.0%). Abdi et al did not find any patient with schisis cavity in similar patients with HbSS.<sup>16</sup>

Epiretinal membranes were reported in 4% by Moriarty et al among Jamaican patients with HbSC and HbSS.<sup>48</sup> In this study, epiretinal membranes were found in one (1.08%) patient. The difference could be due to the differences in genotype of the

patients seen in our study and the Jamaican study. Clarkson J however reported 2.8% of HbSS patients had epiretinal membranes.<sup>1</sup>

A macula hole was found in one (1.08%) patient, a 32 year old patient in one eye. She had severe visual impairment and was on follow-up by vitreoretinal surgeon. The literature search did not reveal any patient with SCD who had had been reported to have macula hole in our region (East, Central and Southern Africa). Clarkson reported 1.8% cases of macula hole among HbSS patients. No patient with HbSC had a macular hole.<sup>1</sup>

Only one (1.08%) patient was found to have proliferative sickle retinopathy diagnosed on ultra sound. She was a 6 year old who had an old retinal detachment when she was 3 years old. The findings are similar to what was reported among Kenyan patients with HbSS where only one patient was reported to have proliferative sickle retinopathy.<sup>16</sup> A prevalence of as high as 45% among patients with HbSC has been reported Friberg et al.<sup>43</sup>

The prevalence of blindness among patients with SCD was 1.06%, which is high by World Health Organization standard which estimated a global prevalence of 0.57% and 1.00% for African region in 2002.<sup>56</sup> However, the sample size was too small to accurately measure this prevalence. A study with a bigger sample size is required.

## **7.1 CONCLUSION**

It was concluded that:

- All the subjects with SCD had HbSS.
- Ocular manifestations of SCD occurred in 69.15% of the patients attending the University Teaching Hospital (UTH), Lusaka, Zambia.
- SCD occurs commonly among the Bemba and the Chewa tribes who are found in the Northern and Eastern provinces of Zambia, respectively.
- Ocular manifestations were associated with age.
- There was no association between sex and systemic severity with ocular manifestations of sickle cell disease.

- The commonest systemic symptom found was painful crises while the commonest ocular symptom was yellowness of eyes.
- Vascular tortuosity was the commonest ocular manifestation of sickle cell disease. The prevalence of blindness among patients with SCD was high.

## **7.2 RECOMMENDATIONS**

It was recommended that:

- All patients with sickle cell disease should have at least one ophthalmic examination in childhood and a more frequent follow up in adulthood.
- Physicians (haematologists) should refer all SCD patients with ocular complaints to ophthalmologists for further assessment.
- A further study should be done in Northern and Eastern provinces where sickle cell is commonest with a larger number of subjects to increase the power of the study.

## **7.3 LIMITATIONS OF THE STUDY**

Lack of fluorescein angiography result in reduction of reported retinal findings because early vascular changes could have been missed.

Due to lack of Optical Coherent Tomography (OCT), fundus findings such as epiretinal membranes, macular oedema and macular hole could have been under reported.

Biasness could have been increased by the findings of cataract. Cataract could have been due to other causes like age-related. It was difficult to distinguish cataract from other causes hence it was included in prevalence calculation. Most studies have found the prevalence of cataract among patients with SCD.



## REFERENCES

1. Clarkson J. The ocular manifestations of sickle-cell disease: a prevalence and natural history study, *Tr. Am. Ophth. Soc.* 1992; 90:481-504.
2. Meakaron JE, Taher AT. Sickle Cell Anaemia (Internet). Available from: [www.emedicine.medscape.com/article/205926-overview](http://www.emedicine.medscape.com/article/205926-overview). Accessed February, 2013.
3. Grosse SD, Odame I, Atrash HK, et al. Sickle cell disease in Africa a neglected cause of early childhood mortality. *Am. J. Prev. Med.* 2011;41(6S4):S398–S405
4. Redding L, Knoll C, Sickle cell disease-pathophysiology and treatment, *Curr Probl Pediatr Adolesc Health Care.* 2006 Nov-Dec; 36(10):346-76.
5. Lima CS, Rocha EM, Silva NM, et al. Risk factors for conjunctival and retinal vessel alterations in sickle cell disease, *Acta Ophthalmol Scand.* 2006 Apr;84(2):234-41.
6. Graham RS. Sickle-cell disease, *The Lancet*, 1997 Sept; 350(9079): 725 - 730
7. Wellem's TE, Hayton K, Fairhurst RM. The impact of malaria parasitism: from corpuscles to communities, *J Clin Invest.* 2009 Sep; 119(9):2496-505.
8. Sickle Cell Society. Standards for the Clinical Care of Adults with Sickle Cell Disease in the UK, 2008 (Internet). Available from: [www.sicklecellsociety.org/app/webroot/files/files/CareBook.pdf](http://www.sicklecellsociety.org/app/webroot/files/files/CareBook.pdf). Accessed December 2012.
9. Weatherall DJ, Clegg JB. Inherited haemoglobin disorders: an increasing global health problem. *Bull. World Health Organ.* 2001; 79: 704-12
10. Embury SH, Vichinsky EP, Haematology, Basic Principles and Practice, 3<sup>rd</sup> edition. London; Churchill Livingstone. 2000.
11. Ashworth TG, Macpherson F. A tribal analysis of the sickle cell trait and blood group distribution in Zambia. *Trans R Soc Trop Med Hyg* (1968) 62(1): 76-83.
12. Barclay GP. Sickle cell anaemia in Zambia. *Trans R Soc Trop Med Hyg* 1971;65:529 –30.
13. Athale UH, Chintu C. Clinical analysis of mortality in hospitalized Zambian children with sickle cell anaemia. *East Afr Med J* 1994; 71:388 –91.
14. World Health Organization. Report of a joint WHO–March of Dimes meeting: management of birth defects and haemoglobin disorders. Geneva, Switzerland: World Health Organization, 17–19 May 2006.

15. Lehmann H, Huntsman RS, Casey R, et al. Williams Haematology, 6<sup>th</sup> edition, Toronto; McGraw-Hill. 2001.
16. Abdi DS, Ilako DR, Schaller U, et al. Ocular features in patients with sickle cell disease seen at Kenyatta National Hospital, Postgraduate thesis. Department of Ophthalmology, University of Nairobi, 2005.
17. Osafo-Kwaako A, Kimani K, Ilako D, et al. Ocular manifestations of sickle cell disease at the Korle-bu Hospital, Accra, Ghana. *Eur. J. Ophthalmol.* 2011 Jul-Aug; 21(4):484-9.
18. Skuta GL, Cantor LB, Weiss JS. Retina and Vitreous, American Academy of Ophthalmology. AAO USA. 2011 -2012, 12: 132-137.
19. Van Meurs JC. Vision-threatening eye manifestations in patients with sickle cell disease in Curacao. *Ned Tijdschr.* 1990 Sept 15; 134(37): 1800-2.
20. Ganesh A, William RR, Mitra S, et al. Orbital involvement in sickle cell disease: A report of five cases and review literature, *Eye (Lond)*. 2001 Dec;15(Pt 6):774-80
21. Acheason RW, Ford SM, Maude GH, et al. Iris atrophy in sickle cell disease. *Br J. Ophthalmol.* 1986 Jul; 70(7): 516-21
22. Bergren RL, Brown GC, Neovascular glaucoma secondary to sickle-cell retinopathy, *Am. J. Ophthalmol*; 1992, 113(6);718-719.
23. George IO, Cookey SAH, Eye manifestations of children with homozygous sickle cell disease in Nigeria. *J. Med. Med. Sci.* 2012 May; 3(5): 302-305.
24. Sayag D, Binaghi M, Souied EH, et al. Retinal photocoagulation for proliferative sickle cellretinopathy: A prospective clinical trial with new sea fan classification. *Eur. J. Ophthalmol.* 2008. 18(2): 248 – 254
25. Condon PI, Whitelocke RAF, Bird AC, et al. Recurrent visual loss in homozygous sickle cell disease, *Br J Ophthalmol.* 1985 September; 69(9): 700–706
26. Acacio I, Goldberg MF. Peripapillary and macular vessel occlusions in sickle cell anemia. *Am J Ophthalmol* 1973; 75:861-6.
27. Chopdar A. Multiple major retinal vascular occlusions in sickle cell haemoglobin C disease. *Br J Ophthalmol.* 1975 September; 59(9): 493–496
28. Kaimbo Wa Kaimbo D, Ngiyulu Makuala R. Ocular findings in children with homozygous sickle cell disease in the Democratic Republic of Congo, *Bull Soc Belge Ophtalmol.* 2000; 275:27-30.
29. Obikili AG, Oji EO, Onweukeme KE. Ocular findings in homozygous sickle cell disease in Jos, *Nigeria. Afr J Med Sci* 1990 Dec; 19(4): 245-50.

30. Roy H, Jayne RP, Ophthalmic manifestations of sickle cell disease (Internet). Available from: [www.emedicine.medscape.com/article/1918423-overview](http://www.emedicine.medscape.com/article/1918423-overview). Accessed January 2013.
31. Asdourian G, Nagpal KC, Goldbaum M, et al. Evolution of the retinal black sunburst in sickling haemoglobinopathies *Br J Ophthalmol*. 1975 December; 59(12): 710–716
32. Hamilton AM, Pope FM, Condon PI, et al. Angioid streaks in Jamaican patients with homozygous sickle cell disease. *Br J Ophthalmol*. 1981 May; 65(5): 341–347
33. Bonnet P. Les stries angioides de la retina. *Arch Ophthalmol* (Paris) 1933; 50:721-50.
34. Babalola OE, Wambebe CO. When should children and young adults with sickle cell disease be referred for eye assessment? *Afr J Med Med Sci*. 2001 Dec; 30(4):261-3.
35. Serjeant G.R. Sickle Cell Disease. 2<sup>nd</sup> Ed. New York; Oxford University Press. 1992, 21:247-250.
36. Condon PI, Serjeant GR, Behaviour of untreated proliferative sickle retinopathy, *Br J Ophthalmol*, 1980, 64, 404-411.
37. Akinsola FB, Kehinde MO. Ocular findings in sickle cell disease patients in Lagos. *Niger. Postgrad. Med. J*. 11(3):203-6.
38. Ed.Duane T, Jeager E, Sickle cell retinopathy in Clinical Ophthalmology. Philadelphia; Harper and Row publishers, 3(17):1-45.
39. Talbot JF, Bird AC, Serjeant GR, et al. Sickle cell retinopathy in young children in Jamaica, *Br J Ophthalmol*, 1982, 66, 149-154.
40. Condon PI, Serjeant GR, Behaviour of untreated proliferative sickle retinopathy, *Br J Ophthalmol*, 1980, 64, 404-411.
41. Hayes RJ, Condon PI, Serjeant GR. Haematological factors associated with proliferative retinopathy in homozygous sickle cell disease. *Br. J. Ophthalmol*. 1981 Jan; 65(1):29-35.
42. Fox PD, Vessey SJ, Forshaw ML, et al. Influence of genotype on the natural history of untreated proliferative sickle retinopathy-an angiographic study. *Br J Ophthalmol*. 1991 Apr; 75(4): 229-31.
43. Friberg TR, Young CM, Milner PF. Incidence of ocular abnormalities in patients with sickle haemoglobinopathies. *Ann Ophthalmol*. 1986 Apr; 18(4): 150-3.

44. Balo KP, Mensah A, Mihluedo H, et al. Haemoglobinopathies and retinopathies in Lome UHC. *J Fr Ophthalmol* 1996; 19(8-9): 497-504.
45. Babalola OE, Wambebe CO. Ocular morbidity from sickle cell disease in a Nigerian cohort. *Niger Postgrad Med J* 2005 Dec; 12(4): 241-4.
46. Al-Salem, Ismail L. Ocular manifestations of sickle cell anaemia in Arab children. *Ann Trop Paediatr.* 1990; 10(2): 199-202.
47. Kampik A, Kenyon K, Michels RG, et al. Epiretinal and vitreous membranes. *Arch. Ophthalmol.* 1981 Aug; 99(8):1445-54.
48. Moriarty BJ, Acheson RW, Serjeant GR, Epiretinal membranes in sickle cell disease, *Br J Ophthalmol*, 1987, 71, 466-469.
49. Goldberg MF, Jampol LM. Treatment of neovascularisation, vitreous haemorrhage, and retinal detachment in sickle cell retinopathy. In symposium on medical and surgical diseases of the retina and vitreous; *Transactions of the New Orleans Academy of Ophthalmology*. St. Louis, CV Mosby Co, 1983, 1983;53-81.
50. Kimmel AS, Magargal LE, Tasman WS. Proliferative sickle retinopathy and neovascularisation of the disc: regression following treatment with peripheral retinal scatter laser. *Ophthalmic Surg*, 1986; 17: 20-22.
51. Yanoff M, Duker JS. *Ophthalmology*. 3rd edition, New York: Mosby Elsevier Inc. 2009. section 6.
52. WHO. (2006). Sickle cell Disease in the African Region: current situation and way forward. Fifty-sixth session, Addis Ababa, Ethiopia, 28 August–1 September 2006.
53. Quinn CT, Rodgers ZR, Buchanan GR. Survival of children with sickle cell disease. *Blood*. 2004 June 1; 103(11); 4023-7.
54. Thrusfield M, *Veterinary Epidemiology*, 3rd edition, Ames, Iowa, USA; Blackwell Publishing Professional, 2005.
55. Elebesunu-Amadasu M, Okafor LA, Ocular manifestations of sickle cell disease in Nigerians; experience in Benin City, Nigeria *Trop Geogr Med*. 1985 Sep;37(3):261-3.
56. Resnikoff S, Pascolini D, Etya'ale D, et al. Global data on visual impairment in the year 2002. *Bull World Health Organ* 2004; 82:844-851. Epub 2004 Dec 14.

## APPENDICES

### APPENDIX I: QUESTIONNAIRE

Study No..... Date..... IP No. ....

Ward ..... Clinic: ..... Genotype: .....

#### DEMOGRAPHICS:

1 Age in years: .....

2. Gender: 1: Male....; 2: Female .....

3. Tribe: Mother..... Father.....

4. Region: Mother..... Father.....

#### SYSTEMIC HISTORY

Hospital admissions:

1 Number of admissions .....

2 Reasons for admissions

- i) Severe anaemia
- ii) Fever/Malaria
- iii) Abdominal pain
- iv) Chest pain
- v) Bone pain
- vi) Stroke
- vii) Others .....

#### OCULAR HISTORY:

1. Are you experiencing difficulties in seeing?

Yes..... No.....

If yes, which eye? Right eye..... Left eye..... Both eyes.....

2. Are you experiencing pain in the eyes?

Yes..... No.....

If yes, which eye? Right eye..... Left eye..... Both eyes.....

3. Have you noticed any colour changes of your eyes?

Yes..... No.....

If yes, what colour.....

Which eye? Right eye..... Left eye..... Both eyes.....

4. Are you experiencing any foreign body sensation in your eyes?

Yes..... No.....

If yes, which eye? Right eye..... Left eye..... Both eyes.....

### GENERAL OCULAR EXAMINATION

<b>Visual acuity</b>	RE	LE
At presentation		
BCVA		

EXAMINATION	RE	LE
<b>Proptosis</b>		
<b>EOMM</b>		
<b>Pupillary reaction</b>		
<b>Tonometry</b>		

**ADNEXA/ANTERIOR SEGMENT**

RE

LE

Peri-ocular changes:

Eye lids:

Conjunctiva:

- i) Vessels
- ii) Injection
- iii) Jaundice

Cornea:

A/C:

Pupil:

Iris:

- i) Depigmentation
- ii) Atrophy
- iii) Rubeosis

Lens:

**POSTERIOR SEGMENT**

Vitreous:

Fundus:

1. Disc condition (1:Normal; 2:Swollen; 3: Pallor; 4: Other-specify)

	RE	LE
Condition		

2. Macula status (1:Normal; 2:Neovascularisation; 3: Hole; 4:Pigmentation; 5:others-specify) .....

	RE	LE
Condition		

3. Vessels condition (1:Normal; 2:Occluded; 3:Tortuos; 4:Others-specify).....

	RE	LE
Condition		

4. Retina (1:Normal; 2:Ischaemic; 3:Angiod streaks; 4:Haemorrhages; 5:Neovascularisation; 6:Black sunburst; 7:Schisis cavity; 8:Retinal detachment; 9:Others-specify) .....

	RE	LE
Condition		

5. Fundus photography (1:Normal; 2:Abnormal)

	RE	LE
Condition		

Fundus drawing/photo documentation



## **APPENDIX II: PARTICIPANT INFORMATION FORM**

**TITLE OF THE RESEARCH STUDY: *OCULAR MANIFESTATIONS OF SICKLE CELL DISEASE AMONG PATIENTS AT THE UNIVERSITY TEACHING HOSPITAL, LUSAKA, ZAMBIA***

**PRINCIPAL INVESTIGATOR: DR. BWALYA W. MUMBI**

**ADDRESS: Department of Ophthalmology, University of Nairobi, Kenyatta National Hospital, P.O. Box 19676-00202, Nairobi, Kenya.**

**CONTACT NUMBER: +260 977 810 542 / +254 788 783 546**

### **1 Introduction**

I am Dr. Bwalya W. Mumbi, currently pursuing my studies in Master of Medicine in Ophthalmology at the University of Nairobi in Kenya. I am carrying out a research study on the ocular manifestations of Sickle Cell Disease among patients at the University Teaching Hospital, Lusaka, Zambia.

You are invited to take part in this research study. This is because you have Sickle Cell Disease.

### **2 What is the purpose of this research?**

The aim of this study is to document findings in the eyes of patients with sickle cell disease. There has been no similar study done in Zambia before to provide knowledge on the effects of this disease on the eyes. Findings of this study could provide information needed to prevent blindness.

### **3 What does participation in this research involve?**

Consent form will be signed prior to any study assessments being performed. The procedure will involve research assistants who will ask you questions on age, tribe and questions related to your disease. Visual assessment will be done and your eyes will be examined using a number of instruments. An eye drop in each eye will be administered and repeated after 10 minutes until your pupils become dilated. This is to enable us to fully examine the back of your eye.

#### **4 What are the possible risks?**

The eye drop may give you a temporal stinging sensation. Vision may be temporally blurred and you may have difficulties seeing from far and near clearly. This is because this medication dilates the eye and this effect may also cause the eyes to be sensitive to light causing glare. Use caution or suspend activities like driving or performing of activities that require clear vision until effects of the drug wear off. The effects are not permanent and last about 4-6 hours.

#### **5 What are the possible benefits of taking part?**

There is no material or financial gain in this study. However, it may provide valuable information on diagnosis, treatment and care of people with eye diseases as a result of sickle cell disease.

#### **6 Do I have to take part in this research project?**

Participation is voluntary; refusal to participate will involve no penalty or loss of benefits to which you are otherwise entitled. You may discontinue participation at any time without comment or penalty.

#### **7 What will happen to information about me?**

By signing the consent form, you consent to the study doctor and relevant research staff collecting and using personal information about you for the research study. Any information obtained in connection with this study that can identify you will remain confidential. Your information will only be used for the purpose of this study and it will only be disclosed with your permission, except as required by law.

#### **8 Who has reviewed the research project?**

All research in Zambia involving humans is reviewed by an independent group of people called University of Zambia Biomedical Research Ethics Committee. The ethical aspects of this research study have been approved by this committee

You/your child/dependent are hereby selected as one of the participants in this study, by the virtue of having Sickle cell Disease

Your participation will be highly appreciated.

Kindly sign the consent form if you voluntarily accept to be one of the participants.

For any clarifications, contact the principle investigator on the number given above or  
The University of Zambia Biomedical and Research Ethics Committee  
(UNZABREC) on Telephone: +260-1-256067.

**APPENDIX II: PEPALA YOTHANDIZA KUDZIWA ZA OTENGAKO MBALI MUTU WA KUFUFUDZA: ZIONETSERO ZA MANSO YA ANTHU NDI MATENDA A SICKLE CELL PAKATI PA ODWALA, PA CHIPATALA CHA UNIVERSITY TEACHING HOSPITAL, KU LUSAKA, ZAMBIA**

**PRINCIPAL INVESTIGATOR: DR. BWALYA W. MUMBI**

**ADDRESS: Department of Ophthalmology, University of Nairobi, Kenyatta National Hospital, P.O. Box 19676-00202, Nairobi, Kenya.**

**CONTACT NUMBER: +260 977 810 542 / +254 788 783 546**

**1. Mau otsogolera**

Ndine Dokotala Bwalya W. Mumbi. Pano, ndikuchita maphunziro, kuti ndipeze digili ya Mastala, pa nkhani yamankhwala Kuchipatala. Maphunziro yanga ndikupangila ku University ya Nairobi ku Kenya. Ndikupanga Mafufudzo, yofuna kudziwa zizindikiro zamatenda a Sickle Cell, kudzera kuyang'ana m'maso pakati pa anthu odwala pa chipatala cha University Teaching Hospital (UTH), mumzinda wa Lusaka. Ndinu oitanidwa kutengako mbali pa kufufudza umeneu, pakuti inu mulinayo matenda a Sickle Cell.

**2. Mafufudzo aya ndiya chiani?**

Mu kafufudza, tifuna kupeza zimene tikufuna. Tifuna kudziwa, ndi ku ziika pamodzi, zizindikiro zamatenda a Sickle kuyanjana ndi m'maso anu. Kufufudza kwamutundu uyu, kofuna kudziwa zizindikiro zamatend awa kudzera m'maso sikuna chitikepo muno mu Zambia. Zimene tinga peze pa kufufudza uku zinga thandize kupeza njila yo lesa kufa maso chifukwa chama tenda ya sickle cell.

**3. Nanga zofunika kutengako mbali mukufufudza uku ndizotani?**

Pepala yosonyeza kuti mwa vomera kutengako mbali iyenera ku sainidwa kufufudza kusana yambe. Othandizira, mu ku fufudza, adza kufunsani mafunso ang'ono, monga dzaka zanu, mtundu wanu ndi mafunso ya matenda anu. Tidzafufuza mmene maso anu akwanitsira kuona. Kuona kwa maso anu kuza pimidwa ndi zidwa zosiyana-siyana.

Tidza donthezera mankhwala m'maso mwanu ndiku bwereza pakapita mphindi khumi, mpaka maso a tseguke kuti kumbuyo ku pimidwe.

**4. Ndi zinthu zotani zinga dabwitse potenga malo muku fufudza uku?**

Muzamva tolasa pang'ono chifukwa cha Mankhwala amene tiza dontheza m'maso mwanu. Kayanganidwe kanu kadza cheperapo pa kanthawi kochepa chifukwa cha

mphamvu yamankhwala. Koma zonse izi zizango tenga kanthawi kang'ono, sizokhalisa ai.

#### **5. Nanga zabwino potengako mbali mu kufufudza uku ndi chiani?**

Simudza paciwa zinthu kapena ndalama pa ku tenga mbali mu mafufudzo awa. Koma, muza thandiza kubweretsa njira zopolezera manso mu anthu amene ali ndimatenda yamaso chifukwa cha matenda ya sickle cell.

#### **6. Kodi ndikofunikira kutenga kombali pa kufufudza uwu?**

Kutengako mbali pa kafufudza uku, mufunika kudzipereka. Sizo kakamiza ai. Palibe amene azalangidwa chifukwa chokana kutengako mbali. Ndipo ufulu umene mulinawo wo onedwa kuno kuchipatala sudzatengedwa kwainu, ai. Munga siye kutengako mbali, nangu mulipakati pa mafufudzo aya nthawi iriyonse mopanda chilango chilichonse.

#### **7. Kodi zokhuzana zanga siziza lengezedwa kuanthuena?**

Pamene mu saina pepala yoku vomereza kutengako mbali, mu gwirizana ndi dotolo komanso ndi akulu-akulu ena pa kafuku-fuku umeneu. Kugwiritsa nchito inu pakufufudza uyu, ndiku tsimikizira kuti nkhani zonse zimene tiza tenga zidza khala za chinsinsi. Choncho musa ope kuti nkhani yanu iza lengezedwa. Nkhani yanu idzango gwiritsidwa nchito pa kufufudza uku basi. Ndipo ngati tizafuna kuilengeza, inu muzafunika kuvomereza, monga lamulo ifunikila.

#### **8. Ndi ndani avomekeza kapena akuyanganira kufufudza uku?**

Mafufudzo alionse muno mu Zambia ya anthu yayangaridwa ndibungwe yochedwa University of Zambia Biomedical Research Ethics Committee (Bungwe yoyanganila kuti ma fufudzo ya mankhwala yagwiritsa nchito njira zoyenera 'ethics'). Kufufudza ko yenera pa mafufudzo ya anthu ya vomerezedwa ndi bungwe limeneli.

Inu, kapena mwana wanu, kapena munthu amene musunga, nonsenu mwa sankhidwa kutengakombali pa kufufudza uku chifukwa muli ndi matenda a Sickle cell.

Mukatengako mbali, tidza yamikira kwambiri.

Ndiku pemph mu saine pepala yosonyeza kuti mwa vomela kuzipeleka kutengako mbali mu kufufudza uku.

Ngati palizina zamene simunamvetsetse, koma mukufuna kumvetsa, imbani lamyakwa A principle Investigator pa namabala imene yapasidwa pa mwamba. Kapena Munga tumile ku University of Zambia Biomedical and Research Ethics Committee (UNZABREC) pa namba iyi: +260-1-256067.

**APPENDIX III: CONSENT FORM**

I.....of .....hereby  
give consent/accept to be included in the study

The nature of examination procedure has been explained to me and I fully understand  
what is to be done.

Date: ..... Signed: .....

I confirm that I have explained to the patient or relative the nature and effect of the  
examination procedure.

Date: ..... Signed: .....

**APPENDIX III: PEPALA YOSONYEZA KUTI MWAVOMERA NDIPO  
MWAVOMEREZEDWA**

Ine.....waku.....ndik  
udzipereka kuti nditengeko mbali pa kafuku-fuku.

Mmene kafuku-fuku udzachitikira andifotokozero bwino-bwino njira yake ndipo  
ndamvetsa zimene zikufunika kuchitika.

Tsiku: ..... Sainani: .....

Ndikutsimikiza kuti ndawamasulila odwala kapena abale awo zokhudzana ndi  
zochitika zonse pa kafuku-fuku.

Tsiku ..... Sainani: .....

**APPENDIX IV: ASSENT FORM FOR CHILDREN/DEPENDENTS.**

**(To be completed by the child and their parent/guardian)**

***TITLE OF STUDY: OCULAR MANIFESTATIONS OF SICKLE CELL DISEASE  
AT THE UNIVERSITY TEACHING HOSPITAL, LUSAKA, ZAMBIA.***

***Investigator: Dr. Bwalya W. Mumbi, Department of Ophthalmology, University of  
Nairobi, Kenyatta National Hospital, P.O. Box 19676-00202, Nairobi, Kenya.***

Child (parent/guardian on their behalf) / young person to circle all they agree with:

Have you read (or read it to you) information about this study? Yes/No

Has somebody else explained this study to you? Yes/No

Do you understand what this study is about? Yes/No

Have you asked all the questions you want? Yes/No

Have you had your questions answered in a way you understand? Yes/No

Do you understand that you may stop taking part at any time? Yes/No

If any answers are 'no' or you **don't** want to take part, don't sign your name!

If you **do** want to take part, you can write your name below

Your name \_\_\_\_\_ Date \_\_\_\_\_

Parent/guardian to write their name if they agree for you to participate in the study.

Name \_\_\_\_\_ Sign \_\_\_\_\_ Date \_\_\_\_\_

The researcher who explained this project to you needs to sign too.

Name \_\_\_\_\_ Sign \_\_\_\_\_ Date \_\_\_\_\_



**APPENDIX IV: PEPALA YOVOMEREZA KWA ANA/NDI ANTHU ENA OSUNGIDWA**

**(Izi zidzachitidwa ndi mwana pamodzi ndi makolo ao kapena owayanganila)**

**MUTU WA KAFUKU-FUKU: ZIZNDIKIRO/ZIONETSERO ZA MATENDA A SICKLE CELL PAKATI PA ODWALA METANDAWA KUDZERA KUYANGANA MMASO PA CHIPATALA CHA UNIVERSITY TEACHING HOSPITAL, KU LUSAKA, ZAMBIA**

**Principal Investigator: Dr. Bwalya W. Mumbi, Department of Ophthalmology, University of Nairobi, Kenyatta National Hospital, P.O. Box 19676-00202, Nairobi, Kenya.**

Mwana (ngati sakwanitsa kuyankhula, makolo/omusunga)/musonyeza pozunguliza ndi pensulo pa yankho yanu: **Inde** kapena **ai**:

Kodi wawerenga (kapena anakuwerengela) nkhani ya kafuku-fuku umeneu? Inde/Ai

Pali munthu wina emene wakumasulila pa nkhani ya kafuku-fuku umeneu? Inde/Ai

Kodi ukumvetsa bwino lomwe cholinga cha kafuku-fuku ameneyu? Inde/Ai

Kodi wafunsa mafunso onse amene unayenera kufunsa? Inde/Ai

Kodi mafunso omwe iwe wafunsa, yayankhidwa bwino ndipo wamvetsa? Inde/Ai

Wamvetsa kuti, palibe vuto ungasiye nthawi iliyonse kutengako mbali? Inde/Ai

Ngati mayankho onse akusonyeza ‘Ai’ kapena sukufuna kutengako mbali, usasaina dzina lako munsimu! Koma ngati **ukufuna** kutengako mbali, utha kulemba dzina lako pansipa ndipo usainile

Dzina lako \_\_\_\_\_ Tsiku \_\_\_\_\_

Kholo/Okuyanganira ayenera kulemba dzina lawo ngati ndiwokondwera kuti iwe utengeko mbali pa kafuku-fuku umeneu.

Dzina lawo \_\_\_\_\_ Asaine \_\_\_\_\_

Tsiku \_\_\_\_\_

Munthu wopanga kafuku-fuku umeneu, amene wakumasulilani nchitoyi ya kafuku-fuku, nayenso ayenera ku saina.

Dzina \_\_\_\_\_ Saina \_\_\_\_\_

Tsiku \_\_\_\_\_

## APPENDIX V: ETHICS APPROVAL LETTERS



UNIVERSITY OF NAIROBI  
COLLEGE OF HEALTH SCIENCES  
P O BOX 19675 Code 00202  
Telegrams: varsity  
(254-020) 2726300 Ext 44355

Ref: KNH-ERC/A/323

Dr. Bwalya Willard Mumbi  
Dept. of Ophthalmology  
School of Medicine  
University of Nairobi

Dear Dr. Mumbi

KNH/UON-ERC  
Email: [uonknh\\_erc@uonbi.ac.ke](mailto:uonknh_erc@uonbi.ac.ke)  
Website: [www.uonbi.ac.ke](http://www.uonbi.ac.ke)

Link: [www.uonbi.ac.ke/activities/KNHUoN](http://www.uonbi.ac.ke/activities/KNHUoN)



KENYATTA NATIONAL HOSPITAL  
P O BOX 20723 Code 00202  
Tel: 726390-9  
Fax: 725272  
Telegrams: MEDSUP, Nairobi

11<sup>th</sup> October 2013



**RESEARCH PROPOSAL: OCULAR MANIFESTATIONS OF SICKLE CELL DISEASE AT THE UNIVERSITY TEACHING HOSPITAL, LUSAKA, ZAMBIA (P334/06/2013)**

This is to inform you that the KNH/UoN-Ethics & Research Committee (KNH/UoN-ERC) has reviewed and approved your above proposal. The approval periods are 11<sup>th</sup> October 2013 to 10<sup>th</sup> October 2014.


This approval is subject to compliance with the following requirements:

- Only approved documents (informed consents, study instruments, advertising materials etc) will be used.
- All changes (amendments, deviations, violations etc) are submitted for review and approval by KNH/UoN ERC before implementation.
- Death and life threatening problems and severe adverse events (SAEs) or unexpected adverse events whether related or unrelated to the study must be reported to the KNH/UoN ERC within 72 hours of notification.
- Any changes, anticipated or otherwise that may increase the risks or affect safety or welfare of study participants and others or affect the integrity of the research must be reported to KNH/UoN ERC within 72 hours.
- Submission of a request for renewal of approval at least 60 days prior to expiry of the approval period. (*Attach a comprehensive progress report to support the renewal*).
- Clearance for export of biological specimens must be obtained from KNH/UoN-Ethics & Research Committee for each batch of shipment.
- Submission of an executive summary report within 90 days upon completion of the study. This information will form part of the data base that will be consulted in future when processing related research studies so as to minimize chances of study duplication and/or plagiarism.

For more details consult the KNH/UoN ERC website [www.uonbi.ac.ke/activities/KNHUoN](http://www.uonbi.ac.ke/activities/KNHUoN).

"Protect to Discover"

Yours sincerely



**PROF. M. L. CHINDIA**  
**SECRETARY, KNH/UON-ERC**

c.c. Prof. A.N.Guantai, Chairperson, KNH/UoN-ERC  
The Deputy Director CS, KNH  
The Principal, College of Health Sciences, UoN  
The Dean, School of Medicine, UoN  
The Chairman, Dept. of Ophthalmology, UoN  
AD/Health Information, KNH  
Supervisors: Dr. Jefitha Karimurio, Dr. Lucy Njambi, Dr. Grace Chipalo-Mutati



THE UNIVERSITY OF ZAMBIA

BIOMEDICAL RESEARCH ETHICS COMMITTEE

Telephone: 260-1-256067  
Telegrams: UNZA, LUSAKA  
Telex: UNZALU ZA 44370  
Fax: + 260-1-250753  
E-mail: unzareo@unza.zm  
Assurance No. FWA00000338  
IRB00001131 of IORG000774

Ridgeway Campus  
P.O. Box 50110  
Lusaka, Zambia

16<sup>th</sup> September, 2013.

Your Ref: 009-06-13.

Dr. Bwalya Willard Mumbi,  
University of Nairobi,  
Department of Ophthalmology,  
Kenyatta National Hospital,  
P.O Box 19676-00202,  
Nairobi.

Dear Dr. Mumbi


**RE: RE-SUBMITTED RESEARCH PROPOSAL: "OCULAR MANIFESTATIONS OF SICKLE CELL DISEASE AT THE UNIVERSITY TEACHING HOSPITAL"**

The above mentioned research proposal was re-submitted to the Biomedical Research Ethics Committee with recommended changes on 9<sup>th</sup> September, 2013. The proposal is approved.

**CONDITIONS:**

- This approval is based strictly on your submitted proposal. Should there be need for you to modify or change the study design or methodology, you will need to seek clearance from the Research Ethics Committee.
- If you have need for further clarification please consult this office. Please note that it is mandatory that you submit a detailed progress report of your study to this Committee every six months and a final copy of your report at the end of the study.
- Any serious adverse events must be reported at once to this Committee.
- Please note that when your approval expires you may need to request for renewal. The request should be accompanied by a Progress Report (Progress Report Forms can be obtained from the Secretariat).
- **Ensure that a final copy of the results is submitted to this Committee.**

Yours sincerely,

  
Dr. J.C. Munthali  
CHAIRPERSON

Date of approval: 16<sup>th</sup> September 2013

Date of expiry: 15<sup>th</sup> September 2014.



REPUBLIC OF ZAMBIA  
**MINISTRY OF HEALTH**  
**University Teaching Hospital**

Fax: +260 211 250305  
e-mail: mduth@yahoo.com

P/Bag Rw 1X  
Lusaka - Zambia  
Tel: +260 211 253947 (Switch Board)  
+260 211 251451

OFFICE OF THE SENIOR MEDICAL SUPERINTENDENT

---

Our Ref:  
Your Ref:

10<sup>th</sup> May, 2013

Dr. Bwalya Willard Mumbi  
University of Nairobi  
Department of Ophthalmology  
Kenyatta National Hospital  
NAIROBI

Dear Dr. Mumbi

RE: APPLICATION FOR PERMISSION TO CONDUCT RESEARCH STUDY FOR  
MY POSTGRADUATE THESIS IN MASTER OF MEDICINE IN  
OPHTHALMOLOGY AT UNIVERSITY TEACHING HOSPITAL

Reference is made to your letter of 6<sup>th</sup> May, 2013 regarding the above subject matter.

This serves to inform you that management has approved your request to conduct a research entitled "Ocular manifestations of sickle cell disease at the University Teaching Hospital".

Yours Sincerely,

Dr. L. Chikoya  
Head Clinical Care  
For/Senior Medical Superintendent  
UNIVERSITY TEACHING HOSPITAL

CC: Senior Medical Superintendent  
Head of Department – Paediatrics  
mm