

**ROOT AND CANAL MORPHOLOGY OF PERMANENT MANDIBULAR INCISORS  
IN A KENYAN POPULATION**

**DR GAICHU JOYCE KATHURE**

**V60/68168/11**

**DEPARTMENT OF CONSERVATIVE AND PROSTHETIC DENTISTRY,  
SCHOOL OF DENTAL SCIENCES,  
COLLEGE OF HEALTH SCIENCES,  
UNIVERSITY OF NAIROBI.**

**THESIS SUBMITTED IN PARTIAL FULFILMENT OF THE REQUIREMENTS FOR  
THE AWARD OF A MASTER OF DENTAL SURGERY DEGREE IN  
PROSTHODONTICS.**

**2014.**

## **DECLARATION**

I declare that this thesis is my original work and has not been presented for the award of a degree in this or any other university.

Signed: \_\_\_\_\_ Date: \_\_\_\_\_.

DR GAICHU JOYCE KATHURE (BDS (NBI), 2002).

## **APPROVAL**

This thesis has been carried out under our supervision and has been submitted with our approval as University of Nairobi supervisors.

### **SUPERVISORS**

**1. DR. DIENYA TOM JOSEPH MBOYA:** BDS (Nbi), CIBRD (KASADA), MDSc – Endo (Mal), Cert in Oral Implantology (Mal).

Department of Conservative and Prosthetic Dentistry, School of Dental Sciences.

College of Health Sciences, University of Nairobi.

Signed: \_\_\_\_\_ . Date \_\_\_\_\_ .

**2. DR. SUSAN MAINA:** BDS (Nbi), MSC (USA), AEGD & ED (USA), OGW, FICD.

Department of Conservative and Prosthetic Dentistry, School of Dental Sciences.

College of Health Sciences, University of Nairobi.

Signed: \_\_\_\_\_ . Date: \_\_\_\_\_ .

**3. DR. FRED OTIENO:** BDS (Nbi), MSC (UK).

Department of Conservative and Prosthetic Dentistry, School of Dental Sciences.

College of Health Sciences, University of Nairobi.

Signed: \_\_\_\_\_ . Date: \_\_\_\_\_ .

**4. PROF. LOICE GATHECE:** BDS (Nbi), MPH (Nbi), PhD (Nbi).

Department of Periodontology, Community and Preventive Dentistry, School of Dental Sciences.

College of Health Sciences, University of Nairobi.

Signed: \_\_\_\_\_ . Date: \_\_\_\_\_ .

## **DEDICATION**

This thesis is dedicated to all my teachers, past and present, my husband Japheth and my sons Sammy, Kelvin and Mark. You have all contributed immensely to my success and have been a positive influence in my life.

## **ACKNOWLEDGEMENTS**

I would like to thank God to whom I attribute every success.

I wish to express my sincere gratitude to my supervisors, Dr. Dienya Tom, Dr. S. Maina, Dr. F. Otieno and Professor L. Gathece for their patience, time, support and encouragement. They worked tirelessly to see this research work come to completion.

I also wish to acknowledge my family support and particularly my husband Japheth.

Special thanks go to the Chairman, Department of Oral and Maxillofacial Surgery, Oral Pathology and Oral Medicine for allowing me to use their Histopathology laboratory for teeth analysis.

I am indebted to the clinicians, dental assistants and statisticians who assisted me in collection of teeth as well as data analysis.

I also appreciate my colleagues Dr. Ogada and Dr. Ombuna for their criticism and moral support during the period of study.

I am grateful to my employer, the Ministry of Health, for granting me study leave and sponsorship to pursue this course. I also thank the University of Nairobi, Board of Postgraduate Studies for their support throughout the course.

## TABLE OF CONTENTS

DECLARATION .....	i
APPROVAL .....	ii
DEDICATION .....	iii
ACKNOWLEDGEMENTS .....	iv
TABLE OF CONTENTS.....	v
LEGEND OF FIGURES.....	xi
LIST OF APPENDICES.....	xii
ABBREVIATIONS .....	xiii
DEFINITION OF TERMS .....	xiv
ABSTRACT.....	xv
CHAPTER ONE.....	1
1.0. INTRODUCTION.....	1
1.1. LITERATURE REVIEW.....	4
1.1.1 General information .....	4
1.1.2 General anatomy of permanent mandibular central and lateral incisors.....	4
1.1.3 Crown morphology of permanent mandibular central and lateral incisors.....	5
1.1.4 Root morphology.....	6
1.1.4.1 Number and shape of roots in permanent mandibular central and lateral incisors...	6
1.1.4.2 presence of Grooves on the roots of permanent mandibular central and lateral incisors.....	7
1.1.4.3 Position of the root relative to the crown in permanent mandibular central and lateral incisors.....	7

1.1.4.4	Position and direction of root curvature in permanent mandibular central and lateral incisors.....	7
1.1.4.5	Root length in permanent mandibular central and lateral incisors .....	8
1.1.5	Canal morphology of permanent mandibular central and lateral incisors .....	8
1.1.5.1	Size and shape of pulp canal in permanent mandibular central and lateral incisors.	8
1.1.5.2	Number of canals in permanent mandibular central and lateral incisors.....	9
1.1.5.3	Canal configurations in permanent mandibular central and lateral incisors.....	10
1.1.5.4	Lateral canals in permanent mandibular central and lateral incisors .....	15
1.1.5.5	Apical deltas in permanent mandibular central and lateral incisors .....	15
1.1.5.6	Intercanal anastomosis in permanent mandibular central and lateral incisors.....	16
1.1.5.7	Position and number of apical foramina in permanent mandibular central and lateral incisors.....	17
1.1.6	Role of genetics in canal morphology of permanent mandibular central and lateral incisors .....	19
1.1.7	Techniques used to study root and canal morphology .....	19
1.2.	RESEARCH PROBLEM .....	21
1.3	JUSTIFICATION OF THE STUDY .....	22
1.4	STUDY OBJECTIVES .....	22
1.4.1	Broad objectives.....	22
1.4.2	Specific objectives.....	22
1.5	NULL HYPOTHESIS .....	23
1.6	STUDY VARIABLES .....	23

CHAPTER TWO .....	24
MATERIALS AND METHODS.....	24
2.1 STUDY DESIGN.....	24
2.2 STUDY AREA.....	24
2.3 STUDY POPULATION.....	26
2.3.1 Inclusion Criteria.....	26
2.3.2 Exclusion Criteria.....	26
2.4 SAMPLE SIZE DETERMINATION.....	26
2.5 SAMPLING.....	27
2.6 DATA COLLECTION INSTRUMENTS AND TECHNIQUE .....	27
2.6.1 Collection of Teeth.....	27
2.6.2 Teeth Examination .....	28
2.6.3 Root Length and root curvature .....	28
2.6.4 Canal Morphology.....	30
2.6.4.1 Number of canals, canal configuration, number of lateral canals, number of apical deltas, position of apical foramen and number of apical foramen .....	30
2.7 DATA ANALYSIS AND PRESENTATION.....	31
2.8 DATA RELIABILITY AND VALIDITY .....	31
2.9 CONTROL OF ERRORS AND BIASES .....	32
2.10 ETHICAL CONSIDERATIONS .....	32
2.11 STUDY LIMITATIONS .....	32
2.12 ENVIRONMENTAL CONSIDERATIONS.....	33



CHAPTER THREE .....	34
3.1 RESULTS.....	34
3.2 General observations .....	34
3.3 Presence of bilateral grooves in permanent mandibular central and lateral incisors .....	34
3.4 The position of the roots relative to the crown in mandibular central and lateral incisors	35
3.5 Root curvature in permanent mandibular central and lateral incisors .....	36
3.6 Position and direction of root curvature in permanent mandibular central and lateral incisors.....	36
3.7 Crown length, root length and total tooth length in permanent mandibular central and lateral incisors.....	37
3.8 Number of canals permanent mandibular central and lateral incisors .....	38
3.9 Canal configurations in permanent mandibular central and lateral incisors .....	39
3.10 Number of lateral canals in permanent mandibular central and lateral incisors .....	40
3.11 Number of apical deltas and intercanal anastomoses in permanent mandibular central and lateral incisors.....	40
3.12 Number of apical foramina in central and lateral incisors .....	41
3.13 Position of apical foramen in relation to anatomical apex in permanent mandibular central and lateral incisors.....	42
 CHAPTER FOUR.....	 43
4.0 DISCUSSION .....	43
4.1 CONCLUSIONS .....	49
4.2 RECOMMENDATIONS .....	50

APPENDIX 1: DATA COLLECTION FORM .....	57
APPENDIX 2: CONSENT FORM.....	59
APPENDIX 3: APPROVAL LETTER.....	61
APPENDIX 4: DIAGRAMMATIC CANAL CONFIGURATION AS PER VERTUCCI (1984) CLASSIFICATION.....	62

## LIST OF TABLES

	<b>PAGE</b>
Table 1.1: Frequency of two canals in permanent mandibular central incisors.....	10
Table 1.2: Frequency of two canals in permanent mandibular lateral incisors.....	10
Table 1.3: Number of apical foramina in relation to number of canals.....	18
Table 1.4: Study Variables.....	23
Table 3.1: Distribution of bilateral grooves in mandibular central and lateral incisor.....	35
Table 3.2: Distribution of the position of roots relative to the crown in mandibular central and lateral incisors.....	35
Table 3.3: Distribution of straight versus curved roots in permanent mandibular central and lateral incisors.....	36
Table 3.4: Direction of root curvature in permanent mandibular central and lateral incisors.....	37
Table 3.5: Comparison of mean tooth length in mandibular central and lateral incisors.....	38
Table 3.6: Distribution of one and two canals in mandibular central and lateral incisors.....	38
Table 3.7: Distribution of canal configurations in mandibular central and lateral incisors.....	39
Table 3.8: Frequency of lateral canals in mandibular central and lateral incisors.....	40
Table 3.9: Frequency of apical deltas in permanent mandibular central and lateral incisors.....	41
Table 3.10: Number of apical foramen in permanent mandibular central and lateral incisors....	41
Table 3.11: Position of apical foramen in permanent mandibular central and lateral incisors....	42

## LEGEND OF FIGURES

	<b>PAGE</b>
Figure 1.1: Classification of root canal configurations by Weine F.S .....	12
Figure 1.2: Classification of root canal configurations by Kartal and Yanikoglu.....	13
Figure 1.3: Supplemental canal configurations by Gulabivara <i>et al</i> .....	13
Figure 1.4: Classification of intercanal anastomosis by Yi-Hsu Yeung .....	16
Figure 2.1: An ultrasonic scaler.....	28
Figure 2.2: An electronic vernier caliper.....	29
Figure 2.3: Root curvature on a graph paper.....	29
Figure 2.4: A transparent central incisor root.....	31
Figure 3.1: Distribution of analyzed mandibular incisors.....	34

## LIST OF APPENDICES

	<b>PAGE</b>
Appendix 1: Data collection form.....	57
Appendix 2: Consent form.....	59
Appendix 3: Ethical approval.....	61
Appendix 4: Diagrammatic representation of canal configurations.....	62

## ABBREVIATIONS

<b>CBCT:</b>	Cone Beam Computer Tomography
<b>df:</b>	Degrees of freedom
<b>DOM:</b>	Dental Operating Microscope
<b>D:</b>	Distal
<b>KNH:</b>	Kenyatta National Hospital
<b>MDS:</b>	Master of Dental Surgery
<b>M:</b>	Mesial
<b>mm:</b>	Millimeters
<b>M.O.H:</b>	Ministry of Health
<b>SD:</b>	Standard Deviation
<b>SPSS:</b>	Statistical Package for Social Sciences
<b>UoN:</b>	University of Nairobi
<b>W.H.O</b>	World Health Organization
<b><math>\chi^2</math>:</b>	Chi Square

## DEFINITION OF TERMS

<b>Accessory canal:</b>	Any branch of the main pulp canal or chamber that communicates with the external surface of the root <sup>1</sup> .
<b>Dental caries:</b>	Dental caries is a disease of dental hard tissues which results from a localized chemical dissolution of the tooth surface caused by metabolic events taking place in the biofilm (dental plaque) covering the affected area <sup>1,2</sup> .
<b>External root morphology:</b>	Number of roots, root fusion, root curvature and root length <sup>1</sup> .
<b>Internal root morphology:</b>	Number of canals and canal configurations <sup>3</sup> .
<b>Lateral canal:</b>	An accessory canal located in the coronal or middle third of the root and extending horizontally from the main canal <sup>1,2</sup> .
<b>Number of canals:</b>	The highest number of canals visualized at the floor of the pulp chamber and at the root apex <sup>3</sup> .
<b>Pulp canal:</b>	Portion of the pulp cavity which is located in the root of the tooth <sup>1,2</sup> .
<b>Pulp cavity:</b>	Entire central portion of a tooth which contains the pulp <sup>1,2,3</sup> .
<b>Pulp chamber:</b>	The elongated portion of the pulp which lies in the central portion of the anatomical crown of the tooth <sup>1,2,3</sup> .
<b>Pulp horns:</b>	The elongations or extensions of the pulp chamber which often correspond to the cusps, or lobes of the teeth <sup>1,2</sup> .
<b>Root:</b>	Portion of the tooth which is covered with cementum <sup>1,2</sup> .
<b>Root canal treatment:</b>	Cleaning, shaping and filling of the pulp canal <sup>3</sup> .
<b>Root curvature:</b>	An external description of root morphology in relation to a root which is not straight <sup>1,2</sup> .
<b>Root length:</b>	The length from a reference cusp tip to the most apical point on the root <sup>2</sup> .

## ABSTRACT

**Background:** Knowledge of root and canal anatomy is essential in designing and preparing access cavities that give straight line access to the main root canals. Thorough knowledge and understanding of dental anatomy and variations in root and canal morphology of mandibular incisors which include length, shape, position and number is important for favorable root canal treatment.

**Objective:** To determine the root and canal morphology of permanent mandibular incisors in a Kenyan population.

**Study duration:** The study was conducted for a period of three years, from 2011 to 2014.

**Study Design:** This was a descriptive cross sectional study.

**Study area:** The study was conducted in selected public dental institutions within Nairobi and its environs namely Kenyatta National Hospital - Dental clinic, University of Nairobi - Dental Hospital, Mbagathi District Hospital, Kiambu District Hospital, Thika Level Five Hospital, Social League Dispensary, Gatundu District Hospital, Kajiado District Hospital, Machakos Level Five Hospital, Ngong District Hospital and Mathari District Hospital.

**Materials and methods:** A total of 208 permanent mandibular incisors (124 lateral and 84 central) that conformed to the inclusion criteria were collected from the selected centres. The teeth were washed in 3.85% m/v sodium hypochlorite (Reckitt Benckiser E.A Nairobi, Kenya) to remove adherent tissue and then stored in labeled containers containing 10% formalin (ART- M3 Bonart, Taiwan). First, data was collected on root morphology by direct observation. Root length was measured using a calibrated electronic vernier caliper. A standard clearing technique was applied to determine the number of canals and canal configurations according to Vertucci's classification. A data collection form was used to record the findings for each tooth examined.



**Data analysis and presentation:** The data was stored, coded and analyzed using Statistical Package for Social Sciences (SPSS Version 16, Illinois-Chicago). Obtained data was used to calculate frequencies, means, chi-square and t-statistics of various variables and inferences were drawn from the values obtained. The values obtained from inferential statistics were used to compare results with those obtained in studies done in other populations. A value of  $P < 0.5$  was considered statistically significant. Results were presented in form of frequency tables and pie charts.

**Results:** A total of 208 mandibular incisors (124 lateral and 84 central) were analyzed. All the incisors had one root. Of the central incisors, 56 (66.67%) had curved roots while 86 (69.35%) of lateral incisors had curved roots. Distal curvatures were the most prevalent.

The mean root lengths were  $12.38 \pm 0.244\text{mm}$  and  $13.55 \pm 0.4\text{mm}$  in central and lateral incisors respectively..

Majority of central, 68 (80.5%) and lateral, 102 (82.26%) incisors had one canal at the floor of the pulp chamber. Type I canal configuration was the most frequent in both central (71.43%) and lateral (67.74%) incisors. Single apical foramina were the commonest in both central (88.1%) and lateral (90.32%) incisors.

**Conclusions:** All central and lateral incisors had one root. Roots were mostly centrally located and distally curved. Majority of teeth had a single canal at the pulpal floor and anatomical apex and type one canal configuration was the most prevalent. Lateral canals, apical deltas and intercanal anastomosis were uncommon in central and lateral incisors.

**Recommendations:**

There is need for investigation of a second canal and unusual canal morphology in permanent mandibular central and lateral incisors during routine endodontic treatment.

## CHAPTER ONE

### 1.0. INTRODUCTION

Mandibular permanent incisors are the first permanent teeth to erupt and play a very critical role in aesthetics and speech <sup>1</sup>. However, their location in the anterior region of the mandible makes them prone to fractures due to trauma from sports, interpersonal violence and accidents <sup>2</sup>. Proximity to sublingual salivary glands increases incidence of perio-endo lesions and dental caries due to heavy deposits of calculus on the lingual aspect <sup>2, 3</sup>. These conditions may necessitate endodontic therapy hence the need to understand root and canal morphology of these teeth.

Favorable treatment outcome is based on accurate diagnosis and treatment planning, thorough chemo-mechanical preparation of the canal and root filling with inert root filler <sup>4</sup>. Therefore, detailed knowledge of the root canal systems contributes immensely to favorable endodontic treatment outcome while inadequate understanding of the root canal systems, improper shaping and cleaning as well as poor obturation contributes to unfavourable treatment outcome <sup>4,5</sup>.

Dental practitioners must be aware that the main root canals in a tooth may only provide access to the complexities of the root canal systems, which must be fully cleared of all micro-organisms. Research has shown that the dental anatomy learned as a student may be out of date <sup>4, 5</sup>. More so teachings in endodontics are based on text books and articles from western countries <sup>3, 4, 5</sup>. Many studies have shown variation in root and canal morphology from population to population. Hence appropriate knowledge of canal root and canal morphology of a particular population is essential in designing and executing access cavities that give straight line access to the main root canals <sup>5,6</sup>.

Unfavorable root canal treatment outcome has been reported in 3%-60% of worldwide treatments <sup>7, 8, 9</sup>. In Kenya, the situation could be worse though no data exists. This has led to many retreatments, waste of valuable time and resources and reduction in quality of life as a result of discomfort. The unfavorable treatment outcomes have been attributed to lack of knowledge in canal morphology of teeth and inability to identify, clean and obturate unusual canals due to variations in root and canal morphology <sup>10, 11, 12</sup>.

Variations in root and canal morphology can be associated with any tooth with varying degrees and incidences <sup>13, 14, 15, 16, 17, 18, 19, 20, 21</sup>. From the early work of Hess & Zurcher <sup>22</sup> to the most recent studies by Boruah *et al.* <sup>23, 24</sup>, it has been established that a root with a tapering canal and a single apical foramina is the exception rather than the rule. Most investigators have shown that the pulp canal system for most, if not all permanent teeth is complex and canals may branch, divide and rejoin <sup>16, 17, 18, 19, 20</sup>.

Unfavourable root canal treatment outcome has been reported to be high in mandibular incisors <sup>7, 8, 9</sup>. Permanent mandibular incisors often have a single root and a single canal, however various anomalies of the root and root canal systems as well as multiple canals have been reported in literature <sup>7, 25, 26, 27</sup>. Studies have shown that variation in number of roots is uncommon while canal types may vary according to race <sup>5, 20, 23, 24, 28, 29, 30</sup> with a high percentage having more than one canal <sup>23, 24, 28, 29, 30</sup>. For example, a prevalence of 30% and a 36.25% of two canals in mandibular central incisors was reported in an American and a North East Indian population respectively. In these studies, all mandibular incisors were reported to have single roots <sup>19, 23</sup>.

In Kenya, cases of unfavorable root canal treatment outcome in mandibular incisors are on the rise. This can only be attributed to improper shaping, cleaning and obturation of the canal systems due to lack of knowledge of root canal systems in these teeth. There being no data on root and canal morphology of permanent mandibular incisors in the Kenyan population, there

was a gap in knowledge that required filling by way of research. The aim of the study was therefore to investigate the root and canal morphology of mandibular incisors in a Kenyan population using decalcification and clearing technique. The research findings will form a national data for Kenyans and provide a useful source of information to dentists practicing endodontics and other disciplines of dentistry. The findings will also form a basis for further research in these fields.

## **1.1. LITERATURE REVIEW**

### **1.1.1 General information**

A root is the portion of the tooth which is covered with cementum while a canal is the portion of the pulp cavity which is located in the root of the tooth<sup>1,2</sup>. Root and canal morphology refers to the macroscopic features by which the root and canal of a tooth can be described.

Generally, mandibular incisors have a single root and canal<sup>2</sup>. However, variations have been encountered in research especially in the area of number of canals, presence of accessory canals and number of apical foramen<sup>3,4,5</sup>. Incidence of perio-endo lesions and dental caries in these teeth is high and this necessitates endodontic treatment<sup>6</sup>. Despite the fact that mandibular incisors have a single root and canal, cases of post treatment disease are on the rise. Conventional endodontic therapy has been reported to have post treatment disease in 3-60% of the global population<sup>7,8,9</sup>.

Many of the problems encountered in root canal treatment could be directly attributed to an inadequate understanding of root and canal morphology of the tooth<sup>5,6,7,8,9</sup>.

### **1.1.2 General anatomy of permanent mandibular central and lateral incisors**

The permanent mandibular incisors are the smallest teeth in the human dentition. In Africans, the mandibular central incisor is usually the first permanent tooth to erupt in the mouth closely followed by the mandibular first permanent molar between the age of 5 - 6 years in both girls and boys. The mandibular lateral incisors erupt at about 6 - 7 years. Root formation in both types of teeth is completed 3-4 years after their eruption<sup>1,2</sup>. The central incisor is smaller than the lateral incisor and often bilaterally symmetrical. In newly erupted permanent incisors, three mamelons are seen separated by two grooves on the crowns of these teeth<sup>1,2</sup>.

### **1.1.3 Crown morphology of permanent mandibular central and lateral incisors**

The crown is made up of macroscopic units including the lobes, marginal ridges, cingulum and supernumerary coronal structures <sup>1, 2</sup>. These features may differ from population to population and gender differences may also be present. The shape, height and width of the crown may vary in the population even in normal individuals. Peg shaped lateral incisors have been reported and are associated with congenital malformations and some disease entities in an expectant mother. The malformations appear in the child <sup>1,2</sup>. Ngassapa *et al.* <sup>2</sup> reported that mandibular central and lateral incisors have a convex buccal and lingual surface.

The permanent mandibular central incisor has a slightly convex buccal surface in the transverse and longitudinal direction with the maximum convexity at the cervical region <sup>2</sup>. The buccal surface flattens on the incisal half and forms two to three lobes. The lingual surface is convex in its cervical part and the convexity forms a low cingulum <sup>1,2</sup>. Marginal ridges are present on the mesial and distal lingual surfaces. The crown of the mandibular central incisor is 9mm in height and it is symmetrical from the midline. Ash M.M <sup>1</sup> reported that the mandibular central incisor is smaller and symmetrical as compared to the mandibular lateral incisor.

The crown of the mandibular lateral incisor is slightly larger than that of central incisor in width and height. The crown has a slight buccal convexity in the transverse and longitudinal direction with the maximum convexity at the cervical region. The buccal surface flattens on the incisal half to form two to three lobes. The lingual surface is convex in its cervical part and the convexity forms a low cingulum. Marginal ridges are present on the mesial and distal lingual surfaces. The crown of the lateral incisor is 9.5mm in height <sup>1,2</sup>.

The crown morphology of permanent mandibular incisors necessitates use of incisal access opening as the most direct path to the long axis of the root canal<sup>1,2</sup>. Studies done by Weine F.S<sup>9</sup> Zillich R.M & Jerome J.K<sup>10</sup>, Mauger *et al.*<sup>11</sup> and Clements R.E & Gilboe D.B<sup>12</sup> concluded that, ideal endodontic access for mandibular incisors should be inclusive of and labial to the incisal edge.

#### **1.1.4 Root morphology**

##### **1.1.4.1 Number and shape of roots in permanent mandibular central and lateral incisors**

The number and shape of roots are determined by Hertwig's epithelial root sheath that bends in a horizontal direction below the cemento-enamel junction before fusing in the centre thus leaving openings for development of the roots<sup>13</sup>.

###### **1.1.4.1.1 Number and shape of roots in permanent mandibular central incisors**

The mandibular central incisor has a single conical root flattened mesio-distally and wider labio-lingually. Variation in number of roots has not been reported in literature. However, the shape may vary from conical to round in different populations. Sexual dimorphism in the number and shape of roots has not been reported<sup>1,2</sup>. A study done in a South Eastern Romanian population reported single conical roots on all the mandibular central incisors using radiography and similar findings were reported in a North East Indian population using staining technique<sup>18, 23, 24</sup>. According to Roshan P<sup>16</sup>, Boruah *et al.*<sup>24</sup> and Bardelli *et al.*<sup>31</sup> variations in number of roots in these teeth are very rare.

###### **1.1.4.1.2 Number and shape of roots in permanent mandibular lateral incisors**

The mandibular lateral incisor has a single conical root flattened mesio-distally and wider labio-lingually<sup>1,2</sup>. The root is larger than that of the central incisor in mesio-distal and labio-lingual direction<sup>1,2</sup>. Variation in number of roots has not been reported in literature. However, the shape

may vary from conical to round in different populations. Sexual dimorphism in the number and shape of roots has not been reported<sup>2</sup>. A study done in a South Eastern Romanian population reported single conical roots on all the mandibular lateral incisors using radiography and similar findings were reported in a North East Indian population using staining technique<sup>18, 23, 24</sup>.

#### **1.1.4.2 Grooves on the roots of permanent mandibular central and lateral incisors**

The presence of grooves, concavities and other surface aberrations on the root surface was thought to accentuate periodontal disease by acting as stagnation areas for plaque<sup>2</sup>. The roots of mandibular incisors have longitudinal grooves on both the mesial and distal surfaces, the distal groove being deeper than the mesial. Very deep grooves may suggest division of the root into two and therefore the possibility of a second canal<sup>14, 29, 32</sup>. Variations in presence and absence of grooves exist in the general population. However, sexual predilection has not been reported<sup>32</sup>. The presence of a deep groove dividing the root into two is invisible clinically. This necessitates the use of proper radiographs as diagnostic aid<sup>14, 33</sup>. Ngassapa *et al.*<sup>2</sup> reported presence of bilateral grooves in all mandibular central and lateral incisors in an East African population.

#### **1.1.4.3 Position of root relative to crown in permanent mandibular central and lateral incisors**

Mandibular incisor roots can be centrally or laterally located in relation to the long axis of the crown<sup>1, 2, 13, 32</sup>. Perrini *et al.*<sup>29</sup> reported that roots can be central or lateral to long axis of crown. Similar findings were reported by Ezoddini *et al.*<sup>34</sup>.

#### **1.1.4.4 Position and direction of root curvature in permanent mandibular central and lateral incisors**

Mandibular incisor roots are commonly reported to be straight and in rare occasions curved in the apical region<sup>1, 2, 13</sup>. Curvature can be in the mesial, distal, labial or lingual direction<sup>1, 2, 13</sup>.



Studies done by Sinziana *et al.*<sup>18</sup>, Boruah *et al.*<sup>23,24</sup> and Pineda & Kuttler Y<sup>33</sup> and in an East Romanian, Indian and American populations respectively reported that root curvatures are very rare in mandibular central and lateral incisors. All the teeth they studied had straight roots.

#### **1.1.4.5 Root length in permanent mandibular central and lateral incisors**

Mandibular incisors have the shortest roots in the human dentition<sup>2</sup>. Root length ranges between 9mm-12.5mm in mandibular central incisors while in mandibular lateral incisors root length ranges between 10mm-14mm<sup>2</sup>. Mean root lengths of 12.5mm and 14.0mm have been reported for the permanent mandibular central and lateral incisors respectively in an East African population<sup>2</sup>. Hilary O. and Akpata E.S.<sup>35</sup> reported mean root lengths of 12.5mm in central incisors and 14.0mm in lateral incisors in a Nigerian population. Similarly, Maina *et al.*<sup>36</sup> reported mean root lengths of 12.5mm and 14.0mm in mandibular central and lateral incisors respectively in a Kenyan population. In case of traumatic fracture or iatrogenic orthodontic extrusion, crown lengthening may not be feasible due to shortness of roots in these teeth.

#### **1.1.5 Canal morphology of permanent mandibular central and lateral incisors**

##### **1.1.5.1 Size and shape of pulp canal in permanent mandibular central and lateral incisors**

The pulp chamber of the permanent mandibular central incisor is wider mesio-distally than bucco-lingually<sup>2,13,31</sup>. It continues incisally in two or three indistinct and short pulp horns<sup>2,13,31</sup>. The pulp canal is flattened mesio-distally corresponding to the shape of the root<sup>2,13,31</sup>. The pulp chamber and pulp canal of the lateral incisor is similar to that of the central incisor<sup>2</sup>.

Canal orifices can be oval, round or ribbon shaped<sup>1,2,6,17,19,20,32,37</sup>. A study by Uma Ch *et al.*<sup>37</sup> in an Indian population reported that canals were round or oval, closer to the apex and tended to elongate to a long oval or ribbon shape more coronally. Similar findings have been reported in

an Italian and Romanian population<sup>18, 29</sup>. Since most endodontic instruments are round, preparation of these canals pose certain challenges.

#### **1.1.5.2 Number of canals in permanent mandibular central and lateral incisors**

Permanent mandibular central and lateral incisors tend to have a single canal<sup>1, 2, 31, 32</sup> although variations may exist among different racial groups<sup>5, 16, 17, 18, 23, 24, 28</sup>. Cases of two and more canals have been reported in literature<sup>27, 38, 39, 40, 41</sup>. These variations and deviations from the norm easily leads to missed canals during endodontic treatment and this could explain why there is high incidence of unfavorable outcome in endodontic treatment carried out in these teeth<sup>8, 42, 43, 44, 45, 46</sup>. Vertucci F. J.<sup>19, 20</sup> reported presence of two canals in 30% of teeth studied in an American population. Boruah *et al.*<sup>24</sup> and Perrini *et al.*<sup>29</sup> reported two canals in 36.25% and 36% of central incisors in an Indian and Italian population respectively while Caliskan *et al.*<sup>28</sup> reported two canals in 14 % of lateral incisors in a Turkish population. Uma Ch. *et al.*<sup>37</sup> reported presence of two canals in 2% of central and lateral incisors in an Indian population. In a similar study done in an Iranian population, Ashofteh & Jafari<sup>47</sup> reported presence of two canals in 3.5% of mandibular central and lateral incisors using in-vitro radiography, dyeing and sectioning technique. There is no data on number of canals in the African population. Some of these variations in number of canals are shown on table 1.1 and 1.2 below.

**Table 1.1: Frequency of two canals in permanent mandibular central incisors.**

<b>Year/s</b>	<b>Investigator/s</b>	<b>Population studied</b>	<b>Method of Study</b>	<b>Sample Size studied</b>	<b>Percentage with Two Canals</b>
1974, 1984	Vertucci F.J. <sup>19, 20</sup>	U.S.A	Invitro section	300	30
2010	Sinziana et al <sup>18</sup>	Romanian	Radiography	32	34.4
1992	Kartal & Yanikoglu <sup>15</sup>	Turkish	clearing	100	43
2010	Boruah L. C & Bhuyan A. C. <sup>23</sup>	Indian	clearing	480	36.25
2006	Al-qudah A. A & Awawdeh L. A. <sup>5</sup>	Jordanian	clearing	450	26.2

**Table 1.2: Frequency of two canals in permanent mandibular lateral incisors.**

<b>Year/s</b>	<b>Investigator/s</b>	<b>Population studied</b>	<b>Method of study</b>	<b>Sample size studied</b>	<b>Percentage with two canals</b>
1995	Caliskan <i>et al</i> <sup>28</sup>	Turkish	clearing	100	14
1974	Benjamin and Dowson <sup>21</sup>	U.S.A	radiography	364	40
1991	Perrini <i>et al</i> <sup>29</sup>	Italian	sectioning	144	1

### **1.1.5.3 Canal configurations in permanent mandibular central and lateral incisors**

It has been suggested that prior to commencement of root canal therapy, the dentist ought to be familiar with the various pathways that root canals may take to the apex <sup>48</sup>. Vertucci F.J <sup>48</sup> described the pulp canal system as a complex structure that presented forms that were

complicated. Several studies have now explicitly established that a root with a tapering canal and a single foramen was the exception rather than the rule<sup>17, 28, 49, 50</sup>. The most commonly used system for describing root canal configurations are mainly based on the work of Vertucci<sup>20</sup> and Weine<sup>51</sup>. However, other classifications exist as described by Kartal and Yonikoglu<sup>15</sup> and Gulabivala *et al.*<sup>49, 50</sup>.

Vertucci F. J<sup>20</sup> classified canal configurations into eight types as described below (Appendix 4).

**Type I:** A single canal from the pulp chamber to apex (1).

**Type II:** Two separate canals leaving the pulp chamber before joining short of the apex to form one canal (2-1).

**Type III:** One canal leaving the pulp chamber before dividing into two in the root then merging to exit as one canal (1-2).

**Type IV:** Two distinct canals that extended from the pulp chamber to the apex (2).

**Type V:** One canal leaving the pulp chamber and dividing short of the apex into two separate distinct canals with different apical foramina (1-2).

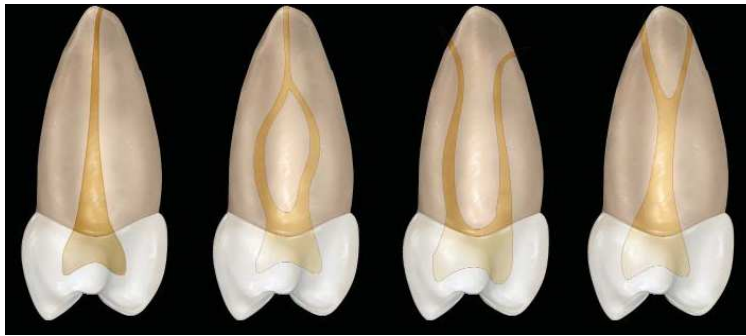
**Type VI:** Two separate canals leaving the pulp chamber, merging in the body of the root, and re-dividing short of the apex to exit as two distinct canals (2-1-2).

**Type VII:** One canal leaving the pulp chamber, dividing and then rejoining in the body of the root, and finally re-dividing into two distinct canals short of the apex (1-2-1-2).

**Type VIII:** Three separate, distinct canals that extended from pulp chamber to apex (3).

This classification is simple to use and can be used for classification of canals in all teeth.

Additional canal configurations have been identified and described by Weine F.S<sup>51</sup> as depicted below (Figure 1.1).



**Figure 1.1: Canal classification by Weine F. S. <sup>51</sup>**

Weine F.S <sup>51</sup> described each of the canal types as below.

**Type I:** Single canal from pulp chamber to apex;

**Type II:** Two canals leaving the chamber and merging to form a single canal short of the apex;

**Type III:** Two separate and distinct canals from chamber to apex;

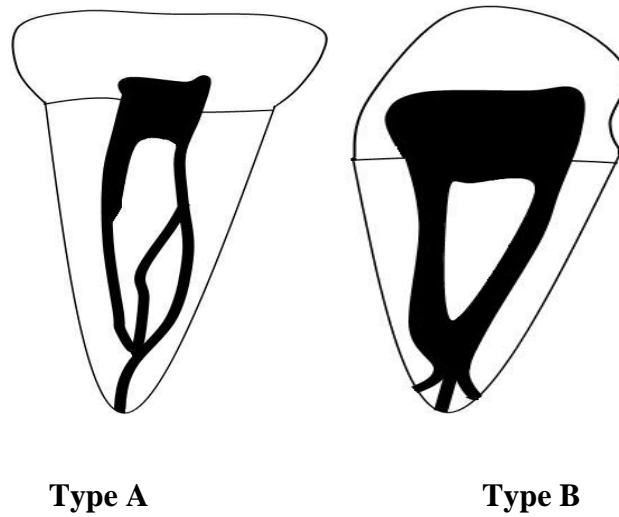
**Type IV:** One canal leaving the chamber and dividing into two separate and distinct canals.

Weine's classification is commonly used in describing canals of mesial buccal root of maxillary molars <sup>51</sup>.

Kartal & Yonikoglu <sup>15</sup> described two canal additional configurations (in addition to those described by Vertucci <sup>20</sup>).

**Type A:** Two separate canals extends from the pulp chamber to mid-root, whereas the lingual canal divides into two; all three canals join in the apical third of the root and exit as one canal.

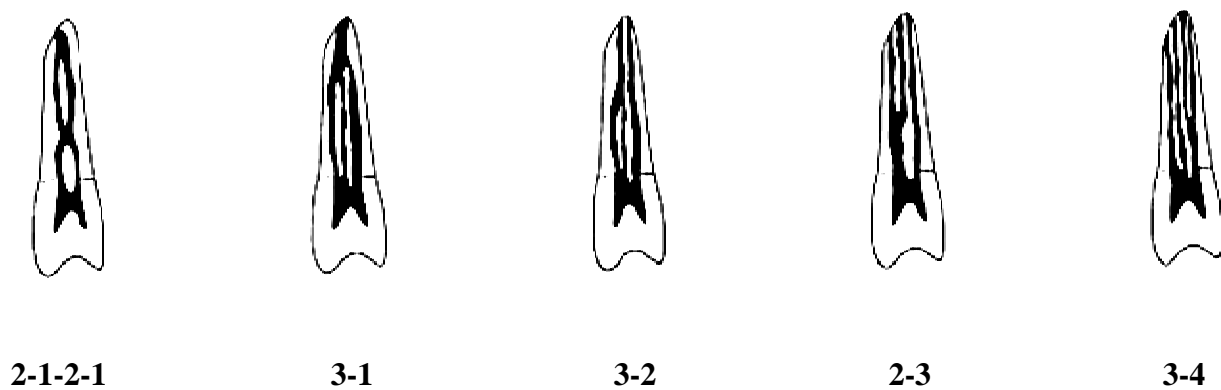
**Type B:** one canal exits the pulp chamber, divides into two in the middle third of the root, then rejoins to form one canal, which again divides and exit as three separate canals with separate foramina (Figure 1.2).



**Figure 1.2: Canal configuration by Kartal & Yonikoglu <sup>15</sup>**

The additional canal types described by Kartal & Yonikoglu are very rare hence not commonly used for classification of canals.

Gulabivala *et al.* <sup>49, 50</sup> described five additional canals in a Burmese population. These are shown below (Figure 1.3).



**Figure 1.3: Supplemental canal configurations by Gulabivala *et al.* <sup>49, 50</sup>.**

These canal configurations are rarely encountered.

Canal configurations vary from one tooth to another and from one population to another<sup>16, 18, 20, 24, 28</sup>. Sinziana *et al*<sup>18</sup> reported 65.6%, 6.3%, 25% and 3.1% of canal types I, II, III and VII respectively in mandibular central incisors in a Romanian population using Vertucci's<sup>20</sup> classifications. Another study done by Boruah & Bhuyan<sup>23</sup> showed a 63.75% canal type I configuration with straight, J and S shaped curvatures as well as frequent apical ramifications, lateral canals and reticular structures in mandibular central and lateral incisors in a North East Indian population using vertucci's<sup>20</sup> classification. Uma Ch. *et al.*<sup>37</sup> reported canal types I, II, III and VII in 44%, 2%, 52% and 2% of mandibular central and lateral incisors respectively in an Indian population. A similar study done by Ashofteh & Jafari<sup>47</sup> in an Iranian population using in-vitro radiography, staining and sectioning technique reported 88%, 3.5%, 0.5% and 8 % of canal types I, II, IV and V respectively in both mandibular central and lateral incisors. Studies done in a Turkish, Japanese and Chinese populations by Roshan<sup>16</sup>, Caliskan *et al.*<sup>28</sup> and Walker<sup>30</sup> showed that canal type I were the most prevalent. Studies done by other investigators such as Al-qudah & Awawdeh<sup>5</sup> and Sert & Bayirli<sup>17</sup> showed similarities to the above findings and reported that racial differences was a significant factor in canal variations.

These configurations may have an implication in endodontic treatment outcome. A properly executed root canal treatment will lead to success in type I, II, IV and VIII canal configuration while the same treatment might lead to unfavorable treatment outcome in type III canal configuration. Apically dividing systems like types V, VI and VII are most difficult to prepare and obturate and may have an influence on the outcome of root canal treatment<sup>5, 7, 16, 17, 18, 20, 23,</sup>

<sup>30</sup>.

#### **1.1.5.4 Lateral canals in permanent mandibular central and lateral incisors**

Lateral canals are accessory canals located in the coronal or middle third of the root<sup>2</sup>. Lateral canals extend horizontally from the main canal to the external surface of the root<sup>2</sup>. Lateral canals are formed by the entrapment of periodontal vessels in Hertwig's epithelial root sheath during calcification<sup>13</sup>. Lateral canals communicate with the periodontal ligament space and this increases risk of spread of periodontal disease into the pulp canal. Lateral canals are a common feature in mandibular incisors<sup>18, 23</sup>. Sinziana *et al.*<sup>18</sup> reported lateral canals in 12.5% of mandibular central incisors in a Romanian population while Boruah and Bhuyan<sup>23</sup> observed lateral canals in 13% of both mandibular central and lateral incisors. In both studies, lateral canals were frequently found in the middle of the canal.

#### **1.1.5.5 Apical deltas in permanent mandibular central and lateral incisors**


Apical deltas are accessory canals found on the apical third of the root<sup>2</sup>. Apical deltas are either a normal variant or could be formed due to disturbances of Hertwig's root epithelium by external factors such as orthodontic tooth movement<sup>13</sup>. Apical deltas open into the periodontal ligament space and peri-apical region of the root. In terms of age, most apical deltas occur between 20-40 years, and after this age, the number diminishes<sup>22</sup>. Apical deltas have been reported to be of great importance in endodontics because of the difficulties involved in instrumenting them during chemico-mechanical preparation<sup>32</sup>. Similarly, pulp tissue and micro-organisms hidden in the deltas could lead to post-treatment disease<sup>32, 37</sup>. To minimise this, thorough irrigation with sodium hypochlorite followed by the use of intracanal medicaments such as calcium hydroxide should be utilised especially in infected canals or those with apical pathosis prior to root filling<sup>3, 4</sup>. Sinziana *et al.*<sup>18</sup> reported apical deltas in 9.3% of mandibular central incisors in a Romanian population.



### 1.1.5.6 Intercanal anastomosis in permanent mandibular central and lateral incisors

An intercanal anastomosis commonly referred to as isthmus, is a fin or corridor which may be present between the two canals. Green D.<sup>41</sup> described this corridor as a “ribbon shaped passage” of embryonic origin, formed through the epithelial root sheath<sup>52</sup>. An isthmus is formed when an individual root projection is unable to close itself off<sup>52</sup>. Intercanal anastomosis can be found anywhere along the canal length. Presence of untreated intercanal anastomosis is one of the causes of unfavorable endodontic treatment outcome<sup>53</sup>.

Yeung Yi Hsu<sup>52</sup> classified intercanal anastomosis as shown below (Figure 1.4).



Type I



Type II



Type III



Type IV



Type V

**Figure 1.4: Classification of intercanal anastomosis by Yeung Yi Hsu <sup>52</sup>**

The intercanal anastomoses are described below.

**Type I:** Two or Three canals with no notable communication.

**Type II:** Two canals that possess a definite connection between the two main canals.

**Type III:** Three canals that are present with a definite connection. Incomplete "C" shaped canals with three canals are also included.

**Type IV:** Canals extending into the isthmus area.

**Type V:** True connections or corridor present throughout a section of the root canal.

Green D. <sup>51</sup> found this ribbon shaped passage in 22% of mandibular central and lateral incisors.

**1.1.5.7 Position and number of apical foramina in permanent mandibular central and lateral incisors**

An apical foramen is the apical entry point of the neurovascular bundle into the canal and exit point of canal contents into the peri-apical region <sup>1, 2, 31</sup>. Variation in the position and number of apical foramina is a common feature in mandibular incisors. This is mostly seen in teeth with two canals. Boruah & Bhuyan <sup>23</sup> reported that 8.7% of teeth with two canals had two separate foramina while 91.3% of teeth with two canals had the canals merging into one canal before exiting the tooth through one apical foramen. The apical foramen can be located at the tip of the anatomical root apex or some distance away from the anatomical apex. The position varies from tooth to tooth. According to Walker R.T <sup>30</sup>, the distance between the apical foramen and the most apical end of the root ranges 0.2mm to 2.0mm. The shape of the root and presence of root

curvature may influence the position of the apical foramen. In a recent study, Boruah & Bhuyan<sup>23</sup> reported that apical foramen was found to coincide with the apical root tip in 47.2% of mandibular central and lateral incisors. Researchers have demonstrated varying number of apical foramen (one to three) in relation to number of canals (Table 1.2)<sup>19, 20, 21, 28, 39, 40, 41, 47</sup>.

**Table 1.3: Number of apical foramen in relation to number of canals**

Investigator	Population studied	Sample size	Method of investigation	One canal and one apical foramen	One canal and two apical foramina	Two canal and one apical foramina	Two canals and two apical foramina	Three canals and three apical foramina
Green D. <sup>41</sup>	U. S. A	200	In-vitro section	80%	-	7%	13%	-
Wilson R. and Henry p. <sup>40</sup>	U. S. A	111	In-vitro radiographs	60%	-	35%	5%	-
Green D. <sup>41</sup>	U. S. A	500	In-vitro section	79%	-	17%	4%	-
Madiera M.C and Hetem S. <sup>39</sup>	-	1330	In-vitro clearing and dyeing	88.5%	-	11%	0.5%	-
Benjamin and Dowson <sup>21</sup>	U. S. A	364	In-vitro radiographs	59%	-	40%	1.0%	-
Vertucci F. J. <sup>19, 20</sup>	U. S. A	200	In-vitro section	92.5%	-	5%	2.5%	-
Caliskan <sup>28</sup>	Turkish	100	clearing	82%	2%	14%	-	2%

The size of apical foramen in permanent mandibular incisors has been reported to be 262.5µm in diameter<sup>54</sup>.

### **1.1.6 Role of genetics in canal morphology of permanent mandibular central and lateral incisors**

The role of genetics in root morphology has been demonstrated by the fact that specific types of canal morphology appear to occur in different racial groups. Patients of Asian descent have different frequencies of canals and configurations when compared to those reported in studies dominated by Caucasian and African populations<sup>5, 18, 23, 24, 25, 26, 28, 49, 50</sup>. Chromosomal aberrations have been associated with unusual canal morphology especially canal length<sup>25, 26</sup>.

### **1.1.7 Techniques used to study root and canal morphology**

Plain radiography, sectioning, microscopy, photography, polyester casting resin, computer tomograms, cone beam computer tomography and clearing techniques have been used to study root and canal anatomy of teeth. Some of these techniques are described below.

Plain radiography: This involves taking a peri-apical radiograph to assess canal morphology. It is the simplest method of studying root and canal anatomy but less inaccurate as compared to other methods<sup>18, 21</sup>.

Sectioning: This involves surgical resection of a given portion of the root such as the apical third, coronal third or middle portion through the use of burs or lasers<sup>29</sup>.

Microscopy: This involves use of loupes and an operating microscope. Introduction of the dental operating microscope has increased the reported prevalence of extra canals identified at the floor of the pulp chamber. It is reported to enhance the dentist's ability to selectively remove dentine with great precision thereby minimizing procedural errors such as missed canals, under preparation of canals and over preparation of canals<sup>54</sup>.

Computerized tomography: This involves production of 3D images of objects using slices obtained from scanning<sup>56</sup>.

Standard clearing technique: This involves use of a staining material such as India ink followed by decalcification of the specimen through the use of acids such as nitric acid or hydrochloric acid. Clearing is then done mostly with methyl salicylate, which renders the teeth transparent<sup>55</sup>.

Cone Beam Computerized Tomograph: This is also an example of a 3D imaging system but unlike the CT scanner that takes axial slices of the patient, it captures multiple images for 14 to 20 seconds during a single partial rotation around the patient's head. The main structural difference is that the x-ray beam is in the shape of a cone instead of a fan. The x-ray source in CBCT is a low energy fixed anode similar to that used in panoramic machines while that of CT is a high output rotating anode generator<sup>56</sup>. CBCT been shown to be advantageous to CT scans in a number of ways<sup>57, 58, 59</sup>. The CBCT scanner, such as the I-CAT, significantly reduced radiation exposure by 80-90%. In addition, CBCT also reduced scatter from existing restorations. Another distinct advantage it offers over CT is that it takes images of both arches at the same time instead of one thereby reducing exposure to patients. CBCT also high resolution images resulting in excellent detail production and is extremely fast, taking approximately 9 to 40 seconds to produce 512 axial images<sup>57, 58, 59</sup>.

Clearing and staining technique was first highlighted by Robertson *et al.*<sup>55</sup> and since then many researchers have used it. Caliskan *et al.*<sup>28</sup> used staining and clearing technique in studying root and canal morphology of mandibular incisors in an Italian population. Staining and clearing

technique has been shown to be an effective method of studying the canal morphology. Unlike radiographic images, it provides a three dimensional view of the pulp cavity in relation to the exterior of the teeth and allows a comprehensive examination of the pulp chamber and root canal system. The Dental Operating Microscope (DOM) is an equally effective method in studying root and canal morphology. However, the microscope is expensive and requires training on its use and is therefore not readily available in our Kenyan hospitals dental set up. This necessitates use of anatomical knowledge on root and canal morphology and radiographical examination during root canal treatment. The study of root and canal morphology using clearing technique will therefore provide information relevant in execution of root canal treatment among Kenyans.

## **1.2. RESEARCH PROBLEM**

It is universally accepted that retention of a natural tooth with a good prognosis is a superior choice to loss and replacement and therefore restorative and endodontic treatments are some of the modalities of restoring affected teeth to health and function. Unfortunately, not all treatments results in favorable outcome due to clinicians lack of knowledge on root and canal morphology of mandibular incisors, inappropriate chemo-mechanical preparation and obturation of these teeth. The high rate of unsuccessful outcomes translates into relatively large numbers of patients requiring retreatment <sup>7, 51, 60, 61, 62</sup>.

Even though the complex fins, webs and communications may not contribute significantly to endodontic treatment outcome, knowledge of number of roots and canals and their configurations contributes to overall endodontic treatment outcome <sup>42, 43, 62</sup>. It is therefore important for the clinicians to have knowledge of root and canal morphology before undertaking endodontic therapy even in such circumstances. In the absence of diagnostic aids, this can only be achieved through scientifically supported research findings such as this.

### **1.3 JUSTIFICATION OF THE STUDY**

In Kenya, cases of unfavorable root canal treatment outcome in mandibular incisors are on the rise. This can only be attributed to improper shaping, cleaning and obturation of the canal systems due to lack of knowledge of root canal systems in these teeth. There being no data on root and canal morphology of permanent mandibular incisors in the Kenyan population, there was a gap in knowledge that required filling by way of research. The aim of the study was therefore to investigate the root and canal morphology of mandibular incisors in a Kenyan population using decalcification and clearing technique. The research findings will form a national data for Kenyans and provide a useful source of information to dentists practicing endodontics and other disciplines of dentistry. The findings will also form a basis for further research in these fields.

### **1.4 STUDY OBJECTIVES**

#### **1.4.1 Broad objectives**

To investigate root and canal morphology in permanent mandibular central and lateral incisors in a Kenyan population.

#### **1.4.2 Specific objectives**

1. To determine the root morphology in permanent mandibular central and lateral incisors.
2. To determine the average root and total tooth length in permanent mandibular central and lateral incisors.
3. To determine the canal morphology in permanent mandibular central and lateral incisors.
4. To determine canal configurations in permanent mandibular central and lateral incisors.

5. To determine the number and position of apical foramina in permanent mandibular central and lateral incisors.

### 1.5 NULL HYPOTHESIS

1. There is no variation in root morphology in the permanent mandibular central and lateral incisors.
2. There is no variation in canal morphology in the permanent mandibular central and lateral incisors.

### 1.6 STUDY VARIABLES

<b>Classification</b>	<b>Variable</b>	<b>Measurement</b>
Independent Variable	Tooth type	Permanent mandibular central or lateral incisor.
Dependent Variable	Root morphology	Number of roots Presence of bilateral grooves Root curvature Root length in millimeters Position of root curvature
	Canal morphology	Number and shape of canals Canal configurations Number of lateral canals Number of apical deltas Number of apical foramina Position of apical foramen in relation to apex Number of intercanal anastomosis



## CHAPTER TWO

### MATERIALS AND METHODS

#### 2.1 STUDY DESIGN

This was a descriptive cross sectional study.

#### 2.2 STUDY AREA

The study was conducted in public hospitals and dental clinics which attend to high number of dental patients within Nairobi County in Kenya and its neighboring counties.

Nairobi is a cosmopolitan city with a population of about 4 million people. Majority of the city residents are migrants from all parts of the country. Non-probability purposeful sampling method was used to select the hospitals with high number of dental patients.

The hospitals included; the University of Nairobi Dental Hospital, Kenyatta National Hospital Dental Clinic, Kiambu District Hospital, Thika Level Five Hospital, Mbagathi District Hospital, Social League Dispensary, Gatundu District Hospital, Kajiado District Hospital, Machakos Level Five Hospital, Ngong District Hospital and Mathari District Hospital. Some hospitals are described below.

##### **Kenyatta National Hospital**

Kenyatta National Hospital (KNH) is the national referral hospital located in Nairobi County, along Ngong road and handles referral patients from all over the country and from neighboring African countries for specialized treatment. The Dental Department is situated in the old wing of the hospital. It has divisions catering for specialties' in dentistry. It serves as an internship training centre where newly qualified doctors treat patients under the supervision of specialists.

### **University of Nairobi Dental Hospital**

University of Nairobi School of Dental Sciences is situated off Argwings Kodhek road opposite Nairobi Hospital. The hospital trains both undergraduate students leading to a degree of Bachelor of Dental Surgery and postgraduate students leading to a Master of Dental Surgery degree in disciplines of Oral and Maxillofacial Surgery (OMFS), Paediatric Dentistry, Prosthodontics and Periodontology. The hospital is a referral centre for treatment of oral and maxillofacial conditions such as fractures and oral cancers.

### **Mbagathi District Hospital**

This is situated off Mbagathi road and adjacent to Forces Memorial Hospital. The hospital was initially a referral centre for infectious diseases but currently attends to all patients', outpatient and inpatient including those in need of dental treatment. Due to proximity and relatively low cost, the hospital attends to many patients from the neighboring Kibera slums.

### **Mathari District Hospital**

This Hospital is located along Thika super highway opposite Muthaiga police station. The hospital is a referral hospital for patients with mental illnesses. However, the Hospital offers inpatient and outpatient services for other medical and dental conditions. The hospital attends to a huge number of patients due to relatively low cost of services and proximity to major slums within the city.

### **Kajiado District Hospital**

This Hospital is located along Nairobi-Namanga road about 80km from Nairobi. The hospital is a referral hospital within Kajiado County. The hospital offers inpatient and outpatient services for medical and dental problems. The Hospital attends to many patients from the neighboring Maasai community and other communities who have intermingled with the Maasai.

## **Gatundu District Hospital**

This Hospital is located along Juja-Githunguri road off Thika super highway approximately 50km from Nairobi. The Hospital offers inpatient and outpatient services for medical and dental conditions. The Hospital attends to patients from the neighboring Kikuyu community and from Nairobi due to its proximity and low cost of services.

### **2.3 STUDY POPULATION**

The study sample consisted of extracted permanent mandibular central and lateral incisors obtained from Kenyans of African descent.

#### **2.3.1 Inclusion Criteria**

1. Only permanent mandibular central and lateral incisors were included in the study.
2. Sound teeth with no caries, root filling, metallic restorations, fracture or incompletely formed apices, attrition, erosion and abrasion.
3. Teeth from Kenyans of African descent.
4. Teeth from patients 10 years old and above.
5. Teeth from patients who consented to the study.

#### **2.3.2 Exclusion Criteria**

1. All other teeth other than permanent mandibular central and lateral incisor.
2. Teeth from Kenyans not of African descent.
3. Teeth with caries, root filling, metallic restorations, fracture or incompletely formed apices, attrition, erosion and abrasion.
4. Teeth from patients under 10 years old.
5. Teeth from patients who did not consent to the study and children who did not assent.

### **2.4 SAMPLE SIZE DETERMINATION**

Betty R. Kirkwood (1992) method was used to determine the sample size<sup>63</sup>.

$$n = \frac{z^2 \cdot u}{e^2}$$

Where ,

n= desired sample size,

u=Estimated proportion of an attribute in the target population. In this study, different aspects of teeth morphology will be studied. A previous study in the population reported 12.5 millimeters mean root length in permanent mandibular central incisor. This will be used as a reasonable estimate for one of the characteristics under study <sup>2</sup>.

e= maximum size of standard error in the measurement set at 0.5mm.

z= standard deviation set at 1.96 (95% confidence level).

$n = 1.96 \times 1.96 \times 12.5 / 0.5 \times 0.5 = 192$  teeth. The minimum sample was calculated to be 192 for both central and lateral incisors. However, 208 teeth were involved in the study.

## **2.5 SAMPLING**

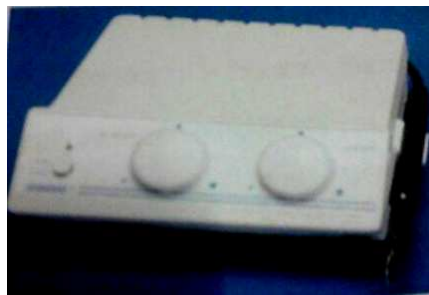Convenient sampling was done. Teeth were obtained from patients who visited the hospital for dental treatment and had an extraction of a permanent central or lateral mandibular incisor.

## **2.6 DATA COLLECTION INSTRUMENTS AND TECHNIQUE**

### **2.6.1 Collection of Teeth**

The patients went through the hospital diagnostic process and extraction of a permanent mandibular central or lateral incisor was done where indicated. Prior to extraction, consent to collect the teeth after extraction was obtained from the patient, while consent from guardian and assent from children was obtained for those below 18 years. The extracted teeth were washed in tap water immediately after extraction then immersed in 3.85% m/v sodium hypochlorite solution (Reckitt Benckiser E.A. Nairobi, Kenya) for a minimum of thirty minutes to remove adherent soft tissue and for disinfection.

Two labeled containers were supplied at each collection point. Teeth were collected by the principal investigator and trained assistants into containers labeled as either mandibular central incisor or mandibular lateral incisor. Verification of the teeth for specificity was done at the collection centres by the principal investigator and trained assistants. Subsequently the teeth were washed in plain water and calculus and organic debris were removed using an ultrasonic scaler (Parkell, inc, Edgewood, USA) shown below (Figure 2.1). Subsequent storage was done in 10% formalin (ART-M3 Bonart, Taiwan).



**Figure 2.1: Ultrasonic scaler**

### **2.6.2 Teeth Examination**

A data collection form was used to record observations and measurements of each specimen. Data collected included number of roots, crown length and root morphology. Crown length was measured from incisal edge to cemento-enamel junction. The presence or absence of bilateral grooves on the roots was also recorded in the data collection form.

### **2.6.3 Root Length and root curvature**

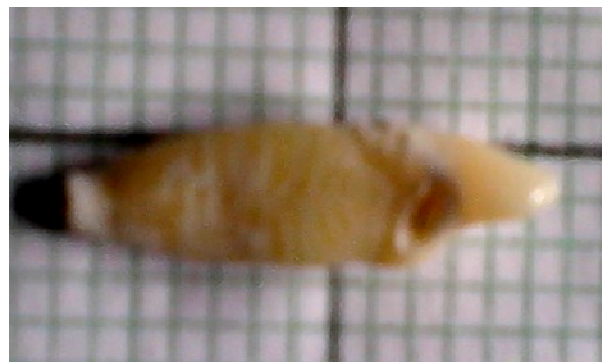Only teeth with complete root apices and coronal reference points unaffected by attrition, erosion caries or fracture were studied. The root length was measured from the cemento-enamel junction to the apex using calibrated electronic vernier caliper (Shengya Machine & tools Co., Ltd.) to the nearest 0.01mm (Figure 2.2). Curved roots were measured in two sections; the section from the

cemento-enamel junction to point of curvature was added to section from point of curvature to the anatomical apex.



**Figure 2.2: Electronic vernier caliper**

The teeth were orientated in their anatomical positions on a calibrated graph paper (Kartasi Graph Book, Nairobi Kenya) and root curvature determined with reference to the long axis of root from cemento-enamel junction. Visual examination of the root against the grid was done to determine whether the root is straight, curved towards mesial, distal, labial or lingual directions (Figure 2.3). The direction of root curvature was determined by the position of the root apex from long axis of root. Position of root curvature was also determined as either coronal 1/3, middle 1/3 or apical third of the root.



**Figure 2.3: Root curvature on a graph paper. The tooth is rotated 90 degrees to the right.**


## **2.6.4 Canal Morphology**

### **2.6.4.1 Number of canals, canal configuration, number of lateral canals, number of apical deltas, position of apical foramen and number of apical foramen**

A standard clearing technique was applied to determine the number of canals, canal configurations, position of apical foramen and number of apical foramen.

Access cavities were prepared on the extracted teeth using a high speed hand piece and diamond fissure burs and the coronal pulp tissue extirpated until the canal orifices. The teeth were immersed in 5.25% sodium hypochlorite solution (Chlorex-5, Syner –chemie, Nairobi, Kenya) for 24 hours to dissolve organic debris then washed in running water for 2 hours. This was followed by drying for 12 hours. An endodontic syringe with a gauge 27 needle (BU Kwang Medical Inc., Seoul, Korea) was used to inject Indian ink (Sanford rotring GmbH, Hamburg, Germany) into the root canal system. The root apex was then connected to a central suction system, until the ink exited through the apical foramen, and left to dry for 12 hours. The teeth were immersed in 10% nitric acid (Ridel Thaeen, Germany) for 5 days for decalcification. The acid was agitated daily and the process was monitored every 24 hours by radiography to avoid over decalcification.

Decalcified teeth were then washed in running tap water for 4 hours, dried and dehydrated in ascending concentrations (70%, 95%, 100%) of ethyl alcohol (Scharlab S.L. Sentmenat, Spain) for 3 days to ensure firmness. They were then rendered transparent by immersing in methyl salicylate (Rankem RFCL Limited Okhla-India) for six hours (Figure 2.4).



**Figure 2.4: Diagram of a transparent central incisor root rotated 90 degrees to the right**

The decalcified teeth were observed with a magnifying lens (magnification power of  $\times 3$ ) for the following; number of canals, canal configurations, number of lateral canals, number of apical deltas, position and number of apical foramen. Classification of root canals was done using Vertucci's 1984<sup>20</sup> classification.

## **2.7 DATA ANALYSIS AND PRESENTATION**

The collected data was stored, coded and analyzed using Statistical Packages for Social Sciences (SPSS Version 16, Illinois-Chicago) for windows and Microsoft excel. Analysis done included frequencies, means, chi-square tests and t-tests. The information obtained was organized and presented as descriptive statistics in form of frequency tables and pie charts. Relationships found were tested using appropriate inferential statistics and a  $P < 0.05$  was considered significant.

## **2.8 DATA RELIABILITY AND VALIDITY**

To ensure that data is representative of the general population, the teeth were collected from public dental clinics in Nairobi and its environs. To control for external and internal influences the investigator participated in teeth collection and trained assistants. Verification of teeth collected was done prior to analysis. To ensure internal morphology was fully studied, a standard clearing technique was strictly followed and monitored.



The principal investigator was calibrated by the lead supervisor for inter-examiner variability. The lead supervisor checked and verified measurements and data obtained on root and canal morphology of 10% of the specimens collected. Cohen's Kappa score of 0.9 was obtained. The investigator re-examined every 10<sup>th</sup> tooth to evaluate intra-examiner variability. Cohen's Kappa score of 0.8 was obtained for mean root length. This showed good consistency and minimal variability and according to WHO classification of Kappa score, this was good to near perfect agreement. The principal investigator did all the measurements on teeth to reduce intra-examiner variations.

## **2.9 CONTROL OF ERRORS AND BIASES**

Teeth which met the inclusion criteria were the only ones included in the study. All data collection tools were pretested and all instruments were calibrated.

## **2.10 ETHICAL CONSIDERATIONS**

Before commencing the study, approval was obtained from Kenyatta National Hospital and University of Nairobi Standards, Ethics and Research committee.

The permission to collect teeth from the dental clinics was sought and obtained from the administrators in the selected hospitals. All extracted teeth were accompanied by a consent form duly signed by the patient or guardian allowing the use of their teeth for study.

Patients were not required to reveal their identity and even when this was known, it was kept confidential.

Every tooth that met the inclusion criteria had an equal chance of being included in the study and study findings will be used for the benefit of the entire population.

## **2.11 STUDY LIMITATIONS**

Application of non-probability sampling method may have eliminated some clinics where teeth with varied morphology may have been collected.

Research assistants were required during collection and verification of teeth. Observer bias might have occurred leading to wrong identification of either a mandibular central or lateral incisor.

## **2.12 ENVIRONMENTAL CONSIDERATIONS**

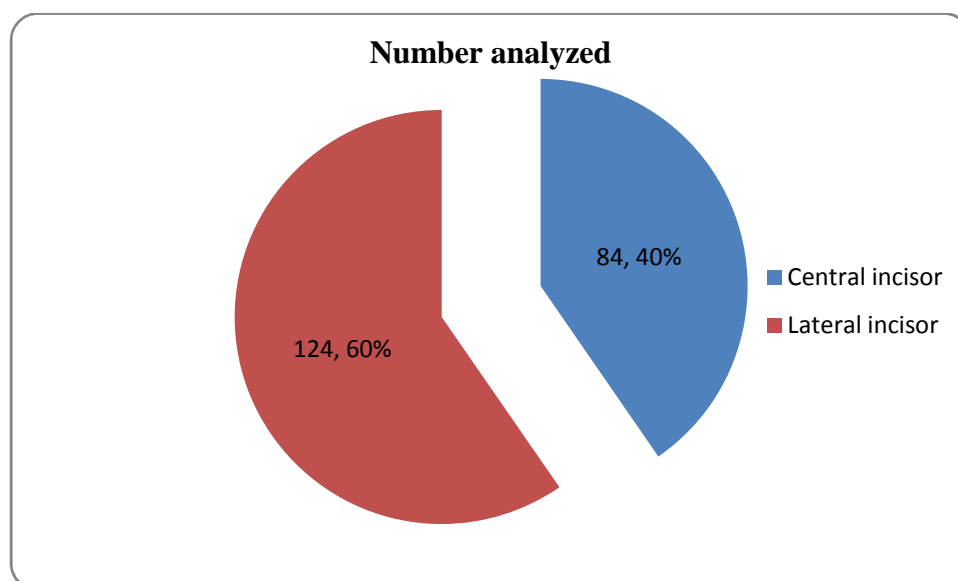
All teeth used in the study were incinerated as per the established guidelines at the School of Dental Sciences, University of Nairobi.

## CHAPTER THREE

### 3.1 RESULTS

#### 3.2 General observations

Two hundred and eight permanent mandibular incisors were included in the study. Out of these, 84 (40.4%) and 124 (59.6%) were central and lateral mandibular incisors respectively (Figure 3.1). All the extracted teeth studied had one root.



**Figure 3.1: Distribution (n) of analyzed permanent mandibular incisors.**

#### 3.3 Presence of bilateral grooves in permanent mandibular central and lateral incisors

Table 3.1 shows the distribution of unilateral and bilateral grooves in mandibular central and lateral incisors. In both central and lateral incisors, bilateral grooves were seen in 130 (62.5%). Though mandibular central incisors had a higher percentage of bilateral grooves than mandibular lateral incisors, the difference was not statistically significant ( $\chi^2 = 1.04$ ,  $df = 1$ ,  $P = 0.307$ ).

**Table 3.1: Distribution of bilateral grooves in permanent mandibular central and lateral incisors**

Tooth	Distribution of grooves		$\chi^2$	df	P
	Unilateral grooves	Bilateral grooves			
Mandibular central incisors (n=84)	28 (33.33%)	56 (66.67%)	1.04	1	0.307
Mandibular lateral incisors (n=124)	50 (40.32%)	74 (59.68%)			
Total	78 (37.5%)	130 (62.5%)			

### 3.4 The position of the roots relative to the crown in mandibular central and lateral incisors

Table 3.2 shows that majority, 73.81% of mandibular central incisors and 72.58% of lateral incisor had their roots laterally positioned relative to the long axis of the crown.

Mandibular central incisors had an insignificant higher percentage of laterally positioned roots than mandibular lateral incisors. ( $\chi^2 = 0.384$ , df = 1, P = 0.845).

**Table 3.2: Distribution of the position of the roots relative to the crown**

Tooth	Position of root in relative to the crown		$\chi^2$	df	P
	Central	Lateral			
Mandibular central incisors (n=84)	22 (26.19%)	62 (73.81%)	0.384	1	0.845
Mandibular lateral incisors (n=124)	34 (27.42%)	90 (72.58%)			
Total	56 (26.92%)	152 (73.08%)			

### 3.5 Root curvature in permanent mandibular central and lateral incisors

Majority, 68.27% of the teeth had curved roots as compared to 31.73% that had straight roots.

Mandibular lateral incisors had an insignificant higher percentage of curved roots as compared to mandibular central incisors ( $\chi^2 = 0.167$ ,  $df = 1$ ,  $P = 0.683$ ) (Table 3.3).

**Table 3.3: Distribution of straight versus curved roots in permanent mandibular central and lateral incisors.**

Tooth	Root curvature		$\chi^2$	df	P
	Straight	Curved			
Mandibular central incisors (n=84)	28 (33.33%)	56 (66.67%)	0.167	1	0.683
Mandibular lateral incisors (n=124)	38 (30.65%)	86 (69.35%)			
Total	66 (31.73%)	142 (68.27%)			

### 3.6 Position and direction of root curvature in permanent mandibular central and lateral incisors

The position of root curvature was apical 1/3 in all the curved mandibular central and lateral incisors. Most teeth, 69.01% were curved distally, 19.72% of the teeth were curved mesially and 11.27% were labially curved as shown in table 3.4. Lingual curvatures were not observed. Mandibular central incisors had an insignificantly higher percentage of mesially curved roots than mandibular lateral incisors while mandibular lateral incisors had an insignificant higher percentage of distally and labially curved roots than mandibular central incisors ( $\chi^2 = 0.18$ ,  $df = 1$ ,  $P = 0.914$ ).

**Table 3.4: Direction of root curvature in permanent mandibular central and lateral incisors**

Tooth	Direction of root curvature			$\chi^2$	df	P
	Mesial	Distal	Labial			
Mandibular central incisors (n=56)	12 (21.43%)	38 (67.86%)	6 (10.71%)	0.18	2	0.914
Mandibular lateral incisors (n=86)	16 (18.6%)	60 (69.77%)	10 (11.63%)			
Total	28 (19.72%)	98 (69.01%)	16 (11.27%)			

### **3.7 Crown length, root length and total tooth length in permanent mandibular central and lateral incisors**

The length of crown ranged between 7mm and 10mm with a mean of  $8.45 \pm 0.244$ mm in mandibular central incisors and  $8.9 \pm 0.188$ mm in mandibular lateral incisors.

The root length in mandibular central incisors ranged between 10mm and 15mm with a mean root length of  $12.38 \pm 0.244$ mm while the root length in mandibular lateral incisors ranged between 10mm and 16mm with a mean of  $13.55 \pm 0.4$ mm.

The total tooth length ranged between 18mm and 24mm with a mean of  $20.83 \pm 1.67$ mm in mandibular central incisors while that of mandibular lateral incisor ranged between 17.5mm and 25.5mm with a mean of  $22.45 \pm 2.03$ mm.

The mandibular lateral incisors were significantly longer than mandibular central incisors ( $t=6.06$ ,  $P=0.000$ ) (Table 3.5).

**Table 3.5: Comparison of mean tooth lengths in mandibular central and lateral incisors**

<b>Tooth</b>	<b>Mean tooth length</b>	<b>t</b>	<b>P</b>
Mandibular central incisors (n=84)	20.83 ± 1.67mm	6.06	0.000
Mandibular lateral incisors (n=124)	22.45 ± 2.03mm		

### 3.8 Number of canals in permanent mandibular central and lateral incisors

Table 3.6 shows that majority of mandibular central, 80.95% and lateral 82.26% incisors had one canal at the pulp chamber floor. Two canals were observed in 16 (19.05%) and 12 (17.74%) of central and lateral incisors respectively. Mandibular lateral incisors had an insignificant higher percentage of one canal as compared to mandibular central incisors ( $\chi^2 = 0.572$ ,  $df = 1$ ,  $P = 0.811$ ).

All the incisors had one canal at the anatomical root apex.

**Table 3.6: Distribution of one and two canals in permanent mandibular central and lateral incisors**

<b>Tooth</b>	<b>Number of canals at the pulp chamber floor</b>		$\chi^2$	<b>df</b>	<b>P</b>
	<b>One canal</b>	<b>Two canals</b>			
Mandibular central incisor (n=84)	68 (80.95%)	16 (19.05%)	0.572	1	0.811
Mandibular lateral incisor (n=124)	102 (82.26%)	22 (17.74%)			
Total	170 (81.73%)	38 (18.27%)			

### 3.9 Canal configurations in permanent mandibular central and lateral incisors

Table 3.7 shows the distribution of canal configurations in mandibular central and lateral incisors. According to Vertucci classification, 71.43% of central incisors had type I classification, 19.05% had type II configuration and 8.33% had type III configuration. Of the mandibular lateral incisors, 68.55% had Vertucci type I canal configuration, 17.74% had type II configuration and 13.71% had type III configuration. Mandibular central incisors had an insignificant higher percentage of Vertucci type I and II canals as compared to mandibular lateral incisors while mandibular lateral incisors had an insignificant higher percentage of Vertucci type III canal as compared to mandibular central incisor ( $\chi^2 = 1.36$ ,  $df = 2$ ,  $P = 0.507$ ). A canal type undescribed by neither Vertucci F.J.<sup>20</sup> nor Weine *et al*<sup>51</sup> was observed in one (1.2%) mandibular central incisor. This undescribed canal began as one from the pulp chamber, divided into two at the coronal 1/3 of the root, one of the two canals divided into two making a total of three canals at the middle 1/3 of the root and then all joined together to exit as one canal.

**Table 3.7: Distribution of Canal configurations in permanent mandibular central and lateral incisors**

Tooth	Canal type I - III			$\chi^2$	df	P
	I	II	III			
Mandibular central incisor (n=84)	60 (71.43%)	16 (19.05%)	7 (8.33%)	1.36	2	0.507
Mandibular lateral incisor (n=124)	85 (68.55%)	22 (17.74%)	17 (13.71%)			
Total	145 (69.71%)	38 (18.27%)	24 (11.54%)			

Canal types IV-VIII were not observed and therefore not included in the table above.



### 3.10 Number of lateral canals in permanent mandibular central and lateral incisors

Only 28 (13.46%) teeth out of the total 208 mandibular central and lateral incisors had lateral canals. There was no significant difference in the occurrence of lateral canals between the mandibular central and lateral incisors ( $\chi^2 = 0.293$ ,  $df = 1$ ,  $P=0.588$ ). The lateral canals were observed in the middle third of the root.

**Table 3.8: Frequency of lateral canals in mandibular central and lateral incisors.**

Tooth	Lateral canals		$\chi^2$	df	P
	Present	Absent			
Mandibular central incisor (n=84)	10 (11.9%)	74 (88.1%)	0.293	1	0.588
Mandibular lateral incisor (n=124)	18 (14.52%)	106 (85.48%)			
Total	28 (13.46%)	180 (86.54%)			

### 3.11 Number of apical deltas and intercanal anastomoses in permanent mandibular central and lateral incisors

Apical deltas were not a frequent occurrence in mandibular incisors (Table 3.9). Of the mandibular central and lateral incisors, only 22 (10.58%) had apical deltas. There was no significant difference in the presence of apical deltas between the mandibular central and lateral incisors ( $\chi^2 = 0.263$ ,  $df = 1$ ,  $P=0.608$ ). Intercanal anastomoses were not observed in either of the teeth.

**Table 3.9: Frequency of apical deltas in permanent mandibular central and lateral incisors**

Tooth	Apical deltas		$\chi^2$	df	P
	Present	Absent			
Mandibular central incisors (n=84)	10 (11.9%)	74 (88.1%)	0.263	1	0.608
Mandibular lateral incisors (n=124)	12 (9.68%)	112 (90.32%)			
Total	22 (10.58%)	186 (89.42%)			

**3.12 Number of apical foramina in central and lateral incisors**

Of the 208 mandibular central and lateral incisors, 186 (89.42%) had a single apical foramina while 22 (10.58%) had three apical foramen as depicted in table 3.10. There was no significant difference in the occurrence of a single or three apical foramen between mandibular central and lateral incisors ( $\chi^2 = 0.263$ , df = 1, P = 0.608).

**Table 3.10: Number of apical foramina in permanent mandibular central and lateral incisors**

Tooth	One apical foramina	Three apical foramina	$\chi^2$	df	P
Mandibular lateral incisor (n=124)	112 (90.32%)	12 (9.68%)			
Total	186 (89.42%)	22 (10.58%)			

### 3.13 Position of apical foramina relative to anatomical apex in permanent mandibular central and lateral incisors

Majority of teeth, 146 (70.19%) had apical foramen positioned at the anatomical apex, 41 (19.71%) had apical foramen positioned 0.25mm-0.5mm from the anatomical and 21 (10.1%) had apical foramen positioned 0.5mm- 1mm from the anatomical apex. There was no significant difference in the positioning of the apical foramen between mandibular central and lateral incisors ( $\chi^2=0.283$ ,  $df = 2$ ,  $P=0.868$ ) (Table 3.11).

**Table 3.11: Position of apical foramina relative to anatomical apex**

Tooth	Position of apical foramen in relation to anatomical apex			$\chi^2$	df	P
	At the anatomical apex	.25mm- 0.5mm from apex	0.5mm-1mm from apex			
Mandibular central incisors (n=84)	58 (69.05%)	18 (21.43%)	8 (9.52%)	0.283	2	0.868
Mandibular lateral incisors (n=124)	88 (70.97%)	23 (18.55%)	13 (10.48%)			
Total	146(70.19%)	41 (19.71%)	21 (10.1%)			

## CHAPTER FOUR

### 4.0 DISCUSSION

Root canal treatment is part of patient management in both public and private dental clinics around Kenya. The facilities in the different clinics vary in terms of availability and adequacy especially the equipment required for establishment of root and canal morphology. In the absence of modern diagnostic equipments, knowledge on the root and canal morphology of the teeth is important. This study sought to establish the root and canal morphology of permanent mandibular central and lateral incisors to obtain data that can be relied upon by clinicians undertaking endodontic treatment in these teeth.

#### **Number of roots and presence of bilateral grooves in permanent mandibular central and lateral incisors**

All mandibular incisors had one root. No bifid roots were observed. These findings were similar to a previous study done in an East African population. Ngassapa *et al.*<sup>2</sup> reported single conical roots flattened mesio-distally with longitudinal grooves on both the mesial and distal surfaces with the distal groove being deeper than the mesial. However in this study, bilateral grooves were only found in 66.7% of central incisors and 59.7% of lateral incisors respectively. The difference between the current study and the previous study can be attributed to method of observation of bilateral grooves. Direct observation was used to determine the presence of grooves in the previous study unlike the combined direct and indirect observation (use of magnification lens and loupes) used in this study.

### **Position of root in relation to long axis of the crown in permanent mandibular central and lateral incisors**

The position of the root may signify straight or curved canals. Majority of the central and lateral incisor roots were laterally positioned in relation to the long axis of the crown. However a previous study by Bardelli *et al.*<sup>31</sup> in an Italian population reported a ratio of 1:1 in the position of the roots relative to the crown. The difference between the current study and study by Bardelli *et al.*<sup>31</sup> can be attributed to racial variation method of observation of position of the roots (use of loupes and magnification lens). In the current study, direct (visual) and indirect observation methods were used to determine the positioning of the root in a Kenyan population while Bardelli *et al.*<sup>31</sup> used direct observation (visual) only in an Italian population.

### **Position and direction of root curvature in permanent mandibular central and lateral incisors**

Endodontic treatment in curved roots has been associated with iatrogenic errors such as loss of working length, apical transportation, creation of ledges, perforations and instrument separation. Knowledge of the degree of curvature enables the clinician to pre-curve the endodontic files. Two dimensional radiographs must therefore be interpreted with caution since a straight root in a mesio-distal dimension may be curved in a labio-lingual direction.

Majority of the mandibular incisor roots were curved. The curvatures were in the apical 1/3 of the root. The direction of curvature was mesial, distal or labial. Previous studies by Sinziana *et al.*<sup>18</sup>, Boruah *et al.*<sup>24</sup> and Pineda & Kuttler<sup>33</sup> reported that root curvatures are very rare in these teeth.

The difference in frequency of curvature between this study and previous studies may be attributed to racial variation and technique employed in studying the root curvature. Pineda &

Kuttler<sup>33</sup> used a radiographic method which differs from graphic method used in this study. Sinziana *et al.*<sup>18</sup> obtained the sample from a Romanian population while Boruah *et al.*<sup>23, 24</sup> obtained the sample from an Indian population as compared to Kenyan population in this study.

### **Crown, root and total tooth length in permanent mandibular central and lateral incisors**

The knowledge of average lengths of mandibular permanent incisors is of great interest and practical value in endodontic treatment. These findings may be useful in determining working lengths accurately with hand files or while using apex locators particularly in cases of Vertucci canal types V, VI and VII. The knowledge of root canal curvature and root length may be useful in determination of post length and whether a favorable post length: crown height ratio can be achieved during restoration of endodontically treated teeth.

The mean mandibular central and lateral incisor crown length, root length and total tooth length in this study were lower than those reported by previous studies by Ngassapa *et al.*<sup>2</sup> and Maina *et al.*<sup>36</sup> in an East African population and Kenyan population respectively. Hilary *et al.*<sup>35</sup> reported mean tooth lengths of 21.5mm and 23.5 mm in central and lateral incisors respectively which are higher than the 20.83mm and 22.45mm in the current study. The difference may be explained by the variation in instruments used for measurements. Current study measured tooth lengths in two parts; from the incisal edge to cemento-enamel junction added to measurement from cemento-enamel junction to tip of the root using a calibrated digital vernier caliper while the previous studies measured tooth lengths directly from incisal edge to root tip using a manual vernier caliper. Measurement of length in two parts is more accurate because curvatures are taken into account by either of the partial measurements.

### **Number of canals in permanent mandibular central and lateral incisors**

Identification of a second canal on the lingual aspect of the usual canal in central and lateral incisors is of significance since unfavorable endodontic treatment outcomes have been attributed to missed canals. Knowledge of canal shape may help in selection of endodontic files.

Most of mandibular central and lateral incisors had one canal at the floor of the pulp chamber and at the apical exit. All canals on visual examination were conical with the widest portion being on the coronal aspect and thinning out into a taper towards the apex. These results are in agreement with previous studies by Sinziana *et al.*<sup>18</sup>, Benjamin & Dowson<sup>21</sup>, Caliskan *et al.*<sup>28</sup> and Parrini *et al.*<sup>29</sup>. Sinziana *et al.*<sup>18</sup> reported 34.4% frequency of two canals at the floor of pulp chamber in central incisors in a Romanian population. This frequency was higher than that observed in this study. On the other hand, Benjamin & Dowson<sup>21</sup> and Perrini *et al.*<sup>29</sup> reported 4% and 1% frequency respectively of two canals at the floor of pulp chamber in lateral incisor. This was less than the frequency observed in this study.

The difference in number of canals at the floor of the pulp chamber between the current study and previous studies may be attributed to variation in technique of studying canals and racial differences. Sinziana *et al.*<sup>18</sup> and Benjamin & Dowson<sup>21</sup> used radiography in Romanian and U.S.A population respectively while Perrini *et al.*<sup>29</sup> used sectioning in an Italian population as opposed to staining and clearing technique among Kenyans of African descent in the current study.

### **Canal configuration in permanent mandibular central and lateral incisors**

Knowledge of canal configurations is very important in endodontic treatment of mandibular incisors. Complexity of canals in these teeth leading to difficulties in cleaning, shaping and

adequately filling the canals has been identified as one of the causes of unfavorable endodontic treatment outcomes.

Vertucci type I canal was the most prevalent in mandibular central and lateral incisors. Sinziana *et al.*<sup>18</sup> reported 65.6% frequency of type I canal in central incisors in a Romanian population while Boruah & Bhuyan<sup>23</sup> reported a 63.75% frequency of type I canal in a North East Indian population. The difference in distribution of canal types between the current study and previous studies may be attributed to racial variation and technique of studying canal morphology or a combination of these factors. Sinziana *et al.*<sup>18</sup> used radiography in a Romanian population as opposed to staining and clearing technique used in the current study. Boruah & Bhuyan<sup>23</sup> used clearing technique like in the current study but in an Indian population.

### **Lateral canals, apical deltas and intercanal anastomosis in permanent mandibular central and lateral incisors**

Lateral canals and apical deltas are a common feature in mandibular incisors<sup>5, 7, 15, 23, 24, 28, 29</sup>. Uncleaned and unobturated apical deltas and lateral canals are a possible cause of unfavorable endodontic treatment outcome. There can also be ingress of infected material from the periodontal ligament space through lateral canals to the main canal causing unfavorable outcome in root canal therapy. In the current study, lateral canals and apical deltas were observed in a few mandibular central and lateral incisors. Sinziana *et al.*<sup>18</sup> reported apical deltas in 9.3% and lateral canals in 12.5% of central incisors. Boruah & Bhuyan<sup>23</sup> reported 13% frequency of lateral canals in central and lateral incisors using clearing technique in a North East Indian population. In all the studies including the current one, lateral canals were found in the middle of the canals and apical deltas in the apical 1/3 of the root. The difference in occurrence of lateral canals and apical deltas between the current study and previous studies may be attributed



to racial variation or technique of study or a combination of these factors. Sinziana *et al.*<sup>18</sup> used radiography technique in a Romanian population while Boruah & Bhuyan<sup>23</sup> and Boruah *et al.*<sup>24</sup> used clearing technique like in the current study but in an Indian population as opposed to clearing technique in a Kenyan population in the current study.

### **Number and position of apical foramen in permanent mandibular central and lateral incisors**

Variation in position and number of apical foramen is mostly seen in teeth with two canals at the floor of the pulp chamber<sup>23</sup>. In the current study, 88.1% of the central incisors and 90.32% of the lateral incisors were found to have one apical foramina and apical foramina was found to coincide with the root tip in 69.05% of central incisors and 70.97% of lateral incisors. Boruah & Bhuyan<sup>23</sup> reported that 8.7% of teeth with two canals had two separate foramina while 91.3% of teeth with two canals had the canals merging into one before exiting through apical foramen. Apical foramen was found to coincide with the anatomical apex in 47.25% of teeth. The difference in number and position of apical foramen between the current and previous study may be attributed to racial differences.

## 4.1 CONCLUSIONS

All the mandibular central and lateral incisors had one root. Those with bilateral grooves were more than those with unilateral grooves. The difference in presence of grooves between central and lateral incisors was not statistically significant.

Majority of the central and lateral incisors had curved roots. Majority of the curvatures were in the distal direction, followed by mesial curvatures and the least were labial curvatures. Lingual curvatures were not observed. Difference in presence and positioning of curvatures between central and lateral incisors was not statistically significant.

The mean crown length was 8.45mm and 8.9mm in central and lateral incisors respectively. The mean root length was 12.38mm and 13.55mm in central and lateral incisors respectively. The lateral incisor was therefore longer than the central incisor.

Most of the central and lateral incisors had one canal at the floor of the pulp chamber and at the exit from the root. All the canals were conical in shape with the widest portion being on the coronal 1/3 of the root and thinning out into a taper towards the apex.

Vertucci type I canal was the most prevalent in all teeth, followed by Vertucci type II and the least prevalent was Vertucci type III. The difference observed in distribution of canal configuration between central and lateral incisors was not statistically significant.

Lateral canals and apical deltas were infrequently found in mandibular incisors. Intercanal anastomosis was not observed in any tooth.

Most teeth had one apical foramen, only a few had three apical foramina.

Apical foramina coincided with the root tip in majority, 83.3% and 80.6% of central and lateral incisors respectively.

## **4.2 RECOMMENDATIONS**

The mandibular incisor roots are frequently curved in the apical 1/3. The severity of root curvature is important in choosing instruments for chemo-mechanical preparation of the canals. Use of flexible files or pre-curving is advised. Further research is needed to measure and determine the degree of root curvatures for purposes of endodontic treatment planning and assessment of instrumentation costs.

In view of the complex anatomical pattern seen in this study, emphasis should be put towards searching for a second canal lingual to the usual single canal in mandibular incisors. Use of microscopes should be recommended for search of a second canal which is lingually placed. Also, the use of advanced three dimensional diagnostic techniques may provide accurate and non-invasive method for identification of essential anatomical features such as root curvatures, extra roots and unusual canal morphology which in turn will enhance clinical treatment outcomes in endodontic therapy and subsequent post crowns.

## REFERENCES

1. Ash M.M. Wheeler's Dental Anatomy, physiology and Occlusion, 6<sup>th</sup> edn. London, UK;Saunders Company, 1985; pp.196-208.
2. Ngassapa D., Hassanali J., Amwayi P., Guthua S. Essentials of Orofacial Anatomy. Dar es Salaam:Dar es Salaam University Press 1996 pp. 98-129.
3. Ingle J.I., Bakland L.K. Endodontics, 6<sup>th</sup> edn. Philadelphia: Lea & Febiger, 2002; pp.156.
4. Carrotte P. Morphology of the root canal system. British Dental Journal 2004; 197: 379-383.
5. Al-qudah A.A., Awawdeh L.A. Root canal morphology of mandibular incisors in a Jordanian population. International Endodontic Journal 2006; 39: 873-877.
6. Burns R.C., Buchanan L.S. Tooth Morphology and Access Openings. Part one: The Art of Endodontics in Pathway of the Pulp, 6<sup>th</sup> edn.pp. 156.
7. Boltacz, Rzepkowska E., Pawlicka H. Radiographic features and outcome of root canal treatment carried out in the Lods region of Poland. International Endodontic Journal 2003; 36: 27-32.
8. Giuseppe C., Elio B., Arnaldo C. Missed anatomy; Frequency and clinical impact. Endodontic Topics 2009; 15: 3-31.
9. Weine F.S. Access cavity preparation, an initiating treatment. In Weine F.S, Endodontics therapy, 5th edn. St Louis: Mosby; 1996.pp.243.
10. Zillich R.M., Jerome J.K. Endodontics access to maxillary incisors. Oral Surgery, Oral Medicine, Oral Pathology Journal 1981; 52: 443-445.

11. Mauger M.J., Waite R.M., Alexander J.B., Schindler W.G. Ideal access in mandibular incisors. *Journal of Endodontics* 1999; 25: 206-207.
12. Clements R.E., Gilboe D.B. Labial endodontic access opening for mandibular incisors. *Journal of Canadian Dental Association* 1991; 57: 587-589.
13. Berkovitz B.K., Holland G.R., Moxham B.J. *Oral Anatomy, Histology and Embrology*. Mosby Elsevier Science Limited 3<sup>rd</sup> edn. 2000; pp. 13-33.
14. Castelucci A., Becciani R., Bertelli E. Endodontic anatomy of the lower incisors. Radiographic studies and therapeutic approaches. *Minerva Stomatology Journal* 1988; 37: 159- 166.
15. Kartal N., Yonikoglu F.C. Root canal of mandibular incisors. *Journal of Endodontics* 1992; 18: 562-564.
16. Roshan P. Root and canal morphology of permanent teeth in a Srilankan and Japanese population. *Anthropological Science Journal* 2008; 116: 123-133.
17. Sert S., Bayirli G.S. Evaluation of the root canal configurations of the mandibular and maxillary permanent teeth by gender in the Turkish population. *Journal of Endodontics* 2004; 30: 391-8.
18. Sinziana S., Andreea C.D., Stefan L.S., Darian R., Mihaela G., Maria G., Andrei I. Root canal morphology of mandibular central incisors in a South- Eastern Romanian population. *Timisoara Medical Journal* 2010; 60: 280-283.
19. Vertucci F.J. Root canal anatomy of mandibular anterior teeth. *Journal of American Dental Association* 1974; 89: 369-371.
20. Vertucci F.J. Root canal anatomy of the human permanent teeth. *Oral Surgery, Oral Medicine, and Oral Pathology* 1984; 58: 589-99.

21. Benjamin K.A., Dowson J. Incidence of two roots in human mandibular incisor teeth. *Oral Surgery, Oral Medicine, Oral Pathology Journal* 1974; 38: 122-26.
22. Hess W., Zurcher E. The anatomy of root canals of the teeth of the permanent and deciduous dentitions. New York: William Wood & Co. 1925.
23. Boruah L.C., Bhuyan A.C. Morphologic characteristics of root canal of mandibular incisors in North- East Indian population: An invitro study. *Journal of Conservative Dentistry* 2011; 14: 346-350.
24. Boruah L.C., Lalit Chandra, Bhuyan A. C., Atool, Chandana. Root canal morphology of permanent mandibular incisors in a North-East Indian population –invitro study using root canal staining technique. *Endodontics Journal* 2010; 4: 273-277.
25. Lahdesmaki R., Alvesalo L. Root growth in the permanent teeth of 45, X/46, XX females. *European Journal of Orthodontics* 2006; 28: 339-344.
26. Lahdesmaki R., Alvesalo L. Root lengths in 47, XYY males' permanent teeth. *Journal of Dental Research* 2004; 83: 771-775.
27. Funato A., Funato H., Matsumoto K. Mandibular central incisor with two root canals. *Dental traumatology Journal* 1998; 14: 285-286.
28. Caliskan M.K., Yesim P., Figen S., Murat T., Saliya S.T. Root canal morphology of human permanent teeth in a Turkish population. *Journal of Endodontics* 1995; 21: 200-4.
29. Perrini N., Francini E., Perrini U. Morphological analysis of lower permanent incisor roots. *Journal of Italian Endodontics* 1991; 5: 32-35.
30. Walker R.T. The root canal anatomy of mandibular incisors in a Southern Chinese population. *International Endodontic Journal* 1988; 21: 218-223.

31. Bardelli M., Bruno E., Rossi G. Anatomy of lower incisor root canals. *Journal of Italian Endodontics* 1990; 4: 34-37.
32. Brescia N.J. *Applied Dental Anatomy*. St Louis: CV Mosby Co., 1961; pp. 46-8.
33. Pineda F., Kuttler Y. Mesiodistal and buccolingual roentgenographic investigation of 7275 root canals. *Oral Surgery, Oral Medicine, and Oral Pathology Journal* 1972; 33: 101-10.
34. Ezoddini F., Mohammed Z., Tabrizadeh M. Root canal morphology of human mandibular incisors in Yazd province. *Dental Research Journal* 2006; 1: 37-39.
35. Hilary O., Akpata E.S. Tooth lengths in Nigerians. *International Endodontic Journal* 1988; 19: 248-252.
36. Maina S.W., Wagaiyu C.K. The average tooth length in a black Kenyan population. *East Africa Medical Journal* 1990; 67: 33-38.
37. Uma Ch, Ramachandran S., Indira R., Shankar P. Canal and isthmus morphology in mandibular incisors – An in vitro study. *Journal of Endodontology* 2004; 16: 7-11.
38. Kabak Y.S., Abbott P.U. Endodontic treatment of mandibular incisors with two root canals; Report of two cases: *Australian Endodontic Journal* 2007; 33: 27-31.
39. Madiera M.C., Hetem S. Incidence of bifurcated canal in mandibular incisor. *Oral Surgery* 1973; 36: 589-91.
40. Wilson R., Henry P. The bifurcated canal in lower anterior teeth. *Journal of American Dental Association* 1965; 70: 1162-66.
41. Green D. Double canals in single roots. *Oral Surgery Journal* 1973; 35: 689-96.
42. Siquiera J.F., Jr. Aetiology of root canal treatment failure; why well treated teeth can fail (literature review). *International Endodontic Journal* 2001; 34: 1-10.

43. Slowey R.R. Root canal anatomy. Road map to successful endodontics. *Dental Clinics of North America* 1979; 23: 555-73.
44. Nair P.N. The causes of persistent apical periodontitis. *International Endodontic Journal* 2006; 39: 249-281.
45. Friedman S., Abitbol S., Lawrence H.P. Treatment outcome in endodontics: the Toronto study. Phase 1: Initial treatment. *Journal of Endodontology* 2003; 29: 787.
46. Friedman S., Mor C. The Success of endodontic therapy – healing and functionality. *Journal of California Dental Association*.2004; 32: 493-503.
47. Ashofteh Yazdi, A. Jafari. Internal Anatomy of Mandibular Incisors. *Journal of dentistry, Tehran University of Medical Sciences, Tehran, Iran* 2004; 4: 43-47.
48. Vertucci F.J, James E, Leandro R. Tooth morphology and access cavity preparation. In: Cohen S and Hargreaves K.M, *Pathways of the Pulp*, 9<sup>th</sup> edn. St Louis, MO, USA: Mosby Elsevier 2006; pp.148-232.
49. Gulabivala K., Alavi A., Aung T.H., Ng Y.L. Root and canal morphology of Burmese maxillary molars. *International Endodontic Journal* 2001a; 34: 620-630.
50. Gulabivala K., Alavi A., Aung T.H., Ng Y.L. Root and canal morphology of Burmese mandibular molars. *International Endodontic Journal* 2001b; 34: 359.
51. Weine F.S. Nonsurgical re-treatment of endodontic failures. *Compendium of Continuing Education in Dentistry* 1995; 16: 326-35.
52. Yi-Hsu Y, Kim S. The resected root surface. The issue of canal isthmuses. *Dental Clinics of North America* 1997; 41: 529-540.
53. *Surgical Endodontics in Harty's Endodontics in Clinical Practice-4th ed.* 1997 pp.179.



54. Morfis A., Sylaras SN., Georgopoulou M., Kernani M., Prountzos F. Study of apices of human permanent teeth with the use of a scanning electron microscope. *Oral Surgery, Oral Medicine, Oral Pathology Journal* 1994; 77: 172-176.
55. Robertson D., Leeb I.J., McKee M., Brewer E. A clearing technique for the study of root canal systems. *Journal of Endodontics* 1980; 6: 421-4.
56. Darforth R.A., Dus I., Mah J. Volume imaging for dentistry: A new dimension. *Journal of Californian Dental Association* 2003; 31: 817-21.
57. Scarfe W.C., Farman A.G., Sukovic P. Clinical application of Cone Beam Computed Tomography in dental practice. *Journal of Canadian Dental Association* 2006; 72: 75-80.
58. Taylor P., Todd M., David H., Scott S., Schindler W. Endodontic application of Cone Beam Volumetric Tomography. *Journal of Endodontics* 2007; 3: 1121-1132.
59. Pinsky H.M., Dydas S., Pinsky R.W. Accuracy of three dimensional measurements using Cone Beam Computer Tomography. *Dental Maxillofacial Radiology* 2006; 34: 410-416.
60. Vertucci F.J. Root canal morphology and its relationship to endodontic procedures. *Endodontic Topics* 2005; 10: 3-29.
61. Marcus T. The management of periapical lesions in endodontically treated teeth. *Australian Endodontic Journal* 2006; 32: 2-15.
62. Travassos R. M.C., Caldas, A.D.F., Albuquerque, D.S. Cohort study of endodontic therapy success. *Brazilian Dental Journal* 2003; 14: 109-113.
63. Betty K, Jonathan A.C.S. *Essential Medical Statistics*, 2<sup>nd</sup> edn. 2003; pp. 413-428.

## APPENDIX 1: DATA COLLECTION FORM

1. Tooth type
  - ❖ Central incisor
  - ❖ Lateral incisor
2. Number of roots
3. Root description
  - ❖ Central
  - ❖ Lateral
  - ❖ Other
4. Root status
  - ❖ Single
  - ❖ Bifid
5. Root length in millimetres
  - ❖ Crown length and total tooth length in millimetres
6. Root curvature
  - ❖ Root curved
  - ❖ Root not curved
7. Curved root-Direction of curvature
  - Position of curvature: Coronal 1/3, Middle 1/3 or Apical 1/3.
8. Internal morphology
  - I. Number of canals
  - II. Canal configuration
  - III. Number of lateral canals

IV. Apical deltas

❖ Present

❖ Absent

V. Number of apical deltas if present

VI. Intercanal anastomosis

❖ Present

❖ Absent

VII. Number of intercanal anastomosis

9. Position of apical foramen in relation to apex.

10. Number of apical foramina

## **APPENDIX 2: CONSENT FORM**

This is to certify that I -----, hereby agree to participate in this educational and research study on root and canal morphology of permanent mandibular central and lateral incisors by allowing the use of my extracted tooth.

This will be carried out by Dr. Gaichu Joyce Kathure, a postgraduate student pursuing a master's degree in prosthodontics at the University of Nairobi School of Dental Sciences P.O BOX 15-00202 Nairobi. The consent to carry out this study has been given by the UoN and KNH Standards, Ethics and Research Committee.

### **Perceived benefits**

I understand that my tooth will not be used for any other purposes other than this study.

I understand that this study will benefit me and other patients who will seek endodontic treatment following publication of the research results.

I understand that the results obtained will provide baseline information for teaching purposes and for use by dentists during endodontic and fixed prosthodontic treatment.

I understand that the results obtained will be beneficial in future research carried out in these teeth.

### **Risks**

There are no anticipated risks for participating in the study.

### **Costs and payments**

I understand this study is strictly voluntary and no monetary compensation will be given.

### **Confidentiality**

I understand that all personal information is not required in the study and whatever is learned will be kept strictly confidential.

**Withdrawal privilege**

I understand that I may refuse the use of my tooth for the study and if I do this, I will not be reprimanded or denied health care at the UoN Dental Hospital, KNH, Mbagathi District Hospital, Mathari District Hospital or any other public or private hospital.

**Voluntary consent**

I certify that I have read all this consent form or it has been read to me and that I understand it. Any questions pertaining the research have been answered to my satisfaction. My signature below means I freely agree to participate in this study.

Signature of participant -----, Date -----.

**Investigator statement**

I certify that I have explained to the above named individual the nature and purpose of this study; potential benefits and I have answered all questions that have been raised. I have explained the above to the participant on the date on this consent form.

Investigators signature -----, Date -----.

## APPENDIX 3: APPROVAL LETTER



UNIVERSITY OF NAIROBI  
COLLEGE OF HEALTH SCIENCES  
P O BOX 19676 Code 00202  
Telegrams: varsity  
(254-020) 2726300 Ext 44355  
Ref: KNH-ERC/A/356



KENYATTA NATIONAL HOSPITAL  
P O BOX 20723 Code 00202  
Tel: 726300-9  
Fax: 725272  
Telegrams: MEDSUP, Nairobi  
19<sup>th</sup> December 2012

KNH/UoN-ERC  
Email: [uonknh\\_erc@uonbi.ac.ke](mailto:uonknh_erc@uonbi.ac.ke)  
Website: [www.uonbi.ac.ke](http://www.uonbi.ac.ke)  
Link: [www.uonbi.ac.ke/activities/KNHUoN](http://www.uonbi.ac.ke/activities/KNHUoN)

Dr. Gaichu J.K.  
Dept. of Conservative and Prosthetic Dentistry  
School of Dental Sciences  
University of Nairobi

Dear Dr. Gaichu

**RESEARCH PROPOSAL: ROOT AND CANAL MORPHOLOGY OF PERMANENT MANDIBULAR INCISORS IN A KENYAN POPULATION ((P539/10/2012))**

This is to inform you that the KNH/UoN-Ethics & Research Committee (KNH/UoN-ERC) has reviewed and **approved** your above revised proposal. The approval periods are 19<sup>th</sup> December 2012 to 18<sup>th</sup> December 2013.

This approval is subject to compliance with the following requirements:

- a) Only approved documents (informed consents, study instruments, advertising materials etc) will be used.
- b) All changes (amendments, deviations, violations etc) are submitted for review and approval by KNH/UoN ERC before implementation.
- c) Death and life threatening problems and severe adverse events (SAEs) or unexpected adverse events whether related or unrelated to the study must be reported to the KNH/UoN ERC within 72 hours of notification.
- d) Any changes, anticipated or otherwise that may increase the risks or affect safety or welfare of study participants and others or affect the integrity of the research must be reported to KNH/UoN ERC within 72 hours.
- e) Submission of a request for renewal of approval at least 60 days prior to expiry of the approval period. (*Attach a comprehensive progress report to support the renewal*).
- f) Clearance for export of biological specimens must be obtained from KNH/UoN-Ethics & Research Committee for each batch of shipment.
- g) Submission of an *executive summary* report within 90 days upon completion of the study  
This information will form part of the data base that will be consulted in future when processing related research studies so as to minimize chances of study duplication and/or plagiarism.

For more details consult the KNH/UoN ERC website [www.uonbi.ac.ke/activities/KNHUoN](http://www.uonbi.ac.ke/activities/KNHUoN)

**APPENDIX 4: DIAGRAMMATIC CANAL CONFIGURATION AS PER VERTUCCI (1984) CLASSIFICATION**



Type I



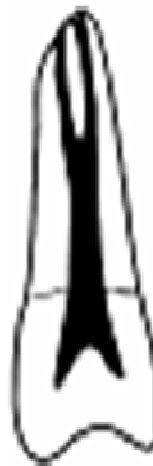Type II



Type III



Type IV



Type V



Type VI



Type VII



Type VIII

Canal configurations as per Vertucci(1984) classification are described below:

**Type I:** A single canal present from the pulp chamber to the apex.

**Type II:** Two separate canals leave the pulp chamber, but join to form one canal at the site of exit.

**Type III:** One canal leaves the pulp chamber, divides into two within the root, and then merges to exit as one.

**Type IV:** Two separate and distinct canals are present from the pulp chamber to the apex.

**Type V:** Single canal leaving the pulp chamber but dividing into two separate canals with two separate apical foramina.

**Type VI:** Two separate canals leaving the pulp chamber but join at midpoint and divides again into two separate canals with two separate apical foramina.

**Type VII:** One canal leaving the pulp chamber divides into two within the root and then merges at midpoint and divides again into two separate canals with two separate apical foramina.

**Type VIII:** Three distinct canals from the pulp chamber to the apex.