

THESIS

**Anatomic variations of paranasal sinuses in patients undergoing CT scan
evaluation at the Kenyatta National Hospital**

PRINCIPAL INVESTIGATOR

DR. FUAD FARAH MAALIM

H58/71002/2009

MASTERS IN MEDICINE IN ENT HEAD AND NECK SURGERY

**A THESIS FOR DESERTATIONAS PARTIAL FULFILLMENT OF THE
REQUIREMENTS BY THE UNIVERSITY OF NAIROBI FOR THE AWARD OF
THE DEGREE OF MASTERS IN MEDICINE IN ENT HEAD AND NECK
SURGERY.**

DECLARATION

This is my original work which has not been presented for a degree award at any other university.

Signed _____ Date _____.

Dr Fuad Farah.

This thesis is supervised by:

Prof. H.O Oburra

Professor

Department of Surgery. ENT Head and Neck Surgery.

University of Nairobi.

Signed _____ Date _____.

Dr Jane Thinwa.

Consultant.

Department of Radiology. Kenyatta National Hospital.

Signed _____ Date _____.

Dr John Ayugi.

Lecturer and consultant.

Department of Surgery. ENT Head and Neck Surgery

University of Nairobi.

Signed _____ Date _____.

1.0 ACRONYMS AND ABBREVIATIONS:

CT Scan : Computed Tomographic Scan.

ENT HN: Ear, Nose, Throat, Head and Neck Surgery.

FESS : Functional Endoscopic Sinus Surgery.

KNH : Kenyatta National hospital.

PNS : Paranasal sinus.

2.0 ABSTRACT

Objective: To determine radiologic variants of paranasal air sinuses among patients undergoing CT scan evaluation at KNH. To determine demographic characteristics of patients requiring paranasal CT scanning at KNH.

Study Design: Prospective cross sectional study

Methods: This is a prospective cross sectional study that was conducted at the Department of Radiology in Kenyatta National Hospital comprising of 100 patients' computed tomography scans of paranasal sinuses. The machine that was used is Phillips Brilliance CT scanner, 16 slice. Model 45356702331, serial number 729. CT scans were taken in axial plane and then three millimeter slices reconfigured into coronal and sagittal planes. Anatomical variants assessed are agger nasi, haller cells, onodi cells, concha bullosa, and deviated nasal septum. Other uncommon variants were also detected.

Study duration: From October 2013 and completion will be in October 2014.

Data Management and Analysis: The data collected was transferred into Microsoft Access database and then analyzed using STATA version 13 (Stata Corp, College Station, Texas) statistical software. Descriptive analysis was used to determine the means, frequencies and proportions of the various anatomical variations. The proportions of the various anatomical variations further have the 95% CI. Results are presented in the form of tables and graphs together with their descriptions.

Results: Sample size of 100 patients, 56 females and 44 males. Of the common variants, 91(91%) patients have agger nasi cells, 13(13%) patients have haller cells, 44(44%) patients have concha bullosa, 41(41%) patients have onodi cells while 16(16%) have septal nasal deviation.

Of the uncommon variants, maxillary sinus hypoplasia was identified in 1(1%) patient.

Superior concha bullosa was identified in 4(4%) patients. Inferior concha bullosa was identified in 1(1%) patient. Bilateral paradoxical middle turbinate was present in 5(5%) patients.

Paradoxical superior turbinate was present in the right in 1(1%) patient. Septate sphenoid was present in 14(14%) patients.

Keros type 1 in 25(25%) patients; keros type 2 in 67(67%) patients, keros type 3 in 7(7%) patients and keros type 4 in 1(1%) patient.

Conclusion: anatomical variations are best viewed and appreciated in the coronal plane. The Keros classification of olfactory fossa depth is best calculated in coronal plane. Both sagittal and axial planes don't give adequate information with regards to the anatomy of paranasal sinuses and the presence of anatomical variations.

Gender had significant correlation (Pearson chi-square p-value=0.043) with Onodi cell, which implied that the variant was mainly dominant on males as compared to females.

3.0 INTRODUCTION

Evaluation of anatomic variations of the paranasal air sinuses is important in patients who are undergoing CT scan evaluation for various rhinologic reasons. Knowledge of the anatomic variations does reduce the surgical complication rates during FESS, helps explain recurrence of disease and allows one to change the operative technique.

The ethmoid air sinuses play a crucial role in FESS. The posterior ethmoids and the sphenoid sinuses can be accessed via the anterior ethmoid cells. Anterior ethmoidectomy helps improve frontal air sinus drainage hence minimizing the need for opening the frontal sinus during surgery.

The anatomic variations of paranasal sinus make the approach to FESS much more complex.¹ Some anatomic variants are probably not responsible for development of chronic rhinosinusitis, but knowledge of their presence is paramount. Variations in the pneumatization

of ethmoid sinuses may disturb sinus ventilation.^{2,3} These can be the etiological factor for sinusitis and spread of infection to adjacent structures.

During FESS, straying beyond the surgical field may lead to serious complications such as cerebrospinal fluid leak, meningitis, or blindness, so a detailed knowledge of the possible anatomical variations is essential.

Computer Tomography scan is a mandatory radiological investigation for patients undergoing FESS. CT scan helps identify these anatomic variations. Many centers use the three millimeter cuts for all views – coronal, sagittal and axial to assess the different anatomical structures of the lateral nasal wall and the paranasal sinuses. The coronal views are best for the sphenoid and the ethmoid cell variants such as the onodi or sphenoidal cell.⁴

The development and refinement of CT scans has allowed extensive assessment of patients' paranasal sinuses thus providing a guide map for FESS surgeons to operate.⁵

4.0 BACKGROUND

4.1 ANATOMY

Understanding the embryology and gross anatomy of the paranasal sinuses is of paramount importance in the surgical aspect due to its close proximity to vital structures such as the orbit and optic nerve.

Embryology

The frontal, maxillary and ethmoid sinuses arise from evaginations of the lateral nasal wall, whereas the sphenoid sinuses arise from a posterior evagination of the nasal capsule.

Embryological development of ethmoid sinus begins during the fifth month of intrauterine life as numerous evaginations from the fetal nasal chamber into the anlage of the ethmoid bone. At first these evaginations are mere slits, but they quickly grow into a tubular form before assuming a round or globular shape at term. The expansion of each air cell with rapid growth of the cells is at the expense of the ethmoid bone. The haphazard growth of cells makes each person's

ethmoid labyrinth different from the next. The expansion of these cells continues until late puberty or until the wall of the sinus strikes a layer of compact bone or another sinus. By adulthood, the ethmoid block averages 3.3 by 2.7 by 1.4 cm in size, with the longest dimension being the anteroposterior. The ethmoids complete pneumatization by the age of twelve years.

Frontal sinuses are either absent or insignificant at birth, but gradually increase in size and reach maximum dimension at around age twenty years.⁶ Further pneumatization due to atrophic changes may occur in old age.⁷ Structural changes can only be caused by alteration due to tumours, fractures or severe infections.⁸ The two develop independently hence often asymmetry.

Maxillary sinus development begins at tenth week gestation as some mucosal invagination of primitive ethmoid infundibulum. Shaping of maxillary sinus starts by fusion of multiple invaginations into a single cavity from week eleven. Growth is progressive in all dimensions more so anteroposteriorly, similar to the cranial elongation.⁹ It undergoes two periods of rapid growth, between birth and age of three years, also between ages seven and eighteen years. A poorly developed infundibular passage is associated with hypoplasia.¹⁰

Sphenoid sinus develops from evagination of sphenoid recess at birth. Pneumatization begins age three and reaches sellar by age seven and proceeds rapidly after. Development continues until age twelve to fifteen years.

Gross Anatomy:

The ethmoid bone is a light, papyraceous, osseous structure attached to each edge of the cribriform plate as a block of ethmoid sinuses. Each block is made of a group of three to fifteen air cells. The ethmoidal cell block or labyrinth is pyramidal in shape, being wider posteriorly (where it abuts the sphenoid bone) than anteriorly (where it contacts the lacrimal bone). The ostia of the ethmoidal sinuses are the smallest found in any of the paranasal sinuses, measuring one to two millimeters in diameter. To understand the anatomic relations of the ethmoid labyrinth its best to consider it as a box. The roof of the box is the top wall or roof of the ethmoidal air cell box and is termed the fovea ethmoidalis. The fovea is not a flat plate of bone but undulating, because the domes of the topmost ethmoidal cells bulge into it and mold it into such a contour. The anterior part of the fovea lies more superior to the posterior part, since the anterior cranial fossa descends approximately fifteen degrees from a horizontal plane as it

passes posteriorly. The lateral wall of the box is the lamina papyracea. It is a flat, smooth, rectangular plate of bone articulating with the frontal bone superiorly, the lacrimal bone anteriorly, the maxilla inferiorly and the lesser wing of the sphenoid bone posteriorly.

Along the frontoethmoidal articulation lie two foramina, the anterior and posterior ethmoidal foramina. Through these pass branches of the ophthalmic artery and trigeminal nerve to supply blood and sensation to the mucosa of the ethmoidal air cells.

The anterior side of the ethmoidal box abuts the lacrimal bone, the smallest of the facial bones. The importance of lacrimal bone is that it is frequently pneumatized with the group of anterior ethmoidal cells termed *agger nasi*. The posterior part of the ethmoidal box is formed by the back walls of the posterior ethmoidal cells. Because a large ethmoidal cell often abuts the sphenoidal sinus, these cells frequently share a common osseous wall. The inferior and medial walls of the ethmoidal box must be considered together, for they comprise almost a single slightly convex curved plane bowing into the nasal chamber. Thus, the ethmoidal sinuses do not lie directly atop the maxilla but touch the latter only at the upper medial part of the maxillary sinus.

Projecting into the nasal chamber from the medial wall of the ethmoidal block are the turbinates. The support of these structures is a partition of bone – the basal lamella – that continues from the base of the turbinate and traverses laterally through the mass of ethmoidal cells to attach to the medial side of the lamina papyracea. The inferior, middle and superior turbinate lamellae internally divide the intramural ethmoidal cells into anterior, posterior and postreme groups. The lamella in each case is not a straight divide because the developing air cells push and distort what was its original linear position in the fetal ethmoid bone. In general, the cells of the anterior ethmoidal group are more numerous (two to eight) but smaller, whereas those of the posterior group are larger but fewer in numbers (one to seven).

The sphenoid sinus is located in the sphenoid bone and may differ in size and shape depending with individuals. One or more vertical septa divide the sinus and the septa are rarely in midline.¹¹ The degree of pneumatization of the sphenoid sinus may vary considerably. The sphenoid sinus can be described as conchal, presellar and sellar.

Radiological anatomy:

CT scan is the investigation of choice for paranasal sinuses. Modern multi slice CT scanner allow thin axial plane slices to be obtained, from which reconstruction to sagittal and coronal planes can be made. The coronal plane best displays the osteomeatal complex. The axial plane helps identify the basal lamella of middle turbinate which is the dividing point of anterior and posterior ethmoid sinuses.⁴

Ethmoid air sinuses are the most developed paranasal sinus at birth but are not evident on X-ray until the age of 1 year. Anatomical boundaries of anterior ethmoid cells are: anteriorly, the ethmoid infundibulum; posteriorly, the basal lamella; laterally, the lamina papyracea; superiorly, the skull base. Anatomical boundaries of posterior ethmoid cells are: anteriorly, the basal lamella; posteriorly, the anterior sphenoid wall; medially, the superior turbinate; laterally, the lamina papyracea; superiorly, the skull base.⁴

Agger nasi is the most anterior ethmoidal air cells. It forms the anterior inferior border of frontal recess. Its degree of pneumatization has significant effect on frontal sinus drainage and surgical access. Frontal recess may be displaced medially and posteriorly, depending on the size of agger nasi cell. Onodi cell is assessed by comparing both coronal and sagittal cuts carefully. They pneumatize superolateral to the sphenoid sinus: hence surgical clearance should be in the inferomedial direction, due to optic nerve and internal carotid relations.

Sphenoid sinus' most reliable landmark is the ostium which lies approx 1cm superior to the posterior inferior end of superior turbinate and approx 1.5cm superior to the choana. CT scan evaluation focuses on pneumatization and the relation to both internal carotid artery and optic nerve.

The boundaries of the frontal sinus tract/ recess are: anteriorly, the agger nasi cell; posteriorly, the ethmoid bulla and skull base; laterally, the lamina papyracea and medially, the middle turbinate.

Anatomic Variants:

Concha bullosa: – it is pneumatization of the concha. The middle concha is the most commonly involved. Bolger et al classified concha bullosa pneumatization as per the location into lamellar, bulbous and extensive. The extensive type is the combination of both the lamellar and bulbous type. Pneumatization of the middle concha is the extension of normal pneumatization of the ethmoid cells.¹² This is usually by the anterior ethmoid cells but the posterior ethmoid cells have also been documented or by both groups. Concha bullosa is implicated in the pathogenesis of rhinosinusitis because of its tendency to narrow the middle meatus and the infundibulum. Some studies have found the prevalence of concha bullosa to be the same in patients with and without sinus disease symptoms.¹

Superior Concha bullosa: - pneumatization of superior turbinate is extremely rare condition.

Inferior concha bullosa: - pneumatization of the inferior turbinate as well is very rare.¹³

Keros classification: the length of the lateral lamella of the cribriform plate, defining the type of olfactory fossa. In most of the cases, the cribriform plate is symmetrical; however, an asymmetric skull base is an anatomic variant.⁴⁴

Type I: cribriform plate 1-3 mm below fovea ethmoidalis.

Type II: 4-7 mm below.

Type III: 8-16 mm below.

Nasal septal deviation: - asymmetric nasal septum position which can put force on nasal turbinates.

Haller cells: – pneumatization of ethmoid cells extends into anterior roof of maxillary sinus, along the floor of the orbit. They are an etiological factor for sinusitis since they vary in size and when large can narrow the ostium of the maxillary sinus or the ethmoid infundibulum. The presence of an infraorbital cell may increase the risk of injury to the orbit during FESS, an unrecognized cell masking the position of the orbital wall.¹⁴

Bolger et al defined a haller cell as any cell located beneath ethmoid bulla, lamina papyracea or orbital floor.¹

Agger nasi cells: – most anterior ethmoid air cell located below the frontal sinus and are intimately related to the frontonasal recess, reaching the lacrimal fossa inferolaterally. They are anterosuperior to the hiatus semilunaris. The agger nasi cell may form a significant part of the anterior wall of the frontal recess and impinge upon the frontal sinus drainage tract. Recognition of this relationship is crucial in management of chronic frontal sinusitis.¹⁵

Onodi cells: – posterior ethmoid cells that extend posterior, lateral and always superior to sphenoid sinus, lying medial to the optic nerve. First described by Adolf Onodi in 1903. Extensive pneumatization can expose the circumference of optic nerve, which is surrounded by air spaces, mainly the inferior half.¹⁶ Onodi cells are also known as sphenoid cells and are important to the surgeon in FESS. When present, both optic nerve and carotid artery may be exposed in the posterior ethmoid cell.¹⁷ The best orientation is on axial cuts where the course of optic nerve can be followed as a relation.¹⁸

Uncinate bulla:- pneumatization of the uncinat process and is a rare entity. Uncinate process projects from the ethmoid bone to the ethmoid process of the inferior nasal concha. Pneumatization can result in narrowing of infundibulum and sinus drainage occlusion.²⁰

Maxillary sinus hypoplasia:- uncommon condition that is misdiagnosed as chronic sinusitis.¹⁹ In its severe form, it impedes mucociliary clearance and is liable to retention of mucus. Failure to recognize maxillary sinus hypoplasia intraoperation can lead to injury to the medial orbital wall.²⁰ Finding the maxillary sinus ostium may be difficult.²¹

Classification of maxillary sinus hypoplasia:

Type 1. Mild sinus hypoplasia:

- Normally developed uncinat process.
- Well-developed infundibular passage.
- Varying degree of mucosal thickening of affected sinus.

Type 2. Significant sinus hypoplasia:

- Hypoplastic or absent uncinat process.
- Ill-defined or absent infundibular passage.
- Total opacification of affected sinus.

Type 3. Profound sinus hypoplasia:

- Sinus represented by shallow cleft in the lateral nasal wall of the nose.
- Absent uncinat process.

Sphenoid sinus hypoplasia:- defined as an oval-shaped sinus with pneumatization limited to the presphenoid that is anterior to the vertical plane of the tuberculum sellar. It is an uncommon

condition. Few cases of agenesis have been reported.²²Mainly seen in patients with craniofacial anomalies and skeletal diseases.²³

Sphenoid sinus pneumatization:-can be divided into conchal, presellar or postsellar. Conchal: the area below the sellar is a solid block of bone without pneumatization. Presellar: the sphenoid is pneumatized to the level of the frontal plane of the sellar and not beyond. Sellar: the most common type, where pneumatization extends into the body of the sphenoid beyond the floor of sellar and reaches clivus.

Frontal sinus hypoplasia:-it is uncommon to find one dominant, one hypoplastic or both hypoplastic frontal sinus. Rarely both aplastic frontal sinuses.²⁴

5.0 LITERATURE REVIEW

Paranasal sinus anatomy is variable from individual to individual and so is the incidence of the anatomical variations. Different studies around the globe demonstrate different percentages for the anatomic variations. As for CT scan, it being the imaging modality of choice, most authors use three millimeter coronal plane cuts as it gives similarity with surgical orientation. Axial plane cuts are used for a clearer, exact diagnosis when coronal plane is not clear.

Stammerger and Hawke have shown that CT scan of PNS provides an anatomic road map to identify presence of abnormalities, the location and severity of disease and exact location of obstruction.¹⁹CT scan in a coronal plane is more informative than on an axial plane as indicated by Perez P et al. This shows anatomical structures progressively as a surgeon's visualization and the relationships of sinus cavities and adjacent structures. Axial cuts are also imperative, since they give anatomical relations of the paranasal sinuses.²⁵Perez had a sample size of one hundred patients of whom nearly all had agger nasi cells while 73% had concha bullosa and 3% had haller cells.

Removal of disease in the osteomeatal complex region is the basic principle of FESS, which is best appreciated on CT scan as documented by Dua et al²⁶whose sample size was fifty patients. Fourty percent had agger nasi cell while both haller cells and concha bullosa had 16% each. Mamatha H did re-emphasize the concept that osteomeatal complex is the key factor in the causation of chronic sinusitis.This study also gave justification as to why the coronal plane is preferred, since it displays the osteomeatal complex best.²⁷Mamatha had a sample size of forty patients and nearly half of them had agger nasi cells while 17.5% had haller cells and 15% had concha bullosa. In a study by Hatipoglu, he looks at the statistical relationship between concha bullosa type and osteomeatal disease, hence concluded that pneumatization of the inferior part of the middle concha plays a major role in osteomeatal disease development.²⁸

A comparison of anatomic variants in patients with sinus disease and patients without was made by Kayalioglu. Clearly anatomical variants were common in patients with sinus disease.²⁹His sample size was ninety sinus patients and eighty two non sinus patients. Concha bullosa which was close was seen 28.8% in sinus patients and 26.8% in non sinus patients. Basic who did a CT scan study to determine frequency of anatomic variations in mainly

ethmoid pneumatization and did indicate it is imperative to adopt standardized classification and definition of paranasal sinus variations. This would avoid discrepancies amongst various authors.³⁰ A study by Arslan H et al had a large sample size of two hundred patients and looked into anatomical variants of the paranasal sinus on two millimeter CT scan cuts where he found that 30% had concha bullosa while onodi cells at 12% and haller cells were 6%.¹⁴

A comparison of prevalence of anatomic variation on CT scan and clinical findings was made by Lerdlum, who observed that anatomic variation can compromise mucociliary drainage. However, only large agger nasi had significant correlation to inflammatory sinus disease.³¹ A study on agger nasi cell, the key to understanding anatomy of the frontal recess was done by Wormald The anatomy and variations in the area are poorly understood by FESS surgeons. Reconstructed CT scan cuts of PNS, mainly coronal and sagittal aid in identification of each cell and assist the surgeon to formulate a clear, precise surgical plan.³²

Onodi cell is an obstacle to sellar lesions with a transphenoidal surgical approach. Sinusitis in the sphenoid region can present with visual symptoms due to its close relations to the optic nerve. Intraoperatively, the Onodi cell can be easily mistaken for sphenoid sinus, hence incomplete procedures sometimes. Risk of injury to both the optic nerve and internal carotid artery are high as seen in the study by Ji-hyeon Shin.¹⁷ A CT scan study done on patients requiring revision FESS by Bradley et al found agger nasi cell present in 93%, mainly the patients with frontal rhinosinusitis. Frontal sinus disease correlates with severity of overall sinus disease.³³

A comparison study of anatomic variations of lateral nasal wall of patients undergoing FESS was done by Badia L et al . Caucasians and Chinese were compared. Concha bullosa incidence was higher in the Caucasian population, though incidence of Onodi cells was much greater in Chinese population. There was no difference in presence of agger nasi cells.³⁴ A study on anatomic variations of lateral nasal wall in Thai patients undergoing FESS was done by Nitinavakarn B et al and the most common site of sinus infection and inflammation was the anterior ethmoid sinuses. Thai FESS surgeons should be informed about the variants, which might be different if compared to western incidence.³⁵ Vincent T et al did a study on association of concha bullosa and deviated nasal septum with chronic rhinosinusitis in FESS patients. The two anatomic variants and agger nasi are very common. In Malaysia, concha bullosa was statistically more common among females and the Indian and Chinese ethnic groups.³⁶ A study

done by Baradaranfar et al looked into the frequency of anatomical variations in patients with chronic rhinosinusitis who underwent sinus surgery. A total of 120 patients and he found agger nasi in 36%, concha bullosa in 12.5%, septal deviation in 45% and haller cells in 4%.³⁷

Maxillary sinus hypoplasia has been reported as being very uncommon and mainly noticed on the coronal cuts of the CT scan. Bolger et al reported prevalence of unilateral hypoplastic maxillary sinus to be 10.4% while Kantarci et al reported 7% in a study of 512 patients.³⁸ It is imperative to look for other anomalies on the lateral nasal wall, especially the uncinata process which can impede mucociliary clearance of the sinuses. Secondary middle turbinate is rare anomaly characterized by a bony projection covered by soft tissue, arising from the lateral wall of the middle meatus, studies done by Khanobthamchai et al put the incidence at 1.5%,³⁹ while Aykut et al found it to be 6.8%⁴⁰ and Aksungur et al at 0.8%.⁴¹

A retrospective study on sphenoid sinus hyperplasia and agenesis was done by Binal C et al who looked into 384 patients and found unilateral agenesis in 0.26%, unilateral sphenoid sinus hypoplasia in 0.26% and bilateral sphenoid sinus hypoplasia in 0.26%. Bilateral sphenoid sinus agenesis was not seen.⁴²

6.0 STUDY JUSTIFICATION

This study offers local statistics on paranasal sinus anatomy and its variants. It acts as a baseline research for anyone who wishes to carry further studies on particular paranasal sinuses. This data will help the otorhinolaryngologist to build a complication free learning curve, assist in local training and also emphasize on the need for radiological evaluation. This study helps in standardization of the cuts size and view to request for in terms of paranasal sinus CT scans. Clear information on trends of variation among the local population can be obtained in the

study. Paranasal air sinuses are important in FESS and knowledge of its anatomical variants helps a surgeon in his/ her orientation during FESS.

7.0 AIMS AND OBJECTIVES

To determine the incidence of paranasal air sinus variations in patients undergoing CT scan evaluation at Kenyatta National Hospital.

Specific Objectives

1. To determine demographic characteristics of patients requiring paranasal CT scanning at KNH.
2. To determine radiologic variants of paranasal air sinuses among patients undergoing CT scan evaluation at KNH.

8.0 STUDY DESIGN

Prospective cross sectional study.

8.1 Sample size

We want to estimate the proportion of population with anatomic variations of paranasal sinuses in patients undergoing CT scan evaluation

The incidence of paranasal air sinus variations in patients undergoing CT scan is varying for the different parameters of our interest i.e. Agger nasi cells (50%), Haller cells (17.5%) and

Concha bullosa (15%) and further there are no documentation/ publication in Africa/ Kenya – the proportion of anatomic variations

For the cross sectional study and since we do not know the estimated population proportion or prevalence we use $p=0.05$

We use a margin of error of 10% to allow us estimate the sample size that fits our estimated resources

Based on the 95% confidence interval, a precision (margin of error) $d = \pm 10\%$ and that the estimated population prevalence proportion is unknown we use $p=0.50$

Significance level $\alpha = 0.05$ implying $Z_{1-\alpha} = 1.96$ i.e. 95 % confidence level

The following Sample size determination formula for incidence studies (Lwanga SK & Lameshow S)⁴³ was used to estimate the proportion of population study size.

$$n = \frac{[Z_{1-\alpha}^2]^2 p(1-p)}{d^2}$$

$$n = \frac{[1.96]^2 \times 0.50 \times (0.50)}{0.1^2} = 96$$

The estimated sample size of 96 will be expanded to 106 to allow for 10% possible non respondent / missing data.

8.2 Sampling method

Consecutive sampling

8.3 Study setting

Kenyatta National Hospital, Department of Radiology

8.4 Study Period

October, 2013 –November, 2014.

8.5 Inclusion Criteria

Patients above fifteen years age. Paranasal sinuses are developed.

Patients who consent to be included in the study.

CT scans of three millimeter cuts.

8.6 Exclusion Criteria

Patients with history of previous nasal surgery or trauma.

Patients who do not consent to be included in the study.

Patients below the age of fifteen years.

8.7 Confounding Factors

Presence of nasal polyposis may hinder visualization of some of the anatomic variations of ethmoid sinuses.

8.8 Clinical Evaluation

CT scans of the paranasal sinuses were taken in axial position. 3mm reconstruction cuts to sagittal and coronal view were made of patients in the study.

8.9 Data Management and Analysis

Data Management

The collected data in the questionnaires was entered into Microsoft office access 2007 database and then transferred to STATA version 13 (Stata Corp, College Station, Texas) for cleaning, validation, coding and analysis. It was checked for any wrong entry and double entry and corrected. Back up was created in an external hard disk in case of damage and/or loss of original data and then password protected. All data was stored under lock and key and with password protected files under the custody of the principal investigator to prevent any illicit access to the data. Use of coded data was done to ensure maximum confidentiality. At the end of the study, the raw data was stored in one soft copy storage device.

Data Analysis

Data analysis was done using the STATA version 13 (Stata Corp, College Station, Texas) statistical software. Descriptive analysis was used to determine the mean, frequency and proportion of variables describing variations. 95% Confidence Interval for the proportions was

presented. Results was presented as table and graphs together with brief descriptions. Confidence level was taken as 95% ($p < 0.05$) where applicable.

9.0 MATERIALS AND EQUIPMENT

Materials and equipment that was used include:-

1. Phillips Brilliance CT scanner, 16 slice. Model 45356702331, serial number 729. Manufactured by Phillips Medical Systems, Cleveland USA in 2007.
2. Compact Disks for storing soft copy of the patient's paranasal CT scans.

Procedure

The study was mainly based at the department of radiology in Kenyatta National Hospital. It is an outpatient setting and patients come for the procedure which does not take a long time. It takes half an hour to do CT scanning. After the procedure, it takes time for the radiologist to review and report on the various findings on the CT scan, hence patients are requested to either wait or come back for the CT scan films and report on the following day. No extra time of the patients was required to conduct this study.

The targeted patients in this study were the ones who were requested to undergo paranasal sinus CT scan for various rhinologic reasons mainly from different clinics in Kenyatta National

Hospital. Hence patient recruitment was at the Radiology Department in Kenyatta National Hospital. The principal investigator had to explain to the patients the study in order for them to agree to consent to be included in the study. Patients incur the cost of doing the paranasal CT scan, but no extra cost was incurred by the patients in regard to this particular study. Patients were expected to give a short bio data on their ages and home. This took place prior to the patient undergoing the CT scanning.

The CT scan machine at Kenyatta National Hospital takes axial cuts initially in order to save hospital time for patients and also be able to have a high turnover with regards to the workload. The reconfiguration into both coronal and sagittal planes was done to the specified three millimeter cuts by the machine. The machine is capable of producing whichever requested information in terms of size and planes. The radiologist took time to look at the scans in different views and cuts in order to diagnose and report on the pathology and disease process that is deduced from the images. The films produced eventually give a picture that helps best to display the pathological findings.

After the CT scanning, the primary investigator accessed the films with the radiologist supervisor and filled in the anatomical variants visualized on a check list with regards to the plane and side, whether left or right or bilateral. The information and data was stored at the radiology department. The primary investigator stored a soft copy of all the CT scan films of the patients recruited in the study and that extra cost was not incurred neither by the patients nor the Department of Radiology. The data collected from this study will be used by the Departments of Radiology and Ear, Nose and Throat Surgery in conjunction with Kenyatta National Hospital as a benchmark and reference for other related studies in the future.

Quality Control

1. The primary investigator did the enlisting of patients undergoing CT scan evaluation.
2. The primary investigator with one supervisor radiologist reviewed the scans and the variations noted down in the check list.
3. The CT scans was standardized in size (3mm cuts) and all views requested.

10.0 ETHICAL CONSIDERATION

1. The study was carried out only after approval by Kenyatta National Hospital and University of Nairobi Ethics and Research committees.
2. Those included in the study were required to give an informed consent either by themselves or guardians in cases below 18 years.
3. Patients incurred no extra financial costs and their confidentiality was maintained.
4. There was no monetary gain by the primary investigator from this study.
5. There was no penalty for declining to participate in the study.
6. The study results shall be published in reputable journals and periodical publications for the benefit of the medical fraternity, the study subjects and general population.

11.0 IMPLEMENTATION TIMETABLE

OCT 2013 – JANUARY 2014	PROPOSAL WRITING
MAY2014	PRESENTATION AND ETHICAL APPROVAL
JULY 2014 – SEPTEMBER 2014	DATA COLLECTION
OCTOBER 2014	DATA ANALYSIS
OCTOBER 2014	PRESENTATION OF RESULTS

12.0 BUDGET

Consideration	Unit	Quantity	Unit cost	Total cost
Biostatistician				30,000
Soft copy material				20,000
Printing paper		40	400	16,000
Ethical research committee				2,000
Contingency				20,000
Total				88,000

13. 0 RESULTS.

Demographic characteristics

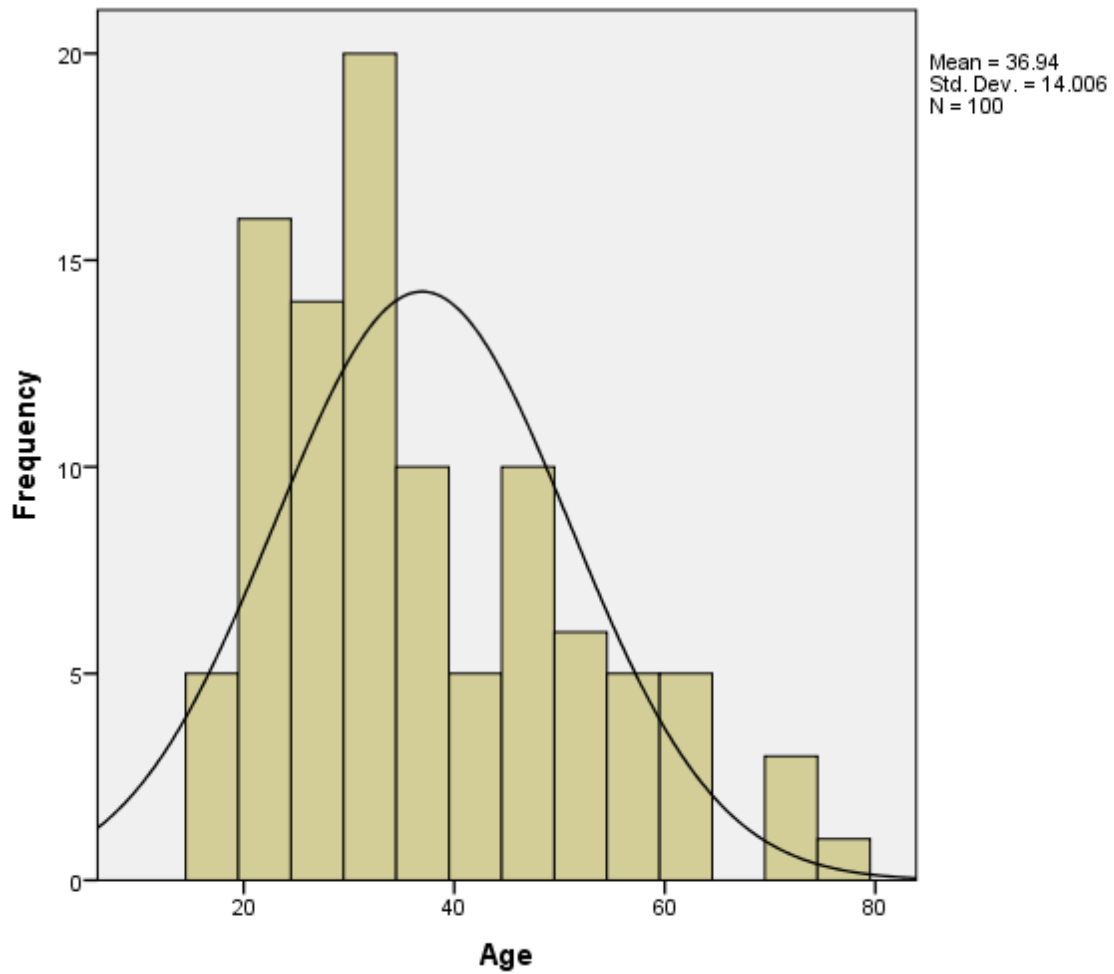
In the study to determine the incidence of paranasal air sinus variations in patients undergoing CT scan evaluation at Kenyatta National Hospital a sample of 100 respondents was used. We had 56 females and 44 males. The mean age of the respondents was 36.9(\pm 14.0) years within the range of 17 to 79 years. Age had no effect on any of the anatomical variants (P-values $>$ 0.05).

Anatomic variants	Categories	Age							Total	P-value
		17-26	27-36	37-46	47-56	57-66	67-76	77-86		
Concha bullosa	No	11	19	10	9	4	2	1	56	0.081
	Yes	16	14	4	6	3	1	0	44	
Haller	No	26	28	11	11	7	3	1	87	0.255
	Yes	1	5	3	4	0	0	0	13	
Agger nasi	No	3	4	1	0	1	0	0	9	0.347
	Yes	24	29	13	15	6	3	1	91	
Onodi	No	11	23	12	8	4	1	0	59	0.378
	Yes	16	10	2	7	3	2	1	41	

TABLE 1

Keros classification	Categories	Age							Total	P-value
		17-26	27-36	37-46	47-56	57-66	67-76	77-86		
Keros 1	Absent	20	21	12	13	5	3	1	75	0.215
	Present	7	12	2	2	2	0	0	25	
Keros 2	Absent	9	13	3	4	4	0	0	33	0.62
	Present	18	20	11	11	3	3	1	67	
Keros 3	Absent	26	32	13	13	5	3	1	93	0.089
	Present	1	1	1	2	2	0	0	7	
Keros 4	Absent	26	33	14	15	7	3	1	99	0.193
	Present	1	0	0	0	0	0	0	1	

TABLE 2



GRAPH 1

Study sample comprised of 44(44%) males and 56(56%) females. Gender had significant correlation (Pearson chi-square p-value=0.043) with Onodi which implied that the variant was mainly dominant in males as compared to females.

Anatomic variants	Categories	Gender		Total	P-value
		Male	Female		
Concha bullosa	No	25	31	56	0.885

	Yes	19	25	44	
Haller	No	38	49	87	0.868
	Yes	6	7	13	
Agger nasi	No	4	5	9	0.541
	Yes	40	51	91	
Onodi	No	21	38	59	0.043
	Yes	23	18	41	

TABLE 3

Paranasal sinus variations on CT scan

a. Ethmoidal air cell variations

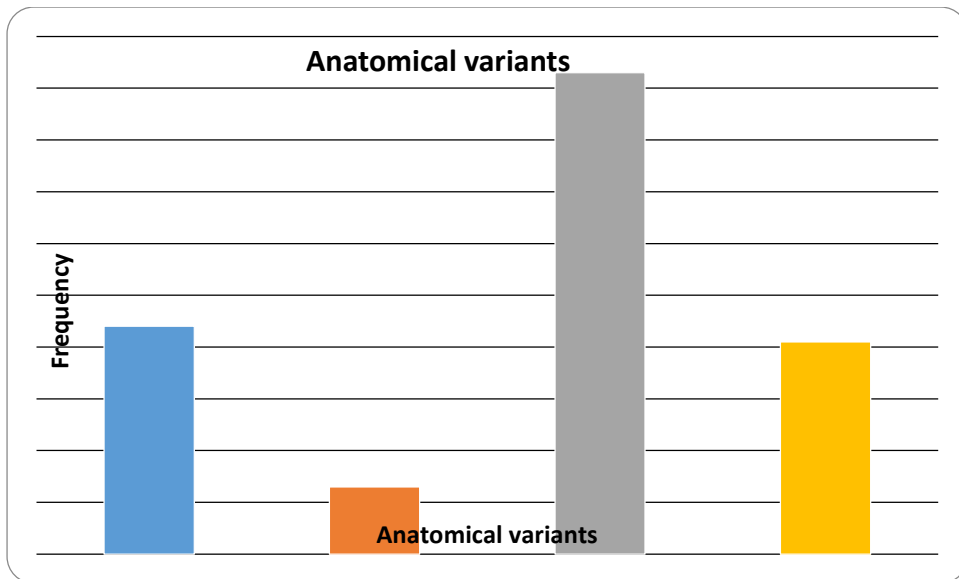
Concha bullosa was identified among 44(44%) patients. This was identified in the right among 11(11%), in the left among 8(8%) and in both left and right in 25(25%).

Haller was identified among 13(13%) patients. This was identified in the right in 1(1%), in the left among 4(4%) and in both left and right in 8(8%) patients.

Agger nasi which was the commonest anatomical variant was identified among 91(91%). This was identified in the right side alone in 3(3%), in the left side alone in 4(4%) and in both left and right in 84(84%).

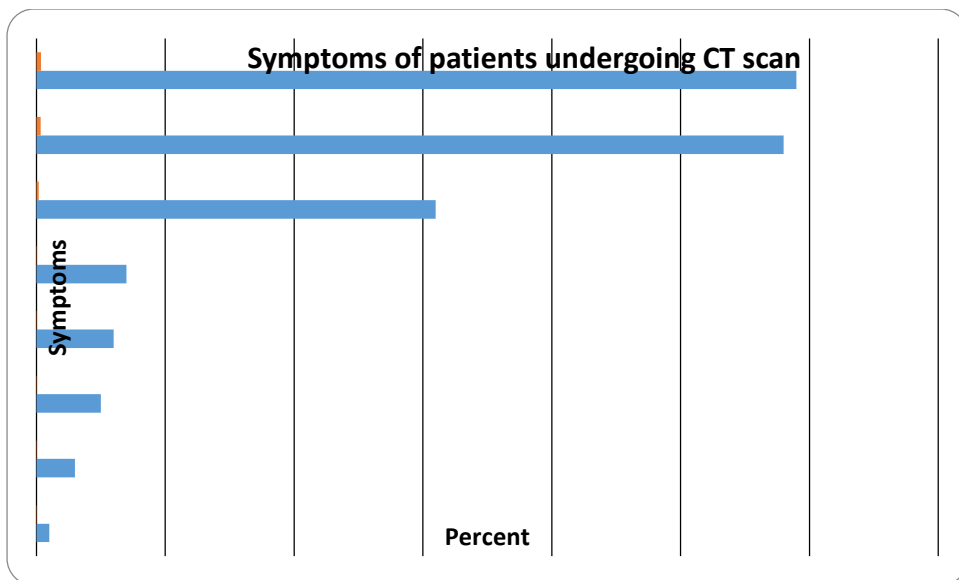
Onodi was identified among 41(41%) patients. This was identified in the right side alone in 11(11%), in the left side alone in 13(13%) and in both left and right in 17(17%).

Nasal septal deviation was identified among 16(16%) patients.



GRAPH 2

Symptoms for CT scanning were indicated in all patients and mainly included nasal blockage 34.7%, headache 34.1% and rhinorrhea 18.2% among others as indicated below.



GRAPH 3

Symptoms Vs. Anatomic variants

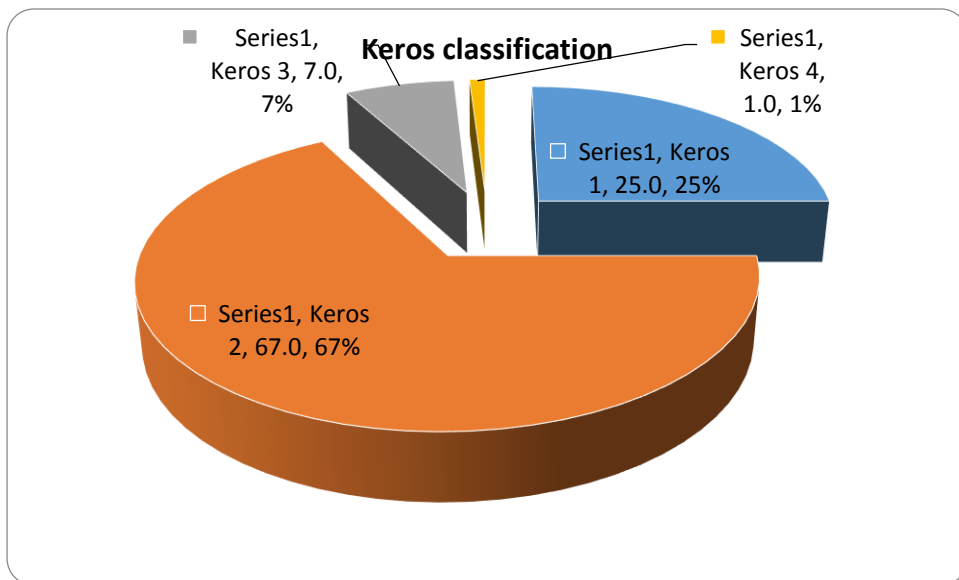
Symptoms for CT scanning	Concha bullosa		Haller		Agger nasi		Onodi	
	No	Yes	No	Yes	No	Yes	No	Yes
Nasal blockage	28	24	47	5	6	46	34	18
Watery rhinorrhea	1	0	1	0	1	0	0	1

Headache	18	14	24	8	1	31	17	15
Rhinorrhea	4	3	7	0	1	6	3	4
Epistaxis	1	1	2	0	0	2	1	1
Poor visibility	4	2	6	0	0	6	4	2
P-value	0.663		0.720		0.268		0.261	

TABLE 4

b. Keros Classification.

Keros 1 was present in 25(25%) patients; keros 2 was present in 67(67%) patients, keros 3 was present in 7(7%) patients and keros 4 was present in 1(1%) patient.



GRAPH 4

Keros	Frequency	Percent
Keros 1	25	25.0
Keros 2	67	67.0
Keros 3	7	7.0

Keros 4	1	1.0
---------	---	-----

TABLE 5

Keros classification	Categories	Gender		Total	P-value
		Male	Female		
Keros 1	Absent	35	40	75	0.357
	Present	9	16	25	
Keros 2	Absent	13	20	33	0.52
	Present	31	36	67	
Keros 3	Absent	41	52	93	0.95
	Present	3	4	7	
Keros 4	Absent	43	56	99	0.261
	Present	1	0	1	

TABLE 6

c. Uncommon variation

Maxillary sinus hypoplasia was identified in 1(1%) patient.

Superior concha bullosa was identified among 4(4%) patients. This was identified in the right side alone in 1(1%) and in both left and right in 3(3%).

Inferior concha bullosa was identified in 1(1%) patient. This was identified in the right side.

Secondary middle turbinate, frontal sinus hypoplasia and sphenoid sinus hypoplasia were the uncommon variants that were not detected in patients from the study.

Bilateral paradoxical middle turbinate was present in 5(5%) patients.

Paradoxical superior turbinate was present in the right in 1(1%) patient.
Septate sphenoid was present in 14(14%) patients.

14.0 CONCLUSION.

Anatomical variations are best viewed and appreciated in the coronal plane. Agger nasi is the commonest anatomical variation of the paranasal sinuses followed by Concha bullosa, then Onodi cells and Haller cells respectively.

Few of the very uncommon variations were also seen, namely paradoxical middle turbinate, superior and inferior concha bullosa.

Gender had significant correlation (Pearson chi-square p-value=0.043) with Onodi cell, which implied that the variant was mainly dominant on males as compared to females. Onodi cells are due to extensive pneumatization of the posterior ethmoids extending over the sphenoid sinus.

Statistical comparison of other anatomic variations did not show any significance between the two sexes, different ages or even between the two sides.

Anatomic variations in paranasal sinuses can lead to recurrent sinusitis, mainly due to impaired sinus drainage and ventilation. Understanding the different variations and location is very important.

The Keros classification of olfactory fossa depth is best calculated in coronal plane, considering it is the best for evaluating the ethmoid roof anatomy.

Anatomical associations of the Keros classification suggest that Keros 1 patients have the least risk of intracranial entry while Keros 3 patients carry the greatest risk during endoscopic sinus surgery.

COMPARISON OF RESULTS WITH OTHER SIMILAR STUDIES

Authors	Agger nasi cells	Haller cells	Concha Bullosa	Onodi cells	Nasal septal deviation	Sample size
Zinreich et al (2003)	Nearly all	10%	36%	-	21%	
Bolger et al (1991)	98.5%	45%	53%	-	18.8%	
Pinas IP (2000)	Nearly all	3%	73%	-	80%	100
Baradaranfar et al (2007)	36%	4.17%	12.5%	-	-	120

Dua et al (2005)	40%	16%	16%	6%	-	50
Mamatha et al (2010)	50%	17.5%	15%		-	40
Arstan et al (1999)	-	6%	30%	12%	-	200
Nitinavakaran et al (2005)	92%	24%	34%	25%		88
Present study	91%	13%	44%	41%	16%	100

COMPARISON OF RESULTS WITH SIMILAR STUDIES

Keros	Frequency	Percent	Keros	Hatipoglu
Keros 1	25	25.0%	26.3%	13.4%
Keros 2	67	67.0%	73.3%	76%
Keros 3	7	7.0%	0.5%	10.5%
Keros 4	1	1.0%		

15.0 RECOMMENDATIONS.

CT scan of the paranasal sinuses in Kenyatta National Hospital should be standardized by doing 3mm cuts, mainly in coronal plane for one to appreciate the sinuses clearly and anatomical variations. Some CT scans are produced with cuts ranging from 3mm upwards up to 7mm, which do not give clear, precise images of the paranasal sinuses and disease processes. There is no standardization or uniformity.

Further studies can be done to compare paranasal sinus CT scan findings with Chronic rhinosinusitis, severity of the disease and symptomatic presentations.

A study on the CT scan findings of patients undergoing functional endoscopic sinus surgery in Kenyatta National Hospital can also be undertaken.

Another study can be on the comparison of anatomical variations on CT scan for patients with sinusitis as compared to non-sinusitis patients. This will help give information with regards to whether anatomical variations contribute to, cause or complicate sinusitis.

16. 0 APPENDICES

APPENDIX 1: GENERAL PATIENT INFORMATION AND CONSENT FORM.

Title: Anatomical variations of paranasal sinuses in patients undergoing CT scan evaluation at the Kenyatta National Hospital.

Investigator Dr Fuad Farah Maalim. Resident ENT, Head and Neck Surgery, University of Nairobi. Contact: 0721448162; Email: drfuadf@gmail.com. P.O Box 10726-00100 Nairobi.

Supervisors: Professor H.O Oburra 0722516675, Dr J. Thinwa 0720879211, Dr J. Ayugi 0722883041.

KNH/UON-ERC Professor M.L Chindia Email: uonknh_erc@uonbi.ac.ke. Contact 2726300, ext 44102.

Introduction

Participation in this study is voluntary. We aim to find out the anatomical variations of the paranasal air sinuses in patients having CT scan evaluation, presenting to Kenyatta National Hospital.

What is involved in this study?

Once you consent to participate, we will take a short medical history. The paranasal sinus CT scan will be evaluated with a consultant radiologist.

Are there any risks involved?

There are no risks involved in participating in this study.

Will I be penalized for not participating?

No, you will receive the same attention and treatment as those who choose to participate in this study.

What benefits will I get if I participate?

There will be no benefits accorded for your participation in this particular study.

The benefits of the study will be towards assisting in local training, emphasis in radiological evaluation of paranasal sinus of patients. Information of ethnic variation trends will eventually be obtained.

What about confidentiality?

All the information we obtain from you will be kept confidential.

How much will it cost me?

No extra cost will be incurred

What are my rights as a participant?

Participation in the study is voluntary. Once inducted in the study, you can choose to discontinue at any time. This will not cause discrimination.

What do you do with the information you get?

This information will help us find out more about anatomical variations of the paranasal air sinuses in patients undergoing CT scan evaluation. The data will act as a baseline research for anyone who wishes to carry further studies on the various other paranasal sinuses.

Are you satisfied with the information given?

If yes and you are willing to participate or let child participate, please fill in and sign the consent below.

APPENDIX 2: CONSENT FOR THE STUDY (ADULT).

Your participation in this study is entirely voluntary.

I..... Of.....

Address.....

study no..... do hereby consent for myself to be included in this study on anatomical variations of the ethmoid air sinuses in patients having CT scan evaluation for rhinosinusitis presenting to Kenyatta national hospital.

The nature of the study has been fully explained to me by Dr Fuad Farah Maalim. Telephone number 0721448162.

I have not been promised any material gain to participate.

I hereby agree to a soft copy of my CT scan be utilized for the study.

Signed..... (Self)

Date.....

KIBALI CHA UTAFITI.

Kushiriki kwako katika utafiti huu ni kwa hiari yako.

Mimi Anwani.....

Nambariyautafiti..... Nimekubali kuhusishwa katika utafiti huu unaongalia utofauti ya anatomia wa ethmoid sinasi kwa kutumia picha ya CT scan.

Nimefahamu baadaya kusoma na kufahamishwa na Dr Fuad Farah M, nambari ya simu 0721448162.

Hakuna malipo nitakayopewa.

Nimekubali picha yangu ya CT scan kutumika katika utafiti huu.

Sahihi..... (Mgonjwa)

Tarehe.....

CONSENT FOR THE STUDY (CHILD).

The participation of your child in this study is entirely voluntary.

I.....

Address

.....

Parent or guardian of study no..... do hereby consent for my child to be included in this study on anatomical variations of the ethmoid air sinuses in patients having CT scan evaluation for rhinosinusitis presenting to Kenyatta national hospital.

The nature of the study has been fully explained to me by Dr Fuad Farah Maalim. Telephone number 0721448162.

I have not been promised any material gain to participate.

I hereby agree to a soft copy of my child's CT scan be utilized for the study.

Signed..... (Parent/guardian)

Date.....

ASSENT FORM FOR MINORS (age 8 – 17 years).

I voluntarily agree to participate in the research study, having had the information and procedure being read out to me by the principal investigator Dr Fuad Farah. I have understood the nature of the study and whatever information given will remain confidential.

Sign your name here (minor) Date

KIBALI CHA UTAFITI (MTOTO).

Kushiriki kwa motto wako katika utafiti huu ni kwa hiari yako.

Mimi Anwani.....

Mzazi ama msimamizi wanambari ya utafiti.....

Nimekubali mtoto wangu kuhusishwa katika utafiti huu unaongalia utofauti ya anatomia wa ethmoid sinasi kwa kutumia picha ya CT scan.

Nimefahamu baada ya kusoma na kufahamishwa na Dr Fuad Farah Maalim, nambari ya simu 0721448162.

Hakuna malipo nitakayopewa.

Nimekubali picha ya mtoto wangu ya CT scan kutumika katika utafiti huu.

Sahihi..... (Mzazi/ Msimamizi)

Tarehe.....

KIBALI CHA MTOTO (miaka 8 – 17).

Nimekubali kushiriki katika utafiti huu kwa hiari yangu, baada ya Daktari Fuad Farah kunielezea na kusoma utaratibu utakaofuatwa. Nime elewa na kufahamu utafiti huu.

Sahihi ya mtoto Tarehe

APPENDIX 3: QUESTIONNAIRE

Serial no: _____.

A. Bio Data

I. Initials: _____.

II. Sex: Male Female

III. Age.

Symptoms and reason for undergoing CT scan of paranasal sinus.

.....

.....

.....

APPENDIX 4

Check list for paranasal sinus variations on CT scan.

Serial no:

a. Ethmoidal air cell variations.

	YES	SIDE	CORONAL	AXIAL	SAGITTAL
CONCHA BULLOSA					

HALLER					
AGGER NASI					
ONODI					
NASAL SEPTAL DEVIATION					

b. Uncommon variations.

	Yes	Type	Side	Coronal	Axial	Sagittal
FRONTAL SINUS HYPOPLASIA						
MAXILLARY SINUS HYPOPLASIA						
SPHENOID SINUS HYPOPLASIA						
UNCINATE BULLA						
SUPERIOR CONCHA BULLOSA						
INFERIOR CONCHA BULLOSA						
SECONDARY MIDDLE TURBINATE						

c. Depth of olfactory fossa

SIDE	KEROS 1	KEROS 2	KEROS 3	KEROS 4
RIGHT				
LEFT				

16.0 REFERENCES

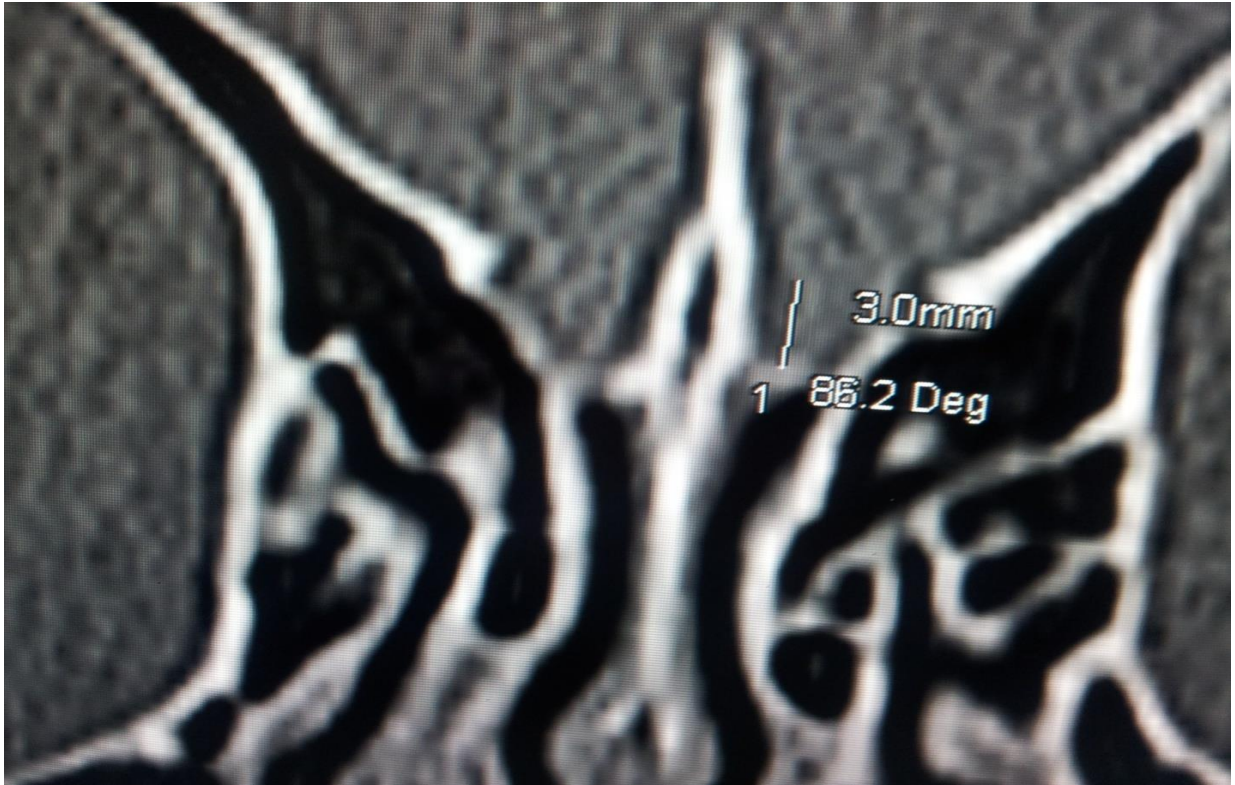
1. Bolger W. E., Butzin C. A., Parsons D. S. Paranasal sinus bony anatomic variations and mucosal abnormalities: CT analysis for endoscopic sinus surgery. *Laryngoscope*. 1991; 101:56–64.
2. Kennedy DW, Zinreich SJ: Functional endoscopic approach to inflammatory sinus disease: Current perspectives and technique modifications. *American Journal of Rhinology*. 1988; 2, 89 – 96.
3. Mosher HP: Symposium on the ethmoid: the surgical anatomy of the ethmoidal labyrinth. *Trans American Academy of Ophthalmology and Otolaryngology*. 1929: 376–410.
4. Y Ramakrishnan, I Zammit-Maempel, N S Jones. Paranasal sinus computed tomography anatomy: a surgeon's perspective. *The Journal of Laryngology & Otology*. 2011; 125, 1141 – 1147.
5. Hudgins P. Complications of endoscopic sinus surgery: the role of the radiologist in prevention. *Radiologic Clinics of North America*. 1993; 31:21–32.
6. Ribeiro Fde A. Standardized measurements of radiographic films of the frontal sinuses: an aid to identifying unknown persons. *Ear Nose Throat Journal*. 2000; 79:26–33.
7. Yoshino M, Miyasaka S, Sato H, Seta S. Classification system of frontal sinus patterns by radiography. Its application to identification of unknown skeletal remains. *Forensic Science International*. 1987; 34:289–299.
8. Tatlisumak E, Yilmaz Ovali G, Aslan A, Asirdizer M, Zeyfeoglu Y, Tarhan S. Identification of unknown bodies by using CT images of frontal sinus. *Forensic Science International*. 2007; 166:428.
9. Morimoto N, Ogihara N, Katayama K, Shiota K. Threedimensional ontogenetic shape changes in the human cranium during the fetal period. *Journal of Anatomy*. 2008; 212:627-635.
10. Hanna EH, Levine HL, Timen S, Kotton B. Hypoplasia of the maxillary antrum: anatomic abnormalities, diagnostic difficulties and surgical implications. *American Journal of Rhinology*. 1993; 7:105-110.

11. Yonetsu K, Watanabe M, Nakamura T. Age-related expansion and reduction in aeration of the sphenoid sinus: volume assessment by helical CT scanning. *American Journal of Neuroradiology*. 2000; 21:179–182.
12. Zinreich SJ, Mattox DE, Kennedy DW, Chisholm HL, Diffley DM, Rosenbaum AE. Concha bullosa: CT evaluation. *Journal of Computer Assisted Tomography*. 1988; 12:778–84.
13. Dogru H, Doner F, Uygur K, Gedikli O, Cetin M. Pneumatized inferior turbinate. *American Journal of Otolaryngology*. 1999; 20:139–41.
14. Arslan H, Aydinlioglu A, Bozkurt M, Egeli E. Anatomical variations of the paranasal sinuses: CT examination for endoscopic sinus surgery. *Auris Nasus Larynx*. 1999; 26:39–48.
15. Calhoun KH, Waggenspack GA. CT evaluation of the paranasal sinuses in symptomatic and asymptomatic populations. *Otolaryngology Head and Neck Surgery*. 1991; 104:480–3.
16. Meloni F, Mini R, Rovasio S, Stomeo F, Teatini GP. Anatomic variations of surgical importance in ethmoid labyrinth and sphenoid sinus. A study of radiological anatomy. *Surgical and Radiological Anatomy*. 1992; 14:65–70.
17. Ji-Hyeon Shin, Sung Won Kim, Yong Kil Hong. The Onodi Cell: An Obstacle to Sellar Lesions with a Transsphenoidal Approach. *Otolaryngology Head and Neck Surgery*. 2011; 145(6) 1040–1042.
18. Driben JS, Bolger WE, Robles HA, Cable B, Zinreich SJ. The reliability of computerized tomographic detection of the Onodi (sphenoethmoid) cell. *American Journal of Rhinology*. 1998; 12:105–11.
19. Stammberger H. Endoscopic sinus surgery-concepts in treatment of recurring rhinosinusitis. Part II. Surgical technique. *Otolaryngology Head and Neck Surgery*. 1986; 94:147–56.
20. Bolger WE, Woodruff Jr WW, Morehead J, Parsons DS. Maxillary sinus hypoplasia classification and description of associated uncinata process hypoplasia. *Otolaryngology Head and Neck Surgery*. 1990; 103:759–65.

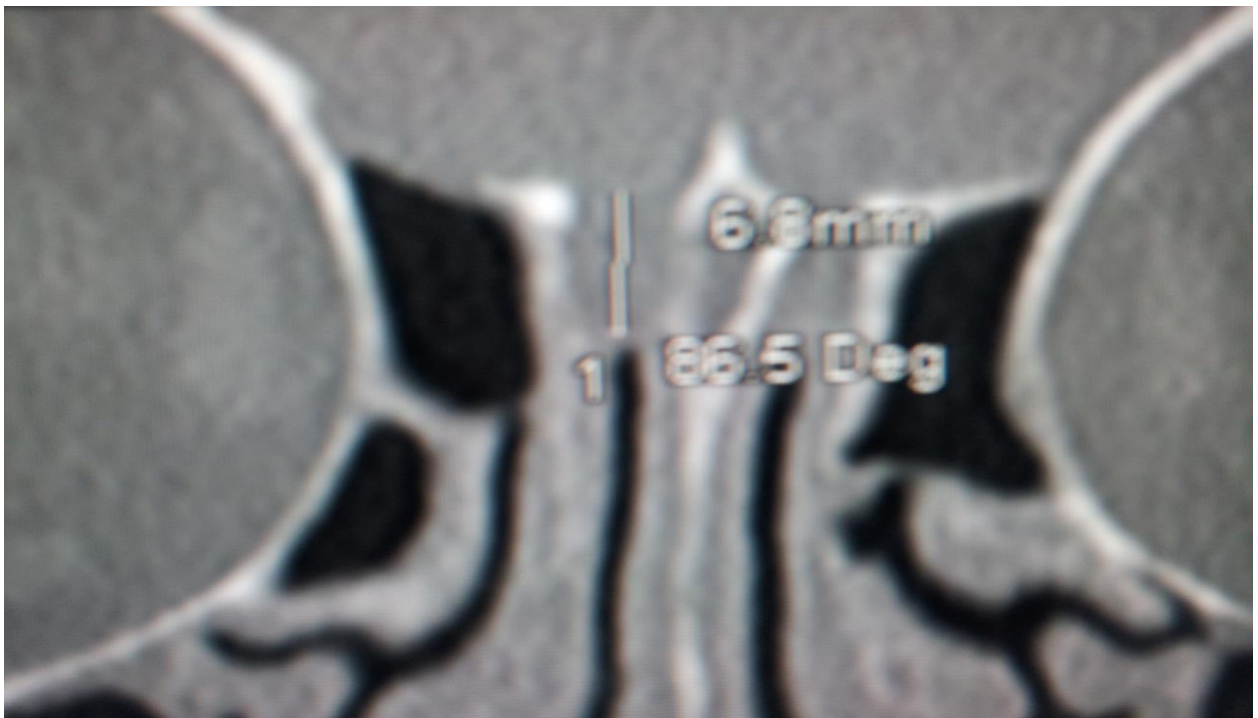
21. Kennedy DW, Zinreich SJ, Shaalan H, Kuhn F, Navlerio R, Loch E. Endoscopic middle meatal antrostomy theory, technique and patency. *Laryngoscope (Suppl)*. 1987; 97:1–9.
22. Anik I, Anik Y, Koc K, Ceylan S. Agenesis of sphenoid sinuses. *Clinical Anatomy*. 2005; 18:217–219.
23. Keskin G, Ustundag E, Ciftci E. Agenesis of sphenoid sinuses. *Surgical and Radiological Anatomy*. 2002; 24:324–326.
24. Duque CS, Casiano RR, Surgical Anatomy and Embryology of the Frontal Sinus. In: Kountakis S, Senior BA, Draf W. *The Frontal Sinus*. Springer. 2005.
25. Perez P, Sabate J, Carmona A. Anatomical variations in the human paranasal sinus region studied by CT. *Journal of Anatomy*. 2000;197:221–227.
26. Dua K, Chopra H, Khurana AS and Munjal M. CT scan variations in chronic sinusitis. *Indian Journal of Radiology and Imaging*. 2005; 15(3), 315-320.
27. Mamatha H, Shamasundar NM, Bharathi M, Prasanna L. Variations of Osteomeatal Complex and Its Applied Anatomy: A CT scans Study. *Indian Journal of Science and Technology*. 2010; 3(8): 904-7.
28. Hatipoğlu HG, Cetin MA, Yüksel E. Concha Bullosa Types: Their Relationship with Sinusitis, Ostiomeatal and Frontal Recess Disease. *Diagnostic and Interventional Radiology*. 2005; 11(3): 145- 149.
29. Kayalioglu G, Oyar O, Govsa F: Nasal cavity and paranasal sinus bony variations: a computed tomographic study. *Rhinology*. 2000; 38(3):108–113.
30. Basic N, Basic V, Jukic T, Basic M, Jelic M, Hat J. Computed tomographic imaging to determine the frequency of anatomical variations in pneumatization of the ethmoid bone. *European Archives of Otorhinolaryngology*. 1999; 256:69–71.
31. Lerdlum S, Vachiranubhap B. Prevalence of anatomic variation demonstrated on screening sinus computed tomography and clinical correlation. *Journal of Medical Association of Thailand*. 2005; 88 Suppl 4: S110-115.
32. Wormald PJ. The agger nasi cell: the key to understanding the anatomy of the frontal recess. *Otolaryngology Head and Neck Surgery*. 2003; 129: 497-507.

33. Bradley DT, Kountakis SE. The role of agger nasi air cells in patients requiring revision endoscopic frontal sinus surgery. *Otolaryngology Head and Neck Surgery*. 2004; 131: 525-527.
34. Badia L, Lund VJ, Wei W, Ho WK. Ethnic variation in sinonasal anatomy on CT-scanning. *Rhinology*. 2005; 43: 210-214.
35. Nitinavakarn B, Thanaviratananich S, Sangsilp N. Anatomical variations of the lateral nasal wall and paranasal sinuses: a CT study for endoscopic sinus surgery (ESS) in Thai patients. *Journal of Medical Association of Thailand*. 2005; 88(6): 763-8.
36. Vincent TE, Gendeh BS. The Association of Concha Bullosa and Deviated Nasal Septum with Chronic Rhinosinusitis in Functional Endoscopic Sinus Surgery Patients. *Medical Journal of Malaysia*. 2010; 65(2): 108-11.
37. Baradaranfar MH, Labibi M. Anatomic variations of paranasal sinuses in patients with chronic sinusitis and their correlation with CT scan staging. *Acta Medica Iranica*. 2007; 45:477-80.
38. Kantarci M, R. Murat Karasen, Fatih A, Omer O, Adnan O. Remarkable anatomic variations in paranasal sinus region and their clinical importance. *European Journal of Radiology*. 2004 (50)296–302.
39. Khanobthamchai K, Shankar L, Hawke M, Bingham B. The secondary middle turbinate. *Journal of Otolaryngology*. 1991; 20:412–3.
40. Aykut M, Gümüşburun E, Müderris S, Adigüzel E. The secondary nasal middle concha. *Surgical and Radiologic Anatomy*. 1994; 16:307–9.
41. Aksungur EH, Biçakçı K, Inal M, Akgül E, Binokay F, Aydoğan B. CT demonstration of accessory nasal turbinates: secondary middle turbinate and bifid inferior turbinate. *European Journal of Radiology*. 1999; 31:174–6.
42. Binal C, Muhammed AS, Ahmet BY. A retrospective analysis of sphenoid sinus hypoplasia and agenesis using dental volumetric CT scan in Turkish individuals: *Diagnostic and Interventional Radiology*. 2011; 17:205 – 208.
43. Wanga SK, Lemeshow S. Sample size determination in health studies. A practical manual. Ginebra: *World Health Organization*, 1991.

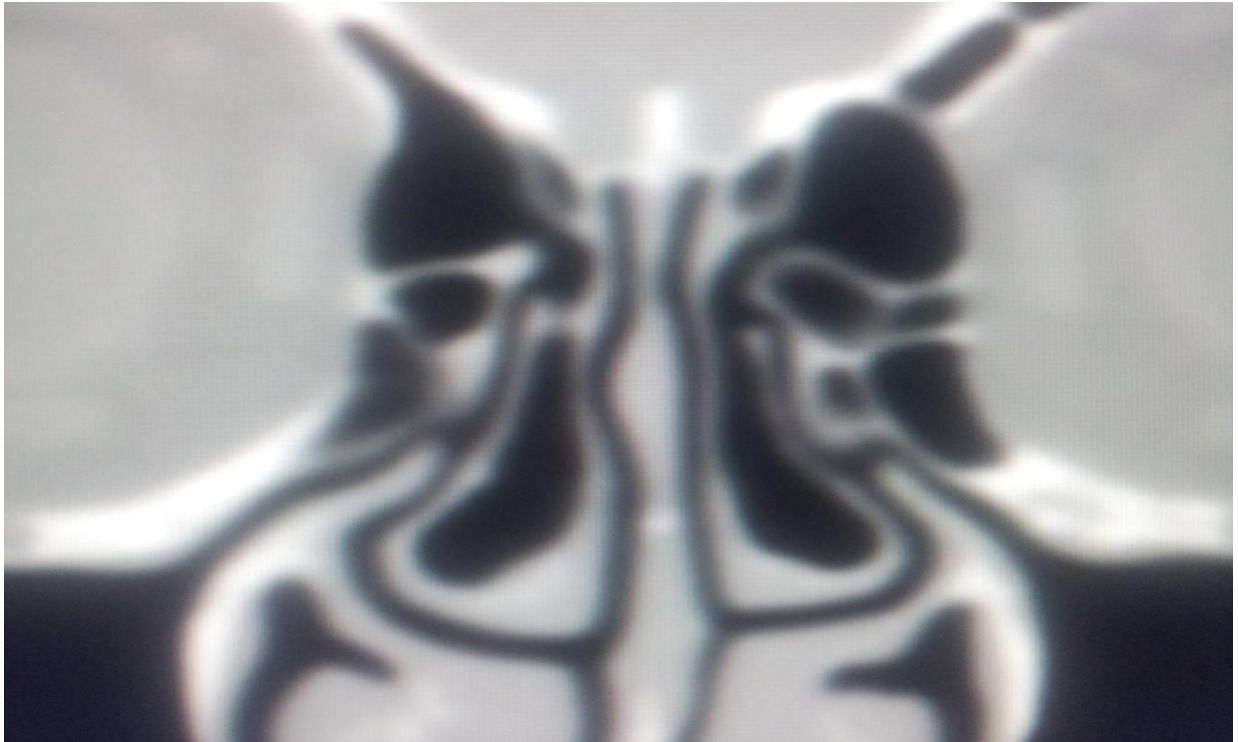
44. Keros P. On the practical value of differences in the level of the lamina cribrosa of the ethmoid. *Z Laryngology Rhinology Otology*. 1962; 41:809–13.



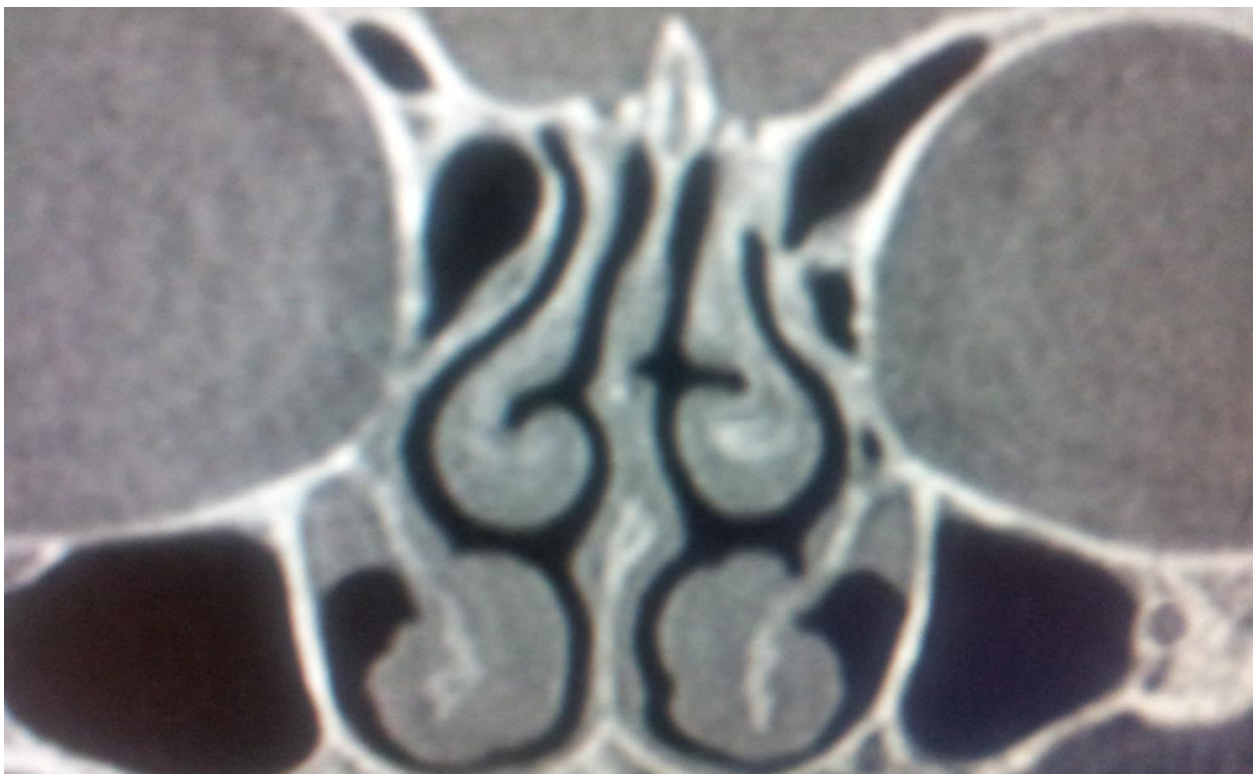KEROS TYPE 1



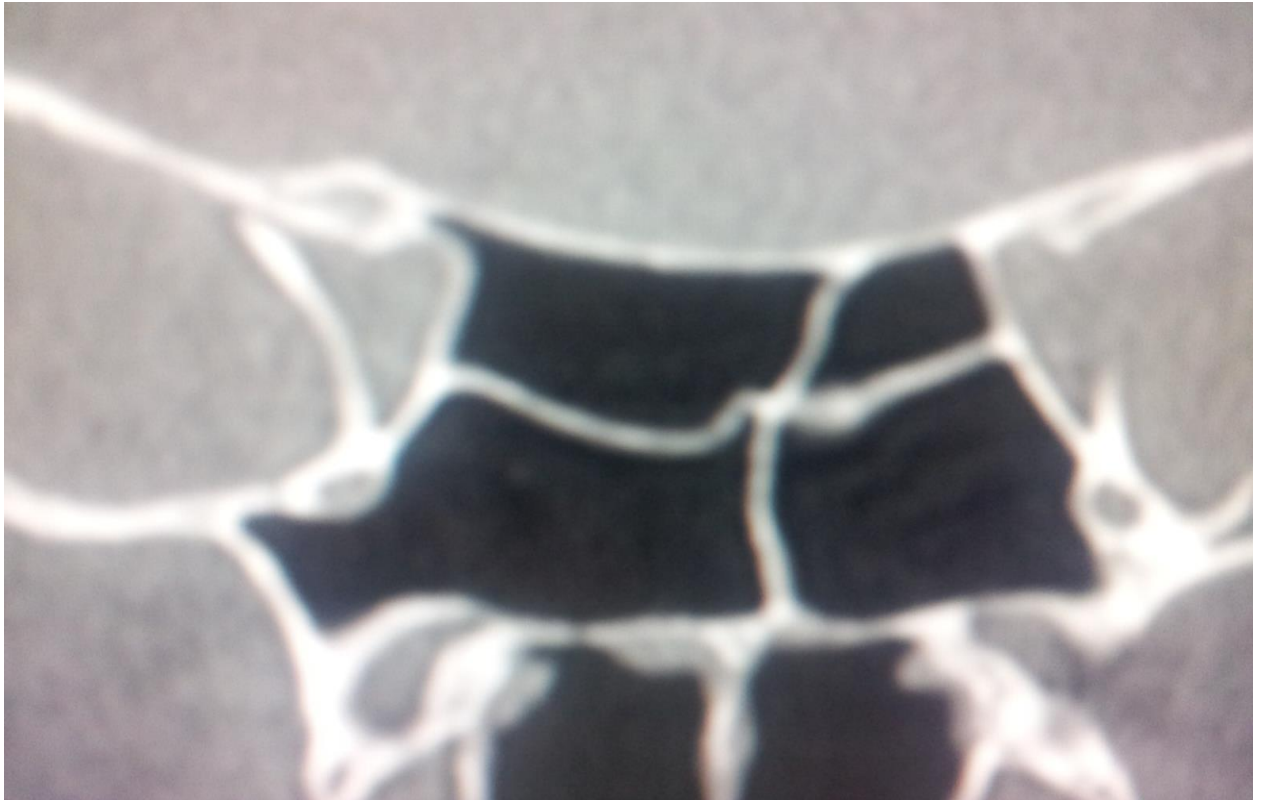KEROS TYPE 2



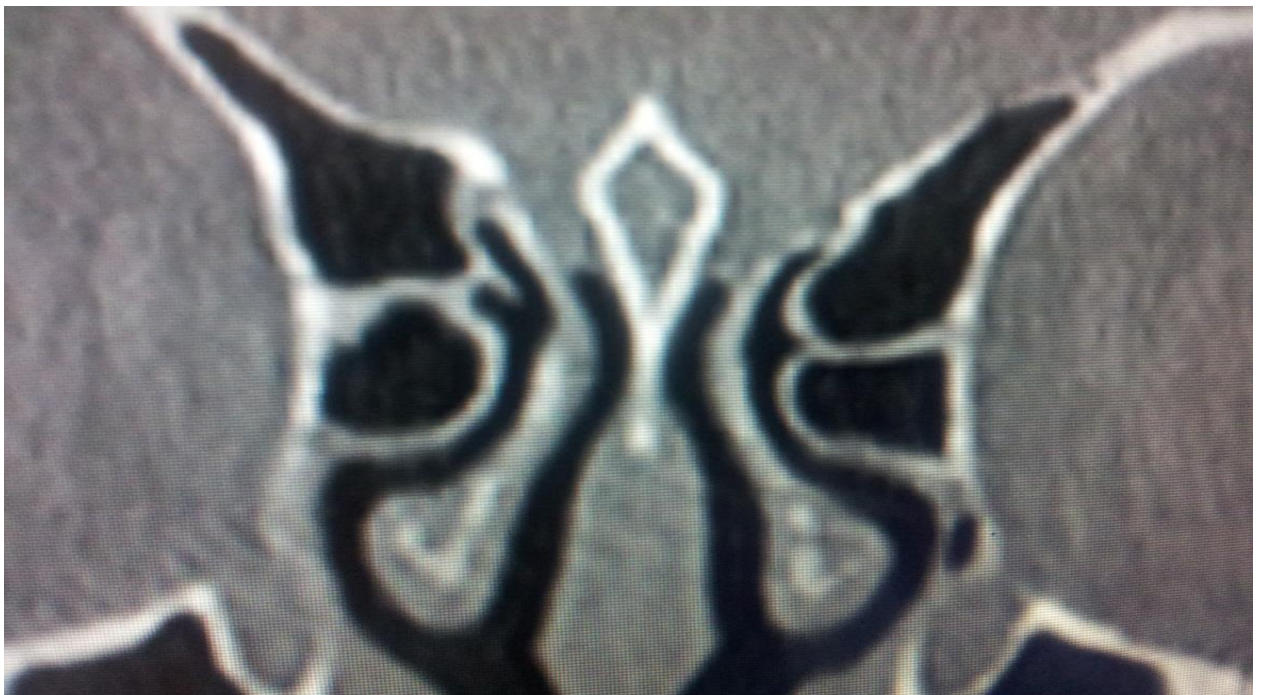BILATERAL CONCHA BULLOSA



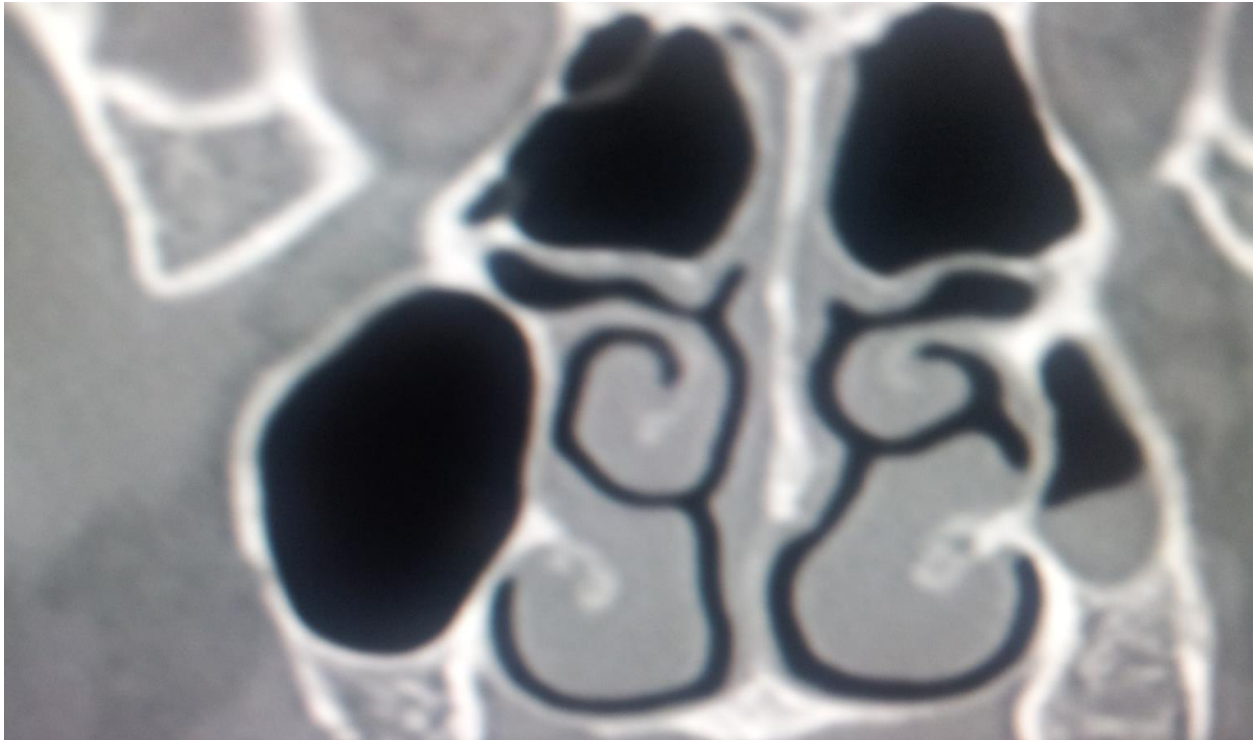
BILATERAL PARADOXICAL MIDDLE TURBINATES



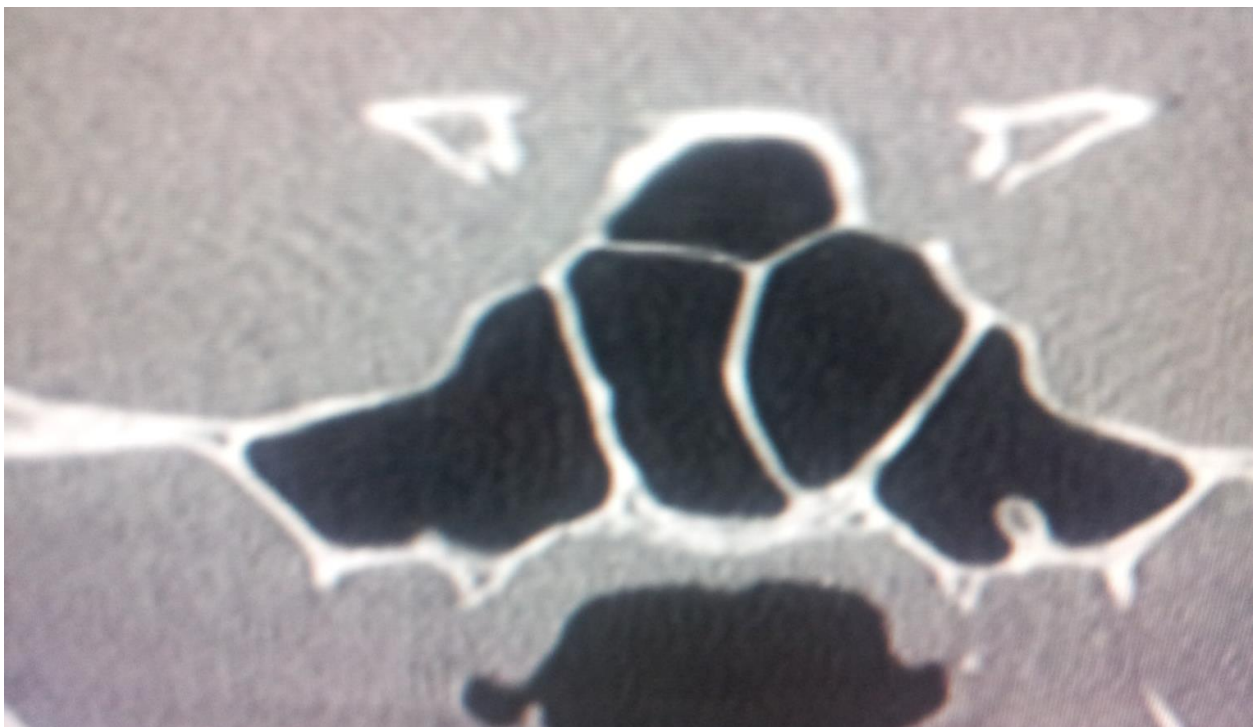
ONODI CELLS.



AGGER NASI CELLS.



LEFT MAXILLARY SINUS HYPOPLASIA TYPE 1.



SEPTATE SPHENOID SINUS