

See discussions, stats, and author profiles for this publication at: <http://www.researchgate.net/publication/235726073>

SHORT COMMUNICATION AN OUTBREAK OF ACUTE BOVINE DERMATOPHILOSIS IN A LARGE SCALE DAIRY HERD IN KENYA

ARTICLE *in* BULLETIN OF ANIMAL HEALTH AND PRODUCTION IN AFRICA. BULLETIN DES SANTÉ ET PRODUCTION ANIMALES EN AFRIQUE · OCTOBER 2006

DOI: 10.4314/bahpa.v54i2.32741

CITATION

1

DOWNLOADS

12

VIEWS

109

5 AUTHORS, INCLUDING:



James Kihang'a Wabacha

University of Nairobi

23 PUBLICATIONS 87 CITATIONS

SEE PROFILE



Pauline Gitonga

Kenyatta University

10 PUBLICATIONS 1 CITATION

SEE PROFILE



Andrew Thaiyah

University of Nairobi

7 PUBLICATIONS 3 CITATIONS

SEE PROFILE

SHORT COMMUNICATION

AN OUTBREAK OF ACUTE BOVINE DERMATOPHILOSIS IN A LARGE SCALE DAIRY HERD IN KENYA

J.K. WABACHA*, N.P. GITONGA, M.J. NJENGA, A.G. THAIYAH
and C.M. MULEI

Department of Clinical Studies, Faculty of Veterinary Medicine, University of Nairobi,
P.O. Box 29053, Nairobi, Kenya

Dermatophilosis, caused by *Dermatophilus congolensis*, is a disease that affects mainly cattle, sheep, camels, horses and goats and occurs as an acute or chronic exudative skin disease¹. Injury of the skin by insect and tick bites and thorny bushes accompanied by prolonged wetting are thought to be important predisposing factors^{1,2}. Affected animals initially develop moist, round, circumscribed papules that later turn to scabs and crusts whose location is highly variable^{3,4}.

In tropical and subtropical areas, the disease can be epizootic and can result in considerable economic losses as a result of lost production, premature culling, treatment costs and downgrading of hides and skins^{1,5}. Although the clinical disease has been recognised in several African countries^{4,6,7,8} the occurrence of clinical disease in Kenya was only recently reported in three dairy cows in a zero grazing unit⁹. This case report describes an outbreak of acute bovine dermatophilosis in a large scale dairy herd and highlights that the disease in Kenya could occur in outbreak proportions and in clinically severe form as has been reported in other countries in West and Central Africa. We believe that this is the 1st documented outbreak of a severe form of bovine cutaneous dermatophilosis in exotic dairy animals in Kenya.

On 26th November 2006, the manager of a large scale dairy farm with 262 heads of cattle reported the occurrence of skin lesions in two yearling heifers.

*Corresponding author: Tel.: +254-2-630451; fax: +254-2-632059; e-mail: wabachajames@uonbi.ac.ke

At the farm, a clinical history of the condition was taken and this was followed by a clinical examination. The examination revealed that yearling and bulling heifers were pastured during the day and paddocked at night. The rest of the animals were confined and fed in well-fenced paddocks. The main clinical signs in the two heifers were grey-white, crusty, localised lesions on the lateral neck. By 30th November 2006, 44 out of the 74 yearling and bulling heifers were noted to have similar lesions. In the month of December 2005, sixty-eight (68) new cases broke out and this time it involved weaned calves as well as the yearling and bulling heifers. A total of 114 (43.5%) cases were observed during the outbreak period that lasted from mid November 2005 to early January 2006 when the weather was rainy (Figure 1).

Two types of skin lesions were seen in the affected animals. The most common lesions were manifested as discrete, circumscribed lesions of variable sizes that were covered with grey-white crusts (Figure 2). Some crusts had coalesced to form large lesions covering large areas of the skin (Figure 3). The pustular lesions were less common and involved the formation of small scabs protruding above the skin surface causing the hair over the affected site to be erect and matted in tufts (paintbrush lesion) (Figure 4). Removal of the crusts from the discrete circumscribed lesions revealed an alopecic, red, moist epidermis oozing either blood or serum. The lesions of the pustular form were evenly distributed over the whole skin surface while for the crusty form the lesions were mainly on the lateral neck, head region, brisket and down the hind limbs.

A tentative diagnosis of cutaneous bovine dermatophilosis was made on 26th November 2006 and the affected heifers were isolated from the rest of the animals. Some skin scrapings were taken from the lesions for bacterial isolation and characterisation. The scrapings were directly streaked on blood agar and incubated at 37^oC. The growth was relatively slow, forming grey raised granular colonies in 72 hours which were adherent to the medium and produced a β -haemolysis. Gram stain of the colonies revealed Gram-positive cocci in rows of multiseptate branched filaments which is characteristic of *Dermatophilus congolensis*.

All the affected animals were treated on 30th November 2005 with a single intramuscular injection of 20mg/kg long-acting oxytetracycline (Centrivet®, Norbrook laboratories). The animals with severe lesions received a second injection after 5 days on

5th December. New cases in December and January received the same regimen of treatment. Lesions began to dry off 3 days following treatment and regression of lesions was complete after 4 weeks.

The disease was observed first in heifers that were being grazed on pastures. The hard prickly pastures that the animals were grazing on following prolonged draught accompanied with wetting from the rains could have contributed to the occurrence of the disease on the face, the neck and the extremities, for the initial cases, as has been reported previously^{1,2,3}. The high population of flies at the time could have contributed to the occurrence of pustular lesions all over the body⁴. The clinical signs observed in the present outbreak were similar to those reported for dermatophilosis in cattle^{1,2,3,4,5}. The weaner calves, though they were in isolation from the infected heifers, came down with the clinical disease and this was attributed to insect bites.

The isolation and morphological identification of *Dermatophilus congolensis* supported the clinical diagnosis. In the present outbreak, the crusts were grey-white, greasy and firmly attached to hair fibres and when removed they left a red, moist epidermis oozing serum or blood. These findings were consistent with dermatophilosis lesions as described in the literature^{1,2,3,4,5}. The treatment of the animals with long-acting tetracycline at 20mg/kg body weight intramuscularly was able to cure the animals and this was in agreement with previous findings⁵. Other drugs that have been shown to be effective include, procaine penicillin combined with streptomycin, erythromycin and a combination of lincomycin and spectinomycin⁵.

Considering the large number of animals involved, and the severity of the lesions, that necessitated veterinary intervention, it would be necessary to assess the prevalence and economic importance of the disease in dairy herd establishments in Kenya.

Acknowledgements

We acknowledge the cooperation and commitment of the farm Manager and his stockmen during the investigation.

References

1. Lloyd, D.H. and Sellers, K.C. (1976). Dermatophilus infections in animals and man. Proceedings of a conference held at the University of Ibadan, Nigeria. New York: Academic Press.
2. Scott, D.W. (1988). In: Large Animal Dermatology: Saunders Philadelphia. :136
3. Bwangamoi, O. (1976). In: Dermatophilus infection in Animals and Man. Lloyd D.H. and K.C. Sellers (Editors). Academic Press, London: 49
4. Oduye O.O. (1976). In: Dermatophilus infection in Animals and Man. Lloyd D.H. and K.C. Sellers (Editors). Academic Press, London: 2
5. Radostitis, O.M., Blood, D.C., Gay, C.C. and Hinchcliff, K.W. (2000). In: Veterinary medicine: A textbook of the diseases of cattle, sheep, pigs, goats and horses, 9th Ed: Saunders Philadelphia: 938.
6. Koney, E.B. and Marrow A.N. (1990). Trop. Anim. Hlth. Prod. Afri., **22**: 89
7. Kaminjolo, J.S. and Karua S.K.(1981). The Kenya Veterinarian, **5**(2): 1
8. Samui, K.L. and Hugh-Jones, M.E. (1990). Vet. Res. Commun., **14**:267
9. Wabacha, J.K., Mulei, C.M., Maribei, J.M. and Mbithi, P.M.F. (2001). The Kenya Veterinarian **21**: 43.

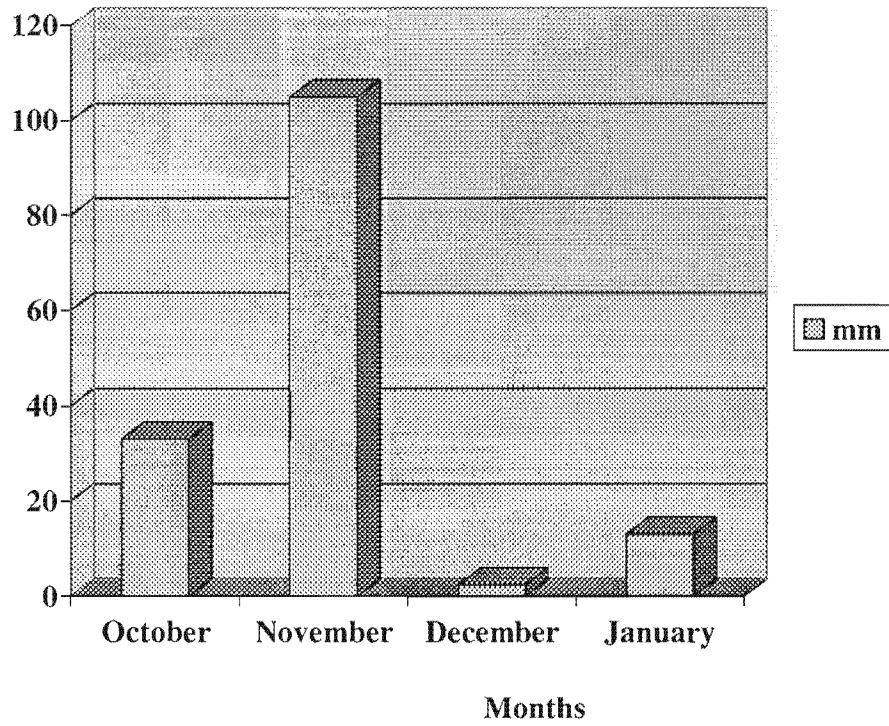


Figure 1. The amount of rainfall received per month from October 2005 to January 2006.

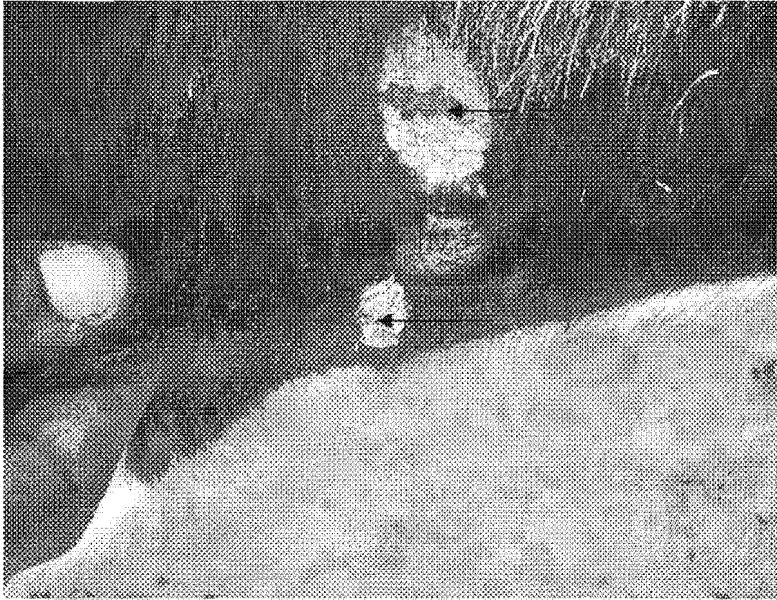


Figure 2. Circumscribed greyish crusty lesions on the neck of a bulling heifer oozing blood and serum (arrows)




Figure: 3 Confluence of the lesions and areas where crusts had fallen off leaving alopecic areas oozing blood and serum (arrows)



Figure 4: A bulling Heifer with small horny scabs protruding above the skin surface