

**THE HISTOMORPHOLOGY AND TENSIOMETRY OF
THE FIBROUS VENTRAL ABDOMINAL WALL OF THE
BABOON (*PAPIO ANUBIS*) AND THE GOAT (*CAPRA
HIRCUS*)**

by

Dr Paul O. Odula

H80/81045/2010

**A thesis submitted in fulfillment of the requirements for the degree of Doctor of Philosophy
in the University of Nairobi**

Department of Human Anatomy

University of Nairobi

P.O Box 30197, 00100 GPO Nairobi.

2015

DECLARATION

I hereby confirm that this thesis is my original work, and has not been presented for a degree in any other university

Sign: _____ Date: _____

Dr. Paul O. Odula, BSc, MBChB, MMed, FCS


Department of Human Anatomy, University of Nairobi

This thesis has been submitted with our approval as university supervisors:

Sign: _____ Date: _____

Prof. Stephen G. Kiama, BVM, MSc, PhD

Department of Veterinary Anatomy and Physiology, University of Nairobi



Sign: _____ Date: _____

Prof. Jameela Hassanali, BDS; DDS (Edin)

Formally: Department of Human Anatomy, University of Nairobi

Currently: Chairman of Anatomy and Physiology, Pwani University.

DEDICATION

*To Jonathan, Kyle and Lisa.....keep going, each step may get
harder, but don't stop. The view is beautiful at the top.*

*To my darling Carol... thank you for being patient, for showing love and
generosity especially during my most trying moments.*

ACKNOWLEDGEMENTS

My sincere gratitude goes to my supervisors Prof. J. Hassanali and Prof S.G Kiama for tirelessly and painstakingly going through my work and guiding me through the many challenges that I came across. Prof Kiama was very instrumental in giving brilliant, well thought and non-prejudicial comments which were invaluable in shaping the work from its inception to the end. In a special way, I would like to appreciate Prof Hassanali's encouragement, insistence on alignment, consistency and elimination of redundancy. A special thanks also goes to Mr. J. Mugweru of the Department of Veterinary Anatomy and Physiology, Mr. John Kahiro and David Macharia for assisting during material testing and the Department of Mechanical Engineering, University of Nairobi, for allowing the use of their equipment. I would like to express gratitude to Dr. M. Ngotho and the staff of Institute of Primate Research, National Museums of Kenya for giving us permission to collect the tissues from the experimental baboons. I would also like to appreciate the efforts of Dr. Philip Mwachaka for assistance with statistical analysis and Stephen Muita, Sarah Mungania and Acleus Murunga for assistance with materials procurement. Margaret Irungu is hereby appreciated for her tireless efforts in the labeling of samples and the histological processing of the tissues. My sincere and deep gratitude goes to Prof Julius Ogeng'o and Prof Saidi Hassan for exemplary mentorship, encouragement and regular follow-up of my personal academic progress. Last but not least, I cannot forget BSc (Anat) students, the rest of the staff in the department of Human Anatomy and as well as the staff of the department Veterinary Anatomy and Physiology of the University of Nairobi, for their constant friendship and support throughout the study. Finally, I am deeply grateful to the University of Nairobi for waiving tuition fees and awarding me a Dean's committee grant to facilitate my research work.

TABLE OF CONTENTS

Title	i
Declaration	ii
Dedication	iii
Acknowledgements	iv
Table of Contents	v
List of Figures	viii
List of Tables.....	x
List of Abbreviations.....	xi
Summary	xiii
BACKGROUND	xiii
OBJECTIVE	xiii
MATERIALS AND METHODS.....	xiv
RESULTS.....	xiv
CONCLUSIONS.....	xvii
CHAPTER ONE.....	1
1.0 INTRODUCTION, LITERATURE REVIEW, STUDY OUTLINE AND OBJECTIVES.....	1
1.1 Introduction	1
1.2 Literature review	5
1.2.1 Morphology of the fibrous ventral abdominal wall	5
1.2.2 Histology of the fibrous ventral abdominal wall.....	7
1.2.3 Biomechanical properties of the fibrous ventral abdominal wall.....	14
1.2.4 Clinical significance.....	17
1.3 Study design	19
1.4 Objectives of the study.....	19
1.4.1 Broad objective:	19

1.4.2	Specific objectives:	19
CHAPTER TWO	20
2.0	MATERIALS AND METHODS.....	20
2.1	Experimental Animals (The baboon and the goat)	20
2.1.1	The baboon and goat as a study model.....	20
2.1.2	Harvesting and tissue sampling of the FVAW	20
2.3	Light microscopy of each of the tissues sampled	25
2.4	Morphometric analysis of the laminae.....	25
2.5	Biomechanical testing of the fibrous ventral abdominal wall.....	26
2.5.1	Sampling of the test specimens.....	26
2.5.2	Tensiometric measurements of the baboon and goat samples	28
2.6	Statistical analysis of the fibrous ventral abdominal wall parameters.....	32
2.7	Ethical considerations for use of the animals.....	32
CHAPTER THREE	33
3.0	RESULTS.....	33
3.1	Histomorphology and tensiometric characteristics of the baboon fibrous ventral abdominal wall	33
3.1.1	Morphology of the baboon fibrous ventral abdominal wall	33
3.1.2	Histology of the baboon fibrous abdominal wall.....	36
3.1.3	Measurement of the various laminae of the baboon fibrous ventral abdominal wall	45
3.1.4	Tensiometry of the baboon fibrous ventral abdominal wall.....	48
3.1.5	Coefficient of elasticity (Young’s modulus) of the baboon fibrous ventral abdominal wall	57
3.2	Histomorphology and tensiometric characteristics of the goat fibrous ventral abdominal wall	62
3.2.1	Morphology of the goat fibrous ventral abdominal wall	62
3.2.2	Histology of the goat fibrous abdominal wall	65
3.2.3	Measurement of the various laminae of the goat fibrous ventral abdominal wall	76
3.2.4	Tensiometry of the goat fibrous ventral abdominal wall.....	79

3.2.5	Coefficient of elasticity (Young’s modulus) of the goat fibrous ventral abdominal wall.....	85
CHAPTER FOUR.....		90
4.0	DISCUSSION	90
4.1	Morphology of the fibrous ventral abdominal wall	90
4.2	Histology of the fibrous ventral abdominal wall.....	92
4.2.1	Histology of the linea alba	92
4.2.2	Histology of the rectus sheath.....	94
4.3	Morphometry and biomechanics	97
4.3.1	The biomechanical role of collagen and elastic fibres in the fibrous ventral abdominal wall	97
4.3.2	The role of morphometry and tensiometry in the fibrous ventral abdominal wall	100
4.4	Conclusions	105
4.5	Suggestions for further studies	106
CHAPTER FIVE.....		107
5.0	REFERENCES	107
6.0	APPENDICES- Abstracts of publications.....	119

LIST OF FIGURES

		<u>Page</u>
Figure 1	Photograph of an olive baboon	22
Figure 2	Photograph of a goat	22
Figure 3	Photomicrographs of the baboon FVAW showing landmarks for sampling sites	24
Figure 4	Photomicrographs of the goat FVAW showing landmarks for sampling sites	24
Figure 5	Photograph of the Houston tensiometer used in the study	31
Figure 6	Photographs of the harvested sample undergoing traction	31
Figure 7	Photomicrographs showing the parts of the baboon fibrous ventral abdominal wall	35
Figure 8	Photomicrographs of the transverse sections of the baboon LA	38
Figure 9	Photomicrographs of the transverse sections of the baboon VRS	41
Figure 10	Photomicrographs of the transverse sections of the baboon DRS	44
Figure 11	Bar charts showing measurements of the different laminae of the baboon fibrous ventral abdominal wall	47
Figure 12	Graphs illustrating the stress-strain curves at the baboon LA	50

Figure 13	Graphs illustrating the stress-strain curves at the baboon VRS	53
Figure 14	Graphs illustrating the stress-strain curves at the baboon DRS	56
Figure 15	Bar charts showing the elasticity of coefficient of the baboon fibrous ventral abdominal wall when exposed to different traction forces	59
Figure 16	Photomicrographs showing the parts of the goat fibrous ventral abdominal wall	64
Figure 17	Photomicrographs of the transverse sections of the goat LA	67
Figure 18	Photomicrographs of the transverse sections of the goat VRS	70
Figure 19	Photomicrographs of the transverse sections of the goat EDRS	73
Figure 20	Photomicrographs of the transverse sections of the goat DRS	75
Figure 21	Bar charts showing measurements of the different laminae of the goat fibrous ventral abdominal wall	78
Figure 22	Graphs illustrating the stress-strain curves at the goat LA	81
Figure 23	Graphs illustrating the stress-strain curves at the goat VRS	84
Figure 24	Bar charts showing the elasticity of coefficient of the goat fibrous ventral abdominal wall when exposed to different traction forces	87

LIST OF TABLES

Table 1	Table showing the number of samples exposed to the longitudinal, oblique and transverse traction force in the baboon and the goat.	28
Table 2	Table showing the geometrical dimensions of the mean thickness of the fibrous ventral abdominal wall samples in the epigastric, umbilical and hypogastric regions in the baboon.	47
Table 3	Table showing the maximal forces, highest ultimate tensile strengths and highest coefficient of elasticity recorded for the fibrous ventral abdominal wall samples in the epigastric, umbilical and hypogastric regions in the baboon.	61
Table 4	Table showing the geometrical dimensions of the mean thickness of the fibrous ventral abdominal wall samples in the epigastric, umbilical and hypogastric regions in the goat.	78
Table 5	Table showing the maximal forces, highest ultimate tensile strengths and highest coefficient of elasticity recorded for the fibrous ventral abdominal wall samples in epigastric, umbilical and hypogastric regions in the goat.	89

LIST OF ABBREVIATIONS

FVAW-	Fibrous ventral abdominal wall
EOM-	External oblique abdominis muscle
EOA-	External oblique abdominis aponeurosis
IOM-	Internal oblique abdominis muscle
IOA-	Internal oblique abdominis aponeurosis
TAM-	Transversus abdominis muscle
TAA-	Transversus abdominis aponeurosis
DF	Deep fascia
LA-	Linea alba
RS-	Rectus sheath
VRS-	Ventral wall of rectus sheath
DRS-	Dorsal wall of rectus sheath
RAM-	Rectus abdominis muscle
PT-	Pubic tubercle
YM	Young's Modulus
UTS	Ultimate tensile strength
XP	Xiphoid process
SL	Superficial lamina
IL	Intermediate lamina
DL	Deep lamina

EF	Elastic fibres
Co	Collagen fibres
FT	Fascia transversalis
FTR	Fascia transversalis lining rectus abdominis muscle dorsally
FTI	Fascia transversalis lining internal oblique muscle dorsally
N	Newtons
mm	millimetre

SUMMARY

BACKGROUND

It is generally known that the fibrous ventral abdominal wall comprises of mainly an admixture of longitudinal, oblique and transverse bundles of collagen and elastic fibres. The formation, orientation and the strength of this fibrous wall would be expected to differ between animals depending on the forces applied to them. The baboon, a terrestrial primate, is a quadruped but occasionally referred to as a facultative biped when feeding or when hunting for food. The goat is a quadruped who is a browser capable of consuming and accommodating large quantities of forages which markedly distends its caudal abdomen. The different modes of locomotion and feeding would influence the structure of the fibrous ventral abdominal wall. Despite these unique differences, there is scanty information regarding the structure and tensile strength of the fibrous ventral abdominal wall in the baboon and the goat. Data on the structure of the fibrous ventral abdominal wall would give us an insight on how these animals cope with the various forces applied on the ventral abdominal wall and the likelihood of predisposition to rectus diastases and/or herniation.

OBJECTIVE

This study was undertaken to ascertain the histomorphology and morphometry of the fibrous ventral abdominal wall of the baboon and the goat so as to elucidate the elements that are accountable for maintaining the integrity of the wall when it is exposed to forces due to normal functions, posture and movements. The study also undertook to determine the ultimate tensile

strength and elastic coefficient of the different regions of the baboon and the goat fibrous ventral abdominal wall and how it relates to structure and function.

MATERIALS AND METHODS

The fibrous ventral abdominal wall was harvested from seven healthy male baboons aged 12 – 24 months sacrificed at the Institute of Primate Research and six male goats aged 1 - 2 years procured from an animal slaughter market. The baboon experiments were approved by the internal review committee of the Institute of Primate Research. After ensuring that ethics and scientific issues had been addressed, strips of tissue were resected from the mid-epigastric, the umbilical and hypogastric part of the linea alba. Equivalent strips were also obtained from the ventral and dorsal rectus sheath. Some strips of tissues were set aside for mechanical testing, while others were processed for light microscopy and then morphometric measurements. Observations and measurements were coded and tabulated. Data collected were entered into the Statistical Package for Social Sciences software (Version 17.0, Chicago, Illinois) for coding, tabulation and statistical analysis. Since the data was non-parametric, the Kruskas Wallis test was conducted. Graphs, tables, and photographs were used to present the results.

RESULTS

Observations of this study have revealed that although the fibrous ventral abdominal wall of the baboon and the goat are similar in their gross morphology and hence the formation of the individual laminae, they however, have unique differences in their collagen and elastic ratios, orientation, laminae thickness and tensiometric characteristics. In both animals, the aponeurosis of external and internal oblique abdominis muscle joined to form the ventral rectus sheath while the

aponeurosis of transversus abdominis formed the dorsal rectus sheath. Light microscopic observations revealed that the linea alba, ventral and dorsal rectus sheath in the two animals were made up of three, two and one distinct laminae respectively. In both animals the superficial lamina was noted to be lined or at times closely apposed to the deep fascia ventrally.

In the baboon, the epigastric linea alba comprised of predominantly obliquely aligned collagen bundles while the umbilical was mainly composed of a fused thick mass of transversely oriented collagen bundles. Virtually all the collagen bundles in the hypogastric linea alba were longitudinally aligned. The rectus sheath however, was found to be more elastic than the linea alba. The baboon ventral rectus sheath was found to be predominantly made up of obliquely aligned collagen fibres with infrequent fine elastic fibres in the deep fascia ventrally and lining the deep lamina dorsally. The oblique collagen bundles in the hypogastric ventral rectus sheath were arranged in a characteristic crisscross manner. The dorsal rectus sheath in contrast, was noted to consist of mainly transversely aligned overlapping collagen bundles which had heavily infiltration of transversely aligned elastic fibres. The deep fascia was indistinct and contained very few elastic fibres.

In the goat, the epigastric linea alba was made up of a superficial lamina composed of predominantly obliquely aligned collagen bundles, an intermediate lamina comprising of longitudinally aligned collagen bundles and a deep lamina consisting of transversely oriented collagen fibres. The umbilical and hypogastric linea alba was composed of an intermediate lamina which had discrete and prominent collagen bundles. The ventral rectus sheath was made up of two

laminae which comprised of obliquely aligned collagen bundles. The collagen bundles were markedly thinner in the deep lamina of the umbilical and the hypogastric regions of the linea alba and ventral rectus sheath. The goat epigastric dorsal rectus sheath consisted of transversely aligned collagen bundles sandwiched by longitudinally arranged sheets of elastic fibres. These collagen bundles in the umbilical and hypogastric dorsal rectus sheath were noted to be thinner and were surrounded by sparse elastic fibres. The deep fascia (tunica flava abdominis) was intimately apposed to the ventral surface of the superficial lamina in the goat linea alba and the ventral rectus sheath. This fascia was thicker and more prominent in the umbilical and hypogastric regions of the linea alba and the ventral rectus sheath.

Results of tensiometry revealed that the goat's umbilical ventral rectus sheath recorded the highest ultimate tensile strength of 125 N/mm² in both animals followed by the baboon's umbilical dorsal rectus sheath (95 N/mm²). This was noted when they were exposed to transversely aligned traction. However, when the umbilical and hypogastric regions ultimate tensile strengths were combined, the goat's ultimate tensile strength of ventral rectus sheath and the baboon's ultimate tensile strength of dorsal rectus sheath was noted to have similar values of 201.8 N/mm² and 195 N/mm² respectively.

The highest elastic coefficient recorded in either animal was seen when the fibrous ventral abdominal wall was exposed to longitudinal loading. Although the baboon umbilical dorsal rectus sheath recorded the highest elastic coefficient of 1000(SD 0.1)N/mm², it also had the thinnest

lamina (0.051mm) recorded. In both animals, however, the rectus sheath recorded a uniformly higher elastic coefficient than the linea alba.

CONCLUSIONS.

The findings of this study show that the collagen bundles with the heavy elastic fibre impregnation seen in the baboon dorsal rectus sheath and the unusually elastic rich ventral surface of goat fibrous ventral abdominal wall, constitute a strong fibroelastic structure “band-like” of variable tension” which serve to support the abdominal viscera. This allows for graduated accommodation/ stretch and recoil while at the same time conserving energy by preventing unnecessary muscular use due to increased abdominal pressures/ forces. The findings of an unusually thin baboon DRS which had the highest UTS and also had the highest elastic coefficient, would serve to inform the industry on future development of meshes. The intimate association of the elastic and collagen fibres in the fibrous ventral abdominal wall of the baboon and the goat may allow the strengthening of the wall, like the steel in tyres. Thus, not only would it serve as an energy saving structure, but it would possibly keep the incidences of rectus diastases and ventral hernia formation to minimal levels in these animals.

CHAPTER ONE

1.0 INTRODUCTION, LITERATURE REVIEW, STUDY OUTLINE AND OBJECTIVES.

1.1 Introduction

The abdominal wall components, specifically muscle and connective tissue, must meet and accommodate a wide range of force demands for torso movement, spine stabilization, and respiration (Brown and McGill, 2008). The ventral abdominal wall comprises skin, superficial fascia, a fibrous part and a muscular part. The oblique and transversus abdominis muscles constitute the ventro-lateral abdominal muscles, while the rectus abdominis muscle forms the ventro-midline muscular part (Moeinzadeh et al., 1983). The fibrous parts in the abdominal midline namely, the linea alba, the rectus sheath and an overlying deep fascia, are very important for the stability of this system from a mechanical and postural point of view.

The linea alba (LA), is a tough midline tendinous structure formed by the interlocking aponeurotic fibers of three ventrolateral abdominal muscles namely external oblique, internal oblique and transversus abdominis passing from one side to the other (Askar, 1977; Axer et al., 2001a; Standring et al., 2008). The rectus sheath (RS) is made up of two walls that enclose the rectus abdominis (RAM) muscle and its neurovascular bundle. The ventral wall is firmly attached to rectus abdominis (RAM) muscle while the dorsal wall sheath is not (Sinnatamby, 2000).

The pattern of formation of the rectus sheath may be explained by its embryogenesis (Walmsley, 1937; Rizk, 1980; Yang et al., 2012). The ventral abdominal wall is first formed by

ectoderm and parietal mesoderm (Risk, 1980). For the sheath above the umbilicus, Rizk (1980) postulated the so-called “bilaminar theory” that provided a good biomechanical model for the adult rectus sheath as an intermediate tendon for the bilateral abdominal wall muscles. A lamina from each of the external oblique and internal oblique would divide into two laminae according to the collagen fiber direction. Rizk (1980) further suggested that differentiation into bilaminar and decussating collagen fibres in the rectus sheath may be established by mechanical demands after birth.

The function of the linea alba is to maintain the abdominal muscles, particularly the rectus abdominis muscles, at a certain proximity to each other (Beer et al., 2009). In a study done on quadrupeds, Smit (2002) proposed that the linea alba acts as a passive tensile band which assists in conserving energy by bearing the weight of the intra-abdominal organs and hence prevent sagging of the abdominal wall.

In the abdominal region, the deep fascia is a fibrous, membranous sheath which consists of thin layers of connective tissue of approximately 156 μ m that strongly adhere to the surrounding musculature and aponeuroses. This fascia has several functions namely shrouding and separating neurovascular structures, strengthening ligaments, and generally binding structures together into compact masses. These layers physiologically mimic thin lamina of collagen fibers, but also contain an irregularly distributed mesh of elastic fibers and nerve fibers (Stecco, 2011; Findley, 2012). Hardly any microscopic work has been done on the deep fascia of animals despite its prominence as yellow sheet in ruminants (tunica flava abdominis).

The pattern of formation of the fibrous ventral abdominal wall in its comparative form, morphological interpretation, and its possible functional significance has been a subject of

numerous studies in humans (Askar, 1977; Axer et al., 2001; Axer et al., 2001b; Mwachaka et al., 2009; Pulei et al., 2015). However, very few studies have been done in other animals (Walmsley 1937; Acostasantamaria et al., 2015)

The human abdominal linea alba has been described as composed of a three dimensional fibre architecture of highly structured meshwork of oblique and transverse collagen (Axer et al., 2001a). Other workers have noted collagen fibres lying in an oblique alignment in the epigastric region and transversely orientation in the hypogastric regions of the abdomen (Pulei et al, 2007).

Elastic fibres have also been found in the superficial lamina and in the lateral and the hypogastric parts of the linea alba (Pulei et al, 2015). These findings were confirmed by Mwachaka et al (2009), who also noted a high concentration of elastic fibres in the medial edge of the human rectus sheath. Pulei et al (2015), who further examined the linea alba of different sexes, noted that females had more transverse collagen and elastic fibres than males especially in the hypogastric region.

Studies have shown a high correlation between the structure and the mechanical function of fibrous ventral abdominal wall connective tissue fibres (Axer et al., 2001a). Other studies have also shown that the tensile strength of the linea alba is directly proportional to the thickness and density (Korenkov et al., 2001). Using a biomechanical study, Grassel et al (2005) proposed that when the linea alba is exposed to increasing force in the longitudinal, transverse and oblique direction, compliance was highest in the longitudinal direction and least in the transverse direction.

The baboon, a terrestrial primate, is a quadruped but occasionally referred to as a facultative biped when feeding or when hunting for food. It has longer and more powerful forelimbs than the hindlimbs (Rose, 1976). In addition, while on one hand the baboon's abdominal organs are adapted

to an omnivorous diet, the goat on the other hand has a purely herbivorous kind of gastrointestinal adaptation. The goat is a quadruped with hind limbs which are more powerful and stronger than the forelimbs. It is also a browser capable of consuming and accommodating large quantities of forages which markedly distends its lower abdomen. Both the baboon and the goat are exposed to various degrees of abdominal pressures depending on their posture when feeding or hunting and also depending on the capacity of the abdominal cavity. The different grades of locomotor and feeding adaptations would be expected to influence the structure of the fibrous ventral abdominal wall.

With this in mind, it is important to study the histomorphology and tensile strength of the fibrous abdominal wall of the baboon (primate) and the goat (a quadruped) so as to understand how the structure relates to its various functions. In addition, due to the similarities in structural arrangement between these animals and man, the present study may also help us understand the possible mechanisms for occurrence of recti diastases and ventral abdominal wall hernias in man.

1.2 Literature review

1.2.1 Morphology of the fibrous ventral abdominal wall

The fibrous ventral abdominal wall is composed of the linea alba, the rectus sheath and the deep fascia. The linea alba runs from the xiphoid to the pubic symphysis. It separates the pair of rectus abdominis within a sheath. Formed by the interlacing and crisscrossing aponeurotic fibers of the external and internal obliques and the transversus abdominis, the linea alba is physically shown as a light groove in lean, muscular bodies. The sheath surrounding the rectus abdominis muscle is also formed ventrally by the aponeurotic fibres of the EOM and dorsally by the aponeurotic fibres of the TAM. Varying amounts of aponeurotic fibres of the IOM will form either the VRS or the DRS or both (Standring, 2008). The deep fascia is a fibrous, membranous sheath that has properties which vary from region to region throughout the human body (Gallaudet, 2008). This dense connective tissue surrounds and sometimes interpenetrates the abdominal wall muscles, aponeurosis, nerves and blood vessels (Gallaudet, 2008).

Various studies have described the pattern of formation of the linea alba and rectus sheath, and its possible functional significance in humans (Askar 1977; Axer et al., 2001; Mwachaka et al., 2009). Walmsley (1937) described the construction of the rectus sheath in mammals and noted that it varied from order to order and even among related species. He went on further to illustrate the three (3) forms or groups in which the rectus sheath exists in mammals.

In group I, the ventral rectus sheath was formed by the aponeurosis of the external oblique abdominis only while the dorsal rectus sheath was formed by the aponeurotic fibers of the internal

oblique and transversus abdominis muscle. Group I type of rectus sheath was commonly seen in marsupials, ornithorhynchus, talpidae and pteropus.

In group II, the aponeurosis of external and internal oblique abdominis muscle joined to form the ventral rectus sheath while the aponeurosis of transversus abdominis formed the dorsal rectus sheath. These authors observed this arrangement in primates like the gibbon, baboon, rhesus monkey, chimpanzee and the gorilla. The rabbits, dogs and the insectivora (except Talpidae) were also described as having a similar rectus sheath formation pattern and thus also belonged to this group.

In group III, the aponeurosis of internal oblique abdominis muscle split to enclose the rectus abdominis muscle while the aponeurosis of the external oblique and transversus abdominis muscle completed the ventral and dorsal rectus sheath respectively (Walmsley, 1937). Animals that belong to group III pattern of rectus sheath formation included the cat, pig, horse, ox, sheep, mouse and man.

Variations within a group have been reported for instance in man. Monkhouse et al (1986) observed three different patterns of formation of this sheath in the latter. In their study, only 60% of the cases conformed to the classical pattern observed in man. In 27.5% of their cases, the internal oblique abdominis did not split but passed ventral to the rectus abdominis leaving the transversus abdominis to form the dorsal wall of the rectus sheath. Still in the same study, the transversus abdominis was noted to split to enclose the rectus abdominis in 12.5% of the cases.

Walmsley (1937) observed other variations within the mouse for example. He noted that the caudal part of the aponeurosis of the internal oblique abdominis which normally splits around the rectus abdominis muscle may sometimes shift wholly to join the aponeurosis of the external

oblique abdominis. This would leave the aponeurosis of the transversus abdominis to solely form the dorsal rectus sheath as would normally be seen in group II.

Within group III namely, in the ox, the sheep and man the dorsal rectus sheath has been noted to cease abruptly at the arcuate line as the lower part of the aponeurosis of the internal oblique and transversus abdominis all shift ventrally to join the external oblique abdominis aponeurosis.

Other variations noted include the gibbon in group II, whereby the aponeurosis of lower part of the transversus abdominis in the lower part quarter suddenly splits into two layers to surround the rectus abdominis as far as the pubis. In the chimpanzee, the transversus abdominis aponeurosis has been observed to maintain its position in the dorsal rectus sheath in its whole extent. In the baboon, Walmsley (1937) noted that the internal oblique aponeurosis passed wholly ventrally to the rectus while the dorsal rectus was formed wholly by the aponeurosis of lower part of the transversus abdominis until the arcuate line. At the arcuate line the latter abruptly wholly shifts ventrally as seen in the human pattern.

1.2.2 Histology of the fibrous ventral abdominal wall

1.2.2.1 Histology of the linea alba

The microscopic structure of the fibrous ventral abdominal wall has been reported by several workers in man (Askar, 1977; Axer et al., 2001a; Pulei et al., 2007; Pulei et al., 2015; Mwachaka et al., 2009) and in the pig (Acostasantamaria et al., 2015). The linea alba in the human has been reported by several workers to exhibit zonation (Askar, 1977; Axer et al., 2001a; Pulei et al., 2007; Pulei et al., 2015). Axer et al (2001a) described the human linea alba as the area of decussation of the tendinous aponeurotic fibers of the muscular strata passing from one side to the

other. Using confocal laser scanning microscopy they outlined three different zones of fiber orientation that follow each other from ventral to dorsal:-

1. The lamina fibrae obliquae consists of intermingling oblique fibers (on average, four to six layers of fibers).
2. The lamina fibrae transversae contains mainly transverse fibril bundles (on average, four to six layers of fibers).
3. An inconstant, small lamina fibrae irregularium is composed of one to two layers of oblique fibers.

Axer et al (2001a) further suggested a histological classification of the linea depending on three different aponeuroses crossing the flat abdominal muscles above the umbilicus. Type I was demonstrated to be characterized by a single aponeurosis crossing on the anterior surface of the linea alba and another single aponeurosis on the posterior surface (30% of the cases), the type II had threefold anterior and threefold posterior aponeuroses (60% of the cases), and type III had one aponeurotic crossing on the anterior and three on the posterior. The workers suggested that these aponeurotic crossings in the linea alba had different strengths and durability. In studies done later, Axer et al (2001b) postulated that type I predominates in patients with herniae of the abdominal wall.

Askar, (1978) classified the human linea alba into three morphological types according to fiber density namely a weak type (fibers that were thin and widely meshed), compact type (fibers that were thick and closely meshed), and an intermediate type that was a mixture of both. They

suggested that the weak type of the linea alba may be a predisposing factor for development of incisional hernia.

The human abdominal linea alba has been described as composed of a three dimensional fibre architecture of highly structured meshwork of oblique and transverse collagen (Axer et al., 2001a). Axer et al, (2001a) noted that 35 to 60% of the fibers in the human linea alba, were transversely aligned. Other studies have described the human linea alba as consisting of a superficial, intermediate and deep lamina (Pulei et al., 2007). Pulei et al (2007) observed certain important gender difference in human linea alba in the different regions. They noted that the hypogastric part of the linea alba in the female contained more transverse collagen fibers as opposed to longitudinal fibers than the males. The longitudinal fibres were more in the male, and in some cases the middle lamina of the male adults was entirely composed of longitudinal collagen fibers. The dorsal and middle laminae of the linea alba were indistinguishable in the females since they both contained transverse fibres. These findings are similar to those seen in the porcine (Acostasantamaria et al., 2015). However both Acostasantamaria et al (2015) and Axer et al, (2001a), paid little attention to elastic fibres. The latter being critical for long range deformability and pressure recoil without energy input in tissues wherever they exist (Kielty et al., 2002).

Only Pulei et al (2015) described in a bit more detail the orientation and distribution of elastic fibres in the human linea alba. The elastic fibres were noted to be longitudinally and obliquely disposed in the entire length of the LA. In both males and females, the elastic fibres were observed to be more abundant in the ventral lamina, in the lateral and hypogastric parts of the LA. Females were found to have more elastic fibres than males particularly in the hypogastric region. However to date, no microscopic work yet has been done on animals like the goat and the baboon to show adaptations of the linea alba to posture and intraabdominal pressures.

1.2.2.2 Histology of the rectus sheath

The rectus sheath is a strong connective tissue made of collagen. It forms a sheath of dense white fibrous tissue that encloses the rectus abdominis muscles. These muscles are a superficial pair of muscles extending along the entire length of the anterior abdominal wall, from the thoracic cage to the pelvis. The rectus sheath has multiple functions, such as abdominal compression to increase the intra-abdominal pressure (parturition, defecation, etc.), support the abdominal contents and flexion. The rectus sheath enables the rectus abdominis muscles to slide through neighboring structures and also protects them from injury. Other lateral abdominal muscles (external oblique, internal oblique and transversus abdominis) become aponeurotic near the linea alba and contribute fibres to the formation of the rectus sheath (Standring, 2004).

Studies on the human rectus sheath have shown it to be organized into distinct zones (Axer et al., 2001a; Mwachaka et al., 2009). Axer et al (2001a) noted that the ventral rectus sheath mainly consisted of oblique fibril bundles, while the dorsal rectus sheath consists mainly of transverse fibril bundles. In some cases the innermost layers of the dorsal rectus sheaths consisted of a few layers of oblique fibril bundles. The oblique and transverse fibril bundles were noted to intermingle forming a three-dimensional mesh of fibers similar to the pattern described in the linea alba. Below the level of the umbilicus the dorsal transverse fibril bundles began to spread onto the ventral rectus sheath. This transition of fibers from dorsal to ventral continues over two to three segments, so that three craniocaudal regions could be described as epigastric, umbilical and hypogastric. These three zones are also displayed by the diameter of the rectus sheaths as the dorsal rectus sheath became continuously thinner in the transition zone and diminished in size caudally. The ventral rectus sheath, in contrast, continuously became thicker in the transition zone (Axer et al., 2001a).

Although the rectus sheaths are built from the aponeuroses of external oblique, internal oblique, and transversus abdominis muscles, the composition of ventral and dorsal rectus sheaths is rather variable (Monkhouse, 1986). Moreover, additional fibers in ventral rectus sheaths come from the tendinous intersections of the rectus abdominis muscle, which intermingle with the oblique fibers of the ventral rectus sheath (Walmsley, 1937). Fiber orientation influences the mechanical characteristics of the intact tissue (Chouke, 1935; Anson, 1938). The meshwork character of the collagen architecture has some dynamic properties. The meshwork as such can be deformed less or more before the fibers themselves come under substantial strain (Moeinzadeh et al., 1983).

A significant step towards a better understanding of the morphology and biomechanics of the rectus sheath was carried out by Axer et al (2001 b). These authors provided information on rectus sheath fibre orientations, fibre diameter and distribution in humans (Axer et al., 2001a), as well as an interpretation for the biomechanical role of different fibre groups (Axer et al., 2001b).

Seen in a different perspective, the collagen fibre bundles in the ventral rectus sheath ran in the same direction as the fascicles of internal oblique muscle (William et al., 1995). The lower fascicles of this muscle were transversely disposed while the upper ones slant upwards and medially to be inserted into the costal margin. In the dorsal rectus sheath, the collagen fibre bundles were transversely aligned in tandem with the orientation of the transversus abdominis muscle (William et al., 1995). Axer et al, (2001b) postulated that the lamina fibrae obliquae on one hand would have a role in movement, torque, and stabilization while the lamina fibrae transversae on the other hand, would play a major role in resisting intraabdominal pressure.

The pattern of formation of the rectus sheath in humans and animals may be explained by its embryogenesis (Walmsley, 1937; Rizk, 1980; Yang et al., 2012). The ventral abdominal wall is first formed by ectoderm and parietal mesoderm (Rizk, 1980). For the sheath above the umbilicus, Rizk (1980) postulated the so-called “bilaminar theory”. According to Rizk, (1980), the ventral abdominal wall muscles are derived from the lower thoracic myotomes that migrate ventrally invading the somatopleura during the sixth week of intra-uterine life. Rectus abdominis muscle develops first from the tips of these myotomes then the rest of the mesodermal sheet divides into two strata: internal oblique stratum and external oblique stratum. The internal oblique stratum gives rise to transversus abdominis and internal oblique abdominis muscles while the external oblique stratum develops into external oblique abdominis muscle.

Later in development, the distal parts of the ventral abdominal muscles become aponeurotic (Rizk et al., 1982). The aponeurosis of the internal oblique abdominis muscle attaches to the primordial rectus sheath and grows on both ventral and dorsal surfaces towards the linea alba forming its superficial and deep lamina. External oblique becomes placed anterior to the superficial lamina of internal oblique because it is derived from the external oblique stratum that lies ventral to the internal oblique stratum (Rizk et al., 1982). Transversus abdominis muscle on the other hand assumes a position posterior to the deep lamina of internal oblique as it is derived from the internal oblique stratum (Skandalakis et al., 1997).

Yang et al, (2012) found that after the physiological umbilical hernia had resolved, the dorsal sheath seemed to secondarily disappear below the umbilicus along the inferior epigastric artery. They considered changes in mechanical stress after hernia resolution seemed to induce this disappearance. These observations together with those of Niikura et al (2008) suggest that the dorsal sheath below the umbilicus completely disappears by 25 weeks of gestation. At the stage

just after the herniated gut returned, the linea alba began to develop as a transversely directed fibrous tissue. Thus, resolution of the hernia could be an important accelerating factor in the differentiation of connective tissues in the anterior midline area, albeit only one of a few factors. Rizk's bilaminar sheaths, as well as his proposed digastric configuration of the abdominal muscles including the differentiation of the bilaminar and decussating collagen fibers in the rectus sheath is believed to have resulted from functional adaptation to mechanical demands during trunk muscle function after birth. The bilaminar theory is suggested to have provided a better biomechanical model for the adult rectus sheath as an intermediate tendon of the bilateral abdominal wall muscles.

The morphology of the adult fibrous ventral abdominal wall cannot be fully explained by its embryology. As observed by other workers, VRS is firmly attached to RA while the DRS is not (William et al., 1995; Sinnatamby, 2000). The maturation of the rectus sheath could be influenced by the mechanical activities of the muscles of the anterior abdominal wall. To date, no microscopic work has been done on animals like the goat and the baboon to show adaptations of the rectus sheath to posture and intraabdominal pressures.

1.2.2.3 Histology of the deep fascia

The deep fascia is responsible for shrouding and separating nerves and vessels, strengthening ligaments, and binding structures together into compact masses. The thickness and strength of the fascia at each location corresponds to forces generated by the surrounding muscles.

Deep fascia is a connective membrane nearly devoid of fat, and is composed of autonomous fibrous planes that aid in muscle contractions. The high density of collagen fibers is what gives the deep fascia its strength and integrity. The amount of elastin fiber determines how much extensibility and resilience it will have (Schleip et al., 2012). It has the following critical functions

namely :- It acts like an anatomical "girdle" to bind and hold muscles together in a compact manner; It maintains the proper position of the individual muscle fibers, blood vessels, and nerves within the muscles, and prevents them from moving all over the place during movement or muscle contraction; It helps prevent injury by evenly distributing forces and loads for uniform transmission of these forces and loads over the whole muscle; It creates a uniformly smooth / slick surface that essentially lubricates the various tissues that come in contact with each other during movement. This helps to prevent friction injuries and subsequent tissue degeneration and degradation. It allows muscles to change shape as they are both stretched and shortened (contracted).

The tunica flava abdominis has been described in animals as an extensive sheet of elastic tissue that helps to support the abdomen. It is mentioned as being conspicuous in large animals as a yellow corset and is a modified part of the deep fascia and aponeurosis of the external oblique muscle (Studdert et al., 2011). However, there is no published study that has been done on the deep fascia of animals like the goat and the baboon to show its adaptations to posture and intraabdominal pressures.

1.2.3 Biomechanical properties of the fibrous ventral abdominal wall

The mechanical action of the fibrous ventral abdominal wall has been studied in humans (Ozdogan et al., 2006; Rath and Chevrel, 1997; Pans et al., 1999; Hollinsky and Sandberg, 2006) and in the pig (Acostasantamaria., 2015). The resistance of the anterolateral abdominal aponeuroses is important when planning the surgical repair of incisional hernias (Rath and Chevrel, 1997). It also provides relevant data for mathematical modelling and model tissue engineering on collagen tissue herniation (Kureshi et al., 2008).

Other biomechanical studies done in humans have shown that the LA has elastic properties (Kirker-Head et al., 1989, Rath et al., 1996). Further, this mechanical elasticity of the LA varies topographically such that the hypogastric part exhibits a higher elastic coefficient (Rath et al., 1996). Studies have shown that the tensile strength of the LA is directly proportional to its thickness and density (Korenkov et al., 2001). In vivo biodynamic properties of the intact equine linea alba has been found to show regional variations such that the hypogastric linea alba experienced greater stress than the epigastric linea alba (Kirker-Head et al., 1989).

Using a structural model built within the framework of non-linear soft damage of the ventral rectus sheath, data from Grässel et al (2005) showed that when the linea alba is exposed to increasing force in the longitudinal, transverse and oblique direction, compliance was highest in the longitudinal direction and least in the transverse direction. They further showed that the hypogastric region exhibited a coefficient of elasticity greater than that of the epigastric portion. In the female, the compliance of the hypogastric part was found to be significantly smaller in the transverse than in the oblique direction. This compliance in the transverse direction was also found to be smaller in women than in men (Grässel et al., 2005).

Minimal one-dimensional tensile testing of human abdominal fascia has been conducted by other workers in order to examine the viscoelasticity, non-linearity, and anisotropy of the tissue (Kirilovam et al., 2009). The viscoelasticity of abdominal wall fascia is further supported by the varied elastic moduli and ultimate tensile stresses (UTS). Samples running parallel to the collagenous fibres exhibited a greater elastic modulus and UTS than those running perpendicular to the fibres (Kirilovam et al., 2009).

In the toe region of the stress-strain curves, the viscoelastic nature of fascia was evident, a behavior which can be attributed to collagen fiber bundles located within the tissue (Kirilovam et al., 2009). Microscopic examination showed that the structural components of collagen and elastin began to align in the direction of the applied load, and produced stress-strain graphs demonstrated as a viscoelastic response. This allowed for some initial stretch in the tissue, a quantity that increases as the elastin begins to linear-elastically deform and collagen bundles continue to expand further until failure (Kirilovam et al., 2009).

A study of the biomechanics of the superficial fascia showed a failure load of 102.6 ± 74.4 N whereas when the dermis and fascia were evaluated as a single unit, the value for failure load increased to 401.4 ± 44.9 N (Song, 2004). While previous research has been able to gather mechanical data for yield strength and ultimate tensile strength, the data is greatly varied between studies, indicating a lack of a consensus about the mechanical properties of the superficial fascia.

The surrounding rectus sheath, formed by fibers from the external and internal obliques and the transversus abdominis, encloses each portion of the rectus abdominis. It is further joined by the fascia and other connective tissues in the lower third. The combination of the rectus abdominis with the sheath can withstand up to 180N of force applied in a transverse direction, and requires sutures that retain high tensile strength when surgeries are performed (Carriquiry, 1996).

Tensile properties of connective tissues of the abdominal wall are necessary to better analyze the mechanical response of the abdominal wall. Though tensile properties of these tissues have been reported in humans and the porcine, data is still missing regarding the directional loading rates in other animals such as the baboon and the goat.

1.2.4 Clinical significance

Access to the peritoneal cavity takes into account the composition of the abdominal wall as well as the neurovascular structures within it. Most incisions are made through the linea alba since it is relatively avascular and provides extensive exposure (April, 1997). However, these midline incisions predispose to incisional herniae, a well-known post-surgical complication (Gibson et al., 1989).

Incisional herniae are one of the commonest postoperative complications of laparotomy in humans (Bucknall et al., 1982; Korenkov et al., 2001). The incidence is between 1% and 11% in humans and as great as 16% in large animals, depending on the surgical approach to the abdomen. Flank laparotomy approach has hence been associated with a higher incidence of wound dehiscence than midventral approach. Mid ventral was reported to be superior and proper attention to technical detail when suturing the rectus has been reported to be critical in preventing wound dehiscence (Slatter D, 2003; Abubakar et al., 2014).

In a study regarding the aetiological factors concerned in the production of paraumbilical and epigastric hernias, Askar (1978) demonstrated a positive relation between the aponeurotic pattern and herniation of paraumbilical or epigastric hernias. The incidence of epigastric hernias in men was suggested to be due to straining and coughing. In women, abdominal distension due to pregnancy and obesity were the commonest causes for paraumbilical herniation. It has also been observed in humans, that epigastric herniae occurred almost exclusively in patients who had a single midline pattern of decussating collagen fibres in the LA compared to those with the more secure digastric aponeurotic pattern of decussation (Axer et al., 2001a).

Patients with a wide LA, often referred to by some authors to having a “sick linea alba complex”, are prone to developing ventral hernias (Naraynsingh et al., 2012). Ruminants like the goat, have a stomach volume which is capable of consuming and accommodating large quantities of relatively indigestible forages causing marked abdominal distension. However, the abdominal wall of a goat is relatively thin and hence muscle tearing and separation often occur from blunt trauma during shearing, fighting or crowding through narrow doorways (Gohar et al., 1987; Abdin-Bey and Ramadan., 2001). All these make the fibrous abdominal wall of the goat easily predisposed to developing rectus diastases or even hernia (Yami and Merkel, 2013).

Inguinal hernias have been reported in non-human primates (Chaffee et al., 1973; Warren et al., 1979; Carpenter et al., 1980). Whereas rectus abdominis diastasis (Bursch, 1987; Hsia and Jones, 2000) and ventral herniae are common in humans and quadrupeds, there are no reports of their existence in non-human primates (Fitzgibbons et al., 2002; Brengio et al., 2003).

1.3 Study design

A cross-sectional descriptive, histological, morphometric and biomechanical research study.

1.4 Objectives of the study

1.4.1 Broad objective:

To study the histomorphological organization and tensiometry of the fibrous ventral abdominal wall in the baboon and the goat.

1.4.2 Specific objectives:

1. To describe the morphology and histological organization of the fibrous ventral abdominal wall in the baboon and the goat.
2. To determine the thickness of the different laminae of the fibrous ventral abdominal wall in the baboon and the goat.
3. To determine the tensiometric characteristics of the epigastric, umbilical and hypogastric regions of the fibrous ventral abdominal wall in the baboon and the goat.

CHAPTER TWO

2.0 MATERIALS AND METHODS

2.1 Experimental Animals (The baboon and the goat)

2.1.1 The baboon and goat as a study model

The advantage of using the olive baboon is that they are now considered as terrestrial bipedal walkers as a locomotor mode in itself and not a random pattern. They have been observed to walk in a constant and well-coordinated manner, with flexed hips and knees, slightly bent trunk, albeit with some peculiarities in the type of foot contact to the ground and in forelimb posture and motion (Berillon et al., 2013; D'Aout et al., 2014). While the use of quadrupeds, such as the goat, as models for human abdominal impact response biomechanical research is well documented (Huelke et al., 1986).

2.1.2 Harvesting and tissue sampling of the FVAW

The ventral abdominal wall was harvested from seven (7) healthy male baboons (*Papio anubis*) (weight range 10-13kg), 1- 2year old, obtained from the Institute of Primate Research, Kenya (Fig 1) and six (6) male goats (*Capra hircus*) (Fig 2) procured from the animal slaughter market. The baboons were sedated with KETAMINE HCl (10 mg/kg, vetelar, parnke Davies co., ponypool Germany) and XYLAZINE (10 MG/KG, ILIUM XYLAZIL^R, Troy lab Pty limited, Smithfield, Australia) IP/IM and then euthanized with 20% pentobarbitone sodium (80mg/ kg body weight).

Figure 1. Photograph of a 2 year old olive baboon. (*Papio anubis*)



Figure 2. Photograph of a 12 month old domestic goat (*Capra hircus*)



The skin and the fat were incised via a midline abdominal incision to form skin flaps that exposed the ventral abdominal wall aponeuroses with its deep fascia intact. Thereafter, the FVAW was removed from the animals and the tissues for tensiometry immediately immersed in phosphate buffered saline while the rest were immersed in 10% formaldehyde solution. Animals with abdominal wall scars, overt abdominal pathology or those which were more than 1 hour post mortem were excluded from the study.

Using the xiphoid process, the umbilicus, and the pubic tubercle as landmarks, pieces of tissue were resected from the linea alba using a metal template (40mm x 20mm) from the mid-epigastric, the umbilical and hypogastric levels of the linea alba just above the arcuate line. Similarly tissues were also resected from the middle part of the rectus sheath about 2 to 2.5cm from the midpoint of LA, at the same level as the linea alba resections (Fig 3, 4).

Legends for figures 3 and 4

Figure 3 - Photomacrograph of the ventral abdominal wall of an 18 month old olive baboon *Papio Anubis* showing the linea alba, a few relevant landmarks. Blue pinhead - the xiphoid process (XP); ELA- Epigastric linea alba; Red pinhead- Umbilical linea alba- (ULA); HLA- Hypogastric linea alba; Green pinhead- the pubic symphysis (PS); VRS- Ventral wall of the rectus sheath; RM- Rectus abdominis muscle; EOM- External oblique abdominis muscle.

Figure 4 - Photomacrograph of the ventral abdominal wall of a 2-year old goat (*Capra hircus*) showing the linea alba, a few relevant landmarks. Blue pinhead - the xiphoid process (XP); ELA- Epigastric linea alba; Red pinhead- Umbilical linea alba- (ULA); HLA- Hypogastric linea alba; Green pinhead- the pubic symphysis (PS); VRS- Ventral wall of the rectus sheath; RM- Rectus abdominis muscle; EOM- External oblique abdominis muscle.

Figure 3 Photomicrograph of the ventral abdominal wall of the baboon.


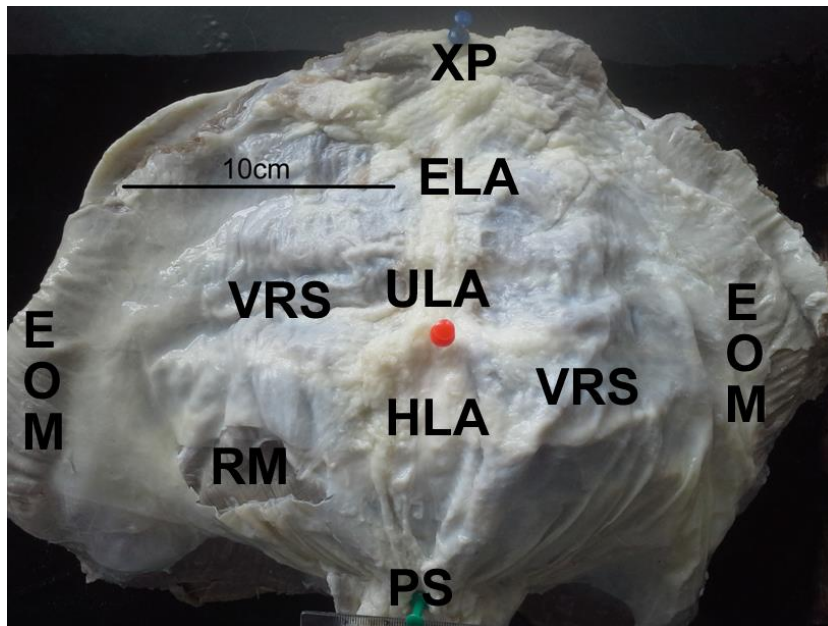


Figure 4 Photomicrograph of the ventral abdominal wall of the goat.



2.3 Light microscopy of each of the tissues sampled

A transverse section (20mm x 10mm) was fixed in 10% formol-saline. Thereafter, the sections were trimmed and processed for paraffin embedding by passing them through increasing concentrations of alcohol at 10% increments, xylene 100% each for one hour and cleared with cedar wood oil for 12 hours. The sections were then embedded in fresh molten paraplast wax for 12 hours. Seven micrometer (7micrometre) sections were cut from paraffin blocks using a LEITZ WETZLAR sledge microtome (Leica^R Model SM2400, Leica Microsystems, Nussloch GmbH, Germany), floated in water at 37⁰c, then stuck onto glass slides using egg albumin, applied as a thin film. Fifty six sections from each region (making a total of 168 sections) were selected for histomorphometry. The slides were dried in an oven at 37⁰c for 16-24 hours, then stained with the Weigert resorcin – fuchsin stain and counterstained with Van Gieson stain for demonstration of elastic fibres (Drury et al 1967). The sections were examined under a Leica Light microscope (BME model, Germany) at various magnifications x 40; x 100; x 400 and x 1000. Photomicrographs were taken using ZeissTM digital photomicroscope (Carl Zeiss AG, Oborkochen, Germany).

2.4 Morphometric analysis of the laminae

The Photomicrographs of the fifty six sections showing the different laminae were transferred to a computer installed with ImageJ-Fiji software for morphometric. ImageJ is open source software which has an inbuilt morphometric and stereological tools for analyzing images (Schneider et al., 2012). The thickness of laminae for each region (ie epigastric, umbilical and

hypogastric) for the LA, VRS and DRS were measured in millimetres and the ratios plotted on bar graphs.

2.5 Biomechanical testing of the fibrous ventral abdominal wall

2.5.1 Sampling of the test specimens

All mechanical tests were done according to Seifert et al (2012). Tissue strips of 30mm x 20mm which were fresh from four (4) different baboons and four (4) different goats were kept in phosphate buffered saline before exposure to mechanical testing. The specimens, which had a rectangular shape, were carefully prepared so as to avoid causing any damage to the test sample. They were collected in three orthogonal directions. Specimens cut parallel to the linea alba were denoted as *L* (longitudinal) in this study, while the direction parallel to the direction of oblique muscles were denoted as *O* (oblique) while those perpendicular to the linea alba were named as *T* (transverse).

For each animal, a total of 60 samples were tested out of which only 44 were validated and included in the study (Table 1). Tissue width (mm) and thickness (mm) at the waist (around the middle third of the tissue between the clamps) were measured using a vernier caliper before loading was started. The distance between each clamp was standardized at 12 mm. The width ranged from 13mm to 23 mm.

Legends for Table 1

Table 1 – The table showing the number of samples exposed to each of the 3 different tractional force directions in the baboon and the goat. Note that oblique and transverse traction were difficult to perform in areas where the linea alba was thin.

Table 1 Table showing the number of samples exposed to each of the 3 different tractional force directions in the baboon and the goat.

		Baboon		Goat	
Direction of traction forces					
Longitudinal		10		7	
Oblique		9		7	
Transverse		7		4	

2.5.2 Tensiometric measurements of the baboon and goat samples

The ends of the tissue samples were wrapped with pieces of sandpaper before being placed into customized clamps designed with teeth to grip the ends of the tissue samples as shown in Fig. 5, 6. The sandpaper promotes friction with the metal screw clamp, while staying in contact with the tissue sample. To ensure that no sliding occurred during the tests all the mechanical tests were visually validated by 2 other researchers. The clamps were fixed to the crosshead and base of a materials testing machine Hounsfield tensometer (80035; Pesola, Baar, AG Switzerland). The strain, load to failure (N), ultimate tensile strength (N/mm²) and coefficient of elasticity (N/mm²) were then determined.

Load to failure was determined by placing the tissue in a bidirectional strain along its long axis, at an elongation rate of 20 mm/min. Each test took on average 2 to 4 minutes to complete. Force (N) and displacement (mm) were measured on a xy plotter, and these points were

subsequently recorded as stress (force per cross sectional area) and strain (fractional change in length) and replotted in Microsoft Excel (Microsoft Office Professional 2013). Ultimate tensile strength was defined as the maximum obtained load at the failure point of the tissue samples per area squared of the tissue waist. In this study, ultimate tensile strength and yield point were interchangeable. For each tissue specimen, stiffness (Young's modulus) or coefficient of elasticity was calculated by determining the slope of a line that fit the most linear portion of the stress-strain curve. Young's modulus is the gradient of the stress-strain graph for the region that obeys Hooke's law.

$$\text{Young's modulus} = \text{Stress} / \text{strain}$$

When a sample tore or ruptured outside the measured area (outside the waist), the result was excluded from the analysis. The mean stress – strain curves were then plotted in a graph to compare the three regions examined. Some of the tissues were not amenable to certain traction forces. This was seen in the baboon linea alba where transverse traction could not be performed and the goat dorsal rectus sheath which was too thin. No prior preconditioning was done on the tissues. The tissues were kept wet throughout the tests.

Legends for figures 5 and 6

Figure 5 - Photomacrograph showing a tissue sample (blue arrows) being stretched by the tensiometer.

Figure 6 - Photomacrograph showing the waist of the tissue being formed at the beginning of the tensile experiment (A) while (B) illustrates the tissue being torn across the fracture plane at its waist after it reached its ultimate tensile strength breaking point at the end of the process (arrows).

Figure 5:- Photograph of the Hounsfield tensiometer used in the study.





Figure 6:- Photographs showing a tissue sample being stretched to its ultimate tensile strength by the tensiometer.



2.6 Statistical analysis of the fibrous ventral abdominal wall parameters

Data collected were entered into the Statistical Package for Social Sciences software (Version 17.0, Chicago, Illinois) for coding, tabulation and statistical analysis. Comparison between the laminae (superficial, intermediate and deep) and the 3 regions (epigastric, umbilical and hypogastric) were made for the LA, the VRS and the DRS. The data was non-parametric and hence the Kruskal Wallis test was used to compare the means. The advantage of using this test is that it does not assume a normal distribution, unlike the one- way analysis of variance (the parametric equivalent).

2.7 Ethical considerations for use of the animals

Statement of Justification for animal invasive procedure

The goats were procured from a local butchery immediately after slaughter. The tissues from the baboon were obtained from animals sacrificed at the end of experiments at the Institute of Primate Research (IPR). These animals were used by researchers at IPR to investigate preclinical drugs on various parasites harmful to humans using the baboon as a model. The study protocols followed by the researchers at IPR were approved by the Institutional Scientific Evaluation and Review Committee (ISERC) and the Animal Care and Use Committee of the Institute of Primate Research.

CHAPTER THREE

3.0 RESULTS

3.1 Histomorphology and tensiometric characteristics of the baboon fibrous ventral abdominal wall

3.1.1 Morphology of the baboon fibrous ventral abdominal wall

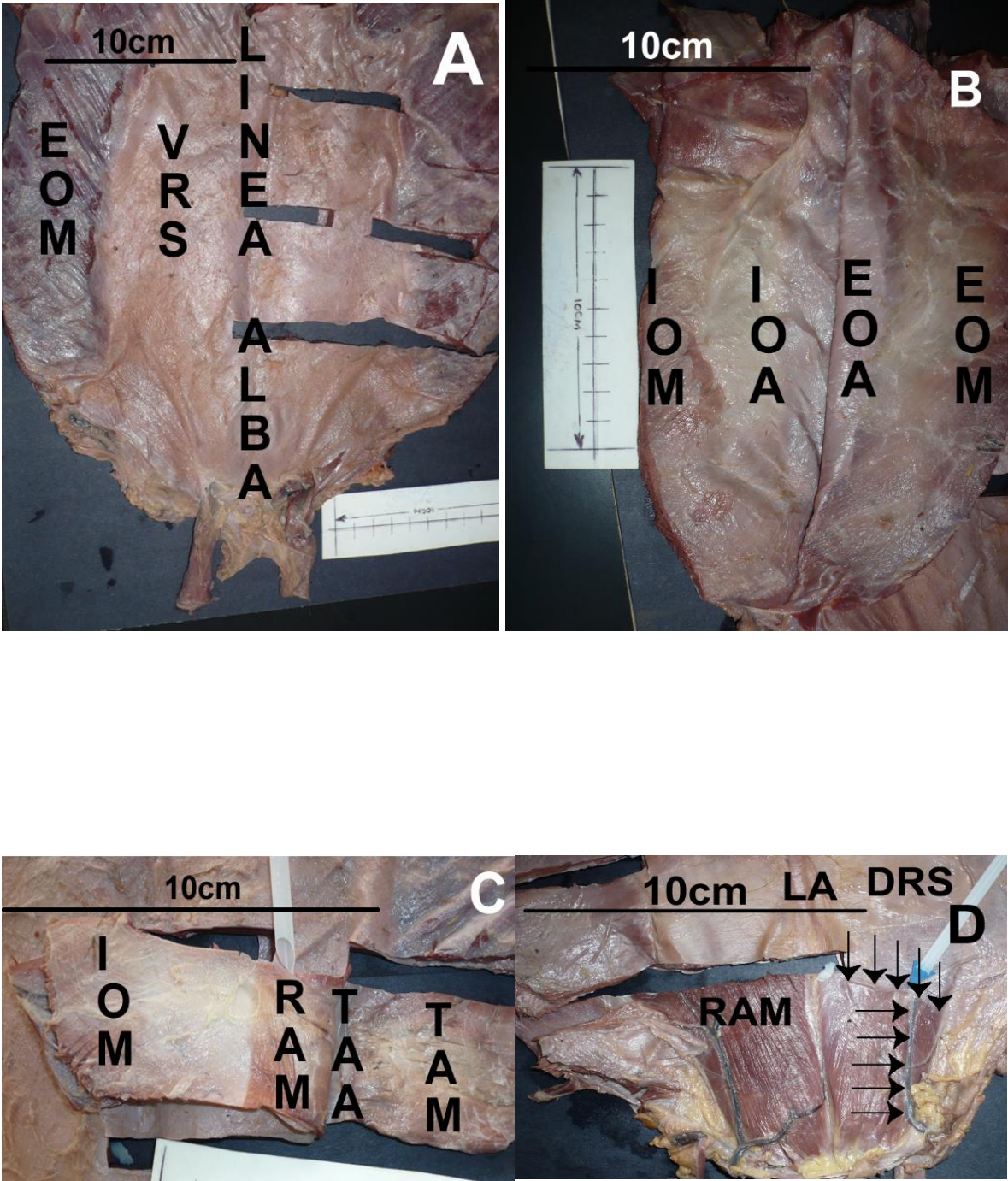
The rectus abdominis, which extended from the manubrium sternum to the pubic symphysis, was ensheathed by the aponeuroses of the three flat abdominal muscles namely the transversus abdominis, the external and internal oblique abdominis muscles. The aponeuroses of the external and internal oblique abdominis muscles passed ventral to the rectus throughout its extent (Fig 7A, B, C).

The aponeurosis of the transversus muscle (Fig 7C, D) formed the dorsal rectus sheath and then passed ventrally to join the aponeuroses of the external and internal oblique at the linea alba at the arcuate line. From this line caudally the dorsal wall of the rectus abdominis was lined by the fascia transversalis (Fig 7D).

Legends for Figure 7

- Figure 7A Photomacrograph of the ventral abdominal wall showing external oblique abdominis muscle (EOM) forming the external oblique aponeurosis which in turn partly forms the ventral rectus sheath (VRS) and the linea alba. Note that the umbilical and the hypogastric VRS are less than 10cm.
- Figure 7B Photomacrograph of the ventral abdominal wall showing the external oblique abdominis muscle (EOM) and internal oblique abdominis muscle (IOM) forming the external oblique aponeurosis (EOA) and internal oblique aponeurosis (IOA) respectively. The aponeuroses in turn formed the ventral rectus sheath. Note that the EOA has been reflected to the right.
- Figure 7C Photomacrograph of the ventral abdominal wall showing the muscle fibres of the transversus abdominis muscle (TAM) forming the transversus abdominal aponeurosis (TAA) and the longitudinally aligned fibres of the rectus abdominis muscle (RAM). Note the internal oblique abdominis muscle (IOM) reflected to the left.
- Figure 7D Photomacrograph of the ventral abdominal wall showing the dorsal rectus sheath (DRS) lying dorsal to the rectus abdominis muscle (RAM). The latter lie on either side of the linea alba (LA). Note the inferior epigastric artery (horizontal arrows) crossing the arcuate line (vertical arrows). The line marks the caudal end of the dorsal rectus sheath.

Figure 7. Photomicrographs of parts of the baboon fibrous ventral abdominal wall



3.1.2 Histology of the baboon fibrous abdominal wall

3.1.2.1 Histology of the baboon linea alba

The epigastric, the umbilical and the hypogastric linea alba contained mainly collagen and elastic fibres. The collagen fibres were organized into three laminae namely, a superficial, an intermediate and a deep one which are named in relation to the skin. (Fig.8A - C).

The superficial lamina of the epigastrium was made up of predominantly longitudinally arranged collagen bundles. The intermediate lamina consisted of an admixture of thick longitudinal and oblique collagen fibres (Fig.8A). While the deep lamina consisted of mainly obliquely aligned collagen bundles. This lamina was lined ventrally by fine elastic fibres in the deep fascia and dorsally by distinct longitudinally aligned elastic fibres. (Fig.8D).The deep fascia was thin and hardly discernible in most areas.

Caudally, around the umbilicus, all the laminae had prominent collagen bundles. The bundles were mainly oriented in a transverse direction especially in the deep and superficial lamina. These were thicker towards the midline at the centre of the umbilicus, and appeared to fuse into a thick mass (Fig.8B). The collagen bundles contained fine elastic fibres embedded within it (Fig.8E).

The three laminae of the hypogastrium consisted of predominantly longitudinally aligned collagen fibres. There were a few obliquely collagen fibres found in the deep lamina and some of these became oriented in a transverse direction laterally. Adipose tissue was also prominent in the deep lamina. The superficial and intermediate laminae had thick collagen bundles while the deep lamina had thinner bundles. (Fig.8C).The longitudinally aligned fine elastic fibres were seen mainly lining the dorsal part of the deep lamina (Fig.8F).

Legends for Figure 8

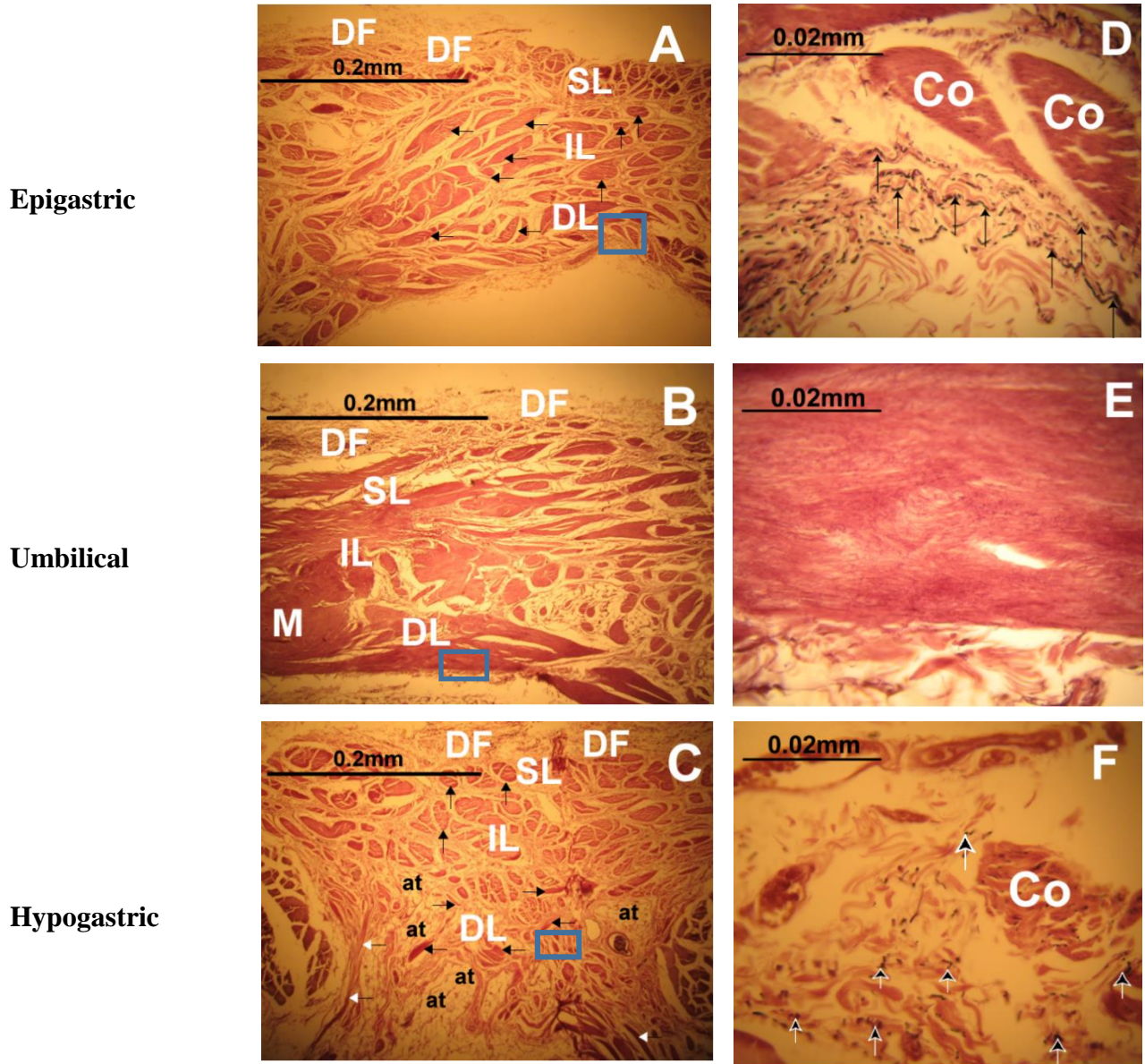
Figures 8(A-C)-Photomicrographs of a transverse section of the epigastric, umbilical and hypogastric linea alba illustrating the deep fascia (DF) lying ventrally and the three characteristic laminae of the linea alba namely, the superficial (SL), intermediate (IL) and deep (DL). The epigastric part consisted of longitudinal (vertical black arrows) and oblique collagen bundles (horizontal black arrows). The umbilical part showed collagen bundles in the intermediate (I) and deep (D) laminae fusing to form a midline mass (M). The hypogastric part comprised of longitudinal (vertical black arrows), oblique collagen bundles (horizontal black arrows) and transversely aligned collagen bundles (horizontal white arrows). Note the adipose tissue (at) in the deep lamina.

Figure 8D A high magnification photomicrograph of the epigastric linea alba showing the thin edge of longitudinally elastic fibres (arrows) found lying dorsal to the collagen bundles (Co) in the deep laminae.

Figure 8E A high magnification photomicrograph of the umbilical linea alba showing the fine dark elastic fibres (purplish) embedded in the collagen bundles in the deep lamina.

Figure 8F A high magnification photomicrograph of the hypogastric part of the linea alba showing the fine collagen (Co) and elastic fibres (black arrows) arranged in an irregular manner in the deep lamina of the hypogastric linea alba.

Figure 8. Photomicrographs of a transverse section of the three regions in the baboon linea alba.



3.1.2.2 Histology of the baboon ventral rectus sheath

Laterally, the ventral rectus sheath had collagen fibres organized into two laminae namely a superficial lamina and a deep lamina in relation to the deep fascia lying ventral to it (Fig.9A - C). The epigastric ventral rectus sheath, consisted of obliquely oriented collagen fibres impregnated with elastic fibres while the deep fascia had a few distinct elastic fibres (Fig.9 D).

The umbilical VRS was made up of rows of obliquely oriented collagen fibres (Fig 9B). The collagen fibres were lined by fine longitudinally aligned elastic fibres (Fig 9E).

The hypogastric VRS consisted of rows collagen bundles which are arranged predominantly in a crisscross oblique alignment meeting at an angle (Fig.9C). As noted in the other regions, each bundle was impregnated with fine elastic fibres (Fig.9F).

Legends for Figure 9

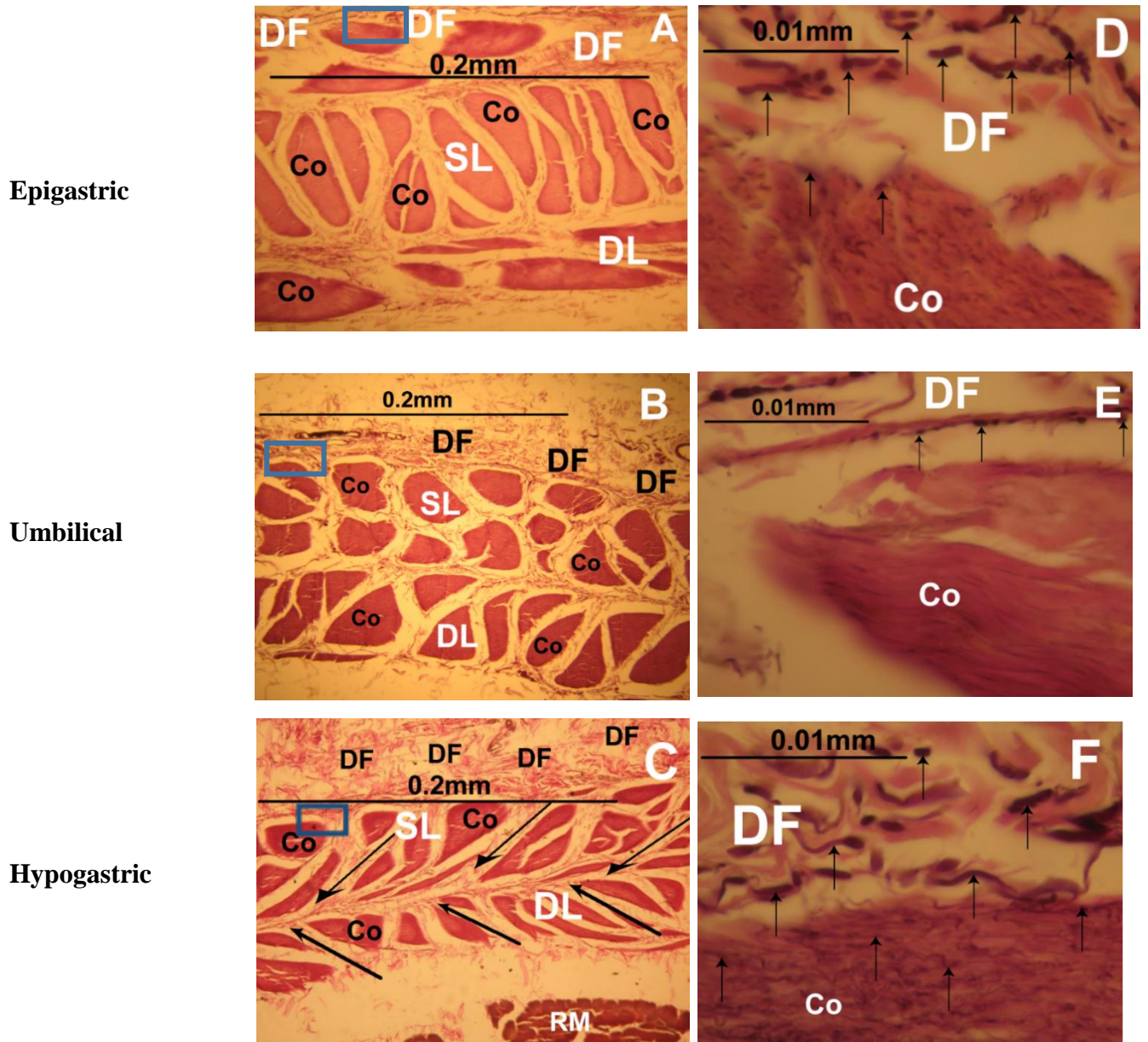
Figures 9(A-C)- Photomicrographs of a transverse section of the epigastric, umbilical and hypogastric rectus sheath illustrating the deep fascia (DF) lying ventrally and the two characteristic laminae of the ventral rectus sheath namely the superficial (SL) and deep. Note the characteristic sandwich appearance of the superficial (SL) encased by the deep fascia (DF) and the deep lamina (DL) in epigastric ventral rectus sheath, the numerous oblique collagen bundles (Co) organized in rows in the umbilical ventral rectus sheath and the crisscross arrangement (arrows) of the collagen bundles (Co) found in the hypogastric ventral rectus sheath.

Figure 9D A high magnification photomicrograph of the epigastric ventral rectus sheath showing the prominent elastic fibres (arrows) found within the deep fascia (DF) and the collagen bundles (Co) in the superficial lamina.

Figure 9E A high magnification photomicrograph of the umbilical ventral rectus sheath illustrating the black fine elastic fibres (arrows) found in the deep fascia (DF) and lining the collagen bundles (Co).

Figure 9F A high magnification photomicrograph of the hypogastric ventral rectus sheath showing the elastic fibre (arrows) infiltration of the deep fascia and the collagen bundles (Co).

Fig.9 Photomicrographs of a transverse section of the three regions in the baboon ventral rectus sheath.



3.1.2.3 Histology of the baboon dorsal rectus sheath

The epigastric, umbilical and hypogastric dorsal rectus sheath were composed of overlapping bundles of transversely oriented collagen (Fig.10A, B, C). Each collagen bundle had a heavy embedding of obliquely and transversely aligned elastic fibres (Fig.10D, E, F). A few blood vessels and elastic fibres were found scattered juxtaposed to the deep lamina. (Fig.10B).

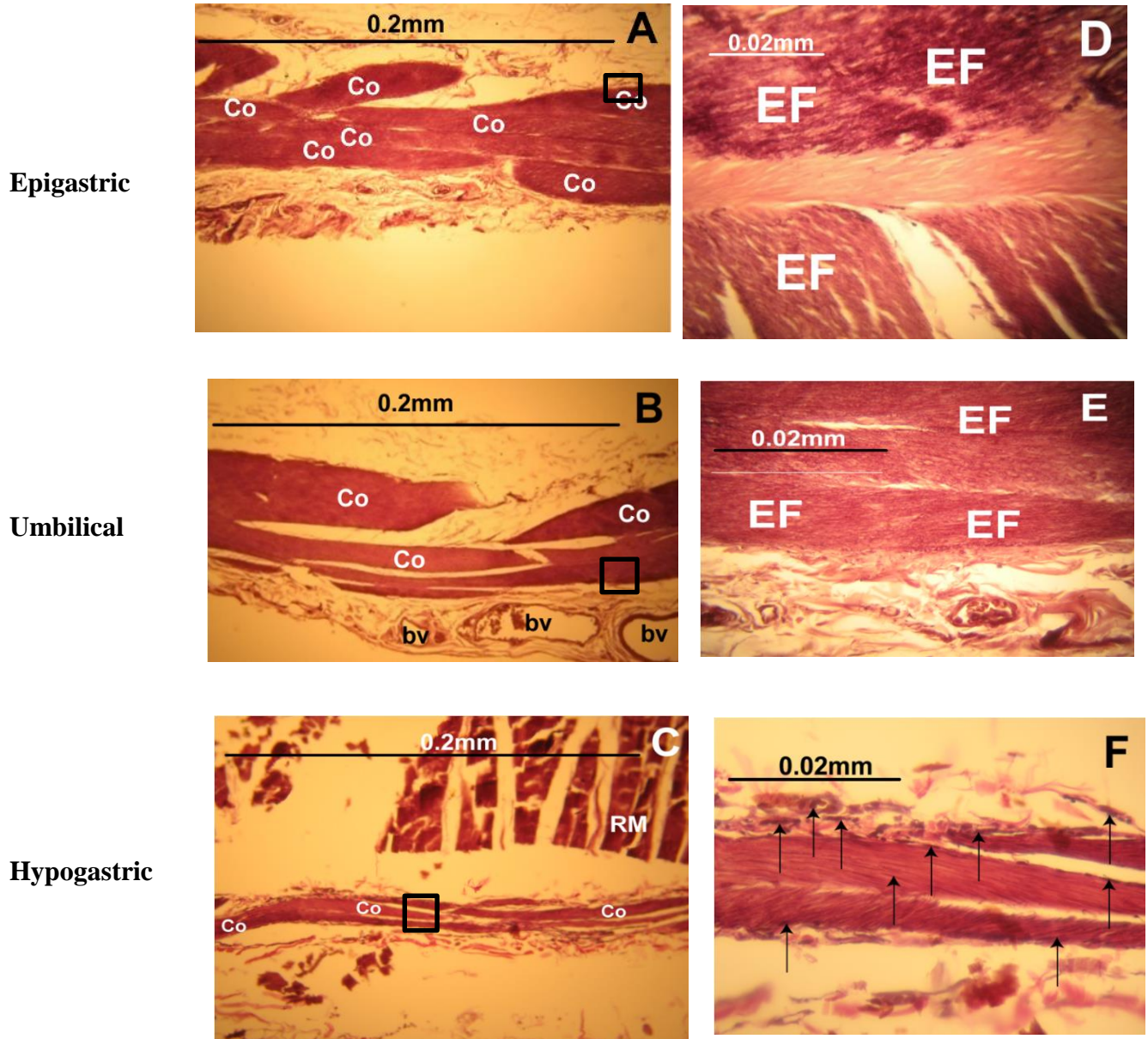
The collagen bundles in the HDRS were thinner and transversely aligned (Fig.10C). The elastic fibres embedded each collagen bundle were fewer and transversely aligned (Fig.11F).

Legends for Figure 10

Figures 10(A-C)-Photomicrographs of a transverse section of the epigastric, umbilical and hypogastric dorsal rectus sheath illustrating the characteristic overlapping transverse collagen bundles (Co). Note the blood vessels (bv) juxtaposed to the dorsal aspect of the umbilical dorsal rectus sheath.

Figures 10(D-F)-A high magnification photomicrographs of the epigastric, umbilical and hypogastric dorsal rectus sheath illustrating the dark elastic fibres (EF and arrows) embedded within the collagen bundles.

Fig.10. Photomicrographs of a transverse section of the three regions in the baboon dorsal rectus sheath.



3.1.3 Measurement of the various laminae of the baboon fibrous ventral abdominal wall

The linea alba was noted to be the thickest at the umbilical part. It measured 0.779mm at the umbilical part, 0.467mm at the epigastrium and 0.246mm at the hypogastrium (Table 2). The superficial lamina contributed about 24% and 23% of the wall section in the epigastrium and hypogastrium respectively while in the umbilical part it contributed 46% (p-0.003). (Fig.11A).

The epigastric ventral rectus sheath and the dorsal rectus sheath measured about 0.210mm and 0.139mm respectively. The umbilical VRS (0.203mm) was more than twice the size of the hypogastric VRS (0.083mm) (Fig.11B). In contrast, the umbilical DRS (0.051mm) was about the same size as the hypogastric DRS (0.052mm). (Table 2).

Legends for Figure 11 and Table 2

- Figure 11A - Bar chart showing percentage proportions of the mean measurements of the different laminae at the epigastric linea alba (ELA), umbilical linea alba (ULA) and hypogastric linea alba (HLA) regions. The deep lamina was the thinnest lamina proportionately in the umbilical region ($p=0.018$), when compared to the deep fascia and superficial lamina.
- Figure 11B - Bar chart showing percentage proportions of the mean measurements of the different laminae at the epigastric ventral rectus sheath (EVRS), umbilical ventral rectus sheath (UVRS) and hypogastric ventral rectus sheath (HVRS) regions. Note how the deep lamina was the thickest proportionately in the umbilicus when compared to the deep fascia and superficial lamina.
- Table 2 - Table showing the geometrical dimensions (mm) of the mean thickness of the linea alba, ventral and dorsal rectus sheath samples in the epigastric, umbilical and hypogastric regions. Note that the umbilical linea alba was the thickest while the umbilical DRS and hypogastric DRS were the thinnest with roughly the same values.

Figure 11. Bar charts showing percentage proportions of the mean measurements of the different laminae of the baboon.

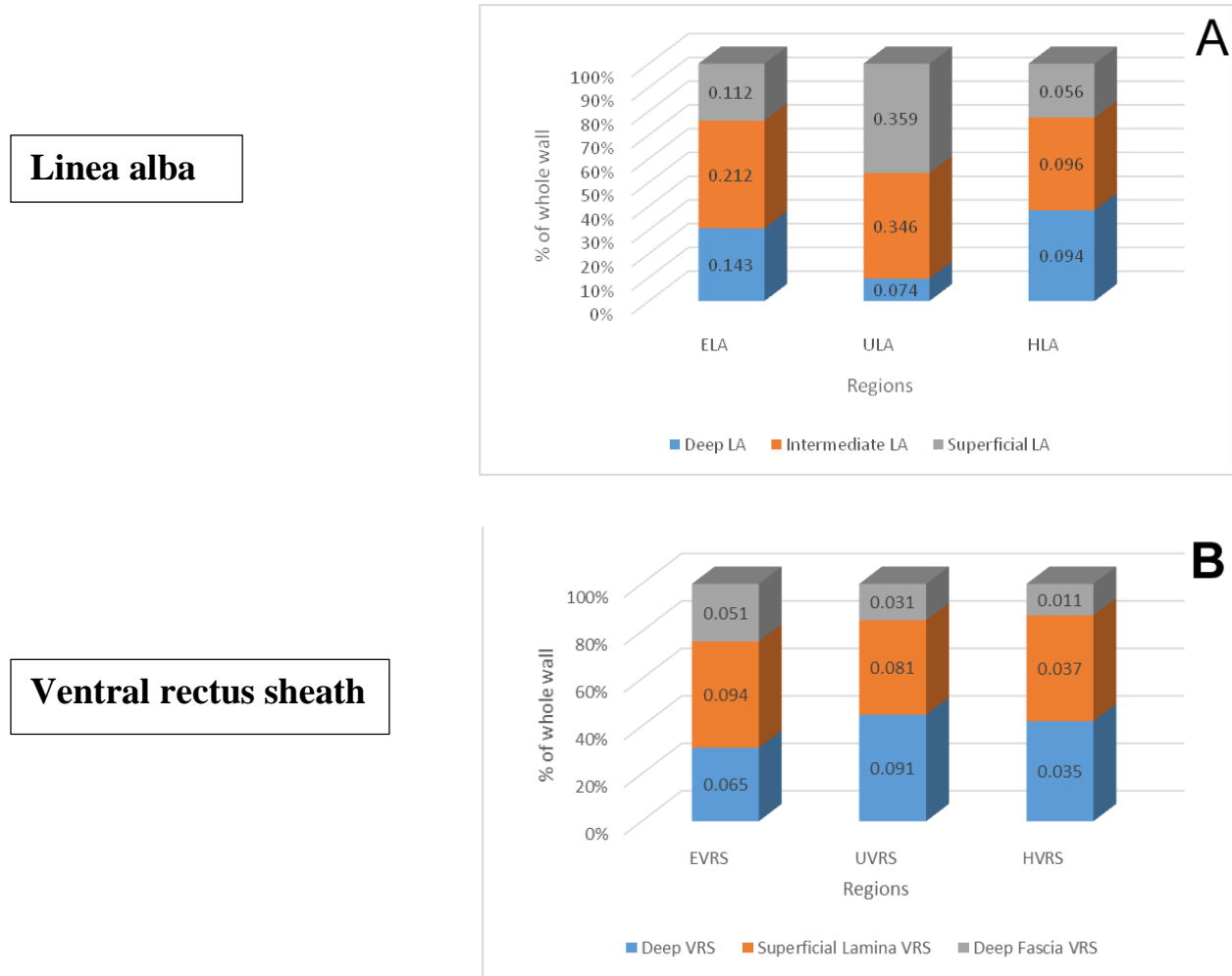


Table 2 Table showing the geometrical dimensions (mm) of the mean thickness of the fibrous ventral abdominal wall samples in three different regions in the baboon.

	Epigastrium	SD	Umbilicus	SD	Hypogastrium	SD
*Linea alba	0.467	0.073	0.779	0.064	0.246	0.052
*Ventral rectus sheath	0.210	0.028	0.203	0.031	0.083	0.016
Dorsal rectus sheath	0.139	0.012	0.051	0.001	0.052	0.018

*Inclusive of the deep fascia

3.1.4 Tensiometry of the baboon fibrous ventral abdominal wall

3.1.4.1 Tensiometry of the baboon linea alba

During longitudinal and oblique mechanical loading, the linea alba displayed the typical stress-strain curves with an elastic (Toe and linear) and a plastic region except for the epigastric and umbilical region when exposed to oblique traction (Fig 12A, B). The toe region was more easily demonstrable during longitudinal traction compared to oblique traction (Fig 12A, B).

The typical stress-strain curve seen during longitudinal loading of the linea alba did not seem to vary significantly among the 3 regions. The maximal/ultimate stress needed (load to failure) to fracture the linea alba during longitudinal traction and oblique traction was 40N/mm^2 and 63.6N/mm^2 at a strain of 0.35 and 1.19 respectively (Fig 12A, 12B). The hypogastric linea alba had a higher UTS when compared to the epigastric and umbilical linea alba (40N/mm^2 vs 32.4N/mm^2 vs 18.8N/mm^2) respectively during longitudinal traction.

The stress-strain curve seen during oblique loading of the linea alba did not seem to vary significantly among the epigastric and the umbilical linea alba. The hypogastric linea alba however, showed a typical stress-strain curves for destructive tensile testing of soft tissues. When exposed to oblique traction, the hypogastric linea alba again had a significantly higher load to failure compared to the epigastric and umbilical linea alba (63.6N/mm^2 vs 40N/mm^2 vs 23.6N/mm^2) respectively.

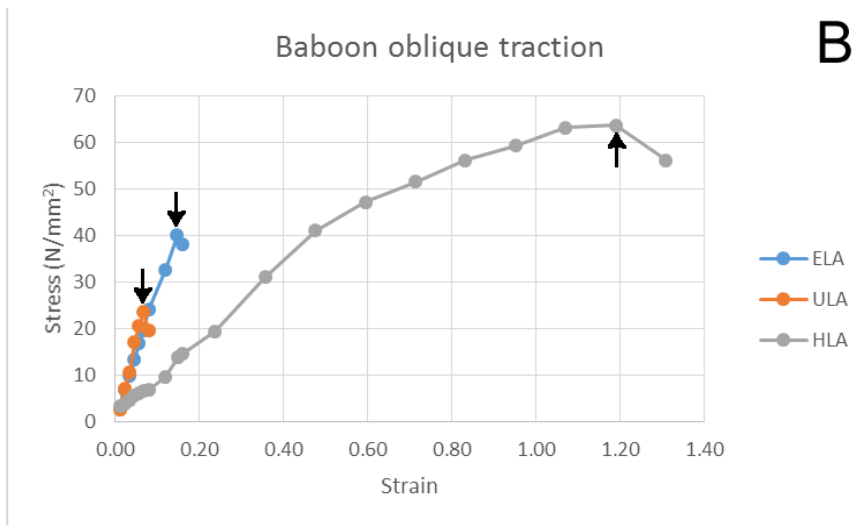
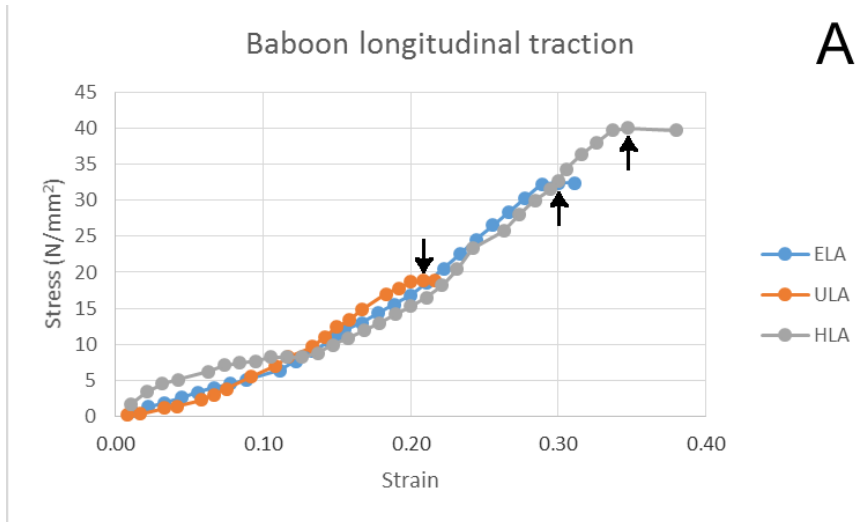
The greatest elasticity/ strain noted in the linea alba encountered was seen in the hypogastrium at 0.35 and 1.19 when it was exposed to longitudinal and oblique traction respectively at its ultimate breaking point. Regionally, the hypogastrium also exhibited the largest toe region (Fig 12A, 12B) compared to the other regions.

Legends for Figure 12

Figure 12A -Line graphs showing the longitudinal stress - strain curves on the epigastric linea alba (ELA), umbilical linea alba (ULA) and hypogastric linea alba (HLA) of the baboon. The arrows point to the ultimate tensile strength point of each part of the linea alba.

Figure 12B -Line graphs showing the oblique stress - strain curves on the epigastric linea alba (ELA), umbilical linea alba (ULA) and hypogastric linea alba (HLA) of the baboon. The arrows point to the ultimate tensile strength point of each part of the linea alba.

Figure 12. Graphs showing the stress - strain curves on the various parts of the baboon line alba



3.1.4.2 Tensiometry of the baboon ventral rectus sheath

During mechanical loading, the elastic behaviour and the plastic behaviour of the VRS was well demonstrable in all the regions when they were exposed to longitudinal, oblique or transverse traction (Fig 13A - C). In the epigastric ventral rectus sheath, the toe region was the most prominent when compared to the other regions when exposed to longitudinal traction. (Fig 13A).

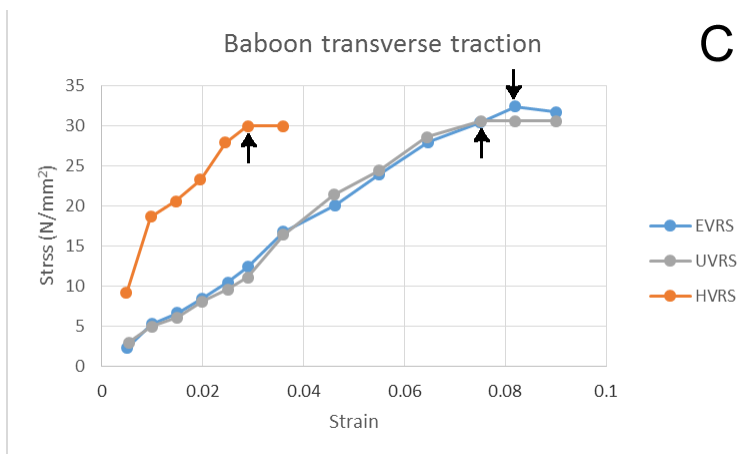
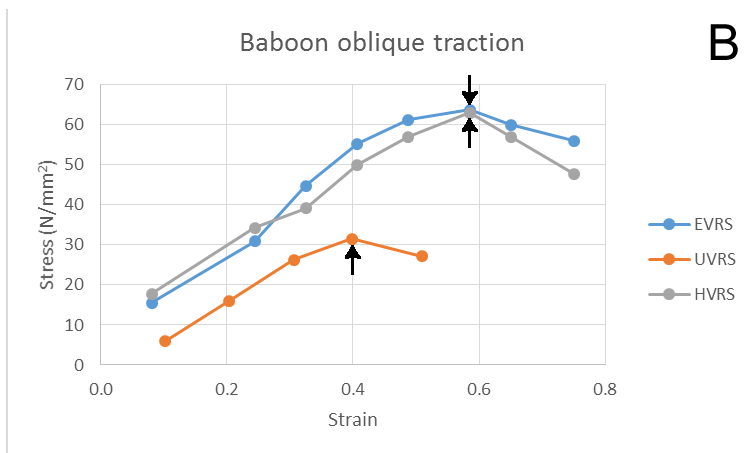
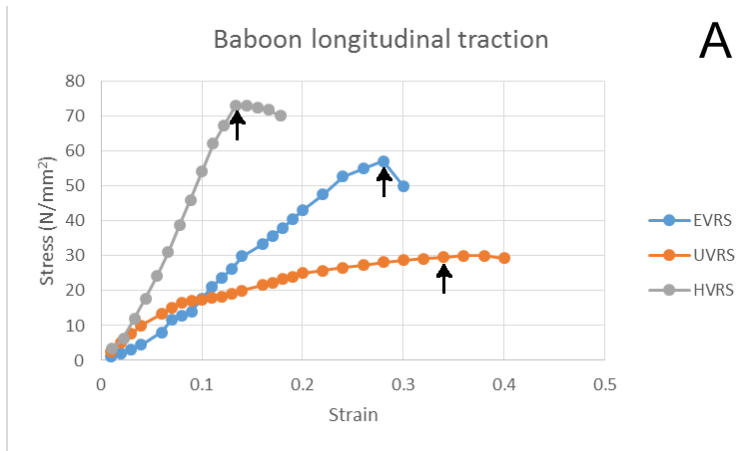
The regions of the VRS that withstood maximal/ultimate stress during longitudinal, oblique and transverse oblique traction were hypogastric VRS (73N/mm^2) and epigastric VRS (63.8N/mm^2 and 32.4N/mm^2) at a strain of 0.34, 0.6 and 0.082 respectively (Fig 13A - C).

The greatest elasticity/ strain encountered was 0.6 when umbilical and hypogastric VRS was exposed to oblique traction until their ultimate breaking point (Fig 13B). The stress-strain curve of the epigastric and hypogastric did not seem to vary significantly during oblique and transverse loading of the VRS (Fig 13B, C).

Legends for Figure 13

- Figure 13A - Line graphs showing the longitudinal stress - strain curves on the epigastric ventral rectus sheath (EVRS), umbilical ventral rectus sheath (UVRs) and hypogastric ventral rectus sheath (HVRs) of the baboon. The arrows point to the ultimate tensile strength point of each part of the ventral rectus sheath.
- Figure 13B - Line graphs showing the oblique stress - strain curves on the epigastric ventral rectus sheath (EVRS), umbilical ventral rectus sheath (UVRs) and hypogastric ventral rectus sheath (HVRs) of the baboon. The arrows point to the ultimate tensile strength point of each part of the ventral rectus sheath. Note the similar curves in the epigastric ventral rectus sheath and hypogastric ventral rectus sheath (HVRs).
- Figure 13C - Line graphs showing the transverse stress - strain curves on the epigastric ventral rectus sheath (EVRS), umbilical ventral rectus sheath (UVRs) and hypogastric ventral rectus sheath (HVRs) of the baboon. The arrows point to the ultimate tensile strength point of each part of the ventral rectus sheath. Note the similar curves in the epigastric ventral rectus sheath and umbilical ventral rectus sheath (HVRs).

Figure 13. Line graphs showing the longitudinal, oblique and transverse stress - strain curves on the various parts of the baboon ventral rectus sheath.



3.1.4.3 Tensiometry of the baboon dorsal rectus sheath

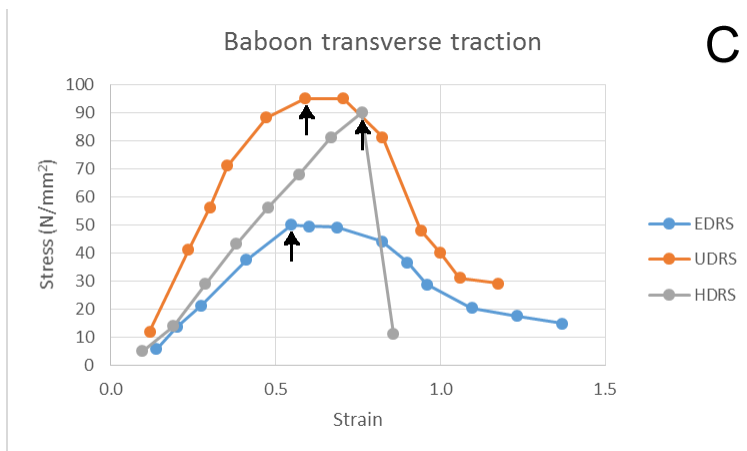
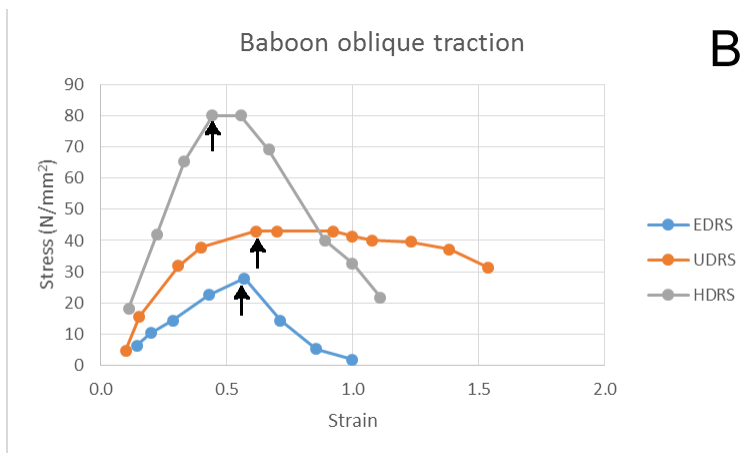
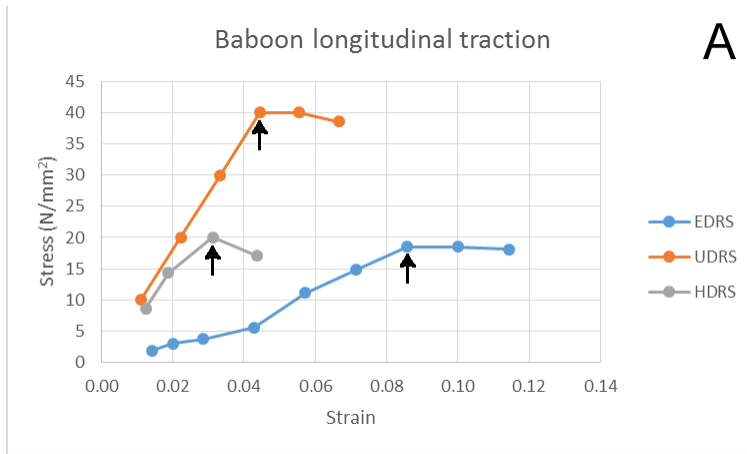
During mechanical loading, the elastic behaviour and the plastic behaviour of the VRS was well demonstrable in all the regions when they were exposed to longitudinal, oblique or transverse traction (Fig 14A - C). In the epigastric ventral rectus sheath, the toe region was the most prominent compared to the other regions when exposed to longitudinal traction. (Fig 14A).

The maximal/ultimate stress needed to fracture the DRS during longitudinal, oblique and transverse traction were 40N/mm^2 (umbilical DRS), 80N/mm^2 (hypogastric DRS), and 95N/mm^2 (umbilical DRS) at a strain of 0.04, 0.6 and 0.45 respectively(Fig 14A - C). The greatest elasticity/ strain encountered was seen in the hypogastrium at 0.8 when DRS was exposed to transverse traction at its ultimate breaking point. The epigastric DRS had uniformly the lowest load to failure point whether it was exposed to longitudinal (18.5N/mm^2), oblique (27.8N/mm^2) or transverse traction(50N/mm^2)(Fig 14C).

Legends for Figure 14

- Figure 14A - Line graphs showing the longitudinal stress - strain curves on the epigastric dorsal rectus sheath (EDRS), umbilical dorsal rectus sheath (UDRS) and hypogastric dorsal rectus sheath (HDRS) of the baboon. The arrows point to the ultimate tensile strength point of each part of the dorsal rectus sheath.
- Figure 14B - Line graphs showing the oblique stress - strain curves on the epigastric dorsal rectus sheath (EDRS), umbilical dorsal rectus sheath (UDRS) and hypogastric dorsal rectus sheath (HDRS) of the baboon. The arrows point to the ultimate tensile strength point of each part of the dorsal rectus sheath.
- Figure 14C - Line graphs showing the transverse stress - strain curves on the epigastric dorsal rectus sheath (EDRS), umbilical dorsal rectus sheath (UDRS) and hypogastric dorsal rectus sheath (HDRS) of the baboon. The arrows point to the ultimate tensile strength point of each part of the dorsal rectus sheath.

Figure 14. Line graphs showing the longitudinal, oblique and transverse stress - strain curves on the various parts of the baboon dorsal rectus sheath.



3.1.5 Coefficient of elasticity (Young's modulus) of the baboon fibrous ventral abdominal wall

The highest Young's modulus/ stiffness among the LA, VRS and the DRS was seen when they were exposed to longitudinal loading.

The linea alba's calculated Young's modulus showed that on average, the umbilical and the epigastric regions appeared about three times stiffer when exposed to oblique traction compared to longitudinal traction (Table 3). The epigastrium and umbilicus part of LA were the stiffest at 289(SD 31) N/mm² and 328(SD 7.5) N/mm² respectively when exposed to oblique traction. The hypogastric LA was the weakest at 72(SD 11) N/mm² when exposed to oblique traction (Fig 15A). The linea alba's Young's modulus did not seem to vary significantly among the three regions during longitudinal loading.

The VRS was stiffest at 753(SD 55) N/mm² when the hypogastrium was exposed to longitudinal traction. The stiffest values recorded in the epigastrium and umbilicus were 435(SD 19) N/mm² and 493(SD 7) N/mm² when they were exposed to transverse traction respectively. (Fig 15B). The umbilical VRS was the weakest at 83(SD 3) N/mm² when exposed to longitudinal traction (Fig 15A). The VRS's Young's modulus did not seem to vary significantly among the three regions during oblique and transverse loading.

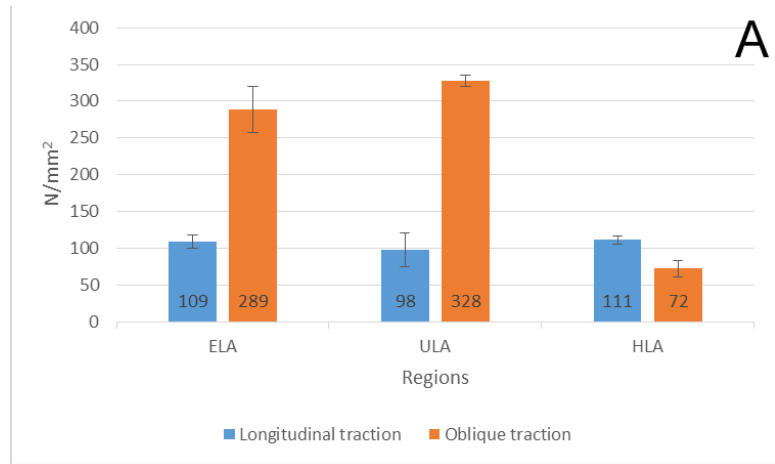
The DRS was stiffest at 1000(SD 0.1) N/mm² when the umbilicus was exposed to longitudinal traction (YM). The stiffest values recorded in the epigastrium and hypogastrium were 339(SD 32) N/mm² and 570(SD 0.1) N/mm² when they were exposed to longitudinal traction respectively (Fig 15C). The epigastric DRS was the weakest at 81.5(SD 1) N/mm² when exposed to oblique traction. The DRS's Young's modulus did not seem to vary significantly among the three regions during transverse loading.

Legends for Figure 15

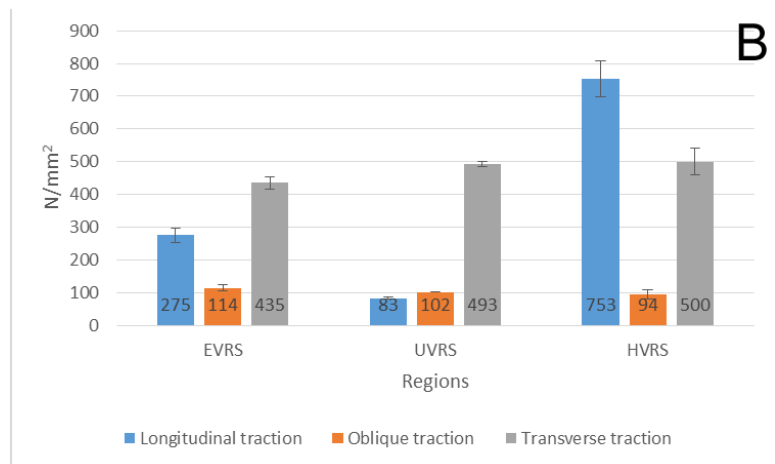
- Figure 15A - Bar chart showing coefficient of elasticity (Young's modulus) of the epigastric linea alba (ELA), umbilical linea alba (ULA) and hypogastric linea alba (HLA) of the baboon when they were exposed to various traction forces. The umbilical linea alba recorded the highest elastic coefficient (YM) at 328 N/mm^2 when exposed to oblique traction. Note that the elastic coefficient for the three regions were similar when they were exposed to longitudinal traction.
- Figure 15B - Bar chart showing coefficient of elasticity (Young's modulus) of the epigastric ventral rectus sheath (EVRS), umbilical ventral rectus sheath (UVRS) and hypogastric ventral rectus sheath (HVRS) of the baboon when they were exposed to various traction forces. The hypogastric ventral rectus sheath recorded the highest elastic coefficient (YM) at 753 N/mm^2 when exposed to longitudinal traction. Note that the elastic coefficient for the three regions were similar when they were exposed to oblique or transverse traction.
- Figure 15C - Bar chart showing coefficient of elasticity (Young's modulus) of the epigastric dorsal rectus sheath (EDRS), umbilical dorsal rectus sheath (UDRS) and hypogastric dorsal rectus sheath (HDRS) of the baboon when they were exposed to various traction forces. The umbilical dorsal rectus sheath recorded the greatest elastic coefficient at 1000 N/mm^2 when exposed to longitudinal traction. The elastic coefficient (YM) for the three regions were similar when they were exposed to oblique or transverse traction.

Figure 15. Bar charts showing coefficient of elasticity (Young's modulus) of the different regions of the baboon's fibrous abdominal wall when they were exposed to various traction forces.

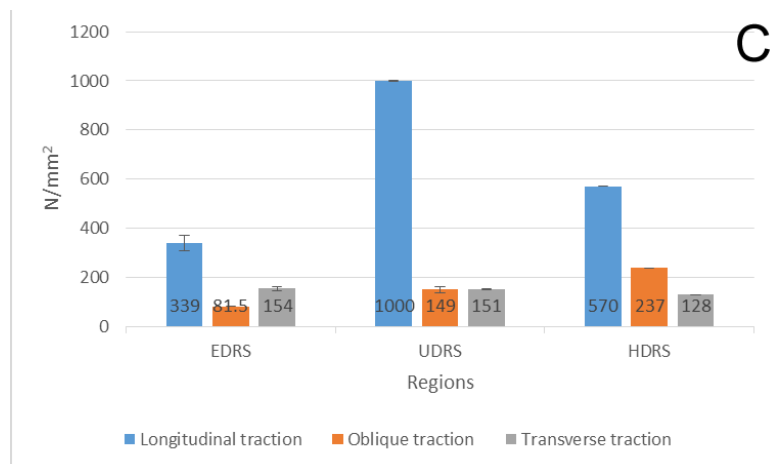
Linea alba



Ventral rectus sheath



Dorsal rectus sheath



Legend for Table 3

Table 3 -Showing the maximal forces, highest ultimate tensile strengths and highest coefficient of elasticity recorded for fibrous ventral abdominal wall in the baboon with regards to the epigastric, umbilical and hypogastric regions when they were exposed to longitudinal (L), oblique (O) and transverse(T) tractional forces. Note the highest ultimate tensile strengths and highest coefficient of elasticity was recorded at the umbilical region of the dorsal rectus sheath.

Table 3 Table showing the maximal forces, highest ultimate tensile strengths and highest coefficient of elasticity recorded for fibrous ventral abdominal wall in the baboon for the epigastric, umbilical and hypogastric regions.

Baboon			
	Tractional force N	Stress N/mm ²	YM N/mm ²
Linea alba			
epigastric	308-L	40-O	289-O
umbilical	300-L	23.6-O	328-O
hypogastric	420-O	63.6-O	111-L
Ventral rectus sheath			
epigastric	255-O	63.8-O	435-T
umbilical	145-O	31.5-O	493-T
hypogastric	146-L	73-L	753-L
Dorsal rectus sheath			
epigastric	115-T	50-T	339-L
umbilical	95-T	95-T	1000-L
hypogastric	90-T	90-T	570-L

3.2 Histomorphology and tensiometric characteristics of the goat fibrous ventral abdominal wall

3.2.1 Morphology of the goat fibrous ventral abdominal wall

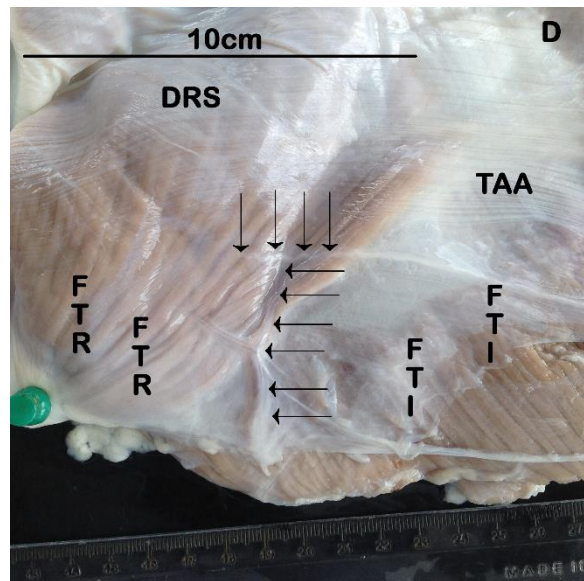
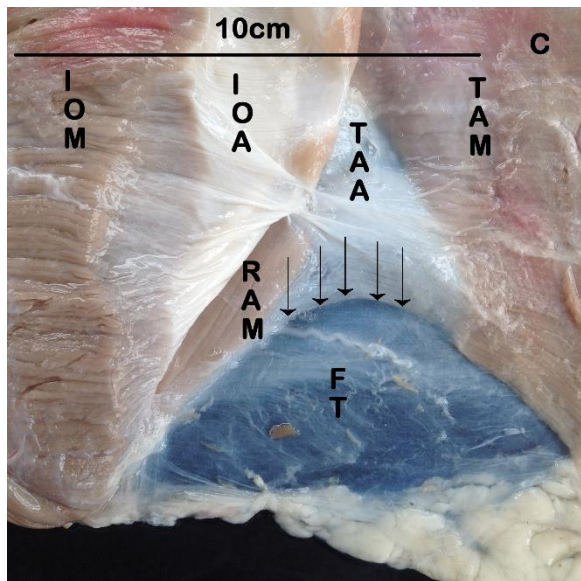
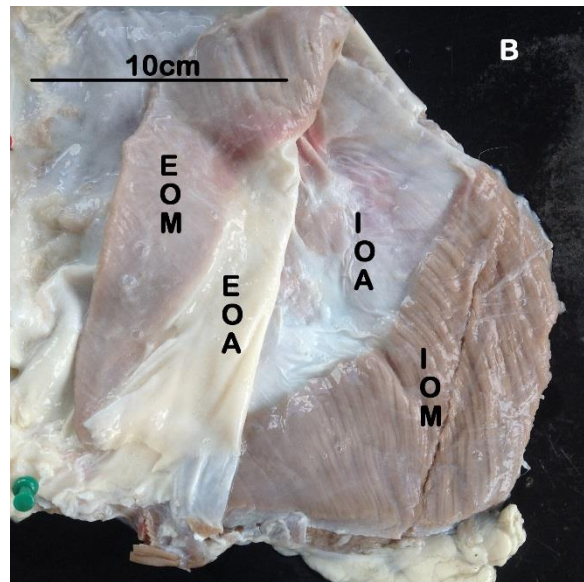
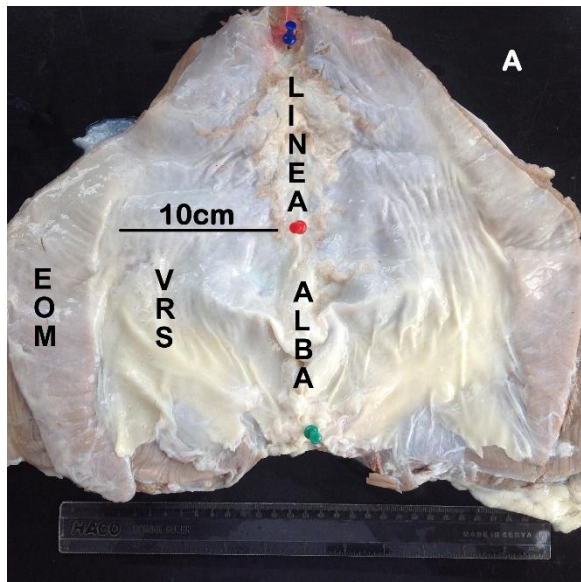
The rectus abdominis, which extended from the manubrium sternum to the pubic symphysis, was ensheathed by the aponeuroses of the three flat abdominal muscles namely the transversus abdominis, the external and internal oblique abdominis muscles. The aponeuroses of the external and internal oblique abdominis muscles passed ventral to the rectus throughout its extent (Fig 16A, B, C).

The aponeurosis of the transversus abdominis muscle (Fig 16C, D) formed the dorsal rectus sheath and then passed ventrally to join the aponeuroses of the external and internal oblique muscle at the linea alba at the arcuate line. From this line caudally the dorsal wall of the rectus abdominis muscle was lined by the fascia transversalis (Fig 16D).

Legends for Figure 16

- Figure 16A Photomacrograph of the ventral abdominal wall showing external oblique abdominis muscle (EOM) forming the external oblique aponeurosis which in turn partly forms the ventral rectus sheath (VRS) and the linea alba. Note that the umbilical and the hypogastric VRS are wider than 10cm.
- Figure 16B Photomacrograph of the ventral abdominal wall showing the external oblique abdominis muscle (EOM) and internal oblique abdominis muscle (IOM) forming the external oblique aponeurosis (EOA) and internal oblique aponeurosis (IOA) respectively. Note that the EOA has been reflected to the left.
- Figure 16C Photomacrograph of the ventral abdominal wall showing the muscle fibres of the transversus abdominis muscle (TAM) forming the transversus abdominal aponeurosis (TAA). The internal oblique abdominis muscle (IOM) reflected to the left to expose the longitudinally aligned fibres of the rectus abdominis muscle (RAM). Note the fascia transversalis (FT) exposed caudal to the arcuate line (arrows). The line marks the caudal end of the dorsal rectus sheath.
- Figure 16D Photomacrograph of the dorsal view of the ventral abdominal wall illustrating the dorsal rectus sheath (DRS) medially and the transversus abdominis aponeurosis laterally (TAA) located cranial to the arcuate line (vertical arrows). The fascia transversalis is seen lining the rectus abdominis muscle medially (FTR) and the internal oblique muscle laterally (FTI) caudally. Note the inferior epigastric artery (horizontal arrows) crossing the arcuate line (vertical arrows).

Figure 16. Photomicrographs of parts of the ventral abdominal wall a goat (*Capra hircus*).



3.2.2 Histology of the goat fibrous abdominal wall

3.2.2.1 Histology of the goat linea alba

The linea alba of the three regions contained collagen and elastic fibres which were organized into three, namely a superficial, intermediate and deep laminae in relation to the skin. The superficial lamina was made up of rows of obliquely arranged collagen fibres which were closely apposed to a ventral zone of longitudinally aligned elastic fibres found in the deep fascia (Fig.17A - F).

The deep fascia and the superficial lamina increased in size craniocaudally to become more distinct and thicker in the hypogastrium. In addition, the longitudinally aligned collagen bundles in the intermediate lamina became more prominent craniocaudally in total contrast to the transversely oriented collagen bundles in the deep lamina which diminished in size gradually towards the hypogastrium (Figure 17A - C).

Legends for Figure 17

Figures 17(A-C)- Photomicrographs of a transverse section of the epigastric, umbilical and hypogastric linea alba illustrating the deep fascia (DF) lying ventrally and the three characteristic laminae of the linea alba namely the superficial (SL), intermediate (IL) and deep (DL).

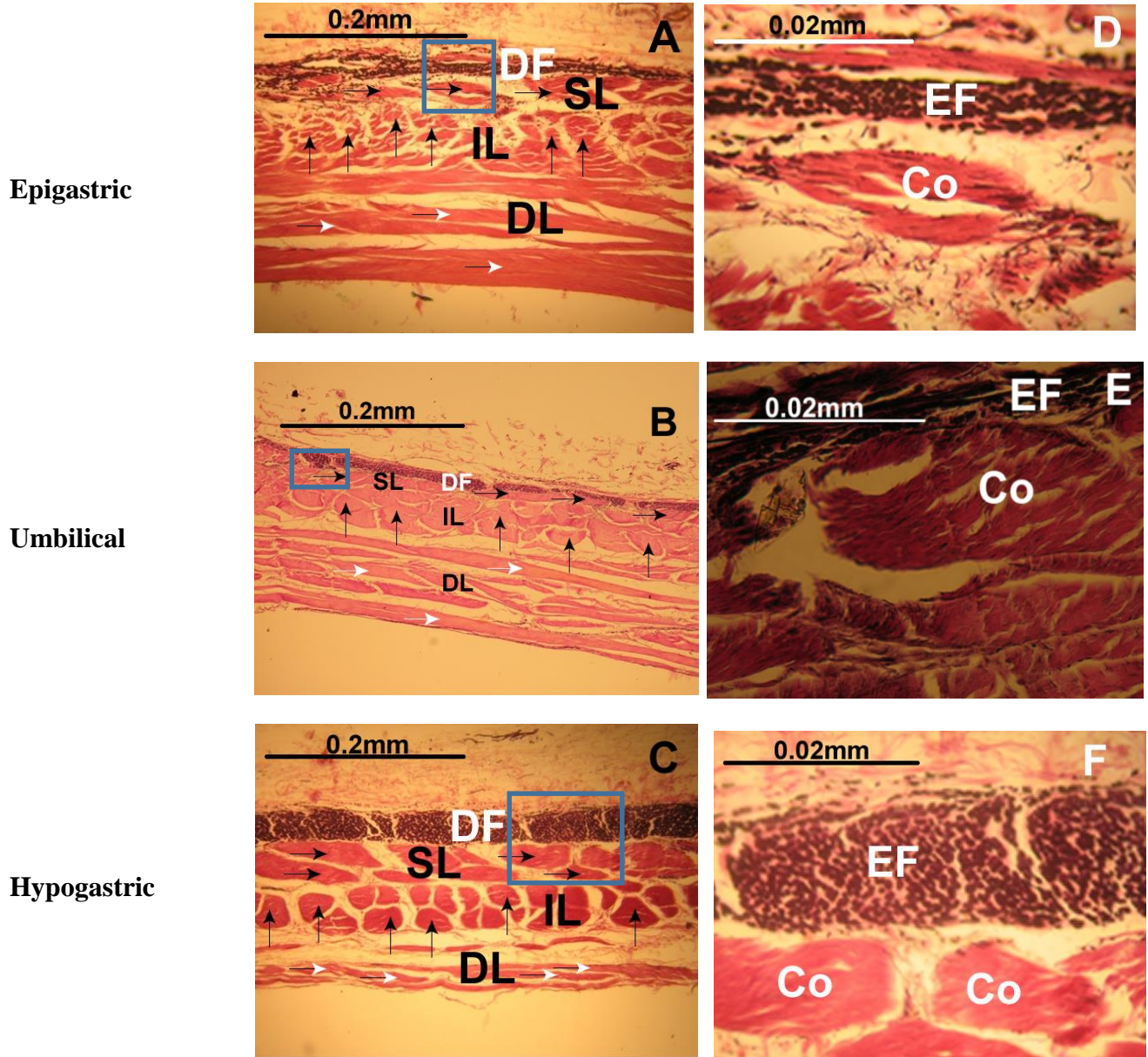
Figure 17A -Photomicrograph of the epigastric part of the linea alba consisted of transversely aligned collagen (horizontal white arrows) bundles dorsally while the ventral part comprised of an admixture of longitudinal (vertical arrows) and oblique (horizontal black arrows) collagen bundles.

Figure17B -Photomicrograph of the umbilical part of the linea alba showing the longitudinally aligned collagen bundles (vertical arrows) in the intermediate lamina (IL) and the elastic fibre zone in the deep fascia (DF).

Figure 17C -Photomicrograph of the hypogastric part of the linea alba showing the obliquely aligned collagen bundles and the elastic fibre zone in the superficial lamina (SL) and deep fascia (DF) respectively. Note the transversely aligned (horizontal white arrows) collagen bundles in the deep lamina (D) which have markedly diminished in size.

Figure17(D-F) High magnification photomicrographs illustrating the prominent elastic fibers (EF) found within the deep fascia (DF) lying ventral to the collagen bundles (Co) found within the superficial lamina (SL) of the epigastric linea alba, umbilical linea alba and hypogastric linea alba.

Figure 17. Photomicrographs of a transverse section of the three regions in the goat linea alba.



3.2.2.2 Histology of the goat ventral rectus sheath

Laterally, the ventral rectus sheath had collagen fibres organized into two laminae namely, a superficial and a deep one in relation to the deep fascia (Fig.18A - C).

The epigastric, the umbilical and hypogastric ventral rectus sheath were made up of a deep fascia which consisted of a sheet of elastic fibres while the superficial and deep laminae were each made up of rows of obliquely aligned collagen bundles (Fig.18D - F).

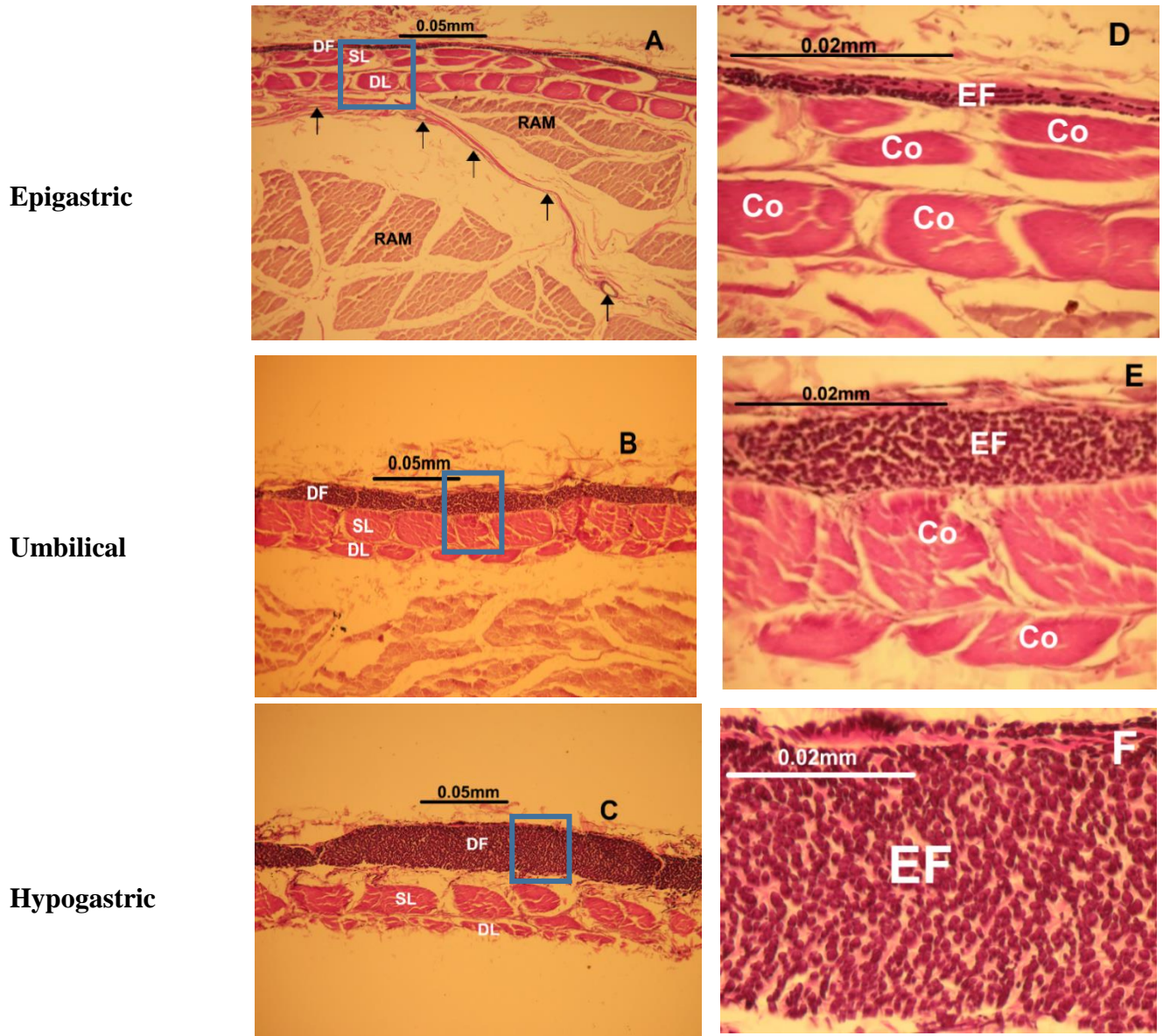
The deep fascia, which consisted of rows of longitudinally oriented elastic fibres, was thickest at the hypogastric ventral rectus sheath (Fig.18D - F).

Legends for Figure 18

Figures 18(A-C)- Photomicrographs of a transverse section of the epigastric, umbilical and hypogastric rectus sheath and hypogastric ventral rectus sheath illustrating the deep fascia (DF) lying ventrally and the two characteristic laminae of the ventral rectus sheath namely the superficial (SL) and deep (DL). Note the blood vessel (arrows) traversing the rectus abdominis muscle (ram) to supply the ventral rectus sheath in figure 18A.

Figure 18(D- F)-High magnification photomicrographs of the epigastric ventral, umbilical and hypogastric ventral rectus sheath showing the prominent black, elastic fibers (EF) found in the deep fascia (DF) and the oblique collagen bundles (Co) found in the superficial (SL) and deep laminae (DL).The zone of longitudinally aligned black elastic fibers were notably thickest at the hypogastric ventral rectus sheath as seen in Figure 18F.

Figure 18. Photomicrographs of a transverse section of the three regions in the goat ventral rectus sheath.



3.2.2.3 Histology of the goat dorsal rectus sheath

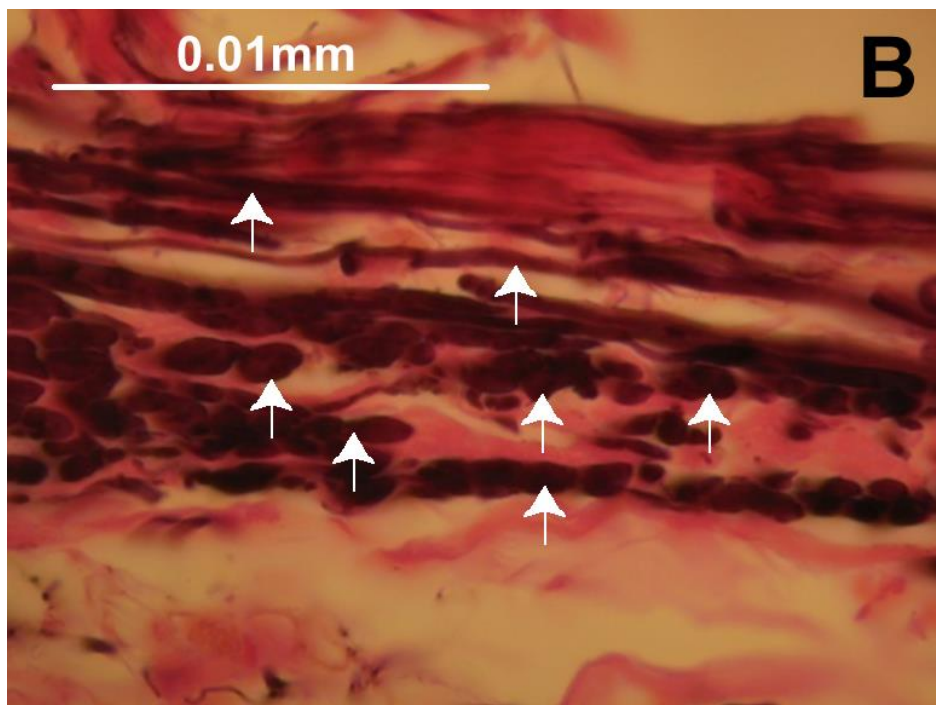
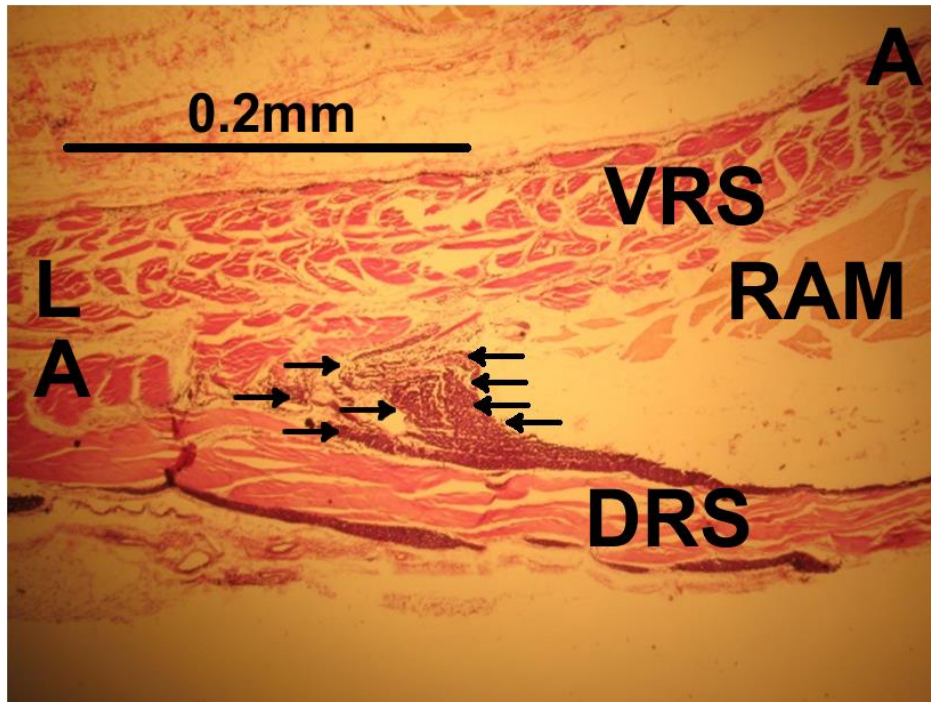
The epigastric dorsal rectus sheath consisted of a layer of transversely oriented collagen bundles which were sandwiched ventrally and dorsally by a sheet of longitudinally aligned elastic fibres (Fig.20A, D). The sheet was noted to be continuous with a thick zone of elastic fibres found at the medial edge of the rectus sheath (Fig.19A, B). Umbilical dorsal rectus sheath had similar zone of transversely oriented collagen bundle but with much fewer dorsally oriented elastic fibres (Fig.20B, E). The hypogastric dorsal rectus sheath consisted of transversely aligned collagen bundles however, with a few fine sparsely distributed elastic fibres lining it dorsally. (Fig.20C, F).

Legends for Figure 19

Figure 19A - Photomicrograph of a transverse section of the epigastric, umbilical and hypogastric rectus sheath (DRS) joining to form the linea alba (LA). Note the heavy presence of elastic fibers (arrows) found lying medial to the rectus abdominis muscle (RAM).

Figure 19B -A high magnification photomicrograph of the medial edge of epigastric ventral rectus sheath illustrating the orientation of elastic fibres (arrows).

Fig.19 Photomicrographs of a transverse section of the epigastric dorsal rectus sheath showing the elastic fibers at the medial edge of the rectus sheath (A) and their orientation (B).



Legends for Figure 20

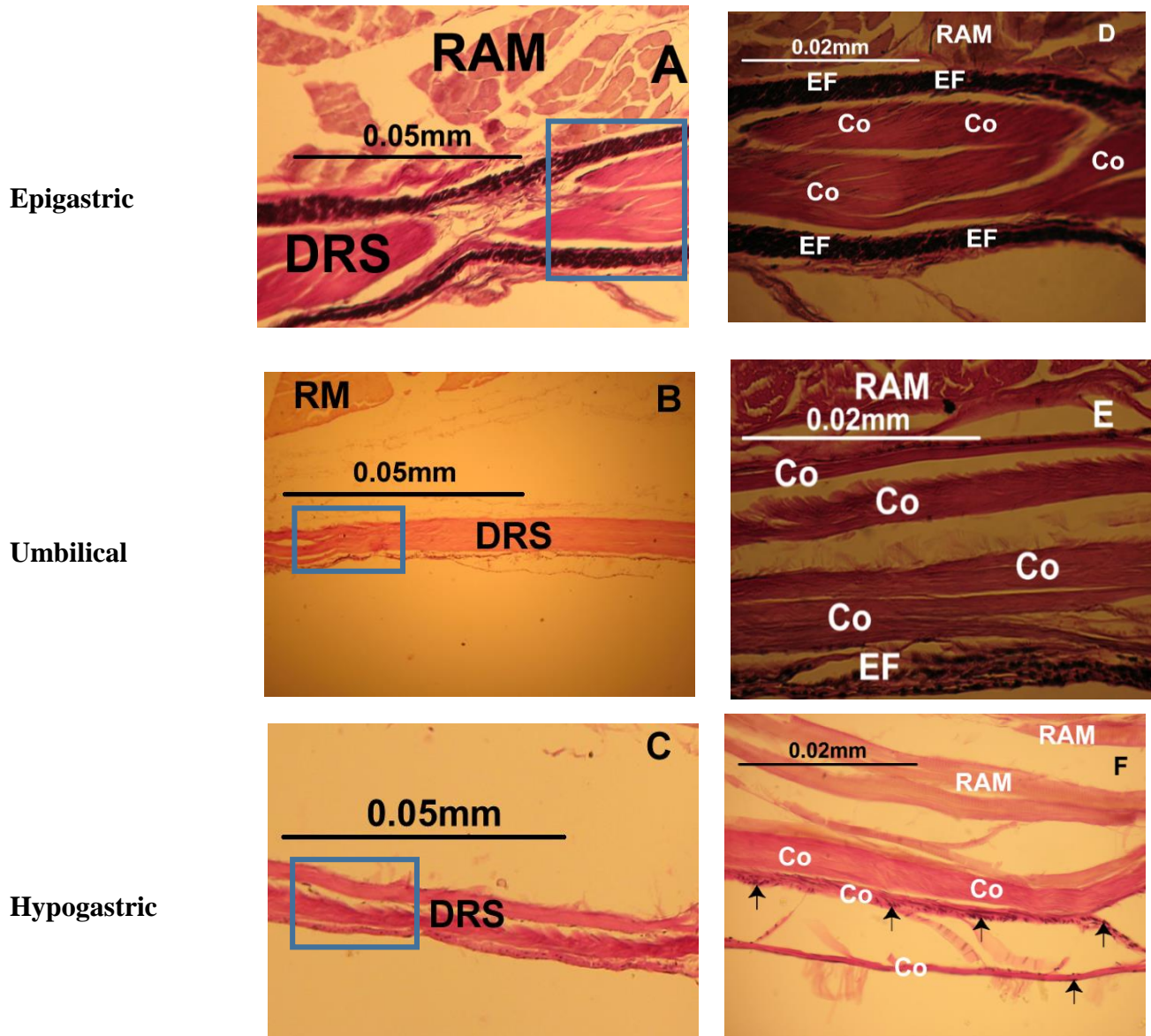
Figures 20(A-C)- Photomicrographs of a transverse section of the epigastric, umbilical and hypogastric dorsal rectus sheath (DRS) illustrating the characteristic transversely aligned overlapping transverse collagen bundles lying dorsal to the rectus abdominis muscle (RAM).

Figures 20(D) - A high magnification photomicrograph of a transverse section of the epigastric dorsal rectus sheath lying dorsal to the rectus abdominis muscle (RAM). Note the collagen bundles (Co) intimately ensheathed by the longitudinally oriented elastic fibres (EF).

Figure 20E -A high magnification photomicrograph of a transverse section of the umbilical dorsal rectus sheath lying dorsal to the rectus abdominis muscle (RAM). Note the less compact collagen bundles (Co) and the few elastic fibers (EF).

Figure 20F - A high magnification photomicrograph of a transverse section of the hypogastric dorsal rectus sheath lying dorsal to the rectus abdominis muscle (RAM). Note the few collagen bundles (Co) surrounded by very fine sparsely populated elastic fibers (arrows).

Figure 20. Photomicrographs of a transverse section of the three regions in the goat dorsal rectus sheath.



3.2.3 Measurement of the various laminae of the goat fibrous ventral abdominal wall

The epigastric region of the linea alba noted to be the thickest (0.365mm) while the hypogastric region was the thinnest at 0.238mm (Table 3). The deep lamina was 49% of wall thickness in the epigastric region and 27% in the hypogastric region ($p=0.002$). The deep fascia and superficial lamina, which was smallest in the umbilical region at 7% and 9%, was 23% and 21% respectively in the hypogastric region ($p=0.002$). The intermediate lamina hardly changed in percentage proportion craniocaudally ($p=0.008$). (Fig.21A).

The hypogastric region of the VRS was noted to be the thickest (0.074mm) while the epigastric was the thinnest at 0.036mm (Table 3). (Fig.21B). When the laminae were compared, the deep lamina was the thinnest at an average of 0.007mm ($p=0.008$) in the hypogastric VRS. The superficial lamina and the deep fascia on the other hand were thickest at 0.04mm ($p=0.002$) and 0.04mm ($p=0.007$) in the umbilical and hypogastric VRS respectively. The superficial lamina nearly doubled in size from 0.016mm in the epigastric VRS to 0.032mm in the umbilical VRS. The elastic rich deep fascia was nearly 50% of the wall section in the hypogastric VRS compared to less than 20% in the epigastric VRS. The deep fascia and superficial lamina in the hypogastric VRS made up nearly 90% of the wall thickness (Fig.21B) ($p=0.007$).

There was no significant difference in thickness between the epigastric and umbilical DRS of the (Table 4).

Legends for Figure 21 and Table 4

- Figure 21A -Bar chart showing percentage proportions of the mean measurements of the different laminae at the epigastric linea alba (ELA), umbilical linea alba (ULA) and hypogastric linea alba (HLA) regions. The deep lamina was the thinnest lamina proportionately in the hypogastric region ($p=0.018$), when compared to the epigastric and the umbilical region.
- Figure 21B -Bar chart showing percentage proportions of the mean measurements of the different laminae at the epigastric ventral rectus sheath (EVRS), umbilical ventral rectus sheath (UVRS) and hypogastric ventral rectus sheath (HVRS) regions. Note how the intermediate lamina and the superficial lamina were thickest in the umbilical and hypogastric region respectively.
- Table 4 -Table showing the geometrical dimensions (mm) of the mean thickness of the linea alba, ventral and dorsal rectus sheath samples in the epigastric, umbilical and hypogastric regions. Note that the epigastric linea alba was the thickest while the umbilical DRS and hypogastric DRS were the thinnest with roughly the same values.

Figure 21. Bar charts showing percentage proportions of the mean measurements of the different laminae of the goat.

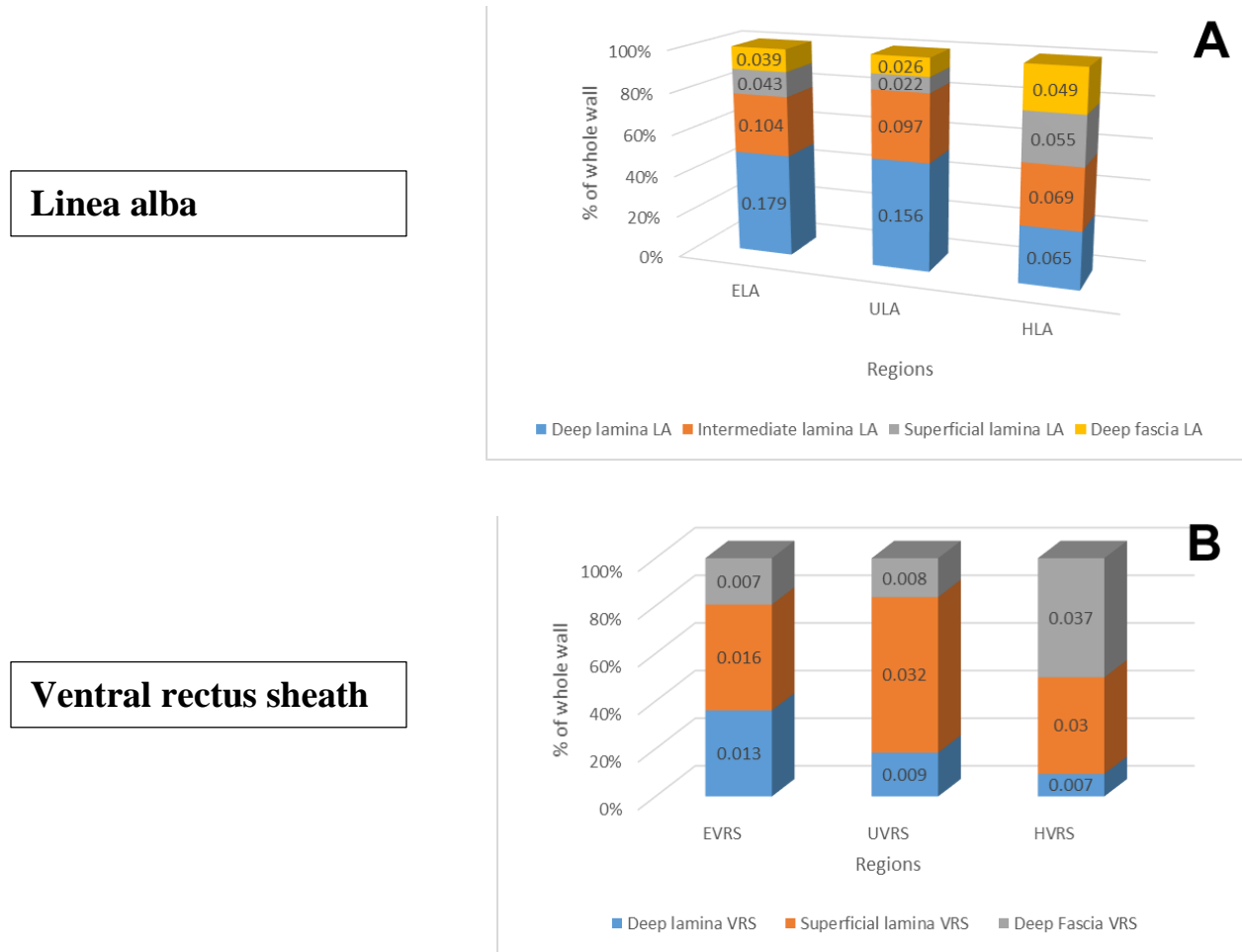


Table 4 Table showing the geometrical dimensions (mm) of the mean thickness of the fibrous ventral abdominal wall samples in three different regions in the goat.

	Epigastrium	SD	Umbilicus	SD	Hypogastrium	SD
*Linea alba	0.365	0.033	0.301	0.021	0.238	0.013
*Ventral rectus sheath	0.036	0.005	0.049	0.007	0.047	0.003
Dorsal rectus sheath	0.026	0.004	0.012	0.003	0.013	0.005

*Inclusive of the deep fascia

3.2.4 Tensiometry of the goat fibrous ventral abdominal wall

3.2.4.1 Tensiometry of the goat linea alba

During longitudinal and oblique mechanical loading, the linea alba displayed the typical stress-strain curves with an elastic (Toe and linear) and a plastic region (Fig 22A, B).

The typical stress-strain curve seen during longitudinal loading of the linea alba did not seem to vary significantly among the 3 regions. The maximal/ultimate stress needed (load to failure) to fracture the linea alba during longitudinal traction and oblique traction was 35N/mm^2 and 44.7N/mm^2 at a strain of 0.15 and 1.6 respectively (Fig 22A, B). The epigastric linea alba had a significantly higher load to failure of 35N/mm^2 compared to the hypogastric linea alba (26.5N/mm^2) respectively during longitudinal traction.

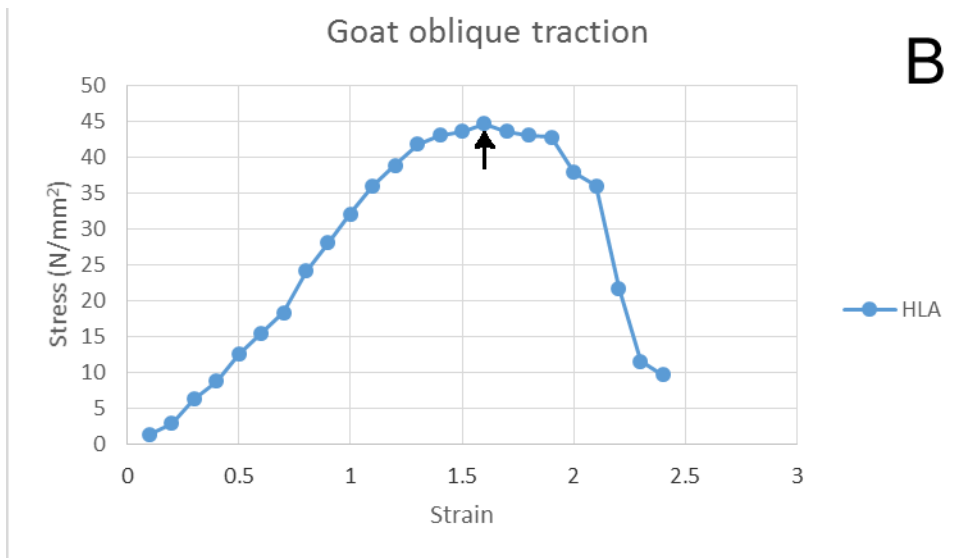
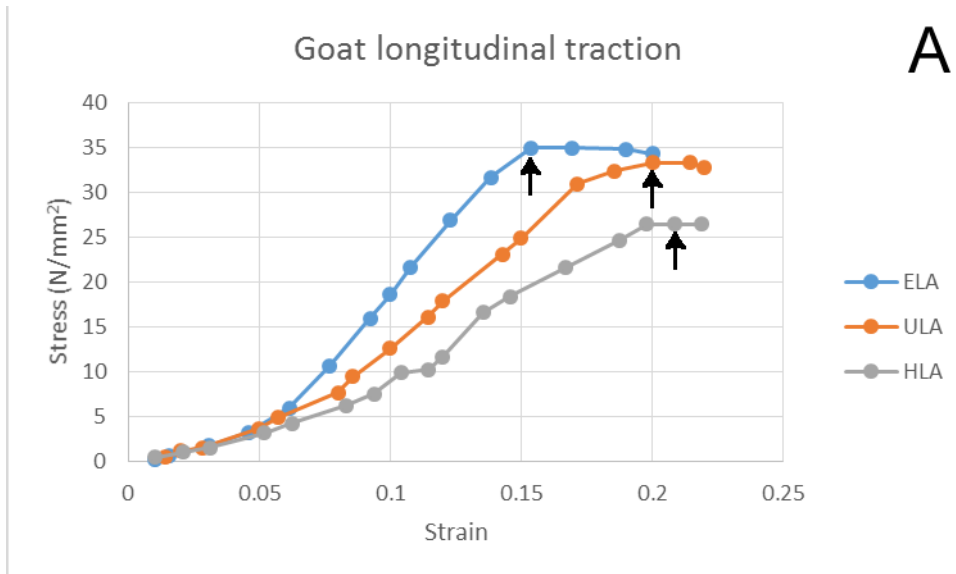
When LA was exposed to longitudinal traction, the most strain it encountered before breaking at its ultimate breaking point was seen in the hypogastrium at a strain of 0.21. (Fig 22A).

Legends for Figure 22

Figure 22A -Line graphs showing the longitudinal stress - strain curves on the epigastric linea alba (ELA), umbilical linea alba (ULA) and hypogastric linea alba (HLA) of the goat. The arrows point to the ultimate tensile strength point of each part of the linea alba.

Figure 22B -Line graphs showing the oblique stress - strain curve on the hypogastric linea alba (HLA) of the goat. The arrows point to the ultimate tensile strength point of the linea alba.

Figure 22. Graphs showing the longitudinal and oblique stress/ strain curves on the various parts of the linea alba.



3.2.4.2 Tensiometry of the goat ventral rectus sheath

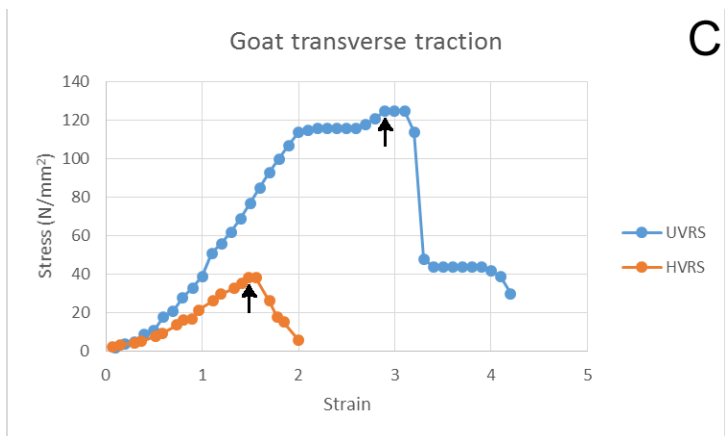
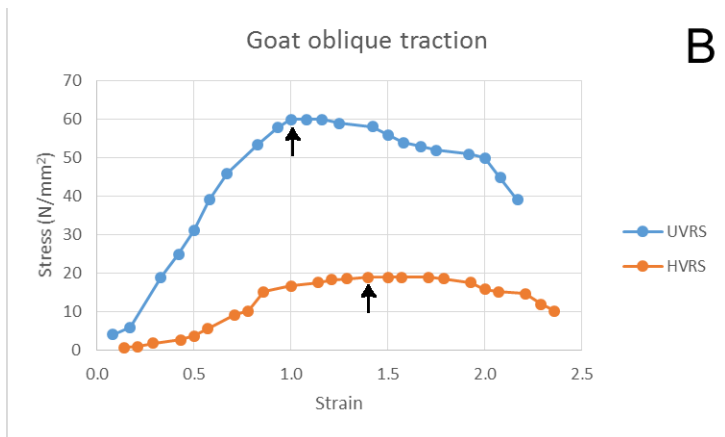
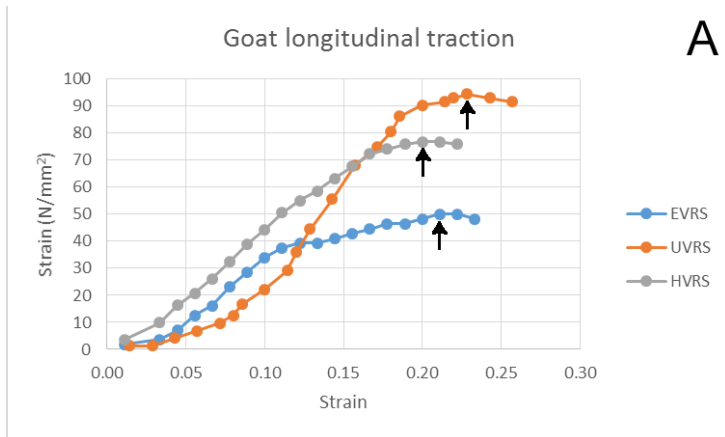
During mechanical loading of the ventral rectus sheath the toe region, characteristic of the collagen fibril strength, was present in all the curves. The elastic behaviour and the plastic behaviour of the VRS was also well illustrated in the regions when exposed to longitudinal, oblique or transverse traction (Fig 23).

The maximal/ultimate stress needed fracture the umbilical VRS during longitudinal traction was 94.5N/mm^2 at a strain of 0.23, the hypogastric VRS was 76.8N/mm^2 at a strain of 0.2 while the epigastric VRS was 50N/mm^2 at a strain of 0.22 respectively (Fig 23A). The greatest elasticity/ strain encountered, was seen in the umbilicus at 2.9 when VRS was exposed to transverse traction until its ultimate breaking point (Fig 23C).

Legends for Figure 23

- Figure 23A -Line graphs showing the longitudinal stress - strain curves on the epigastric ventral rectus sheath (EVRS), umbilical ventral rectus sheath (UVRS) and hypogastric ventral rectus sheath (HVRS) of the goat. The arrows point to the ultimate tensile strength point of each part of the ventral rectus sheath
- Figure 23B - Line graphs showing the oblique stress - strain curves on the epigastric ventral rectus sheath (EVRS), umbilical ventral rectus sheath (UVRS) and hypogastric ventral rectus sheath (HVRS) of the goat. The arrows point to the ultimate tensile strength point of each part of the ventral rectus sheath..
- Figure 23C - Line graphs showing the transverse stress - strain curves on the epigastric ventral rectus sheath (EVRS), umbilical ventral rectus sheath (UVRS) and hypogastric ventral rectus sheath (HVRS) of the goat. The arrows point to the ultimate tensile strength point of each part of the ventral rectus sheath..

Figure 23. Graphs showing the longitudinal, oblique and transverse stress/ strain curves on the various parts of the VRS.



3.2.5 Coefficient of elasticity (Young's modulus) of the goat fibrous ventral abdominal wall

The linea alba's Young's modulus was calculated over linear portions of the stress strain curves. These values show that on average, the umbilicus and the epigastrium appeared about three times stiffer when exposed to oblique traction compared longitudinal traction. These values show that on average, the epigastrium appeared to be the stiffest at 350(SD 17) N/mm² when exposed to longitudinal traction. The hypogastric LA was the weakest at 42.4(SD 4.6) N/mm² when exposed to oblique traction (Fig 23A). The linea alba's Young's modulus did not seem to vary significantly between the umbilical and hypogastric VRS during longitudinal loading (227(SD 6.5) N/mm² vs 217(SD 6.5) N/mm²)(Fig 24A).

The VRS was stiffest at 669(SD 21.2) N/mm² when the hypogastrium was exposed to longitudinal traction. The hypogastric VRS was the weakest at 28.6(SD 7.9) N/mm² when exposed to oblique traction (Fig 23A). The VRS YM did not seem to vary significantly between the epigastric and hypogastric VRS during longitudinal loading [554(SD 29) N/mm² vs 591(SD 5.5) N/mm²].(Fig 24B). The umbilical or hypogastric VRS's Young's modulus also did not seem to vary significantly whether exposed to oblique and transverse loading.

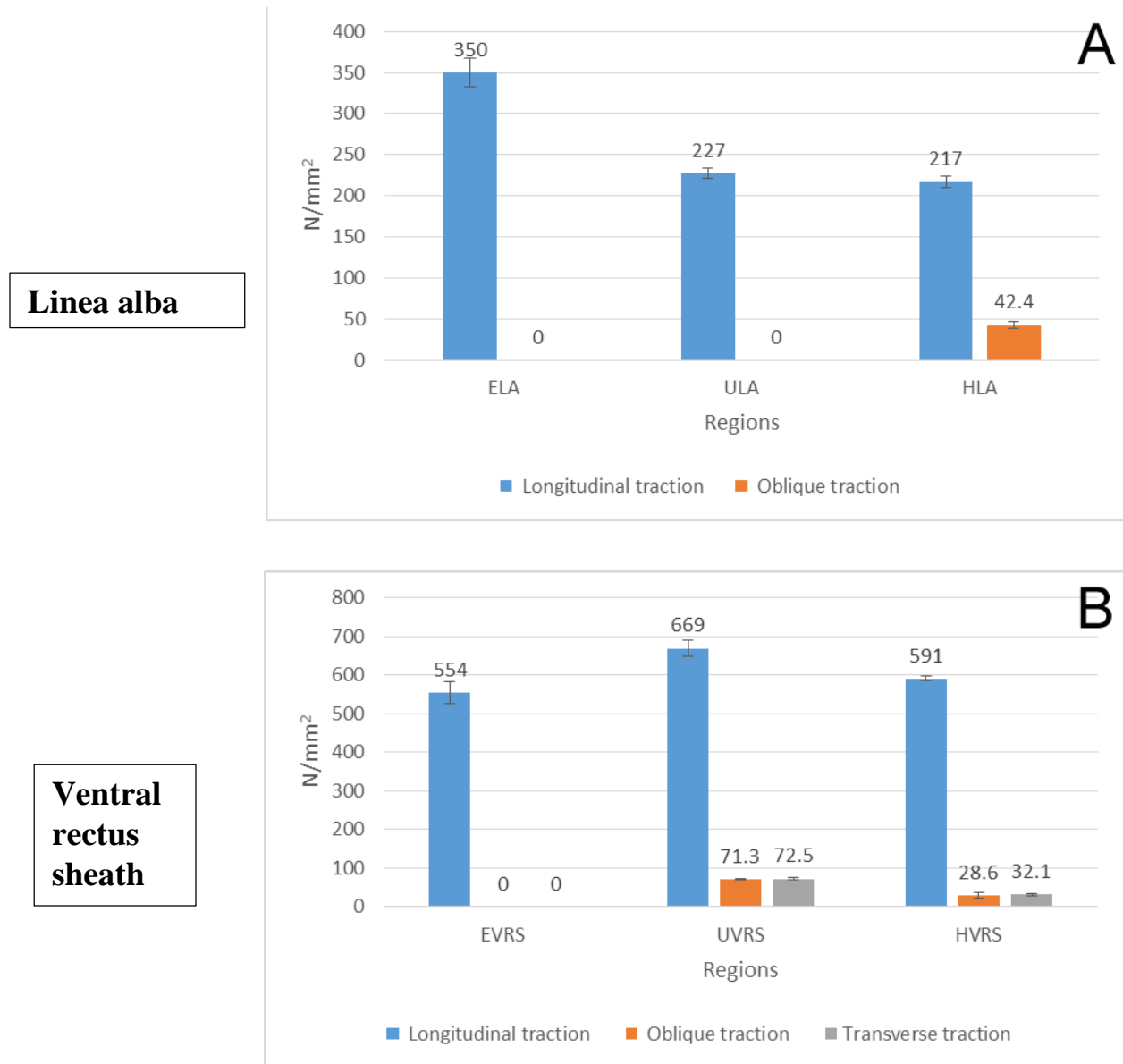
In summary, the highest Young's modulus/ stiffness among the LA and VRS was seen when they were exposed to longitudinal loading (Table 5).

Legends for Figure 24

Figure 24A -Bar chart showing coefficient of elasticity (Young's modulus) of the epigastric linea alba (ELA), umbilical linea alba (ULA) and hypogastric linea alba (HLA) of the goat when they were exposed to various traction forces. Note how the epigastric linea alba recorded the highest elastic coefficient at 350 N/mm^2 when exposed to longitudinal traction.

Figure 24B -Bar chart showing coefficient of elasticity (Young's modulus) of the epigastric ventral rectus sheath (EVRS), umbilical ventral rectus sheath (UVRS) and hypogastric ventral rectus sheath (HVRS) of the goat when they were exposed to various traction forces. Note how the umbilical ventral rectus sheath recorded the highest elastic coefficient at 669 N/mm^2 when exposed to longitudinal traction.

Figure 24. Bar charts showing Young's modulus of the different regions of the goat's LA and VRS when they were exposed to various traction forces.



Legend for Table 5

Table 5 -Showing the maximal forces, highest ultimate tensile strengths and highest coefficient of elasticity recorded for fibrous ventral abdominal wall in the goat for the epigastric, umbilical and hypogastric regions when they were exposed to longitudinal (L), oblique (O) and transverse(T) tractional forces. Note the highest ultimate tensile strengths and highest coefficient of elasticity recorded was recorded at the umbilical region of the ventral rectus sheath.

Table 5 Table showing the maximal forces, highest ultimate tensile strengths and highest coefficient of elasticity recorded for linea alba and ventral rectus sheath in the goat for the epigastric, umbilical and hypogastric regions.

Goat			
	Tractional force N	Stress N/mm ²	YM N/mm ²
Linea alba			
epigastric	280-L	35-L	350-L
umbilical	210-L	33.3-L	227-L
hypogastric	170-O	44.7-O	217-L
Ventral rectus sheath			
epigastric	50-L	50-L	554-L
umbilical	125-T	125-T	669-L
hypogastric	146-L	76.8-L	591-L

CHAPTER FOUR

4.0 DISCUSSION

4.1 Morphology of the fibrous ventral abdominal wall

Observations of this study have revealed that the ventral abdominal aponeurosis of the baboon and the goat are similar in their pattern of formation. In both animals, the aponeurosis of external and internal oblique abdominis muscle joined to form the ventral rectus sheath while the aponeurosis of transversus abdominis formed the dorsal rectus sheath in all cases seen.

The above results are in conformity with the findings for group II type of arrangement as described by Walmsley (1937). This author observed group II type of arrangement in primates such as the baboon, gibbon, chimpanzee and the gorilla. The rabbits, dogs and the insectivora (except Talpidae) were also described as having a similar rectus sheath formation pattern and thus also belonged to this group.

The formation of the rectus sheath has been known to show regional variation in some species (Walmsley (1937). Typically the umbilical part is taken as classical or primary morphological position while the epigastric part has been explained to be different due to the presence of the costal skeleton in the abdominal wall. The variations seen in the hypogastric part almost always consist of a ventral shifting of a part or whole of the dorsal sheath into the ventral rectus sheath with an abrupt suddenness leaving a sharp free border; the arcuate line (Mwachaka et al., 2009). However, neither the baboons nor the goats we studied had any variations from their group type.

The fibrous ventral abdominal wall is a complex dynamic system which performs multiple interactions within a framework of bones and muscles. The abdominal wall is an important structure serving many different functions. The two major functions are movements of the trunk (De Troyer, 1983) and regulation of intra-abdominal pressure (Cresswell et al., 1993). Moreover, it supports respiration and plays a role in stabilization of the spine (Tesh et al., 1987). All these functions are facilitated by the coordinated and task-specific activation pattern of the abdominal muscles (Cresswell et al., 1993). However, electromyographic observations clearly demonstrated the transversus muscle to be most significant in intra-abdominal pressure production and to be recruited preferentially in breathing (De Troyer, 1983). In contrast, the internal and external oblique muscles are more effective in contributing to trunk movements (McGill, 1996) and stabilization of the spine (Tesh et al., 1987).

The cranial fascicles of transversus abdominis act as a circular compressor of both thoracic and abdominal cavities (Hodges et al., 2000). As proposed by Richardson et al (2002) and other authors, the lower fascicles of TAM and IOM support abdominal viscera and generate forces that compress the sacro-iliac joints for postural stability (Rizk, 1980; Richardson et al., 2002). Electromyographic studies on the TAM have shown greater tonic activity in the caudal fibres during upper limb movements. Rapid flexion of the upper limb produces a brief challenge to postural stability of the trunk with most of the effects being felt at the sacroiliac joints (Hodges et al., 2000). Contraction of lower fibres of TAM and IOM flex the spine leading to stabilization of the sacroiliac joints (Richardson et al., 2002). The rectus abdominis muscle is also recruited during these maneuvers (Hodges et al., 1997). The ventral position of the fibrous abdominal wall is thus the most favorable as the forces act on the most curved surface with the contracted RAM acting as a rigid support.

4.2 Histology of the fibrous ventral abdominal wall

4.2.1 Histology of the linea alba

The microscopic structure of the fibrous ventral abdominal wall has been reported by several workers in man (Askar, 1977; Axer et al., 2001a; Pulei et al., 2007; Pulei et al., 2015; Mwachaka et al., 2009) and in animals (Acostasantamaria et al, 2015). Studies by Acostasantamaria et al., (2015) dwelt mainly on the distribution of collagen fibres in the porcine LA, with scarce reports on elastic fibres. Our study has for the first time reported the microscopic structure of the fibrous ventral abdominal wall in the baboon and goat.

Our study showed that the linea alba of the baboon and the goat, was similar to that in man (Pulei et al, 2009), with regards to the three distinct laminae namely the superficial, intermediate and deep lamina. Pulei et al, 2009 reported that the elastic fibres in man were longitudinally and obliquely disposed in the entire length of the LA and in addition were more abundant in the lateral and hypogastric parts of the LA especially in the superficial lamina. Human females were noted to have more elastic fibres than males particularly in the hypogastric region.

The results of our study showed that the lateral, ventral and hypogastric aspects of the goat linea alba also had a lot of elastic fibres. This thick zone of elastic fibres were also seen in the ventral and hypogastric aspects of the goat VRS. Our study in the goat however noted the distinct zone of elastic fibres seen in the ventral aspect of the LA and VRS, as described by Pulei et al (2015), were actually part of the deep fascia intimately adherent to the underlying superficial lamina and not part of the superficial lamina. It is hereby suggested that the high content of elastic fibres noted, may have a role in facilitating the smooth gliding of the rectus abdominis muscle during truncal movement.

In our study, the baboon epigastric LA comprised of mainly obliquely aligned collagen bundles while the umbilical LA was composed of a fused thick mass of transversely oriented collagen bundles. The arrangement of the collagen bundles in man (Pulei et al., 2015) were similar to that seen in our study in the baboon, even though in the latter virtually all the collagen bundles in the hypogastric LA seemed more longitudinally disposed.

The goat LA had an intermediate and deep lamina, which consisted of longitudinally aligned collagen bundles and transversely oriented collagen fibers respectively. The deep lamina of the male goat LA had transversely aligned collagen bundles which are consistent with reports from the human female (Pulei et al., 2015) and in the porcine (Acostasantamaria et al., 2015).

Our study hence extends the argument about the role of the admixture of oblique and transversely aligned collagen fibers observed in the baboon and goat LA. Pulei et al (2015) had suggested that they may constitute a “strong aponeurosis of variable tension” which would serve various functions (Pulei et al., 2015). The thicker deep lamina, which contains transversely aligned collagen fibers, seemed to represent the main reason for the great compliance (350 N/mm^2) noted in the goat ELA when it was exposed to longitudinal traction (Table 4). This was higher than what was seen in the baboon ULA (328 N/mm^2).

Considering that most of the weight of the compound stomach in the goat will be loaded on the epigastrium and hence the LA, the crisscrossing multidirectional collagen bundles would allow for changes in the shape of the abdominal wall while at the same time strengthen the ELA during browsing or grazing when it is over distended. The substantial amount of elastic fibers seen in the LA of the goat, not comparable with the findings in the baboon and in man (Pulei et al., 2015), make the LA of the goat, more compliant to stretch during grazing.

The compact bundles of collagen fibres seen fusing in the intermediate zones of the baboon umbilical linea alba is a feature of the tissues subjected to biomechanical stresses such as tendons and ligaments (Parry et al., 1978; Birk and Trelstad, 1986). It is suggested that this zone was designed to provide tensile strength to the linea alba. Pertinent to this is the report by Parry et al (1978), that the presence of collagen fibres in compact bundles increases the cross-linkages in these fibres leading to an increase in the tensile strength. This was confirmed by the high elastic coefficient of 328N/mm² noted in the baboon ULA.

4.2.2 Histology of the rectus sheath

The microscopic structure of the ventral rectus sheath has been reported by several workers in humans only (Askar., 1977; Axer et al., 2001a; Mwachaka et al., 2009). Only Mwachaka et al, (2009), studied the dorsal rectus sheath.

4.2.2.1 Histology of the ventral rectus sheath

The baboon and goat VRS were found to consist of 2 laminae which were predominantly made of obliquely aligned collagen fibres. The collagen bundles in the baboon VRS hypogastrium were arranged in a characteristic crisscross manner. While the goat epigastric VRS had an obliquely aligned collagen bundles in the superficial lamina which became more prominent in the hypogastric region in contrast to the bundles in the deep lamina which diminished in size.

These findings are similar to previous work done in the human rectus sheath (Askar, 1977; Axer et al., 2001a; Axer et al., 2001b; Mwachaka et al., 2009). Mwachaka et al (2009) reported a random arrangement of collagen and elastic fibres in the deep zone of the VRS. As was described earlier in the LA, it is plausible that the elastic fibres seen by Mwachaka et al (2009) in the superficial lamina were also actually part of the deep fascia and not part of the rectus sheath.

The arrangement of collagen and elastic fibres in the VRS in the present study suggests a functional adaptation. Disparities in fibre composition and orientation in the various laminae however, suggests that these laminae are modified for specific functions. Loosely arranged connective tissue fibres function to anchor tissues to one another. In support of this is the report by Viidik (1978) that the orientation of connective tissues fibres is greatly influenced by the mechanical activities of tissues around. By virtue of its position, this zone is subjected to multidirectional forces emanating from the pull of the rectus abdominis muscle as well as those from the three anterolateral muscles (McArdle, 1997). Accordingly, the multidirectional orientation of collagen and elastic fibres may be designed to accommodate these forces.

As elucidated by McArdle (1997), the assumption of the upright posture in human beings lead to the generation of more intra- abdominal pressure in the lower abdomen as a result of the weight of abdominal viscera. Consequently, it is proposed that the characteristic crisscross orientation of collagen bundles in the baboon hypogastric VRS and the prominent deep fascia elastic fibres intimately adherent to the superficial lamina of the goat VRS may provide a “check-rein” mechanism for absorbing sudden intra-abdominal pressures. This would support the documented constant bipedal form of locomotor activity reportedly seen in the olive baboon (Berillon et al., 2013).

4.2.2.2 Histology of the dorsal rectus sheath

Our study has for the first time reported the microscopic structure of the DRS of the baboon and goat. The baboon and the goat DRS, were noted to consist of predominantly transversely aligned collagen bundles. However, while the baboon epigastric and umbilical DRS collagen bundles contained heavily infiltration of transversely aligned elastic fibers, the goat epigastric DRS in contrast, was noted to consist of a thin zone of longitudinally aligned thin sheets

elastic fibres lining transversely aligned collagen bundles. The collagen bundles in the both animals became thinner craniocaudally as the elastic fibre content diminished rapidly in size and number. The transversely oriented collagen fibres seen in our study in both the goat and baboon dorsal rectus sheath were consistent with those seen in the human DRS (Mwachaka et al., 2009). However, in contrast to our findings, Mwachaka et al, (2009) reported only very few and fine sparsely distributed elastic fibres which were limited to lining the deep lamina and interspersed within the transversely aligned collagen bundles. It is known that the transversely aligned collagen fibre bundles seen in the fibrous abdominal wall follow the orientation of the fibres of the transversus abdominis muscle (William., 1995; Mwachaka et al., 2009).

Consequently, from the foregoing, it is suggested that the transversus abdominis muscle exerts the most effect on the dorsal wall of the rectus sheath. It is further suggested that the entire rectus sheath above the arcuate line takes part in all movements of the transversus abdominis such as in respiration (Hodges et al., 1997; Urquart et al., 2005). In this way, the contraction of TAM pulls the deep lamina of internal oblique muscle. This same traction force then draws the superficial lamina of internal oblique muscle together with the rectus abdominis muscle. This phenomenon is observed during normal respiration and supports the classification of the upper abdominal wall into a respiratory portion (Rath et al., 1997).

This observation may be an adaptation of the transversus abdominis muscle in generating intra-abdominal pressure. Pertinent to this is the report by Muramatsu et al (2001) that skeletal muscles contain contractile elements (muscle fibres) and elastic components (aponeuroses or tendons). The elastic component interacts with the contractile element (Kubo et al., 2000) and functions as a store of elastic energy when the muscle contracts (Alexander, 1984). It is plausible therefore that the aponeurotic part of transversus abdominis or dorsal rectus sheath stores energy

when this muscle contracts and releases the energy when the muscle relaxes. This leads to build up of pressure in the lower abdomen.

4.3 Morphometry and biomechanics

4.3.1 The biomechanical role of collagen and elastic fibres in the fibrous ventral abdominal wall

The view generally held is that collagen fibres provide tensile strength (Parry et al., 1978) whose main purpose is to withstand forces, while grossly maintaining the body's shape. In contrast, elastic fibres, have a difficult task trying to overcome the tensile forces that are constantly trying to pull joints or points of attachments apart whenever movement or muscle contraction takes place. They thus allow stretch and recoil of tissues to their original shape and size (Kielty et al., 2002). These tissues don't need to be able to bear heavy loads, but instead, must be able to stretch and "deform" (at least to a slight degree) while resisting tearing. Of these tissues, fascia is the most elastic, while tendons are considered the least elastic (some say that tendons are actually non-elastic). Accordingly the fibroelastic composition of the rectus sheath and linea alba may be a design to enable it to withstand high levels of biomechanical stresses emanating from the pull of the muscles and also to tolerate sudden changes in the intra-abdominal pressure.

Typical stress–strain curves for tendon and virtually all other collagen-containing connective tissues, tend to have a 'J-shaped' stress–strain curve. At low strains the slope is low, but as extension proceeds it rises gradually and becomes constant when the collagen fibres become aligned and then finally stretched. These data, and particularly the load cycle, show that collagen is definitely capable of reversible deformation and it is this aspect of collagen that establishes it as

an elastic protein. Indeed, the resilience of tendon collagen is *ca.* 90% (Bennett et al., 1986; Shadwick, 1990).

In spite of this, collagen does not always function as an elastic protein in animals. Rather, collagen is frequently arranged in parallel with elastin fibres to form connective tissues, and in these circumstances the ‘stretchy’ elasticity of the tissue is due primarily to the elastin. The collagen provides a network of wavy, reinforcing fibres that become aligned in the direction of stretch. When taut, this network limits tissue deformation and prevents the rupture of the softer and weaker elastin fibres. Some tendons, however, do function as elastic devices and have a remarkable energy storage capacity.

Elastic implies the property of elasticity, or the ability to deform reversibly without loss of energy; so elastic proteins should have high resilience. Another meaning for elastic is ‘stretchy’, or the ability to be deformed to large strains with little force. Thus, elastic proteins should have low stiffness. The combination of high resilience, large strains and low stiffness is characteristic of rubber-like proteins that function in the storage of elastic-strain energy. Other elastic proteins play very different roles and have very different properties. Collagen fibres provide exceptional energy storage capacity but are not very stretchy. Mussel byssus threads and spider dragline silks are also elastic proteins because, in spite of their considerable strength and stiffness, they are remarkably stretchy. The combination of strength and extensibility, together with low resilience, gives these materials an impressive resistance to fracture (i.e. toughness), a property that allows mussels to survive crashing waves and spiders to build exquisite aerial filters (Gosline, 2002).

Some workers described intriguing material properties of two segments from *Mytilus californianus* (Bell and Gosline, 1996). They showed that the proximal segment is extremely

stretchy suggesting a rubber-like behaviour, but its stiffness and strength are about an order of magnitude greater than those for elastin and resilin. The distal region is somewhat less extensible but its stiffness and strength approach those of collagen. Because of the combination of high strength and extensibility, the toughness of both proximal and distal byssal threads is approximately an order of magnitude greater than that of resilin or elastin and about six times greater than that of tendon collagen. The toughness of byssal fibres is quite comparable with that of Kevlar and carbon fibres, and this high toughness is certainly key to the survival of mussels in the marine intertidal zone (Bell and Gosline, 1996).

Elastic fibres respond to low pressures by stretching without obeying Hooke's law, but rather resisting stretch the more it is stretched (Wolinsky and Glagov, 1964). When the stretch is removed normal morphology can be resumed (Sandberg, 1976). In concert with the microfibrillar glycoproteins, elastin is considered to provide resilience to connective tissue structures (Parks et al., 1993). By virtue of their wide range and reversible stretch-ability, elastic fibres may act as tensioregulators, thus enabling the tissues or organs in which they are found to adapt adequately to sudden variations of tension, or to sustained stresses with minimum expenditure of energy (Sandberg, 1976).

Several workers have described in the ligamentum nuchae (Reed, 1973) and in the wing tendon of the domestic fowl (Oakes and Bialkower, 1977) that elastic fibres are closely invested by a system of collagen fibres, and most cases, the collagen fibres intrude intimately into the fine scale dimensional network of elastic fibres and not the converse (Ogeng'o, 2008).

Kimani (1993) described cases of collagen fibrils extending into the surface of elastic fibers and at times were found intermingled with microfibrils of elastic fibers. Microfibrils and elastic

fibers not only have biomechanical properties but may also be involved in anchoring mechanisms between collagen fibers, stromal cells, lymphatic capillary walls, mature elastic fibers and muscle cells (Bancroft, 1994). Elastic fibers complement collagen fibers in their function (Kelty, 2002). If collagen and elastin composition is altered, tissue complacency may be jeopardized (La Bourenne, 1990).

Ozdogan et al (2006) investigated the collagen and elastic fibre content of the abdominal wall layers rich in connective tissue, such as the skin, the rectus sheath, the transversalis fascia and the peritoneum. He managed to correlate inguinal hernia formation with (local) connective tissue disorders. The integration of elastic fibers with collagen fibers is important and is suggested to be critical for the maintenance of normal tissue resistance (Quintas et al., 2000).

4.3.2 The role of morphometry and tensiometry in the fibrous ventral abdominal wall

Studies by Shadwick (1990) have described collagen fibres in tendons as stretchy; with some having a modulus of approximately 1000 times greater than that of elastin or resilin. Our study has shown that the highest coefficient of elasticity (Youngs modulus) recorded in either animal was seen when the fibrous ventral abdominal wall was exposed to longitudinal loading (Table 3, 5). This is consistent with work done by Martin et al, (2011) whose data showed that forces along the longitudinal direction of the rectus sheath was not only stronger but also stiffer than if loaded in a transverse direction.

Our observations in the baboon have shown that on one hand, umbilical DRS(YM 1000N/mm²) recorded the highest elastic coefficient and the high UTS (95N/mm²) despite its small

size (0.051mm) while on the other hand, the baboon umbilical LA which was the thickest (0.779mm) had only a UTS of 23.6N/mm² and an elastic coefficient of 328N/mm² when exposed to tractional forces. Our study has thus suggested that the tensile strength is inversely proportional to the wall thickness.

In the goat, the epigastric LA and hypogastric LA regions were the thickest (0.365mm) and thinnest (0.012mm) respectively. The deep fascia and superficial lamina of the goat LA and VRS made up more than 72% and 85% of the hypogastric wall thickness compared to 25% and 63% of the epigastric wall thickness respectively (p-0.002). While the umbilical of the goat VRS recorded the highest elastic coefficient (YM 669N/mm²), it was less than 14% in size in relation to the thickest wall in the goat fibrous ventral abdominal wall.

From the foregoing and as will be seen in the following section, Korenkov's (2001) proposal was not in agreement with our findings. The tensile strength of the fibrous ventral abdominal wall may not be necessarily directly proportional to the thickness and density but would also depend on the orientation and composition of the connective tissue fibre content. This is consistent with suggestions by other authors who showed that the ratio of collagen type I and III may play a direct role in the tensile strength of the fibrous ventral abdominal wall (Calvi et al, 2011).

Our study confirms and extends studies by others (Axer et al., 2001a; Acostasantamaria et al., 2015) by showing significant differences in tensiometric characteristics between the three regions of the LA. The baboon and the goat hypogastric LA had the highest UTS of 63.6 N/mm² and 44.7 N/mm² (Table 3, 5) respectively when exposed to oblique traction despite showing the least elastic coefficient. In our samples, the baboon ULA and the goat ELA showed a highest

elastic coefficient of 328 N/mm² and 350 N/mm² respectively. This is in contrast to the porcine samples (Acostasantamaria et al., 2015) and the human samples (Axer et al., 2001a) where the hypogastric linea alba was reportedly significantly stiffer than the epigastric linea alba (Table 3, 5).

Although the goat's umbilical ventral rectus sheath recorded the highest ultimate breaking strength of 125 N/mm² in both animals, however, when the umbilical and hypogastric regions ultimate breaking strengths were combined, the goat's VRS (201.8 N/mm²) and the baboon's DRS(195 N/mm²) had a similar values.

Our study has confirmed biomechanical studies done by others which showed that the fibrous ventral abdominal wall has elastic properties (Kirker-Head et al., 1989; Rath et al., 1999; Kirilovam et al., 2009). Further to this, mechanical elasticity in our study of the fibrous ventral abdominal wall was observed to vary topographically in such a way that in both animals, the rectus sheath was recorded to have a higher elastic coefficient while the LA had the least elastic coefficient (Table 3, 5).

Kirilovam et al, (2009) reported that the viscoelasticity of the fibrous abdominal wall is supported by the varied elastic moduli and ultimate tensile stresses (UTS). They noted that samples cut parallel to the direction to the collagen fibres exhibited 3 times the elastic modulus and had nearly twice the ultimate tensile strength compared to those cut perpendicular to the fibres. Parallel samples hence exhibited a greater elastic modulus and UTS primarily due to the mostly uniform orientation of the collagen fibers. This was consistent with our findings in the baboon umbilical DRS and the goat VRS which exhibited a high elastic coefficient and ultimate tensile strength because they were cut parallel to the direction of the main connective tissue fibres. However, we

suggest that the high content of elastic fibres in these tissues contributed also a great deal to the tensile strength noted.

In vivo biodynamic properties of the intact equine linea alba has been found to show regional variations such that the hypogastric linea alba experienced greater stress than the epigastric linea alba (Kirker-Head et al., 1989). This was confirmed in man (Grassel et al., 2005). Using a biomechanical study, Grassel et al (2005) proposed that when the linea alba is exposed to increasing force in the longitudinal, transverse and oblique direction, compliance was highest in the longitudinal direction and least in the transverse direction (Grassel et al., 2005). They further showed that the hypogastric region exhibited a coefficient of elasticity greater than that of the epigastric portion (Grassel et al., 2005). In the female, the compliance of the hypogastric part was found to be significantly smaller in the transverse than in the oblique direction. This compliance in the transverse direction was also found to be smaller in women than in men.

A study of the biomechanics of the superficial fascia attempted to characterize properties of human abdominal tissue through tensile testing (Song, 2004). The superficial fascia was found to have a failure load of 102.6 ± 74.4 N, and when the dermis and fascia were evaluated as a single unit, the value for failure load increased to 401.4 ± 44.9 N (Song, 2004). Other authors have found the combination of the rectus abdominis with the sheath can withstand up to 180N of force applied in a transverse direction, and requires sutures that retain high tensile strength when surgeries are performed (Carriquiry, 1996). Our study has described values as high as 420N for the baboon hypogastric LA and 280N for the goat epigastric LA, without the rectus abdominis muscle, when they were exposed to oblique and longitudinal traction respectively (Table 3, 5). This is suggestive of the important role the elastic fibres play in the dorsal rectus of the baboon and in the deep fascia

of the goat fibrous ventral abdominal wall. It is important to note however, tensile strength calculated as stress in N/mm^2 is more useful for analysis than using actual forces in Newtons.

The fibrous ventral abdominal wall was suited to accommodate the rapid acceleration/ deceleration forces associated with strenuous activity which might otherwise cause injury to the abdominal viscera as suggested by Kirker-Head et al, (1989). The latter further proposed that minimizing exercise and rectus abdominis palpation post-operatively reduces the likelihood of incisional dehiscence. The resistance of the fibrous ventral abdominal wall is important when planning the surgical repair of incisional hernias (Rath and Chevrel, 1997).

Transverse deformation of the epigastric abdominal wall is limited by the thoracic cage. The abdominal wall in this region experiences more deformation resulting from trunk movement than intra-abdominal pressure. Oblique fibers in linea alba transmit tension especially in trunk rotation. The hypogastric abdominal wall has been shown to respond more to a loading induced by intra-abdominal pressure (Acostasantamaria et al., 2015). The tensions, in fibrous ventral abdominal wall, is transmitted mostly by transverse fibers. Our study shows that the highest UTS was seen in the baboon umbilical DRS (95N/mm^2) and the goat umbilical VRS (125N/mm^2) when they were each exposed to transverse traction. Our findings suggests that in both animals, the fibrous ventral abdominal wall function correlates well with microstructure which in turn determines the macroscopic mechanical behavior.

The fibrous ventral abdominal wall has been seen as the decussation of the tendon fibers of the abdominal wall muscles. The three-dimensional fiber architecture of the fibrous ventral abdominal wall and its tensiometric characteristics shows the functional anatomical entity of this structure as it acts as the midline insertion of the abdominal wall muscles. Thus, it has to perform

the stabilization of the abdominal wall while the muscles resemble the dynamic elements (Grassel et al, 2005).

4.4 Conclusions

The findings of this study suggests that the collagen bundles with the heavy elastic fibre impregnation seen in the baboon dorsal rectus sheath and the unusually elastic rich deep fascia, which was closely apposed to the ventral aspect of the goat fibrous ventral abdominal wall, may constitute a strong fibroelastic “band-like” structure of variable tension” which would serve important adaptive functions. Furthermore, the baboon’s dorsal rectus sheath and the goat’s ventral rectus sheath, which had some of the highest amount of elastic tissue, exhibited a very high elastic coefficient when exposed to longitudinal traction. This suggests that the umbilical and hypogastric rectus sheath of the goat and the baboon are best suited for visceral support when the fibrous ventral abdominal wall is exposed to high pressures and tension. The intimate association of the elastic and collagen fibres observed embedded in or closely apposed to the fibrous ventral abdominal wall of the baboon and the goat may allow the strengthening of the wall, like the steel in tyres, thus reducing incidences of rectus diastases and hernia formation.

4.5 Suggestions for further studies

1. To study the microstructure and tensiometry of the fibrous ventral abdominal wall in different ages of baboon and goat
2. To study the microstructure and tensiometry of the fibrous ventral abdominal wall in the female baboon and goat.
3. To study the microstructure and tensiometry of the fibrous ventral abdominal wall in the pig and the cat.
4. To study the underlying molecular mechanisms that regulates the adaptive behavior of the fibrous ventral abdominal wall of the baboon and goat.

CHAPTER FIVE

5.0 REFERENCES

Abdin-Bey MR, Ramadan RO (2001). Retrospective study of hernias in goats. *Scientific Journal of King Faisal University (Basic and Applied Sciences) Vo.2 No.1 Dhu Al Hajjah* 1421: 77-88.

Abubaker AA, Andeshi RA, Yakubu AS, Lawal FM, Adamu U (2014). Comparative Evaluation of Midventral and Flank Laparotomy Approaches in Goat. *Hindawi Publishing Corporation Journal of Veterinary Medicine. Volume 2014, Article ID 920191, 6 pages* <http://dx.doi.org/10.1155/2014/920191>

Acostasantamaría VA, Siret O, Badel P, Guerin G, Novacek V, Turquier F, Avril S (2015)."Material model calibration from planar tension tests on porcine linea alba." *Journal of the mechanical behavior of biomedical materials* 43: 26-34.

Alexander RM (1984). Elastic energy stores in running vertebrates. *Am Zool*; 24: 85-94.

Anson BJ, McVay CB (1938). The anatomy of the inguinal and hypogastric regions of the abdominal wall. *The Anatomical Record* Vol. 70 (2) 211–225.

April WE (1997). Anterior Abdominal Wall. *Clinical anatomy*. Lippincot Williams and Wilkins. 3rd edition. 321.

Askar OM (1977). Surgical Anatomy of the Aponeurotic Expansions of the Anterior Abdominal Wall .*Annals of Royal College of Surgeons of England*, 59:313-321

Askar OM (1978). A New Concept of the Etiology and Surgical Repair Of Paraumbilical And Epigastric Hernias. *Annals of Royal College of Surgeons of England*.60:42-48.

Axer H, Keyserlingk DG, Prescher A, (2001a). Collagen Fibers in Linea Alba and Rectus Sheaths II. Variability and Biomechanical Aspects. *Journal of Surgical Research*; 96:239-245

Axer H, Keyserlingk DG, Prescher A (2001b). Collagen Fibers in Linea Alba and Rectus Sheaths II. Variability and Biomechanical Aspects. *Journal of Surgical Research*. 2001b; 96:239-245.

Bell EC, Gosline J M (1996) Mechanical design of mussel byssus: material yield enhances attachment strength. *J. Exp. Biol.* **199**, 1005–1017.

Beer GM, Schuster A, Seifert B, Manester M, Mihic-Probst D, Weber SA (2009). The normal width of the linea alba in nulliparous women, *Clin Anat* 22:706-11.

Bennett MB, Ker RF, Dimery NJ, Alexander RM (1986).Mechanical properties of various mammalian tendons. *J. Zool. Lond. (A)*.209, 537–548.

Berillon G, Vila PM, Lacosta R, Rimbaud B, Anvari Z, D’Aout K, Dussea SM, Moulin VM (2013). Biomechanics and control of walking in Olive baboons (*Papio Anubis*): New perspectives from trained and instrumented animals. *Folia Primatol* 84; 249.

Birk D, Trelstad R (1986). Extracellular compartments in tendon morphogenesis: collagen fibril, bundle and macroaggregate formation. *J Cell Biol*; 103: 231-240.

Bregio S, Rios O, Baigorria LJ (2003). Anesthetic protocol for surgical repair of an umbilical hernia in a Papion (Papion Hamadryas). *Internet Journal of Veterinary Medicine* 1:4-8

Brown SHM, McGill SM (2008). An ultrasound investigation into the morphology of the human abdominal wall uncovers complex deformation patterns during contraction. *Eur J Appl Physiol*. 104:1021-1030.

Bucknall TE, Cox PJ, Ellis H (1982). Burst Abdomen and Incisional Hernia: A Prospective Study of 1129 Major Laparotomies. *British Medical Journal*. 284:931-933

Calvi ENC, Nahas FX, Barbosa VJ, Ihara SSM, Calil JA, Ferreira LM (2011). Immunohistochemical analysis of collagen content and types in the rectus abdominis muscle of cadavers of different ages. *Acta Cir. Bras.* vol.26 supl.2. <http://dx.doi.org/10.1590/S0102-86502011000800002>

Carpenter RH, Riddle KE (1980). Direct inguinal hernia in the cynomolgus monkey (*Macaca fascicularis*). *Medical Primatology* 9:194-9,

Chaffee V, Shehan T (1973). Indirect inguinal hernia in two baboons. *Journal American Veterinary Medical Association*. 163:638.

Chouke K S, Friedman H, Loeb L. (1935). Proliferative activity of the thyroid gland of the female guinea pig during the sexual cycle. *The Anatomical Record*. Volume 63, Issue 2, pages 131–137, September 1935.

Cresswell AG (1993) Responses of intra-abdominal pressure and abdominal muscle activity during dynamic trunk loading in man. *European Journal of Applied Physiology and Occupational* 66(4): 315 -20

D'Aout K, Aerts P, Berillon G (2014). Using primate models to study the evolution of human locomotion: concepts and cases. *BMSAP*, 26 (3 – 4). Pp105 -110.

De Troyer A, Estenne M, Ninane V, Van Gansbeke D, Gorini M (1990). Transversus abdominis muscle function in humans. *J Appl Physiol* 68, 1010–1016.

Drury RAB, Wallington EA, CameronR (1967).Connective Tissue Fibers. Carleton's Histological Techniques.4th edition. New York. Oxford university press. 166-181

Findley T, Chaudhry H, Stecco A, Roman M (2012). Fascia research: Narrative review. *Journal of Bodywork and Movement Therapie* 16 (1):67-75 <http://dx.doi.org.ezproxy.wpi.edu/10.1016/j.jbmt.2011.09.004>

Fitzgibbons RJ Jr, Greenburg AG (2002). Nyhus and Condon's hernia, 5th edn. Lippincott Williams & Wilkins, Philadelphia

Gallaudet B.B (2008). A description of the planes of fascia of the human body with special reference to the fascia of the abdomen, pelvis, and perineum. Copyright Triggerband LLC

Gibson KT, Curtis CR, TurnerAS, Mellwraith CW, Aanes WA, Stashak TS,(1989). Incisional Hernias in the Horse: Incidence and Predisposing Factors. *Veterinary Surgery* .18; 360-366.

Gohar HM, Ramadan RO, Mugal H (1987). Umbilical and abdominal hernias in ruminants. *J. Egypt.Vet.Med.Ass.* 47:563-575.

Gosline J, Lillie M, Carrington E, Guerette P, Ortlepp C, Savage K. (2002). "Elastic proteins: biological roles and mechanical properties." *Philosophical Transactions of the Royal Society B: Biological Sciences* 357.1418 (2002): 121-132.

Grassel D, Prescher A, Fitzek S, Keyserlingk D G, Axer H (2005). ‘Anisotropy of human linea alba: A biomechanical study’, *Journal of Surgical Research* 124(1), 118 – 125.

Hodges PW, Butler JE, McKenzie D, Gandevia SC (1997). Contraction of the human diaphragm during postural adjustments. *Journal of Physiology.* 505:239–248.

Hodges PW, Gandevia SC (2000). Changes in the intra-abdominal pressure during postural and respiratory activation of the human diaphragm. *Journal of Applied Physiology*; 89:967-976.

Hollinsky C, Sandberg S (2006). Measurement of the tensile strength of the ventral abdominal wall in comparison with scar tissue. *Clinical Biomechanics* 01/2007; 22(1):88-92.

Huelke DF, Nusholtz GS, Kaiker PS (1986). Use of quadruped models in thoraco-abdominal biomechanics research. *Journal of biomechanics*, 19(12) 969-977.

Kielty CM, Sherratt MJ, Shuttleworth CA (2002). Elastic Fibers. *Journal of Cell Science.* 115:2817-2828.

Kimani JK (1993). Structural linkage between collagen and elastic fibres in the mammalian carotid sinus wall with special reference to baroreceptor mechanisms. *Discovery and innovation*, 5:51-56.

Kirilovam M, Stoytchev S, Pashkouleva D, Tsenova V, Kristoskova R (2009). Viscoelastic mechanical properties of the human abdominal fascia. *Journal of Bodywork & Movement Therapies*.13: 336-337.

Kirker-Head CA, Kerwin PJ, Steckel RR, Rubin CT (1989). The in vivo biodynamic properties of the intact equine linea alba. *Equine Veterinary Journal Supplement 7*. 1989; 98-106

Korenkov M, Beckers A, Koebeke J, Lefering R, Tiling T, Troidi H (2001). Biomechanical and Morphological Types of the Line Alba and Its Possible Role in Pathogenesis of Midline Incisional Hernia. *European Journal of Surgery* 167:909-914.

Kubo K, Kanehisa H, Kawakami Y, Fukunaga T (2000). Elasticity of tendon structures of the lower limbs in sprinters. *Acta Physiol Scand*; 168:327-335

Kureshi A, Vaiude P, Nazhat SN, Petrie A, Brown RA (2008). Matrix mechanical properties of transversalis fascia in inguinal herniation as a model for tissue expansion. *J Biomech*; **41**: 3462–3468.

La Bourene JL, Coles JG, Johnson DJ (1990). Alterations In Elastin And Collagen Related To The Mechanism Of Progressive Pulmonary Venous Obstruction In Piglet Model. A hemodynamic, ultrastructural and biochemical study. *Circulation Research* 438-456

McArdle G (1997). Inguinal hernia a defect in human evolution. *Clinical Anatomy*, Pages 47 – 55

McGill SM (1996). A revised anatomical model of the abdominal musculature for torso flexion efforts. *J Biomech* 29, 973–977

Moeinzadeh MH, Engin AE, Akka N (1983). Two-dimensional dynamic modelling of human knee joint. *J Biomech.*; 16(4):253-64.

Monkhouse WS, Khalique A (1986). Variations in the composition of the human rectus sheath: a study of the anterior abdominal wall. *J Anat*; 145: 61-66.

Muramatsu T, Muraoka T, Takeshita D, Kawakami Y, Hirano Y, Fukunaga T (2001). Mechanical properties of tendon and aponeurosis of human gastrocnemius muscle in vivo. *J. Appl. Physiol.*, 90(5):1671-8.

Mwachaka PM, Odula P, Awori KA, Kaisha WO (2009). Regional variations in the microscopic organization of the human rectus sheath. *Journal of Morphological Sciences*. 26(2):84-90.

Naraynsingh V, Maharaj R, Dan D, Hariharan S (2012). Strong linea alba: Myth or reality? *Med Hypotheses*. 78(2):291-2.

Niikura H, Okamoto S, Nagase S, Takano T, Murakami G, Tatsumi H, Yaegashi N (2008). Fetal development of the human gubernaculum with special reference to the fasciae and muscles around it. *Clin Anat*; 21:547-57.

Oakes BW, Bialkower B (1977). Biochemical and ultrastructural studies on the elastic wing tendon of the domestic fowl. *J. Anat.*123:369-383

Ogeng'o JA (2008). Structure and adrenergic innervation of the aorta in the goat (*capra hircus*). PhD thesis; University of Nairobi.

Ozdogan M, Yildiz F, Gurer A, Orhun S, Kulacoglu H, Aydin R(2006). Changes in collagen and elastic fiber contents of the skin, rectus sheath, transversalis fascia and peritoneum in primary inguinal hernia patients. *Bratisl Lek Listy*; **107**: 235 – 238.

Pans A, Pierard GE, Albert A (1999). Immunohistochemical Study of the Rectus Sheath and Transversalis Fascia in Adult Groin Hernias. *Hernia Springer Verlag* 45-51.

Park HS, Martin BJ (1993). Contribution of the tonic vibration reflex to muscle stress and muscle fatigue. *Scandinavian journal of work, environment & health*, 35-42.

Parry D, Craig A, Barnes R (1978). Tendon and ligament from the horse: an ultrastructural study of collagen fibrils and elastic fibers as a function of age. *Proc R Soc. Lond. B.*; 203: 293-303.

Pulei AN, Ogeng'o JA, Odula, P, Abdel-Malek A (2007). Sexual dimorphism and ageing changes of the human abdominal linea alba. *Journal of Anatomy.*767-775

Pulei AN, Odula PO, Abdel-Malek AK, Ogeng'o JA (2015). Distribution of elastic fibres in the human abdominal linea alba. *Anat. J. Afr.* 4 (1): 476 – 480.

Quintas ML, Rodrigues CJ, Yoo JH, Rodrigues Junior A (2001). Age Related Changes in the Elastic Fiber System of the Interfoveolar Ligament. *Review. Hosp. Clin.* 83-86

Ramadan RO, Abdin-Bey MR (2001). Abdominal and inguinal hernias in the camel (*Camelus Dromedarius*) in Saudi Arabia (Field Cases) *Emir. J. Agric. Sci.* (13):57-61.

Rath A, Attali P, Dumas J, Goldlust D, Zhang J, Chevrel J (1996), ‘The abdominal linea alba: an anatomico-radiologic and biomechanical study’, *Surgical and Radiologic Anatomy* 18(4), 281–288.

Rath A, Chevrel JZJ (1997). The sheath of the rectus abdominis muscle: an anatomical and biomechanical study. *Hernia* 1, 139–142.

Reed R (1973). Freeze-etched connective tissue. *Inten. Rev. connect. Tissue Research.* 6:257-305.

Richardson CA, Snijders CJ, Hides JA, Damen L, Pas MS, Storm J (2002). The relationship between the transversus abdominis muscles, sacroiliac joint mechanics, and low back pain. *Spine*; 27: 399-405.

Rizk NN (1980). A new description of the anterior abdominal wall in man and mammals. *J Anat*; 131(Pt 3):373-85.

Rizk NN, Adieb N (1982). The development of the anterior abdominal wall in the rat in the light of a new anatomical description. *J Anat*; 134(Pt 2):237-42.

Rose MD (1976). Bipedal behavior of Olive baboons (*Papio anubis*) and its relevance to an understanding of the evolution of human bipedalism. *Am J Phys Anthropol* 44:247-62.

Sandberg LB (1976). Elastic tissue in health and disease – Int. Rev. Connect. Tissue Res. 7, 159-210.

Schleip R, Duerselen L, Vleeming A, Naylor I.L, Lehmann-Horn F, Zorn A, Klingler W (2012). Strain hardening of fascia: static stretching of dense fibrous connective tissues can induce a temporary stiffness increase accompanied by enhanced matrix hydration. *Journal of bodywork and movement therapies*, 16(1), 94-100.

Schneider CA, Rasband WS, Eliceri KW (2012). NIH image to image: 25 years of image analysis. *New methods* 9(7): 671-5.

Schneider RK, Milne DW, Kohn CW (1982) Acquired inguinal hernia in the horse: a review of 27 cases. *Journal American Veterinary Medical Association*: 317-20

Seifert AW, Kiama SG, Seifert MG, Goheen JR, Palmer TM, Maden M (2012). Skin shedding and tissue regeneration in African spiny mice (*Acomys*). *Nature*. 489:561-566.

Shadwick R E (1990). Elastic energy storage in tendons: mechanical differences related to function and age. *J. Appl. Physiol.* **68**, 1022–1040.

Sinnatamby SS (2000) Abdomen. In: Last's Anatomy. London. Churchill Livingstone 10th Edition. 217-218.

Skandalakis JE, Colborn L, Skandalaki JL (1997). The embryology of the inguinofemoral area: an overview. *Hernia*; 1: 45-47.

Slatter DH (2003). Textbook of small animal surgery, Vol. 1 page 466. Elsevier health sciences Amazon.ca.

Smit TH (2002). The use of a quadruped as an in vivo model for the study of the spine-biomechanical considerations. *Eur Spine J.* 11:137-144.

Song AY, Askari M, AzemiE, Alber S, Hurwitz DJ, Marra KG, Shestak KC, Debski.R, Rubin JP (2004). Biomechanical Properties of the Superficial Fascial System. The Aesthetic Meeting 2004 of the American Society for Aesthetic Plastic Surgery (ASAPS). Inc. doi:10.1016/j.asj.2006.05.005

Standring S, Harold EH, Healy JC, Johnson DA, Williams PL (2008). Abdomen and pelvis. In Gray's Anatomy. The anatomical basis of clinical practice. Elsevier, Churchill Livingstone. 39th edition. 1105-1111.

Stecco C (2011)"The fascia: the forgotten structure". *Italian journal of anatomy embryology* 116(3):127

Studdert VP, Gay CC, Blood DC (2011). Saunders Comprehensive Veterinary Dictionary, 4thedn. Elsevier, Inc.

Tesh KM, Dunn JS, Evans JH (1987). The abdominal muscles and vertebral stability. *Spine,* 12(5), 501-508.

Urquart D, Parker P, Hodges P, Story I, Briggs C (2005).Regional morphology of the transverses, obiquus internus and externus muscle. *Clinical Biomechanics;* 233-241

Viidik A (1978). On the correlation between structure and mechanical function of soft connective tissue. *Verh. Anat. Ges.* 72: 75-76.

Warren RG, Piccoli, AJ(1979).Bilateral inguinal hernia in a pig-tailed monkey (*Macaca nemestrina*). *Laboratory Animal Science* 400-

Walmsley R (1937). The sheath of the rectus abdominis. *J. Anat.*; 404-414

Williams PL. (1995).Gray's Anatomy.38th ed. Edinburgh: Churchill Livingstone; P.825-9.

Wolinsky H, Glagov S (1964). Structural basis for the static mechanical properties of the aortic media. *Circulation Research*, 14(5), 400-413.

Yang J D, Hwang HP, Kim JH, Rodríguez-Vázquez JF, Abe SI, Murakami G, Cho BH (2012). Development of the rectus abdominis and its sheath in the human fetus. *Yonsei medical journal*, 53(5), 1028-1035.

Yami A, Merkel RC (2013). Sheep and goat production handbook for Ethiopia. Produced by Ethiopia sheep and goat productivity improvement program (ESGPIP). Funded by USAID. Chapter 7.

6.0 APPENDICES- Abstracts of publications

Research Article

Regional Variation in the Histomorphology and Tensile Strength of the Ventral Rectus Sheath in the Male Goat (*Capra Hircus*)

Odula PO*, Hassanali J¹ and Kiama SG*

¹Department of Human Anatomy, University of Nairobi, Kenya

²Department of Veterinary Anatomy and Physiology, University of Nairobi, Kenya

*Corresponding author: Odula PO, Department of Human Anatomy, University of Nairobi, P.O. Box 20540-00605 Nairobi, Kenya, Tel: +254-204442368; Mobile: +254-722773025; Email: paulodula@yahoo.com; odula@uonbi.ac.ke

Received: May 18, 2015; Accepted: July 14, 2015; Published: July 18, 2015

Abstract

The ventral rectus sheath (VRS) plays a key role in the stabilization of the ventral abdominal wall. This sheath has to be particularly strong in ruminants to accommodate the viscera and the large quantities of forage in their stomach. This study was conducted to establish the structural and the mechanical properties of the ventral rectus sheath in the goat, a browser, in order to elucidate its function. The ventral rectus sheath was formed by superficial and deep lamina consisting of obliquely aligned collagen fibers derived from the external and internal oblique abdominal aponeuroses respectively. Closely apposed and intimately held to the superficial lamina was a layer of longitudinally aligned elastic fibers, the tunica flava abdominis or modified deep fascia. This tunica flava abdominis progressively increased in thickness from the epigastrum to the hypogastrum. On tensiometry, the epigastric ventral rectus sheath withstood about half the load (50N/mm²) required to reach yield point compared to the umbilical ventral rectus sheath (94.5N/mm²). Furthermore, the Youngs modulus showed that the umbilical ventral rectus sheath was the stiffest at 669 (SD 22.2) N/mm² while the epigastric ventral rectus sheath was the weakest at 554 (SD 29) N/mm² respectively when exposed to longitudinal traction. In conclusion, the progressively thickening of the tunica flava abdominis and the superficial lamina from the epigastrum to the hypogastrum may confer reversible stretch ability and strength to the ventral rectus sheath and is therefore well suited for longitudinal load strength needed to support the compound stomach during browsing.

Keywords: Goat; Ventral rectus sheath; Collagen fibers; Tunica flava abdominis; Elastic fibers; Tensile strength

Abbreviations

LA: Linea Alba; EM: External Oblique Abdominis Muscle; RM: Rectus Abdominis Muscle; VRS: Ventral Rectus Sheath; EVRS: Epigastric Ventral Rectus Sheath; UVRS: Umbilical Ventral Rectus Sheath; HVRS: Hypogastric Ventral Rectus Sheath; PS: Pubic Symphysis; XP: Xiphoid Process; DF: Deep Fascia; SL: Superficial Lamina; DL: Deep Lamina

Introduction

The ventral abdominal wall is formed by the aponeurotic tendon of the abdominal wall muscles. The aponeuroses wrap the rectus abdominis muscle before forming the linea alba ventrally. The aponeuroses wrapping the rectus abdominis muscle ventrally is termed the ventral rectus sheath. It plays a key role in the stabilization of the ventral abdominal wall [1]. This tough tendinous structure is formed by the interlocking aponeurotic fibers of the external oblique abdominis and the superficial lamellae of the internal oblique abdominis [2,3]. In herbivores, the ventral rectus sheath is reinforced by the tunica flava abdominis which is part of the deep fascia of the trunk [4].

Ruminants like the goat, have a stomach capacity which is capable of accommodating large quantities of forages causing

marked abdominal distension. Furthermore, goats have the ability to stand on their hind legs for long periods and sometimes can even climb in order to reach parts of trees they prefer for browsing [5]. Studies on the human ventral rectus sheath provided insights into its biomechanical structure [1,6]. However, apart from the macroscopic work done by Walmsey, the structure of the ventral rectus sheath of the goat is largely unknown [2]. This is despite the fact that the ventral abdominal hernias are fairly common in goats [7,8]. For instance, retrospective studies by Abdin-hey and Ramadan reported a prevalence rate of ventral abdominal hernias of more than to 88% in adult goats who presented with hernia swellings [9].

The aim of this study is to describe the histomorphology of the ventral rectus sheath and evaluate its tensile strength in the goat. This may explain how the ventral rectus sheath of the goat, as a quadruped grazer and browser, is adapted to its function.

Materials and Methods

The ventral abdominal wall was harvested from 1-2-year old 6 (six) healthy male goats (*Capra hircus*) weight range 10-13kg. The goats were procured from a local butchery immediately after slaughter.

The skin and fascia were incised along a midline abdominal incision to form skin flaps that exposed the anterior abdominal wall

Regional Variation in the Microscopy and Tensile Strength of the Linea Alba in the Male Goat (*Capra Hircus*)

Paul Ochieng Odula, Jameela Hassanali, Stephen Gitahi Kiama

Correspondence to Dr. Paul O. Odula Department of Human Anatomy University of Nairobi P.O. Box 25540-00603 Nairobi, Kenya. +254-722773025; 254-204442368. paulodula@yahoo.com; odula@uonbi.ac.ke

ABSTRACT

The linea alba (LA), a midline tendinous structure formed by the interlocking anterior abdominal wall aponeurotic fibers, acts as a passive tensile band that prevents sagging of the lower abdomen. The microstructure and the strength of these fibres would thus be expected to reflect on the forces that act on the linea alba. This study was undertaken to establish the histomorphology, morphometry and tensiometric characteristics of the linea alba of the goat so as to elucidate on the elements that are responsible for maintaining the integrity of the wall. Tissues resected from the linea alba in six male goats and prepared for routine light microscopy and stained with Weigert resorcin–fuchsin stain revealed three distinct laminae namely a superficial, intermediate and deep. The superficial lamina of goat epigastric linea alba, which was closely apposed to the overlying elastic tunica flava abdominis (deep fascia), was made up of predominantly obliquely aligned collagen bundles, an intermediate lamina comprising longitudinally aligned collagen bundles and a deep lamina consisting of transversely oriented collagen fibres. When exposed to longitudinal traction, the epigastric LA on average was the stiffest at 35 N/mm² with an elastic coefficient 350 N/mm² while the hypogastric LA was the weakest at 26.5 N/mm² with an elastic coefficient 217 N/mm² respectively. In conclusion, the epigastric LA was well suited for longitudinal load strength to support the compound stomach during grazing while the relatively elastic hypogastric LA was most suited for allowing a degree of midline sagging during browsing. The variations noted in tensiometry suggest that the hypogastric linea alba is more compliant to stretch but more predisposed to tearing than the epigastric line alba especially when exposed to sudden violent force or trauma.

Key Words: linea alba, histomorphology, tensile strength, collagen fibers, elastic fibers.

INTRODUCTION

The linea alba (LA), a midline structure, together with the fibrous ventral abdominal wall plays a key role in the stabilization of the abdominal wall (Ayer et al 2001a). This tough tendinous structure is formed by the interlocking aponeurotic fibers of three ventrolateral abdominal muscles: external oblique, internal oblique and transversus abdominis muscle passing from one side to the other (Askar 1977; Standing 2008).

The function of the linea alba is to maintain the abdominal muscles, particularly the rectus abdominis muscles, at a certain proximity to each other (Beer et al, 2009). The linea alba in man has been described as composed of a highly structured meshwork of oblique and transverse collagen fibers (Ayer et al 2001a, Pulei et al 2015). Elastic fibres have also been found in the superficial lamina and in the lateral and the caudal parts of the LA (Pulei et al, 2015). These authors also noted that females had more transverse collagen and elastic fibres than males

Received 1st August 2015. Edited 9th September 2015. Published online 17th September 2015. To cite: Odula PO, Hassanali J, Kiama SG. Regional variation in the microscopy and tensile strength of the linea alba in the male goat (*capra hircus*). Anatomy Journal of Africa. 2015. Vol 4 (2): 555 – 562.