

CASE RECORDS AND COMMENTARIES

IN

OBSTETRICS AND GYNAECOLOGY

SUBMITTED BY

DR. JOHN M. MURIMA

**IN PART FULFILLMENT FOR THE
DEGREE OF MASTER OF MEDICINE**

IN

OBSTETRICS AND GYNAECOLOGY

OF THE

UNIVERSITY OF NAIROBI

University of NAIROBI Library



0393220 9

UNIVERSITY OF NAIROBI
MEDICAL LIBRARY

FEBRUARY 2005

USE IN THE LIBRARY ONLY

Table of contents

Abbreviations	i
Acknowledgement	ii
Declaration	iii
Certification	iv
Introduction	I

Obstetric short cases

1. Cervical incompetence – MacDonalld stitch insertion – live baby	22
2. Deep venous thrombosis – live baby	23
3. HIV infection in pregnancy – Elective caesarean section.....	44
4. Placenta praevia type IV – Caesarean section-live baby	56
5. Eclampsia – live baby.....	66
6. Retained placenta – manual removal	79
7. Unsensitised rhesus negative pregnancy.....	86
8. Breech presentation - Emergency caesarean section	97
9. Post date pregnancy - induction of labour - live baby	108
10. Pre-labour rupture of membranes (PROM) - Induction of labour	116
11. Gestational diabetes mellitus – live baby	125
12. Cardiac diseases Grade IV in pregnancy	137
13. Malaria in pregnancy	149
14. Two previous scars – Elective caesarean section.....	161
15. Twin pregnancy –Emergency caesarean section	171

Obstetric long Commentary

Title: Prevalence of foetal distress due to cord entanglement among patients undergoing emergency caesarean section delivery at Kenyatta National Hospital.....	182
---	-----

Gynaecology short cases

1. Endometriosis – Conservative surgical therapy	222
2. Ruptured ectopic pregnancy- Partial salpingectomy	234
3. Symptomatic uterine fibroids – TAH	242
4. Bartholin's abscess – Marsupialization done	251
5. Incomplete Abortion – MVA	257
6. Abdominal wound dehiscence – Secondary repair	264
7. Acute Pelvic Inflammatory disease – Antimicrobial therapy	271
8. Carcinoma of the ovary stage III – TAH + BSO + Omentectomy & Chemotherapy	278
9. Endometrial Carcinoma stage I – TAH + BSO	291
10. Carcinoma of the cervix stage IIIb – Radiotherapy	303
11. Choriocarcinoma – Remission after chemotherapy	314
12. IUCD with missing threads – Retrieval	326
13. Desired family size – BTL	333
14. Primary Infertility – Laparoscopic tuboplasty	341
15. Vesicovaginal fistula – successful repair	352

Gynaecology long commentary

Title: Pelvic abscess at KNH – A 5 year Retrospective study (1998-2002).....	366
1. Appendix 1	402
2. Appendix 2	407

DEDICATION

This book is dedicated to my mother Mrs. Rahab Wanjiku Murima for inspiring me to work hard throughout my education life.

Also dedicated to my wife Veronica Wairimu and my children, Lorna Wanjiku and Nick Murima

UNIVERSITY OF NAIROBI
MEDICAL LIBRARY

Abbreviations used

KNH	-	Kenyatta National Hospital
STI	-	Sexually Transmitted Infections
PID	-	Pelvic Inflammatory Disease
HIV	-	Human Immunodeficiency Virus
AIDS	-	Acquired Immunodeficiency Syndrome
HAART	-	Highly Active Anti-retroviral Therapy
MTCT	-	Mother to child Transmission
IUCD	-	Intrauterine Contraceptive Device
β-HCG	-	Beta Human Chorionic Gonadotrophin
BPD	-	Biparietal Diameter
AC	-	Abdominal Circumference
FL	-	Femur Length
HC	-	Head Circumference
KCCT	-	Koalin Cephalin Clotting time
PTI	-	Prothrombin Time Index
INR	-	International Normalized Ratio
ALP	-	Alkaline Phosphatase
ASP	-	Aspartate Aminotransferase
ALA	-	Alanine Aminotransferase
GGT	-	Gumma Glutamyltransferase
IVF	-	Invitro Fertilization
GIFT	-	Gametal Intrafallopian Transfer
UON	-	University of Nairobi
OBS/GYN	-	Obstetrics and Gynaecology

ACKNOWLEDGEMENT

I wish to express my most sincere gratitude to the following;

1. Ministry of health for sponsoring my training in M Med Obs/Gyn, University of Nairobi.
2. To all the consultants, Lecturers and senior registrars of the department of Obstetrics and Gynaecology for their dedication and commitment to see that I achieve the necessary skills and knowledge during my training at the University of Nairobi.
3. To Dr. J B O Oyieke and Dr. Kamau Gichuru for supervising my proposals and write up of my long commentaries.
4. To Dr. R M Rukaria, formerly a lecturer at UON, for her guidance and supervision of my proposals.
5. To Dr. Kiarie and Dr. Qureshi for their advice on my write up of the long commentaries.
6. To Alice Akinyi and Mbela of the department of medical records (KNH) for files' retrieval for the gynaecological long commentary.
7. To Mr. Alex of UON for assisting me in data analysis.
8. To Dr. S N M Maina for his criticism and suggestions on the long commentaries.
9. To Mr. Moses M Migwi for allowing me to access to his computer. Mr. Njuguna Migwi and Joan for the typing of the book
10. To all my colleagues for their support and encouragement to complete this course.

DECLARATION

This is to certify that the case records and commentaries presented in this book are my original work and were managed by me under the supervision of the senior members of the Department of Obstetrics and Gynaecology, Kenyatta National Hospital.

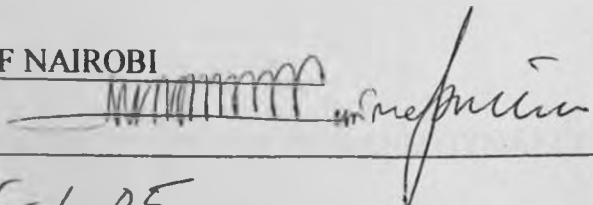
DR. JOHN M MURIMA

MBChB

UNIVERSITY OF NAIROBI

SIGNATURE

DATE


25-1-05

UNIVERSITY OF NAIROBI
MEDICAL LIBRARY

CERTIFICATE OF SUPERVISION

This is to certify that the long commentaries in this book by Dr. John M Murima were researched upon under my guidance and supervision and that this book is submitted with my approval.

1. DR. J. B. O. OYIEKE MBChB, M. MED
SENIOR LECTURER, CONSULTANT OBSTETRICIAN AND
GYNAECOLOGIST
AND
CHAIRMAN
DEPARTMENT OF OBSTETRICS AND GYNAECOLOGY
UNIVERSITY OF NAIROBI

Signature

Date

CERTIFICATE OF SUPERVISION

This is to certify that the long commentaries in this book by Dr. John M Murima were researched upon under my guidance and supervision and that this book is submitted with my approval.

2. DR. KAMAU GICHURU MBCHB, M. MED

HONORARY LECTURER AND CONSULTANT OBSTETRICIAN
AND GYNAECOLOGIST

DEPARTMENT OF OBSTETRICS AND GYNAECOLOGY

UNIVERSITY OF NAIROBI.

Signature

Date 26/1/2005

CERTIFICATION

This is to certify that Dr. Murima managed Obstetrics cases Nos. 1,2,3,4,7,14 and 15, and, Gynaecology cases Nos. 1,2,3,4 and 14, under my supervision at Kenyatta National Hospital.

SIGNATURE



DATE

30/1/005

PROF. S.B.O OJWANG MD, M. MED (OBS/GYN), DIP. ONCOLOGY

PROFESSOR


DEPARTMENT OF OBSTETRICS AND GYNAECOLOGY

UNIVERSITY OF NAIROBI.

CERTIFICATION

This is to certify that Dr. Murima managed Obstetrics cases Nos. 1,2,3,4,7,14 and 15. and, Gynaecology cases Nos. 1,2,3,4 and 14, under my supervision at Kenyatta National Hospital.

SIGNATURE _____



DATE _____

30-11-04

DR. NJOROGE GICHUII, MBChB, M. MED

CONSULTANT AND HEAD OF DEPARTMENT OF OBSTETRICS AND
GYNAECOLOGY

KENYATTA NATIONAL HOSPITAL.


HON. LECTURER – UNIVERSITY OF NAIROBI.

CERTIFICATION

This is to certify that Obstetric cases Nos. 5,8,10 and 11, and Gynaecology cases Nos. 7,8,9,10,11 and 15 were managed by Dr. Murima under my supervision at Kenyatta National Hospital.

SIGNATURE

DATE


26.01.05

DR. J B O OYIEKE MBChB, M. MED

SENIOR LECTURER AND CHAIRMAN


DEPARTMENT OF OBSTETRICS AND GYNAECOLOGY

UNIVERSITY OF NAIROBI

CERTIFICATION

This is to certify that Obstetric cases Nos. 5,8,10 and 11, and Gynaecology cases Nos. 7,8,9,10,11 and 15 were managed by Dr. Murima under my supervision at Kenyatta National Hospital.

SIGNATURE _____



DATE _____

26 Jan 2005

DR. KOIGI KAMAU MBChB, M. MED

SENIOR LECTURER


DEPARTMENT OF OBSTETRICS AND GYNAECOLOGY

UNIVERSITY OF NAIROBI

CERTIFICATION

This is to certify that Obstetric cases Nos. 5,8,10 and 11, and Gynaecology cases Nos. 7,8,9,10,11 and 15 were managed by Dr. Murima under my supervision at Kenyatta National Hospital.

SIGNATURE _____



DATE _____

26/1/05.

DR. MUIA NDAVI MBChB, M. MED, MSc.

SENIOR LECTURER


DEPARTMENT OF OBSTETRICS AND GYNAECOLOGY

UNIVERSITY OF NAIROBI

CERTIFICATION

This is to certify that Obstetrics cases Nos. 6,9,12 and 13, and Gynaecology cases Nos. 5,6,12 and 13 were managed by Dr. Murima under my guidance and supervision at Kenyatta National Hospital.

SIGNATURE _____



DATE _____

31.01.2005

PROF. KARANJA J G, MBChB, M. MED

ASSOCIATE PROFESSOR

DEPARTMENT OF OBSTETRICS AND GYNAECOLOGY


UNIVERSITY OF NAIROBI.

CERTIFICATION

This is to certify that Obstetrics cases Nos. 6,9,12 and 13, and Gynaecology cases Nos. 5,6,12 and 13 were managed by Dr. Murima under my guidance and supervision at Kenyatta National Hospital.

SIGNATURE

DATE


Jan. 28th 05

DR. MACHOKI M'IMUNYA MBChB, M. MED, ANDROLOGY

SENIOR LECTURER

DEPARTMENT OF OBSTETRICS AND GYNAECOLOGY

UNIVERSITY OF NAIROBI.

INTRODUCTION

KENYATTA NATIONAL HOSPITAL

Kenyatta National Hospital (KNH) is situated in the capital city of Kenya, Nairobi, about 3.5 kilometres from the city centre. It was started in 1901 as the Native Civil Hospital. It serves as a national referral centre as well as serving the population within and around the neighbouring countries of East and Central Africa.

It is currently administered as a state corporation through a parastatal board established in 1986 by an act of parliament. It is a training centre for undergraduate and postgraduate students from the college of Health Sciences of the University of Nairobi. It is also a training centre for Clinical officers, Nurses and other paramedical staff from the Kenya Medical Training College. The hospital is housed in a 10 storey-building complex with extensions or wings that serve as outpatient clinics, casualty unit, theatres and laboratories.

OBSTETRIC AND GYNAECOLOGIC SERVICES

Obstetric Services

The obstetric unit of Kenyatta National Hospital was commissioned in 1965. Initially it handled about 1,500 deliveries per year but currently it handles approximately 8,000 deliveries annually. Outpatient services are provided at clinic number 18 which include antenatal screening and follow up, adolescent clinic, Gynaecology outpatient clinic, and fertility clinic as well as family welfare clinic.

The in-patient department is comprised of labour ward, lying-in wards, neonatal unit and mothers' hostel. This is divided into three firms; each headed by a senior consultant Obstetrician and Gynaecologist, and senior Registrars, Intems, Nurses and paramedical staff. The consultants and senior Registrars are from both the University of Nairobi and Kenyatta National Hospital.

The department utilizes Kenyatta National Hospital laboratories and departmental laboratory, which also serves other University departments and whose facilities include radioimmunoassay, cytology, semen-analysis, surfactant bubble test, glucose tolerance test, bilirubin spectrophotometry and chromosomal analysis.

The Casualty Department

This has a receiving area for all Obstetrics and Gynaecologic emergencies. A medical officer under the supervision of senior members of staff screens all patients and admits those requiring emergency admissions. Others are treated and discharged home, while those who require specialized consultation are referred to the relevant clinics.

Antenatal Care (ANC)

Selection of patients with high risk factors in pregnancy and booking of mothers who wish to be followed up at Kenyatta National Hospital is done on every Monday morning by each of the three Firms on alternate bases. The midwives record the mothers' personal history, obstetric history, and medical and surgical history. Height measurement, weight, blood pressure and urinalysis are carried out on every patient. A senior registrar reviews all the patients and makes selection of high-risk patients for closer follow-up in the ANC. The high-risk mothers are selected according to the following criteria.

1. Primigravidae especially the teenagers, elderly, short or have pelvic deformity.
2. Grand multiparity (Para 5 and above)
3. Bad obstetric history (BOH). These include recurrent abortions, previous stillbirth and neonatal deaths.
4. Previous obstetric complications. These comprise postpartum haemorrhage, uterine rupture, and obstetric fistulae.
5. Medical conditions complicating pregnancy: anaemia, diabetes mellitus, thyroid diseases, renal disease and Deep venous thrombosis (DVT)
6. Previous operative delivery: caesarean section, vacuum extraction
7. Others include Rhesus incompatibility, multiple gestation and a pregnancy after prolonged infertility period.

Booked mothers get investigation forms completed for antenatal blood profile, which includes haemoglobin concentration, serology test for syphilis and Human Immunodeficiency virus (HIV) infection and blood grouping.

Trained counselors counsel the mothers before and after HIV testing. They are clerked by the senior house officers, who record medical, gynaecologic, obstetric and family history. The mothers are then examined, the findings are recorded on antenatal card and then given next appointment date.

Antenatal follow-up

The patients are seen four weekly up to 28 weeks gestation, two weekly up to 36 weeks then weekly until delivery. Each patient is treated on her own merit, and may be seen more often when necessary. Medical personnel from appropriate clinical disciplines give health education lectures to the patients in the morning when they report to the antenatal clinic.

Emphasis on better nutrition, importance of regular clinic attendance, psychological and factual preparation for labour and delivery, postnatal care and the need to make family planning decisions during the antenatal period.

At each antenatal visit the following are carried out:

1. The mother is weighed and the weight gained since the last visit is recorded.
2. Blood pressure is taken, recorded and compared with the previous readings.
3. Urine specimen is examined for proteins, sugar and leucocytes.

The mothers are then ushered into examination rooms where the senior house officers question the patient regarding symptoms and changes related to previous treatment. The abdomen is examined at each visit together with general physical examination. The fundal height is noted and the rate at which the uterus is enlarging is assessed. The foetal heart can be heard with the Pinnard's fetoscope after 24 weeks of gestation and the foetal lie and presentation can be determined with reasonable accuracy after 30 weeks of gestation.

The breasts are examined at least once during the third trimester of pregnancy. Those with inverted nipples are taught how to avert them in preparation for breastfeeding. This provides a good opportunity to discuss the importance of breastfeeding.

Patients with severe medical complications such as diabetes mellitus, pre-eclampsia, deep venous thrombosis (DVT), cardiac disease and severe anaemia during pregnancy are admitted to the various maternity wards for closer observation, investigations and management.

At 36 weeks, clinical pelvimetry is done on all primigravidae and patients with one previous scar. Radiology pelvimetry is performed on patients with one previous caesarean section with cephalic presentation, and those with breech presentation who have been assessed and found favourable for vaginal delivery.

At 38 weeks, amniocentesis for foetal lung maturity is performed for patients planned for induction of labour or delivery by elective caesarean section. This procedure may be performed earlier than 38 weeks gestation if there is an indication for it.

MARTENITY UNIT

The maternity unit is made up of labour ward, three antenatal wards and the newborn unit. Over 7,000 deliveries are conducted in labour ward annually. The labour ward has the first stage cubicles each with one bed, and two delivery suites with two couches each. In addition, there is an acute room for close monitoring of very sick patients and another room for giving oxygen by mask to mothers with foetal distress. There are two incubators, one in each delivery suite for transfer of preterm babies to nursery. There is an ultrasound machine used for inpatients. There are two operating theatres used for both emergency and elective obstetric surgery but only one is functional currently.

Each antenatal ward has 32-bed capacity and there is usually no distinction between how many are allocated for antenatal patients and how many are for postnatal patients. Registrars review all patients and do daily ward rounds, while major rounds are conducted once a week by the consultants in each firm.

The paediatrics department manages the newborn unit. It has five nursery cubicles one of which is an isolation area for infected babies and those born before arrival to hospital. There are 30 incubators and 10 cots in the newborn unit.

All newborn babies with problems or whose mothers are very sick are taken to the newborn unit for management. The obstetrics team works in close co-operation with the paediatricians and combined two weekly postnatal mortality meetings are held.

The booked patients present to the labour ward for admission. The unbooked or referred ones are admitted through casualty.

Patients who are not in labour or not requiring emergency care are transferred to the various antenatal wards for observation and management.

The firm on call manages labour ward each week. The team is composed of nurses, midwives, intern-doctors, registrars, senior registrars and consultants.

On admission, the intern-doctors and registrar respectively take full history and conduct a thorough physical examination of the patient.

First stage of labour

Patients in active labour are admitted in the first stage where a partogram is started at once. The partogram used in KNH labour ward has the alert and action lines already drawn and consists of the following.

1. Particulars identifying the patient, parity and time of admission.
2. Date and time on the onset of labour.
3. Date, time and mode of rupture of membranes as well as colour of liquor.
4. Half-hourly foetal heart rate monitoring.
5. Progress on descent of the foetal head into the pelvis.
6. Progress of cervical dilation recorded four-hourly.
7. Uterine contraction each 10 minutes, their frequency and duration.
8. Use of oxytocin, its concentration and rate of infusion.
9. Other drugs used, dosage and time administered.
10. Maternal vital signs (blood pressure, pulse rate, respiratory rate and her body temperature) are taken with pulse rate every half, pulse rate and respiratory rates two hourly and blood pressure and temperature four hourly.

Cervical dilation is recorded at the time of admission and then four hourly. The other parameters are charted every thirty minutes.

The patient is nursed in left lateral position and is reviewed at regular intervals by the registrar, during which appropriate interventions are effected.

Analgesia is provided by parenteral pethidine or tramadol. Patients with meconium staining of liquor but with regular foetal heart rates are maintained on oxygen by mask, 5% dextrose and nursed in left lateral position. Those with poor progress of labour are augmented with oxytocin infusion. Patients known to be seropositive for

HIV are not routinely done amniotomy until they attain a cervical dilatation of over 6cm or they are allowed to have spontaneous rupture of membranes.

Induction of labour is routinely performed in the morning, usually by amniotomy and oxytocin drip. Where indicated, Prostaglandin vaginal pessaries may be inserted the night before to ripen the cervix. Extra-amniotic prostaglandin induction is used in cases with intrauterine foetal death.

Speculum examination

This is done inpatients with antepartum haemorrhage or premature rupture of membranes. The patient is placed in dorsal or semi-lithotomy position and the vulva cleaned with antiseptic and draped. An appropriate sized Cusco's speculum is selected. It is then lubricated with a gel. The labia are parted with the left hand, and a speculum held with the right hand. It is then inserted through the introitus with the jaws in a cervical plane, and gently rotated while being advanced into the horizontal plane. The speculum jaws are opened once the speculum is advanced fully into the vagina. With the aid of a good light source, the vaginal walls, the cervix and any lesions, bleeding or liquor draining through the cervical os are noted.

Vulvovaginal toilet

The patient is placed on her dorsal position with her lower limbs folded at the knees and wide apart.

The examiner wears sterile gloves and uses sterile swabs soaked in an antiseptic solution. Five soaked swabs are held with the right hand and one is dropped at a time to the left hand. The left hand is then used to swab the vulva. The distal labia minora are swabbed anteroposteriorly, followed by proximal labia minora, then the distal labia majora, and then the proximal labia majora.

The left hand is then used to part the labia exposing the introitus. The last swab in the right hand is then used to swab the urethra and vestibule anteroposteriorly. Digital examination then follows.

Surgical scrubbing

The surgeon must first wear the standard theatre attire on entering the operating rooms with the hair covered and wearing a facemask. Before scrubbing one may add a waterproof apron. The surgeon then proceeds to scrub.

The elbow tabs are adjusted to appropriate flow. The hands are then wetted with water followed by addition of soap or antiseptic liquid from a dispenser. The soap is rubbed over the hands, forearm, and up to 5cm above the elbow for at least one minute. Then these are rinsed with water. A sterile brush is then added soap or antiseptic and used to scrub. First, one scrubs the lateral side of the thumb, then medial side, then lateral and medial side of each successive finger. Then the nails are scrubbed, followed by the back and front of the forearm up to the elbow. The same is done for the other arm. This is repeated three times.

Finally, the brush is dropped to a receiver and the hands are then added soap and rubbed up to the elbow for about another minute. The hands are then rinsed with flowing water. The hands are then dried with two towels, one for each hand. The drying starts at the palms followed by the digits, then progressing up towards the elbow.

Second stage of labour

Once confirmation of full dilation of the cervix is done in the first stage section, the patient is then taken to the second stage room. The vulva and perineum are prepared by performing a vulvovaginal toilet, and the perineum draped with sterile towels. The patient is then instructed to bear down with each uterine contraction.

The perineum is supported by the right hand with a sterile pad, while the left hand keeps the head in flexion to prevent sudden expulsion. This prevents sudden trauma of the perineum and to the foetal head in preterm babies.

Once delivery of the head occurs, the mouth and nares are wiped with sterile gauze to prevent aspiration of blood or amniotic fluid. A finger is passed around the neck to check for the umbilical cord. When found and if loose, the cord is slipped over the head. If it is tight, it is double clamped and divided. After restitution and external rotation has

occurred, the anterior shoulder is delivered by upward traction. The rest of the body easily follows. The cord is clamped and divided. The mother is shown the baby briefly before the baby is handed over to another midwife who will carry out oral-pharyngeal suction as required. In high-risk cases, a paediatrician is usually in attendance.

Third stage of labour

At the delivery of the anterior shoulder, 0.5 mg of ergometrine is given intramuscularly to effect contraction of the uterus. For patients with history of post-partum haemorrhage and grand multiparity, ergometrine is given intravenously for more rapid action. For cardiac and hypertensive patients, oxytocin 5 international units is given as an intravenous infusion if uterine contraction does not occur spontaneously.

The placenta and membranes are delivered by controlled cord traction. The birth canal is inspected for any tears and the episiotomy is repaired. The patient is encouraged to empty her bladder. Post delivery blood pressure, pulse rate, uterine contraction and lochia loss are observed and recorded. The patient is further observed for 1 hour and then transferred to the lying-in wards for further overnight observation. The patients who had normal delivery are discharged after 24 hours due to pressure of bed space. They are nursed together with their babies to establish good location and bonding. The patient is advised on perineal hygiene and frequent saline sit baths until healing of episiotomy is achieved.

OPERATIVE PROCEDURES

Episiotomy

A medio-lateral or midline episiotomy is performed at crowning of the foetal head at the perineum in all cases where the perineum is tight and for some of operative vaginal deliveries and pre-term deliveries. A medio-lateral episiotomy is commonly used in this unit because it has less risk of extension to the anal sphincter and rectum.

During repair, a gauze pack is inserted into the vagina. The apex at the vaginal mucosa is identified. From the apex, repair of vaginal epithelium is carried out using continuous chronic catgut number 2/0. The perineal muscles are then approximated using deep interrupted sutures. The skin edge is then apposed using interrupted or continuous catgut

number 2/0, burying the knots by starting from the lateral edge. The patient is advised on maintaining the perineum and having frequent saline sit baths until the healing occurs.

Vacuum Extraction

The common indications for assisted vacuum delivery are poor maternal effort, foetal distress or cord prolapse with a fully dilated cervix, and in patients with cardiac disease. The patient is placed in lithotomy position and a digital examination is performed to confirm a fully dilated cervix and cephalic presentation. The largest ventouse cap that fits into the vagina is applied to the foetal scalp close to the occiput. The index finger of the right hand is passed around the perineum to ensure that the maternal tissue (cervix and vaginal) is not trapped within the cup. The vacuum suction pressure is gradually increased at a rate of $0.2\text{kg}/\text{cm}^2$ to between 0.5 and $0.8\text{kg}/\text{cm}^2$. This allows for the formation of an artificial caput or 'chignon'. A medio-lateral episiotomy is made under local anaesthesia, if required at the time the head is crowning.

The traction pressure or pull is applied along the midline of the pelvis and simultaneously with the uterine contractions. Once the baby's head is delivered the ventouse cup is released immediately and the second and third stages of labour conducted as usual.

CAESAREAN SECTION

The lower segment caesarean is the commonest major obstetric operation performed either electively or as an emergency. Classical caesarean section is rarely performed except for case of transverse lie with ruptured membranes.

Preoperative Management

The haemoglobin estimation and blood grouping plus cross matching are carried out. Those undergoing operation electively are starved for 6 hours prior to the operation. Informed consent for the operation and for general anaesthesia is obtained. Two units of compatible blood are obtained. The abdominal wall, vulva and perineum are shaved clean. Pre-medication is given in the form of Atrophine Sulphate 0.6mg intramuscularly half an hour before going to theatre. In cardiac patients, 0.4mg of Hyoscine is used instead.

Surgical procedure

In theatre, the patient is placed in supine position and an intravenous infusion is started through a large bore needle. In semi-lithotomy position, the vulva and perineum are cleaned with 1% savlon (chlorhexidine) solution. Aseptic catheterization is carried out and all the urine drained and the catheter is retained to provide continuous bladder drainage during the operation. The patient is then repositioned to supine position.

The anterior abdominal wall is then cleaned with antiseptic solution and iodine/spirit solution (betadine). Then draping with sterile drapes is done exposing only an area bounded by the mons pubis below to about 4cm above the umbilicus and 2cm on each side of the midline if sub-umbilical midline incision is to be used. If a Pfannenstiel incision is to be used, the upper draped border need to be placed above the umbilicus. Then 100% pre-oxygenation is given to the patient for five minutes then general anaesthesia is induced using intravenous thiopentone sodium 250 to 500mg depending on patient's weight. A short neuromuscular blocking agent suxamethonium 100mg is used to provide muscle relaxation. Anaesthesia is maintained with nitrous oxide and oxygen in the ratio of 1:1 before the baby is delivered, then a ratio of 2:1 is given. A total of 6 to 8 litres per minute is used depending on the circuit used.

Throughout the operation, halothane 0.5% or trilene 0.35% is used to maintain unawareness. When the effect of suxamethoneum has worn off, pancuronium or d-tubocurare a long acting muscle relaxant is used.

The abdomen is opened in layers through either a pfannensteil incision or a midline sub umbilical incision or rarely a paramedian incision.

With a clean knife, the incision is deepened, the rectus sheath is divided and elevated with two long artery forceps and the muscles are separated from their attachment to it by blunt dissection and then drawn to one side to expose the peritoneum. The latter is held with two straight artery forceps and opened taking care not to injure the gut. The incision limits are extended with index and middle fingers of the left hand placed intra-peritoneal guiding the scissors, avoiding injury to the bladder and bowels.

The uterus is then identified; wet and warm sterile abdominal packs are placed on either side of the uterus to prevent spillage of blood and liquor into the peritoneal cavity and to

protect the gut. A Doyen's retractor is then used to reflect the bladder downwards as well as to expose the uterovesical fold of peritoneum. Using a non-toothed dissecting forceps the loose peritoneum over the lower uterine segment is picked up and incised with curved scissors in an elliptical manner. The peritoneum is then stripped off the lower uterine segment with a mounted swab. The Doyen's retractor is shifted to include the lower part of the peritoneal fold in retracting the bladder away from the lower uterine segment. The lower uterine segment is then incised in the midline about 2cm below the uterine attachment of the uterovesical peritoneal fold. Once the membranes are reached, the incision is extended laterally on either side in an elliptical manner using curved scissors directed by two fingers of the left hand and the incision is enlarged enough to allow delivery of the head and trunk. The retractor is removed and the membranes are ruptured allowing some liquor to escape. The hand is slipped into the uterus between the foetal head and symphysis pubis, and the head is lifted gently with the fingers and palm through the incision while a modest fundal pressure is applied. After delivery of the head, the nostrils and the mouth are wiped. The shoulders are then delivered using gentle traction. The trunk delivery follows readily. The anaesthetist gives intravenous ergometrine 0.5mg after delivery of the shoulders. The cord is then clamped and divided, and the baby is handed over to a midwife or assistant for resuscitation.

The placenta and membranes are delivered manually or by controlled cord traction. Green armytage (uterine clamps) are used to hold the cut edges of the uterus to control bleeding and then inside of the uterus is wiped of clots and membranes. If the cervix was not dilated in labour, it is dilated at this juncture with a mounted swab to allow postpartum lochia drainage. The uterus is then repaired with or without lifting it out through the incision. The uterus is closed with a number 2 chromic catgut suture in two layers; as a continuous stitch for both layers, the second layer burying the first and extending beyond its lateral cut edges. The visceral peritoneum is then closed with number one plane catgut continuous stitch.

The abdominal packs are then removed, the abdomen is mopped and the pelvic viscera are inspected for any abnormality. Instruments and swabs are counted, if reported correct with the initial count, the abdomen is closed in three or four layers. Number 1 chromic

catgut is used on the peritoneum while number 2 chromic catgut is used as a continuous stitch on the rectus sheath. The skin is closed with interrupted nylon or silk suture or with subcutaneous vicryl 2/0. The wound is cleaned with normal saline, and then painted with iodine solution if it is available. The wound is then covered with a gauze and light strapping applied to hold the dressing in place. The catheter is removed and colour of the urine is noted. The uterus is massaged and any blood clots are expelled or evacuated from the vagina. A clean vulval pad is applied.

General anaesthesia is reversed with 1.2mg atropine sulphate and 2.5mg of neostigmine. Ex-tubation is done and oropharyngeal suction carried out. Blood loss is estimated and recorded, and the patient is transferred to the recovery room, then later to labour ward as the anaesthesia wanes.

Post operative care

The pulse, blood pressure, temperature and respiratory rate are observed and recorded quarter hourly until the patient is fully awake and then four hourly. Intramuscularly Pethidine 50 to 100mg is given four to eight hourly for 48 hours for pain relief depending on the patient's weight. When the patient is allowed oral intake, analgesics are given as oral Paracetamol 1000mg 8 hourly. Prophylactic antibiotics are administered routinely to all patients. Initially the patient is observed in the labour ward and if her general condition remains stable and satisfactory, she is transferred to the lying-in wards. Early ambulation is encouraged.

Haemoglobin and urine bacteriological examination are done on the third postoperative day. Two to three litres of intravenous fluids are given in the first 24hours (with at least 500mls of normal saline).

Normal diet is gradually introduced after free fluids and light diet. All stitches are removed on 7th postoperative day and the patient is discharged home with a case summary. She is advised to attend child welfare clinic and postnatal clinic in two and six weeks respectively.

Care of the newborn

All the newborn babies who are normal join their mothers after delivery unless the mother is moribund. A paediatric registrar reviews all the babies with problems or where complications are anticipated or babies delivered by operative vaginal delivery or by caesarean section. Those having problems or who are expected to develop some problems are transferred to nursery in a warm incubator. Premature babies are managed in nursery until their weight is about 2000grams upon which they are discharged. All babies are immunized with BCG before discharge. The recuperating mothers who have babies in nursery are lodged in a mothers hostel.

Post Natal follow-up

The clinic is held on every Friday. Only those patients who had a complicated or operative delivery are seen. The rest are followed up in their nearest facility. In this clinic the blood pressure and weight are taken, urinalysis performed, history of puerperium, lactation and immunization of the baby is taken. The patient is then examined and any problems managed. The family planning advice is given and the patient is referred to the family planning clinic for appropriate method.

Family Planning Clinic

The clinic used to be at family welfare centre (clinic 66) but is currently in clinic 18. Oral, injectable contraceptives, norplants, intrauterine contraceptive devices and barrier method are offered. Patients requiring postpartum sterilization are prepared for operation in the wards then taken to theatre with an informed consent duly signed.

THE GYNAECOLOGIC UNIT

This is comprised of an outpatient consultant clinic and wards 1B and 1D on the first floor of the tower block. In ward 1D, emergency services are provided throughout the 24 hours and is manned by acute gynaecology team who include a registrar, interns and supervising consultants.

The Gynaecology Clinics

There are three outpatient clinics per week; Firm I on Tuesday, Firm III on Wednesday and Firm II on Thursday. At any time, there are one or two consultants, several senior

registrars, registrars, medical students and nurses. There is an additional oncology patients who are on follow-up.

A colposcopy clinic is held every Friday morning for further evaluation of patients with abnormal cervical cytology. A fertility clinic is held every Monday afternoons. Majority of patients attending gynaecology clinic are referred from other specialist clinics of Kenyatta National Hospital, other hospitals in and around Nairobi as well as from district and provincial hospitals. Infertility cases constitute two thirds of the gynaecology consultations, followed by uterine fibroids, abnormal uterine bleeding and adnexal masses. In the clinic, history is taken and a thorough physical examination is conducted. Most of the investigations are carried out while the patient attends the clinic in order to reduce the hospital stay.

Elective gynaecology admissions - ward 1B

This is the non-emergency ward to which patients are usually admitted from the clinic or are transferred from the acute gynaecologic ward for further management. The ward has 32 beds divided among the three firms. Commonly, the patients admitted here have uterine fibroids, genito-urinary fistulae, gynaecological malignancies and infertility among others.

Acute gynaecological – ward 1D

This is the emergency gynaecology ward and it has 32 beds, with each room having 8 beds. On average, 15 to 25 patients are admitted daily and majority of cases are abortions. They are examined by the registrar who undertakes the management in consultation with senior members of the firm. Other common cases include ectopic pregnancies, acute pelvic inflammatory disease (PID) and pelvic abscess.

Uncomplicated cases of incomplete abortion have uterine evacuation done using Karman's canula and syringe. They are discharged home on the same day if they are stable, or the next day after overnight observation and treatment in the ward. They are also counseled for contraception and those willing are put on a method of contraception before discharge. Patients who have undergone emergency laparotomy for ectopic pregnancy, pelvic mass or abscess have a minimum stay of four days postoperatively.

Patients with suspected carcinoma of the cervix and who require admission are admitted to this ward. They receive emergency care; blood transfusion, antibiotic and analgesic treatment and investigations carried out. Thereafter, the patients are prepared for examination under anaesthesia (EUA) in the Caesium theatre for staging and biopsy. They are then transferred to the oncology ward for definitive management on receiving the histology report.

GYNAECOLOGICAL OPERATIONS

A theatre is always reserved for emergency gynaecologic operations on daily basis. Laparotomies for ectopic pregnancies, ovarian cysts, tubo-ovarian masses, pelvic abscesses and other minor operations such as marsupialization, removal of misplaced intra-uterine devices, diagnostic and suction curettage of uterus are done here.

Elective operations are done on Firm basis, Firm II on Mondays while Firm Firm III and I on Thursdays. The operations are done from 8 a.m. to 5 p.m.

The operations are done under general anaesthesia in which intravenous sodium thiopentone and succinylcholine are used for induction of anaesthesia. Nitrous oxide, oxygen and halothane are used for maintenance of anaesthesia. Curare is given intermittently for muscle relaxation. Atropine and neostigmine are used for reversal.

Pre-operative preparation

Patients for emergency laparotomies are prepared for theatre immediately in ward ID. Pre-medication with atropine 0.6mg intramuscularly is given half an hour before theatre. Blood is cross-matched and intravenous drip commenced. For elective operations, basic and specialised investigations are carried out and the date for surgery fixed. The patient is explained the nature and purpose of the operation, and she then gives an informed consent. The patient is starved for midnight on the evening prior to the operation. A soap enema is given in the morning and the abdomen plus pubic hair is shaved. Pre-medication is given in form of atropine sulphate 0.6mg and pethidine 50mg intramuscularly half an hour before theatre.

Postoperative Care

Vital signs are observed half hourly until the patient fully recovers from anaesthesia and then 4 hourly thereafter. Antibiotics, usually crystalline penicillin 2 mega units six hourly and then gentamycin 80mg eight hourly for the first two days then oral amoxicillin 500mg eight hourly for five days are given. The patient is maintained on intravenous fluids of about 2.5-3.5 litres per day until she is able to take orally. Pethidine 50 to 100mg is given every 6 or 8 hours for analgesia during the first 48 hours and thereafter, oral analgesics are given. Oral feeds are re-started after ascertaining the establishment of bowel sounds. Early ambulation is encouraged to decrease the incidence of deep venous thrombosis. Postoperative haemoglobin level is checked on the third postoperative day. The wound is inspected on the fourth postoperative day and if it is satisfactory, the patient is allowed home for the removal of the non-absorbable sutures on the 7th postoperative day at the nearest health facility. The patient is discharged home with a discharge summary and booked for review in the gynaecology outpatient clinic after six weeks.

Total Abdominal Hysterectomy

General anaesthesia induction and maintenance is done as described above. A vulvo-vaginal toilet is performed with savlon (chlorhexidine) solution. The bladder is catheterized aseptically and the catheter left in situ to provide continuous bladder drainage during the operation. Pelvic examination under anaesthesia is performed and pathological and normal findings noted. The vagina is painted with methylene blue.

The abdomen is then cleaned with chlorhexidine and painted with iodine solution followed by draping with sterile towels. The abdomen is opened in layers as described for caesarean section.

The bowels are packed away from the pelvis using warm moist packs after general inspection of the abdomen viscera.

The round ligaments on either side are identified, clamped using straight long artery forceps and divided between the two forceps. The lateral lumps are each transfixed with number 2 chromic catgut. The anterior leaf of the broad ligament is parched forwards and incised with scissors. The next step depends on whether the fallopian tubes and ovaries are to be preserved or not. If they are to be preserved, the tube and the ovarian ligament

are double clamped en-masse and cut using a scalpel. The distal clamp holds the ovarian vessels as they approach where they anastomose with the uterine vessels. This stump is tied with a transfixing chromic catgut number 2 suture. The same is done on the opposite side. If the tube and ovaries are to be removed with the uterus, the infundibulopelvic portion of the broad ligament is double clamped with long curved artery forceps with the tips reaching the open window in the broad ligament. The ligament together with the ovarian vessels is divided between the clamps and tied using chromic catgut number 2. The same is repeated on the opposite side.

The reflection of the bladder peritoneum onto the uterus is then freed by extending the incision in the anterior leaf of the broad ligament towards the midline. The bladder is thus separated from the lower uterine segment, the cervix and vaginal vault by careful blunt sharp dissection of the fascial fibres beneath the bladder wall. Usually the bladder can be displaced into the lower pelvis quite easily but if it is adherent, it is surgically released.

The posterior leaf of the broad ligament on either side is cut parallel with the side of uterus to better demonstrate and skeletonise the uterine vessels between the leaves of the broad ligament for clamping. The uterine vessels are double clamped and cut using a scalpel and freed from the uterus by extending the incision around the tip of the distal clamp. This enables adequate ligation. Care should be taken to avoid freeing the tissue beyond the tip of the clamp, as this could permit bleeding from vessels that are not included in the clamp.

Before clamping and cutting the uterine vessels, it is always advisable to palpate the lower portion of the pelvic ureters as they cross beneath the uterine artery, lateral to the internal os, and pass medially through the base of the broad ligament to the trigone of the bladder.

The uterine vessels are ligated with chromic catgut number 2. The uterus is retracted forwards and upward to demonstrate and stretch the uterosacral ligaments posteriorly. A transverse incision is made through the uterine reflection of the cul-de-sac peritoneum

between the attachments of the two-uterosacral ligaments. The peritoneum is then incised with the scalpel and reflected mobilizing it past the cervix to the posterior vaginal fornix. Each uterosacral ligament is double clamped, cut and transfixed using chromic catgut number 2 sutures. Here, particular care is exercised to avoid the pelvic portion of the ureter as it courses along the base of the broad ligament. The cardinal ligaments of either side of the uterus are then clamped, cut and tied.

The anterior vaginal fornix is opened and the vagina is circumcised by sharp knife or dissection by scissors round the cervix. The uterus together with its cervix is delivered as the anterior, posterior and lateral angles of the vaginal are secured with long straight artery forceps. The vaginal margins are then closed using a series of figure of eight interrupted sutures. Particular care is taken when tying the lateral angles to ensure that the descending vaginal branches of uterine vessels are securely ligated.

Suspension of the vaginal vault is done by tying the peritonealisation suture to the lateral and mid sutures of the vault. Peritonealisation is accomplished by means of a continuous number 1 chromic catgut suture that first pierces the vaginal walls close near the midline and passes through the posterior leaf of the broad ligament, the free margin of the uterosacral ligament, then through the infundibulopelvic ligament, the free margin round ligament and the anterior bladder peritoneum. The suture is tied at the centre.

The same is repeated on the opposite side with the suture being tied at the midline.

The abdominal viscera are inspected. If haemostasis has been achieved and instruments and swabs counts are correct, the abdomen is closed in anatomical layers.

General anaesthesia is reversed and patient is then managed as described in postoperative care above.

COUNSELLING CLINICS

There are four such clinics in the hospital, which offer counseling to obstetrics and gynaecology patients. These are the: 1) patient support centre, 2) gynaecological outpatient clinic, 3) high risk teenage clinic, 4) the Nairobi Hospice.

THE PATIENT SUPPORT CENTRE

This is situated in the old hospital building where patients regularly attend from all departments of the hospital. Sometimes the counselors are called to the wards to counsel those patients who cannot go there. The counselors consist of psychiatrists, sociologists, psychologists and nurses. Mostly, they deal with HIV counseling, puerperal psychosis patients, bereaved patients and support for those patients who are poor and neglected by relatives. They counsel, treat and even assist patients find their way home.

THE HIGH RISK CLINIC (HRC)

This clinic is situated on the ground floor next to the maternity wards. It deals with young single mothers who have had an abortion, those who have delivered babies and even those who do not want to bring up their children. These counselors may be nurses, sociologists or consultant obstetricians and gynaecologists.

They counsel their clients, treat them for any illness they may have with assistance from the obstetric and gynaecology wards and also provide them with family planning and sexual transmitted infection management services. The patients come from other institutions or from the obstetrics and gynaecology wards.

THE NAIROBI HOSPICE

Workers here also offer counseling care in addition to management of terminal disease. They also offer narcotics analgesia and encourage home-based care for such patients instead of hospital care. Most of their patients have cancer of the cervix.

THE HOSPITAL CHAPEL

This provides spiritual nourishment to those who are in need. It is situated on level 2 of the tower block.

THE MOTHERS HOSTEL

This accommodates mothers with babies in nursery. When they get sick, they are treated from the wards where they were initially admitted.

OBSTETRICS SHORT CASES

Case No. 1

CERVICAL INCOMPETENCE-MACDONALD STITCH

INSERTION-TERM DELIVERY

Name:	L.M	Parity:	0+3
Age:	22 years	DOA:	16.03.04
IP NO:	0948466	DOD:	18.03.04

Presenting Complaints

She was admitted through the antenatal clinic for Macdonald stitch insertion because of repeated pregnancy losses in the second trimester. At the time of admission, she did not have any complaints.

Past obstetric and gynaecologic history

She was a para 1+2 with no living child. Her first pregnancy was in 1999, which ended-up with spontaneous abortion at two and a half months gestation. She had per vaginal bleeding accompanied by lower abdominal pain followed by the expulsion of the foetus. She had manual vacuum aspiration (MVA) done. The second pregnancy was in 2002 and had a premature birth at 30 weeks gestation. She had drainage of liquor followed by lower abdominal pain and then premature birth. The infant died 5 days later due to prematurity. The third pregnancy loss was in 2003 at 24 weeks gestation. She had sudden drainage of liquor followed by lower abdominal pain and expulsion of the foetus.

She had menarche at 14 years. Her menses lasted 3 to 4 days, had a 28-30 days cycle and were regular, with no associated dysmenorrhoea. She had never used any form of contraception.

History of the present pregnancy

Her last menstrual period was on 7/12/2003 and her expected date of delivery was 14/9/2004 giving a gestational age of 14 weeks and 4 days. She had booked her antenatal clinic at Kenyatta National Hospital at 10 weeks gestation.

A pelvic examination done on her first antenatal visit had revealed short a cervix (1.5cm long) but the os was closed.

There were no obvious cervical defects detected. Given her past obstetric history plus the pelvic examination findings, she was planned for cervical cerclage due to incompetent cervix.

Past Medical and Surgical History

This was not contributory.

Family and Social History

She was married, a housewife and her husband was a second-hand clothes businessman. They stayed at Kayole. Neither smoked cigarette nor consumed alcohol. She had no family history of chronic illnesses.

Physical Examination

General Examination

She was a young lady in good nutritional status. She had no pallor, no jaundice, afebrile, no peripheral oedema and no lymphadenopathy.

Vital signs: -

- Blood pressure – 110/70mmHg
- Pulse - 76/minute, regular and good volume
- Respiratory rate – 18/minute
- Temperature – 36.8°C

Abdominal examination

The abdomen was slightly distended in the lower half and moved with respiration. The fundus corresponded to 14 weeks gestation and there was no tenderness. She had no hepatosplenomegally.

Pelvic Examination

The external genitalia was normal. The cervix was short (1.5cm), soft, posterior and the os closed.

Other Systems

The cardiovascular, central nervous and respiratory systems were normal.

Diagnosis

An impression of cervical incompetence at 14 weeks was made.

Investigations

- 1) Blood group O and Rhesus positive
- 2) VDRL – negative
- 3) ELISA (HIV) – negative
- 4) Total blood count –
 - WBC – $9 \times 10^9/L$
 - Hb - 14.3g/dL
 - Haematocrit -43%
 - Platelets - $298 \times 10^9/L$
- 5) Urea and electrolytes
 - Urea – 2.6 mmol/L
 - Potassium – 3.7 mmol/L
 - Sodium – 135 mmol/L
- 6) Fasting blood sugar – 4.1 mmol/L
- 7) Brucella titres – Negative, Toxoplasmosis – IgG Negative.
- 8) Anti – Nuclear antibody – Negative
- 9) Ultrasound.

Ultrasound done at 12 weeks gestation had revealed a viable intrauterine foetus at a gestation of 12 weeks 2 days. There was no obvious congenital malformation detected.

Management

Although the patient had been duly explained the nature her condition and the planned management, she was once again explained before she gave an informed consent.

She was starved from midnight. Half an hour before being wheeled to theatre, she had atropine sulphate 0.6mg intramuscularly.

In theatre, the general anaesthesia was induced and maintained. She was put in lithotomy position, vulvovaginal toilet done, draped and bladder emptied. Examination under anaesthesia confirmed earlier findings.

Anvard's speculum was inserted into the vagina to expose the cervix. The cervix was held by a sponge holding forceps. Using silk number 2/0, a purse string suture was inserted on the cervix circumferentially just below the reflection of vaginal mucosa, the needle being directed into the stroma but avoiding the endocervical canal. The bites were taken over 4 portions at 7/8, 10/11, 1/2 and 4/5 O' clock. A knot was made posteriorly and tightened just enough to admit the tip of a finger. The suture was cut short (3cm stump). The blood loss was minimal. The general anaesthesia was reversed successfully.

The patient was observed quarter hourly until she was fully awake, then transferred to antenatal ward for further observations. The vital signs remained stable. She had no per vaginal bleeding, no drainage of liquor and no uterine contractions.

She was discharged on tocolytics and phenobarbitone for 2 weeks. She was to have bed rest for two weeks and thereafter allowed only light duties. She was advised to avoid coitus for the remainder of the pregnancy. She was further advised to report back if she developed per vaginal bleeding, drainage of liquor or lower abdominal pains. She was to continue with antenatal follow-up starting one week after discharge.

Antenatal Follow-up and delivery

She attended antenatal clinic as scheduled and the entire antenatal period was uneventful. The stitch was removed at 37 completed weeks. She was admitted to labour- ward 3 days later with labour pains. She progressed well and delivered a life male infant who weighed 3100 grams and scored 8 at 1 minute and 10 at 5 minutes.

The placenta was delivered by controlled cord traction, weighed 480 grams and was grossly normal. The estimated blood loss was 100mls.

The vital signs remained within normal range. The mother and the baby were discharged after 24 hours and booked for postnatal clinic after 6 weeks.

Follow-Up

She was lost to follow-up.

Discussion

The patient presented was a 22 years old para 1+2 with bad obstetric history (BOH) secondary to cervical incompetence. She was successfully managed with cervical cerclage using Macdonald technique at 14 weeks gestational age. The stitch was removed at 37 completed weeks and subsequently went into labour a few days later. She had a spontaneous vertex delivery to a life male infant who weighed 3100 grams and scored well.

The term incompetent cervix is applied to a discrete obstetrical entity characterized by painless cervix dilation in the second trimester or early third trimester. There is prolapse and ballooning of membranes and subsequent expulsion of an immature infant (1). Unless effectively treated, this sequence tends to repeat in each pregnancy (1,2).

The patient presented had the second and third pregnancy losses in early third trimester and second trimester respectively. Both pregnancy losses started with drainage of liquor, followed by lower abdominal pains and subsequent expulsion of the products of conception.

The incidence of cervical incompetence shows great variation worldwide, ranging between 0.05 to 1% of all pregnancies and accounts for approximately 16% of all mid-trimester abortions (1,2,3). The wide variation of the incidence could be as a result of the fact that many cases of cervical incompetence are inconsistent with the classic picture of repetitive acute painless pregnancy losses in the mid-trimester without associated bleeding or uterine contractions (3). Locally, Njagi (1979) found an incidence of 1.1% at Kenyatta National Hospital (4). This high incidence at KNH could be attributed to the fact that it is a referral institution catering for high-risk pregnancies.

The aetiology of cervical incompetence is still obscure. Previous trauma to the cervix as in previous precipitate labour, operative vaginal delivery with an incompletely dilated cervix or trauma in the course of dilation and curettage have been implicated as major causes. Surgical amputation, conization and cauterization have also been implicated (1,3,5)

Though rare, a diagnosis of congenital cervical incompetence is usually made when the condition occurs in the first pregnancy (primigravida). In this clinical entity, there is abundance of muscle tissue with sparse connective tissue- the opposite of distribution in a normal cervix. On physical examination, the cervix appears normal but sudden pregnancy loss occurs at 18 to 20 weeks of gestation. In other instances, abnormal cervical development occurs leading to physiological dysfunctional disorders as a result of exposure to diethylstilboestrol in -utero (1,3).

The patient presented had a short cervix with no obvious anatomical defects and no obvious predisposing factors except previous manual vacuum aspiration (MVA).

Diagnosis of cervical incompetence is mainly clinical. A careful history and physical examination is essential. There may be history of previous mid-trimester abortions or early third trimester pregnancy loss. The classical picture of sudden spontaneous rupture of membranes with subsequent escape of liquor preceded by sensation of a mass herniating into the vagina, followed by relative painless and rapid labour may be elicited in many cases. A pattern of decreasing gestational age of the lost pregnancies is collaborative. There may be history of dilation and curettage or cervical tears during a previous birth. On speculum examination, a cervix usually shorter than 2.5cm, a dilated cervix or bulging membranes may be observed. Obvious anatomical defects arising from previous trauma may be also observed (3,5,6).

The patient presented had an abortion at about 10 weeks gestation that was managed by manual vacuum aspiration. She subsequently had an early third trimester pregnancy loss and a mid-trimester abortion. In the later two pregnancies, she had drainage of liquor followed by relative rapid painless labour. On examination, she had a short cervix (1.5cm long) but had no obvious anatomical defects of the cervix.

Sometimes, the history and physical examination may be obscure and therefore certain investigative tools may be of assistance in making a diagnosis of cervical incompetence. During pregnancy, ultrasonographic findings of cervical length of less than 2.5cm and a width of internal os more than 1.5cm in the first trimester with or without bulging of the membranes are suggestive of cervical incompetence.

Outside pregnancy, the following procedures may be adopted for confirmation of the diagnosis (1,3,5,7).

- Passage of size 6 to 8 Hegar dilator beyond the internal os without any resistance or pain and absence of internal os snap on its withdrawal especially in premenstrual period is indicative of cervical incompetence.
- Premenstrual hysterosalpingogram (HSG) demonstrates funneling and shortened endocervical canal.
- A ballooned catheter (with 1ml of water) placed inside the uterine cavity with external traction using a weight of 600 grams is positive if the balloon falls out.

The patient presented was not subjected to these confirmatory tests.

Block and colleagues (1976) suggested a diagnostic and prognostic scoring system in patients with suspected cervical incompetence and is used to identify patients who may benefit from the treatment (9).

These factors are;

1. Previous premature labour or spontaneous mid-trimester abortion without obvious cause.
2. Visualized evidence of previous surgical or obstetrical cervical trauma.
3. Previous history of relatively painless premature labour and rapid delivery.
4. Progressive cervical dilation or dilation greater than 2cm on initial examination during mid-trimester.
5. Previous diagnosis of cervical incompetence with previous cerclage.

A score of 1 is given for each positive factor giving a maximum total score of 5.

Patients with score greater than 3 have higher success rates due to the fact that one is likely to select actual cases of cervical incompetence (9).

The treatment of cervical incompetence in pregnancy mainly involves the mechanical strengthening of the weak uterocervical junction and is best performed after the first trimester to allow completion of early abortions that are due to other factors (1,4,5). The cerclage is best undertaken between 14 and 16 weeks gestational age or at least two weeks earlier than the lowest period of previous pregnancy wastage (5).

Njagi (1979) in his series found that cerclage had best results when performed at 13 – 19 weeks gestation (4). There is no consensus as to how late in pregnancy the procedure should be performed (1). However, the more advanced the pregnancy is, the more likely the surgical procedure will stimulate preterm labour, or membranes rupture. Thus, it is seldom done after 20 weeks and almost never after 26 weeks (1).

The patient presented had the cerclage done at 14 weeks gestation.

Contraindications for cervical cerclage include uterine bleeding, uterine contractions, drainage of liquor, intra-uterine foetal death, congenital malformation and chorioamnionitis. Before cerclage is performed, an ultrasound scan is recommended to exclude major foetal anomalies and to confirm the foetal viability. It is also equally important to rule out other common causes of abortions. These include diabetes mellitus, Rhesus incompatibility, syphilis, brucellosis, HIV infection and toxoplasmosis (1,3,6).

The patient presented had an ultrasound that confirmed a viable foetus and other tests were carried out to rule out these common causes of abortion.

Various techniques for cervical cerclage in pregnancy have been described. These include Macdonald, Shirodkar, and modified Shirodkar operative procedures. There is less trauma and blood loss in both Macdonald and modified Shirodkar procedures than in the original complicated Shirodkar procedure. The Shirodkar stitch insertion involves placement of a submucosal band of mersilene tape at the level of the internal os. This procedure requires anterior displacement of the bladder and submucosal dissection. The Shirodkar cerclage may be difficult to remove and therefore successful pregnancies may require delivery by caesarean section (1,3,6,7).

The Macdonald stitch first described by Macdonald in 1963, involves insertion of a purse string suture material round the cervix. It is easier to perform and remove, less traumatic and allows for vaginal delivery unless there are other obstetric reasons for caesarean section (1,3,5).

The patient presented had a Macdonald stitch inserted.

The Macdonald stitch is removed at 37 completed weeks or at any time before this if the patient goes into labour has drainage of liquor, uterine bleeding, intrauterine foetal demise or develops chorioamnionitis. The main complications of cerclage include haemorrhage, rupture of membranes, chorioamnionitis, abscess formation, premature labour and cervical fibrosis. If labour ensues with the stitch in-situ, cervical amputation, cervical tears, vesicovaginal fistula and uterine rupture may occur (1,3,5,6).

The patient presented did not develop any complication and the stitch was removed at 37 completed weeks.

The precise success rate for cervical cerclage is difficult to assess because the diagnosis of cervical incompetence in every case may be not all that certain. Success rates approaching 85 to 90% are achieved with both Macdonald and modified Shirodkar techniques (1,3,6,7). Macdonald himself reported term pregnancy rates of 85.5% while Shirodkar reported 70 to 80% success rates.

Locally, Njagi (1979) reported 64.2% foetal survival rates and 53% term pregnancy rates (4). Ruminjo (1991) reported 69.5% term pregnancy rate and 78.1% foetal survival rate (10).

It is actually possible to reduce the incidence of cervical incompetence through good obstetric practices and preventing unwanted pregnancies. This can be achieved through minimizing obstetric injuries by avoiding bearing down before attaining full cervical dilation, immediate repair of cervical tears and providing contraception to prevent unwanted pregnancies.

References

1. Cunningham F.G. Gant F.G.
Abortion.
In: Williams Obstetrics, 21 Ed, McGraw-Hill publications, 2001; page 862-865
2. Philip G. Jack Ludmir
Surgical procedures in pregnancy.
In: Obstetrics-Normal and problem pregnancies, 4th ed., Churchill Livingstone publications, 2002; page 607-613.
3. Richard F.M. John D.T.
Cervical incompetence
In: Telinde's operative gynaecology, Lippincott-Raven publications, 1997; page 518-521
4. Njagi S.
Radiological diagnosis of cervical incompetence.
M. Med thesis, UON, 1979.
5. Dutta D.C.
Haemorrhage in early pregnancy
In: Textbook of obstetrics 5th Ed., New Central publications, 2001; page 180-185.
6. Reynolds R.A., Angeria A.H.
A review of cervical incompetence.
Journal of reproductive medicine, Vol 32: 168; 1998
7. Sonia S.H., Romero R, Eli M.
Does cervical cerclage prevent preterm delivery in patients with a short cervix?
AM J Obstet. Gynaecol, 2001; **184**: 1325-1331.

8. Nakayama T, Mimura T, Okitsu O.

Early prediction of preterm delivery by transvaginal ultrasound.

Obstet. Gynaecol Survey 48(8): 519; 1994.

9. Block M.F., Rahel D.K.

Cervical incompetence – A diagnostic and prognostic scoring system.

Obstet. Gynaecol. 48: 504; 1976.

10. Gomel V.

Reconstruction tubal surgery.

In: Telinde's operative gynaecology, 8th Ed, Lippincott Raven, 1997; page 549 – 584.

11. Ruminjo J.K, Nuwengubu E.

Experience with Macdonald's cervical cerclage in a rural setting.

East Africa Medical Journal Vol. 68 No. 8: August 1991.

Case No. 2

DEEP VENOUS THROMBOSIS IN PREGNANCY-LIVE BABY

Name:	EN	Parity:	0+0
Age:	27 years	DOA	3.04.04
IPNo:	0936113	DOD:	15.04.04

Presenting complaints

The patient was admitted with a history of left leg pain and swelling for 3 days.

History of presenting illness

She was well until 3 days prior to admission when she developed sharp pain in the thigh and calf of the left leg, which was soon followed by swelling. Both the pain and swelling were progressive. The pain and swelling started from the calf spreading upwards. The pain was worsened by leg movement and partially relieved by paracetamol or by resting the leg. She gave no history of preceding trauma and had never been treated for deep veins thrombosis before.

History of current pregnancy

She was a primigravida. Her last menstrual period was on 11/07/03 and her expected date of delivery was on 8/04/04. Her gestation by dates on admission was 39 weeks and 2 days. She booked her antenatal clinic at Kenyatta National Hospital at 20 weeks gestation.

Her antenatal profile was; VDRL-negative, HIV- negative, haemoglobin-10.7g/dl, blood group O positive and urinalysis-normal.

Past Obstetric and Gynaecological history

She had menarche at 15 years of age. Her menses lasted 3 to 4 days, recurred after 28 days, regular and no associated dysmenorrhoea. She had never used any method of contraception.

Past medical and surgical history

This was not significant

Family and social history

She was married, a housewife and lived in Embakasi. Her husband was clearing and forwarding agent at Jomo Kenyatta International airport. Neither consumed alcohol nor smoked cigarettes. She had no family history of chronic illness.

Systemic Enquiry

She did not have chest pain or breathing difficulties.

Physical Examination

General Examination

She was found to be in good general condition, not pale, afebrile, not jaundiced, not cyanosed, no pedal oedema and no lymphadenopathy. Her blood pressure was 115/70 mmHg, pulse rate- 74 beats per minute, respiratory rate-18 per minute and temperature - 36.70C.

Local Examination

Both the calf and thigh of the left leg were moderately swollen, tender and warmer than the right leg. The left dorsal pedal artery was palpable and had normal capillary filling of the toes. The circumference measurement of the left leg taken at 10cm below the tibial tuberosity was 32cm while the right at the same reference point was 28cm. Similarly, measurement of the left thigh taken at 25 cm above the tibial tuberosity was 49 cm while the right thigh at the same reference point was 44cm.

Abdominal Examination

The fundal height was term. The foetus was in longitudinal lie, cephalic presentation, descend of 5/5 up and foetal heart was heard with a regular rate of 144 beats per minute. There were no contractions.

Pelvic Examination

She had normal external genitalia. The cervix was in the anterior position, soft, 1 cm long, admitting a tip of a finger and had a clinically adequate pelvis. There was no discharge or blood on the gloved examining fingers.

Other systems

The central nervous, cardiovascular, respiratory systems were essentially normal.

Diagnosis

A diagnosis of deep venous thrombosis of the left leg was made

Investigation results

Total blood count: Hb -12g/dl, WBC- $8.1 \times 10^9/l$, RBC- $3.3 \times 10^{12}/l$, Platelets - $238 \times 10^9/l$, MCV -92.3 fl

5.04.04 KCCT: Test- 84 seconds, control -38 seconds

PTI: Test -16 seconds, control- 16 seconds, PTI – 100% and INR = 1

09.04.04 KCCT: Test-79 seconds, control-34 seconds

14.04.04 PTI: Test-36 seconds, contro-20 seconds

Doppler ultrasound: Doppler ultrasound of the left leg showed thrombosis of the popliteal vein (PV), femoral vein (FV) and extending to the external iliac vein (EIV). The vessels were distended and non compressible.

Conclusion: Deep venous thrombosis of PV, FV and EIV.

Management

The patient was explained the nature of the diagnosis and the intended management. She was put on bed rest with elevation of the left leg, oral analgesics and heparin infusion 10,000 international units 8 hourly and titrated against a KCCT of 1.5-2.5 times the control until the symptoms subsided.

Meanwhile, daily measurement of the patient's calf and thigh circumference were done together with periodic chest examination. Investigations were done and results indicated as above.

Delivery

While on treatment in the ward, she went into labour at a gestation of 40 weeks. On examination, the fundus was term, foetus in longitudinal lie, cephalic presentation, descend 5 fifths up and a regular foetal heart rate of 140 beat per minute. She had 2 contractions in 10 minutes each lasting between 20 and 40 seconds.

Pelvic examination revealed a cervical dilation of 5cm, fully effaced and was draining clear liquor. There was no cord felt and no caput or moulding. The last dose of heparin had been given 5 hours prior to the onset of labour. A quick bedside blood clotting time was 20 seconds. Two units of blood and protamine sulphate were available in anticipation of any postpartum haemorrhage.

She was reviewed 4 hours later and found to have a foetal heart rate of 130 beats per minute, descent of 3/5, 3 contractions in 10 minutes and each lasting over 40 seconds. She had a cervical dilatation of 8 cm with moderate caput and moulding 2+.

A diagnosis of cephalopelvic disproportion (CPD) was made and a decision to deliver her by emergency caesarean section was arrived at. Having been informed of the diagnosis, she gave an informed consent, was shaved and premedicated with 0.6mg Atropine sulphate intramuscularly and wheeled to theatre.

In theatre, the patient was put in semi-lithotomy position, vulvovaginal toilet done, catheterised (about 50mls of clear urine obtained) and repositioned to supine position.

The abdomen was cleaned, draped and then she was anaesthetised. The abdomen was opened through pfannenstiel incision and a lower uterine segment section done as described in the introduction.

The outcome was a life male infant who weighed 2800g, and *apgar* scores of 4 at 1-minute and 6 at 5-minutes. The infant was admitted in Newborn Unit due to low *apgar* scores. She had fresh meconium stained liquor grade II. The placental was delivered by controlled cord traction. Both the placenta and cord appeared grossly normal. Instruments, swabs, needles and gauze rolls' count was reported correct before the abdomen was closed in layers. The average blood loss was estimated at 400mls. General anaesthesia was reversed successfully.

Post-operative care

She had continuous vital signs observations until she was fully awake and thereafter 4 hourly. She had intravenous fluids 500mls of normal saline alternating with 5% dextrose every 4 hours until the bowel sounds were auscultated. She received intramuscular 100mg of pethidine 8 hourly for 24 hours, intravenous crystalline penicillin 2mu 6 hourly, gentamycin 80mg 8 hourly and metronidazole 500mg 8 hourly for 48 hours and then converted to oral amoxycillin and metronidazole.

Twelve hours postoperatively, heparin infusion at 10,000iu 8 hourly was resumed. The patient remained stable, vital signs remained normal, chest clear, wound clean, minimal and non-fowl smelling lochia. The swelling and tenderness had subsided by the second post-operative day. The baby was discharged from nursery and joined the mother on the 2nd post-operative day. The patient was started on warfarin 5mg once daily while still on heparin for 3 days after which the heparin was stopped. She was discharged on warfarin 5mg once a day and booked for review in the postnatal and haematology clinics after 6 weeks.

Follow-up

After 6 weeks, she was reviewed in the postnatal clinic as per the appointment. She had no complaints. On physical examination, she was found to be in good general condition, not pale, afebrile and the incision site had healed well. Both lower limbs were of equal size, without any swelling and no tenderness on palpation. She was counselled on various contraceptive options and opted for an intrauterine device (IUCD). She was advised to book antenatal clinic as early as possible in the future pregnancies.

Discussion

The patient presented was a 27 years old primigravida with deep venous thrombosis (DVT) of the left leg at term. She was managed by bed rest, analgesics and heparin infusion. She later went into labour while in the ward and was delivered by emergency caesarean section due to cephalopelvic disproportion (CPD). The baby was admitted to Newborn unit (NBU) due to asphyxia but was discharged to join the mother 2 days later.

Thromboembolic disease is a vascular occlusive disorder caused by the formation of a pathological thrombus in the blood vessels in a living person (1,2). A thrombus comprises of polymorphonuclear cells, platelets and fibrin strands with trapped red blood cells. Vascular clotting develops mainly due to circulatory stasis, vascular damage and increased coagulability of blood commonly referred to as the elements of *Virchow's triad*. As such, any factor that leads to the components of the triad will predispose to venous thromboembolic disease (1,2,3).

The incidence of venous thrombosis in pregnancy is 1 in 1000 pregnancies. The incidence per age group is about 0.615 per 1000 pregnancies in those aged below 35 years and 1 per 1.216 per 1000 in those aged over 35 years (1,3). Most studies have observed that half of the DVT cases are encountered during antenatal period and the other half during puerperium. Antenatal venous thrombosis is encountered commonly in the second and third trimesters than the first (1,3,4).

Locally, the incidence of deep venous thrombosis at Kenyatta National hospital is reported to be 0.16% (1.6 per 1000) of all pregnancy admissions. Waweru (1981) analysed 80 cases of venous thrombosis associated with pregnancy and found that 76% of cases occurred in the left lower limb (5). Gherman and associates observed that 80% of venous thrombosis occurred in the left leg (1).

The patient presented was 27 years old and developed left leg venous thrombosis during the third trimester.

Pregnancy and puerperium are traditionally considered as one of the highest risks to developing venous thrombosis and pulmonary embolism when compared to non-pregnant state of similar age (1).

Pregnancy is a hypercoagulatory state in which all the elements of *Virchow's triad* are present. Increase in calibre of capacitance vessels produces vascular stasis while venous return from the lower extremities is reduced- by the pressure of the gravid uterus on both the iliac veins and the inferior vena cava. Blood hypercoagulability is due to increased amount of factors II, VII, VIII and X (2,3,7).

Thrombin-mediated fibrin degeneration is increased many times during pregnancy. Significant vascular damage occurs during labour especially if prolonged, operative delivery and postpartum endometritis (1,2,3,4). Other risk factors include previous history of venous thrombosis, bone or pelvic surgery, history of pelvic radiation, hormonal contraceptive use and prolonged duration under anaesthesia. Other important predisposing factors include heavy cigarette smoking, obesity, heart disease, hypertensive disorders, anaemia and diabetes mellitus (1,2).

The patient presented did not have any other risk factor except pregnancy.

Attention has recently been directed to a number of isolated protein deficiencies involved either in coagulation inhibition or in the fibrinolytic system. These deficiencies collectively referred to as thrombophilias can lead to hypercoagulability and recurrent venous thromboembolism. The principal thrombophilias arise from mutations that causes quantitative or qualitative deficiencies of anti-thrombin III, protein S and C, factor V and IX, prothrombin and homozygosity for an abnormal methylenetetrahydrofolate reductase (MTHFR) gene (1,4).

Lupus anti-coagulant has strongly been associated with deep venous thrombosis. Mwanda (6) recommended screening for lupus anti-coagulant for patients with recurrent thromboembolism, positive VDRL and those with recurrent foetal losses.

Screening for the protein deficiencies in the patient presented were not done due to unavailability of relevant technology. Equally, Lupus anti-coagulant screening was not done since the patient presented had no history of recurrent foetal losses (was a primigravida), VDRL was negative and had no history of previous thromboembolic episodes.

Deep venous thrombosis (DVT) can be divided into two: the proximal (iliofemoral) and the distal (calf).

Eighty percent of DVT cases encountered belong to the proximal in which the popliteal, femoral and iliac veins are involved. The distal is limited to the calf and accounts for the remaining 20% of deep venous thrombosis of the lower limbs (1,2,7). Proximal vein thrombosis is associated with higher incidence of pulmonary embolism (2,3). About 50% of patients with pulmonary embolism have clinical evidence of deep vein thrombosis in the lower limbs. The calf venous thrombosis rarely causes pulmonary embolism unless there is an extension into the proximal veins. Proximal extension of calf deep venous thrombosis occurs in about 30% of cases (1,3,7).

The patient presented had both distal and proximal deep venous thrombosis but she did not develop clinically detectable pulmonary embolism.

Signs and symptoms of deep venous thrombosis involving the lower extremity vary greatly depending mainly upon the degree of occlusion, the status of collateral venous circulation and the intensity of the inflammatory response. Classical features of the affected limb include swelling, pain, tenderness, local fever and a positive Homan's sign. Reflex arterial spasms may cause a pale and cool extremity with diminished pulsations (1,3). However, it is important to note that most patients with deep venous thrombosis may be asymptomatic. Differential diagnosis includes leg trauma, cellulitis, obstructive lymphadenopathy and ruptured Baker's cysts (1,3).

The patient presented had clinical findings of leg swelling, shiny, tenderness and local warmth.

Clinical diagnosis of deep vein thrombosis is neither sensitive nor specific; the false positive rate is as high as 50%. For many years, venography was the standard for confirming deep venous thrombosis but lately non-invasive methods have largely replaced this test to confirm the clinical diagnosis (1,7). Venography is time consuming, expensive, cumbersome and has serious complications such as phlebitis. Doppler ultrasonography is currently the procedure of choice to detect proximal deep vein thrombosis. Other tests include radioactive iodine laden fibrinogen scanning used in non-pregnant women since it is contra-indicated in both pregnant and nursing mothers (3,7).

Magnetic resonance imaging (MRI) and computerised tomographic scanning (CT-scan) are usually reserved for specific cases in which ultrasound findings are equivocal or with negative ultrasound findings but strong clinical suspicion (1,2,3).

In the patient presented, Doppler ultrasonography confirmed the diagnosis of deep venous thrombosis of the left leg.

The objective of deep venous thrombosis treatment is to stop further growth of the existing thrombus, control pain and swelling with bed rest, analgesics and anti-coagulants (7). During the acute phase, the mainstay of treatment is intravenous heparin infusion coupled with measures to improve venous return and reduce patient's discomfort. During pregnancy, heparin is the drug of choice since it does not cross the placental barrier. Heparin can be given by continuous intravenous infusion, intermittent intravenous boluses or by intermittent subcutaneous injections. During the acute phase, heparin daily dosage ranges between 30,000 to 40,000 international units (2,3,7).

Heparin is only available in injectable form hence the inconvenience of repeated injections with resultant poor compliance.

It is never given intramuscularly because of bleeding into the muscles. Its half life is 60-90 minutes and its action is immediate through acceleration of the anti-thrombin III activity which results in decreased activity of clotting factors IX, X and XI (2,3). Its main side effect is bleeding. Other adverse-effects include thrombocytopenia, anaphylactic reactions, alopecia, local fat necrosis and with prolonged use it causes osteoporosis (3,7).

Protamine sulphate is the anti-dote for heparin given as 1mg for every 100 international units of heparin. If more than 30 minutes have elapsed after the last known heparin administration, half the dose of protamine sulphate is given. Since protamine sulphate is anticoagulant per se, it is considered unsafe to exceed 100mg within a short period. Intravenous protamine sulphate administration may be associated with sudden hypotension and bradycardia (2,7).

Heparin administration is monitored using APTT or KCCT, which should be 1.5 to 2 times the control value in order to realise adequate anti-coagulation. Other monitoring tools include blood coagulation time, thrombin clotting time, heparin assays and total blood count (7).

In the patient presented, bedside clotting time, KCCT and total blood count were used to monitor the heparin treatment.

During labour, heparin injection should be withheld until after delivery – usually resumed after 12 hours. For precaution purposes, fresh grouped and cross-matched blood or fresh frozen plasma together with protamine sulphate should be on stand-by in case of uncontrollable bleeding (7).

In the patient presented, these precautionary measures were undertaken both during labour and caesarean section. Heparin was resumed after 12 hours.

Anti-coagulant therapy should be continued throughout the puerperium, preferably by oral anti-coagulant. Warfarin has no significant transfer across the breast hence its safe during lactation (1,3).

The patient presented was on warfarin throughout the puerperium and advised that in future pregnancies she should book antenatal clinic as early as possible and should have anti-coagulant prophylaxis. Warfarin was stopped after six weeks postpartum. After being counselled on merits and demerits of various contraception, she opted for IUCD.

References

1. Cunningham F, G. MacDonald P.C
Pulmonary disorders
In: Williams obstetric, 21st Edition, Mcgraw-Hill Publishers, 2001; page 1223-1250
2. Dechemey A.H
Cardiac, haematological and pulmonary disorders in pregnancy
In: Current obstetric and gynaecologic diagnosis and treatment, 8th edition, Appleton and Lange publication, 1994; Pg 454 – 457
3. Borner J, Chamberlain G
Venous thrombosis and pulmonary embolism
In: Tumbull's Obstetrics 2nd edition, Churchill Livingstone publication, Edinburgh England, 1995; Pg 789 – 801
4. Greer I.A
Thrombosis in pregnancy, maternal and foetal issues
Lancet 353: 1258 – 65; 1999
5. Waweru J.M
Deep venous thrombosis
M. Med Thesis, University of Nairobi, 1981
6. Mwanda O.W
Lupus anti-coagulant syndrome: case report
East Afri. Medical Journal 75 (10): 619 – 620; 1998
7. Dutta D.C
Abnormalities of the puerperium
In: Textbook of obstetric, 5th edition, New Central book agency, Calcutta, 2001; Page 476 – 478;

Case No. 3

HIV INFECTION IN PREGNANCY – ELECTIVE CAESAREAN SECTION

Name:	JW	Parity:	0+0
Age:	29 years	DOA:	16.04.04
IPNO	0612470	DOD:	23.04.04

Presenting complaints

The patient was admitted through the antenatal clinic for elective caesarean Section due to HIV-infection in pregnancy at term.

History of presenting complaints

The patient had tested positive for the HIV infection during the routine antenatal screening. She was counseled and opted to have an elective caesarean section and not to breastfeed. She was started on Zidovudine (AZT) 300mg twice daily from 34 weeks gestation (Thailand regime)

History of current pregnancy

Her last menstrual period was on 24.07.03 and her expected date of delivery on 01.05.04 giving a gestation of 38 weeks. She had booked her antenatal clinic at 29 weeks gestation at KNH. Antenatal profile was done;

- VDRL- negative
- (ELISA) HIV -positive
- Haemoglobin - 11.1g/dL
- Blood group O and rhesus negative
- Indirect coombs test (ICT) - negative
- Repeat ICT at 35 weeks – negative

Past obstetric and gynaecologic history

She was a para 1+0 and her delivered was via spontaneous vertex delivery in 1998. The baby weighed 3100grams and was alive and well. She had received an injection of anti-D Immunoglobulin soon after delivery.

Her menarche was at 16 years. Her menses recurred after 28 days, lasting 3-4 days, regular and no associated dysmenorrhoea. She had never used any form of contraception.

Past medical and surgical history

She was a known asthmatic and was maintained on salbutamol tablets and occasionally salbutamol inhaler. She was being followed-up regularly at the medical outpatient clinic (MOPC) at KNH since 1999. She had never been transfused blood. She had no history of sexually transmitted infections.

Family and social history

She was married, a housewife and stayed at Uthiru market. Her husband was a peasant farmer. Neither smoked cigarettes nor consumed alcohol. There was no family history of chronic illnesses.

Physical examination

General Examination

She was found to be in good general condition, not pale, not jaundiced, afebrile, no peripheral oedema and no lymphadenopathy.

The vital signs were:

- Blood pressure -120/80mmHg
- Pulse rate -76/minute, regular and good volume
- Respiratory rate- 18/minute
- Temperature -36⁰C

Abdominal examination

The abdomen was uniformly distended. The fundal height corresponded to term. The foetus was in longitudinal lie, cephalic presentation and the foetal heart rate of 140 beats per minute and regular. There was no hepatomegally or splenomegally.

Pelvic examination

She had normal female external genitalia, the cervix os was closed, cervix 2.5cm long, central and no vaginal discharge or blood on the gloved examining fingers.

Other systems

The cardiovascular, central nervous and respiratory systems were normal.

Management

On the eve of the operation, the patient was reviewed by the anesthetist especially in view of being an asthmatic and was Okayed for the operation. She gave an informed consent. Blood for grouping and cross matching was taken and a theatre list prepared. She was starved from midnight. The next morning, she was shaved and an intravenous line established and six hours before the operation, the patient was given nevirapine 200mg orally stat. Thirty minutes before being wheeled to theatre, she was premedicated with atropine 0.6mg intramuscularly.

The caesarean section was performed as described in the introduction.

The outcome was a life female infant who weighed 2400 grams and scored 7 at one-minute, 9 at 5-minutes and 10 at 10 minutes. Intravenous ergometrine 0.5mg was given after the birth of the baby. The cord was double clumped and cut. The placenta and membranes were complete and appeared grossly normal. The placenta weighed 400 grams. The skin was stitched subcutaneously with vicryl number 1/0. Blood loss was estimated at 500mls. She was started on intravenous crystalline penicillin 2 mu 6hourly, gentamycin 80mg 8hourly and metronidazole 500mg 8hourly .She also received pethidine 100mg 8hourly intramuscularly for 24hours and intravenous fluids; 500mls of normal saline alternating with 5% dextrose at a rate of 1litre 8hourly until the bowel sounds were auscultated and normal.

Meanwhile, cord blood was taken and the baby admitted to Newborn unit due to maternal rhesus negativity. The baby received an oral dose of nevirapine 5 mg after 10 hours. Both the mother and the baby did well post-operatively. Baby's direct Coombs test (DCT) was negative, blood group O positive, haemoglobin level of 18g/dL and normal bilirubin level. The mother received 300 µgrams of anti-D Immunoglobulins.

She was discharged on the 4th post-operative day on oral antibiotics and bromocriptine 2.5mg twice a day for 10 days. She was booked for review after 6 weeks in the post-natal clinic.

Follow-up

She came to the clinic as per the appointment. Both the mother and the baby were doing well. The baby was on formula milk. The incision site had healed well. She was counseled on family planning options, opted for depo-provera and referred to the family planning clinic.

She was booked for the next postnatal clinic follow-up after 6 weeks. Four days before the next scheduled postnatal clinic, she had the following investigations done and brought on the clinic day.

1. Urea and electrolytes

- Sodium -142 mmol/l
- Potassium- 4.5 mmol/l
- Chloride -106 mmol/l
- Urea -4.3 mmol/l
- Creatinine -106 μ mol/l.

2. Total Blood count : WBC - 5.86×10^9 /L (neutrophils 52.2%, lymphocytes 30.4%, monocytes 7.84%, basophils 0.997%, and eosinophils 8.5%)

RBC- 4.82×10^{12} /l, haemoglobin- 11.3g/dl, haematocrit -33.9%, MCV- 75.1 fl, MCH- 23.4 Pg, MCHC -31.2g/dl, and Platelets- 347×10^9 /L

3. CD4 – 78 Range (518 – 1971)

CD8 – 661 Range (270 – 1350)

CD3 – 807

CD4/CD8 – 0.12

CD4/CD3 – 0.10

CD8/CD3 – 0.82

4. Liver function tests

- Total protein 93g/dl
- Albumin 41g/dl
- Total bilirubin 4.9 μ mol/l

- Direct bilirubin 1.7 $\mu\text{mol/l}$
- AST 22 u/l
- ALT 15 u/l
- Alkaline phosphatase 129 u/l
- GGT 13 u/l

5. Pap smear was reported as normal

In view of the low CD4 count of less than 200, the patient was started on HAART – Zidovudine and Lamivudine (combivir) and Nevirapine. Subsequently, the patient was referred to the KNH comprehensive care clinic for follow-up.

Discussion

Acquired Immunodeficiency Syndrome (AIDS) was first described in the United States around 1981 among homosexual men with defective cellular immunity, pneumocystis carinii and other opportunistic infections (1). In Kenya, the first case was reported in 1984. Since then HIV/AIDS has reached epidemic proportion and has been described as the single most important challenge ever in post-independent Kenya (2).

HIV is a single stranded RNA retrovirus, which replicates by using reverse transcriptase enzyme to translate its genomic RNA into DNA copy. The viral DNA is then inserted as a provirus into the host cell DNA, where it may remain latent or be copied again into viral RNA to produce new viral particles. T-lymphocytes defined phenotypically by the CD4 surface antigen are the principal targets. The CD4 site serves as a receptor for the virus. The lifespan of an infected cell is shortened. Over time, the number of T-cells declines insidiously and progressively and eventually results in profound immunosuppression (3).

In sub-saharan Africa, HIV/AIDS has caused a severe and generalized epidemic. In at least 16 countries, the HIV seroprevalence among pregnant women exceeds 10% and in at least 6 countries, it is over 20% (4). In Kenya, HIV prevalence at urban sentinel in 2001 among antenatal women ranged between 11% and 17% while in rural areas it ranged between 2% and 31%. Overall, in 2001, the prevalence of HIV among adults aged between 15-49 years was estimated at 13% (4).

The mode of transmission of HIV is by contact with body fluids containing viral particles. These modes include sexual contact and therefore exposure to semen and vagina secretions, exposure to blood and blood products such as blood transfusion, intravenous drug use or occupational exposure and finally by mother-to-child transmission, which can be antepartum, intrapartum and postpartum (mainly by breastfeeding). In Kenya, heterosexual contact accounts for nearly 90% of all new HIV infection (4).

The patient presented had most likely acquired the HIV infection by sexual contact since she had never been transfused blood, no *hard* drugs use and no occupational exposure (she was a housewife).

The transmission from male to female is thought to occur more readily than female to male. This could be attributed to the fact that viral concentration in semen is higher than in vaginal secretion and that coitus causes more introital mucosal breaks than in the penile skin (5).

Other factors that increase the risk of heterosexual exposure include the number of exposures to high-risk sexual partners and presence of other sexually transmitted infections especially syphilis, genital herpes and chancroid because they may involve genital ulceration.

The patient presented gave no history of sexually transmitted infections.

A number of tests are used in the diagnosis of HIV infection. These are divided into: - antibody detection, antigen detection and viral nucleic acid (RNA or DNA) testing. ELISA antibody detection is the test used often to detect HIV infection. It determines the presence of HIV antibodies and has a sensitivity of up to 99% (3). A positive ELISA test can be confirmed by the western blot test and Immunofloresence assay. Third generation ELISA's, which use recombinant antigens is highly specific and sensitive.

It is recommended that two ELISA tests for HIV antibody detection should be done; one for screening and the other for confirmation. The two tests must be positive for one to make a diagnosis of HIV infection. In the event that one ELISA test is positive and the other negative, it is recommended that viral nucleic acid (polymerase chain reaction) testing be done to confirm the serostatus.

The patient presented was found to be HIV infected by ELISA test done as part of antenatal profile. Infact, all pregnant women should be counselled and encouraged to be tested for HIV infection so that they can know their serostatus for their own health and to allow corrective measures to reduce the risk of prenatal HIV infection (4).

The effects of pregnancy on the rate of progression of HIV disease is unclear with some authors claiming no effect while others suggest that clinical illness is more likely to develop because of suppressed cell immunity (6,7). Similarly, the influence of HIV infection on pregnancy is also still unclear. In a longitudinal study of immunity in HIV-1 infected women in the United States, Temmerman and associates suggested that pregnancy accelerates the HIV induced loss of CD4 cells (7). In another study in Nairobi, the means of the difference between ante-natal and postpartum values of CD4 were similar for HIV-1 infected and uninfected women thus indicating that pregnancy does not affect the immune status in HIV seropositive women more than in HIV seronegative control (8).

However, many studies done in Africa reports increased incidences of preterm labour, urinary tract infection, low birth weight infants, intrauterine growth restriction (IUGR) and puerperal infection (9,10,11).

Currently, much attention and energy has been focused on means of preventing mother to child transmission (PMCT) of HIV infection. The prevalence of HIV infection among pregnant women in Kenya is currently estimated at 13% (4). In Kenya, mother-to-child transmission of HIV infection accounts for 90% of all HIV cases in children less than 5 years of age (2,4).

The prognosis for these infected children is poor because majority develops early and rapidly progressing disease, putting a further strain on our already overburdened health care system.

Vertical transmission rate of HIV infection ranges between 15 and 35%, with the highest rates being reported in Africa. Vertical transmission can occur antenatally, intrapartum and by breastfeeding. Labour and delivery poses the greatest risk for vertical transmission with 10-20% of exposed infants becoming infected. When mothers breastfeed for 18 to 24 months, 10 to 15% of infant become infected and with prolonged breastfeeding beyond 24 months 25 to 45% of infants become infected (4).

Vertical transmission of HIV infection is dependent on a number of maternal risk factors and intrapartum events. Maternal risk factors favouring MTCT include low CD4 counts, high viral loads, advanced AIDS, preterm delivery, HIV infection acquired during pregnancy, maternal P24 HIV core antigenemia at birth and placental membrane inflammation (12).

The patient presented had a low CD4 count of 78u/L 12 weeks postpartum and most likely she had a similar count antenatally. Maternal P24 HIV core antigenemia and viral load were not done because of the prohibitive costs involved.

Intrapartum events that favour MTCT include mode of delivery (vaginal delivery has a higher risk of transmission than elective caesarean section), prolonged ruptured membranes especially if the duration is over 4 hours, episiotomy, intrapartum haemorrhage, instrumental deliveries such as vacuum assisted and use of invasive foetal monitoring devices. In twin deliveries, the first twin has a higher risk of infection than the second twin (4,7,8).

Elective caesarean section has been shown to reduce the risk of MTCT by 50% in patients not receiving Zidovudine (AZT) and up to 80% in those on AZT therapy.

Although elective caesarean section is not readily available in most health facilities in the developing world (Kenya included) as a routine for HIV positive women, there maybe some cases that merit consideration for caesarean section. These include pregnancies where labour may be expected to be prolonged or where other obstetric complication may be associated with increased risk of transmission such as abruption placenta, placenta praevia and preterm rupture of membranes (PROM)(3,5,9).

Health workers should discuss the risks and benefits of various birth options with the patient to allow them make an informed decision.

The patient presented opted for an elective caesarean section that was done at 38 completed weeks (term).

In situations where elective caesarean section is not practical, a number of precautionary measures to reduce MTCT during vaginal delivery are advocated for. These include avoidance of prolonged rupture of membranes, minimize the number of vaginal examinations and to advocate for vaginal cleansing with chlorhexidine 0.25% solution. Once the baby is delivered it should be washed with chlorhexidine 0.25% solution or wiped with a towel to remove maternal body fluids. Suction of the newborn should be avoided unless in cases of birth asphyxia and even then it should be under direct vision with a laryngoscope (4,12).

The use of antiretroviral (ARV) drugs has definite benefit. The AIDS clinical trial group protocol 076 (ACTOG076) trial with long course of AZT demonstrated a three-fold reduction in MTCT from 25% to 8% (13). ACTOG076 regime is expensive. A short course therapy (Thailand regime) in which AZT is initiated at 34 – 36 weeks without breastfeeding reduces MTCT by 50%. This is the protocol in use currently at Kenyatta National Hospital.

Nevirapine as prescribed by the HIV-NETR trial in Uganda looks like the best option for resource poor countries. The dose of nevirapine 200mg for the mother at the onset of labour and 2mg/Kg single oral dose for the baby within 72 hours of birth shows a 47% reduction of MTCT (4,12,13).

The patient presented had AZT from 34 weeks gestation and chose not to breastfeed (*Thailand regime*), and had an elective caesarean section.

More recent data on antiretroviral therapy using combinations of three or four agents shows greater benefits than use of AZT alone.

The safety and effectiveness of various agents in pregnancy is currently an area of active research with recommendation being continually updated and modified (13).

At Kenyatta National Hospital, pregnant mothers who are beyond the gestational age of 16 weeks and have a CD4 count of less than 200 or with AIDS defining illness (W.H.O stage IV) are being put on HAART (Zidovudine, Lamuvidine and Nevirapine) antenally, and up to six months postpartum and then referred to the comprehensive care clinic.

References

1. CDC
Pneumocystis Pneumonia, Los Angeles
MWWV 1981; 30:250-252
2. Landman S H, Kalish L A, Burns D N, et al
Obstetrical factors and transmission of HIV from mother to child
N Eng J Med 1996; 334:1617-23
3. Cunningham F G, Norman F G
Sexually transmitted diseases
In Williams obstetrics, 21st Ed, McGraw-Hill Publications, 2001; Pages 1498-1504
4. Ministry of Health
National Guidelines on PMCT in Kenya
2nd Ed. NASCOP; 2002
5. Susan M.M, George DW, David LH
Sexually transmitted diseases and pelvic infections
In: Current obstetrics and gynaecologic diagnosis and treatment, 8th Ed.
Appleton and Lange, 1994; pages 764-767
6. Katz D.A
The profile of HIV infection in women: A challenge to the professional social work
Health care, 1997; 24: 127-134
7. Temmerman M, Bwayo J, Ndinya-Achola J.
HIV-1 and Immunological changes during pregnancy
AIDS September 1995; 9:1057-1060

8. Bigger R.J, Pahwa S
Immunosuppression in pregnant women infected with HIV
AM J obstet. Gynaecol 1989; **161**:1239

9. Mmio FA, Ndugwa C M
The effect of HIV infection on the outcome of pregnancy in Ugandan women
J. Obstet Gynaecol. East and Cent. Africa, 1993; **11**: 32

10. Tuomala R, Chang B.H, Vums DN
Vagina colonization or infection with candida albicans in HIV infected women during pregnancy and puerperium
Clinical infectious diseases, 1997; **24**: 201-10

11. Dallabeta G.A, Canner J.K, Tala T.E
The effect of HIV infection on birth weight and infant mortality in urban Malawi
Int. J. STD/AIDS, 1992; **3**: 418-22

12. MinKopp H, Burns DN
The relationship of the durations of ruptured membranes to vertical transmission of HIV
AM J. Obstet. Gynaecol. 1995; **173**: 589-90

13. Anonymous
Therapeutic and other interventions to reduce the risk of MTCT of HIV-1 in Europe: The European Collaborative Study
BMJ of Obstet.Gynaecol. 1998; **105**: 704-9

Case No. 4

PLACENTA PRAEVI TYPE IV - CAESAREAN SECTION - LIVE

BABY

Name:	MW	Parity:	0+4
Age:	32 years	DOA:	31.03.04
IPNo:	0617366	DOD:	21.04.04

Presenting complaints

The patient presented with complains of sudden painless per vaginal bleeding that lasted 4 hours.

History of presenting illness

The patient was well until the morning of admission when she woke-up and noticed blood on her pants and the beddings. There were no blood clots and had changed a single sanitary pad prior to admission. There was no associated abdominal pain or backache and had no drainage of liquor. She had no history of spotting. She had no dysuria, frequency or urgency. She gave no history of abdominal trauma and had no sexual intercourse the previous night. The patient had no history of hypertension or coagulatory disorders.

Obstetric and gynaecologic history

She was a para 0+4 gravida 5. Her last menstrual period was on 20.08.03 and her expected date of delivery was on 27/05/04 giving a gestation by dates as 32 weeks. Between 1999 and 2003, the patient had four pregnancy losses at gestational ages of between three and four months.

All the pregnancy losses had started with per vaginal bleeding followed by lower abdominal pains and subsequent expulsion of the products of conception. She had manual vacuum aspiration (MVA) for all those abortions at Kenyatta National Hospital.

She had menarche at 13 years and her menstrual cycles were regular, occurring every 28 days and lasting 3-4 days. She gave no history of contraception.

She booked her antenatal clinic at Ruiru health centre at a gestation of 26 weeks and because of her bad obstetric history (BOH) she was referred to KNH but declined.

Antenatal profile done; VDRL - negative, blood group B positive, haemoglobin - 13.7g/dl, urinalysis-normal and HIV was negative

Past medical and surgical history

This was not significant.

Family and social history

She was married and worked as a clerk at a local tea factory in Ruiru. Her husband was a businessman. She did not smoke cigarette or consume alcohol. There was no family history of chronic illnesses.

Physical examination

General Examination

She was found to be in good general condition, not pale, afebrile, not jaundiced and no peripheral oedema. Her vital signs were;

Blood pressure: 110/70mmHg

Pulse rate: 82 beat per minute, regular and good volume

Respiratory rate: 20 per minute

Temperature: 36.80C

Abdominal examination

The abdomen was uniformly distended and moving with respiration. The fundal height was corresponding to 32 weeks gestation. The foetus was in transverse lie and foetal heart rate was 144 beats per minute and regular. There was no area of tenderness or rigidity and had no palpable contractions.

Speculum examination

She had normal external genitalia. A speculum was gently inserted and a few small blood clots in the vagina were evacuated. The vaginal walls were normal and the cervix was healthy with no active bleeding from the external cervical os.

Other systems

Cardiovascular, central nervous and respiratory systems were normal.

Diagnosis

An impression of antepartum haemorrhage at 32 weeks gestation was made.

Investigations

Full haemogram

WBC - $8.0 \times 10^9/l$ (differential count - neutrophils 85% and lymphocytes of 15%)

RBC - $3.92 \times 10^{12}/l$

Hb -10.4/g/dl

MCV- 82.8 fl

Platelet count- $242 \times 10^9/l$

Haematocrit-31%

Obstetric ultrasound: – showed a single intrauterine viable foetus in transverse lie. The foetal heart sounds were heard and the rate was 146 bears per minute and regular. The average gestational age by BPD, FL and AC was 29 weeks and 1 day.

The placenta was in the lower uterine segment completely covering the internal cervical OS

The cervical internal os was closed and the amniotic fluid volume was adequate.

Conclusion- Placenta Praevia type IV at 29 weeks gestation.

3) *Urea and electrolytes:*

- Urea - 3.2mmol/l
 - Sodium -140mmol/l
 - Potassium -3.7mmol/l
- Creatinine –56micromol/l

Management

Since the patient had minimal bleeding, stable vital signs and the gestation being not term, a decision was made to manage her conservatively. She was transferred to the antenatal ward for bed rest, and observations. Blood was taken for grouping and cross matching and an intravenous line established. Two units of blood were availed and kept on stand-by. She was put on sedation, haematinics and a foetal kick chart. She was also put on dexamethasone 12mg intramuscular twice a day for one day (2 doses).

The patient stayed for two weeks without any problem. However, at 34 weeks gestation she suddenly developed profuse per vaginal bleeding accompanied by intermittent lower abdominal pains.

She was taken to labour ward where a speculum examination confirmed the profuse bleeding from the cervical os, which was already 3cm dilated. A decision to deliver her by emergency caesarean section was made.

The patient was explained about her condition and consented for the operation. Blood for grouping and cross match was taken and intravenous fluids commenced. She was shaved and wheeled to the operating theatre after premedication with 0.6 mg atropine sulphate intramuscularly. The caesarean section was performed as described in the introduction.

The outcome was a live female infant, who weighed 2400grams and had *apgar* scores of 6 at 1 minute and 8 at 5 minutes. Intraoperatively, the placenta was found covering the internal os completely (Placenta praevia type IV). The placenta and the umbilical cord appeared grossly normal. Haemostasis was achieved easily. The average blood loss was estimated at 600mls. Reversal of general anaesthesia was uneventful. The mother and the baby did well post-operatively. She was discharged on the 4th post-operative day.

She was for removal of stitches on the 7th post operative day at the nearest health facility and booked for review in the postnatal clinic after 6 weeks.

Follow-up

She did not have any complaints. She was in good general condition and was not pale. The incision site had healed well. The uterus had involuted well and had no abnormal vaginal discharge. The baby was doing fine. She was counselled on family planning options but opted to seek family planning services at her nearest health centre.

Discussion

The patient presented had antepartum haemorrhage (APH) secondary to placenta praevia type IV at 32 weeks gestation by dates. She was managed conservatively until she suddenly developed profuse per vaginal bleeding and labour pains at 34 weeks. She was delivered by emergency caesarean section to a live female infant.

Antepartum haemorrhage (APH) is defined as the bleeding from or into the genital tract after the 28th week of pregnancy but before the birth of the baby (1,2). The incidence of APH among hospital deliveries is about 3% (1).

The causes of APH are either non-obstetric or obstetric. The non-obstetric causes include cervical and vaginal lesions such as candidiasis or cervical cancer. Obstetric causes include placenta praevia, abruption placenta, uterine rupture and blood clotting disorders (1,2).

The patient presented had APH secondary to placenta praevia.

Placenta praevia occurs when the placenta is implanted partially or completely over the lower uterine segment. About 33% of all APH cases are secondary to placenta praevia (3). The incidence of placenta praevia ranges between 0.5 – 1% amongst hospital deliveries. In England, Donald reported an incidence of 0.5% while an incident of 0.4% has been reported in the United States (4). In local studies at KNH, Ojwang (1974) found an incidence of 1 in 400 pregnancies while Kirima (1981) found an incidence of 0.9% (5,6).

The exact cause(s) of implantation of the placenta in the lower uterine segment is not known. However, the following theories have been postulated (2,3,4);

- *Dropping down theory*: - The fertilized ovum drops down and is implanted in the lower segment.
- *Defective decidua*: - This results in spreading of the chorionic villi over a wide area in the uterine wall to get nourishment. During this process, not only the placenta becomes membranous but encroaches onto the lower segment.

- *Persistent chorionic activity*: - In the decidua capsularis and its subsequent development into the capsular placenta which comes into contact with decidua vera of the lower segment.
- *Large surface area of the placenta* – as in twin pregnancy, may encroach onto the lower segment.

Increased incidence of placenta praevia has been associated with multiparity, increased maternal age, history of previous caesarean section, myomectomy, excessive dilation and curettage, previous history of placenta praevia and placental abnormalities including succenturiate lobes (1,2,3,4). Both Ojwang (1974) and Kirima (1981) found placenta praevia to be commonest in the age group 20-30 years and in women with parity of 3 and above (5,6).

Four types of placenta praevia are recognised depending upon the degree of extension of the placenta to the lower segment (3,4,5).

Type I: Also called lateral placenta praevia. The major part of the placenta is attached to the upper segment and only the lower margin encroaches onto the lower segment but not upto the os.

Type II: Also called marginal placenta praevia. The placenta reaches the internal os but does not cover it. It is further classified into type II anterior or type II posterior.

Type III: The placenta covers the internal os when the cervix is closed but does not entirely do so when it is fully dilated.

Type IV: The placenta completely covers the internal OS even at full dilation.

For clinical purposes, others, grade the placenta praevia into (4):

Minor (mild) degree –comprising type I and type II anterior

Major degree- comprising type II posterior, type III and IV

The patient presented had placenta praevia type IV or major degree.

Placenta praevia characteristically presents with painless vaginal bleeding. The bleeding is bright red and may cease completely only for it to recur again. In 50% of cases the first bleeding is rarely severe.

The patient presented had a painless vaginal bleeding which ceased but recurred subsequently after 2 weeks.

The cause of bleeding in placenta praevia is the formation of the lower segment and dilation of the internal cervical os leading to tearing off placental attachment (3,4).

Certain signs may point towards the possibility of placenta praevia. These include;

- Malpresentation e.g. breech,
- Transverse lie or unstable lie
- Floating foetal head, which may be slightly displaced from the midline. Abdominal palpation may reveal a non-tender uterus and readily palpable foetal parts. Bright blood oozing from the cervical os or a clot on it may be evident on speculum examination.

The patient presented had a non-tender uterus, fundal height corresponding to dates and a foetus in transverse lie. On speculum examination, she had some blood collection in the vagina, a clot on the external cervical os but without active bleeding.

Ultrasonography provides the simplest, most precise and safest method of placental localisation. It can precisely determine the extent of placental margin in relation to internal os. In addition, it is useful in assessing the foetal viability and maturity thus guiding subsequent management (2,4).

Objectively, there are two types of ultrasonography; the transabdominal and transvaginal ultrasound. Generally, its accuracy for placenta praevia beyond 30 weeks gestation is about 98%. False positive result may arise from a full bladder or myometrial contractions, while false negative may result from poor imaging due to maternal obesity or a posteriorly placed placenta (3).

In a study by Mbithi (1983), an accuracy of 86% was found in diagnosing placenta praevia by abdominal ultrasound at KNH (7).

Transvaginal ultrasound is more accurate than the transabdominal one, which could be attributed to the probe being very close to the target coupled by higher frequencies, which gives a superior resolution. Diagnosis of placenta praevia at an early gestation should be subjected to a repeat scanning at 34 weeks to detect placental migration (3,4).

The patient presented had an abdominal ultrasound, which confirmed the diagnosis of placenta praevia.

Other investigations that can be used to diagnose placenta praevia include magnetic resonance imaging (MRI), displacement placentography, soft tissue radiography and angiography. Radioactive isotopes labelling such as iodine 131 or 132 are now obsolete because of the fear of foetal congenital malformation (2,3,4).

Digital examination is only done in a double set-up in theatre and when the decision to deliver the patient has been made.

Examination under anaesthesia (EUA) is undertaken whereby the vaginal fornices are gently palpated for the presence of the placenta, which is characterised by a boggy feeling. This is useful in determining the type of placenta praevia and hence the mode of delivery. Type I and type II anterior can be delivered vaginally while type II posterior, type III and type IV should be delivered by caesarean section. EUA can also rule out the possibility of abruptio placenta in which the patient may be delivered vaginally.

The management of a patient presenting with placenta praevia can either be expectant or non-expectant, depending on the extent of haemorrhage, gestation, foetal well-being or whether she is already in labour or not. Conservative management is adopted when the bleeding is minimal or has stopped, preterm foetus, no foetal compromise and patient not in labour. The aim is to allow the pregnancy to continue until the baby has grown sufficiently enough to survive ex-utero (2,3,4). In our set up, it is 37 completed weeks of pregnancy.

Delivery is contemplated when the haemorrhage is profuse and continuing or recurrent, foetal compromise or is dead, patient is in labour, is term or there is foetal congenital malformation.

The patient is usually prepared for examination under anaesthesia (EUA) under double set-up. If it is type I or type II anterior, the membranes are artificially ruptured and induction by oxytocin commenced. As observed above, a patient with placenta praevia type II posterior, III or IV, should be delivered by caesarean section. If the patient has any contra-indication to vaginal delivery, e.g malpresentation or contracted pelvis, the patient is delivered by caesarean section irrespective of the type of placenta praevia.

The patient presented had placenta praevia type IV at 32 weeks, with no active bleeding and no foetal compromise. She was managed conservatively but was delivered by emergency caesarean section at 34 weeks when she suddenly developed severe haemorrhage and was found to be already in labour.

Placenta praevia is associated with both maternal and foetal complications. Maternal complications include haemorrhage, which can be antepartum, intrapartum or postpartum. Others include a retained placenta, which may increase the incidence of operative interference. Foetal complication includes low birth weight, prematurity, intra-uterine growth restriction or death in-utero. Others are abnormal lie (38.3%), cord prolapsed (1.7%), premature rupture of membranous (11%) and placenta percreta with bladder penetration (2,3,4). Ojwang in his series found a perinatal mortality of 39% due to placenta praevia (5).

The patient presented had a preterm baby at 34 weeks and who developed respiratory distress due to prematurity but nevertheless it survived - *her only successful pregnancy out of 5 pregnancies!*

References

1. Neilsoa J.P
Antepartum haemorrhage
In: Dewhurst's textbook of obstetric and gynaecology for post-graduates, 5th Ed.
, Blackwell science, 1995; Pg 164-173

2. Martin L. Pernoll
Third trimester haemorrhage
In: Current obstetric and gynaecological diagnosis and treatment, 8th Ed.
Appleton and Lange, 1994; Pg 404-407

3. Dutta D.C
Antepartum haemorrhage
In: Textbook of Gynaecology, 5th Ed, New central book agency, 2001; pg 256 –
267

4. Cunningham FG, Norman FG
Obstetrical haemorrhage
In: Williams obstetrics, 21st Ed, McGraw – Hill Publishers, 2001; Pg 630 – 635

5. Ojwang S B O
Placenta praevia at KNH
M. Med Thesis, UON, 1974

6. Kirima J.M
Antepartum haemorrhage at KNH
M. Med Thesis, UON, 1981

7. Mbithi
Gray scale ultrasonography in the diagnosis of placenta praevia at KNH
M. Med Thesis, UON, 1983

Case No. 5

ECLAMPSIA – LIVE BABY

Name:	P.A.	Parity:	0+0
Age:	25 years	DOA:	10.09.04
IP NO:	0982462	DOD:	20.09.04

Presenting Complaints

The patient was admitted to labour ward with history of having fitted twice at home within two hours prior to admission.

History of presenting complaints

The patient was admitted to labour ward from home with history of having fitted twice within 2 hours prior to admission.

History of presenting illness.

The patient had been well until 2 weeks prior to admission when she noted gradual swelling of legs, hands and the face. A day before admission, she had a frontal headache that gradually became severe, throbbing and could not be relieved by tablets of paracetamol that she had taken. A few hours before the onset of the fits, she had complained of disturbed vision and dizziness. A few moments before the first fit, her husband had noted that she had become confused and restless. The fits were described as generalized with twitching of muscles and frothing from the mouth. She had passed urine involuntarily during the fits. The fits were followed by drowsiness and confusion.

She was not a known diabetic, epileptic or to have hypertension prior to conception.

History of the current pregnancy

She was a primigravida and her last menstrual period was on 14/01/2004. Her expected date of delivery was on 21/10/2004 giving a gestational age of 34 weeks. She had attended antenatal clinic once at Riruta health centre but the records were not available.

Blood pressure taken at the clinic was said to be normal.

Past obstetric and gynaecologic history

She was a para 0+0 gravida 1. She had menarche at the age of 18 years. Her menses lasted 3 to 4 days, of normal flow, recurred after 28 days and were regular. She had no associated dysmenorrhoea. She gave no history of contraception.

Past Medical and Surgical History

This was not significant.

Family and Social History

She was married, a housewife and her husband was a casual labourer at a construction site. They lived at Riruta. Neither smoked cigarettes nor consumed alcohol.

She had no family history of chronic illnesses.

Physical Examination

General Examination

The patient was fully conscious, not pale, not jaundiced, and clinically afebrile but had facial puffiness, bilateral pitting oedema of both hands and legs.

Vital signs were: -

- Blood pressure - 180/110 mmHg
- Pulse rate - 110/minute, regular and good volume
- Respiratory rate – 18/minute
- Temperature – 36.8°C

Central nervous system

She was fully conscious, had no lateralising signs, the neck was soft and Kerning's sign negative.

Respiratory system

Her respiration rate was 18/minute and had no dyspnoea. She had no crepitations or rhonchi.

Abdominal examination

Her abdomen was uniformly distended and moved with respiration. The fundal height corresponded to 32 weeks gestation, foetus was in longitudinal lie, cephalic presentation and the descend was three fifths up. The foetal heart rate was 148 beats per minute and regular. She had two to three contractions in 10 minutes and each lasted between 20 and 40 seconds. She had no areas of tenderness. She had no palpable liver or spleen.

Vaginal examination

She had normal external genitalia. The cervix was 3cm dilated, 50% effaced, 1cm long, soft and central. The membranes were flat. Artificial rupture of membranes was done, had clear liquor and no cord was felt. The pelvis was clinically adequate.

Other systems

The breasts and cardiovascular system were essentially normal.

Diagnosis

A diagnosis of eclampsia in labour at 34 weeks gestation was made.

Management

The patient was put in the acute room. She was given intravenous magnesium sulphate 4 grams bolus over 10 minutes. Another 5 grams of magnesium sulphate was put in 500mls of normal saline infusion at a rate of 1 gram per hour was commenced. She also had an intravenous hydralazine 20mg bolus – slowly over 10 minutes. She was aseptically catheterized, about 200mls of clear urine was obtained and a ballooned foley's catheter left in situ. A sample of urine was taken for urinalysis. She had an intramuscular injection of hyosine (buscopan) 40mg and tramal 100mg start. She was augmented with 5 i.u. of syntocinon in 5% dextrose drip and titrated against the duration and intensity of the contractions. She was started on a partograph. Meanwhile, a blood sample for grouping and cross matching was taken and blood for other investigations as outlined below also taken. She was to have fluid input and output monitoring.

The labour progressed well and she had a spontaneous vertex delivery to a life male infant who weighed 1700 grams and scored 5 at 1- minute and 8 at 5 – minutes.

The baby was admitted to the newborn unit due to prematurity. The placenta appeared grossly normal and weighed 370 grams. The average blood loss was 200mls.

The magnesium sulphate infusion was continued for a total of 24 hours and subsequently transferred to the postnatal ward for continued monitoring of the blood pressure and renal function.

Investigations

- 1) Urinalysis - Proteinuria \pm , sugars nil, ketones nil and leucocytes nil.
- 2) Urea and electrolytes - Sodium 135mmol/L, Potassium 3.2mmol/L, Chloride 108mmol/L, creatinine 108 μ mol/L and urea 2.6 mmol/L.
- 3) Liver function tests - Total proteins 55g/L, albumin 30g/L, AST – 93 u/L,
ALT – 192u/L, ALP- 33u/L.
Total bilirubin -3.4 μ mol/L and direct -1.8 μ mol/L.
- 4) Total blood count-
 - WBC – 6.8×10^9 /L
 - RBC – 4.6×10^9 /L
 - Haematocrit – 36.3%
 - Haemoglobin -12.1g/dL
 - Platelets - 268×10^9 /L
- 5) Random blood sugar - 6.1 mmol/L
- 6) Blood slide for malaria parasites – negative
- 7) Blood group O and Rhesus positive
- 8) VDRL – negative
- 9) ELISA (HIV) – negative.

Post-delivery progress

After delivery, her vital signs remained within the normal range. Her blood pressure ranged between 110/60 mmHg and 140/90 mmHg. The proteinuria was 2+ and the urine output was 2200mls against fluid input of 2500mls. Repeat urea and electrolytes were normal. Repeat liver function tests showed elevated AST 62 u/L and ALT 160 u/L while ALP, bilirubin and albumin levels were normal.

After 24 hours of magnesium sulphate infusion without a fit, it was stopped and instead put on phenobarbitone and alpha – methyl dopa (aldomet) 250mg three times a day. The intravenous crystalline penicillin and gentamycin were stopped after three days and put on oral ampiclox 500mg four times a day and oral metronidazole 400mg three times a day. The catheter was removed and was subsequently weaned off the anti-hypertensives. The blood pressure stabilized and she was discharged home on 6th postnatal day. However, she could not leave the ward until the 10th postnatal day due to financial difficulties. She was booked for postnatal clinic after 4 weeks.

Postnatal Follow-up

She was seen in the postnatal clinic after 4 weeks and had no complains. Her blood pressure was 120/60mmHg and the urine had nil proteins. The uterus was involuted and not palpable the abdomen. The breasts were soft and active. She was not pale and had no peripheral oedema.

She was advised to book antenatal clinic early in the next pregnancy, preferably at Kenyatta National Hospital. She was counseled on family planning and referred to the family welfare clinic.

Discussion

The patient presented was a 25 years old primigravida admitted with antepartum eclampsia at 34 weeks gestation. She was found to be in active phase of labour and on augmentation she progressed well and had a spontaneous vertex delivery. Her blood pressure returned to normal a few days after the delivery and remained normal thereafter.

Pre-eclampsia when complicated with convulsions and / or coma is called eclampsia (1). The term eclampsia is derived from a Greek word meaning “like a flash of lightning”- implying that it may occur quite abruptly and without any warning manifestations (1). Almost without exception, pre-eclampsia precedes the onset of eclamptic convulsions (2). Depending on whether convulsions appear before, during or after labour, eclampsia is designated as antepartum, intrapartum or postpartum. Eclampsia is most common in the last trimester and become increasing more frequent as term approaches (2). In rare instances, eclampsia may develop before 20 weeks gestation. About 75% of eclamptic seizures occur before delivery and about 50% of postpartum eclamptic seizures occur in the first 48 hours after delivery but they may occur as late as 6 weeks postpartum (1,2,3). However, other diagnosis should be considered in women with the onset of convulsions more than 48 hours postpartum (2).

The patient presented had antepartum eclampsia in the last trimester (at 34 weeks gestation).

The incidence of eclampsia varies widely from country to country and even between different zones or regions of the same country. In the developed countries, its prevalence is far and few but in the developing countries, particularly in the rural areas, it is still rampant and contributes significantly to the maternal deaths (1). Eclampsia occurs in 0.2 – 0.5% of all deliveries with its occurrence being influenced by the same factors as in pre-eclampsia (3). Eclampsia is more common in primigravidae (75%) and it is five times more common in twins than in singleton pregnancies (1).

Other pre-disposing factors include black race, maternal age of below 20 years and over 35 years, chronic hypertension, underlying renal disease, hydatiform mole and low socio-economic status (2,4,5). Mati and colleagues (1983) found an incidence of eclampsia in Nairobi to be 0.17% (6).

The patient presented was a 25 years old black primigravida with a singleton pregnancy.

The aetiology of pre-eclampsia and eclampsia is unknown. But since eclampsia is a severe form of pre-eclampsia, the histopathological and biochemical changes are similar although more intensified than those of the pre-eclampsia (1).

Genetic, immunological, endocrine and dietary factors are thought to be involved in the genesis of pre-eclampsia/eclampsia (2,3,7).

Two key features in the pathogenesis of the disease are shallow endovascular cytotrophoblast invasion in the spiral arteries and endothelial cell dysfunction. The cytotrophoblasts are thought to generate inadequate blocking antibodies. The maternal immune system induces rejection phenomenon with altered vascular reactivity and compromised placental perfusion (7). Some authors believe immune reaction also causes disseminated intravascular coagulation and deposition of immune antibody complexes in the kidneys thus damaging the endolium. An imbalance of prostacyclin and thromboxane has been observed in some patients with pre-eclampsia/ eclampsia. In patients with the disease, the thromboxane is increased while prostacyclin and prostaglandin are decreased resulting in vasoconstriction and increased sensitivity to angiotension II (2,3,7). Increased vascular reactivity and altered thromboxane/prostacyclin balance causes hypertension which is compounded by loss of proteins in urine causing salt and water retention hence peripheral oedema (7).

The pathogenesis of eclamptic seizures is poorly understood. However, seizures have been attributed to platelets thrombi, hypoxia due to localized vasoconstriction and foci of haemorrhage in the cerebral cortex. There is a poor correlation between occurrence of seizures and severity of hypertension (2,7). Seizures may occur with insignificant blood pressure elevations that are only slightly higher than readings recorded a few hours earlier (1,2,3,7).

Usually there are no aura preceding the seizures and the patient may have one or more seizures. However, a severe headache, visual disturbances, epigastric pain or right upper quadrant pain or hyperreflexia in a woman with pre-eclampsia- are symptoms of impending eclampsia (1,2,3). The seizures are usually generalized tonic-clonic and followed by unconsciousness that may last for a variable period. Fever is rare but if present, it is a poor prognostic sign. Seizure induced complications may include tongue biting, broken bones, head trauma, aspiration pneumonia and retinal detachment (1,2,3,5).

The patient presented had dizziness, headache and visual disturbances prior to the onset of the seizures. She had a self bite-wound on the tongue.

The differential diagnoses include epilepsy, diabetic mellitus, encephalitis, meningitis, cerebral malaria, intracranial space occupying lesion, hysteria and metabolic diseases which cause electrolyte imbalances. It is therefore important to rule out some of these conditions that causes seizure, while bearing in mind that the commonest cause of convulsions in a pregnant woman is eclampsia, which if misdiagnosed may lead to fatal consequences (2,5).

In the patient presented, some of the differential diagnoses were ruled out by; blood slide for malaria parasites that was negative and random blood sugar that was normal, and a HIV test. Clinically, she had no signs of meningitis – the neck was soft and Kerning's sign was negative. From her past medical history, she was not an epileptic.

The management of eclampsia consists of control of convulsions and blood pressure, correction of hypoxia and acidosis, and delivery once the patient has been stabilized (2,3,8). The mechanism of the anti-convulsant action of magnesium sulphate (MgSO_4) is unknown. However, magnesium sulphate is known to reduce motor plate sensitivity to acetylcholine thereby reducing peripheral neuromuscular irritability. It induces cerebral vasodilation, dilates uterine arteries, increases production of endothelial protacyclin and inhibits platelet activation. It has no detrimental effects on the neonate within therapeutic levels (1,2,3). There are 3 regimens of magnesium sulphate administration, namely, Pritchard, Zuspan and Sibai (1). They vary slightly in the amount of loading and maintenance doses.

The Zuspan regime is the most widely used. The dosage schedule includes an initial loading dose of 4 grams of a 20% solution intravenously at a rate not exceeding 1g/minute. This is followed by a maintenance dose of 5 grams of magnesium sulphate in 500mls of normal saline infusion at a rate of 1 gram/hour. This treatment is continued for up to 24 hours after the last convulsion or delivery (1).

To detect or prevent development of drug toxicity during treatment, one must ensure that the respiratory rate is over 16/minute, urine output of at least 25ml/hour (100mls every 4 hours) and the presence of patella reflex (1,3,9). Other anti-convulsants used include diazepam, phenytoin and paraldehyde.

Currently, magnesium sulphate is the drug of choice for managing eclampsia at Kenyatta national hospital and was used in the patient presented.

Blood pressure is controlled using hydralazine, diazoxide, nitroglycerine, nifedipine or labetalol either singly or in combination. To achieve control of blood pressure, diastolic blood pressure needs to be brought down to between 90 and 100 mmHg. Hydralazine may be given as a bolus of 10-20mg intravenous whenever the diastolic blood pressure rises to or above 110mmHg. It may also be administered as an infusion to achieve a gradual steady decrease in blood pressure which does not impair foetal placental perfusion (1,2,5).

The patient presented had her blood pressure controlled by hydralazine infusion/bolus and later changed to oral alpha-methyldopa. Majority of obstetricians recommend that patients with eclampsia should be delivered without delay once their condition has been stabilized regardless of the gestational age (1,2,5). In majority of cases with antepartum eclampsia, labour starts soon after convulsions. However, if labour fails to start, termination of pregnancy should be done. The mode of delivery depends on maternal status and the viability of the foetus. It is determined amongst others by the speed with which the delivery must be expedited, foetal ability to withstand labour and the chances to successful induction of labour at an early gestational age. If the Bishop Score is good (favourable cervix) and there is no contra-indication to vaginal delivery, induction by artificial rupture of membranes is done and oxytocin drip commenced.

In cases where the Bishop score is poor (unfavourable cervix) and/ or there is contra-indication to vaginal delivery, an emergency caesarean section should be performed (1,2,3,5).

The patient presented was already in labour by the time of admission. However, labour was augmented by oxytocin drip, progressed well and had spontaneous vertex delivery.

Eclampsia may be complicated by pulmonary oedema, which may arise from aspiration pneumonitis or from cardiac failure, which may result from severe hypertension or vigorous intravenous fluid administration (1,3,10). Sudden death may occur synchronously with a convulsion or shortly after as a result of massive cerebral haemorrhage. Hemiplegia and aphasia may result from sub-lethal cerebral haemorrhage. In about 10% of cases, some degree of blindness will follow a seizure. The blindness is caused by retinal detachment or occipital lobe ischaemia, infarction or oedema . However, the prognosis for return of normal vision after retinal detachment is good and usually returns within a week (10). About 5% of women with eclampsia will have substantively altered consciousness, including persistent coma, following a seizure. This is due to extensive cerebral oedema, and transtentorial uncal herniation which may cause death. Rarely, eclampsia is followed by psychosis and the patient may become violent. The psychosis may last up to 2 weeks, but the prognosis for return to normal is good, provided there was no pre-existing mental illness (2,3,10).

Other potentially fatal complications of eclampsia include hepatic rupture, disseminated intravascular coagulation (DIC), renal failure, iatrogenic use of multiple drugs and anaesthetic accidents (1,2,3). Foetal wastage is high and may be done to pre-mature deliveries or intrauterine foetal death as a result of decreased foetoplacental perfusion, abruptio placenta or hypoxia and acidosis caused by the maternal seizures (5,11). Wanjohi (1984) in her series found the perinatal mortality to be 45.9% at Kenyatta National Hospital (11). In the same hospital, Makhoha (1991) found that hypertensive disease in pregnancy account for 12.8% of maternal deaths (4).

The patient presented did not develop any of these complications.

Postnatal follow up for up to 6 weeks is necessary to assess the renal function, proteinuria and blood pressure. For persistent abnormal renal function or raised blood pressure, further evaluation by a physician may be necessary.

The patient presented had normal renal function and her blood pressure had returned to normal during the postpartum follow – up.

Eclampsia is one of the most dangerous conditions that can afflict a pregnant woman and her foetus. However, the prognosis of eclampsia is good if well managed. The risk of eclampsia in subsequent pregnancy is about 2% and a risk of up to 33% for pre-eclampsia (1,2). Proper management of pre-eclampsia is vital since it prevents its progression into eclampsia. Adequate antenatal visits starting as early as possible may allow early detection and management of pre-eclampsia thus preventing the progression to eclampsia.

Though controversial, low dose aspirin has been recommended by some authorities in reducing the incidence of pre-eclampsia as well as hindering the progression to eclampsia (7,12).

The patient presented did not get adequate antenatal care but was advised to book the antenatal clinic as early as possible in future pregnancies.

References

1. Dutta D.C.
Hypertensive disorders in pregnancy.
In: Textbook of Obstetrics, 5th Ed, New Central Publications, 2001; page 234-252
2. Cunningham F.G. Gant F.G. et al
Hypertensive disorders in pregnancy.
In: Williams obstetrics, 21st edition, McGraw-Hill publications, 2001;
Page 567-609.
3. William C.M, Sibai B.M.
Hypertensive states of pregnancy.
In: current Obstetric and Gynaecologic diagnosis and treatment, 8th Ed, Appleton
and Lange, 1994; page 380 – 391.
4. Makokha A.E.
Medico-social and socio-demographic factors associated with maternal mortality at KNH.
J. Obstet. Gynaecol. East and Central Africa, 9: 3; 1991.
5. Redman C.W.G.
Hypertensive diseases in pregnancy.
In: Turnbull's Obstetric 2nd Ed, Churchill Livingstone publications, 1995; page
441 –463.
6. Mati J.K.G, Aggarwal V.P, Sanghvi H.C.G et al.
Nairobi birth survey II: Antenatal care in Nairobi.
J. Obstet. Gynaecol. East and Central Africa, 2: 1; 1983.
7. Sibai R.M, Gustaaf A, Diker P.
Aetiology and pathogenesis of pre-eclampsia: current concepts.
AM J. Obstet. Gynaccol. 179:1359 – 1375; 1998.

8. Ndavi P.M, Sanghvi H.C.G, Mwathe E.G. et al.
Low dose Aspirin therapy in patients at high risk for pregnancy induced hypertension and eclampsia at KNH and Pumwani Maternity Hospital.
J. Obstet. Gynaecol. East and Central Africa 13: 8; 1997.

9. Domisee J.
Phenytoin, sodium and magnesium sulphate in the management of eclampsia.
Brit. J. Obstet. Gynaecol 97:104 – 109; 1990.

10. Cunningham F.G, Twicker D.
Cerebral oedema complicating eclampsia.
AM J. Obstet. Gynaecol. 182: 94; 2000.

11. Wanjohi J.K.
Perinatal outcome among mothers with hypertensive disease in pregnancy.
M Med Thesis, UON, 1984.

12. Wangwe B.W.
Low dose Aspirin therapy in patients at risk for pregnancy – induced hypertension and eclampsia at KNH and Pumwani Maternity Hospital.
M Med Thesis, UON, 1995.

Case No. 6

RETAINED PLACENTA – MANUAL REMOVAL UNDER GENERAL ANAESTHESIA

Name:	JS	Parity:	0+0
Age:	18 years	DOA:	24.12.02
IPNO:	0854301	DOD:	16.01.03

Presenting Complaints

The patient was admitted in labour ward as a referral from Liana health clinic and maternity, Kangemi with a retained placenta for fourteen hours.

History of presenting complaint

The patient had delivered by spontaneous vertex delivery at home assisted by neighbours at around 3 a.m. on 24.12.02. The outcome was a life female infant and was reported to have cried immediately after birth. However, the placenta did not come out despite attempts to remove it. The patient and the baby were taken to the private clinic where further attempts of removal were unsuccessful and hence the referral to Kenyatta National hospital.

Obstetric and gynaecologic history

She was a primigravida whose last menstrual period was unknown, could not recall quickening and had no pregnancy test or ultrasound done earlier. She had not attended any antenatal clinic. She had menarche at 13 years. Her menses occurred after 28-30 days, lasting 3-4 days, regular and no associated dysmenorrhoea. She had never used any form of contraception.

Past medical and surgical history

This was not significant.

Family and social history

She was single and dropped out of school at standard six. She was an orphan, staying with a relative at Kangemi She was the third born out of the four siblings who resided in Vihiga. She neither smoked cigarettes nor consumed alcohol. There was no family history of chronic illnesses.

Physical examination

She was in fair general condition. She was moderately pale, not jaundiced, afebrile and had no peripheral oedema.

The vital signs were:

- Blood pressure -80/40 mmHg
- Pulse rate -118/minute, thready but regular
- Respiratory rate - 18/minute
- Temperature - 36.6°C

Abdominal examination

The abdomen was symmetrically distended on the lower half and moved with respiration. The uterine size corresponded to 24 weeks gestation. The uterus was firm and mildly tender.

Pelvic examination

She had normal external genitalia with no perineal tears or lacerations. A clamped umbilical cord was hanging from the introitus. The cervix was 6cm dilated and the placenta was felt in the uterine cavity but adherent. There was no active bleeding.

Other systems

The cardiovascular, central nervous and respiratory systems were essentially normal.

Diagnosis

An impression of retained placenta with postpartum haemorrhage was made.

Management

The patient was explained the nature of her condition and the intended management. She gave an informed consent. Blood for grouping and cross matching, and urgent packed cell volume (PCV) was taken. The PCV was 14% (Hb-4.8g/dl). An intravenous line was established and 40iu of oxytocin in a normal saline drip commenced. She was premedicated with atropine 0.6mg intramuscularly and wheeled to theatre.

In theatre, she was anaesthetised, put in semi-lithotomy position, done vulvovaginal toilet, draped and aseptically catheterized.

About 30mls of clear urine was obtained. Speculum examination revealed normal vaginal walls, anterior lip of the cervix was oedematous, had no cervical laceration and no active bleeding. The right hand was gently introduced into the vagina, the placenta followed up to the point of separation and shelved off the uterine wall, and delivered out easily.

During the procedure, left hand guarded the fundus of the uterus to prevent uterine inversion. Further exploration revealed no placental tissue left in the uterine cavity. The placenta appeared complete and grossly normal. Ergometrine 0.5mg was injected intramuscularly and the uterus contracted well. Blood loss was estimated at 200mls. General anesthesia was reversed successfully. The patient was transfused one unit of blood intra-operatively.

Post-operative care

She had quarter-hourly observation of vital signs until she was fully awake and then 4 hourly. She was put on parenteral antibiotics; crystalline penicillin 2mu 6 hourly, gentamycin 80mg 8 hourly and metronidazole 500mg 8 hourly for 24 hours and then converted to oral ampiclox, metronidazole and analgesics.

On the 4th post-placental removal, she developed severe abdominal pain of insidious onset and colicky in nature, hotness of the body and vaginal discharge. On examination, she was moderately pale, febrile (38.2⁰C), abdominal distension, marked lower abdominal tenderness, uterine size corresponded to 20 weeks gestation, and sluggish bowel sounds. Pelvic examination revealed a fowl smelling brownish pus-like discharge, cervix 4 cm dilated and a bulky uterus. The adnexae were free and pouch of Douglas empty. There was no per vaginal bleeding. Other systems were essentially normal. An impression of **puerperal sepsis** was made.

The blood count showed an elevated WBC count of $12 \times 10^9/l$ (neutrophils being 91%), and a haematocrit of 15.5% (Hb-5.2g/l). An endocervical swab taken showed growth of *Escherichia coli* and was highly sensitive to Clavulanic acid/amoxycillin (augmentin) among other antibiotics. The patient was put on intravenous Clavulanic acid/amoxycillin (augmentin) 1.2g 8 hourly, metronidazole 500mg 8 hourly and haematinics. She was transfused two more units of blood. She improved remarkably and was discharged after one week. However, because of financial constraints she did not leave the ward until 16.1.03 when she was weaved. The baby succumbed in Newborn Unit on 13.01.03 due to neonatal sepsis. She was booked for postnatal clinic after 3 weeks.

Follow-up

She did not turn up in the postnatal clinic.

Discussion

The patient presented was 18 years old primigravida who had spontaneous vertex delivery at home but had a retained placenta that was manually removed in theatre under general anaesthesia.

Retained placenta becomes a clinical entity when the placenta has not been expelled out within 30 minutes following the delivery of the baby (1). The patient presented had a retained placenta for fourteen hours by the time she was being admitted at KNH.

Physiologically, the uterus should contract after the delivery of the baby. The placenta then separates from the uterine wall and expelled spontaneously (1,2,3). Separation of placenta is evident by a sudden gush of vaginal bleeding, further protrusion of umbilical cord out of the vagina, uterus becomes round and firm, and it seems to rise in the abdomen (3). This process may take up to 30 minutes following the delivery of the baby but it may be hastened by use of oxytocin.

Diagnosis of a retained placenta is made by an arbitrary time spent following delivery of the baby; mostly given as beyond half an hour (1). Whether the placenta is retained with prior separation or not, is evidenced by the presence or absence of features of placental separation. The hour-glass contraction of the uterus or the nature of adherent placenta can only be diagnosed during manual removal (2,3).

Normal expulsion of placenta involves three phases, namely, separation through the spongy layer of decidua, descent into the lower uterine segment and vagina, and finally its expulsion to the outside (1). Interference in any of these physiological processes results in its own retention. A placenta that is completely separated but retained is usually due to poor voluntary expulsive efforts especially following exhaustive and prolonged labour (2,3). A simple adherent placenta is usually due to uterine atonicity especially in multigravidae, over distension of the uterus such as in twin gestation, prolonged labour and uterine malformation. A placenta incarcerated following partially or completely separation is due to constriction ring (hour-glass contraction). This may be due to intravenous ergometrine with the delivery of the anterior shoulder or premature attempts to deliver the placenta before it is separated (2,3,5).

Morbid adherent placenta either partially or rarely complete (placenta accreta, percreta and increta) is usually associated with a retained placenta (1,2).

A morbid adherent placenta is usually associated with a placenta that is implanted on the lower uterine segment (placenta praevia) or over previously injured sites such as in previous caesarean section, dilation and curettage, synaecolysis or myomectomy (1,2,3).

The patient present did not have the risk factors associated with a morbid adherent placenta.

A retained placenta is associated with at least 5-fold increase in postpartum haemorrhage (1,2,3). Makokha (1980) found that 15.2% of all maternal deaths at Kenyatta National hospital at the time were due to postpartum haemorrhage (4).

Other complications associated with a retained placenta include acute renal failure secondary to renal hypoperfusion, puerperal sepsis and risk of recurrence in next pregnancy, or death.

The patient presented had postpartum haemorrhage secondary to a retained placenta. She was transfused three units of blood. She also developed severe puerperal sepsis.

It is possible that the puerperal sepsis could have resulted from delivering under unhygienic conditions at home and having a retained placenta for long a period (23 hours between delivery of the baby and when the placenta was actually removed).

Opinion is divided over the timing of manual removal of the placenta. In the presence of haemorrhage, it is obviously unreasonable to wait for spontaneous separation even for 15 minutes and in such situations, manual removal of the placenta should be undertaken without delay (2). When a diagnosis of retained placenta is made, manual removal preferably under general anaesthesia should be done. The uterus should be kept contracted by use of 20 to 40 international units of oxytocin running in a drip. The placenta is separated manually from the uterine wall through a cleavage line after which it is removed in one piece. The foetal and maternal sides of the placenta should be inspected for completeness (1,2,3,5).

Although rare, a morbid adherent placenta without a cleavage line may be encountered. If bleeding is slight and preservation of reproductive capacity is desired, then the conservative management is advocated (3,5).

Necrosis and piecemeal expulsion does occur over 2-4 weeks. Of course, the risk of infection including anaerobes is high and administration of prophylactic antibiotics is recommended. Hysterectomy (total or subtotal) is usually recommended as the “last resort” in controlling massive postpartum haemorrhage (2,6).

In our set-up, sub-total hysterectomy is preferred. The patient presented had cleavage line identified and placenta removed manually with minimal bleeding.

References

1. Dutta D.C

Complications of the third stage of labour

In: Textbook of obstetrics, 5th Ed, New Central Publishers, 2001; Pg 450 and 451

2. Sabrina D.M, Peter S.K

Postpartum haemorrhage and the abnormal puerperium

In: Current obstetric and gynaecologic diagnosis and treatment, 8th Ed, Appleton and Lange, 1994; Pg 575 – 580

3. Cunningham G.F, Norman G F

Obstetrical haemorrhage

In: Williams's obstetrics, 21st Edition, McGraw-Hill Publishers, 2001; Pg 640 – 643

4. Makokha A.E

Maternal mortality at KNH

East Africa Med. J. 57:45; 1980

5. Beazley T.M

Complications of the third stage of labour

In: Dewhurst's textbook of obstetric and gynaecology for postgraduates
6th Edition, Oxford, Blackwell scientific publications, 1999; Pg 409-416

6. Read J.A, Cotton D.B, Muller FC

Placenta accreta: Changing clinical aspects and outcomes

AM. J. Obstet. Gynaecol, 56:31; 1980

Case No. 7

UNSENSITISED RHESUS NEGATIVE PREGNANCY- LIVE BABY

Name:	GW	Parity:	0+0
Age:	29 years	DOA:	13.05.04
IPNO:	0959839	DOD:	17.05.04

Presenting Complaints

The patient was admitted from home with a complaint of lower abdominal pain for three hours.

History of presenting illness

She had lower abdominal pains that were intermittent, progressively increasing in intensity and frequency. She had no per vaginal discharge or bleeding. She had no drainage of liquor, no dysuria, frequency or urgency.

History of current pregnancy

She was a primigravida. Her last menstrual period (LMP) was unknown and she was not sure of quickening. However, an ultrasound done on 8/04/2004 gave a gestational age of 34 weeks 1 day and on extrapolation, she was at a gestation of 39 weeks 6 days (Expected date of delivery 14.05.04). She had been attending antenatal clinic at Kenyatta National hospital since 30 weeks gestation (by fundal height). Antenatal profile done:

- Haemoglobin 13.8g/dL
- Blood group O negative. Her husband had blood group A positive
- VDRL Negative
- HIV Negative
- Indirect coomb's test (ICT) done at 34 weeks gestation was negative

Her subsequent antenatal visits were uneventful.

Past obstetric and gynaecologic history

Her menarche was at 15 years of age. Her menses lasted 3 to 5 days, normal flow, regular and recurred after 28 days. She had no associated dysmenorrhoea.

Past medical and surgical history

This was not significant

Family and social history

She was married, a vegetable vendor at Dagoretti market and her husband was a taxi driver. Neither of them drunk alcohol or smoked cigarettes. She had no family history of chronic illnesses.

Physical Examination

General examination

She was found to be in good general condition, not pale, not jaundiced, afebrile, and had no pedal oedema. Her vital signs were:

- Blood pressure -120/70 mmHg
- Pulse rate -78 beats per minute, regular and good volume
- Respiratory rate- 18 per minute
- Temperature - 36.7⁰c

Abdominal examination

The abdomen was uniformly distended and moved with respiration. There were no surgical scars. The fundal height was corresponding to term. The foetal lie was longitudinal, cephalic presentation, and a descend of four fifths up. The foetal heart rate was 140 beats per minute but irregular. She had 2 contractions in 10 minutes, each lasting between 20 to 40 seconds.

Vaginal Examination

She had normal external genitalia. The cervix was 4 cm dilated, presenting part well applied to the cervix, fully effaced and membranes were bulging.

She had a clinically adequate pelvis. Artificial rupture of membrane was done and meconium stained liquor grade II was observed. There was no umbilical cord felt.

Other Systems

The respiratory, cardiovascular and central nervous systems were essentially normal.

Diagnosis

A diagnosis of unsensitised rhesus negativity with foetal distress in early labour was made.

Management

The patient was informed about the nature of the diagnosis and the intended management. She gave an informed consent for an emergency caesarean section. Meanwhile, she was put on oxygen by mask, intravenous 10% dextrose drip and instructed to lie on the left lateral position. A blood sample for grouping and crossing matching was taken.

She was then shaved and wheeled to theatre after premedication with atropine sulphate 0.6mg intramuscularly.

Once on the operating table, the patient was positioned into semi-lithotomy, vulvovaginal toilet done and 40mls of clear urine obtained through aseptic catheterisation. Repeat vaginal examination revealed the same findings as those found in labour ward. She was then anaesthetised. The caesarean section was performed as described in the introduction. The outcome was a live male infant who weighed 3400grams and scored 8 at 1-minute and 10 at 5-minutes. The liquor was meconium-stained grade II. There was no cord entanglement encountered. The cord was double clamped and cut. The placenta was delivered manually and weighed 500g. The placenta and the umbilical cord appeared grossly normal. Meanwhile, cord blood for grouping, Rhesus factor determination, bilirubin level (total and differential), haemoglobin concentration and direct coomb's test (DCT) was taken. The abdomen was closed after a correct count of instruments, gauge rolls, swabs and needles. Blood loss was estimated at 400mls. General anaesthesia was successfully reversed.

The baby was admitted to newborn unit for observation because of the possibility of haemolytic disease of newborn.

Post- operative Care

While in the recovery room, the patient had continuous observations of vital signs until she was fully awake and thereafter every four hours. Intravenous fluids, namely, normal saline alternating with 5% dextrose, 500mls within 4 to 6 hours were given until the bowel sounds were auscultated

She also received intravenous crystalline penicillin 2mu 6 hourly, gentamycin 80mg 8 hourly, metronidazole 500mg 8 hourly and intramuscular pethidine 100mg 8 hourly.

Meanwhile, the cord blood sample results were;

- Hb 15.5g/dl
- Blood group: A positive
- Direct Coomb's test: Negative
- Bilirubin levels: Total 5.6 mg/dl (indirect 3.3 mg/dl and direct 2.3mg/dl).

The baby did not develop jaundice and breastfed well. The mother-received 300µgrams of anti-D intramuscularly on the 2nd post-operative day after baby's blood group and Rhesus factor were determined. She was discharged on the 4th postoperative day and booked for review in the postnatal clinic after six weeks but declined in favour of her local dispensary. However, she was advised that in future pregnancies, she must book antenatal clinic as early as possible.

Discussion

The patient presented was 27-years-old primigavida who had blood group O and Rhesus "D" negative, and her husband had blood group A-positive. She was unsensitised at term, went into spontaneous labour but was delivered by emergency caesarean section because of foetal distress. The infant's blood group was A-positive but the direct coomb's test was negative and therefore not affected by the haemolytic condition.

Rhesus negativity is mainly a caucasian trait with an incidence of 15 to 17%. The Basque population of Spain has the highest incidence of Rhesus negativity of 30 to 35%. In the Negroid race, the incidence varies between 4 and 8%. The lowest incidence is found in the Far East with less than 1% in China and almost nil in Japan (1,2). Locally, both Mati and Mulandi have given an incidence of Rhesus negativity among antenatal mothers in Nairobi as between 4 and 5% (3,4).

The patient presented was of black race.

Rhesus isoimmunization occurs when a Rhesus negative mother carries a Rhesus positive foetus and her immune system generates antibodies against the foetal red blood cells. When these antibodies cross the placental barrier and into the foetal circulation, they cause destruction of the antigen carrying Rhesus positive foetal red cells by haemolysis. These results in foetal anaemia with subsequent stimulation of extra-medullary erythropoietic sites giving hepatosplenomegally whereas, erthyroblastosis foetalis or postnatal kernicterus may occur in more severe cases of anaemia (1,2).

The Rhesus blood group is the most complex of human blood groups. The Rhesus antigens are lipoproteins that are confined to the red cell membranes. The Rhesus antigens are grouped into 3 pairs; the Dd, Cc and Ee, and are inherited in the mendellian version. The major antigen in this group is Rhesus D or Rhesus factor and it is of particular concern. If a woman who is lacking the Rhesus factor (Rhesus negative) and is carrying a Rhesus positive foetus and it happens that the foetal red cells pass into the maternal circulation in sufficient numbers, maternal antibodies to the Rhesus positive antigens may develop and cross the placenta causing haemolysis of the foetal red blood cells (1,2,5).

A foetus gets half of its genetic material from the mother and the other half from its father. A person with a Rhesus positive blood group is either homozygous or heterozygous, accounting for 45% and 55% respectively. If the father is homozygous, all of his children will be Rhesus positive. However, if he is heterozygous, half of his children will be Rhesus positive and half will be Rhesus negative. By way of contrast, the Rhesus negative individual is always homozygous (1,2,5,6).

In the case presented, the homozygous or heterozygous state of the husband was not determined because of the unavailability of the medical technology locally.

Isoimmunization occurs following incompatible blood transfusion or following foetomaternal haemorrhage between a mother and an incompatible foetus either during pregnancy or at delivery. With no apparent predisposing factors, foetal red cells have been detected in maternal blood in 6.7% of women during the first trimester, 15.9% during the second trimester and 28.9% during the third trimester (2,5). There is increased risk of foeto-maternal haemorrhage in spontaneous or induced abortions, placenta praevia, abruption placenta, intrauterine foetal demise, multiple pregnancy, manual removal of placenta, caesarean section delivery and following amniocentesis (1,2).

The patient presented had no known risk factor for foeto-maternal haemorrhage antenatally.

Although the exact number of Rhesus positive cells necessary to cause isoimmunization in a Rhesus negative pregnant woman is unknown, as little as 0.1mls of Rhesus positive cells will cause sensitization. Fortunately, about 30% of Rhesus negative persons never become sensitised (non responders) when given Rhesus positive blood (2,3,6).

ABO incompatibility between a Rhesus positive foetus and a Rhesus negative mother provides some protection against Rhesus isoimmunization; the overall incidence being 1.5 to 2% in these cases. This is attributed to the fact that foetal red cells are destroyed as soon as they enter the maternal circulation before they have sufficient time to induce a Rhesus isoimmune response. The overall risk of isoimmunization for a Rhesus positive ABO compatible infant with a Rhesus negative mother is about 16% (5,6,7)

The initial maternal immune response to Rhesus sensitisation is low levels of IgM.

IgM being larger molecules cannot pass through the placental barrier and therefore not harmful to the foetus.

Within 6 weeks to 6 months, IgG antibodies become detectable and being smaller molecules, they are capable of crossing the placental barrier and consequently destroy the Rhesus positive foetal red cells. Foetal anaemia results, thus stimulating extra-medullary erythropoietic sites to produce high levels of nucleated red cell elements. Immature erythrocytes are present in the foetal blood owing to poor maturation control. Haemolysis produces haeme, which is converted into bilirubin; both of these two substances are neuro-toxic (6,7,8).

The immature foetal liver with its low levels of glucoronyl transferase enzyme is unable to conjugate the enormous amounts of the bilirubin generated from red cells destruction. This results in high serum bilirubin levels, which may be deposited in the basal ganglia hence causing kernicterus postnatally. Severe anaemia in-utero leads to foetal hypoxia with hyperdynamic circulation that causes congestive cardiac failure, oedema, pleural, pericardial and peritoneal effusions (a typical picture of erythroblastosis foetalis) or intra-uterine foetal demise (2,6,7,8).

During the first antenatal visit, pregnant women should have their blood group and Rhesus factor or antigen determined. If the pregnant woman is Rhesus negative then the husband's blood group and Rhesus antigen should also be determined. If the husband is Rhesus negative, no further tests will be necessary. However, if the husband is Rhesus positive, his Rhesus phenotype should be determined. If he is heterozygous there is a chance of 50% of the offspring being Rhesus positive and 100% if he is homozygous. If the father's ABO group is incompatible with the mother's, there is a chance of about 60% that the offspring is ABO incompatible thereby reducing the risk of isoimmunization from 16% to 2% (2,6,7).

It is recommended that an antenatal mother should have her blood group and Rhesus factor determined on her first visit. If Rhesus negative, an ICT should also be done and paternal ABO and Rhesus blood group determined. ICT is repeated at 28 weeks, 34 weeks and 38 weeks (term).

The patient presented booked her antenatal clinic at 30 weeks gestation and her ABO and Rhesus factor was determined. Her partner's ABO and Rhesus factor were also determined. ICT was done at 34 weeks and at term; all of which tested negative.

When the initial ICT is negative, repeat tests should be carried out every 4 weeks till delivery and the mother given prophylactic dose of 300 μ grams of anti-D intramuscularly at 28 and 34 weeks gestation (2,4,6).

The patient presented was not given prophylactic anti-D antenatally because of the prohibitive cost involved.

At delivery, cord blood should be tested for ABO and Rhesus factor, direct Coomb's test (DCT), haemoglobin concentration and bilirubin levels. Maternal blood should be tested for ICT for antibodies and for the presence of foetal red blood cells. Prophylactic dose of anti-D 300 μ grams intramuscular is normally given to mothers who test negative for anti-Rhesus D antibodies and have delivered a Rhesus positive baby irrespective of the blood group. When a large amount of foetomaternal haemorrhage is suspected in excess of 30mls, the dose of anti-D may be increased to 500 μ grams or a repeat dose to be given after 4 to 6 weeks (5,6).

The patient presented was given anti-D 300 μ grams on the second postpartum day because the infant blood group was Rhesus positive and the postpartum ICT was negative.

In instances where sensitisation is detected, patients are followed-up with serial antibody titres until a critical level of 1 in 16 is reached (9). Serial ultrasound is done to detect any signs of hydrops or through Doppler studies to detect impairment of blood flow. Amniotic fluid is tested for absorbency of light in the yellow portion of spectrum for semi-qualification of bilirubin content of the fluid (5,6). The amount of bilirubin in the fluid is proportional to the extent of foetal red cell haemolysis. Using gestational specific curves developed by Liley (1964), clinical interpretation of the optical densities is done (9).

The Liley chart sets an intervention criteria for foetal affliction as follows (5,6);

- The mildly affected foetus is placed in zone one of the chart and amniocentesis repeated every fortnight and delivered once lung maturity is reached.

- The moderately affected foetus is placed in zone two, amniocentesis done weekly and delivered once lung maturity is established.
- The severely affected foetus is placed in zone three, and immediate intervention measures such as intra-uterine exchange transfusion with early delivery undertaken.

In the patient presented, ICT remained negative through out pregnancy and therefore amniocentesis or early intervention was unnecessary.

Perinatal morbidity and mortality among isoimmunized mothers has remained high (1,9). At Kenyatta National Hospital (KNH), the perinatal mortality is 600 per 1000 of isoimmunised cases (3,4).

At the moment, the practise at KNH is not to allow a Rhesus negative mother go beyond 40 weeks gestation because the incidence of foetomaternal haemorrhage, perinatal morbidity and mortality increases considerably in pregnancies beyond 40 weeks gestation (3,4).

The patient presented went into spontaneous labour before the 40 weeks gestation cut-off.

References

1. Dutta D.C

Specific cases

In: Textbook of obstetrics, 5th edition, new central book publication, Calcutta, 2002; Pg 352-362

2. Decherney A.H

Late pregnancy complications

In: Current obstetric and gynaecologic diagnosis and treatment, 8th edition, Appleton and Lange, 1994; Pg 339-342

3. Mati J. K.G, Aggarwal V.P, Sanghvi H.G.

The Nairobi Birth survey: Antenatal case in Nairobi

J. Obstet. Gynaecol for East and Central Africa, 2(1): 1; 1998

4. Mulandi T.N

A two-year prospective study to show the effectiveness of anti-D in preventing Rhesus isoimmunization of Rhesus negative pregnant Kenyan women at KNH.

M. Med thesis, University of Nairobi, 1985.

5. Bowine J. W Reece A.E

Maternal alloimmunization and foetal haemolytic disease

In: Medicine of the foetus and mother, 2nd edition, Lippincott- Reven publishers, 1999; Pg 1242-1249

6. Whitfield C.R

Rhesus and other red cell isoimmunization in pregnancy

In: Turnbull's obstetrics, 2nd edition. Churchill Livingstone publications: 1995; Pg 403-420

7. Cunningham FG, Macdonald P.C, Leveno K.J

Foetomaternal haemorrhage and haemolysis from isoimmunization.

In: Williams's obstetrics, 21st edition, Macgraw-Hill publications, 2001; Pg 1056-1068

8. Nicolini U

Foetal liver dysfunction in Rhesus alloimmunization

British J. Obstet. Gynaecol 98: 287; 1991.

9. Liley A, W

Liquor amnii analysis in the management of the pregnancy complicated by Rhesus sensitisation.

AM J. Obstet Gynaccol 82:1356-70; 1963

Case No. 8

BREECH PRESENTATION-CAESAREAN SECTION-LIVE BABY

Name:	D.A	Parity:	2+0
Age:	25years	DOA:	20.08.04
IP NO:	0961133	DOD:	25.08.04

Presenting Complaints

The patient was admitted to labour ward with complaints of lower abdominal pains and lower back pains for 8 hours. The abdominal pains were increasing in both frequency and intensity. She reported no per vaginal bleeding or drainage of liquor. She had no urinary symptoms.

History of current pregnancy

Her last menstrual period was on 15.11.03. The expected date of delivery was on 22.08.04 giving a gestational age of 39 weeks and 5 days. She booked antenatal clinic at Dandora health centre at a gestation of 28 weeks. She had a total of 6 visits. Antenatal profile done;- Haemoglobin – 11.4g/dl

VDRL – negative

ELISA (HIV) – negative

Blood group O and Rhesus factor positive.

During the antenatal follow-up, the presentation was recorded as cephalic except period between 30th and 34th weeks, when it was recorded as breech presentation.

Past Obstetric and Gynaecologic History.

She was para 2+0. The first delivery was in 1996 via spontaneous vertex delivery and weighed 2500g. The second delivery was in 1998 also via spontaneous vertex delivery, weighed 2800g and both babies were alive and well.

She had menarche at 15 years. Her menses lasted between 4 to 5 days, recurring after 30 days, regular and no associated dysmenorrhoea. She used combined oral contraceptives between 1998 and 2003, but stopped so as to conceive.

Past Medical and Surgical History

This was not significant.

Family and Social History

She was married, housewife and her husband was a businessman. They stayed at Dandora and neither smoked cigarettes nor consumed alcohol. Her mother had twins. She had no family history of chronic illnesses.

Physical Examination

General Examination

She was in good general condition and nutritional status. She was not pale, not jaundiced, afebrile, no peripheral oedema and no lymphadenopathy.

The vital signs; blood pressure -110/60 mmHg, pulse rate-78 beats per minute, respiratory rate-18/min and a temperature of 36.7°C.

Abdominal Examination

The abdomen was uniformly distended and the fundal height was corresponding to term. The foetus was in longitudinal lie, breech presentation, a foetal heart rate of 146 beats per minute and regular. She had 2 to 3 contractions in 10 minutes each lasting between 20 and 40 seconds. The estimated foetal weight was 3600g.

She had no organomegally.

Vaginal Examination.

She had normal female external genitalia. The cervix was 5 cm dilated, fully effaced, membranes intact, breech presentation. The sacral promontory was easily reached, the ischial spines were not prominent and the intertuberous space accommodated three knuckles.

Other Systems

The cardiovascular, central nervous and the respiratory systems were essentially normal.

Diagnosis

A diagnosis of breech in labour was made.

Management

A decision to deliver her by emergency caesarean section was made. The patient was informed the nature of her condition and the intended management. She gave an informed consent for an emergency caesarean section. A blood sample for grouping and cross matching was taken. An intravenous line was established and 5% dextrose drip commenced. She was shaved and premedicated with 0.6mg atropine sulphate intramuscularly. She was wheeled to theatre and the caesarean section performed as described in the introduction.

The outcome was a live female infant, complete breech, weighed 3550g, and scored 8 at 1 minute and 10 at 5 minutes. The cord was 80cm long. The liquor was meconium stained grade-1. The placenta appeared grossly normal and the estimated blood loss was 400mls.

Post – Operative care.

The patient's vital signs were observed quarter hourly until she was fully awake and then 4 hourly. Intravenous fluids, normal saline and 5% dextrose, were given 500mls 4 hourly until bowel sounds were auscultated.

Intramuscular pethidine 100mg was given 8 hourly for 24 hours followed by oral mefenamic acid 500mg thrice a daily. She received intravenous crystalline penicillin 2mu 6 hourly and gentamycin 80mg 8 hourly for 72 hours and then converted to oral amoxycillin 500mg 8 hourly for 5 days.

She did well postoperatively and was discharged on the 4th postoperative day.

She was booked for review after 6 weeks in the postnatal clinic.

Follow-Up

She had no complaints. She was in good general condition, not pale and afebrile. The breasts were soft and active. The incision site had healed. She had no vaginal discharge.

She was discharged from the clinic through the family welfare clinic.

Discussion

The patient presented was a 25 years old para 2+0 with breech presentation in labour at term. She was delivered by emergency caesarean section. The outcome was a life female infant who weighed 3550g and scored well

Breech presentation is said to occur when the foetal pelvis or lower extremities engage in the maternal pelvic inlet (1). Three types of breech are distinguished according to the foetal attitude. These are (1,2):-

- **Frank breech** – It is commonly found in primigravidae. The increased prevalence in primigravidae is thought to be due to a tight abdominal wall, good uterine tone and early engagement of breech. In frank breech, the thighs are flexed on the trunk, while the legs are extended at the knee joint. The presenting part consists of the two buttocks and external genitalia only.
- **Flexed (complete) breech** – the normal attitude of full flexion is maintained. The thighs are flexed at the hips and the legs at the knees. The presenting part consists of two buttocks, external genitalia and the two feet. It is commonly present in multiparae.
- **Footling breech** – one or both legs extends below the level of the foetal buttocks and into the birth canal. In singleton breech presentation in which the infant weighs less than 2500g; 40% are frank breech, 10% flexed (complete) breech and 50% footling breech. With birth weights of more than 2500g, 65% are frank breech, 10% flexed (complete) breech and 25% are footling breech (1,2,3).

The patient present was a multipara, birth weigh 3550g and had a flexed (complete) breech.

The global incidence of breech presentation at term is between 3 to 5% (2,3,4). Njuki (1979) found an incidence of 3.5% at Kenyatta National Hospital (5). The incidence of singleton breech presentation is more frequent with prematurity.

The incidence of breech presentation based on gestational age is reported as 3 to 5% at term, 8 to 10% at 34 weeks, 25% at 30 weeks and 30 to 35% at less than 28 weeks (1).

The aetiology of breech presentation remains unknown in over 50% of cases (1,2,4). Among the known causes, prematurity is the most common cause of breech presentation. Before 28 weeks gestation, the foetus is small enough in relation to intra-uterine space to rotate from cephalic to breech presentation and back again with relative ease. As the gestational age and foetal weight increase, the relative decrease in intra-uterine volume makes such movements more difficult. In most cases, the foetus spontaneously assumes the cephalic presentation to better accommodate the bulkier breech pole in the roomier fundal portion of the uterus (3,4).

Other causes include multiple gestation, congenital abnormalities especially hydrocephalus and anencephalus, congenital dislocation of the hip, spina bifida, meningomyelocele, congenital skeletal deformities and chromosomal abnormalities. Foetomaternal factors that favour breech presentation include polyhydramnios, oligohydramnios, placenta praevia and multiparity (1,4).

Uterine anomalies such as bicornuate uterus and presence of uterine fibroids especially in lower segment or pelvic tumours may be a cause of breech presentation (2). Most of these factors either prevent spontaneous version to cephalic as term approaches or cause premature labour and deliver before the spontaneous version occurs (1,4). The incidence of congenital foetal malformation in singleton breech presentation exceeds 6 %, while that of cephalic presentation is only 2-3% (1). Njuki (1979) found foetal congenital malformation in 4% of the cases with breech presentation while 82.7% of the cases were multiparous (5).

The patient presented had no known predisposing factors except multiparity.

The diagnosis of breech presentation is mainly clinical. Performance of Leopold's Maneuver and ballottement at the fundus encounters the hard and rounded foetal head. The breech is softer, ill defined and is located in the lower uterine segment above the pelvic inlet.

The foetal heart sounds are best heard above the umbilicus in breech presentation. On vaginal examination, the sacrum with its soft tissues is palpated in comparison with the firm rounded head in cephalic presentation.

The leg or foot of footling breech may be found protruding through the cervix in established labour with ruptured membranes (2,3,4).

In the patient presented, the foetal head was palpated at the uterine fundus, the foetal heart sounds being heard best above the umbilicus and the breech presentation being confirmed by vaginal examination.

Obstetric sonography is the most useful investigative tool to diagnose breech presentation. It is also useful in documenting the foetal size, estimated foetal weight, attitude, foetal abnormalities, and placenta localization, amount of liquor and to rule out multiple gestation (1,2,4).

Straight abdomino-pelvic X-ray may be done in cases of persistent breech at term to;

- Confirm clinical diagnosis
- Exclude body congenital malformation such as hydrocephalus
- Note the size of the body, the position of the limbs and head.

However, with the availability of ultrasound, the abdominopelvic X-ray is currently not routinely performed for diagnosis to avoid unnecessary exposure of the foetus and mother to radiation (7,8).

The patient presented was admitted in labour and the diagnosis of breech presentation made.

The management of breech presentation before and during labour is controversial. However, the modes of management include external cephalic version, vaginal breech delivery and caesarean section. During antenatal care period, the first consideration is external cephalic version (ECV)(9,10). The procedure is not considered before 34 weeks gestation because the foetus often reverts to breech presentation due to excessive room and liquor in the gravid uterus.

The ideal time for ECV is at 37 weeks but can be attempted at any time thereafter upto early labour. The procedure may be performed with or without tocolytics. ECV should only be performed in a facility where an emergency caesarean section can be carried out.

The procedure involves external rotation of the foetus from a breech presentation to cephalic presentation. The success rate of version is about 70-80%. Successful version reduces the risk of caesarean section significantly.

Contra-Indication of ECV includes;

- Severe pre-eclampsia or marked hypertension because of the risk of placenta abruption.
- Previous caesarean section –there is the risk of the scar giving way
- History of bleeding in early months or in suspected placenta praevia- there is a risk of placental separation.
- Presence of Rhesus isoimmunization because it increases the risk of foetomaternal haemorrhage and sensitization.
- HIV positive antenatal mothers -ECV may carry a risk of HIV transmission to the foetus.

Complications of ECV include placenta abruption, cord entanglement that may result in foetal distress or foetal demise, rupture of membranes with drainage of liquor and rarely rupture of the uterus (2,8,9).

Vaginal breech delivery is an option but it is not a common practice due to increased foetal morbidity and mortality associated with it especially under inexperienced or unskilled personnel. Vaginal breech delivery needs strict guidelines to avoid morbidity and mortality.

The criteria vary from place to place. Zatachni and Andros Prognostic Index is used to assess the possibility of vaginal breech delivery and takes into consideration the following factors: parity; previous history of vaginal breech delivery, gestational age in weeks, estimated foetal weight, foetal attitude in utero and an adequate pelvis. The parity should be one or more and the mother should have delivered successfully a breech of average weight vaginally before. The estimated foetal weight should be between 2500 and 3500 grams and a gestational age of at least 34 weeks. Foetal attitude should be a well-flexed foetus with a flexed head. A score of one is awarded for a favourable factor for vaginal breech delivery and a score of zero awarded when unfavourable. A total score of 0 to 3 is considered unfavourable for vaginal breech delivered and hence should be delivered by caesarean section. The delivery should be conducted by either an experienced obstetrician or midwife.

Other criteria for allowing vaginal breech delivery includes breech presentation in advanced labour, documented foetal congenital anomalies, foetus below 28 weeks of gestation and those between 34 to 40 weeks gestation (3,4,6).

At Kenyatta National Hospital (KNH), the practice has been to deliver breech presentation by caesarean section especially the primigravidae unless the patient is in advanced labour or has a foetal demise or a pre-viable foetus (less than 28 weeks).

The hazards of vaginal breech delivery are increased neonatal morbidity and mortality. The overall perinatal mortality ranges between 5 to 30% in hospital statistics in the developing world. The foetal mortality is least in frank breech and highest in footling breech- whereby the chance of cord prolapse is more likely.

Other common foetal complications in vaginal breech delivery include intracranial haemorrhage, asphyxia, fractures, and visceral or nerve injuries (2,3,4,6).

In an endeavor to improve perinatal outcome for the breech infant, caesarean section has been resorted increasingly (10,11).

In spite of the significant increase in caesarean section rate for breech presentation, Green and associates (11) found the foetal asphyxia rates to have remained the same. However, foetal trauma and death rates had declined. Generally, caesarean section especially the emergency ones are associated with an increased maternal morbidity and mortality from haemorrhage, infections and anaesthetic complications than vaginal deliveries. Consequently, most authors have declined to advocate caesarean section for all breeches (10,12).

Caesarean is, however, indicated in (1);

- Estimated foetal weight of over 3500g
- Premature foetus (25-34weeks)
- Unengaged presenting part
- Elderly primigravidae
- Contracted or borderline pelvis
- Footling breech
- Severe foetal growth restriction (IUGR)
- A mother with bad obstetric history (BOH)

It is the practice of many obstetricians to deliver all patients with breech presentation by elective caesarean section. This may be supported by the substantial excess risk of neonatal morbidity in vaginal breech delivery compared to caesarean section.

The patient presented was delivered by emergency caesarean section as she was considered a high risk. She had no previous success of vaginal breech delivery, and the estimated foetal weight was 3600g. The actual birth weight turned out to be 3550g- a big baby compared to her previous spontaneous vertex deliveries of 2500g and 2800g.

References

1. Collea J.V
Malpresentation and cord prolapse
In: Current Obstetric and Gynaecologic diagnosis and treatment,
8th edition, Appleton and Lange, 1994; pg 411-422
2. Dutta D.C
Malposition, malpresentation and cord prolapse
In: Textbook of obstetrics, 5th Ed. New central Publication, 2001; Pg 400 - 416.
3. Cunningham F.G
Breech presentation and delivery.
In: Williams Obstetrics, 21st Ed. McGraw-Hill Publications, 2001; pg 509-531.
4. Malvern J
Abnormal foetal presentation: Breech presentation
In: Turnbull's obstetrics 2nd Ed. Churchill-Livingstone publications, 1995; pg 666.
5. Njuki S.K
Breech presentation at KNH: mode of delivery and out come.
M. Med thesis U.O.N, 1979.
6. Irion O, Hirsbrunner A.P, Morabic A.
Planned vaginal delivery versus elective caesarean section. A study of 705 Singleton term breech presentation.
Bri. J. Obstet. Gynaecol, 105 (7); 710-717: 1998
7. De-Leeuw J.P, De-Ham et al.
Indications for caesarean section in breech presentation.
European J. Obstet. Gynaecol. And reproductive biology: 78 (1); 19-24: 1998.

8. Tenore A.C, Levotti M et al.
Efficiency of external cephalic version performed at term.
European J. Obstet. Gynaecol. And reproductive biology: 76 (2): 161-163; 1998

9. Coulson R, Seeras R, Mohammed K.
External cephalic version at term. A randomized controlled trial using tocolytics.
British J. Obstet. Gynaecol, 98 (1): 8;1991

10. Gimovsky M.L, Paul R.H.
Singleton breech presentation in labour.
AM J. Obstet Gynaecol. 143: 733; 1982

11. Quillighan E. J. Chein C, Collea J.V.
The randomized Management of term frank breech presentation.
Study of 208 cases.
A M J. Obstet. Gynaecol. 137: 235; 1980

12. Mclean F, Green J.E
Has increased caesarean section rate for term breech delivery reduced the incidence of birth asphyxia, trauma and death?
AM J. Obstet. Gynaecol. 142: 235; 1980.

Case No. 9

POST-DATE PREGNANCY – INDUCTION OF LABOUR-LIVE

BABY

Name:	AW	Parity:	1+0
Age:	25 years	DOA:	23.5.04
ID No:	0558100	DOD:	25.5.04

Presenting Complaint

She presented herself to the labour ward because her pregnancy had gone beyond the expected date of delivery.

Obstetric and Gynecologic History

AW was a para 1+0, gravida 2. Her last delivery was in 1999 through spontaneous vertex delivery at 38 weeks gestation and whose outcome was a live female infant weighing 3000gms and was alive and well. She had menarche at 13 years. Cycles were regular with menses lasting three to four days, recurred after 29-30 days, normal flow and no associated dysmenorrhoea. She had never used any form of contraception.

History of Present Pregnancy

Her last menstrual period (LMP) was on 27/7/03 and her expected date of delivery (EDD) was 3/5/04 giving her a gestation of 42 weeks 6 days on admission. She insisted of being sure of her last menstrual period. She booked her antenatal clinic at PCEA Kikuyu Hospital at 26 weeks gestation and then switched to KNH at 32 weeks gestation. She had a total of 11 visits. An obstetric scan was done on booking antenatal clinic at KNH at 32 weeks gestation.

Scan Report: - Showed a single intrauterine foetus, in longitudinal lie and cephalic presentation. The placenta was fundoposterior, amount of liquor was adequate and a foetal heart rate of 153 beats per minute. The BPD, FL and AC measurements corresponded to 31 weeks and 4 days.

Conclusion: A single intrauterine gestation at 31 weeks and 4 days.

Her antenatal profile done: Blood group A Rhesus positive, VDRL negative, HIV test negative, and Haemoglobin level 12.3grams/dl. Her antenatal follow-up was uneventful.

Past Medical and Surgical history

There was nothing significant.

Family Social History

She was married, worked in a saloon and stayed with her husband at Waithaka trading centre. The husband was a primary school teacher. Neither drunk alcohol nor smoked cigarettes. There was no family history of chronic illnesses.

Physical Examination

She was found to be in good general condition, not pale, afebrile, not jaundiced and no leg oedema. Her vital signs;

- Blood pressure (BP) was 100/60mmHg
- Pulse rate of 82/ minute
- Temperature of 36.7 degrees centigrade
- Respiratory rate of 18/minute

Abdominal Examination

The abdomen was uniformly distended and moving with respiration. There were no surgical scars and no tenderness. The fundal height was term. The foetus was in longitudinal lie, cephalic presentation, descend was three fifths up, foetal heart rate of 140 beats per minute and regular. There were no palpable contractions.

Pelvic Examination

She had a normal external genitalia, cervix was 3cm dilated, 0.5cm long, 80% effaced, soft and in the anterior position. The Bishop score was 8 (dilation – 2, consistency – 2, length – 1, and head station – 1). The pelvis was clinically adequate.

Other Systems

These were found to be essentially normal.

Diagnosis:

A diagnosis of post date pregnancy with a good Bishop score was made.

Management

A decision was made to induce labour after she was duly explained on the relevance of doing so. In view of her good Bishop score, artificial rupture of membranes (ARM) and the stripping of the membranes was done. The liquor was clear and no cord was felt. Five international units of oxytocin in 500mls of 5% dextrose drip was commenced through an intravenous line and titrated against the frequency and the durations of the contractions. A partogram was started and labour events monitored.

The labour progressed well and she had a spontaneous vertex delivery of a live female infant who weighed 3500gms and scored 9 at 1 minute and 10 at 5 minutes. The placenta and umbilical cord appeared grossly normal.

The infant had scaly patchment and wrinkled skin with little subcutaneous fat. The nails were long and protruding beyond the nail bed. The estimated blood loss was 200 mls and the perineum was intact. No episiotomy was done. She was injected with 0.5mgs of ergometrine intramuscularly. Her postnatal observations remained within normal limits. She was allowed home on 25.3.04 and was to be reviewed after 6 weeks in the postnatal clinic.

However, she declined this and preferred to be reviewed and seek family planning services at her local dispensary.

Discussion

The patient presented was a 25 years old para 1+0 with a post-date pregnancy. She was successfully induced and delivered a live female infant.

Literally, any pregnancy that has passed beyond the expected date of delivery is called a prolonged or post dated pregnancy. But for clinical purposes, a pregnancy continuing beyond two weeks of the expected date of delivery is called post term pregnancy or post maturity (1,2,3). Because of lack of uniformity in the definition of a post date pregnancy, the quoted incidence varies from 2% to 15%. (1,2,3). Elfesh (1998) found an incidence of 4.9% at KNH and Pumwani Maternity Hospital.(4).

The most common criteria used to establish the gestational age is the menstrual history. However, menstrual history has been found suspect when early pregnancy ultrasonographic gestational age assessment is compared with the dates. Gestational age arrived through menstrual history, could be influenced by uncertainty in the last menstrual period occurrence, recent history of hormonal contraception and menstrual cycle irregularities (5,6).

Sonographic gestational age assessment is found to be more accurate in early pregnancy. Crown-rump length (CRL), biparietal diameter (BPD) and femur length (FL) measurements are the parameters of choice for assessment of gestational age. If the gestational age estimated by these measurements, especially in early pregnancy, differs from those derived by the last menstrual period (LMP) by more than two weeks, then recalculation of the dates should be considered (7).

Generally, the third trimester sonographic gestational age assessment has a degree of accuracy of ± 2 to 3 weeks and is therefore of limited use in dating a pregnancy (1,6).

In the patient presented, post maturity was based on both menstrual history and extrapolated sonographic gestational age assessment.

There are suspect clinical findings that are evidence when an otherwise uncomplicated pregnancy overruns the expected date of delivery by two weeks.

Post maturity, for example, can be suspected when regular or periodic weight measurements reveal a stationally or even falling weight or when on abdominal palpitation, the uterus feels "full of foetus" as the liquor amount diminishes (1,6).

It is possible to make a retrospective diagnosis of a post date pregnancy. Generally, the infant may appear thin and old, there may be absence of vernix caseosa and the head without much evidence of moulding. The nails may protrude beyond the nail beds and the amniotic fluid may be stained with old meconium. The placental aging may be manifested by excessive infarction and calcification. There may be diminished quantity of Wharton's jelly, which may precipitate cord compression (1,2,3,6).

The patient presented, delivered an infant who looked thin and old, had little subcutaneous fat and nails that had protruded beyond the nail beds. However, the liquor was clear and both the placenta and umbilical cord appeared grossly normal.

Post maturity is associated with increased perinatal morbidity and mortality. There is also increased instrumental and operative interference (1,2,3,7). During pregnancy, placental aging may lead to diminished placental function with resultant foetal hypoxia. The hypoxic state, is however, aggravated by such associated factors like elderly patients, hypertensive disorders of pregnancy and history of antepartum haemorrhage (2,3,7). During labour, there is increased incidence of asphyxia and intracranial damage due to aggravating pre-existing hypoxia that leads to foetal distress. Increased incidence of difficulty labour and delivery due to big baby, non-moulding foetal skull and occasional shoulder dystocia is frequently encountered in post date pregnancies. There is associated scanty liquor amnii and less Wharton's jelly that predisposes to cord compression giving an overall increase in incidence of operative delivery (1,2,3,7,8)

Following birth, post term infant is likely to suffer from meconium aspiration and atelectasis. This results from premature attempt at respiratory efforts due to increased anoxia with consequent inhalation of meconium containing liquor amnii (2,3,7). Post term infants are also associated with lower *apgar* scores and they may also suffer from hypoglycaemia and polycythaemia especially in growth retarded post term infants.

References

1. Dutta D.C
Post maturity
In: Textbook of Obstetric, 5th Ed., New Central Book Publishers, 2001; Pg 338-343
2. Alan H. Decherney
Prolonged pregnancy
In: Current Obstetric and gynaecologic diagnosis and treatment, 8th Ed. Appleton and Lange, 1994; Pg 338-339
3. Cunningham F.G, Grant FN
Post term pregnancy
In: Williams Obstetric, 21st Ed, McGraw-Hill Publishers, 2001; Pg 732-741
4. Elfenesh D
Postdate pregnancy and foetal outcome
M. Med Thesis, UON, 1998
5. Warsof S L, Pearce J. M.
The present place of routine ultrasound screening
Clinical Obstet. Gynaecol. 10: 445-447; 1983
6. Tunon K, Grothum P.
A Comparison between ultrasound and a reliable LMP as predicts of the delivery in 15,000 examinations.
Ultrasound Obstet. Gynaecol. 8: 178-185; 1996
7. Miller DA, Paul H.R
Post term pregnancy
In: Medicine of foetus and mother, 2nd Ed, Lippincott-Raven, 1999; Pg 1627-1640

All these factors leads to increased perinatal loss, the magnitude of which is doubled at 43 weeks and tripled at 44 weeks gestation compared to those delivered at term (1,2,3).

The patient presented, had uneventful labour and went ahead to have a spontaneous vertex delivery. The infant had good *apgar* scores.

Induction of labour refers to the stimulation of uterine contractions before spontaneous onset of labour (9). The methods used for labour induction are either medical or surgical and they include oxytocin, prostaglandins, membrane stripping, amniotomy and use of laminaria tensi (1,2,9).

The patient presented had a good Bishop's score, which facilitated amniotomy and membrane stripping followed by oxytocin in 5% dextrose drip.

The risks of labour induction include iatrogenic prematurity, uterine rupture, cord prolapse, increased caesarean section rate and increased neonatal morbidity and mortality (1,3,9).

Kaguta (1984) found that 2% of induced labour at KNH ended in caesarean section due to failure of the uterus to respond despite what was deemed adequate stimulation and other circumstances like foetal distress, accidental haemorrhage and cephalopelvic disproportion (8).

The patient presented had no complications during labour and post delivery.

8. Kaguta T

Review of induction of labour: outcome and complications as seen at KNH

M. Mcd Thesis, UON, 1984

9. Beatley

Special circumstances affecting labour

In: Dewhurst's Textbook of OBS/GYN for postgraduates 5th Ed, Blackwell
Sciences Ltd, 1995; Pg319-329

Case No. 10

PRE-LABOUR RUPTURE OF MEMBRANES (PROM) – INDUCTION OF LABOUR – LIVE BABY.

Name:	C.A	Parity:	0+0
Age:	23 years	DOA:	16.06.04
IP NO:	0965945	DOD:	18.06.04

Presenting Complaints

The patient was received from ward 6D with a complaint of drainage of liquor for about 9 hours.

History of presenting illness

The patient had been admitted in ward 6D one day earlier with a cut Achilles tendon of the left leg after a fall within her home compound. While awaiting repair, she started draining liquor, soaking her pants and flowing down her legs. She had no associated lower abdominal pains, no dysuria, frequency or urgency. She had not been treated for urinary tract infection or per vaginal discharge. She had no preceding febrile illness.

History of current pregnancy

Her last menstrual period was on 10/9/2003 and her expected date of delivery was on 17/6/2004 giving a gestational age of 39 weeks and 6 days. She booked her antenatal clinic at Wangige health centre at a gestation of 30 weeks. She had made a total of 4 visits. Her antenatal profile was normal; -

- ELISA for HIV- Negative
- VDRL – Negative
- Blood group O, Rhesus positive
- Haemoglobin level – 12.2g/dL and normal urinalysis.

Her antenatal care period was uneventful.

Past Obstetric and Gynaecologic History.

Her menarche was at 15 years of age. Her menses lasted 3 days, of normal flow, recurred after 28 days, regular and no associated dysmenorrhoea. She had no history of contraception.

Past Medical and Surgical History

This was not significant.

Family and Social History

She was married, a student at a teaching college. She was a social drinker, taking alcohol occasionally but did not smoke cigarettes. Her husband was a teacher who neither smoked cigarettes nor consumed alcohol.

There was no family history of twinning or chronic illnesses.

Physical Examination

General Examination

She was found to be in good general condition, not pale, afebrile, not jaundiced and no pedal oedema. Her vital signs: - Blood pressure 110/60 mmHg, pulse rate 78/ minute, respiratory rate 18/minute and a temperature of 36.7°C.

Abdominal Examination

The abdomen was uniformly distended with a gravid uterus and moved with respiration. The fundal height was term, longitudinal lie, cephalic presentation, descend four fifths above the pelvic brim and regular foetal heart rate of 148 beats per minute. There were no palpable contractions.

Speculum and digital examination

The patient was placed in semi-lithotomy position, vulvovaginal toilet done and a sterile spectrum inserted into the vagina gently and aseptically. She had normal vaginal mucosa.

The cervix was healthy and there was obvious drainage of clear liquor through the cervical os but was not foul smelling. A pool of liquor was noted in the posterior fornix. There was no cord seen.

On digital examination, the cervix was found to be 1 cm long, anterior, admitting a tip of the finger (1cm) and soft. There was no palpable cord and the pelvis was clinically adequate. The stripping of the membrane was done.

Musculoskeletal system

The bandage covering the left heel was removed. She had a severed Achilles tendon, was unable to plantar flex the ankle joint, and had a palpable gap above the calcaneus.

Other systems

The cardiovascular, central nervous and respiratory systems were essentially normal.

Diagnosis

A diagnosis of pre-labour rupture of membranes at term was made.

Management

The patient was explained the nature of diagnosis and need of being delivered as soon as possible. She was admitted for induction and started on parenteral anti-biotics; crystalline penicillin 2 mu 6 hourly and gentamycin 80mg 8 hourly. Labour was induced with 5 international units of oxytocin in 500mls of 5% dextrose drip and titrated against the frequency and intensity of contractions.

The labour progressed well and after eight hours, she delivered by spontaneous vertex delivery to a life female infant who weighed 3900 grams and scored 9 at 1 minute and 10 at 5 minutes. The placenta was delivered by controlled cord traction, was complete and appeared grossly normal. She received 0.5mg of ergometrine intramuscular. The episiotomy was repaired with catgut number 0. Average blood loss was estimated at 150mls. The baby was reviewed by the paediatrician and put on prophylactic amide neonatal drips 62.5mg 6 hourly for five days but allowed to join the mother.

On the 1st postnatal day, the patient was reviewed by the surgeon and scheduled for tendon repair, which was undertaken the following day under general anaesthesia and put a back slab.

She was discharged on the third postnatal day through the surgical outpatient clinic (SOPC) and booked for review after 6 weeks.

Follow-Up

The patient was reviewed in the SOPC after 6 weeks as scheduled. She was found to be in good general condition, not pale and afebrile. The Achilles tendon had healed well and the back slab was removed and booked for physiotherapy.

Discussion

The patient presented was a 23 years old primigravida with pre-labour rupture of membranes at term. She was successfully induced with oxytocin and the outcome was a life female infant who scored well. The patient also had a cut left Achilles tendon, which was successfully repaired and discharged on antibiotics and a back slab.

The term pre-labour or premature rupture of membranes (PROM) is defined as the spontaneous rupture of membranes any time beyond the 28th week of pregnancy but before the onset of labour (1). When the rupture of membranes occurs beyond 37 completed weeks of pregnancy but before the onset of labour, it is called term PROM. When the rupture of membranes occurs before 37 completed weeks, it is called pre-term PROM (1). If 24 hours have elapsed between the onset of rupture of membranes and the onset of labour, then prolonged rupture of membranes is said to have occurred (2).

Premature rupture of membranes occurs in approximately 10.7% of all pregnancies. In approximately 94% of the cases the infant is mature, 5% being premature and 0.5% being immature (2). The incidence of premature rupture of membranes at Kenyatta National Hospital was reported as 9.3% by Otieno (1979) and 8.2% by Wanjala (1980) (3,4).

The exact cause of premature rupture of membranes (PROM) is not known (1,5). However, a number of risk factors have been identified. The final pathway is an absolute or relative weakness of the membranes leading to rupture (5). These risk factors include - cervical incompetence, polyhydramnios, multiple pregnancy, urinary tract infection, bacterial vaginosis, chorioamnionitis, cigarette smoking, history of preterm labour or PROM, malpresentations and prenatal diagnostic procedures such as amniocentesis and chorionic villi sampling. Other risk factors include abdominal trauma, nutritional deficiency of trace elements such as zinc, copper and vitamin C, coitus, digital examination, abruption placenta/placenta praevia and connective tissue disorders with inherent decreased tensile strength of foetal membranes (1,2,5).

The patient presented had premature rupture of membranes most probably as a result of abdominal trauma.

The diagnosis of premature rupture of membranes requires integration of history, physical examination and investigative procedures. History alone has an accuracy of 90% (1,5). There may be history of sudden gush of amniotic fluid per vagina or continued intermittent leakage or increased perineal moisture (2). History alone may be misleading especially when there is excessive vaginal discharge or urinary incontinence, which may be mistaken for drainage of liquor. It is therefore important to confirm the diagnosis by a sterile speculum examination whereby amniotic fluid can be seen draining/escaping from the cervical os and forming a pool in the posterior vaginal fornix. If the amniotic fluid cannot be visualized easily, application of some slight fundal pressure or by asking the patient to cough or perform a valsalva maneuver may induce leakage of the fluid through the cervical os. The presence of meconium staining of the liquor often verifies the diagnosis (1,2,5,6).

In the patient presented, the diagnosis of premature rupture of membranes was made from history and speculum examination, which revealed leakage of liquor through the cervical os.

The premature rupture of membranes should be differentiated from vaginal discharge, semen or urine as a result of urinary incontinence. In an event of uncertainty, various diagnostic tests can be used to confirm it is indeed amniotic fluid. The normal vaginal PH during pregnancy is 4.5 to 5.5 whereas that of liquor is 7 to 7.5. Since amniotic fluid is alkaline, it turns nitrazine paper or litmus paper to blue colour. The amniotic fluid has a characteristic ferning pattern when a smeared slide is examined under a microscope. The amniotic fluid may also contain flecks of vernix caseosa and the foetal hair (lanugo). In addition, foetal cells present in amniotic fluid stain with Nile-blue and Sudan red dyes (1,2,6).

Occasionally it may be necessary to inject a dilute solution of Evan's blue or Indigo carmine into the amniotic fluid and observe for flow of the dye into the vagina to confirm membrane rupture (5). Ultrasonography is used to confirm or support the diagnosis. It is also used to assess the amount of amniotic fluid, foetal well-being, foetal malpresentation, placental localization and assessment of foetal maturity (5).

Abdominal palpitation may also reveal a reduced uterine size compared to the period of amenorrhoea.

The patient presented had a reliable diagnosis based on the history and physical examination and therefore these confirmatory tests were not done.

The management of premature rupture of membranes (PROM) depends on the gestational age, foetal lung maturity, whether the patient is in labour or not, presence of infection, compromised foetal well-being and the availability of sophisticated neonatal care (1,2,6). The management of term PROM is controversial. Those who advocate for expectant management argue that over 90% of cases will go into spontaneous labour within 24 hours and that induction of labour before 24 hours are over increases the caesarean section rate (2,5,6). However, those who advocate for active management base their argument on the fact that prolonged PROM increases the risk of infection with the end result of high maternal and perinatal morbidity and mortality. However, both the protagonists and antagonists of active management of term PROM agree that those cases with unfavourable Bishop score requires cervical ripening with prostaglandins and therefore reducing the caesarean section rates due to failed induction (6).

Currently, the practice at Kenyatta National Hospital is to deliver patients with PROM at term as soon as possible by inducing labour or by augmenting mild labour.

The patient presented was managed actively by labour induction using oxytocin.

The management of preterm PROM needs to be selective and individualized. The objective is to balance the risk of infection in expectant management (while pregnancy is continued) versus the risk of prematurity in active intervention (1,2). The initial management involves the confirmation of ruptured membranes, ruling out infection, determining the gestational age and foetal lung maturity. For gestational age of 34 weeks and above, the perinatal mortality from prematurity is less compared to infection.

The practice at Kenyatta National Hospital is to induce labour in such cases. Presentation other than cephalic merits a caesarean section.

Though rare, the leakage may seal spontaneously and pregnancy continues. The objective of conservative management is aimed at prolongation of gestation to allow lung maturity since prematurity is the greatest danger to these foetuses.

When the gestational age is less than 34 weeks, conservative management is advocated. The patient is admitted and advised on strict bed rest. Prophylactic antibiotics are instituted to minimize maternal and perinatal risks to infection. Maternal pulse, temperature and foetal heart rate are recorded every 4 hours. Total blood count is done at least twice weekly and an endocervical swab for culture and sensitivity is taken weekly. Lower abdominal tenderness, and colour, amount and the smell of the sanitary pads being observed daily. An ultrasound is done weekly to determine the amount of liquor and assessment of foetal well-being. A digital examination is avoided unless the decision to deliver the patient has been made.

A raised maternal pulse, foetal tachycardia, lower abdominal tenderness, or a foul smelling liquor-soaked sanitary pad is highly suggestive of chorioamnionitis.

This may be supported by leucocytosis and bacterial growth from the endocervical swab specimen. In such circumstances, the conservative management is abandoned, induction of labour undertaken straight away regardless of the gestational age, and broad-spectrum parenteral antibiotics commenced (1,5).

The role of tocolytics and corticosteroids in the conservative management of preterm PROM has remained controversial. Most studies have concluded that tocolytics have no role because they might shield labour, which is one of the early signs of chorioamnionitis. However, tocolytics may be used when it is absolutely necessary to delay delivery, for example, to allow transportation of a patient to a centre with adequate neonatal care facilities (1,2). Premature rupture of membranes (PROM) per se accelerates foetal lung maturity and therefore the use of corticosteroid to stimulate synthesis of surfactant against respiratory distress syndrome in preterm neonates may not be justified. In fact, the use of corticosteroids may enhance the risk of infection (1,2,6).

Premature rupture of membranes is associated with increased maternal and perinatal morbidity and mortality. PROM is an important cause of preterm labour and prematurity. In case of prolonged rupture of membranes, the liquor becomes infected (chorioamnionitis) and foetal infection supervenes. There is also increased incidence of cord prolapse especially when associated with malpresentation.

Continuous escape of liquor and for long duration may lead to oligohydramnios with the resultant foetal pulmonary hypoplasia and dry labour (1,6).

Foetal compression syndrome is associated with severe oligohydramnios and may be characterized by amniotic band amputations, limb and skeletal deformities and cord compression, which give foetal distress (1,2,6).

References

1. Dutta D.C.
Preterm labour, PROM, postmaturity and intrauterine foetal death
In: Textbook of Obstetrics, 5th edition, New Central publications, 2001; pg 337-338
2. Martin L.P.
Late pregnancy complications
In: Current Obstetric and Gynaecologic Diagnosis and Treatment, 8th edition, Appleton and Lange publications, 1994; pg 331 - 338
3. Otieno J.A.
Spontaneous rupture of membranes
M. Med Thesis, 1979.
4. Wanjala S.M.H.
Preterm rupture of membranes
M. Med Thesis, UON, 1980.
5. Patrick D.
Preterm rupture of membranes
Clinical Obstetrics Gynaecology Vol. 34, No. 4:12; 1991.
6. Cunningham F.G. Gant F.G. et al.
Dystocia: Abnormal labour and foetopelvic disproportion
In: Williams Obstetrics, 21st edition, McGraw-Hill publications, 2001; pg 440-441

Case No. 11

GESTATIONAL DIABETES MELLITUS – CAESAREAN SECTION – LIVE

BABY.

Name:	F.K.	Parity:	2+0
Age:	33 yrs	DOA:	22.07.04
IP NO:	0973185	DOD:	16.09.04

History of Presenting Complaints

The patient was admitted from the antenatal clinic after being found to have an elevated random blood sugar (11.3 mmol/L and a glycosuria +4. She was not a known diabetic and had no history of elevated blood sugar in the previous pregnancies. She had no complaints of polyuria, polydipsia, nocturia or dysuria.

She was also noted to have an elevated blood pressure (140/100) against a previous reading of 110/60 mmHg. She was not a known hypertensive.

History of current pregnancy.

She booked her antenatal clinic at KNH at a gestational age of 18 weeks and had a total of 5 visits by the time of admission. Antenatal profile done- blood group A and rhesus positive, ELISA (HIV)- negative, VDRL- negative and a PCV 40% (Hb 13.3 g/dL). Urinalysis at booking showed glucose -nil and protein -nil. During the antenatal visits, the fundal height was always 4 weeks above the gestational age by dates.

Her last menstrual period was on 4/01/2004 and her expected date of delivery was on 11/10/2004 giving a gestational age of 28 weeks.

Past Obstetric and gynaecologic history

She was a para 2+0 gravida 3. Her first delivery was in 1993 via spontaneous vertex delivery at term and whose outcome was a life male infant who weighed 3500 grams. The second delivery was in 1996 also via spontaneous vertex delivery at term and the outcome was a life male infant who weighed 3800 grams. Both were alive and well.

She had her menarche at 16 years of age. Her menstrual periods lasted two to three days, of normal flow, recurred after 28 to 30 days and were regular. There was no associated dysmenorrhoea. She had used an IUCD inserted after each delivery. She had it removed in December 2003 so that she could conceive.

Past medical and surgical history.

This was not significant.

Family Social History

She was married, a housewife while her husband was a cashier at a hotel in city the centre. They stayed at Rinuta. Neither smoked cigarettes nor consumed alcohol.

She had no family history of twinning. She also had no family history of diabetes mellitus, hypertension or any other chronic illnesses.

Physical Examination

General Examination

She was in fair general condition, obese, had no pallor, not jaundiced, clinically afebrile, no peripheral oedema and no lymphadenopathy .

Vital signs: -

- Blood pressure – 117/72mmHg
- Pulse rate - 78/minute
- Respiratory rate – 18/minute
- Temperature – 36.7°C

Abdominal examination

The abdomen was uniformly distended. The fundal height was corresponding to 32 weeks gestation. The foetus was in longitudinal lie, cephalic presentation and the foetal heart rate was 132 beats per minute and regular. There were no areas of tenderness and no palpable liver or spleen.

Pelvic Examination

This was not done as there was no indication.

Other Systems

The breasts, cardiovascular, central nervous system and respiratory systems were essentially normal.

Diagnosis

A diagnosis of Gestational diabetes mellitus at 28 weeks gestation was made.

Plan of management

She was admitted for blood sugar control and monitoring. A foetal kick chart was kept and was satisfactory. She had a strict diabetic diet and started on soluble insulin 22 units subcutaneous 8 hourly. Daily urinalysis for sugar and protein was done. A midstream specimen of urine (MSSU) was taken for microscopy, culture and sensitivity. She also had serial blood sugars daily. The insulin dose was titrated against the blood sugar level. Obstetric ultrasound was done to rule out any congenital malformation, assess the amount of amniotic fluid, gestational age assessment and estimated foetal weight in order to rule out macrosomia.

Summary of Investigations

1) Serial blood sugars

6AM – Fasting blood sugar range: 4.5 to 10.5 mmol/L

11AM – Blood sugar range: 6.1 to 11.3 mmol/L

6PM – Blood sugar range: 3.4 to 11 mmol/L

Generally, the blood sugars were well controlled and the soluble insulin dose ranged between 20 and 24 IU 8 hourly.

2) MSSU – glycosuria +4, ketones nil, protein nil, leucocytes nil and specific gravity 1.020. Culture – Escherichia coli 100,000/ml were isolated. Sensitivity pattern - sensitive to augmentin, gentamycin, amikacin, nitrofurantoin and cefuroxime.

3) Urea and Electrolytes.

- Sodium – 137 mmol/L
- Potassium – 3.4 mmol/L
- Urea – 3.1 mmol/L
- Creatinine – 58 μ mol/L

4) Total blood count –

- WBC – $6.9 \times 10^9/L$
- RBC – $4.4 \times 10^{12}/L$
- Haemoglobin - 13.3 g/dL
- Platelets - $268 \times 10^9/L$

5) Liver function tests – reported normal.

6) Obstetric Ultrasound (3/08/2004) – Showed a single viable intrauterine foetus in cephalic presentation. The foetal heart rate was 150 beats per minute. The Placenta was fundoposterior. Amniotic fluid volume was normal.

Biometric profile

BPD 8.58 cm corresponding to 34 weeks 4 days, FL 5.89 cm corresponding to 30 weeks 6 days, AC 31.1 cm corresponding to 35 weeks. Estimated birth weight was 2570 grams. BPD and AC gave a gestational age of 4 weeks above that by L.M.P. Umbilical artery resistance index was 0.56, which was normal for gestation (normal 0.50 to 0.72).

Biophysical profile score

Amniotic fluid volume – 2

Foetal movement – 2

Foetal breathing movement – 2

Foetal muscle tone – 2

Total score – 8/8

Repeat obstetric scan (17/08/2004);

Single live and active intra-uterine foetus in cephalic presentation. Regular foetal body and limb movements demonstrated.

Biometric profile

BPD 8.9 mm corresponding to 36 weeks, HC 325mm corresponding to 36 weeks 5 days, AC 293mm corresponding to 33 weeks 2 days, FL 65mm corresponding to 33 weeks 5 days. Estimated foetal weight 3338 grams.

The estimated weight suggested foetal microsomia. No gross foetal anomaly seen. Amniotic fluid volume was normal. Umbilical artery resistance index was 0.60 (normal 0.50 – 0.72).

9/09/2004 – Surfactant shake test - 1:1 and 1:2 both were negative.

PROGRESS

The patient had a good blood sugar control while in the ward. The patient was planned for induction of labour at 37 completed weeks. However, at 36 weeks gestational age, she reported reduced foetal movements and the foetal kick chart was unsatisfactory (5 foetal kicks in 12 hours).

A surfactant shake test done was negative. She received two doses of dexamethasone 12mg 12 hours apart and planned for emergency caesarean section the next morning.

She was fasted from midnight and in the morning of the operation the usual insulin dose was not given. A 10% dextrose drip of 500mls containing 10 IU of soluble insulin and 10 meq of KCL was commenced at a rate of 100mls per hour. She was premedicated with atropine 0.6mg intramuscularly 30 minutes before being wheeled to the operating theatre. The caesarean section was performed as described in the introduction. Intra-operatively, she had hourly blood sugar monitoring and the speed of the drip titrated against the blood sugar level. The outcome was a life female infant who weighed 4000 grams and scored 8/1, 8/5 and 8/10. The baby had no congenital abnormalities detected and was admitted to newborn unit due to mild respiratory distress. Bilateral tubal ligation was also done.

The placenta and the cord appeared grossly normal. The placenta weighed 680g. The estimated blood loss was 400mls. She was put on parenteral antibiotics (crystalline penicillin, gentamycin and flagyl) for 5 days.

Post delivery, the infant's random blood sugar ranged between 5.5 and 7mmol/L. the respiratory distress subsided and joined the mother on the 4th post-operative day.

<

The dose of soluble insulin was reduced stepwise and by the time of discharge, on the 10th post-operative day, she was on 12 IU of soluble insulin 8 hourly while the blood sugar ranged between 7 and 10mmol/L. She was reviewed by a diabetologist who recommended discharge on mixtard insulin 16 units in the morning and 8 units in the evening.

She was discharged and booked for postnatal clinic in 2 weeks.

Postnatal follow-up

She had attended the postnatal clinic as per the appointment. She had no complaints. The random blood sugar was 7 mmol/L and was still on mixtard insulin. She was not pale, was afebrile and the incision site had healed well. The baby was developing normally. She was discharged through the diabetic clinic and given an appointment in two weeks. She came for the diabetic clinic as per the appointment and the random blood sugar was 7.1 mmol/L. The mixtard insulin was stopped and started on glibenclamide 2.5mg once daily and metformin 500mg twice daily and was to be followed up in the clinic.

Discussion

The patient presented was a 33 years old para 2+0 and who was found to have gestational diabetes mellitus during the antenatal follow-up. Her blood sugar was controlled by soluble insulin and was delivered by emergency caesarean section after she complained of reduced foetal movements with unsatisfactory foetal kick chart and foetal macrosomia at a gestational age of 36 weeks. The outcome was a live female infant who weighed 4000 grams and scored eight at 1 minute, eight at 5- minutes and ten at 10-minutes.

Diabetes mellitus may be defined as a chronic disorder of metabolism affecting carbohydrates, proteins and fats (1,2). The diabetes' data group of the National Institute of Health (United States) has proposed a new classification system based on aetiological factors and insulin dependence as follows (3);

- a) Type I – Insulin dependent diabetes mellitus
- b) Type II – Non-insulin dependent diabetes mellitus
- c) Type III – Gestational diabetes or carbohydrates intolerance
- d) Type IV – Secondary diabetes

Foetal and maternal outcome of pregnancy complicated by diabetes depends on the severity of the disease and its duration. Priscilla White's classification of pregnant diabetics was originally used to assess the perinatal outcome and to formulate the obstetric management (1,2,3,4).

It is classified into (5);

Class A- Gestational diabetes

Class B – Overt diabetes – onset >20 years of age; <10 years duration

Class C – Overt diabetes – onset <age 20; 10-19 years duration

Class D – Overt diabetes – onset <age 10; 20 years duration with benign retinopathy

Class E – Has calcified pelvic vessels

Class F – Diabetic nephropathy with proteinuria

Class R – Malignant diabetic retinopathy.

Currently, vasculopathy is given more importance in predicting the foetal and maternal outcome of a pregnancy complicated diabetes. Based on this concept, pregnant diabetics have currently been classified into (2,3,4);

Group – A: Gestational diabetes.

Group – B: Overt diabetes without vasculopathy

Group – C: Diabetes with vasculopathy (retinopathy and /or nephropathy).

Gestational diabetes is further classified into;

- a) A-1: gestational diabetes with fasting glucose of <5.8 mmol/L and a post-prandial blood glucose <6.7 mmol/L.
- b) A-2: gestational diabetes with fasting glucose >5.8 mmol/L and a post-prandial glucose level >6.7 mmol/L.

Practically speaking, women with pregnancies complicated by diabetes mellitus may be separated into 2 groups;

- Gestational diabetes – defined as carbohydrate intolerance of variable severity with onset or first recognized during the present pregnancy.
- Pre-gestational diabetes – women known to have diabetes before present pregnancy.

The incidence of diabetes in pregnancy is about 1% of the pregnancies, making it the most frequent metabolic disorder complicating pregnancy (1). The incidence of diabetes in pregnancy is 1 in 343 at Kenyatta National Hospital (6). Gestational diabetes accounts for about 90% of all pregnant diabetes mellitus (IDDM) while non-insulin dependent diabetes mellitus (NIDDM) account for the remaining 10% (7). Gestational diabetes usually present in late second or during the third trimester.

The patient presented had gestational diabetes and was first diagnosed at 27 weeks gestation (late second trimester).

Gestational diabetes is pathophysiologically similar to type II diabetes. Approximately 90% of patients with gestational diabetes have a deficiency of insulin receptors or marked increase in weight. The other 10% have deficient insulin production. During pregnancy, the human placenta lactogen (HPL) hormone blocks insulin receptors and increases in direct linear relation to the length of pregnancy. Insulin release is enhanced in an attempt to maintain glucose homeostasis, which further decreases insulin receptors due to elevated hormonal levels (1,2,3,4).

The presence of gestational diabetes or identifying those at risk may be necessary in patients exhibiting the any of the following factors (4);

- a) Positive family history of diabetes especially of parents or sibling. The family history includes uncles, aunts and grandparents.
- b) History of previous birth of an overweight baby of 4000grams or more.
- c) History of a previous stillbirth with pancreatic islet hyperplasia revealed at autopsy.
- d) Unexplained perinatal loss.
- e) The presence of polyhydramnios or recurrent vaginal candidiasis in present pregnancy.
- f) Persistent glycosuria or recurrent urinary tract infection.
- g) Those of age 30 years or more.
- h) Presence of obesity.

The patient presented had no known risk factors except being over 30 years of age and obese.

Patients with gestational diabetes may be asymptomatic. However, they may present with polyuria, polydipsia, fatigue, excessive appetite, visual disturbances or even in coma. A fundal height greater than the corresponding gestational age or presence of persistent vaginal candidiasis may raise suspicion (4).

The essentials of diagnosis include the presence of elevated blood glucose levels of over 5.8 mmol/L (fasting blood sugar) or > 6.7 mmol/L (postprandial blood glucose) or an abnormal oral glucose tolerance test (OGTT) of over 120mg/100mls glucose levels 2 hours after ingestion of 75g of glucose (2,3,4). Ultrasound findings of foetal weight greater than or equal to 70% for gestational age, polyhydramnios (amniotic fluid index greater than 20), midline congenital anomalies or an abdominal circumference that exceeds the femur growth by 2 weeks merit suspicion of gestational diabetes.

The patient presented had a random blood sugar of 11.3 mmol/L and fundal height greater than the corresponding gestational age. The estimated foetal weight was greater than the corresponding gestational age.

A pregnancy complicated by diabetes is associated with an increased maternal and perinatal morbidity and mortality compared with a normal pregnancy. These includes (2,3,4);

1) Maternal effects during pregnancy;

- a) Recurrent spontaneous abortion, which is associated with poorly, controlled blood glucose levels.
- b) About 17% of pregnancies end up in preterm labour, probably due to infection or polyhydramnios.
- c) There is increased prevalence of infections especially urinary tract infection.
- d) Increased incidence of pre-eclampsia (25%) irrespective of presence or absence of vascular lesion (vasculopathy)
- e) Between 25 to 50% of the cases have polyhydramnios.

2) During labour there is increased incidence of;

- a) Prolongation of labour due to a big baby
- b) Shoulder dystocia
- c) Perinatal injuries
- d) Postpartum haemorrhage due to a large placenta and trauma to birth canal.
- e) The rate of operative interference with increased maternal risk of surgery including anaesthetics.

3) Foetal hazards

- a) Foetal macrosomia occurs in 30 to 40% of the cases. This probably results from maternal hyperglycaemia with resultant foetal hyperglycaemia, which leads to hypertrophy, and hyperplasia of the foetal islets of langerhans in an effort to increase secretion of foetal insulin. Increased foetal insulin levels stimulate carbohydrate utilization and accumulation of the fat and glycogen. Insulin growth-like factors (IGF I and II) are also involved in foetal growth and adiposity. With effective blood glucose control, the incidence of foetal macrosomia is reduced.
- b) About 6 to 8% of cases have congenital malformation. This is related to the level of control of blood sugars in the first trimester (the period of organogenesis).

The congenital malformations commonly include cardiac abnormalities (ventricular and atrial septal defect), neural tube defects (anencephaly, spina bifida, microcephaly) and caudal regression syndrome (sacral agenesis). The estimation of glycosylated haemoglobin A (HbA1C) before the 14 weeks of gestation can predict affection of the foetus. Mothers with HbA1C value of less or equal to 8.5% have got least chance of severe malformation of the foetus. Chances of major congenital malformation is more if the value of HbA1C rise to 9.5% or more.

Maternal serum alpha-fetoprotein at 16 weeks and a detailed high-resolution ultrasonographic examination of the foetus including assessment of foetal cardiac structure at 20 weeks are advocated.

- c) Unexplained foetal demise has got multifactorial pathogenesis but the final event being hypoxia and acidosis. This could be due to the combined effect of impaired uterine blood flow, reduced placental transfer of oxygen and increased foetal oxygen demand. Other factors involved include foetal hypoglycaemia and foetal blood hyperviscosity and thrombosis.
- d) Neonatal complications include hypoglycaemia, respiratory distress syndrome, hypobilirubinaemia, polythaemia, hypomagnesaemia and cardiomyopathy.

The overall perinatal mortality is increased 2-3 times than in normal pregnancies. The neonatal deaths are principally due to hypoglycaemia, respiratory distress syndrome, polycythaemia and jaundice (2,4).

The patient presented had gestational diabetes complicated by pre-eclampsia, foetal macrosomia and the foetus had mild respiratory distress syndrome.

Irrespective of whether the pregnant woman has pre-gestational or gestational diabetes, she needs more frequent antenatal supervision than a normal pregnancy and may need a consulting team that comprises a physician (diabetologist), paediatrician and a dietician. The goal is to achieve and maintain a blood glucose level as near to physiological level as possible.

Glycaemic goals should be around 90mg/dL (5mmol/L) before meals and not to exceed 120mg/dL (6.7 mmol/L), 2 hours after meals. A fasting blood sugar exceeding 105mg/dl (5.8 mmol/L) and 2 hours postprandial value greater than 130mg/dL (7.2mmol/L) is an indication for insulin therapy (3,4).

Since there is frequent change in insulin need during pregnancy, the changes in the dosage are made in small increments at a time. Oral hypoglycaemia drugs should not be used during pregnancy since they cross the placenta and may have teratogenic effect to the foetus or produce neonatal hypoglycaemia (2,4). Sonographic evaluation of the pregnancy is extremely helpful, not only to diagnose varieties of congenital malformation of the foetus but also to detect foetal macrosomia. A Doppler umbilical artery velocimetry is useful especially in cases with vasculopathy. A biophysical profile should be performed when there are complaints of reduced foetal movement or unsatisfactory foetal kick chart (2,3,5).

The patient presented had her fasting glucose level maintained at between 4.5 and 5.5 mmol/L by a dose of 22 to 24 I.U of soluble insulin 8 hourly. Sonographic evaluations had shown foetal macrosomia but without any foetal congenital malformation. The umbilical artery resistance index remained within the normal range (0.50-0.72).

There is no existing universal guideline on termination of pregnancy complicated by diabetes currently. However, the majority of intrauterine foetal demise occurs in the last two weeks of pregnancy and therefore the termination of pregnancy after 37 completed weeks is recommended. Early termination is justified in situations where there is foetal jeopardy or after considering all the circumstances in the past history as well as the present pregnancy. Termination of pregnancy can be either by induction or caesarean section. Induction of labour is favoured in patients with good obstetric history, primigravida without any obstetric abnormalities and in presence of congenital malformation of the foetus or intrauterine foetal demise (2,4).

Over 50% of pregnancies complicated by diabetes are delivered by caesarean section; partly due to foetal macrosomia, foetal jeopardy, other obstetric complication related to diabetes such as pre-eclampsia and bad obstetric history (BOH) (2,4).

The patient presented was delivered by caesarean section at 36 weeks gestation because of foetal jeopardy (reduced foetal movement and unsatisfactory foetal kick chart), eclampsia and foetal macrosomia. The infant weighed 4000grams.

At the time of delivery, a paediatrician should be present. After delivery, the baby should preferably be kept in an intensive neonatal care unit and one need to remain vigilant for at least 48 hours, to detect and treat effectively any complication likely to arise.

These include (3,4);

- a) Asphyxia is anticipated and should be treated effectively
- b) To look for any congenital malformation
- c) The baby should have blood glucose checked 2 hours after delivery.
- d) The baby should receive 1 mg vitamin K intramuscularly
- e) Early breastfeeding within ½ - hour is advocated and to be repeated at 3 to 4 hourly intervals thereafter, to minimize hypoglycaemia and hyperbilirubinaemia.

Sometimes, the mother may not be in a position to breastfeed immediately especially after a caesarean section or premature baby may have a problem breastfeeding and in such cases, 10% glucose may be given orally (3,4).

In the case presented, a paediatrician was present during the caesarean section, the baby was admitted in the newborn unit because of mild respiratory distress and had early oral 10% glucose orally. The baby joined the mother after 72 hours.

Insulin requirement falls dramatically following delivery. This is due to the delivery of the placenta, which is the source of hormones (human placental lactogen, progesterone and oestrogen) that are functionally antagonistic to insulin. The dosage of insulin should be adjusted as the blood glucose levels fall. However, in pre-gestational diabetes, it is recommended to revert to the insulin regime prior to pregnancy (2,3,4).

The patient presented had persistent elevated blood glucose levels after delivery, that is, she developed overt diabetes.

Barrier methods of contraception are ideal for spacing of births. Oestrogen containing oral contraceptives and intrauterine contraceptive device (IUCD) are best avoided especially in women with overt diabetes. Oestrogen containing oral contraceptives affect carbohydrate metabolism and may cause vascular complications. The IUCD increases the risk of pelvic infection. Progestin only oral contraceptives or progestin implant (Norplant) may be utilized. Permanent sterilization should be considered seriously once the woman wants no more children (4,7).

The patient presented had consented for bilateral tubal ligation (BTL) antenatally and it was therefore done during the caesarean section.

References

3. Sue M.P.
Diabetes mellitus.
In: Current Obstetrics and Gynaecologic diagnosis and treatment, 8th edition, Appleton and Lange publications, 1994; page 374-378.
2. Cunningham F.G, Gant F.G. et al.
Diabetes
In: Williams Obstetrics, 21st edition, McGraw-Hill publications, 2001; Page 1360-1377.
3. Albert R. Hobbins J.
Diabetes mellitus in pregnancy.
In: Medicine of the foetus and mother, 2nd edition, Lippincott-Raven publishers, Philadelphia, 1999; page 1055-1084.
4. Dutta D.C.
Medical and surgical illness complicating pregnancy.
In: Textbook of Obstetrics, 5th edition, new central publishers, 2001; Page 300-306.
5. White P.
Classification of obstetric diabetes.
AM. J. Obstet. Gynaecol. 1978; 130: 228.
6. Manyara K.
A review of diabetes in pregnancy at KNH.
M. Med Thesis UON 1980.
7. Lidegoard O.
Oral contraceptives, pregnancy and the risk of cerebral thromboembolism.
Bri. J. Obstet. Gynaecol, 102: 153; 1995.0

Case No. 12

CARDIAC DISEASE GRADE IV IN PREGNANCY – SUCCESSFUL VACUUM ASSISTED DELIVERY.

Name:	D.W.	Parity:	2+0
Age:	35 years	DOA:	2.10.04
IP NO:	0986581	DOD:	13.10.04

Presenting Complaints

The patient presented with complaints of lower abdominal pain and backache for duration of 6 hours.

History of presenting illness.

She was a known cardiac disease patient who presented with lower abdominal pains that were intermittent and progressively increased in both intensity and frequency. She had no urinary symptoms. She had no per vaginal bleeding or drainage of liquor. She had no complains of palpitation, easy fatigability, chest pain or cough.

History of current pregnancy

She had booked antenatal clinic at Wangige health centre at a gestational age of 28 weeks. She was referred to Kenyatta National Hospital for antenatal follow-up but declined.

Antenatal profile done; blood group A positive, VDRL-negative, Haemoglobin -10.8g/dL and urinalysis was normal. HIV status was unknown.

Her last menstrual period was on 9/1/2004 and her expected date of delivery was on 16/10/2004 giving a gestational age of 38 weeks.

Past Obstetric and Gynaecologic History

She was a para 2+0 gravida 3. Her first delivery was in 1984 by a vacuum assisted delivery. She could not recall the birth weight but died at the age of 17 years through a traffic road accident.

The second delivery was in 2000 also by vacuum assisted delivery, birth weight 2500grams, and was alive and well. She had no heart disease complications during the two pregnancies.

Her menarche was at 16 years. Her menses lasted 4 to 5 days, of normal flow, recurred after 28 to 30 days and were regular. She had no associated dysmenorrhoea. She had used combined oral contraceptives between 1984 and 2000 and then from 2001 to July 2003.

Past Medical and Surgical History

She had a congenital heart disease (Ventricular septal defect – VSD) but the anomaly was corrected surgically in 1978 at Kenyatta National Hospital. She was subsequently followed-up in cardiac clinic until 1995 when she was discharged from the clinic.

Family and Social History

She was single and lived at Kikuyu. She was a farmer and neither smoked cigarettes nor consumed alcohol.

Her mother died in 1997 due to diabetic and hypertensive complications. Her father died in 2003 due to pulmonary tuberculosis. There were no other chronic illnesses in the family.

Physical Examination

General Examination

She was in fair general condition, not pale, not jaundiced, not cyanosed, afebrile but had bilateral pitting pedal oedema.

Vital signs were: -

- Blood pressure - 117/110 mmHg
- Pulse rate - 80/minute, regular, non-collapsing and good volume
- Respiratory rate – 18/minute
- Temperature – 36.9°C

Cardiovascular system

She had no finger clubbing and no splinter haemorrhages. The jugular venous pressure was not raised. She had a thoracotomy scar on the chest. The praecordium was not hyperactive and the apex beat was not displaced.

Abdominal examination

The abdomen was uniformly distended and moved with respiration. The fundal height corresponded to 36 weeks gestation. The foetus was in longitudinal lie, cephalic presentation, descend was two fifths up and the foetal heart rate was 144 beats per minute and regular. She had two to three contractions in 10 minutes and each lasting between 20 and 40 seconds. She had no palpable liver or spleen.

Pelvic Examination.

She had normal external genitalia. The cervix was 5cm dilated, 80% effaced and was draining clear liquor. There was neither caput nor moulding.

Other systems

The respiratory and central nervous systems were essentially normal.

Diagnosis

A diagnosis of cardiac disease grade IV in active labour was made.

Investigations

- 1) Blood group A positive
- 2) VDRL- Negative.
- 3) Rapid test (HIV)- Negative.
- 4) Urinalysis- Normal
- 5) Total blood count: -
 - WBC – $8.2 \times 10^9/L$
 - RBC – $4.3 \times 10^9/L$
 - Haemoglobin -11.8g/dL
 - Platelets - $298 \times 10^9/L$
- 6) Chest X-ray- Normal.
- 7) ECG- Reported normal.

Management

The patient was put on intramuscular analgesics (tramal), oxygen by mask and labour was augmented with syntocinon 5 I.U in 250mls of 5% dextrose. She was also started on intravenous crystalline penicillin 2 mu 6 hourly and gentamycin 80mg 8 hourly. She had input and output chart. She progressed well and during second stage she had a vacuum assisted delivery at a semi-sitting sitting. The outcome was a life female infant who weighed 2250 grams and scored eight at 1- minute, nine at 5- minute and ten at 10- minutes. Ergometrine was avoided in third stage but the syntocinon drip was continued. The average blood loss was 150mls. The patient was observed in the fourth stage room for 6 hours and then transferred to the wards.

The patient had consented for bilateral tubal ligation (BTL) antenatally. On the second postnatal day, she underwent minilaparotomy for bilateral tubal ligation.

She did well while in the ward and discharged on the 10th postnatal day and booked for review in the postnatal clinic after two weeks.

Follow-up

She was seen two weeks later in the postnatal clinic. She and her baby were doing well. She had no complaints. The minilaparotomy incision site for tubal ligation had healed well. She had no lochia loss.

Discussion

The patient presented was a 35 years old para 2+0 with cardiac disease grade IV. She was admitted in active labour, had a vacuum assisted delivery and whose outcome was a life female infant who weighed 2250 grams and scored well.

Cardiovascular disease is the most important non-obstetric cause of disability and death in pregnant women occurring in 0.4 – 4% of pregnancies (1). Maternal mortality rate ranges from 0.4% in patients with New York heart association (NYHA) grade I and II to 6.8% or higher among those with grade III and IV severity (1).

Heart lesions can be categorized into acquired and congenital cardiac diseases. The predominant acquired heart lesion is the rheumatic heart disease. Others include hypertensive, thyrotoxic, syphilitic and coronary heart diseases. Rheumatic heart disease (RHD) is still the major cause of heart disease in the developing countries. Rheumatic valvular lesion predominantly involves the mitral valve and includes mitral stenosis in 80% of the cases. Mitral stenosis is therefore the commonest heart lesion met during pregnancy (1,2,3).

The predominant congenital heart lesions include patent ductus arteriosus, atrial or ventricular septal defects, pulmonary stenosis, coarctation of the aorta and tetralogy of Fallot. In the developed countries, rheumatic heart disease is now less common while congenital heart lesions are seen more commonly (1,2,3). Ngotho (1982) found that rheumatic heart disease in pregnancy was responsible for 86.4% of cardiac disease in pregnancy at KNH (5).

The patient presented had a ventricular septal defect.

An increased number of surgically corrected congenital heart lesions are being met in day-to-day practice. These patients pose fewer problems in obstetrics (2).

But when pregnancy occurs in uncorrected congenital lesions, especially the cyanotic group, the patient may end up in heart failure (2). The risk to the offspring of a pregnant woman with congenital heart disease is high; about 3 – 10% (2).

Ventricular septal defect (VSD) is an example of acyanotic congenital heart disease characterized by left to right shunt. In general, if the VSD is uncorrected and is less than 1.25cm^2 , pulmonary hypertension and heart failure do not develop (2). The pregnancy is well tolerated with small to moderate left to right shunt or with moderate pulmonary hypertension. The major risk is shunt reversal leading to circulatory collapse and cyanosis. The offspring has 8% chance of having the same abnormality (2,3).

The patient presented had the ventricular septal defect corrected in childhood and had relatively few problems in the previous pregnancies. The infant had no VSD or any other congenital heart lesion.

The marked haemodynamic changes in pregnancy and cardiac output in particular, have profound effects on heart disease. A normal heart has enough reserve power to tackle the extra-load. However, a damaged heart with poor reserve, cardiac failure will occur sooner or later. Since significant haemodynamic alteration is apparent early in pregnancy, women with severe cardiac dysfunction may experience worsening of heart failure before mid-pregnancy. Generally, cardiac failure occurs during pregnancy around 30 weeks, during labour and mostly soon after delivery (1,2,3,4).

Additional factors responsible for deterioration of cardiac function of the damaged heart are; -

- a) Advancing maternal age
- b) Cardiac arrhythmias or left ventricular hypertrophy
- c) History of previous heart failure
- d) Appearance of "risk factors" for heart failure such as;
 - Infection
 - Anaemia
 - Pre-eclampsia
 - Excessive weight gain
 - Multiple pregnancy
- e) Inadequate supervision.

Many of the physiological changes in normal pregnancy tend to make the diagnosis of heart disease more difficult. It is important not to diagnose heart disease during pregnancy when none exists, and at the same time not fail to detect and appropriately treat heart disease when it does exist (3). Symptoms associated with heart disease include easy fatigability, progressive dyspnoea or orthopnoea, nocturnal cough, haemoptysis, chest pain and syncope. Clinical findings in a patient with heart disease include cyanosis, finger clubbing, persistent neck vein distention, hyperactive praecordium, displaced apex beat, pansystolic and diastolic murmurs, persistent arrhythmias and criteria for pulmonary hypertension (2,3). The clinical diagnosis should be substantiated with electrocardiography (ECG), chest X-ray, echocardiography and Doppler flow studies (2,3).

Cardiac disease can be graded according to the New York heart association (NYHA). The grading is based on past and present disability and is uninfluenced by physical signs (1,2,3).

Grade - I: Uncompromised: Patients with cardiac disease but no limitation of physical activity.

Grade- II: Slightly compromised: Patients with cardiac disease with slight limitation of Physical activity. The patients are comfortable at rest but ordinary physical activity causes discomfort.

Grade- III: Markedly compromised: Patients with cardiac disease with marked limitation of physical activity. The patients are comfortable at rest but discomfort occurs with less than ordinary activity.

Grade - IV: Severely compromised: Patients with cardiac disease with discomfort at rest. Patients who have had heart surgery are automatically put in grade IV.

Generally, the limitation of New York heart association grading is the fact that it has considered the symptoms only while the severity of the pathology is not assessed (2).

The patient presented had heart surgery for ventricular septal defect in childhood and was therefore put in grade IV.

A known heart disease patient contemplating pregnancy should have proper pre-conceptional counseling because of (2,6); -

- Treatment can be made optimal
- A specific outlay plan for the pregnancy can be prepared.
- Correctable surgery can be undertaken before conception
- Advice against pregnancy can be given to high risk cardiac lesions such as primary pulmonary hypertension and inoperable cyanotic heart diseases.

Considering high maternal deaths, cases of primary pulmonary hypertension, Eisenmenger's syndrome and pulmonary veno-occlusive disease are absolute indications for termination of pregnancy. Relative indications include parous women with grade III and IV cardiac lesions, and grade I or II with previous history of cardiac failure in early months or between pregnancies (2,3,4).

In patients with mitral stenosis, termination of pregnancy by hysterectomy is found to be more risky than risks involved in continuation of pregnancy and delivery (2). Antenatal care of patients with heart disease should be cared from the beginning to the end in a referral hospital and the services of a cardiologist should be sought (2).

Patients with grade I and II disease are seen weekly until term then admitted at least two weeks prior to the expected date of delivery to await labour.

However, the patient in grade I and II disease may be admitted any time if there is;

- a) Deterioration of the functional grading
- b) Appearance of dyspnoea or cough or basal crepitations or tachyarrhythmias
- c) Appearance of pregnancy complications like anaemia, pre-eclampsia or abnormal weight gain

Patients with grade III and IV disease are ought to be admitted throughout the pregnancy (2,6).

The patient presented booked her antenatal care at the health centre at 28 weeks gestation. She was subsequently referred to Kenyatta National Hospital but declined, only to appear in labour.

Most patients with cardiac disease go into spontaneous labour. Majority of obstetricians believe there is no place of induction for heart lesions complicating pregnancy. However, some believe that induction using vaginal prostaglandins may be employed in very selected cases for obstetric indications (2,3,6).

In general, delivery should be accomplished vaginally unless there are obstetrical indications for caesarean delivery (3).

During the first stage of labour;

- The patient should be confined to bed in the left lateral recumbent position to minimize aorto-caval pressure by the gravid uterus.
- Oxygen by mask when required and administration of analgesics
- Precautious intravenous fluid infusion and should be less than 75 mls per hour to prevent pulmonary oedema.
- Careful watch of pulse rate and respiration rate
- Cardiac monitoring and pulse oxymetry to detect arrhythmias and hypoxaemia.

Parenteral antibiotics during labour and at least 48 hours after delivery is recommended to guard against infection especially puerperal infective endocarditis.

Second stage of labour;

There is tendency to delay in second stage of labour and this should be curtailed by vacuum assisted delivery. Administration of ergometrine should be withheld to prevent sudden overloading of the heart by the additional blood squeezed out of the uterus (2,3,6).

Third stage of labour;-

Conventional management of third stage is to be followed. Slight blood loss is beneficial but if it is in excess, oxytocin can be given by infusion and may be accompanied by intravenous frusemide.

The patient presented had a shortened second stage by use of vacuum assisted delivery while ergometrine was avoided. She received intravenous antibiotics; crystalline penicillin 2mu 6 hourly and gentamycin 80 mgs 8 hourly for five days.

Since the postpartum period is critical, the patient was retained in the ward for 10 days and was monitored for infective endocarditis, congestive heart failure and thrombo-embolic disease.

Effects of the lesion or disease on pregnancy include a tendency of preterm labour and delivery, prematurity and intrauterine growth restriction (IUGR) which is particularly common in cyanotic heart disease. There is an increased incidence of congenital heart disease in the offspring of between 3 and 10% (3,4,6,7).

The patient presented delivered at term to a baby weighing 2250 grams but did not have any congenital heart disease. None of the other two children had a congenital heart lesion.

Postpartum contraception is important and surgical sterilization is the preferred method (6). Barrier methods of contraception can be used. Permanent sterilization should be considered on attaining the desired family size; this can be bilateral tubal ligation in the woman or vasectomy for the husband.

Steroidal contraception is contra-indicated as it may precipitate thrombo-embolic phenomenon. Intrauterine device (IUD) is contra-indicated for fear of infection (2,3,4,6).

The patient presented had bilateral tubal ligation (BTL) done on the second postnatal day.

References

1. Manoj. K.B, Dorothee P.
Cardiac, haematologic, Pulmonary renal and urinary tract disorders in pregnancy.
In: Current Obstetric and Gynaecologic diagnosis and treatment, 8th Ed,
Appleton and Lange, 1994; pp 428 – 448.
2. Dutta D.C.
Medical and Surgical illnesses Complicating Pregnancy.
In: Textbook of Obstetrics, 5th Ed, New Central Agency Publishers, 2001; page
293 – 298.
3. Cunningham F.G. Gant F.G.
Cardiovascular diseases.
In: Williams's obstetrics, 21st edition, McGraw-Hill publications, 2001;
Page 1181- 1207.
4. Szekely P, Tumar R, Snaith L.
Pregnancy and the changing patterns of rheumatic heart disease.
Brit. Heart. Journal 35: 1293 – 1303; 1973.
5. Ngotho D.K.
Cardiac disease in pregnancy at KNH.
M. Med Thesis, UON, 1982.
6. Deswiet M.
Cardiovascular problems in pregnancy.
In: Tumbull's Obstetric 3rd Ed, Churchill Livingstone publications, 2001; page
263 –274.
7. Chia P, Raman S, Tham S.W.
The pregnancy outcome of acyanotic heart disease.
J. Obstet. Gynaecol. Res 24:267 – 273; 1998.

Case No. 13

MALARIA IN PREGNANCY – LIVE BABY

Name:	J.M	Parity:	1+0
Age:	25 years	DOA:	3.04.04
IP NO:	0951063	DOD:	7.04.04

Presenting Complaints

The patient was admitted with complaints of headache, nausea, general malaise, dizziness, chills and backache for one week.

History of presenting complaints

The patient had been well until one week prior to admission when she developed a frontal headache that was temporarily relieved by paracetamol. She had no associated vomiting but had nausea. She had dizziness especially on standing or bending forward, backache, joint pains and general malaise. She had no palpitation or difficulty in breathing. She had no dysuria, frequency or urinary urgency. She had no associated lower abdominal pains. Her bowel habits were normal.

She gave a history of having traveled to Homa-bay (Nyanza) to see her in-laws, two and a half weeks prior to the onset of the symptoms.

History of the current pregnancy.

Her last menstrual period was on 24/8/2003 and her expected date of delivery was 31/5/2004 giving a gestational age of 31 weeks and 5 days at the time of admission.

She had booked antenatal clinic at Baba-dogo dispensary since 26 weeks gestation but the antenatal profile had not been done.

Past obstetric and gynaecologic history

She was a para 1+0 gravida 2. Her last delivery was in 2000 by spontaneous vertex delivery at term and the infant weighed 2700 grams, and was alive and well. She had her menarche at 16 years.

Her menses lasted 3 days and recurred after 28 days, regular and no associated dysmenorrhoea. She had used combined oral contraceptives between May 2000 and June 2003.

Past Medical and Surgical History

This was not significant.

Family Social History

She was married; housewife while her husband was a tailor at a textile industry in Nairobi's Industrial Area. Neither smoked cigarettes or consumed alcohol. She stayed at Baba-dogo.

She had no family history of twinning or chronic illnesses.

Physical Examination

General Examination

She was sick looking, mildly pale, not jaundiced, febrile clinically, no pedal oedema and no lymphadenopathy.

Vital signs: -

- Blood pressure - 120/70 mmHg
- Pulse rate - 98/minute
- Respiratory rate – 18/minute
- Temperature – 38.2°C

Abdominal examination

Her abdomen was uniformly distended and moving with respiration. The fundal height was corresponding to 32 weeks gestation, longitudinal lie, cephalic presentation and a regular foetal heart rate of 148 beats per minute. There were no palpable contractions. She had no hepatosplenomegally.

Respiratory System

She had normal chest symmetry. The trachea was central with good bilateral air entry. There was no rhonchi or crepitations.

Cardiovascular System

The pulse rate was 98 beats per minute, regular and normal volume. The blood pressure was 120/70mmHg. The jugular venous pressure was normal. The first and second heart sounds were heard and no murmurs.

Central Nervous System

She was well oriented in time, place and person. The neck was soft and Kerning's sign negative. She had no neurological deficit.

Pelvic Examination

She had normal female external genitalia. The cervix was posterior, long, soft and os was closed. There was no discharge or blood on the gloved examining fingers.

Diagnosis

A diagnosis of malaria in pregnancy was made.

Investigations

- 1) Blood slide for malaria parasites: - Positive for malaria parasites with moderate parasitaemia.
- 2) Stool for ova and cysts: - No ova or cysts seen
- 3) Urinalysis: - PH 6.0, proteins-trace, Ketones-one +, specific gravity 1.025, Bilirubin- nil, sugars-nil, pus cells-nil, leucocytes-nil, and no growth obtained on culture.
- 4) Total blood count: - Haemoglobin 9.2g/dL, haematocrit 27.6%, WBC $8.2 \times 10^9/L$ (differential count- neutrophils 69.1%, lymphocytes 26.3%, monocytes 4.1% and eosinophils 0.5%). Red blood cell morphology was reported normal.
- 5) Urea and electrolytes: - Sodium 133 mmol/L, Potassium 3.6mmol/L, creatinine $68\mu\text{mmol/L}$ and urea 4.2 mmol/L.
- 6) Random blood sugar: - 6.6 mmol/L
- 7) Blood group O and Rhesus positive, VDRL – negative, ELISA (HIV) – negative.

On receiving the result of a positive blood slide for malaria parasites, the patient was started on Artemum (Artemesinin derivative) 300mg intramuscularly and followed by

100mg once a day for 4 days. She was also started on 10% dextrose 500mls drip, folates 5mg once a day and paracetamol 1 gram 8 hourly.

The patient had a quick recovery and a blood slide on the 3rd day was negative for malaria parasites. The fever had come down to 36.6°C and the headache, joint pains and general malaise had also subsided.

The foetal heart rate had remained within the normal range and regular. Once she completed the artemum injection, she was discharged on 5th day on Ranferon (haematinic) 10mls twice a day for 4 weeks. She was advised to take one Fansidar tablet weekly for 4 weeks and to sleep under a mosquito net, preferably a treated one. She was instructed to continue with antenatal clinic follow – up.

The patient was admitted in advanced labour (second stage) on 20/5/2004 at a gestational age of 38 weeks and 3 days. She had a spontaneous vertex delivery to life male infant who weighed 3400 grams and scored 9 at 1 minute and 10 at 5 minutes. She did well post -delivery and was discharged after 24 hours. However, she could not leave immediately because of financial problems.

She declined postnatal follow-up after six weeks at KNH, preferring to be reviewed at Babadogo dispensary because of financial constraints.

Discussion

The patient presented was a 25 years old para 1+0 gravida 2 with malaria and mild anaemia at 31 weeks gestation. She was successfully treated with intramuscular artemesinin derivative (artenum), antipyretics and haematinics. She was discharged home and re-admitted at 38 weeks in advanced labour (second stage). She had a spontaneous vertex delivery to a life male infant who weighed 3400 grams and had a good score.

Malaria is a protozoan infection caused by a parasite of the genus plasmodium. There are four species of plasmodium that affect human beings. These are plasmodium falciporum, plasmodium malariae, plasmodium vivax and plasmodium ovale (1,2).

Plasmodium falciporum is the commonest in Africa and causes the most severe form of malaria across the board (1,2,3,4). In Kenya, plasmodium falciporum accounts for 98% of malaria cases while plasmodium malariae and ovale accounts for upto 2% of the cases. Plasmodium vivax is very rare (3,4,5).

The patient presented had plasmodium falciporum.

Generally, malaria is a disease of the tropical and sub-tropical world. Nearly 300 to 500 million persons worldwide are infected at any given time. Malaria causes 1 to 3 million deaths annually and it is one of the greatest public health problems in the sub-saharan Africa, Asia and parts of Latin America (1,2). The incidence of malaria has been reported as being between 9.8% to 33% in different parts of Kenya.

Sinci (1984) reported an incidence of 33% in rural Kenya while Rukaria (1990) reported a prevalence of 21% in Kilifi (5,6). Infact, malaria is a priority disease in Kenya accounting for 30% of outpatient hospital attendance nationally (3,4).

The malaria causing protozoa are transmitted from man to man via bites by the female anopheles mosquitoes. Transmission can also occur through blood transfusion and through, rare-congenitally (2).

The protozoa invade the red blood cells and sometimes the liver cells as well as the cells of the reticulo-endothelium system such as the spleen and the lungs.

The protozoa replicates in the red blood cells, which ultimately haemolysis releasing numerous schizonts, and subsequently invade other red blood, cells. The haemolysis might lead to anaemia and large quantities of heme, which is converted into bilirubin leading to jaundice or haemoglobinuria. In chronic malaria infection, reticulo-endothelial cells may undergo hyperplasia and hence organomegally (2,7). Of particular interest is the spleen, which is usually enlarged, congested, pigmentation, abundance in macrophages giving the Tropical Splenomegally Syndrome (TSS), which also comprises hepatomegally. In severe forms of malaria such as cerebral malaria, the small and medium vessels are occluded by parasitised erythrocytes and fibrin clots causing brain oedema and petechial haemorrhages which may lead to brain cell death (1,2,7).

Pregnancy is associated with physiological suppression of cell mediated immunity to malaria while the humoral immunity is not altered. Pregnant women are therefore more susceptible to malaria infection than non-pregnant women of the same age. Pregnant women are also more likely to have higher parasitaemia levels (1,7). Malarial infection increases significantly by 3 to 4 fold during the latter two trimesters of pregnancy and within two months postpartum. Indeed, there is increased incidence and maximal density of parasitaemia in second trimester especially in the first pregnancy (primigravidae). The placental parasitaemia is common and more intense in primigravidae, and may occur even in those without peripheral parasitaemia (1,2,7).

The patient presented was a para 1+0 gravida 2.

Malaria is classified into 3 categories, namely (3,4):

- 1) Uncomplicated malaria - It is characterized by parasitaemia plus the clinical features of malaria but without complications.
- 2) Severe malaria- The patient presents with malaria and is either prostrated, unconscious or has respiratory distress. Additional complications include:
 - Cerebral malaria with coma
 - Convulsions
 - Severe anaemia (Hb <5g/dL)
 - Renal failure

- Hypoglycaemia (blood sugar < 2.2 mmol/L)
- Fluid and electrolyte imbalance
- Hypovolaemic shock
- Hyperparasitaemia
- Malaria haemoglobinuria (coca cola coloured urine)
- Hyperpyrexia (temperature > 39°C)
- Disseminated intravascular coagulopathy (DIC).

3) Treatment failure – The patient has persistent symptoms 2 to 3 days after initiation of drug therapy in accordance with the recommended treatment regime and continued presence of asexual forms of parasites in blood.

Malaria in pregnancy, especially the falciparum malaria, is associated with increased maternal and perinatal mortality and morbidity. Placental malaria is associated with low foetal birth weight. The reduction of mean birth weight associated with placental malaria has been greatest in the first pregnancy and decreases with increasing parity. The average reduction in birth weight of babies borne to primigravidae is approximately 170 grams. Malaria associated low birth weight is usually due to intra-uterine growth restriction rather than to premature delivery (1,2,7).

The patient presented was para 1+0 gravida 2 and had a normal birth weight baby of 3400 grams.

In malaria endemic areas, anaemia is common in pregnancy and has many possible causes. Anaemia usually results from destruction of parasitized red blood cells by the spleen, other cells of reticulo-endothelial system and also destruction of non-parasitized cells through autoantibodies production. There is reduction in red cells' survival and bone marrow dysfunction resulting in thrombocytopenia and leukopenia as well (1,2,7). Sinei (1984) found that 33.3% of patients with anaemia had malaria parasitaemia and that severe forms of anaemia were associated with high parasitaemia (5).

Rukaria and colleagues (1996) found that 66% of women with falciparum positive parasitaemia were anaemic (haemoglobin < 10g/dL) and that the higher the parasite density, the severe the anaemia (8).

Other common possible causes of anaemia such as helminthes (hookworms) infestation and urinary tract infection, requires to be investigated.

The patient presented had a haemoglobin level of 9.2g/dL and a blood slide had moderate parasitaemia of plasmodium falciporum. The stool specimen had no ova or cysts and the urinalysis was normal. The patient was put on haematinics.

Falciporum malaria especially in non-immune pregnant subjects commonly induces uterine contractions and subsequent premature labour. The frequency and the intensity of the uterine contractions appear to be related to the height of the fever (8). Foetal prognosis in premature labour is poor and particularly in severe disease. Despite prompt control of the infection and prevention of premature labour, intrauterine growth may be temporarily restricted (8,9).

Pregnant women are particularly susceptible to hypoglycaemia and pulmonary oedema. In untreated patients there is a statistical association of hypoglycemia with hyperparasitaemia and lactic acidosis. It may be asymptomatic or may present with sweating, altered consciousness or convulsions. There may be associated foetal bradycardia or other signs of foetal distress (1,2,7). Pregnant patients with falciporum malaria are particularly prone to develop acute pulmonary oedema. This may present at admission or within a few days after admission to hospital. It commonly develops immediately after delivery or anytime within the first week postpartum (1,2,7).

The patient presented had fever of 38°C that was brought down by antipyretics and had a normal random blood sugar level (6.6 mmol/L).

Congenital malaria is said to occur when a pregnant mother transmits malaria parasites to the foetus (7,10). Infants borne to non-immune mothers who have malaria at the time of delivery may develop parasitaemia and illness in the first few weeks of life. Malaria parasites are commonly present in the umbilical cord in such cases. The rate of neonatal peripheral parasitaemia is lower than the rate of cord parasitaemia. Clinical features of congenital malaria, which usually disappears between the second and eighth weeks of life, include fever, anorexia, lethargy, anaemia, hepatosplenomegally, vomiting, convulsions, and jaundice (1,7,10).

The clinical presentation in patients suffering from malaria varies from symptomless to mild or severe disease. Signs and symptoms include fever, myalgia, mental confusion, nausea and vomiting, diarrhoea, joint pains, general weakness and poor appetite.

On physical examination, they may have anaemia (pallor), jaundice, fever, and hepatosplenomegally. In severe forms of malaria, they may have pulmonary oedema, heart failure or in coma (7,9).

A peripheral blood film to detect malaria parasites together with the degree of parasitaemia is important as it may influence the mode of management apart from confirming the diagnosis. Quantitative buffy coat (QBC) technique can also be used to demonstrate parasites in the infected red blood cells. Other useful investigative tools that may help in detecting complications includes random blood sugar, total blood count, liver and renal function tests. An obstetric ultrasound may detect intrauterine growth restriction (IUGR), assess foetal well-being and chronic placental infarcts may be seen as areas of calcification (2,9,10).

In the case presented, the patient presented with headache, dizziness, loss of appetite, easy fatigability, joint pains, nausea and no vomiting.

A blood slide was positive for malaria parasites (*plasmodium falciporum*). She had a normal random blood sugar, normal urea and electrolytes and haemoglobin showed a haemoglobin level of 9.2g/dL.

History of clinical symptoms, previous drugs used and clinical presentation should be taken into consideration in giving the treatment. In the treatment of uncomplicated malaria, sulphur and pyremethamine combination drugs such as fansidar or metakelfin are used unless the patient is allergic to sulphur based drugs. In such patients, other drugs such as amodiaquine, can be an alternative. (3).

Chloroquine is no longer used as a first line drug in Kenya since 1998. A number of studies have demonstrated varying levels of *plasmodium falciporum* resistance to chloroquine in the country ranging from 7% in Turkana to 85% in endemic areas (Coast and Nyanza Provinces) (3).

Severe malaria is treated with intravenous quinine as a start dose of 20mg/kg body weight in 500mls of 5 or 10% dextrose drip over 4 hours. Eight hours after commencing the initial dose, quinine is given at a dose of 10mg/kg in 500mls of 5% dextrose 8 hourly. This regime is continued until the patient improves clinically and is able to take oral quinine, thus completing a total of 10 days course. Quinine can cause hypoglycemia and therefore periodic blood sugars are recommended especially if the patient is not in a position to feed orally. Quinine should also be monitored closely since it can also induce premature labour. Other useful drugs include the artemisinin group of drugs such as paluther, artenum and artemether (3,4).

Supportive treatment includes rehydration, antipyretics, analgesics, haematinics or blood transfusion depending on the degree of anaemia.

The patient presented was treated with parenteral artenum, rehydration, antipyretic and haematinics.

For prevention of malaria among pregnant women in Kenya, the ministry of health recommends that all pregnant women should receive a treatment dose of 3 fansidar tablets at the first antenatal visit occurring after the first trimester is completed. A second dose is given at the beginning of the third trimester (between weeks 28 and 34). Other preventive measures include sleeping under insecticide treated mosquito nets, environmental management including bush clearing, drainage systems and mosquito repellants (such as mosquito coils).

On discharge from hospital, the patient presented was advised to sleep under a mosquito net or use mosquito repellants (3,4).

References

1. Cunningham F.G. Gant F.G.
Infections
In: Williams's obstetrics, 21st edition, McGraw-Hill publications, 2001;
Page 1477-1478
2. Alecrin W D, Espinosa M F E, Alecrin M G C;
Plasmodium Falciparum infection in the pregnant patient.
Inf D Clin North America, March, 2000; Vol 14. No. 1.
3. National guidelines for diagnosis, treatment and prevention of malaria
Ministry of health, 2002.
4. Focus antenatal care and malaria in pregnancy
Ministry of health, 2002.
5. Sinei S.K.A., Mati J.K.G. Mungai J.
Prevalence of anaemia in pregnancy and the role of malaria in its aetiology in rural Kenya.
J. Obstet. Gynaecol. East and Central Africa, 1984; 3: 117
6. Rukaria R.M.
In vivo and invitro responses of plasmodium falciporum to chloroquine in pregnant women in Kilifi district, Kenya.
M. Med thesis UON, 1990.
7. Ralph D.F., Cherry J.D. et al
Malaria.
In: Textbook of paediatric infectious diseases, 4th edition, vol 2,
W.B. Saunders publications, 1998, page 2437-2449.

8. Rukaria R.M, Ojwang S.B.O, Oyieke J.B.
Haemoglobin levels in pregnant coastal women with malaria parasitaemia.
J. obstet. Gynaecol. East and Central Africa , 1996; 12: 18.

9. Kochav D.K, Theuri I, Joshi. A. et al.
Falciporum malaria and pregnancy.
Indian journal of malaria, 1998; 35 (3): 128 - 130.

10. Dutta D.C.
Medical and surgical illnesses complicating pregnancy.
In: Textbook of Obstetrics, 5th Ed, New Central Publications, 2001; page 312–313.

Case No. 14

TWO PREVIOUS SCARS-ELECTIVE CAESAREAN SECTION-

LIVE BIRTH

Name:	M O	Parity:	2+0
Age:	30 years	DOA:	7.04.04
IPNO:	0801250	DOD:	15.04.04

Presenting Complaints

The patient had been admitted through the antenatal clinic for an elective caesarean section due to two previous scars at term.

History of current pregnancy

She had booked antenatal clinic at Kenyatta national hospital at 31 weeks gestation. Her last menstrual period was on 11.07.03 and the expected date of delivery was on 18.04.04, giving a 38 weeks gestation. Her antenatal profile was; blood group B positive, VDRL-negative, HIV-negative, haemoglobin -12.4g/d and urinalysis-normal Her entire antenatal period was uneventful.

Past obstetric and gynaecologic history

She was a 30 years old para 2+0 with one living child. She had her first delivery in 1996 through a caesarean section due to cephalopelvic disproportion. The outcome was a life male infant weighed 2800grams. The second delivery was in 2001 also through a caesarean section at seven months gestation due to severe pre-eclampsia with a previous scar. The outcome was a life female infant who weighed 1700grams but died 2 days later due to prematurity.

Her menarche was at 14 years. Her menses lasted 3 to 4 days, recurred after 28 days, regular and no associated dysmenorrhoea. She had no history of contraception.

Past medical and surgical history

This was not significant.

Family and social history

She was married and was a business lady. Her husband worked as a manager at a five star hotel in the city centre. Neither smoked cigarettes nor consumed alcohol. There was no family history of twins or chronic illnesses.

Physical examination

General Examination

She was found to be in good general condition. She was not pale, not jaundiced, afebrile and no peripheral oedema. Her vital signs were within normal limits.

Abdominal examination

The abdomen was uniformly distended with a subumbilical midline scar. The fundal height was corresponding to term. The foetus was in longitudinal lie, cephalic presentation, descent of five-fifth up and a regular foetal heart rate of 140 beats per minute.

Pelvic examination

Not done since there was no indication.

Other systems

The central nervous, cardiovascular and respiratory systems were essentially normal.

Diagnosis

A diagnosis of two-previous scar at term was made

Investigations

- 1) Blood group - B positive
- 2) VDRL - Negative
- 3) HIV - Negative
- 4) Total blood count - WBC $6.2 \times 10^9/l$
- Hb 10.9g/dl
- Platelets $242 \times 10^9/l$
- 5) Urea and electrolytes – Sodium 136mmol/l, potassium 3.4mmol/l, urea 2.7 mmol/l and creatinine 66 $\mu\text{mol/l}$

Management

The operation was scheduled for 10.04.04 at 8.00a.m. On the day before, a blood sample for grouping and cross matching was taken and she consented for the operation.

She was starved from midnight. On the morning of the operation, she was shaved, an intravenous line established and 5% dextrose drip commenced. Half an hour before being wheeled to theatre, she received atropine sulphate 0.6mg intramuscularly and two units of blood were availed.

In theatre, the patient was put in semi-lithotomy position, vulvovaginal toilet done, aseptically catheterized and 20mls of clear urine obtained. She was repositioned to supine, abdomen cleaned, draped and then anaesthetised.

The caeserean section was performed as described in the introduction. The outcome was a life female infant who weighed 3000 grams and scored 7/1, 9/5 and 10/5. The infant had a cord round the neck twice but not tight.

The liquor was clear and the placenta was found to be low lying and posterior (placenta praevia type II posterior). The placenta was delivered manually, weighed 450 grams and appeared grossly normal. The abdominal cavity was closed in layers after the count of instruments and swabs was reported as correct. The general anaesthesia was reversed successfully. The blood loss was estimated at 400mls.

Post-operative care

The patient was wheeled to the recovery room where vital signs were observed quarter hourly until she was fully awake. She was then taken to the ward where four hourly observations of vital signs were done. The baby joined the mother in the ward after she was fully awake.

She received intravenous fluids; 500mls of normal saline alternating with 5% dextrose every 6 hours until the bowel sounds were auscultated and started on oral sips. She received intravenous crystalline penicillin 2mu 6 hourly and gentamycin 80mg 8 hourly for three days and intramuscular pethidine 100mg 8 hourly for 24 hours. On the 3rd post-operative day, she was converted to oral ampiclox 500mg 6 hourly for 5 days.

She was discharged on the 4th postoperative day and was for removal of stitches at her nearest health facility on the 7th postoperative day. She was booked for review at the postnatal clinic after 6 weeks.

Follow-up

She came for review after 6 weeks as scheduled. She was in good general condition, not pale, the breasts were active and the incision site had healed. She had no vaginal discharge. She was counseled on various family planning methods and settled on depo-provera. However, she preferred to get her choice of contraception at her nearest health centre. She was subsequently discharged from the clinic.

Discussion

Caeserean section is defined as an operative procedure whereby the foetus, placenta and membranes are delivered through an incision on the abdominal and uterine walls after 28 weeks gestation. This definition excludes removal of the foetus from the abdominal cavity following uterine rupture or an abdominal pregnancy (1,2,3).

Amidst controversy, the term “caeserean section” appears to have been derived from the notification “Lex Ceserea” – a Roman law promulgated in 715 BC which provided either an abdominal delivery in a dying woman with the hope of getting a live baby or to perform post-mortem abdominal delivery for separate burial (of mother and foetus). *The operation does not derive its name from the birth of Caesar, whose mother lived long after his birth* (1,2)!

The first documented caesarean section on a living patient, who died on the 25th postoperative day, was done in 1610. In the United States, the first successful caeserean section was performed in 1794 in Virginia. Both the mother and foetus survived (1,2).

Unlike the past, today a caeserean section is not performed as a last resort but as a safe alternative to a risky vaginal delivery with due consideration for her obstetric future (2). Indications for caeserean section can be maternal, foetal or combined foeto-maternal problems. Common indications for caesarean section include previous caeserien section for a recurrent cause, cephalopelvic disproportion, multiple pregnancy with malpresentation, pre-eclampsia and eclampsia, foetal distress, maternal genital herpes simplex and cancer of the cervix (1,2,3,4).

The incidence of caeserean section is steadily rising. During the last decade, there has been two to three-fold rise in the incidence; from the initial rate of about 10% (1,2).

In the United States, the caeserean section rates have risen from 11.4% in 1976 to about 25% by 1999(1,2,3). Locally, the caesarean section rate at Kenyatta National Hospital has steadily increased from an average of 18% from 1977-1983 to an average of about 20% from 1984-1989 and currently stands at approximately 29 to 31% (5,6). The reasons attributed to this rise are varied and includes (2,4):

- 1) Increased awareness of foetal well-being using modern technology such as electronic foetal monitoring devices and biophysical scoring using ultrasonography – these have a tendency to detect early foetal compromise favouring abdominal delivery.
- 2) Increased identification of at risk mothers
- 3) Wider use of caesarean section in post-caesarean pregnancies and malpresentation.
- 4) Reduction of difficult operative or manipulative vaginal deliveries in favour of caesarean section
- 5) Adoption of small family norm – neither the obstetricians nor patients' desires to take even the slightest extra foetal risk of abnormal labour. This may also increase medical-legal pressure on the obstetricians to opt for caesarean section deliveries (2,4)

Repeat caesarean section is a major contributor to increased incidence of abdominal route deliveries. In the United States, previous caesarean section contributes 36 to 48% of all caesarean sections (3). Locally, Karanja (1982) found repeat caesarean section contribute about 48% of all sections at Kenyatta National hospital (5).

The patient presented had the first caesarean section due to cephalopelvic disproportion (CPD) and the second due to severe pre-eclampsia (PET).

There are two types of caesarean section; the lower uterine segment (LUSCS) and the classical type. In the lower uterine segment section, the extraction of the baby is done through a near transverse incision and it is the most widely used method in present day obstetrics. In fact, caesarean section is almost synonymous to lower segment operation. In the classical operation, the baby is delivered through an incision made in the upper segment of the uterus in a near vertical incision and its indications in present day obstetrics are very much limited and is only done under forced circumstances. These circumstances include situations where accessibility to the lower segments is difficult due to dense adhesions, poorly formed lower segment, fibroids in the lower segment, transverse lie with ruptured membranes and cancer of the cervix in pregnancy. A classical caesarean section scar is likely to rupture in labour or even antenatally without uterine contractions- the so-called silent rupture (3).

Lower uterine segment caesarean section may allow for a trial of scar whereas the classical type must always have a repeat caesarean section (3). The prediction of successful spontaneous vertex delivery after a caesarean section and the likelihood of scar dehiscence can be done on the basis of the indication for previous operation, number of previous caesarean section, assessment of both pelvic and foetal size, and sonographic determination of the thickness of the uterine scar (1,3).

The patient presented had two previous caesarean sections and hence needed no trial of vaginal delivery.

Based on the timing of the operation, caesarean section can be either elective or emergency. Elective caesarean section is defined as an operation that is done at a pre-arranged time during pregnancy to ensure best surgical conditions. A balanced judgement is reprieved to select the optimal time for caesarean section keeping in mind the safety of mother vis- a- vis safety of the baby (in intero or ex-intero) (2). The foetal maturity must be assessed prior to undertaking an elective caesarean section.

In emergency caesarean section, the operation is performed due to unfore-seen complication(s) arising either during pregnancy or during labour without time being wasted following the decision (2,3).

The concept of an elective caesarean section is usually brought up during the antenatal period. This allows the family to arrange for financial requirement, pre-operative assessment and care, and assembling of a more competent team to provide resuscitation of the baby or mother if needed.

The patient presented had an elective caesarean section at 39 weeks gestation by dates (term).

An antenatal mother scheduled for an elective caesarean section can be admitted the day before surgery for evaluation by the obstetrician and the anaesthetist.

The haemoglobin level, urea and electrolytes are checked and least one unit of cross matched blood made available. The patient is starved for 8 hours prior to surgery.

The patient presented had two units of cross-matched blood made available, her haemoglobin level was 10.9g/dL, and urea and electrolytes were normal.

It should be emphasized that a caesarean section is not an absolutely safe operation. Complications related either to the operation or to the indications for which the operation was done, may arise. These complications are more likely to occur in emergency rather than elective operations and they include (1,2,3);

1) Postpartum haemorrhage: - Caesarean section operation is associated with a higher blood loss than in a vaginal delivery with an average blood loss of up to one litre – which may be catastrophic in presence of pre-existing anaemia.

2) Anaesthetic hazards: - These are mostly associated with emergency operations. The hazards are related to aspiration of gastric contents and may result in aspiration atelectasis or aspiration pneumonia.

3) Sepsis: - Infection still remains the leading cause of puerperal morbidity following the operation. These include wound sepsis, urinary tract infection, endometritis, peritonitis and pelvic abscess. Peritonitis is more likely following prolonged rupture of membranes or caesarean section related to labour indications such as obstructed labour or prolonged labour.

4) Thrombosis: - Leg vein thrombosis and pulmonary embolism are more likely to occur after caesarean section than vaginal delivery.

5) Wound complications – These include wound sepsis, haematomas and wound dehiscence; sometimes with evisceration.

6) General complications - These include incisional hernia and intestinal obstructions due to adhesions and bands

7) Iatrogenic prematurity - Prematurity out of mistakes in maturity assessment are not uncommon in elective operation.

The patient presented did not develop any postoperative complication and had an estimated blood loss of 400mls.

Vital steps to minimize complications related to caesarean section include (2);

1. To take an early decision than a late one
2. The sooner the operation is performed following the decision, the better
3. The most experienced persons (surgeon and anaesthetist) should be made available to take the difficult and risky cases especially in emergency situations.
4. Adequate measures should be taken to prevent anaesthetic complications
5. Frantic attempt to delivery a moribund baby ignoring the risks involved to the mother may at times end fatally.

References:

1. Ralph W.H
Operative delivery
In: Current obstetric and gynaecologic diagnosis and treatment, 8th edition;
Appleton and Lange, 1994; pg 559 – 570
2. Dutta D.C
Operative obstetrics
In: Textbook of obstetric, 5th edition, New Central Publication, 2001; pg 631-
641
3. Cunningham F.G, Norman F.G
Caeserean delivery and post partum hysterectomy
In: Williams Obstetrics, 21st edition, McGraw-Hill 2001; pg 538 – 553
4. Traffer P.E, Marie P
Caserean section rate
Br. Med. J. 1994; 38:133
5. Karanja J.G
A review of caesarean section at KNH – 1980
M. Med thesis UON, 1982
6. Muriu F.K.J
A retrospective study on caesarean section pattern at KNH
M. Med thesis UON 1991
7. Tanik A, Ustun C, Arslan A.E et al
**Sonographic evaluation of the wall thickness of lower uterine segment in
patients with previous caesarean section**
J. Clinical ultrasound, 1996; 24 (7):355-7

Case No. 15

TWIN PREGNANCY – CAESAREAN SECTION- LIVE BIRTHS

Name:	FA	Parity:	1+0
Age:	22 years	DOA:	12.5.04
IP NO:	0959822	DOB:	18.5.04

Presenting Complaints

The patient had been admitted as a referral from Kitengela health centre with a two-week history of bilateral leg swelling.

History of Presenting Illness

The patient had been well until 2 weeks prior to admission when she noticed swelling of both legs especially around the ankle joints. The swelling increased insidiously and worsened on walking for a long distance or standing for a long period. She did not have a history of facial swelling or puffiness. She had no headache, no visual disturbances, dizziness, no upper abdominal pain and had not fitted. She reported perceiving foetal movements regularly and having a normal urinary pattern. She was not a known hypertensive.

History of Current Pregnancy

Her last menstrual period was on 2/9/03 and her expected date of delivery was on 9/6/04 giving a gestational age of 36 weeks. She had booked antenatal clinic at Kitengela Health Centre at 28 weeks gestation.

During that first antenatal visit, the blood pressure was noted to be normal – 110/70mmHg, however, the fundal height was not recorded. The antenatal profile done; VDRL negative, HIV negative, blood group A positive haemoglobin 9.8g/dl and normal urinalysis. She was put on ferrous sulphate 200mg three times a day and folic acid 5mg once a day for one month.

During the next visit (2 weeks later) she was noted to have bilateral leg swelling and elevated blood pressure of 145/95mmHg.

Urinalysis was not done. She was put on alpha-methyldopa 250mg three times a day and phenobarbitone 30mg twice a day and then referred KNH.

Past Obstetric and Gynaecologic History

She was para 1+0 and her last delivery was in 1998 by spontaneous vertex delivery. The outcome was a live male infant who weighed 3100grams and was alive and well. She had her menarche at 14 years. Her menses were regular, lasting 3 to 4 days and of normal flow. The menses recurred after 28 days and no associated dysmenorrhoea. She had used oral contraceptive pills for one year but stopped in July 2003 in order to conceive.

Past Medical and Surgical History

This was not significant.

Family and Social History

She was a housewife, her husband was a businessman and they stayed at Kitengela. Neither smoked cigarettes nor consumed alcohol. There was no family history of twins. There was no history of chronic illnesses in the family.

Physical Examination

General Examination

She was found to be in fair general condition. She was not pale, not jaundiced, afebrile, no lymphadenopathy but had bilateral pitting pedal oedema. Her vital signs were; blood pressure 140/90mmHg, pulse rate -96/minute, respiratory rate- 16/minute and temperature- 36.8 degrees centigrade.

Abdominal Examination

The abdominal was uniformly distended. The fundal height corresponded to a term pregnancy. Multiple foetal parts were palpated. The first twin was in breech presentation while the second twin was in cephalic presentation. Both foetal hearts' rates were heard at 138 and 144 beats per minute and regular. She had no palpable contractions.

Pelvic Examination

This was not done, as there was no indication

Other Systems

Cardiovascular, respiratory and central nervous systems were essentially normal.

Diagnosis

A diagnosis of twin pregnancy with pre- eclampsia at 36 weeks gestation was made.

Investigations

1. Urinalysis: Proteinuria +++

2. Urea 3.3mmol/l, creatinine 96micromol/l, sodium 143mmol/l, potassium 4.6mmol/l and chlorine 109mmol/l
3. Full Blood count
 - haemoglobin 12.1g/dl
 - WBC $6.8 \times 10^9/l$
 - RBC $4.6 \times 10^{12}/l$
 - MCV 82fl, MCH 25.8pg, MCHC 31.6g/dl
 - Platelets $197 \times 10^9/l$
4. Liver function tests
 - Total protein 66g/l
 - Albumin 33g/l
 - Total bilirubin 12.2micromol/l
 - Direct bilirubin 6.2micromol/l
 - AST 32 u/l
 - ALT 26 u/l
 - ALP 250 u/l
 - GGT 12u/l

5. Biophysical Profile

The obstetric ultrasonography confirmed the presence of intrauterine twin pregnancy.

First twin: Was in breech presentation, had a normal cardiac and somatic activity demonstrated. The foetal heart rate was 125 beats per minute and regular. The BPD 9.21 cm (37 weeks 3 days), AC 32.2cm (36 weeks 1day) and FL 6.93cm (35weeks 4days) giving an estimated average gestational age of 36 weeks 3days.

The placenta was on the left fundolateral aspect and was not low lying.

Second twin: Was in cephalic presentation, had a normal cardiac and somatic activity demonstrated. The foetal heart rate was 126 beats per minute and regular. The BPD 8.44cm (34 weeks 1day), HC 30.7cm (35weeks 5days) and FL 6.98cm (35 weeks 6days) giving an average of 35 weeks 2 days. The placenta was in the right posterolateral aspect and not low lying.

The amount of liquor was adequate and there was no congenital abnormalities seen. Both twins had a biophysical profile of 8 out of 8.

Management

She was admitted to the antenatal ward for the control of the blood pressure and be worked up for an elective caesarean section at 37 completed weeks due to twin gestation

with the first in breech presentation. She was put on alpha-methyldopa 500mg three times a day, phenobarbitone 30mg thrice a day and dexamethasone 12mg twice a day for three doses. She was put on bed rest, vital signs 4 hourly and foetal kick chart. Blood for liver and renal function evaluation was taken on alternate days. Full blood count was to be taken weekly and daily urinalysis for the evaluation of proteinuria. Her fluid input and output chart remained satisfactory and her blood pressure was well controlled (ranging; systolic 120-140mmHg and diastolic of 80-100mmHg).

However, on the third day she had blood pressure spikes of diastolic of over 110mmHg, reported reduced foetal movements, constant frontal headache and blurred vision. An impression of impending eclampsia was made. Since the first twin was in breech presentation, a decision to deliver her by emergency caesarean section was made.

The patient was explained the nature of her condition and the intended management. She gave an informed consent, shaved and premedicated with atrophine sulphate 0.6mg intramuscularly 30 minutes prior to being wheeled to theatre.

In theatre, the patient was put in a semi-lithotomy position, vulvovaginal toilet done, catheterized aseptically and repositioned to supine. The abdomen was cleaned, draped and anaesthetised. The caesarean section was performed as described in the introduction. Both twins were delivered by breech extraction.

The first twin was male, weighed 2800gms and had *apgar* scores of 7/1, 9/5 and 10/10. The second twin was also male and weighed 2200gms and had *apgar* scores of 7/1, 8/5 and 10/10. They had two separate placentas and amniotic sacs.

The placentas weighed 420gms and 400gms, and they appeared grossly normal. The estimated blood loss was 950mls.

Postoperatively, the mother and the babies did well. Her vital signs remained stable throughout her stay in the ward. She was discharged on the 7th postoperative day after removal of the stitches. She was booked for review in the postnatal clinic after 6 weeks.

Follow Up

She had no complaints. The breasts were active and not engorged. The blood pressure was 120/70mmHg and she was not on any anti-hypertensives. The uterus was well involuted and the incision site had healed. She had no abnormal vaginal discharge. She was discharged through the family welfare clinic for contraception.

Discussion

Multiple pregnancy is said to occur when more than one foetus develops simultaneously in the uterus (1). The most common number of foetuses is two although higher numbers are becoming more frequent due to ovulation-induction and embryo transfer (1,2,3).

The patient presented had a twin pregnancy.

Twins can be divided into two; the monozygotic and diazygotic twins, Dizygotic twins result from fertilization of two ova by two spermatozoa while monozygotic twins result from a single fertilized ovum that divides into two or more similar parts (2,3).

Dizygotic twins are always diamniotic dichorionic while monozygotic twins may be diamniotic dichorionic, diamniotic monochorionic or monoamniotic monochorionic and are always of the same sex (1,2,3).

The patient presented had dizygotic twins.

The incidence of monozygotic twinning is relatively constant for all populations with a rate of 1 in 250 births and is independent of maternal age, parity and heredity (1,2,3). However, the incidence of dizygotic twins shows varied incidence dependent mainly on (1,2,3);

- Race – the frequency is highest amongst Negroes, lowest amongst mongoloids and intermediate among Caucasians.
- Heredity – Dizygotic twins tend to be recurrent. Women with dizygotic twins have a ten-fold increased chance of a repeat multiple pregnancy. The hereditary predisposition is probably transmitted through the female descendant while the male descendant plays little or no part.
- Maternal age – increased incidence of twinning is observed with advancing maternal age, the maximum being between the age of 30-35 years and then declining sharply thereafter.
- Parity – The incidence is increased with the increasing parity especially from the 5th gravida onwards.
- Iatrogenic – Drugs used for induction of ovulation may produce multiple foetuses to the extent of 20-40% following gonadotrophin therapy, but to a lesser extent (5-6%) following clomiphene citrate therapy.

The incidence of dizygotic twins, as observed above, varies widely.

It is highest in Nigeria being 1 in 20 and lowest in the Far East countries being 1 in 200 pregnancies (1). Locally, Oyieke (1978) found the incidence of twinning at Kenyatta national hospital to be 1 in 58 live births (4). Mutungi (1990) in her series at KNH and Pumwani maternity hospital found an incidence of 1 in 46 live births (5).

The patient presented was a 22 years old para 1+0, black with no family history of twinning but had a history of oral contraceptive use.

Slightly more than 30% of twins are monozygotic and nearly 70% are dizygotic (2,3). In her series, Mutungi found 29.6% of twins to be monozygotic and 64.8% to be dizygotic (5).

Generally, about 75% of cases, the twins are of the same sex, both may be males in 45%, both may be females in 30% and in 25% they are of mixed sex (2).

In the case presented both twins were male.

Dizygotic twins develop within two separate amniotic sacs and have two separate placentas. However, the degree of separation of monozygotic twins depends on the time of cleavage of the fertilized ovum. Division occurring within 72 hours (2-3days) before the inner cell mass is formed and the outer layer of the blastocyst is committed to becoming a chorion, results in the dichorionic diamniotic twins with two or fused placentas. Division occurring between 4-8 days when the inner cell mass is already formed and cells that are designated to become the chorion are already differentiated but the amnion is not yet formed, results in monochorionic diamniotic twins. Any division that occurs later than this, after the embryonic sac is formed, results in incomplete cleavage giving rise to conjoined twins (1,2,3).

Clinical diagnosis of multiple pregnancy starts with the history of twins in the family or in the patient's previous deliveries. Exposure to predisposing factors such as ovulation-induction for infertility, recent stoppage of oral contraceptives or embryonic transfer may be elicited (1,2).

In the case presented, the patient had no previous delivery of twins or family history of the same but had a history of oral contraceptive use.

All of the common annoyance of pregnancy are more troublesome in multiple pregnancy. The effects of multiple pregnancy on the patient include earlier and more severe pressure on the pelvis, nausea and vomiting, backache, varicosities, constipation, haemorrhoids, abdominal distension and difficulty in breathing (2). The unusual rate of abdominal enlargement and excessive foetal movements may even be noticed by an experienced parous mother (3).

Over 75% of multiple pregnancy cases can be diagnosed by physical examination (2). Mutungi (1990) found that only 40-54% of multiple pregnancy cases were diagnosed antenatally at Kenyatta National Hospital (5).

The following clinical findings may suggest the possibility of a multiple pregnancy (2);

- Excessive weight gain – not explained by obesity or even pre-eclampsia
- Uterine size larger than the period of amenorrhoea
- Palpation of too many foetal parts
- Finding of two foetal heads or three foetal poles
- Simultaneous auscultation of two distinct foetal heart sounds, located at separate spots with a silent area in between, by 2 persons, gives a certain clue in the diagnosis of twins provided the difference in the heart rates is at least 10 beats per minute.

The patient presented had a uterine size larger than the period of amenorrhoea, had gained excessive weight and had three foetal poles.

Ultrasonography is the most commonly used aid in the diagnosis of multiple pregnancies. It is a safe method and relatively accurate. It can detect the presence of two gestational sacs as early as the 10th week of pregnancy and as early as 4th week by transvaginal ultrasonography (6).

Early pregnancy ultrasonography has shown a higher incidence of multiple gestation than found at delivery.

This has been explained by the fact that some fetuses get dissolved (vanishing twins) while the other embryo or foetus continues to grow. Indeed, foetal death occurring as late as the end of the first trimester can be followed by the complete foetal reabsorption, leaving no evidence at delivery that the twins had ever existed (2,3).

Some biochemical test findings have been shown to differ between singleton and multiple pregnancies.

Maternal serum levels of human chorionic gonadotrophin (HCG), placental lactogen hormone, alpha-fœtal proteins, placental alkaline phosphatase and unconjugated oestriol are approximately double those of singleton pregnancies at the same gestational age (1,3). However, the values cannot clearly diagnose a twin pregnancy from a singleton one (1,2,3).

The patient presented had an ultrasound done to confirm the twin pregnancy.

Multiple pregnancy is a high risk one, being associated with both high maternal and foetal morbidity and mortality. Antenatally, there is a high prevalence of anaemia in multiple pregnancy than in singleton. This is attributed to increased demands by the two foetuses for iron and folates. Megaloblastic anaemia is a result of folate deficiency. Pre-eclampsia is increased three-fold in multiple gestation over singleton pregnancy. Polyhydramnios is 10% more common in monozygotic twins and often involves the second sac. Antepartum haemorrhage may occur with a slight increased frequency than a singleton pregnancy (1,2,3).

The patient presented had mild anaemia, haemoglobin level-9.8g/dl.

The high incidence of placenta praevia in multiple gestation is perhaps due to a bigger size of placenta that encroaches the lower uterine segment. Similarly, the increased incidence of abruption placenta may be due to increased prevalence of pre-eclampsia, sudden escape of liquor in a hydramniotic sac and deficiency of folate (1,3).

Malpresentation and abnormal lie is more common in multiple pregnancy than in singleton. Vertex presentation occurs in the first baby in 70% while both twins present with vertex in 40% of cases. Malpresentation is therefore more common in the second twin but fortunately, the second twin is usually smaller thus posing no much problems. Longitudinal lie is the commonest, occurring in 90% of cases. However, the presence of transverse lie, in both twins, though rare, may raise the possibility of conjoined twins (1,2,3).

The patient presented had pre-eclampsia and the first twin was in breech presentation.

Preterm labour is 30% more common in multiple pregnancy than in singleton. Subsequent foetal prematurity being more common (80%) in multiple pregnancy than in singleton. Over distended uterus, hydramnios and premature rupture of membranes (PROM) are thought to be responsible for the preterm labour.

During delivery, early rupture of membranes and cord prolapse are more likely to occur in multiple gestation due to increased prevalence of malpresentation (1).

Cord prolapse is five times more common in multiple than in singleton pregnancy especially in the second twin. Postpartum haemorrhage (PPH) is a real danger in twin delivery. This could be attributed to uterine atony due to over distension, bigger placental surface area, and prevalence of the large placenta encroaching the lower uterine segment (1,2,3).

There is increased operative interference in multiple pregnancy due to high prevalence of mal-presentation and its associated complications such as cord prolapse. Foetal congenital malformations are increased two-fold over the singleton pregnancy especially in monozygotic twins. These foetal anomalies may include anencephaly, hydrocephalus, cardiac anomalies and conjoined twins (2,3).

The patient presented had an emergency caesarean section delivery due to impending eclampsia and the first twin in breech presentation.

References:

1. Dutta D.C.
Multiple pregnancy, hydramnios and abnormalities of the placenta and cord
In: Textbook of Obstetrics, 5th Ed, New Central Publishers, 2001; Pg 216-225
2. Pemoll M.L. Benson R.C
Multiple pregnancy
In: Current Obstetrics and gynaecologic diagnosis and treatment, 8th Ed, Appleton and Lange, 1994; Pg 357-367
3. Cunningham F.G Norman F.G.
Multifoetal pregnancy
In: Williams Obstetrics, 21st Edition, McGraw-Hill Publication, 2001; pg 765-804
4. Oyieke J.B.O
2 ½ year review of some aspects of twin delivery at KNH
M. Med Thesis, UON, 1978
5. Mutungi A. K.
A prospective study of twin deliveries at KNH and Pumwani maternity hospital
M. Med Thesis, UON, 1990
6. Chittacharoen A, Leelapattana P
Prediction of discordant twins by real time ultrasonography combined with umbilical artery velocimetry
Ultrasound Obstet. Gynaecol J. 2000; 15:18

OBSTETRIC LONG COMMENTARY

**TITLE: PREVALENCE OF FOETAL DISTRESS DUE TO
CORD ENTANGLEMENT AMONG PATIENTS
UNDERGOING EMERGENCY CAESAREAN SECTION
DELIVERY AT KENYATTA NATIONAL HOSPITAL.**

ABSTRACT

Background

Foetal distress is a complex of signs indicating a critical response to stress. It implies metabolic derangements; notably hypoxia and acidosis. These metabolic changes affect the functions of foetal organs to the point of temporary or permanent injury or even death.

Identification of foetal distress based upon foetal heart rate patterns or meconium passage has been imprecise and controversial. Multiple researchers have also differed on the role of cord entanglement as a cause of foetal distress.

In this light therefore, it is important to determine the prevalence and predictive size of cord entanglement, and foetal outcome among patients with foetal distress undergoing emergency caesarean section.

Objectives

To determine the prevalence of cord entanglement and foetal outcome among patients with foetal distress undergoing emergency caesarean section.

Study design

This was a prospective cross-sectional study.

Study site

This study was carried out at labour ward/maternity theatre of Kenyatta National Hospital.

Methodology

Patients who were found to have foetal distress were recruited into the study provided they had satisfied the inclusion /exclusion criteria and were willing to participate. The data was collected using a structured questionnaire. Pre-operative and intra-operative findings of interest were also recorded. Outcome of infants admitted to the newborn unit (NBU) within 48 hours were also recorded. The data was analyzed using appropriate standard statistical methods. A P-value of 0.05 or less signified significant difference between variables of interest.

Results

A total of 283 patients with foetal distress underwent emergency caesarean section between February and July, 2004. 130 (45.9%) cases were found to have foetal cord entanglement. Majority of the patients in this study were young, with those in the 20-29 years age group accounting for 72%. Primigravidae were the majority accounting for 53.7%. Maternal age, educational background, marital status and parity were not associated with foetal cord entanglement (P-value < 0.05).

Abnormal foetal heart rate pattern was observed in 68.5% of cases with cord entanglement compared to 50.6% of cases without cord entanglement. The difference was statistically significant (P-value=0.011). Low APGAR scores at 1-minute was observed in 57% of infants with cord entanglement compared to 26.6% of those without cord entanglement. At 5-minutes, 28.5% of infants with cord entanglement had low APGAR scores compared to 5.2% of those without cord entanglement. The difference was statistically significant (P-value <0.001). About 37% of foetal cord entanglement occurred with cords longer than 70 cm compared to 2% of cords less than 40 cm long. The difference was statistically significant (P-value <0.001).

Five infants (14.3%) among those with cord entanglement admitted to NBU died within 48 hours postpartum compared to none (0%) among those without cord entanglement.

Conclusion

Foetal cord entanglement was common among patients with foetal distress undergoing emergency caesarean section. Abnormal foetal heart rate pattern was identified as an important cord entanglement. Cord entanglement was associated with an increased incidents of early neonatal morbidity and mortality.

INTRODUCTION

The objective of obstetric care is not only to ensure that there is no impairment of the health of the mother but also to ensure that every pregnancy culminates in the delivery of a healthy baby. Around the world, 12.6 million babies die before their fifth birthday and about 25% of these deaths occur during the first week of life and are largely a consequence of poorly managed labour or as the result of inadequate care of the newborn during the first week of life (1).

One of the major causes of perinatal morbidity and mortality is foetal distress, which is defined, as a physiological state in which there is metabolic acidosis secondary to intrauterine hypoxia. Foetal hypoxia is brought about by the factors that cause a umbilical cord compression (such as cord prolapse or cord presentation or cord entanglement) or impaired gaseous exchange between the placenta and maternal circulation (2).

Normally, as labour progresses the foetus descends into the birth canal and in the presence of cord entanglement there is the potential danger of compression of the cord blood vessels especially with tighter cords. This may lead to reduced foetoplacental blood flow and can potentially result in foetal distress and rarely, death (3,4).

Pregnancies with foetal cord entanglement are more likely to have abnormal foetal heart rate patterns consisting of persistent variable and late deceleration while on the continuous electronic foetal monitoring device. These infants are also likely to have meconium stained liquor, a low APGAR scores and a low umbilical artery PH of <7.10 (5,6,7).

When foetal distress occurs in the presence of meconium in amniotic fluid the chances of the newborn respiratory depression and morbidity are greater than if the meconium was not present (2,3). Abnormal foetal heart rate characteristics include: tachycardia of greater than 160 beats per minutes, bradycardia of less than 120 beats per minute, variable deceleration of greater than 50 beats per minute, reduced baseline variability of less than 5 beats per minute and late deceleration.

Blood gases and PH analysis done on a blood sample withdrawn before post-partum physiological adjustment may show a fall in blood PH if the foetal hypoxia and tissue hypoxia was sufficient to cause metabolic acidosis (2,3,4). Once a diagnosis of foetal distress is made, immediate delivery is sought with the mode depending mainly on how far the mother has progressed in labour and the degree or grade of meconium staining of amniotic fluid. At our set-up, meconium staining of amniotic fluid grade 2 plus abnormal foetal heart rate characteristics at cervical dilation of less than 7 cm are delivered by caesarean section while those approaching second stage are given a chance to deliver vaginally while administering oxygen by mask, lying on the left lateral position and infusion of 10% dextrose solution taking into consideration other obstetric factors.

Locally, no study that have been undertaken to determine the prevalence of cord entanglement, its correlates and subsequent foetal outcome among patients with foetal distress undergoing emergency caesarean section.

LITERATURE REVIEW

Of the 140 million babies born yearly around the world, 12.6 million die before the fifth birthday (1). Approximately 25% of these deaths occur during the first week of life and are largely a consequence of poorly managed labour or as the result of inadequate care of the newborn during the first week of life (1). Intrapartum foetal asphyxia is an important cause of stillbirth and neonatal death. In the United States, an estimated 700 infants' death (17.3/100,000 live births) is attributed to intrauterine hypoxia and birth asphyxia (2).

The term foetal distress is too broad and vague to be applied with any precision to clinical situations. Uncertainty about the diagnosis of foetal distress based upon foetal heart rate patterns has given rise to the use of descriptions such as *reassuring* or *non-reassuring* (3). Non-reassuring foetal heart rate pattern implies inability to remove doubt. Nevertheless, the term "foetal distress" is used to express intrauterine foetal jeopardy; as a result of intrauterine foetal hypoxia (4). Foetal heart rate patterns can be measured in various ways such as (2,3);

- Internal electronic foetal heart rate monitoring using a bipolar spiral electrode attached directly to the foetus after membranes have been ruptured.
- External (indirect) electronic foetal heart rate monitoring – the foetal heart rate is detected through the maternal abdominal wall using the ultrasound Doppler principle.
- Intermittent auscultation using a Pinnard's foetoscope.

The general foetal heart rate criteria for foetal distress include;

- ❖ Persistent late deceleration regardless of the depth of the deceleration
- ❖ Persistent severe variable deceleration especially of the type with a slow return
- ❖ Prolonged deceleration which is generally considered as a variant of severe deceleration

Where only intermittent auscultation method is available, foetal tachycardia (>160 beats per minute), bradycardia (<120 beats per minute) and foetal heart rate irregularities during pregnancy or labour, may be accepted as clinical signs of foetal distress (3,4).

Their appearance is generally recognized as a herald of danger to the foetus and they are an indication for intervention to save the baby. Currently at Kenyatta National Hospital, intermittent auscultation using a Pinnard's foetoscope is the only method available to diagnose foetal distress. When a cardiotocogram (CTG) is in use, a finding of late decelerations, reduced or loss of baseline variability of less than 5 beats per minute or variable deceleration of greater than 50 beats per minute either during pregnancy or intrapartum, are indicative for foetal distress (3,5,6).

According to the American College of Obstetricians and Gynaecologists, measurement of the PH in capillary scalp blood may help to identify the fetuses in serious jeopardy. The PH of the foetal capillary scalp is normally lower than umbilical venous blood and approaches that of the umbilical arterial blood. If the PH is greater than 7.25, labour is observed. If the PH is between 7.20 and 7.25, the PH measurement is repeated within 30 minutes. However, if the PH is less than 7.20 it is indicative of foetal distress and delivery by emergency caesarean section is necessary (6).

Carez and Winker in a study of neonatal complications as related to the degree of umbilical artery acidemia found that infants born with umbilical artery PH less than 7.20 were at greater risk of short-term neonatal complications attributable to intrapartum hypoxia. Infants with severe acidemia of PH 7.00 or less with metabolic acidosis as well as low APGAR scores (less than or equal to 3) were at increased risk of neonatal complications of the type commonly associated with neurological sequelae including mortality (7).

Skye's (1982) reported that umbilical cord blood PH determination better reflects the infant's condition at birth than does APGAR score (8). Mohammed and Kasule (1992) did a study on foetal heart rate monitoring and their interpretation. They reported that continuous electronic foetal heart monitoring with cardiocograph and hand held Doppler Ultra Sound foetal monitor were equally reliable in detecting foetal distress with high rates of foetal acidosis, but the two were better than clinical diagnosis with abnormal foetal heart pattern diagnosed with Pinnard's Foetoscope and meconium staining of amniotic fluid alone. They recommended the use of hand held Doppler which is cheaper, easier to handle, less disturbing to the mother, yet equally reliable as continuous electronic foetal heart monitoring (9).

Fujikura. described meconium as consisting mainly of bile pigments, bile salts, foetal hair, squamous cells from the foetal skin and gut, mucopolysaccharides and cholesterol (10). Meconium staining of amniotic fluid may be graded by physical examination into grade 1, 2 and 3, which correspond to light, moderate and thick meconium staining.

Grade 1 – the stained amniotic fluid will appear yellow or light green and if placed in a glass test-tube the examiner will readily see light shone through it.

Grade 2 – the stained amniotic fluid will appear green and if placed in a glass test-tube and light shone through it, it will allow less light to pass through i.e. translucent.

Grade 3 - the stained amniotic fluid will be dark green, thick and tenacious and will not allow light to shine through (opaque) when placed in the glass test-tube (11,12)

Obstetrical teaching throughout the century has included the concept that meconium passage is a potential warning of foetal asphyxia. In fact, Williams (1903) observed that “a characteristic sign of impending asphyxia is the escape of meconium” (13). Others believe that passage of meconium without foetal heart rate abnormalities is not a sign of foetal compromise.

The significance of the passage of meconium stained amniotic fluid in labour is therefore still fraught with controversies. According to Fenton, the passage of meconium takes significance only when it's associated with other classical clinical signs (Tachycardia, bradycardia and foetal heart rate irregularities) of foetal distress. They stated that “the passage of meconium in the absence of any change in the foetal heart rate, is clearly not a sign of foetal distress; but the presence of meconium with an abnormal foetal heart rate is a sure sign of foetal distress and foetal compromise” (14).

In a study by Fongoh (1984) meconium staining of amniotic fluid in labour was associated with lower 1 and 5-minute APGAR scores and higher perinatal morbidity and mortality than clear amniotic fluid. Light meconium staining was of lesser prognostic significance in all stages of labour but thick meconium staining especially in early labour carried particularly ominous neonatal prognosis. Thick meconium was more contributory to severe and moderate neonatal asphyxia than light meconium staining.

He noted a perinatal mortality rate of 80 per 1000 live births for cases of meconium staining of amniotic fluid in labour. The results from this study agreed with those who consider meconium passage as a bad prognostic sign (15). Meconium aspiration syndrome is significantly associated with foetal acidemia at term (16). This syndrome is more common with thick meconium staining (grade 3 meconium). The mechanism of meconium aspiration are poorly understood. Theories postulated include foetal gasping in utero, possibly because of severe hypoxia or with the onset of breathing following delivery (16).

Pathophysiology of foetal distress: - Abnormal foetal heart rate patterns are more of a reflection of foetal physiology than pathology. Physiological control of heart rate includes a variety of interconnected mechanisms that depend on blood flow as well as oxygenation. Under normal conditions when oxygen supply is adequate, aerobic glycolysis occurs in the foetus and glucose is converted into pyruvic acid which is ultimately oxidized via the Krebs's cycle (10,17).

However, in conditions causing cord compression, abruption placenta, decreased placental perfusion by tetanic contractions, maternal shock and distress, there is decreased delivery of oxygen to foetal tissues and decreased clearance of carbondioxide through the placenta into maternal circulation (17).

This results into increased anaerobic respiration in foetal cells and increased partial pressures of carbon dioxide in circulating blood. Tissue anoxia causes individual cells to resort to anaerobic glycolysis resulting in the accumulation of pyruvic and lactic acids leading to metabolic acidosis (4). Initially, the acid is readily neutralized by the body buffer systems. Once the generation of lactic acid and carbonic acid from dissolved carbondioxide outpaces the buffering process acidemia sets in together with a deficit of the buffering bases. The hydrogen (H^+) ions first stimulate and then depress the sino-auricular node (SAN) leading to tachycardia and bradycardia respectively (4,6).

Equally, the foetal central nervous system (CNS) is very sensitive to acidosis resulting in depression of the respiratory centers (4). Factors controlling the passage of meconium are complex and poorly understood. However, hydrogen ions are thought to cause parasympathetic stimulation of the foetal intestines leading to hyperperistalsis and relaxation of the anal sphincter with meconium passage as ultimate consequence (4,10,17)

Miller proposed that reflex vagal stimulation of foetal gut following sporadic or repetitive cord compression may result to relaxation of the anal sphincter thus passage of meconium (11).

They have schematized the events leading to meconium passage as follows:

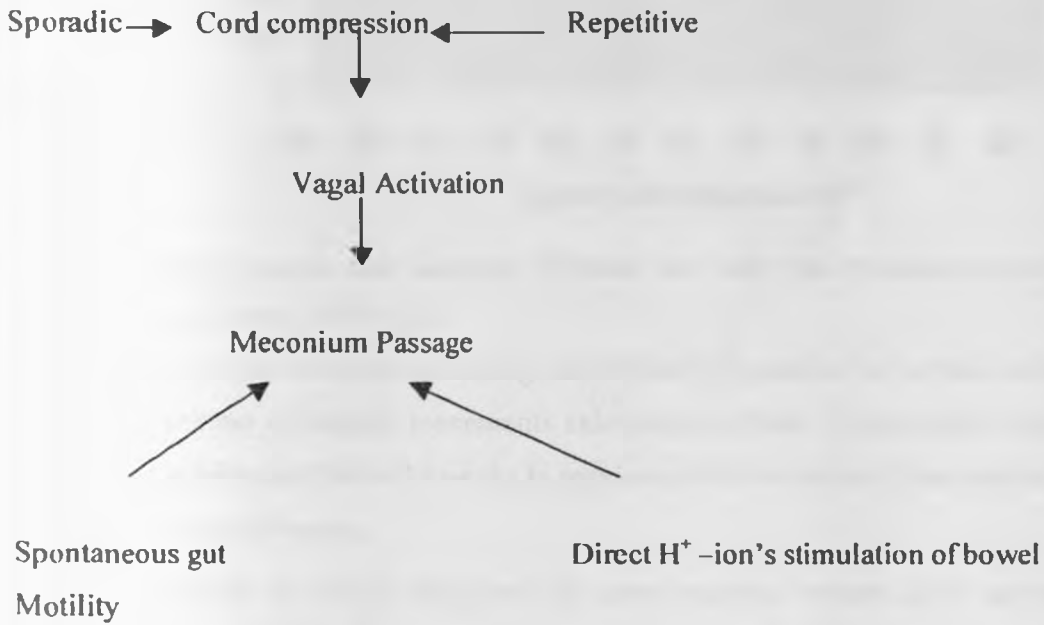


Fig. 1: Aetiology of meconium passage (11).

Passive unstimulated foetal activity commences as early as 7 weeks gestation and becomes more sophisticated and co-ordinated by the end of pregnancy. Between 20 and 30 weeks gestation, general foetal body movements become organized and the foetus starts to show rest-activity cycles. An important determinant of foetal activity appears to be sleep-awake cycles, which are independent of the maternal sleep-awake state. Amniotic fluid volume is another important determinant of foetal activity. The declining of both amniotic fluid volume and intra-uterine space accounts for the diminishing foetal activity towards term (18).

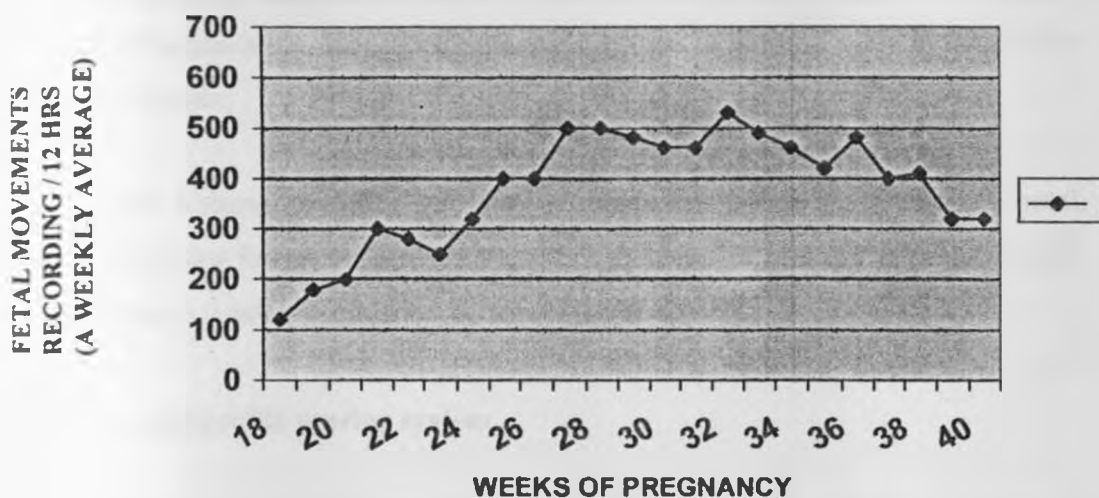


FIGURE 2: Weekly average fetal movements calculated from Daily Fetal Movement Records during normal pregnancy (means + S.E.M) (18).

Fig 2: - shows foetal movements during the last half of gestation in normal outcomes. The mean number of weekly movements calculated on from 12-hour daily recording periods range between 200 at 20 weeks to maximum 600 movements then decline to an average of 300 at 40 weeks.

Foetal movements are noted subjectively by most pregnant women. If 10 movements have not occurred within 12 hours or it takes twice as long for 10 movements to occur as it did the week before, then the count is considered abnormal (18). On further testing, over 90% of high risk patients have a normal foetal movement count with an incidence of foetal distress during labour of less than 5% and abnormal foetal movement is reported in 5-10% of the patients (18). If no further testing or intervention is done foetal death will occur in 10-30% of the patients. Since normal foetal movements are a strong indicator of the foetal well being, most authorities endorse movement counting as a primary means of foetal surveillance, however, further testing with Biophysical profile (BPP) scoring is required (18).

Platt (19) developed the concept of the foetal biophysical profile score by combining five variables that could be assessed by ultrasound namely: -

- Foetal breathing movement
- Gross foetal body movements
- Foetal tone
- Relative foetal heart rate (also known as non stress test) and
- Amniotic fluid volume

Foetal body movement and tone reflect the functions of the foetal central nervous system at the time of examination. The central nervous system is the first body system to be affected by asphyxia.

Amniotic fluid volume provides information about the presence of chronic foetal asphyxia. When the foetus encounters hypoxia, perfusion of kidneys is reduced with resulting decrease in urine production hence oligohydramnios.

Fig 3: Biphysical profile scoring system.

Variable	Normal (score-2)	Abnormal scores
Foetal breathing movements	At least one episode of at least 30 seconds duration in 30 minutes observation	Absent or no episode of at least 30 seconds in 30 minutes
Body movements	At least 3 discrete body movements in 30 minutes (episode of active continuous movement considered a single movement)	Up to 2 episodes of body movements in 30 minutes
Foetal tone	At least one episode of active extension with return of flexion of foetal limbs or trunk, opening and closing of hand considered normal tone.	Either slow extension with return to partial flexion in movements of limbs in full extension or absent foetal movements
Non stress test	At least 2 episodes of acceleration of at least 15 beats per minute and at least 15 seconds duration associated with foetal movements in 30 minutes	Fewer than 2 acceleration less than 15 beats per minute in 30 minutes
Quantitative amniotic fluid volume	At least one pocket of amniotic fluid measuring at least 2 cm in its largest vertical axis	Either no amniotic fluid or pocket less than 1 cm in 2 perpendicular planes.

Each normal variable is scored 2 and abnormal scored zero. The best score is ten out of ten (10/10) and the worst score is zero out of ten (0/10). A score of 10/10 indicates that the risk of foetal asphyxia at that moment is less than 0.1% and there is no indication for immediate intervention unless there are other obstetrics problems. A score of 6/10 to 8/10 with normal amniotic fluid volume is equivocal and indicates possible foetal asphyxia. Conservative management with repeat test after 24 hours is recommended, also taking into consideration other obstetric factors. On the other hand, same score with reduced amniotic fluid volume indicates likely chronic foetal compromise hence delivery should be as soon as possible.

A score of four or less indicates foetal asphyxia and demands immediate delivery otherwise without intervention the risk of perinatal mortality is over 60% (18,19).

Though the incidence of foetal distress varies with the general population, high-risk patients and criteria for diagnosis, foetal distress as an indication for primary caesarean section has contributed significantly to the increase of abnormal deliveries the world over (20).

The United States birth certificate data has reported the incidence of foetal distress of 42.9/1000 live births with the highest rates in infants born to mothers of under 20 years and over 40 years of age and in the blacks (20). Locally, Mati and colleagues found an incidence of foetal distress of about 5.2% of singleton deliveries in Nairobi (21). Teffel studied caesarean section deliveries in the United States in 1994 and found that 63% of foetal distress cases had caesarean sections and 25% of all deliveries were by caesarean section (22).

Locally, the caesarean section rate at Kenyatta National Hospital has steadily increased from an average of 18% from 1977-1983 to an average of about 20% from 1984 -1989 and currently stands at approximately 28.9% (23,24). This trend roughly corresponds to those seen in other countries throughout the world. Gathinji (1976) studied foetal distress managed by caesarean section at Kenyatta National Hospital and found that foetal distress accounted for 10.5% of primary caesarean section deliveries (25). Karanja (1982) reviewed primary caesarean sections done at KNH and of the 339 primary caesarean section delivery analyzed, 82 (24%) cases were done due to foetal distress-a more than two fold increase (23).

Cord entanglement is defined as the twisting of the umbilical cord about (or around) the foetus (or foetal body part(s)) (1). The commonest site of cord entanglement is the foetal neck. Others include the upper and lower limb(s), the shoulder, abdomen and the thorax. The wrappage of the cord around any of these sites/parts may be in form of one or more loops and may also involve a single or multiple parts of the same foetus.

Clayton and colleagues studied loops of the umbilical cord and found single wrappage of the cord around the foetal neck in 21% of all births, double loops in 2% and triple loops in approximately 0.2% (26).

McLennan and colleagues in a similar study, looked at outcomes of pregnancies complicated by a multiple cord entanglement. Of the 8565 deliveries, a single loop of cord around the foetal neck at delivery was found in 2191 (25.6%) deliveries and more than one loop was found in 326 (3.8%) deliveries (27).

Leonardo da Vinci was the first to study the length of the umbilical cord, concluding that its length equaled the length of the foetus throughout gestation (4). Generally, at term a cord shorter than 35cm or longer than 85cm is considered abnormal. A short cord, less than 30cm, may increase the likelihood of placenta abruption (since this is the average distance from uterine fundus to the vulva). Longer cords greater than 85cm may increase the probability of cord entanglement and true knot development (4).

Locally, Ataya (1996) studied the length of the umbilical cord in relation to obstetric outcome at Kenyatta National Hospital. The length of the umbilical cord was measured in the 287 singleton term deliveries that took place. The result was correlated with delivering mothers' age, parity, foetal presentation, sex of the newborn, foetal distress, cord accidents and poor APGAR scores. 89.2% of the cases had normal cord length between 40-70 cm, 4.2% had long cords (>70cm) and 6.6% had short cords (<35cm). It was statistically significant that cases of cord prolapse and cord entanglement occurred with the longer cords (25% of the cases). Also the longer umbilical cords were associated with intrapartum complications of irregular foetal hearts, meconium staining of liquor as well as lower mean APGAR scores (28).

The foetus is tethered by a umbilical cord and its blood flow is constantly under jeopardy because of the potential danger of compression of the cord blood vessels in situations such as foetal neck cord entanglement and cord prolapse or presentation.

Pregnancies with cord entanglement are more likely to have abnormal foetal heart rate consisting of persistent variable deceleration while on continuous electronic foetal monitoring device. These infants are also more likely to have meconium stained liquor, a low APGAR scores at one-minute and a low umbilical artery PH of < 7.10 (29,30).

Associated findings which support the notion that an entanglement is the cause of foetal heart rate abnormalities or foetal death include deep grooving of the skin over the wrappage site of the neck (27).

The outcome related to foetal distress during pregnancy and labour contributes significantly to the perinatal mortality and neonatal morbidity. Severe foetal asphyxia can result in a neonatal death, cerebral palsy or lesser degrees of neurological damage, including retardation of both mental and physical growth, and epileptic seizures-up to 30% in severe asphyxia. It is estimated that 10% of cerebral palsy cases can be directly or indirectly attributed to birth asphyxia (31,32).

STUDY JUSTIFICATION

Though the precise relationship between asphyxia and the foetal heart rate is not well understood, cerebral palsy has been associated with an increased duration of abnormal foetal heart rate patterns and the time taken to deliver such patients (31).

In centres with facilities available for continuous electronic foetal monitoring coupled with foetal scalp blood sampling for PH, foetal distress can be detected early enough and appropriate action taken. Prompt recognition of symptoms and signs of foetal compromise, decisive and well-planned interventions are imperative for the reduction of perinatal mortality and morbidity especially the damage to central nervous system.

In this country, there is an accelerating trend to seek litigation in the event of an abnormal pregnancy outcome. This necessitates improved foetal monitoring, early diagnosis of foetal compromise and timely intervention.

This study is aimed at shedding some light on the significance of cord entanglement as a cause of foetal distress, its associated risk factors and the foetal outcome among patients with foetal distress undergoing emergency caesarean section delivery.

OBJECTIVES

BROAD OBJECTIVE

To determine the prevalence of cord entanglement and foetal outcome among patients with foetal distress undergoing emergency caesarean section at Kenyatta National Hospital.

SPECIFIC OBJECTIVES

1. To determine how frequent cord entanglement is among patients with foetal distress.
2. To determine the prevalence of foetal heart rate abnormalities and meconium stained liquor among patients with foetal cord entanglement.
3. To determine 1 minute and 5 minute APGAR scores, early neonatal morbidity and mortality of infants with cord entanglement.
4. To determine the correlates of cord entanglement.

DESIGN AND METHODOLOGY

STUDY AREA

This study was carried out at the Kenyatta National Hospital which is located about 3 km west of Nairobi City Centre and it offers health services to Nairobi residents as well as the main referral hospital for the rest of the country. Pregnant mothers were selected provided they satisfied the inclusion criteria.

INCLUSION CRITERIA

Included in the study were: -

- Those that were willing to participate after being counselled
- Between age 18 and 45 years.
- At term by dates from the last menstrual period (i.e. Gestational age of between 37 completed weeks and 42 weeks)
- Diagnosed to have a singleton pregnancy
- Diagnosed to have Cephalic presentation.
- Diagnosed to have foetal distress
 - Foetal bradycardia (< 120 beats/minute)
 - Foetal tachycardia (> 160 beats/minute)

-Foetal heart rate Irregularities (such as irregular irregularly or irregular regularly)
-Meconium staining of amniotic fluid(Grade I, II and III).

- Those with reduced foetal movement: -
 - < 10 foetal kicks in 12 hours (by foetal kick chart)
 - biophysical profile score of < 6 out of 10

EXCLUSION CRITERIA.

Mothers exhibiting the following were excluded: -

- Under 18 years or above 45 years of age.
- Pre-mature labour (gestational age below 37 completed weeks).
- Post-datism (Gestation above 42 weeks)
- Discrepancy between uterine size and dates.
- Multiple pregnancy
- Presenting part other than cephalic
- Co-existing maternal diseases such as pre-Eclampsia (PET), Anaemia, diabetes chronic hypertension or chronic renal disease.
- Obvious foetal risk factors e.g Antepartam hemorrhage (APH), oxytocin drug use, contracted pelvis (CPD), Cord prolapse/Presentation
- Previous scars
- Mental disability

PROCEDURE.

Those patients who fitted into the inclusion criteria and were willing to participate after counseling by the investigator were recruited into the study. For those admitted without foetal distress but later developed foetal distress provided they had satisfied the inclusion criteria and were willing to participate, were also included in the study.

Then the patient gave an informed written consent and the investigator quickly administered an open and closed-ended questionnaire privately in a face-to-face encounter with the patient while pre-operative procedures were being carried out. Any mother who declined to participate was assured of continued services. Intra-operative findings at caesarean sections' were recorded.

The colour of liquor was recorded as clear or meconium stained liquor grade I (MSL-I) for light staining, or MSL II- moderate staining (translucent in a glass test tube), or MSL III - for thick meconium (equivalent of spinach paste).

The presence or absence of cord entanglement, , the number of wrappage (loops) around the foetal neck and other body parts were recorded. The infant was subjected to APGAR scoring at 1 minute and five minutes, the sex of newborn, birth weight in grams and the umbilical cord length measurement recorded. Those admitted to newborn unit were followed up for 48 hours and their admission status or outcome recorded accordingly.

DATA COLLECTION, PROCESSING AND ANALYSIS

The data was recorded in the questionnaire, analyzed using appropriate standard statistical methods. The significance of differences between the variables was assessed using the chi-squared (χ^2) test. A P-value of 0.05 or less signified significant difference between the variables of interest.

SAMPLE SIZE DETERMINATION

In his study, Karanja (23) found that foetal distress accounted for 24% of all primary caesarean section at Kenyatta National Hospital. Based on this, the sample size for this study was calculated using the Woolson’s formula as follows;

$$\text{Sample Size } n = \frac{Z^2 (P)(1 - P)}{\delta^2}$$

Where n=desired sample size.

Z = 1.96 (a factor obtained from the normal distribution table in connection with the setting up to a 95% confidence interval)

P = 24% = 0.24 (incidence of foetal distress in primary caesarean section according to Karanja (23))

δ = 0.05 (confidential interval, 95%)

$$= \frac{1.96^2 \times 0.24 \times 0.76}{0.05^2}$$

$$n = 280.28314$$

The minimum sample size was therefore 280.


ETHICAL CONSIDERATIONS

- a) The study commenced after permission was granted by Kenyatta National Hospital Ethics and Research Committee (KNH – ERC).
- b) The information was obtained in confidence and used for the purpose intended and not to incriminate or harm anyone.
- c) Each mother was explained the nature of the study and an informed written consent obtained.

RESULTS

A total of 283 patients with foetal distress had emergency caesarean section performed at Kenyatta National Hospital between February and July 2004. Foetal distress accounted for 29.6% of all caesarean section deliveries done at KNH during the study period.

Fig. 1: Foetal Distress: Prevalence of cord entanglement



One hundred and thirty cases were found to have cord entanglement representing 45.9% of all foetal distress cases that underwent emergency caesarean section delivery during the period mentioned above.

Description of study population: Maternal characteristics

Table 1: Age distribution

Age in Years	Cord entanglement present			
	YES		NO	
	Frequency	%	Frequency	%
≤ 19	12	9.2	12	7.8
20 – 24	41	31.5	57	37
25 - 29	49	37.7	57	37
30 -34	18	13.8	18	11.7
≥ 35	10	7.8	10	6.5
Total	130	100	154	100

Women in the 20 – 29 year age group accounted for 69.2 % of those with foetal cord entanglement and 74% of those without cord entanglement. There was no statistical significance between the maternal age and the presence of foetal cord entanglement. (P=0.616).

Table 2: Parity Distribution

Number of previous pregnancies	Cord entanglement present			
	YES		NO	
	Frequency	%	Frequency	%
0	70	53.8	82	53.5
1	28	21.5	43	27.5
2	18	13.8	20	13
3	10	7.7	6	4
≥ 4	4	3.2	3	2
Total	130	100	154	100

Primigravidae were the majority (53.8%) among women with foetal cord entanglement compared to 53.5% of those without cord entanglement. Women of parity above 4 represented 3.2% of those with cord entanglement compared to 2% of those without cord entanglement. The association between presence of foetal cord entanglement and different parities was found not to be statistically significant (Parity ≤ 2 and ≥ 3 , P-value = 0.931).

Table 3: Educational background

Educational level	Cord entanglement present			
	YES		NO	
	Frequency	%	Frequency	%
None	3	2.3	2	1.3
Primary	46	35.4	59	38.3
Secondary	45	34.6	41	26.6
Tertiary	36	27.7	52	33.8
Total	130	100	154	100

Women with an educational background beyond primary level represented 62.3% of those with foetal cord entanglement compared to 64.9% of those without cord entanglement. However, there was no statistical significance noted between foetal cord entanglement and maternal educational background. (P-value=0.417).

Table 4: Marital status

Marital status	Cord entanglement present			
	YES		NO	
	Frequency	%	Frequency	%
Single	22	16.9	14	9.1
Married	108	83.1	140	90.9
Total	130	100	154	100

Single women represented 16.0% of those with foetal cord entanglement compared to 9.1% of those without cord entanglement.

Married women represented 83.1% of those with foetal cord entanglement compared to 90.9% of those without cord entanglement. The association between the presence of foetal cord entanglement and the maternal marital status was found not to be statistically significant (P-value=0.912).

Table 5: Nature of employment

Nature of employment	Cord entanglement present			
	YES		NO	
	Frequency	%	Frequency	%
Employed	39	30	46	29.9
Self-employed	24	18.5	22	14.3
Unemployed	18	13.8	8	5.2
Housewife	49	38.7	78	50.6
Total	130	100	154	100

Mothers who were either employed or self employed represented 48.5% of those with foetal cord entanglement and 44.2% of those without cord entanglement. The association between the presence of foetal cord entanglement and the maternal nature of employment was found not to be statistically significant (P-value=0.995).

Description of study population: Infant characteristics

Table 6: Foetal outcome: Sex of Newborn

Sex of Newborn	Cord entanglement present			
	YES		NO	
	Frequency	%	Frequency	%
Male	62	47.7	83	53.9
Female	68	52.3	71	46.1
Total	130	100	154	100

The results in table 6 above shows that 52.3% of infants with cord entanglement were females while 47.7% were males. The association between sex of newborn and the presence of cord entanglement was found not to be statistically significant (P-value=0.371).

Table 7: Foetal outcome: Birth weight

Birth weight in grams	Cord entanglement present			
	YES		NO	
	Frequency	%	Frequency	%
< 2500	17	13.1	10	6.5
2501 – 3500	99	76.2	99	64.3
> 3500	14	10.7	45	29.2
Total	130	100	154	100

The results in table 7 above shows that the majority (89.3%) of newborns with cord entanglement weighed less than 3500 grams compared to 70.8% of those without cord entanglement. Foetal cord entanglement was associated with infants of lower birth weight. The association between foetal cord entanglement and birth weight was found to be statistically significant (P-Value=0.002)

Table 8: Foetal outcome: Umbilical Cord length

Umbilical cord length in CM	Cord entanglement present			
	YES		NO	
	Frequency	%	Frequency	%
< 40	3	2.3	16	10.4
40 – 70	79	60.8	117	76
> 70	48	36.9	21	13.6
Total	130	100	154	100

The results in table 8 above, shows that 36.9% of umbilical cords that entangled were over 70 cm long compared to 13.6% of those without cord entanglement. Only 2.3% of umbilical cords less than 40 cm long entangled. Foetal cord entanglement was associated with longer cords and this was found to be statistically significant (P-Value = 0.0004).

Table 9: Sites of cord entanglement

Sites of cord entanglement	Frequency	%
Neck	117	90
Upper limb	1	0.8
Lower limb	1	0.8
Trunk	6	4.6
Multiple	5	3.8
Total	130	100

The results in table 9 above shows that the majority (90%) of cord entanglement occurred around the neck and least around the limbs (1.6%).

Table 10: The number of cord wrappage around the foetal neck only

No. Of wrappage	Frequency	%
Single	93	79.5
Double	21	17.9
Triple	2	1.7
More than triple	1	0.9
Total	117	100

The results in table 10 above shows that 79.5% of umbilical cord wrappage (encirclage) round the foetal neck occurred once (single loop), thus making it the most frequent site for encirclage.

Table 11: Foetal heart rate pattern

Foetal heart rate pattern	Cord entanglement			
	YES		NO	
	Frequency	%	Frequency	%
Normal	41	31.5	76	49.4
Abnormal	89	68.5	78	50.6
Total	130	100	154	100

Abnormal foetal heart rate pattern was present in 68.5% of cases with foetal cord entanglement compared to 50.6% in those without cord entanglement. The association between abnormal foetal heart rate pattern and the presence of foetal cord entanglement was found to be statistically significant (P-value=0.011).

Table 12: Meconium staining of liquor

Colour of Liquor	Cord entanglement			
	YES		NO	
	Frequency	%	Frequency	%
Clear	7	5.4	12	7.8
MSL	123	94.6	142	92.2
Total	130	100	154	100

Meconium stained liquor was present in 94.6% of cases with foetal cord entanglement and in 92.2% of those without cord entanglement. The association between Meconium staining of liquor and the presence of foetal cord entanglement was found not to be statistically significant (P-value=0.593).

Table 13: Foetal outcome via APGAR score at 1-minute

APGAR score at 1-minute	Cord entanglement			
	YES		NO	
	Frequency	%	Frequency	%
0 – 3	8	6.2	5	3.2
4 – 6	66	50.8	36	23.4
7 - 10	56	43	113	73.4
Total	130	100	154	100

Interpretation of APGAR scores

- Low APGAR score <7
- Good APGAR score \geq 7.

The results in table 13 above shows that 57% of the infants with cord entanglement had low APGAR score at 1-minute while only 26.6% of those infants without cord entanglement had low APGAR score at 1-minute. Foetal cord entanglement was associated with low APGAR score at 1-minute and this was found to be statistically significant (P-value 0.000 < 0.001).

Table 14: Foetal outcome via APGAR score at 5 – minutes

APGAR score at 5 -minutes	Cord entanglement			
	YES		NO	
	Frequency	%	Frequency	%
0 – 3	1	0.8	0	0
4 – 6	36	27.7	8	5.2
7 - 10	93	71.5	146	94.8
Total	130	100	154	100

The results in table 14 above shows that 28.5% of infants who had foetal cord entanglement, had low APGAR score at 5-minutes. Only 5.2% of those without cord entanglement had low APGAR score at 5-minutes. Foetal cord entanglement was associated with lower APGAR score at 5-minutes and this was found to be statistically significant ($P\text{-value}=0.000 < 0.001$).

Table 15: Foetal outcome: Admission to newborn unit (NBU)

Admission to newborn unit	Cord entanglement			
	YES		NO	
	Frequency	%	Frequency	%
Admitted to NBU	35	26.9	6	3.9
Not admitted to NBU	95	73.1	148	96.1
Total	130	100	154	100

The results in table 15 above, demonstrates that 26.9% of infants who had cord entanglement were admitted to newborn unit after delivery. Only 3.9% of those infants without cord entanglement were admitted to newborn unit.

Foetal cord entanglement was associated with more admissions to the newborn unit and this was found to be statistically significant ($P\text{-value} < 0.001$).

Table 16: Outcome of newborn unit admissions: 48 hours later

Newborn unit admission outcome: 48 hours later	Cord entanglement			
	YES		NO	
	Frequency	%	Frequency	%
Discharged	20	57.1	4	66.7
Still admitted	10	28.6	2	33.3
Died	5	14.3	0	0
Total	35	100	6	100

Of the 35 infants who had cord entanglement and admitted to newborn unit due to low APGAR scores, 28.6% of these infants were still admitted 48 hours later while 5 infants had died. Only 33.3% of those infants without cord entanglement were still admitted 48 hours later and none had died.

DISCUSSION

From this study, it is evident that the maternal age does not have a bearing on the presence of foetal cord entanglement. Women in the 20 – 29 age group accounted for 69.2% of those cases with foetal cord entanglement compared to 74% of those cases without cord entanglement. Women above the age of 35 years represented 7.8% of those with foetal cord entanglement and 6.5% of those without cord entanglement. The difference was not statistically significant (P-value=0.616).

Generally, the majority of mothers in this study were of low parity. Women of parity less than two accounted for 74.3% of those with cord entanglement compared to 81% of those without cord entanglement. However, the association between foetal cord entanglement and parity was not statistically significant (P-value=0.931).

This study revealed no relationship between maternal educational background and the foetal cord entanglement. Women with no education background accounted for 2.3% of those with foetal cord entanglement and 1.3% of those cases without cord entanglement. The difference was not statistically significant (P-value=0.417).

Single women with foetal cord entanglement represented 16.9% compared to 9.1% of those cases without cord entanglement. Married women represented 83.1% of those with cord entanglement compared to 90.9% of those without cord entanglement. Despite the difference, there was no statistical significance between the marital status and presence of foetal cord entanglement (P-value=0.912).

Only 10.7% of newborns weighing over 3500gms had cord entanglement compared to 88.3% of those weighing less than 3500gms.

The difference was statistically significant (P-value=0.002). Sherer and colleagues (1996) observed decreased foetal activity with diminished amniotic volumes and a restricted intra-uterine space. They suggested that this might physically limit foetal activity (18). At term, the amniotic fluid volumes declines and a large foetus will have limited intra-uterine space and hence reduced foetal activity. Based on these observations, a heavier foetus at term will have reduced activity and therefore has a less chance of cord entanglement than those with lower weight.

Of those newborns with cord entanglement, 36.9% had longer cords measuring over 70cm and only 2.3% had shorter cords measuring less than 40cms. The longest cord was 89cm long and it's instructive that it had three loops around the neck plus one around the trunk. Cord entanglement was associated with longer cords and this was found to be statistically significant (P-value = 0.0004). This agrees with Ataya (1996) who found that cases of cord prolapse and cord entanglement were associated with longer cords - 25% of the cases (28).

Researchers still wonder what regulates the length of the umbilical cord. Muller (33) in his study published evidence that tension applied to the cord by foetal activity influences its length. In fact excessive cord length may be a consequence of foetal cord entanglement (18).

In Indonesia, Sarwano determined that male infants had significantly longer cords than the females and that the rise of cord complications increased parallel to cord length (34). However, this study found that more females (52.3%) had cord entanglements compared to 47.7% in the males but this was not statistically significant (P-value=0.371).

In this study, the umbilical cord was found to be more frequently coiled (encirclaged) around the neck (90%) than the other foetal parts. One loop of the cord around the neck was present in 79.5%, double loops in 17.9%, triple loops in 1.7% and more than triple loops in 0.9%. This made the foetal neck the commonest site for cord entanglement and single cord encirclage to be the most frequent

Melennan and colleagues (27) did a study that looked at the outcomes of pregnancies complicated by cord entanglement. Of the 8565 deliveries (whether vaginal or abdominal), a single loop of cord around the foetal neck was found in 2191 (25.6%) and double loops in 326 (3.8%). In a similar study, Clayton and colleagues, demonstrated single loops around the foetal neck in 21%, double loops 2% and triple loops in approximately 0.2% of the cases (26).

They also observed that for triple loops, the cord was usually longer than 70cm. In this study, only one case of triple loop was found and the cord measured 89cm long. The findings from both studies by Melennan and Clayton correlate well with the findings of this study.

Identification of foetal distress based upon foetal heart rate pattern is imprecise and controversial (3). Dellinger and colleagues (2000) analyzed intrapartum foetal heart rate patterns and the foetal outcomes. They observed that foetal acidemia and admission to neonatal intensive care nursery were significantly related to abnormal foetal heart rate pattern. They concluded that foetal heart rate characteristics can be used to identify a normal and severely compromised foetus (16).

In this study, abnormal foetal heart rate pattern was present in 68.5% of cases with foetal cord entanglement compared to 50.6% of those without cord entanglement. There was statistical significance between abnormal foetal heart rate patterns and foetal cord entanglement (P -value=0.011). These findings correlate with those of Dellinger and colleagues. Typically, as labour progresses and the foetus descends into the birth canal, contractions compresses the cord vessels which cause foetal heart rate decelerations that persists until the contraction ceases. Hankins and colleagues (1987) reported on pregnancies in which labour at term was complicated by a nuchal cord and compared with control infants; those with nuchal cord had more decelerations than those without (20% versus 5%). They also observed that those with nuchal cord were more likely to have lower umbilical artery PH (18).

Meconium stained liquor was present in 94.6% of those cases with foetal cord entanglement compared to 92.2% of those without cord entanglement. However, the difference was not statistically significant (P -value=0.593). The significance of the passage of meconium stained liquor is still fraught with controversies. Obstetrical teaching throughout the century has included the concept that meconium passage is a potential warning of foetal asphyxia. Williams (1903) observed that "a characteristic sign of impending asphyxia is the escape of meconium" (13). Others believe that the passage of meconium without foetal heart rate abnormalities is not a sign of foetal compromise. Proponents of this opinion include Fenton and colleagues who in their study concluded that the passage of meconium takes significance only when associated with other classical clinical signs (abnormal foetal heart rate patterns) of foetal distress. They observed that "the passage of meconium in the absence of any change in the foetal heart rate pattern is clearly not a sign of foetal distress" (14).

However, Miller and colleagues (11) proposed that reflex vagal stimulation of the foetal gut following sporadic or repetitive cord compression may result in relaxation of the anal sphincter with meconium passage as ultimate consequence. Fongoh (1984) observed that light meconium staining of liquor was of lesser prognostic significance in all stages of labour but thick meconium staining in early labour carried particularly ominous neonatal prognosis – agreeing with those who consider meconium passage as a bad prognostic sign (15). The results from this study did not demonstrate statistical significant between the association of foetal cord entanglement and the passage of meconium.

In this study, 57% of infants with cord entanglements had lower APGAR scores (<7 out of 10) at 1-minute. Only 26.6% of infants without cord entanglements had lower APGAR score at 1-minute. The difference was statistically significant (P-value $0.000 < 0.001$). Similarly, 28.5% of infants who had cord entanglements were associated with low APGAR score at 5-minutes. Only 5.2% of infants without cord entanglements were associated with low APGAR scores at 5-minutes. Foetal cord entanglement was associated with low APGAR scores at both 1 and 5-minutes, and this was found to be statistically significant (P-value $0.000 < 0.001$).

Normally as labour progresses, the foetus descends into the birth canal, the loop(s) of the cord may become tighter and may produce sufficient compression of umbilical cord vessels thus impairing foetoplacental blood flow. If prompt and decisive intervention is not undertaken, this may result into foetal distress and subsequently an asphyxiated infant upon delivery as evidenced by lower umbilical artery PH and/or lower APGAR scores. Rarely, a stillbirth or a neonatal death may occur (4,18).

Twenty six point nine percent of the newborn with cord entanglement were admitted to newborn unit while only 3.9% of those without cord entanglement were admitted. The association between foetal cord entanglement and admission to newborn unit was found to be statistically significant (P-value $0.000 < 0.001$). Infants who had cord entanglement and admitted to newborn unit, 28.6% were still admitted 48 hours later compared to 33.3% of newborns without cord entanglement. The main reason for admission in both groups was respiratory distress, asphyxia and meconium aspiration.

Five infants among those with cord entanglement died within 48 hours post partum while none had died among those without cord entanglement. Overall, it was observed that both morbidity and mortality was high among infants who had cord entanglement than those without cord entanglement.

These findings demonstrate that foetal cord entanglement is associated with increased incidence of early neonatal morbidity and mortality (P-value <0.001). Similarly, Naeye (1987) illustrated that cord entanglement may be an important cause of foetal distress and stillbirth (35).

CONCLUSIONS

1. Foetal cord entanglement was common among patients undergoing emergency caesarean section due to foetal distress.
2. Maternal age, educational background, marital status and parity were not identified as risk factors for foetal cord entanglement.
3. Increased umbilical cord length was identified as a major risk factor for cord entanglement.
4. Foetal cord entanglement was associated with low APGAR scores at 1 and 5-minutes.
5. Abnormal foetal heart rate pattern was identified as an important sign of cord entanglement.
6. Foetal cord entanglement was associated with an increased incidence of early neonatal morbidity and mortality.

RECOMMENDATIONS

1. There is need for increased foetal surveillance in patients with foetal distress especially where cord entanglement is suspected. To achieve this, the hospital should strongly consider introducing a cardiotocographic monitor.
2. Early intervention for patients with foetal distress
3. Infants borne to mothers with foetal distress due to cord entanglement should be treated more intensively after delivery.

References

1. Lacro R V, Jones K L, Benirschke K
The umbilical cord twist: origin direction and relevance
AM J. Obstet. Gynaecol 1987; 157: 833-838.
2. Loo, J A, Cox MJ, Karchmer E J et al
The prediction of intrapartum foetal metabolic acidosis by foetal heart rate monitoring
AM J. Obstet Gynaecol 1981; 139: 299
3. Cunningham F G, Gant F N
Antepartum assessment
In: Williams Obstetrics, 21st edition, McGraw-Hill publications, 2001; PP 1096-1108.
4. Dutta D C
Diseases of the foetus and the newborn
In: Textbook of Obstetrics, 5th edition, New Central Book publishers, 2001; PP 502-511.
5. Liewellye J
Foetal distress
In: Fundamentals of Obstetrics and Gynaecology, 3rd edition, Blackwell Scientific publications, 1982; PP 214 – 216.
6. Zallar R W, Quilligan E J
The influence of scalp sampling on caesarean section rate for foetal distress
AM J. Obstet. Gynaecol 1979; 135: 239
7. Carez L, Winker M D
Neonatal complications as related to degree of umbilical artery acidemia
AM J. Obstet. Gynaecol 1999; 164 (2): 637

8. Sykes C S
Do APGAR scores indicate asphyxia?
The Lancet 1982; 1:494

9. Mohammed K, Kasule J, Mulambo T et al
Interpretation of foetal heart rate monitoring
Central Africa Journal of Medicine 1992; 12: 38

10. Fujikura T, Klionsky R
The significance of meconium staining
AM J Obstet Gynecol 1975; 121: 45

11. Miller F, Sacks D A, Paul R H
The significance of meconium during labour
AM J Obstet Gynecol 1975; 122: 573

12. Mati J K G, Aggarwal NP, Sangvi H C G
Nairobi birth survey III: Labour and delivery
J. Obstet Gynecol, East and Central 1983; 2: 47.

13. Nathan L, Leveno K J, Carmody T J et al
Meconium: A 1990s perspective on an old obstetric hazard
AM J Obstet Gynecol 1994; 83: 328.

14. Fenton A N, Steer G M
Foetal distress
AM J Obstet Gynecol 1962; 83: 354.

15. Fongoh F B
Foetal outcome with meconium staining of amniotic fluid in labour at KNH
M Med Thesis, University of Nairobi, 1984

16. Dellinger E H, Boehm F H, Crane M M
Electronic foetal heart monitoring: Early neonatal outcomes associated with normal rate, foetal distress and foetal stress
AM J Obstet Gynecol 2000; 182: 214-220.
17. Goodlin R C, Haesslein H C
When is it foetal distress?
AM J Obstet Gynecol 1997; 128: 440-445.
18. Eduardo H, Martin L P
Complications of labour and delivery
In: Current Obstetrics and Gynaecologic Diagnosis and Treatment, 8th edition, Appleton and Lange, 1994; PP 516 – 519.
19. Platt L, Vinzileos A, Basket T et al
Further experience with the foetal biophysical profile
J Obstet. Gynaecol 1983; 60: 480
20. National Centre for Health Statistics; USA
Maternal and infant health data 1991; vol 42, No. 11: 49
21. Mati J K G, Aggarwal N P, Lucas T et al
Nairobi Birth survey: Foetal distress
Journal of Obstetric and Gynaecology for East and Central Africa, 1982; 14: 132.
22. Taffel S M
Caesarean delivery in the United States
Vital health statistics 1994.
23. Karanja J G.
A review of caesarean section deliveries at Kenyatta National Hospital
M. Med. Thesis, University of Nairobi, 1982

24. Muriu F K J
A retrospective Study on Caesarean Section Pattern at Kenyatta National Hospital
M. Med. Thesis, University of Nairobi, 1991.
25. Gathinji I E
Foetal distress managed by caesarean section
M. Med. Thesis, University of Nairobi, 1977.
26. Clayton C S, Lewis T S
Umbilical cord in Obstetrics
AM J. Obstet Gynecol 1978;12:413.
27. McLennan H, Price E, Craig N
Umbilical cord knots and encirclements
AM. J. Obstet Gynecol 1988;28:116-119.
28. Ataya Willie M
A study to determine the length of the umbilical cord in relation to obstetric outcome at KNH
M. Med. Thesis, University of Nairobi, 1996.
29. Ramin K D, Leveno K J, Kelly M S
Amniotic fluid meconium: Foetal environmental hazard
AM. J. Obstet Gynecol 1996;87:181.
30. Kruger K, Hallberg B, Blennow M, et al
Predictive value of foetal scalp blood lactate concentration and PH as markers of Neurological disability
AM J. Obstet Gynecol 1999;181:1072.
31. Richmond S
The Obstetric management of foetal distress and its association with cerebral palsy
J. Obstet Gynecol 1994;5:83-85.

32. Cunningham F G, Gant E N

Diseases and injuries of foetus and newborn

In: Williams Obstetrics, 21st edition, McGraw-Hill publications, 2001;
PP 1049-1082.

33. Muller M E, Jones M C, Smith D

Tension: The basis of umbilical length

J Paed. 1982; 101: 884.

34. Sarwono E

Umbilical cord length and intrauterine well being

J Paed. (Indonesia) 1991; 31: 136-140.

35. Naeye R L

Functionally important disorders of the placenta, umbilical cord, and foetal membranes

Hum. Pathol. 1987; 18: 680.

GYNAECOLOGY SHORT CASES

Case No. 1

ENDOMETRIOSIS – CONSERVATIVE SURGICAL THERAPY

Name:	M.W.	Parity:	0+0
Age:	25 years	DOA:	14.04.04
IP NO:	0560540	DOD:	24.04.04

Presenting Complaints

The patient presented with complaints of lower abdominal pains on and off for one year.

History of presenting illness.

The patient had been well until about one year prior to the admission when she developed lower abdominal pains that was intermittent but no associated vomiting. She had no urinary symptoms and had normal bowel habits.

Past medical/ surgical history

The patient was admitted in surgical ward at KNH due to a left breast lump in February, 2004. The lump was removed and subsequent histology showed a fibroadenoma.

Obstetric and gynaecologic history

She was a 25years old nulliparous lady who had menarche at the age of 13 years. Her last menstrual period was on 12/4/2004. Her menses lasted 3 to 5 days, of normal flow, recurred after 26 days and were regular. However, she had severe pre-menstrual, intra-menstrual and post-menstrual abdominal pains since the age of 13 years. She had never had sexual intercourse (that is, she was a virgin).

She had no history of contraception.

Family Social History

She was single, unemployed and stayed at home in Embu. She neither smoked cigarettes nor consumed alcohol. She had no family history of chronic illnesses.

Physical Examination

General Examination

She was a young lady, in good nutritional status and in fair general condition. She was not pale, not jaundiced, afebrile, no peripheral oedema and no lymphadenopathy .

Vital signs: -

- Blood pressure – 110/60mmHg
- Pulse rate - 80/minute, regular and good volume
- Respiratory rate – 18/minute
- Temperature – 36.8°C

Abdominal examination

The abdomen was not distended and moved with respiration. She had tenderness on the right iliac fossa but no guarding and no rebound tenderness. There was no palpable mass.

The liver and spleen were not palpable.

Vaginal Examination

She had normal external genitalia. On inspection of the introitus, she had features consistent with virginity.

Rectal Examination

She had a right adnexal mass which was tender but difficult to determine the size. The uterine size was normal and the left adnexa was free. There was tenderness on the pouch of Douglas but no mass was palpable.

There was no blood or discharge on the gloved examination fingers.

Other Systems

The cardiovascular, central nervous and respiratory systems were essentially normal.

Diagnosis

An impression of right adnexal mass – probably an ovarian tumour was made..

Investigations

7) Pelvic Scan – the scan showed a uterus of normal size, shape and normal endometrial stripe. There was a large right adnexal mass with mixed echogenic picture and measured 9.4 x 4.3cm .

The left ovary was normal and the pouch of Douglas was clear.

Conclusion: Right adnexal mass; probably an ovarian tumour.

2) Total blood count –

- WBC – $6 \times 10^9/L$
- Haemoglobin - 16.3 g/dL
- Haematocrit 48.9%
- Platelets $299 \times 10^9/L$
- RBC – $4.04 \times 10^{12}/L$

10) Urea and electrolytes

- Sodium – 141 mmol/L
- Potassium – 4.0 mmol/L
- Urea – 2.9 mmol/L
- Creatinine – 75 $\mu\text{mol}/L$

11) ELISA (HIV) – Negative.

Management

The patient was explained the nature of the working diagnosis and the intended management options of an ovarian mass intra-operatively. She gave an informed written consent. Blood sample was taken for grouping and cross matching, and two units of blood availed for the operation. She was starved from midnight. On the morning of the operation. She was pre-medicated with Atropine Sulphate 0.6mg and Pethidine 100mg intramuscularly 30 minutes before theatre.

Operation

In theatre, the patient was placed supine on the operating table and general anaesthesia induced. She was placed in semi-lithotomy position, vulva and perineum cleaned, and aseptically catheterized with 30mls of clear urine being obtained. Examination under anaesthesia confirmed the earlier findings in the ward.

The abdomen was cleaned and draped. The abdomen was opened through subumbilical midline incision. On exploration, the patient was found to have bilateral ovarian cysts that were chocolate coloured (endometriomas). The right cyst was 6 x 6cm and the left was 6 x 4cm.

There were thick multiple fibrous adhesions that extended and obliterated the pouch of Douglas. The uterus was adherent to the rectum posteriorly. The right fallopian tube was adherent to the right ovary. The left tube was normal. The uterus was grossly normal in size and shape but covered with multiple adhesions. Most of the adhesions were separated as safely as possible and with the aim of trying to restore the pelvic anatomy. The right fallopian tube was released from the right ovary. The ovarian endometriomas were marsupialized and cauterized thus preserving both ovaries. There were no other identifiable endometriotic lesions. Peritoneal lavage was done and the abdomen closed after a reported correct count of swabs, needles and instruments. The general anaesthesia was reversed successfully. Average blood loss was estimated at 200mls. The ovarian and endometrioma tissues were taken for histology.

Post – operative care

The patient had quarter- hourly observations in the recovery room until she was fully awake and then 4 hourly after being transferred to the ward. She received intravenous normal saline alternating with 5% dextrose, 500mls 6 hourly until the bowel sounds were heard. She also received intravenous crystalline penicillin 2 mu 6 hourly, gentamycin 80mg 8 hourly and intramuscular pethidine 100mg 8 hourly for 48 hours. She was started on oral sips on the first post-operative day and light diet on the second day. She was converted to oral ampiclox 500mg 4 times daily and oral mefenamic acid 500mg three times daily for five days.

She was discharged on the 4th post-operative day and booked for review in the GOPC after 2 weeks.

Follow-Up

She never turned up for review and therefore was lost to follow-up.

Histology report

The histology revealed endometrial tissue with both glands and stromal tissue, necrotic tissue areas of haemorrhage and normal ovarian tissue.

Conclusion: Features consistent with ovarian endometriosis.

Discussion

The patient presented was a 25 years old nulliparous woman who had presented with lower abdominal pains that were more severe just before, during and after menses. On examination, she had a right adnexal mass that was also confirmed by pelvic scan. The pre-operative diagnosis was a right ovarian tumour but intra-operatively, she was found to have bilateral ovarian endometriosis. The diagnosis of endometriosis was confirmed on histology.

Endometriosis is defined as the presence of endometrial tissue (glands and stroma) in sites other than uterine mucosa (1,2). Endometriosis is not a neoplastic condition, although malignant transformation is possible (1). These ectopic endometrial tissues may be found in the myometrium when its called endometriosis internal or adenomyosis.

Although endometriosis can occur at any site, it is usually confined to the abdominal structures below the level of umbilicus (2). The common structures involved in order of frequency are ovary, pouch of Douglas, uterosacral ligaments, broad ligament, rectovaginal septum, rectum and pelvic lymph nodes. The rare sites include the gut, appendix, ureter and urinary bladder. Common extra-abdominal sites include abdominal surgical scars, episiotomy scar, umbilicus, vagina and cervix. Remote sites are the pleura, lungs, deep tissues of arms and thighs (1,2,3).

The patient presented had pelvic endometriosis involving the ovaries and the pouch of Douglas.

Endometriosis is predominantly found in women of reproductive age but has been reported in adolescents and post-menopausal women receiving hormonal replacement therapy (1,3). The exact prevalence of endometriosis is unknown because surgery is required for diagnosis but it is estimated to be present in 10% in women of reproductive years. However, prevalence is high amongst the infertile women as based on diagnostic laparoscopy and laparotomy, ranging between 30 to 40% (2,3).

Although endometriosis occurs in women of all ethnic and social groups, its common in Caucasians especially those of higher socio-economic status and who have postponed child bearing (2,3). Locally, the prevalence of endometriosis is unknown but it is still quite rare.

The patient presented was a 25 years old African female in her reproductive age.

The cause of endometriosis is unknown. Several theories have been offered to explain its occurrence, but none has satisfactorily explained all of the features of the disease.

The principal theories are (1,2,3): -

1. Transplantation theory: - It was originally proposed by Sampson in the mid-1920's and it is based on the assumption that endometriosis is caused by the seeding or implantation of endometrial cells by transtubal regurgitation during menstruation (retrograde menstruation). Retrograde menstruation occurs in 70 to 90% of women and it is thought to be more common in women with endometriosis than in those without the disease. The presence of endometrial cells in the peritoneal fluid, indicating retrograde menstruation, has been reported in 55 to 79% of women during menses. Although retrograde menstruation may explain the presence of endometriosis in the dependent portions of the pelvis (the ovaries, anterior and posterior *cul-de-sac*, uterosacral ligaments, posterior uterus and broad ligaments), it fails to explain the endometriosis at distant sites.
2. Coelomic Metaplasia: - this involves the metaplasia of the coelomic epithelium into endometrial tissue. The metaplasia theory postulates that mullerian tissue remnants may persist and get trapped within the peritoneum and under the influence of cyclic hormonal stimulation by the ovary they undergo transformation (metaplasia) into an endometrial tissue. This theory can explain endometriosis of the abdominal viscera and the rectovaginal septum but cannot explain endometriosis of extrapelvic location.
3. Direct implantation theory: - according to this theory, the endometrial or decidual tissues may grow in susceptible individuals when implanted in new sites. The new sites include; abdominal surgical scar following hysterectomy, caesarean section and myomectomy. Others are episiotomy scar, vagina and cervix. However, this theory fails to clarify endometriosis at sites other than these mentioned.
4. Lymphatic and vascular theory: - this theory postulates that normal endometrial tissue may metastasise the pelvic lymph nodes through the lymphatic channels of the uterus while the vascular spread may explain endometriosis at sites such as lungs, arms or thighs.

5. Genetic and immunological theory: - Genetic basis of endometriosis probably account for less than 10% of cases. There is increased incidence of endometriosis in first-degree relatives and multifactorial inheritance is postulated. The risk of endometriosis is 7 times greater if a first degree relative has been affected. Thus it is certain that, not all cases of endometriosis at different sites can be explained by a single theory.

About 25% of patients with endometriosis are asymptomatic, being accidentally discovered either during laparoscopy or laparotomy (1,2,3,4). The symptoms of endometriosis are not related to the extent of the lesion. The symptoms are mostly related to the site of lesion and its ability to respond to the cyclic hormone stimulation (2,4).

Midline lesions are more symptom producing. The depth of penetration is more related to symptoms rather than the spread. About 50% of patients with endometriosis present with symptoms related to menstruation. These include progressively increasing secondary dysmenorrhoea. The pain starts a few days prior to menstruation, get worsened during menstruation and even persist a few days after cessation of menses. Menorrhagia is the predominant abnormality occurring in 60% of cases and there may be pre-menstrual spotting. Endometriosis is found in 15% of infertile women, whereas 40 to 60% of patients with endometriosis suffer from infertility (1,4).

The patients with endometriosis may present with deep dyspareunia that could be due to direct contact-tenderness or stretching of adhesions in the pouch of Douglas.

They may also present with pelvic pain or discomfort, lower abdominal pain or lower backache and is aggravated during menstruation. Other symptoms present and which could be cyclical include; urinary frequency, dysuria or haematuria due to bladder involvement, painful defaecation, diarrhoea, rectal bleeding or even melena stools as a result of sigmoid colon or rectum involvement (1,2,4).

The patient presented had complained of lower abdominal pain which was aggravated by menstruation. Since she was single and a virgin, she did not present with dyspareunia or infertility.

On examination, the patient may have a palpable lower abdominal mass which may be tender with restricted mobility.

Pelvic bimanually examination may reveal pelvic tenderness, nodules in the pouch of Douglas or uterosacral ligaments, fixed retroverted uterus with unilateral or bilateral masses of varying sizes (1,2,3,4). A speculum examination may reveal bluish spots in the posterior fornix while rectal examination findings may also be useful.

The patient presented had tenderness of the right iliac fossa and per-rectal examination revealed a right adnexal mass that was tender. The pouch of Douglas was also tender. Since she was a virgin, no digital vaginal or speculum examination was undertaken.

Ultrasonography, computed tomography (CT-Scan) and magnetic resonance imaging (MRI) are not so much helpful in making a diagnosis of endometriosis (1,3,4). However, they may detect ovarian cysts.

The definitive diagnosis of endometriosis can only be made at laparoscopy or laparotomy – by direct observation of the implants. The diagnosis may also need to be confirmed histological by the demonstration of endometrial glands and stroma.

The diagnosed endometriosis should be appropriately staged based on laparoscopic findings to predict prognosis, choice of therapy and to evaluate the treatment protocol.

The scoring is by the revised American fertility society which is determined by adding specific points given to each item as shown in the table below.

Revised American Fertility Society Scoring System (1985) (1,2):

Peritoneum	Endometriosis	< 1cm	1 – 3cm	> 3cm
	Superficial	1	2	4
	Deep	2	4	6
Ovary	Right: superficial	1	2	4
	Right: deep	4	16	20
	Left: superficial	1	2	4
	Left: deep	4	16	20
	Posterior <i>Cul-de-sac</i> Obliteration	<u>Partial</u> 4	<u>Complete</u> 40	
Ovary	Adhesions	< 1/3 enclosure	1/3 – 2/3 enclosure	>2/3 enclosure
	Right: filmy	1	2	4
	Right: dense	4	8	16
	Left: filmy	1	2	4
	Left: dense	4	8	16
Tube	Right: filmy	1	2	4
	Right: dense	4*	8*	16
	Left: filmy	1	2	4
	Left: dense	4*	8*	16

Note: (*): - If the fimbrial end of the fallopian tube is completely enclosed, change the point assignment to 16.

Interpretation: Stage I (minimal) score 1-5

Stage II (mild) score 6-15

Stage III (moderate) score 16-40

Stage IV (severe) score > 40

Although the patient presented was not staged, she was obviously in stage IV(severe) since she had a completely obliterated *cul-de-sac* (score of 40) and both ovarian endometrial lesions were over 3cm in diameter (score 20x2) giving a total score of 80- which falls into severe (stage IV) disease.

The management options for patients with endometriosis are dependent on symptomatology, site and size of lesions, stage of disease, patient's desire for future fertility and to some extent her age (3). The role of treatment in minimal to mild endometriosis is controversial. However, expectant management may be appropriate in patients with symptomatic disease or those with minimal or mild endometriosis. Although endometriosis is generally a progressive disease, many reports have found no evidence that treating an asymptomatic patient will prevent or ameliorate the onset of symptoms later (2,3).

In patients with mild symptoms and no desire for immediate fertility, treatment with non-steroid anti-inflammatory agents and prostaglandin synthetase inhibitors is advocated. Patients with severe symptoms or severe disease will require either hormonal or surgical therapy or a combination of both hormonal therapy and surgery. The hormonal therapy aims at suppressing the ovarian function that causes atrophy of the endometrial implants. It is best used in implants of 1cm or less and without firm adhesions (2,3).

However, hormonal therapy should be considered as suppressive rather than curative because of high recurrence rate. Hormonal therapy agents include; combined oral contraceptive pills, progestagens, danazol and analogues of gonadotrophin release hormone (GNRH). The GNRH analogues are the best for quick relief of symptoms and in reducing the size of the implants as well as improving fertility and prevention of recurrence. The fertility rate with GNRH analogue therapy is about 40% (1,2,3).

Surgical treatment is indicated in endometrial cases with severe symptoms unresponsive to hormone therapy, correct the distorted pelvic anatomy and in endometriosis of more than 1cm in diameter. Surgery can either be conservative or radical.

Conservative surgery in endometriosis includes any surgery short of removal of the uterus and preserving at least one ovary. The conservative surgery can be done by the conventional laparotomy or by laparoscopy. Surgery may involve destruction of implants by diathermy or resection of the endometriomas and division of the adhesions (1,4).

Radical surgery implies hysterectomy with bilateral salpingo-oophorectomy along with the resection of the endometrial tissues as complete as possible. It is reserved for cases with severe disease and who have attained desired family size.

Appendectomy is indicated as well because 30% of normal appearing appendices in patients with pelvic endometriosis, have microscopic endometriosis implants (1,2,3,4).

Complications of endometriosis include infertility, ovarian torsion, rupture of endometriomas with spillage of the irritant contents and may cause peritonitis. Others include intestinal obstruction, obstructive uropathy with subsequent hydronephrosis, hydronephrosis, renal infection and renal parenchymal damage. Endometrial lesions in the brain and pleural may cause epileptic seizures and pneumohaemothorax respectively. Malignant transformation is rare, the commonest being adenoacanthoma (2,3,4).

Endometriosis tends to recur even after definite surgery. The recurrence rate ranges between 5% and 20% per year, reaching a cumulative rate of 40% after 5 years. The rate of recurrence increases with the stage of the disease, duration of follow-up and occurrence after previous surgery. The likelihood of recurrence appears to be lower when endometriosis is located only on the right side of the pelvis than when the left is involved (2,3,6).

No strategies to prevent endometriosis have been uniformly successful and many believe that its prevention, currently, is not possible. However, some guidelines may be advocated to prevent or minimize endometriosis. These include avoiding tubal patency tests, such as hysterosalpingogram, immediate after curettage or around the time of menstruation and avoid forcible pelvic examination during or shortly after menstruation(4,5). These are mainly aimed at preventing iatrogenic transplantation of endometrial tissue into the peritoneal cavity.

Married women with strong family history of endometriosis are encouraged not to delay their first conception but complete their desired family size (5).

The patient presented was advised not to delay conception any further.

References

4. Thomas M.D. Joseph A.H.
Endometriosis
In: Novak's Gynaecology, 13th ed. Lippincott Williams and Wilkins, Philadelphia, 2002; page 931 – 959.

2. Dutta D.C.
Endometriosis and adenomyosis
In: Textbooks of Gynaecology, 3rd ed, New Central Agency publications, 2001; pg 284 – 296.

7. Kenneth N.M, Michael D.F.
Endometriosis.
In: Current Obstetrics and Gynaecology diagnosis and treatment, 8th edition .Appleton and Lange, 1994; pg 801 – 808.

8. Gomal V.T.
Endometriosis.
In: Telinde's operative gynaecology, 8th ed, Appleton and Lange publications, 1997; pg 530 – 548.

9. Strathy J.H, Molgaard C.A, Coulam C.B.
Endometriosis and infertility.
Fertil Steril 1982; 3 8:667 – 672.

10. Dmowski W.P, Lesniewicz R, Rana N, et al
Changing trends in the diagnosis of endometriosis.
Fertil Steril 1997; 67:238 – 243.

Case No. 2

RUPTURED ECTOPIC PREGNANCY - PARTIAL SALPINGECTOMY

Name:	R.K	Parity:	1+0
Age:	27 years	DOA:	24.04.04
IPNo:	0954717	DOD:	28.04.04

Presenting complaints

The patient was admitted with history of lower abdominal pains, vomiting, and inability to walk for 2 days.

History of presenting complaints

The patient was well until two weeks prior to the admission when she developed lower abdomen pain accompanied by vomiting and dizziness. The pain initially was colicky in nature, increasing in intensity and later became continuous. The pain could not go away with analgesics (brufen). She had vomiting episodes that were non-projectile and the vomitus consisted of what she had fed. Standing upright or bending forward worsened the dizziness. She had no urinary symptoms and the bowel habits were normal.

Obstetric and Gynaecologic history

She was para 1+0 and her last delivery was in 1998. Her last menstrual period was 12th February, 2004 giving an amenorrhea of eleven weeks and one day. She had menarche at 14 years. Her menses were regular, recurring after 28 days and lasted for 3 to 4 days. Her menstrual flow was moderate and no associated dysmenorrhoea. She had no history of contraceptive use and had never been treated for lower abdominal pain or per vaginal discharge or treated for sexually transmitted infections.

Past medical and surgical history

This was not significant.

Family and social history

She was a housewife and lived with her husband, who was a securicor guard, at Uthiru trading centre. Neither smoked cigarettes nor consumed alcohol. There was no family history of chronic illnesses.

Physical examination

She was sick looking and was obviously in pain. She was moderately pale, afebrile, not jaundiced or cyanosed and had no peripheral oedema.

Her vital signs were; blood pressure 100/70 mmHg, temperature 36⁰c, pulse rate 118/minute (low volume but regular) and respiratory rate of 18 per minute

Abdominal examination

The abdomen was slightly distended at the suprapubic region but was moving with respiration. On palpation, she had marked tenderness at the suprapubic area extending to both right and left lower lumbar regions, guarding and slight rigidity. Abdominal paracentesis done on the right side using a 10mls syringe and gauge 21 needle, yielded non-clotting blood.

Pelvic examination

She had normal external genitalia. No active bleeding was observed. The cervix was closed, long and posterior, cervical excitation test was positive and pouch of Douglas was full. The uterine size was difficult to determine due to tenderness. The adnexae were tender but difficult to palpate for masses due to the marked tenderness. The gloved examining fingers had darkish blood but no discharge.

Other Systems

Central nervous, cardiovascular and respiratory systems were essentially normal.

Diagnosis

Diagnosis of ruptured ectopic pregnancy was made.

Management

The patient and her husband were informed of the diagnosis and the intended management. She gave an informed written consent for an emergency laparotomy. An intravenous line was established using cannular size 18, blood samples for grouping and cross matching, and packed cell volume taken. Intravenous normal saline drip was commenced. The lower abdomen was shaved, patient premedicated with atropine 0.6mg intramuscularly and wheeled to theatre.

Laparotomy

In theatre, the patient was put under general anaesthesia and placed in semi-lithotomy position. Vulvovaginal toilet was done and aseptically catheterized. Approximately 40mls of clear urine was obtained. Repeat vaginal examination under anaesthesia

confirmed the earlier findings. The patient was repositioned to supine position, the abdomen cleaned and draped with sterile towels.

A subumbilical midline incision was made and the abdomen opened in layers.

Haemoperitoneum was encountered immediately, about 2000mls of unclotted blood was drained and multiple large clots were evacuated. A right fimbrial ectopic gestation was found and a long artery forceps was applied proximal to the rupture thus controlling the bleeding.

Partial salpingectomy was done with haemostasis being achieved. Other pelvic structures were inspected. The left tube had multiple peritubal adhesions that were thin and spread-out but it was patent. Both ovaries were grossly normal. The uterus was also normal.

Peritoneal toilet was done using warm normal saline. The swabs, instruments and needles' count was reported correct and the abdomen closed in anatomical layers.

General anaesthesia was successfully reversed. Blood loss was estimated at 2500mls. She was transfused one unit of blood intra-operatively.

Post-operative care

The vital signs were observed quarter hourly until the patient was fully awake and thereafter every 4 hours. She was maintained on intravenous fluids; normal saline alternating with 5% dextrose one litre every 8 hours until the bowel sounds were auscultated.

She received intravenous antibiotics; crystalline penicillin 2mu 6 hourly, gentamycin 80mg 8 hourly and metronidazole 500mg 8 hourly. She also received pethidine 100mg 8 hourly intramuscular injection to relieve pain.

Oral sips were commenced 6 hours post-operatively when bowel sounds were auscultated and normal. Her 3rd postoperative day check haemoglobin level was 8.4grams/dl and was put on haematinics. She made good progress and was discharged on the 4th postoperative day and booked for review in the gynaecology outpatient clinic after 4 weeks.

Follow-up

Four weeks later, the patient was seen at the gynaecology clinic as scheduled. She was not pale and the wound had healed well. She had not resumed her menses. She was discharged from the clinic through the family planning welfare for contraception.

Discussion

The patient presented was a 27 years old para 1+0, admitted with a diagnosis of ruptured ectopic pregnancy for which laparotomy and right partial salpingectomy was done.

The term *ectopic pregnancy* refers to the implantation and development of a fertilized ovum outside the normal endometrial lining of the uterine cavity. Implantation therefore occurs in the absence of decidualised endometrium. Tubal pregnancy is the most common type involving over 95% of all ectopic pregnancies (1,2).

The frequency of ectopic pregnancy within the locations (parts) of the tube is (1,2);

- Ampullary- 55%
- Isthmus- 25%
- Fimbrial- 17%
- Intramural (Cornu)- 2%.

Other sites for ectopic pregnancy include ovary <0.5%, abdominal <0.1%, cervical and even vaginal.

The patient presented had a tubal ectopic pregnancy located on the right fimbria.

The incidence of ectopic pregnancy varies significantly in different parts of the world. Mwathe (1984) found an incidence of 1:15 deliveries at Kenyatta national hospital while Akula (2003) found an incidence of 1:100 deliveries at Homabay district hospital (3,4). In Nigeria, Oronsanye and colleagues found an incidence of 1.7% at Benin City (5). These figures compares fairly well with an incidence of 1:100 deliveries in the United States (6).

Generally, the incidence of ectopic pregnancy has been increasing throughout the world in the last two decades. The reasons attributed to the increase include the increasing prevalence of sexually transmitted diseases, increase in the use of contraception that

prevents intrauterine pregnancies such as IUCD and low dose progestational agents, tuboplasty of infertility and unsuccessful tubal fertilization (1,2,7).

The patient presented had no history of sexually transmitted infections or contraception.

Factors implicated in the pathogenesis of ectopic pregnancy include the following (1,2,7);

- *Functional Factors* – These delay the passage of the fertilized ovum to the uterine cavity. These include external migration of the ovum, menstrual reflux, altered tubal motility, cigarette smoking and progestogens use.
- *Mechanical factors* – These may prevent or slow the passage of the fertilized ovum into the uterine cavity. These include salpingitis, peritubal adhesions, previous induced abortions, developmental abnormalities of the fallopian tube and growths that distorts the tube (s).
- *Increased receptivity* of the tubal mucosa to the zygote.
- *Failed contraception*, for example, ligated fallopian tubes.
- *Assisted reproduction*, for example, GIFT and IVF.

Ectopic pregnancy may occur any time between menarche and menopause, but 40% of these cases occur in women of ages between 20 and 29 years (2,3). Ectopic pregnancy is also commonest among women with history of previous ectopic pregnancy. Infact, 10 to 20% may have a second ectopic pregnancy and 4 to 5% of these will occur in the opposite tube (2).

The patient presented was 27 years old and with no history of previous ectopic pregnancy.

Clinical presentation of ectopic pregnancy is diverse and largely depends on the anatomical site, the gestational age and whether it has ruptured or not. It may thus, mimic many other gynaecological and surgical conditions including acute appendicitis (1,2). However, an ectopic pregnancy should be suspected when symptoms of early pregnancy (amenorrhoea, breast tenderness, nausea or vomiting) are followed by vaginal bleeding (usually spotting or dark blood) and diffuse lower abdominal pain within the first 1-8 weeks after the last missed period. The patient may experience a progressive course of faintness, exacerbation of pain (rupture or impending rupture) and shoulder pain.

Symptoms and signs of blood loss such as dizziness, sweating, restlessness, falling blood pressure, rising and low volume pulse, tachycardia and pallor may be present.

Pelvic examination may reveal cervical excitation tenderness, enlarged uterus and fullness of the pouch of Douglas or in the adnexae. Abdominal paracentesis or culdocentesis may yield non-clotting blood (2,7).

The patient presented had a history of 8 weeks amenorrhoea, nausea, abdominal pain, and dizziness and per vaginal bleeding. On examination, she had low blood pressure, rapid pulse of low volume, pallor, distended and tender abdomen. She also had positive cervical motion tenderness and fullness of the pouch of Douglas. Paracentesis yielded non-clotting blood.

In the majority of cases, the diagnosis of ruptured ectopic pregnancy is usually straightforward because of the dramatic nature of the symptoms.

However, the diagnosis of unruptured or slow leaking tubal pregnancy is less straightforward and the possibility of making the wrong diagnosis is real. Ultrasonography, laparoscopy and beta-HCG titres are useful investigative tools in diagnosing ectopic pregnancies especially in the unruptured.

Immediate surgery is indicated when diagnosis of a ruptured ectopic pregnancy is made. This will facilitate prompt control of the bleeding; remove the products of conception, blood clots, free blood and exposing the area of nidation. In this era of advanced medical diagnostic tools, such as laparoscopy and serum beta-HCG assays, it is possible to diagnose early ectopic pregnancy (8).

Conservative medical management involves methotrexate administration to eliminate the unruptured ectopic pregnancy of less than 6 weeks gestation or with a tubal mass of less than 3.5 cm in diameter. The methotrexate administration method fails in 50–100% of patients with a gestation above 6 weeks or tubal mass greater than 4cm in diameter (1,9). The national history of ectopic pregnancy suggests that majority of tubal pregnancies resolves on their own without treatment. Trio and colleagues (1995) reported spontaneous resolution of ectopic pregnancy in 73% of those patients treated expectantly. This was more likely if the initial serum beta-HCG level was less than 1000miu/ml (1).

The patient presented had immediate laparotomy because the ectopic pregnancy had already ruptured. In fact, surgery is the method of choice in management of both unruptured and ruptured tubal ectopic pregnancy at KNH currently.

On average, ectopic pregnancy is associated with a mortality rate of 1%. In the United States, the mortality rate is 1-2% and perinatal mortality of 100% (2). At KNH, Mwathe (1984) found a mortality rate of 4.7% (3). The majority of maternal deaths were due to haemorrhage. Untreated or mis-diagnosed ectopic pregnancy accounts for 8-10% of maternal deaths (7).

A subsequent (second) tubal pregnancy is said to occur in 10 – 20% of patient treated for an ectopic pregnancy and 4 to 5% of these will occur in the opposite tube (2). Secondary infertility develops in approximately 50% of patients who have undergone surgery for the treatment of an ectopic pregnancy (2,7,8). Normal pregnancy is achieved in about 50% of patients who have one ectopic pregnancy (2).

One way of reducing the prevalence of ectopic pregnancy is through prompt and vigorous treatment of salpingitis. Early diagnosis of unruptured tubal pregnancy with prompt intervention will reduce the morbidity and mortality rate associated with ruptured ectopic pregnancy.

The patient presented had both prompt diagnosis and surgical intervention, thus avoiding the mortality and morbidity associated with a ruptured ectopic pregnancy.

References

1. Cunningham FG, Norman F.G
Reproductive success and failure
In: Williams Obstetrics, 21st Ed, McGraw-Hill Publications, 2001; Pg 884 – 905
2. Alan H. Decheney, Martin L.P
Early pregnancy risks
In: Current obstetric and Gynaecological diagnosis and treatment, 8th Ed,
Appleton and Lange, 1994; Pg 314 –325
3. Mwathe E.G
Patterns of Ectopic pregnancy at KNH
M. Med Thesis, UON, 1984
4. Akula O.A
Ectopic pregnancy as seen in rural district hospital - Homabay District hospital
M. Med Thesis UON 2003
5. Oronsanye A.U, Odiase G.I
The prevalence of Ectopic pregnancy in Benin City – Nigeria
Nigeria Journal of Obstet, Gynaecol, 4:19 – 23; 1984
6. A trash H.K, Friede A, Hogues C.J
Ectopic pregnancy mortality in the United States of America between 1970 – 1983
AM J. Obstet Gynaecol, 70: 817; 1987
7. Dutta D.C
Haemorrhage in Early pregnancy
In: Textbook of obstetrics, 5th Ed, New central book Publications, 2001; Pg 190 – 206
8. Maymow R, Shulman A.
Ectopic pregnancy: Review of the modern work-up and the non-surgical treatment options
Int. J. fertile. 37: 146; 1992
9. Falk J
Methotrexate treatment of tubal pregnancy
Int. J. Ferti. 39: 197; 1994

Case No. 3

SYMPTOMATIC UTERINE FIBROIDS – TOTAL ABDOMINAL HYSTERECTOMY

Name:	JW	Parity:	6+0
Age:	42 years	DOA:	5.3.04
IP NO:	0773423	DOD:	12.3.04

Presenting Complaints

The patient was admitted with complains of lower abdominal swelling, prolonged and heavy menses for 3 years.

History of Presenting Illness

She had generally been well until the year 2000, when she discovered a swelling inside her lower abdomen and which was gradually increasing in size. The abdominal mass was associated with prolonged and heavy menses. Prior to the onset of the above, her menses lasted 3-4 days and would use 1 or 2 sanitary pads daily. However, the duration of the menses gradually increased to 10-14 days and would use upto 5 to 6 sanitary pads daily. The menses recurred every 28-30 days and associated with severe lower abdominal pain. The pain was mainly intramenstrual.

Two months prior to admission, she had frequency of micturation, dysuria and urgency, which subsided after treatment with antibiotics and analgesics. Her bowel habits were normal but had a fowl smelling vaginal discharge.

She gave no history of post-coital bleeding prior to separation from her husband and had been sexually inactive since then.

Past Obstetric and gynaecologic History

Her menarche was at 15 years. She was para 6+0 and her last delivery was in 1993. All the deliveries were by spontaneous vertex delivery. All her children were alive and well. She had never used any form of contraception.

Past Medical and Surgical History

She was a known asthmatic for the past 4 years and was on salbutamol on and off. She had no history of drug allergies.

Family and Social History

She was separated from her husband since the year 2000 after she developed the current illness. She stayed at Githunguri where she was a peasant farmer.

She neither smoked cigarettes nor consumed alcohol. She had no family history of chronic illnesses.

Physical Examination

On examination, she was found to be in fair general condition and in good nutritional status. She was not pale, afebrile and no pedal oedema. Her vital signs were; temperature of 36.8 degrees centigrade, pulse 70/minute regular and good volume, respiratory rate of 18/minute and a blood pressure of 120/70mmHg

Abdominal Examination

The patient was obese and a distended lower abdomen. She had no surgical scars. On palpitation, she had a mass arising from the pelvis corresponding to 18 weeks of gestation. The mass felt smooth, firm, non-tender, and mobile and could not go below it. There was no enlargement of the liver or spleen.

Pelvic Examination

She had a normal external genitalia and the vaginal mucosa appeared normal. The cervix was closed, firm, smooth surface and posterior. On bimanual palpitation, the uterus was enlarged, mobile, the mass moved with the cervix and cervical excitation test was negative.

Both adnexae and pouch of Douglas were free. There was no discharge or blood on the gloved examining fingers.

Other Systems

The breasts, central nervous, cardiovascular and respiratory systems were essentially normal.

Diagnosis

An impression of symptomatic uterine fibroids was made.

Investigations

- *Pelvic Ultrasound*- had shown a bulky uterus with multiple uterine fibroids, the largest measuring 47x42mm and were on the posterior uterine wall. The ovaries were normal.
- *Pap smear*- was reported normal.
- *Renal function tests*- were within normal range; urea- 3.7 mmol/L, creatinine- 77.8micromol/L, sodium-141 mmol/L and potassium -4.0mmol/L.
- Haemoglobin level-11.3g/dl, RBC- $5.05 \times 10^{12}/L$, Haematocrit-37.3%, MCH-22.2 pg, MCV- 73fl, Platelet- $392 \times 10^9/l$ and WBC- $6 \times 10^9/l$

Management

She was counseled on hysterectomy and subsequently gave an informed consent. She was starved from midnight, put on laxatives and intravenous metronidazole 1gram stat. Half an hour before being wheeled to theatre, she was premedicated with atropine 0.6mg intramuscularly.

A total abdominal hysterectomy was done as described in the introduction. The operation was uneventful. Postoperatively the patient did well. She was discharged on 5th postoperative day and for removal of stitches at her nearest health facility. She was booked for review in GOPC after 6 weeks.

Follow Up

She was seen in GOPC after 6 weeks as per appointment and she had no complaints. She was not pale and the incision site had healed well. The histology results confirmed the diagnosis of uterine fibroids.

Discussion

Fibroids are benign tumours of uterine smooth muscles. They are also referred to as fibromyomas, myomas, or leiomyomas. Histologically, the tumours are composed of smooth muscles and variable amounts of fibrous connective tissue. (1,2)

Fibroid is not only the commonest benign tumour of the uterus but also the commonest benign solid tumour in females. Leiomyomas are present in 20-25% of women in the reproductive age (1). Fortunately, most of them remain asymptomatic (2). Wanjala (1980), found that uterine fibroids accounted for 1.6% of all gynaecologic admissions and 66.7% of all hysterectomies done at Kenyatta National Hospital at that time (3).

Leiomyomas are said to be rare before the age of 20 years. They are more common in black women being 3-9 times more frequent than in white women (1,2). The prevalence is highest between the age 35-45 years (2). Indeed, by the fifth decade as many as 50% of black women will have leiomyomas. They are also more common among nulliparous or those having one child infertility (2). Wanjala (1980) found that 30% of the patients with uterine fibroids had parity of 3 and above while 85% of these women had not delivered in the past six years (3). The patient presented was a 42-year-old para 6+0, black and whose last delivery was eleven years ago.

The aetiology of leiomyomas still remains unclear. Currently, the prevailing hypothesis is that leiomyomas arises from the neoplastic single smooth muscle cell of the myometrium (2). The stimulus for initial neoplastic transformation is not known. However, the following have been implicated (2): -

- Chromosomal abnormalities – In about 30% of cases have chromosomal abnormality especially chromosome six and seven as a result of re-arrangement and deletions.
- Role of polypeptide growth factors – Epidermal growth factor (EGF), insulin-like growth factor (IGF-I) and transforming growth factor (TGF) are all thought to stimulate the growth of leiomyomas either directly or indirectly via oestrogen.
- Inheritance – Leiomyomas are more common among those with a positive family history.

While there is no evidence that oestrogen cause leiomyomas, they are certainly implicated in their growth. Leiomyomas are predominantly oestrogen-dependent tumours. Oestrogen dependency is evidenced by (1,2):-

- Growth potentiality limited during child bearing period
- Increased growth during pregnancy
- Do not occur before menarche and they regress following menopause
- Frequent association with an ovulation state
- Rapid growth observed among high dose oestrogen pill users

The patient presented had no family history of fibroids and had never used hormonal contraception.

Uterine fibroids are classified by anatomical location into submucous, interstitial (intramural) and subserous. The submucous fibroids lie beneath the serosal surface. The latter can become pedunculated and may occasionally acquire an extra-uterine blood supply from the mental vessels, its pedicle may atrophy and reabsorbed; the tumour is then said to be parasitic (1,2).

Leiomyomas mostly arise in the uterine corpus although they may also arise from the uterine cervix, ovaries, broad ligaments, vagina and vulva. The fibroids in the uterine corpus are often multiple and commonly number between 5 and 20 (4). They vary greatly in size from microscopy seedlings to fairly large ones. They are usually less than 15cm in size and may weigh over 45kg (1). Hunt (1888) reported the largest and heaviest fibroid that weighed over 65kg (4).

The patient presented had multiple intramural fibroids but measurement and weighing was not done.

The majority of fibroids remain asymptomatic-75% (2). They may be accidentally discovered by the physician during routine examinations or at laparotomy or laparoscopy for other reasons. Generally, the symptoms are related to anatomical type and the size of the tumour. The site is more important than the size (2). It's of significance to note that a small submucous fibroid may produce more symptoms than a big subserous fibroid.

Abnormal uterine bleeding is the commonest manifestation and is present in about 30% of the patients (1,2).

Bleeding is thought to be due to interruption of the blood supply to the tumour, distortion and congestion of the surrounding vessels particularly the veins or ulceration of overlying the endometrium. Most commonly, the patient has prolonged and/or heavy menses, premenstrual spotting or prolonged light spotting following menses. Infact, any type of abnormal bleeding is possible (1,2). Wanjala (1980) found menstrual disturbances to be the presenting complaint in 54.7% of the patients while 38.3% of the patients complained of an abdominal mass (3). The patient presented had a progressively increasing abdominal mass, prolonged and heavy menses.

Infertility may be a major complaint for upto 30% of patients with leiomyomas. Infertility could arise as a result of distorted or elongation of the uterine cavity, congestion and dilation of the endometrial venous plexuses thus defective nidation, atrophy and ulcerations of the endometrium over the submucous fibroid hence defective nidation or comual blockage that prevents sperms reaching the ovum (1,2,4)

Pregnancy problems related to uterine fibroids include, spontaneous abortion, preterm labour and intrauterine growth restriction. The reasons being defective implantation of the placenta (2). It's of significance to note that after myomectomy, the incidence of spontaneous abortion reduces from 40% to 20% (1). Pain is rare unless vascular compromise has occurred. Pain may result from degeneration associated with vascular occlusion, infection, torsion of a pedunculated tumour or myometrial contractions to expel a submucous myoma from the uterine cavity (1). Sarcomata's change is rare, occurring in 0.1-0.5% of diagnosed leiomyomata and is usually suspected if myoma continues to grow – after menopause (1,2,4).

Systematic manifestation of myoma includes anaemia which results from prolonged and heavy abnormal uterine bleeding. Paradoxical polycythaemia is seen in certain myomas particularly in the broad ligament. It is believed to be due to erythropoietin production by the tumour or through compression of the ureter by the tumour, which stimulates erythropoietin production by the kidney (1). A large fibroid may compress the ureter causing a hydroureter and if imparted in the pelvis it may cause urinary retention or difficulties in rectum emptying (1,2,5).

The patient presented had dysuria, urinary frequency and urgency, which was recurrent despite treatment. However these symptoms disappeared after the patient had hysterectomy.

Leiomyomata can undergo secondary degenerative changes. These include atrophy, hyaline, cystic, calcification, myxomatous and red degeneration. Red degeneration occurs most commonly during pregnancy and may cause preterm labour and rarely it can initiate disseminated intravascular coagulation (1,2,4,5).

In most cases myomas, do not require treatment especially if they are asymptomatic or if the patient is approaching menopause or is menopausal. No treatment is required for fibroids less than the equivalent of 12 weeks gestation, provided they are not growing rapidly or interfering with fertility or pregnancy. Such patients require follow up every six months.

Medical therapy has established a firm place in the management of symptomatic fibroids (2). The drugs are used either as a temporary palliation or may be used in rare cases, as an alternative to surgery. The objectives of medical treatment are (2);

- To improve menorrhagia and correct anaemia before surgery.
- To minimize the size and vascularity of the tumour in order to facilitate surgery.
- As an alternative to surgery in perimenopausal women or women with high risk factors for surgery
- Where postponement of surgery is planned temporarily

The main drugs used in medical treatment of myomas include progestogens, the gonadotrophin releasing hormone (GnRH) agonist and GnRH antagonists; which interferes with the hypothalamo-pituitary-ovarian axis hence cutting off the oestrogens required for fibroids growth.

The mode of treatment of leiomyomata largely depends on the symptomatology, patient's age, parity, general health, future fertility, size, location and state of the fibroid. Surgery is indicated if the mass becomes larger than a pregnant uterus of 14 weeks gestation. Growing cervical myomas larger than 3-4cm in diameter should be removed surgically to avoid a more difficult operative procedure in future (1,2,4,5). Pedunculated subserous fibroids are more likely to undergo torsion and should therefore be removed.

Myomectomy is the surgical procedure of choice in the patients below 40 years and who wish to retain their menstrual and reproductive function. In 15-40% of patients and about two thirds of these will require further surgical treatment (1).

Patients with desired family size are best treated by hysterectomy. Huge fibroids are equally treated by hysterectomy. Hysterectomy with removal of all leiomyomata is curative and it can either be through the vagina or abdominal route.

The patient presented was over 40 years, had a desired family size, huge fibroids (which corresponded to a pregnancy of 18 weeks gestation) and was thus done hysterectomy.

References

- 1) Wexier A.S, Pemoll M.L
Benign disorders of the uterine corpus
In: Current Obstetrics and gynaecologic diagnosis and treatment, 8th ed. Appleton and Lange, 1994; Pg 731-739
- 2) Dutta D.C
Benign lesions of the uterus
In: Textbook of Gynaecology, 3rd ed. New Central Agency (P) Ltd, 2001; Pg 253-265
- 3) Wanjala S.H.M.
Uterine fibroids at Kenyatta National Hospital
M.Med Thesis, University of Nairobi, 1980
- 4) Vasant B.P.
Benign tumours of the uterus
In: Principles and Practice of Obstetrics and Gynaecology for Post graduates, 2nd ed. Jaypee Brother (P) Ltd, 1997; Pg 291-297
- 5) Tindall V.R.
Tumours of the Corpus Uteri
In: Jeffcoate's principles of Gynaecology, 5th ed. Butterworth and Company, 1987; Pg 417
- 6) Muhiu G
Effect of orgametril on menstrual blood loss in uterine fibroids
M.Med Thesis, University of Nairobi, 1986.

Case No. 4

BARTHOLIN'S ABSCESS- MARSUPIALIZATION DONE

Name:	SN	Parity:	1+0
Age:	27yrs	DOA:	13-5-2004
IPNo:	0959931	DOD:	16-5-2004

Presenting complaint

The patient was admitted with a complaint of a genital swelling for 2 days

History of presenting illness

The patient was well prior to the onset of the painful genital swelling. Both the swelling and pain were progressively increasing. The pain was on and off. The pain was aggravated by walking or coitus and relieved by analgesics. She had history of recurrent bartholin's abscess in the recent past but resolved on medication only. The patient had never been treated for sexually transmitted infections.

Obstetric and gynaecologic history

She was a para 1+0 and the delivery was in 1997 via spontaneous vertex delivery. The child was alive and well. Her menarche was at 18 years. Her last menstrual period (LMP) was on 21.4.04. Her menses lasted 3 to 4 days, recurred after 28-30 days and were regular. There was no history of associated dysmenorrhoea. She had used combined oral contraceptives pills between 1998 and 2003 but stopped in order to conceive.

Past medical and surgical history

This was found not be significant

Family social history

She was a married lady. She and her husband were both tailors and lived in Machakos town. Neither smoked cigarettes nor consumed alcohol. There was no family history of chronic illnesses.

Case No. 4

BARTHOLIN'S ABSCESS- MARSUPIALIZATION DONE

Name:	SN	Parity:	1+0
Age:	27yrs	DOA:	13-5-2004
IPNo:	0959931	DOD:	16-5-2004

Presenting complaint

The patient was admitted with a complaint of a genital swelling for 2 days

History of presenting illness

The patient was well prior to the onset of the painful genital swelling. Both the swelling and pain were progressively increasing. The pain was on and off. The pain was aggravated by walking or coitus and relieved by analgesics. She had history of recurrent Bartholin's abscess in the recent past but resolved on medication only. The patient had never been treated for sexually transmitted infections.

Obstetric and gynaecologic history

She was a para 1+0 and the delivery was in 1997 via spontaneous vertex delivery. The child was alive and well. Her menarche was at 18 years. Her last menstrual period (LMP) was on 21.4.04. Her menses lasted 3 to 4 days, recurred after 28-30 days and were regular. There was no history of associated dysmenorrhoea. She had used combined oral contraceptives pills between 1998 and 2003 but stopped in order to conceive.

Past medical and surgical history

This was found not to be significant

Family social history

She was a married lady. She and her husband were both tailors and lived in Machakos town. Neither smoked cigarettes nor consumed alcohol. There was no family history of chronic illnesses.

Physical Examination

She was found to be in a fair general condition, not pale, not jaundice, afebrile and no oedema. Her vital signs were; temperature 36.8⁰C, pulse rate of 88 beats per minute, respiratory rate of 18/minute and blood pressure of 100/60 mmHg

Pelvic Examination

She had a swelling involving the posterior and medial aspect of the left labia majora. The swelling was reddish in colour, warm, tender and fluctuant. The right labia majora was normal. The cervix was closed, long and cervical excitation test negative. The uterus was of normal size, adnexae and pouch of Douglas were free. The inguinal nodes were not palpable.

Other systems

Cardiovascular, central nervous and respiratory systems were essentially normal. Abdominal examination was also normal.

Diagnosis

A diagnosis of left Bartholin's abscess was made.

Investigations

- Haemoglobin level - 12.2 g/dl
- WBC- 12×10^9 /L (neutrophils 90% and lymphocytes 9%)
- RBC- 4.1×10^{12} /L
- Haematocrit – 36.6%
- Platelets count - 248×10^9 /L
- Urea 2.4 mmol/l
- Creatinine 52 μ mol/L
- Sodium 143 mmol/L
- Potassium 4.6 mmol/L.

Management

She gave an informed written consent, starved from midnight and in the morning of the operation, she was premedicated with atropine sulphate 0.6 mg and pethidine 50 mg intramuscularly 30 minutes before being wheeled to theatre.

In theatre, general anaesthesia was instituted and the patient put in lithotomy position. Vulvovaginal toilet was done, aseptically catheterised and draped. The earlier clinical findings were confirmed on being examined under anaesthesia.

The vaginal canal was then obliterated with sterile gauze. A 2 to 3 cm longitudinal incision was made at the mucocutaneous junction of the left labia majora. The abscess was opened and the loculi broken using a small artery forceps. About 30mls of purulent bloody pus was drained and a pus swab for culture and sensitivity taken. The abscess edges were everted with interrupted sutures using catgut no. 2/0. The bleeding was minimal. A wet gauze soaked in normal saline was left in the cavity to facilitate drainage. The patient was cleaned, repositioned to supine and anaesthesia successfully reversed.

Post operative care

She had continuous observation of vital signs until she was fully awake and then 4 hourly. She was put on doxycycline 100mg twice daily for seven days and analgesics. The gauze was removed after 24 hours and instructed to have saline sit baths twice daily. She was discharged on the third post-operative day and booked for review after two weeks in the GOPC.

Follow up

The patient was reviewed in the gynaecology outpatient clinic (GOPC) after the two weeks. The wound had granulated well and without sepsis. The culture report showed growth of staphylococcus aureus, which was sensitive to various antibiotics including doxycycline. She was discharged from the clinic

Discussion

The patient presented was a 27years old, para 1+0 with bartholin's abscess of the left labia majora, which was marsupialized.

Bartholins are a pair of compound racemose glands. The gland itself lies just anterior and lateral to the bulbocavernosus muscle. Each gland is drained by a duct, which is 1.25-2 cm long, 5mm in diameter and they open at 5 and 7 o'clock positions just central to the hymen. The epithelium of the duct is cuboidal and stratified squamous epithelium at the orifice. During sexual arousal, the glands secrete viscid mucoid and alkaline fluid, which may act as a lubricant during coitus. Nonetheless, after the age 30 years, the glands undergo involution and became atrophic and shrunken (1,2).

Bartholin's abscess is the end result of acute bartholinitis. The duct gets blocked by fibrosis and the exudates pent up to produce an abscess. If left uncared for, the abscess may burst through the lower vaginal wall (2). Organisms implicated in bartholins abscess include neisseria gonorrhoea, staphylococcus aureus, streptococcus faecalis, escherichia coli and even trichomonas vaginalis. Other causes of bartholin's blockage include congenital narrowing of the duct, iatrogenic narrowing following mediolateral episiotomies and inspissated secretions. These results in the accumulation of secretions and subsequent secondary bacterial infections hence bartholin's abscess (2, 3).

The patient presented had staphylococcus aureus isolated from the pus swab specimen.

Both acute bartholinitis and bartholin's abscess are usually sexually transmitted infections. In such infections, the most common offending organism is neisseria gonorrhoea (2). Chetham (1985) cultured neisseria gonorrhoea in all 34 cases in his study (4).

The patient presented had no history of sexually transmitted infections.

Bartholin's abscess usually presents with severe pain and swelling of the vulva. There may be purulent discharge and obvious local signs of inflammation. Symptoms of bartholin's abscess include general malaise, headache and fever (1,2).

The patient presented had a painful swelling of the left labia majora.

At Kenyatta National Hospital (KNH), the treatment of Bartholin's abscess involves bed rest, analgesics, antibiotics and marsupialization.

Marsupialization provides permanent drainage and reduces not only the risk of abscess recurrence but also the cyst formation (2,3). Incision and drainage of Bartholin's abscess may provide relief to the patient and this is preferably done under general anaesthesia. Other alternative methods of treatments includes aspiration, use of an inflated bulb typed catheter or complete excision. In the developed world, where advanced medical technology is available, window operation and laser surgery are undertaken to manage Bartholin's abscess (2,4).

The patient presented had incision and drainage, and the incisional edges marsupialized under general anaesthesia. She was put on analgesics and antibiotics.

Although the glandular function of the Bartholin's glands is retained after marsupialization, the procedure is often associated with delayed healing and fibrous scarring (1,2). The risk of recurrence is about 10-15%. Mumia (1990) found a recurrence rate of 3% at KNH (5). Oliphant (1960) reported a recurrence rate of 68-75% when only simple incision and drainage was done without marsupialization (6). Fibrous scarring may result in closure of the Bartholin's duct with subsequent recurrence of the abscess. The fibrous scarring may later cause dyspareunia and may as well cause perineal tears during vaginal deliveries (2).

References

1. Alan H. Decherney
Benign disorders of the vulva and vagina
In: Current obstetric and gynaecologic diagnosis and treatment, 8th edition,
Appleton and Lange, 1994; Pg 710

2. Tindall V.R
Anatomy
In: Jeffocates principles of Gynaecology 5th Ed, Butterworths, London, 1987; Pg
18-20

3. Dutta D.C
Infections of the individual pelvic organs
In: Textbook of gynaecology, 3rd Ed. Central Book Publishers, 2001; Pg 151 and
152

4. Chetham D.R
Bartholin's Cyst: Marsupilization or Aspiration?
AM. J. Obstet. Gynaecol, 1985; **152** (5):569 – 700

5. Mumia J.A
Bartholin's abscess at KNH
M. Med Thesis, UON, 1990

6. Oliphat M.M
Management of bartholin's duct, cysts and abscess
AM. J. Obstet Gynaecol, 1960; **16**: 476

Case No. 5

INCOMPLETE ABORTION – MANUAL VACUUM ASPIRATION.

Name:	S.W.	Parity:	1+0
Age:	28 years	DOA:	9.10.02
IP NO:	0839834	DOD:	10.10.02

Presenting Complaints

The patient was admitted in the acute gynaecological ward with a 2 days history of per vaginal bleeding and lower abdominal pains.

History of presenting illness.

She was well prior to the onset of lower abdominal pains. The pain was intermittent, progressively increasing in intensity and frequency, and radiated to the back. The pains were soon followed by per vaginal bleeding. The bleeding progressively increased in amount and had expelled many clots. She denied interfering with the pregnancy.

Obstetric and gynaecologic history

She was a para 1+0. Her last menstrual period was on 28/7/2002 giving an amenorrhoea of 10 weeks and 3 days. She had not booked antenatal clinic. Her menarche was at 18 years. Her menses lasted 3 to 4 days, normal flow, recurred after 28 to 30 days and regular. She had no associated dysmenorrhoea. She gave no history of contraception.

Past Medical and Surgical History

This was not significant.

Family Social History

She was married, a housewife and her husband was an electrician. Neither smoked cigarettes nor consumed alcohol. She had no family history of chronic illnesses.

Physical Examination

She was a young lady in fair general condition pain, had blood stained clothes, mildly pale, afebrile and no peripheral oedema.

Her vital signs were: -

- Blood pressure – 120/70mmHg
- Pulse rate - 84 beats per minute.
- Respiratory rate – 18/minute
- Temperature – 36.5°C

Abdominal examination

The abdomen was not distended and moved with respiration. She had tenderness on the hypogastrium but had no palpable mass.

Pelvic Examination

She had normal external genitalia but soiled with blood. The vaginal walls were normal. The cervix was about 3cm dilated with products of conception being easily felt in the uterine cavity. On bimanual palpation, the uterine size was about 12 weeks and both the adnexae and pouch of Douglas were free. There was blood on the gloved examining fingers.

Other Systems

The cardiovascular, central nervous and respiratory systems were essentially normal.

Diagnosis

A diagnosis of incomplete abortion was made.

Investigations

- 11) Blood group O and Rhesus positive.
- 12) Packed cell volume (PCV) – 34.2% (Hb – 11.4g/dL).

Management

She was informed the nature of her illness and the intended management. She was started on intravenous infusion of normal saline and wheeled to the procedure room.

In the procedure room, she was put in lithotomy position with her legs fastened on the stirrups. With the surgeon dressed in sterile gown and gloved, the perineum was cleaned with antiseptic lotion and draped. A digital examination confirmed the earlier findings.

A bivalve speculum was gently inserted into the vagina and secured in place. The products of conception were visualized hanging from the cervical os and were removed using an ovum forceps. The anterior lip of the cervix was then held with a tenaculum. A 60cc syringe was used to create a vacuum. Gentle traction was applied to the tenaculum and a size 12 (12mm diameter) Karman's canula held with only the thumb and index fingers of the surgeon, was inserted into the uterine cavity through the dilated cervical os. The canula was attached to the syringe and the valve released causing immediate aspiration of blood clots and products of conception into the syringe. Suction and curettage was undertaken by forward and backward motions of the canula and 360 degrees rotation until a gritty sensation was felt.

About 50cc of non-septic products of conception were aspirated. There was very minimal bleeding. She was then transferred to the ward for observations. The vital signs remained stable and was later discharged on tetracycline, metronidazole, haematinics and analgesics. Before leaving the ward, she was counseled on contraception and advised to book antenatal clinic early in future pregnancies.

Follow-Up

She was lost to follow up.

Discussion

The patient presented was a 28 years old para 1+0 with incomplete abortion and was subsequently managed by manual vacuum aspiration (MVA) using Karman's canula.

Abortion is defined as the termination of pregnancy before the period of viability, which is considered by majority as 28 weeks (1,2). However, in the developed world, the limit of viability has been brought down to either 20 completed weeks of gestation or foetus weighing 500grams or less (1,2,3). Incomplete abortion is defined as the expulsion of some but not all of the products of conception before the period of viability (2,3).

The patient presented had incomplete abortion at 12 weeks of gestation.

The true incidence of spontaneous abortion is unknown. However, most studies estimate that 15 to 20% of all clinical pregnancies end in spontaneous abortion (1,2,3). With the use of serial human chorionic gonadotrophin (HCG) measurements to detect early subclinical pregnancy losses, the percentage increases to about 30% (1). About 75 to 80% of spontaneous abortions occur before the 16th week and of these, 75% occur before the 8th week of pregnancy (1,2,3,4). At Kenyatta National Hospital, Aggrarwal and colleagues (1982) reported that abortion was the leading cause of admission into the acute gynaecological ward and that 62.3% of the abortions were either induced or suspected to be induced (5).

The patient presented had spontaneous abortion at 12 weeks gestation.

The aetiology of abortion is often complex and obscure. However, most spontaneous abortions are associated with abnormal products of conception and occur prior to clinical evidence of pregnancy. Over 15% of fertilized ova do not divide. About 15% are lost before implantation (first week of gestation), approximately 25% are lost during implantation (second week of gestation) and 10% are lost following the first missed menses (2,3).

About 60% of spontaneous abortions occurring in the first trimester have an abnormal Karyotype – in which 50% are aneuploid and 50% are euploid (2,3). Autosomal trisomy is the most frequent chromosomal abnormality and is associated with first trimester abortions. Others include monosomy, polysomy and triploidy.

These are caused by single or interplay of genetic mutations, polygenic, maternal diseases, environmental toxins or immunological factors (2,3). Maternal disease conditions such as hypothyroidism, uncontrolled diabetes mellitus and infections such as syphilis, brucellosis, toxoplasmosis, herpes simplex, cytomegalovirus and malaria are common causes of abortions (3).

Corpus luteum insufficiency may secrete inadequate progesterone hormone, which may lead to foetal loss (2).

Cigarette smoking and alcohol consumption are associated with increased rate of euploid abortion. Connective tissue disorders such as lupus erythromatosis have been implicated as a cause of abortions. Others include dietary deficiency in vitamin E and folic acid, ABO incompatibility, Rhesus incompatibility and direct abdominal trauma (2,3,4).

The products of conception aspirated from the patient presented, were not subjected to karyotyping.

Diagnosis of incomplete abortion is based on history and physical examination. The patient usually presents with per vaginal bleeding, lower abdominal pains and backache. On physical examination, she may be pale or in shock depending on the amount of blood loss. The cervix may be dilated, the uterine size may be smaller than the period of amenorrhoea and the products of conception may be felt in the uterine cavity through the dilated cervix.

The patient presented had mild pallor, vital signs were stable, the cervix was 3cm dilated and the products of conception were felt in uterine cavity.

The management of incomplete abortion is by evacuation of the uterus. Suction curettage using manual vacuum aspiration has been found to be safer and easier than sharp curettage in the management of incomplete abortion.

Unlike the sharp curettage which is done under general anaesthesia or spinal block, manual vacuum aspiration using the Karman's canula can be done under "verbal anaesthesia" after thorough counseling or under analgesics or mild sedation.

Apart from avoiding the risks associated with general anaesthesia, the manual vacuum aspiration using the Karman's canula reduces the duration of hospital stay and therefore reducing the costs (2).

The patient presented had the incomplete abortion managed by manual vacuum aspiration under "verbal anaesthesia" and discharged 6 hours after the procedure.

Complications associated with abortions include severe haemorrhage, postabortal sepsis and even death. Sepsis is usually associated with prolonged duration between the onset of abortion and the time of uterine evacuation, as well as the aetiology of the abortion. Induced abortions, which are often performed under unhygienic conditions, are often complicated by sepsis. Other complications of abortion include pelvic abscess, endometrial and tubal damage, which may lead to future infertility or tubal pregnancy. At KNH, Makokha (1982) observed that 22.2% of maternal deaths were due to postabortal sepsis while haemorrhage was the second commonest cause of maternal death (6).

The patient presented was put on antibiotics for 5 days and haematinics for one month.

World Health Organization (WHO) estimates that 99% of all maternal deaths occur in the developing world and of which 40% are as a result of unsafe and illegally performed abortions (7). Availability of contraceptive services may actually reduce the maternal deaths associated with termination of unwanted pregnancies.

References

1. Thomas G.S.
Early pregnancy loss and ectopic pregnancy.
In: Novak's Gynaecology, 13th edition, Lippincott-Williams and Wilkins, 2002; page 507-509.
2. Dutta D.C.
Haemorrhage in early pregnancy.
In: Textbooks of Gynaecology, 3rd edition, New Central Publications, 2001; page 170-179.
3. Martin L.P, Sara H.G.
Early pregnancy risks.
In: Current Obstetric and Gynaecologic Diagnosis and treatment, 8th edition, Appleton and Lange, 1994; page 306-310.
4. Cunningham F.G. Gant F.G.
Abortion.
In: Williams Obstetrics, 21st edition, McGraw-Hill publications, 2001; page 855 – 877.
5. Aggarwal V.P., Mati J.K.G.
Epidemiology of induced abortions in Nairobi.
Journal of Obstetrics and Gynaecology for East and Central Africa 1: 54; 1982.
6. Makokha A.E.
Material mortality at Kenyatta National Hospital.
East Africa Medical Journal 57: 451; 1978.
7. World Health Organization.
Maternal health and safe motherhood.
Program progress report 1987-90 Geneva 1990.

Case No. 6

ABDOMINAL WOUND DEHISCENCE – SECONDARY REPAIR

Name:	GM	Parity:	6 + 2
Age:	42 years	DOA:	30.9.02
IP No:	0839017	DOD:	2.11.02

Presenting Complaint

The patient had an immediate gaping of the surgical wound after removal of the sutures.

History of presenting Complaint

The patient had been admitted as a referral from Pumwani Maternity Hospital with a diagnosis of eclampsia at 35 weeks gestation by dates. On admission, she was noted to be semi comatose, had facial puffiness, bilateral pitting pedal oedema and a raised blood pressure of 230/130mmHg. The fundal height was corresponding to 34 weeks. The foetus was in longitudinal lie, breech presentation and a foetal heart rate of 142 beats per minute and regular. She had no palpable uterine contractions. She was admitted in the acute room and started on intravenous infusion of magnesium sulphate and hydralazine.

Once the patient was stabilized, she underwent an emergency caesarean section due to eclampsia with viable foetus in breech presentation. The outcome was a live male infant weighing 2050gms and scored 6/1 and 8/5. The baby was admitted to the newborn unit due to poor score and prematurity. The patient also had bilateral tubal ligation.

Postoperatively, the patient was put on intravenous antibiotics – crystalline penicillin 2mu 6 hourly, gentamycin 80mg 8 hourly and metronidazole 500mg 8 hourly. On the 3rd post operative day she was converted to oral Ampiclox 500mg four times a day and oral metronidazole 400mg thrice a day. No fever or fits were reported postoperatively. The gaping of the surgical wound edges, oozing of serous serosanguineous fluid and protruded gut was noticed immediately after suture removal on the 7th postoperative day.

Obstetric and Gynaecologic history

She was a para 6+2 and had delivered through an emergency caesarean section due to eclampsia with breech presentation. The other deliveries were via spontaneous vertex deliveries. The two abortions occurred at a gestation of about 12 weeks and evacuation done. She had menarche at 16 years. Her menses lasted 3-4 days and recurred after 28-30 days, were regular and no associated dysmenorrhoea. She had no history of contraception.

Past medical and surgical history

This was not significant

Family and Social History

She was a housewife, her husband was a businessman and they stayed at Dandora. Neither smoked cigarette nor consumed alcohol. She was not a known hypertensive outside pregnancy and was not diabetic. She had no family history of chronic illnesses.

Physical Examination

She was in fair general condition, not pale, not jaundice, afebrile but had slight facial puffiness and bilateral pitting pedal oedema. Her vital signs were; blood pressure 140/80mmHg, pulse rate 84/minute, respiratory rate 18/minute and a temperature of 36.7 degrees centigrade.

Abdominal Examination

The abdomen was not distended. The dressing was soaked with serosanguineous fluid. The midline incisional wound had a wide separation of the edges. The small gut and part of the omentum was protruding out.

Other systems

The cardiovascular, central nervous and respiratory systems were essentially normal.

Diagnosis

A diagnosis of the complete wound dehiscence was made.

Management

The wound was covered with sterile gauze soaked in warm normal saline. The patient was explained the nature of her condition and the intended management. She gave an informed consent. Blood was taken for urgent blood urea and electrolytes, total blood count and for grouping and cross matching. An intravenous line was established and commenced on 5% dextrose infusion.

She was premedicated with 50mg of pethidine and 0.6mg of atropine intramuscularly half an hour before being wheeled to theatre. The laboratory results and one unit of blood were made available. The results were as follows;

- WBC- $3.35 \times 10^9/l$
- Haemoglobin -11.9g/dl
- Platelets- $436 \times 10^9/l$
- Urea 3.2mmol/l, creatinine 74 micromol/l, sodium 130mmol/l and potassium 4.91 mmol/l

The random blood sugar was 6.6mmol/l and ELISA (HIV) negative.

Operation

In theatre, she was placed on the table and anaesthetized. She was put in a semi-lithotomy position, vulvovaginal toilet done and aseptically catheterized. She was again repositioned to supine, the area around the wound cleaned and draped.

The bowel and omentum that had protruded through the wound was cleaned and returned to the peritoneal cavity. The peritoneal cavity was inspected. The uterine incisional wound was intact without signs of infection, the peritoneal cavity was cleaned with warm normal saline.

The wound edges were refreshed and using nylon no. 2, interrupted sutures were placed through the whole thickness of the abdominal wall (mass closure). The wound was dressed and anaesthesia reversed successfully.

Post operative management

Her vital signs were observed half hourly until she was fully awake and thereafter 4 hourly. She was maintained on intravenous fluids, normal saline alternating with 5% dextrose drip until the bowel sounds were heard and normal.

She was also put on intravenous augmentin (clavulanic acid/amoxicillin) 1.2gms 8hourly and metronidazole 500mg 8hourly for seven days, pethidine 100mg 8hourly intramuscularly for 24hours and then put on oral Ibuprofen 400mg thrice a day.

The 3rd postoperative day check haemoglobin was 11.4g/dl. The stitches were removed on the 10th day and the wound was clean and healing well. She was discharged home but could not leave until 2nd November due to financial constraints. She was booked for postnatal clinic after four weeks.

Follow up

She was reviewed in the postnatal clinic and both the mother and the baby were doing well. The blood pressure was 120/70mmHg; the incision wound had healed well and had no lochia loss. She was not referred to the family welfare clinic since she had been done a bilateral tubal ligature during the caesarean section. However, she was advised on the need for yearly Pap smear.

Discussion

Wound dehiscence, sometimes also referred to as “burst abdomen”, is defined as the disruption of all or part of the layers of the abdominal wall. Wound dehiscence can either be complete or incomplete. Incomplete or partial dehiscence implies the disruption or separation of the layer posteriorly. If the peritoneum is included in the disruption, the dehiscence is referred to as complete. If the intestines protrude through the wound, the term **evisceration** is used (1,2,3).

The patient presented had complete wound dehiscence with evisceration.

The incidence of wound dehiscence ranges between 0.3-5% of all cases of pelvic surgery (1). Locally, the incidence is unknown. Evisceration is an emergency and is associated with a mortality rate of 10-35% (1).

The transverse lower abdominal (pfannenstiel) incision used by many gynaecologists rarely result in wound dehiscence. Vertical incisions may carry a somewhat greater risk of breakdown (2). The type and the strength of the suture material plus the surgical technique may predispose to wound dehiscence (1). Systemic and local factors may contribute to the development of wound dehiscence. Wound dehiscence is found to be rare in patients of 30 years of age and below. Other factors that predisposes to wound dehiscence includes diabetic state, ureamia, immunosuppression, wound sepsis, obesity, malignancy, anaemia and poor nutritional status. Formation of a haematoma within the wound and use of high doses of corticosteroids may also cause wound dehiscence. Increased intra-abdominal pressure, as experienced in chronic cough or repeated vomiting, may cause wound dehiscence (1,2,4).

The patient presented was 42 years old, in good nutritional status and not anaemic. Her blood sugar was normal and HIV negative. She had a lower midline (pfannenstiel) incision but there was no evidence of wound sepsis. However, chromic catgut suture had been used. The most likely cause of the wound dehiscence was poor surgical technique and the suture material used. Catgut sutures have the highest likelihood of dehiscence (5).

Although wound dehiscence may occur any time following the wound closure, it is most common between the fifth and tenth postoperative days when the wound strength is minimal. The first sign of dehiscence involves the discharge of serosanguineous fluid from the wound (1,2,3).

The patient presented had discharge of serosanguineous fluid and evisceration upon the removal of stitches on the 7th postoperative day.

Complete wound dehiscence is a critical postoperative complication and secondary closure must be performed as soon as possible under general anaesthesia. The wound should be explored meticulously to determine the extent of dehiscence. Surgical rebridement is carried out; removing the necrotic tissue, the clots and the suture material. Inspection of the bowel and omentum should be done, and peritoneal lavage done with warm normal saline. The appropriate suture to use is nylon no.2. Through and through sutures (mass closure) are passed 2cm apart and 3cm from the skin margins to close the skin. The sutures are tied loosely and incorporate a tubing stent to prevent them from cutting into the skin. The sutures are then left in place for a period of 10 to 14 days (1,2,4). Broad-spectrum antibiotics, preferably through parenteral route, are recommended.

The patient presented had surgical debridement, mass closure technique using nylon no.2, broad-spectrum antibiotics intravenously and the sutures removed after 10 days.

Incisional hernias are reported to occur in about 20% of patients with recurrent evisceration (1). At Kenyatta Hospital, the use of nylon no.2 to close the rectus sheath in conditions that are likely to result in wound evisceration, such as immunosuppression, is usually recommended.

References

1. Mattingly R.F, Thompson J.D
Incision for Gynaecologic surgery
In *Telinde's Operative Gynaecology*, 8th Ed. Lippincott-Raven Publications, 1997;
Pg 310-311
2. Pemoll M.L, Benson R.C
Intraoperative and Postoperative complications of Gynaecologic surgery
In *Current Obstetrics and Gynaecologic diagnosis and Treatment*, 8th ed.
Appleton-Lange, 1994; Pg 881-882
3. Cunningham FG, Norman FG
Puerperal Sepsis
In: *Williams Obstetrics*, 21st Ed, Mc Graw-Hill Publications, 2001; Pg 678
4. Dutta D C
Practical Gynaecology
In: *Textbook of Gynaecology*, 3rd Ed. New Central Publications, 2001; Pg 583
5. Sean J, Mulvihill T, Carlos A P
Postoperative Complications
In: *Current Surgical Diagnosis and Treatment*, 10th Ed, Appleton and Lange,
1994; Pg 210-213

Case No. 7

ACUTE PELVIC INFLAMMATORY DISEASE (PID) – ANTIMICROBIAL THERAPY

Name:	M.K	Parity:	1+0
Age:	22 years	DOA:	13.08.04
IP NO:	0977910	DOD:	20.08.04

Presenting Complaints

The patient was admitted with complaints of lower abdominal pains, vomiting and lower backache for 4 days.

History of presenting complaints

The patient had been well until 4 days prior to admission when she developed lower abdominal pains that were of insidious onset. The pains were persistent, radiating to the back and had no relieving factors. She had episodes of vomiting precipitated by feeding or ingestion of drugs. She was unable to walk upright. She had a vaginal discharge that was yellowish and fowl smelling. She had no dysuria, no urinary frequency and no urgency. She had normal bowel habits.

She had never been treated for a similar disease or complaints.

Obstetric and gynaecologic history

She was a para 1+0 and her last delivery was in 2001 by spontaneous vertex delivery and the baby was alive and well. Her last menstrual period was on 06/07/2004. She had been on oral contraceptives but had stopped one month prior to admission. Her menses lasted for 3 days, normal flow, recurred after 28 days and were regular. The menses were often associated with moderate to severe dysmenorrhoea.

Her menarche was at 15 years.

Past Medical and Surgical History

The patient had never been treated for pelvic inflammatory disease or other sexually transmitted infections.

Family Social History

She was married, a housewife and her husband was a casual labourer in a construction company in industrial area. They stayed at Kayole. Neither smoked cigarettes or consumed alcohol. She had no family history of chronic illnesses.

Systematic Enquiry

There was no abnormality.

Physical Examination

General Examination

The patient was sick looking and was in pain. She was not pale, not jaundiced, no peripheral oedema but was clinically febrile.

Vital signs: -

- Blood pressure - 120/80 mmHg
- Pulse rate - 138/minute but regular
- Respiratory rate – 22/minute
- Temperature – 38.2°C

Abdominal examination

The abdomen was flat with marked tenderness in both the right and left iliac fossae and suprapubically. There was no guarding or rebound tenderness. There was no palpable mass. There was no hepatosplenomegally. The bowel sounds were present and of normal tone and frequency.

Pelvic Examination

The external genitalia was normal. She had a yellow-greenish and foul smelling vaginal discharge. Cervical excitation test was positive with marked bilateral adnexal tenderness. Bimanual palpitation was not possible due to the tenderness. The pouch of Douglas was empty but had marked tenderness. There was no blood on the gloved examining fingers.

Other Systems

The cardiovascular, central nervous and respiratory systems were essentially normal.

Diagnosis

A diagnosis of acute pelvic inflammatory disease was made.

Investigations

1. Total blood count:
 - Haemoglobin – 11.2g/dL
 - WBC – $14 \times 10^9/L$ (differential: Neutrophils 89%, Lymphocytes 8%)
 - Platelets – $298 \times 10^9/L$.
2. Pregnancy test – negative
3. Endocervical swab – No growth obtained (specimen taken on 3rd day after commencement of antibiotics).
4. Urea and electrolytes – Sodium 139mmol/L, Potassium 3.8mmol/L, urea 5.8mmol/L and creatinine of 72 μ mol/L
5. Ultrasound – ordered but not done.
6. ELISA (HIV) – positive.

Management

The patient was empirically started on intravenous zinnacef (cefuroxime) 750mg 8 hourly, metronidazole 500mg 8 hourly and intramuscular diclofenac 100mg 8 hourly. By the third day after admission, the patient had showed remarkable improvement. She was afebrile, the tenderness had reduced and the vaginal discharge was minimal.

She was discharged after 5 days on oral metronidazole, doxycycline and ibuprofen tablets. She was booked for review at the gynaecology outpatient clinic (GOPC) after one week. Meanwhile, the patient was given a prescription for doxycycline and metronidazole for the husband to buy and take.

Follow – up

The patient was reviewed as scheduled at GOPC. She had no complaints. The lower abdomen was not tender and the cervical excitation test was negative, the adnexae were not tender and there was no discharge or blood on the examining fingers.

Discussion

The patient presented was a 22 years old para 1+0 admitted with severe lower abdominal pains, vomiting and lower backache. She was febrile, marked tenderness of the iliac fossae and yellowish foul smelling vaginal discharge. She had a positive cervical excitation test, tender of both adnexae and pouch of Douglas. An impression of acute pelvic inflammatory disease was made and put on appropriate anti-microbial therapy.

Pelvic inflammatory disease (PID) is a general term used to describe the infection of upper genital tract. The upper genital tract infection involves the endometrium (endometritis), fallopian tubes (salpingitis), ovaries (oophoritis), parametrium (parametritis) and often with the involvement of adjacent structures or organs. However, majority prefer the term salpingitis instead of pelvic inflammatory disease (PID) because its the fallopian tubes that ultimately bears the brunt of the infection (1,2). The disease process can be divided into acute, sub-acute or chronic forms.

The patient presented had acute PID.

Despite better understanding of the aetiology, pathogenesis, improved diagnostic tools and the advent of wide range of anti-microbials, PID still constitutes a health hazard both in the developed and more so in the developing countries (1,2). The readily availability of contraception together with increased permissive sexual attitude has resulted in increased incidence of sexually transmitted infections and correspondingly, pelvic inflammatory disease (PID) (1,2). The incidence varies from 1 to 2% per year among the sexually active women. About 85% are as a result of spontaneous infection in sexually active females of reproductive age. The remaining 15% precedes procedures, which favours the ascending of organisms up the genital tract. Such iatrogenic procedures include endometrial biopsy, uterine curettage, insertion of intrauterine device (IUCD) and hysterosalpingogram (HSG) (2). PID can also be a consequence of infection of retained products of conception following either delivery or abortion.

Rarely, PID may result from blood-borne bacterial transmission, for example, pelvic tuberculosis. Two thirds of PID cases are restricted to young women of less than 25 years (2). At Kenyatta National Hospital, Fomulu (1981) found PID to be commonest in females below 20 years and that 18.2% of cases preceded abortion (3).

Although there is no authoritative data, many authors believe HIV/AIDS has also contributed greatly to the increased incidence of PID (1,2,6). Locally, Ayoma (1990) reported a HIV prevalence rate of 21% among patients presenting with PID at Kenyatta National Hospital (4). Wanyonyi (2002) found a HIV seroprevalence rate of 40% among PID/pelvic abscess patients at the same hospital (5).

The patient presented was 22 years old and HIV positive.

Acute PID is usually a polymicrobial infection caused by organisms ascending "upstairs from downstairs" (2). The primary organisms are sexually transmitted and limited approximately to gonococcal (30%), chlamydial (30%) and mycoplasma in 10%. Other causive organisms include aerobic streptococcus, staphylococcus, *Escherichia coli*, ureaplasma and even tubercular bacilli (1,2,6,7). At Kenyatta National Hospital, Cartley (1972) found that *neisseria gonococcus* caused 75% of all PID cases (8). At the same hospital, Fomulu (1981) found a polymicrobial pattern, with *Escherichia coli* accounting for 30% of PID cases (3).

The patient presented had an endocervical swab taken but no bacterial growth was obtained probably as a result of prior anti-microbial therapy.

The diagnosis of acute PID is usually clinical. The patient usually present with lower abdominal or pelvic pain, which is dull in nature. The patient may also complain of hotness of the body (fever), lassitude and headache of varying intensity, abnormal vaginal discharge (often purulent and copius), nausea and vomiting, and deep dyspareunia. On examination, the patient is usually febrile with temperature being elevated beyond 38°C, tenderness of the iliac fossae, presence of a foul smelling vaginal discharge, positive cervical excitation test and tender adnexae (1,2,6,7).

A total blood count may reveals leucocytosis and an elevated erythrocyte sedimentation rate (ESR). Serological test for syphilis in both partners is usually recommended. An endocervical swab should be taken, preferably before initiation of anti-microbial therapy, for culture and sensitivity. Laparoscopy is the most liable investigative tool to diagnose PID but unfortunately it is only available in a few selected centres and it is not feasible to do in all cases (1,2,6,7).

Pelvic ultrasound may be useful to rule out other causes of pelvic disease such as acute appendicitis and ectopic pregnancy. Others include culdocentesis for both biochemical and microbiological studies, and blood cultures (2,6).

The patient presented had complaint of lower abdominal pains, nausea and vomiting, and hotness of the body. On examination, she was febrile (temperature 38.2C), had tenderness of the iliac fossae, a yellowish foul smelling vaginal discharge and a positive cervical excitation test. A total blood count showed elevated leucocytes (leucocytosis of $14 \times 10^9/L$), VDRL negative and was ELISA (HIV) positive. The endocervical swab had no bacterial growth obtained, probably as a result of the anti-microbial therapy initially before the specimen collection.

Based on the fact that PID is polymicrobial in cause, empirical antibiotic protocols should cover a wide range of microorganisms including gonococcal, chlamydial, ureaplasma species, gram-positive anaerobes and aerobes, and gram-negative anaerobes and aerobes (1,2,6,7). The patient should also receive antipyretics (if febrile) and analgesics.

The anti-microbials can be changed later after the results of the culture and sensitivity pattern. Although controversy exists over the issue of outpatient treatment with oral antibiotics versus inpatient with parenteral antibiotics. The practice at Kenyatta National Hospital is to admitted the moderate to severe PID cases for parenteral antibiotics or where the diagnosis is uncertain. Otherwise, the rest are treated as outpatient on oral medication.

The patient presented was admitted, put on parenteral metronidazole and cefuroxime (zinnacel) and diclofenac.

The sequelae of acute PID can be devastating and includes infertility, ectopic pregnancy, chronic pelvic pain, deep dyspareunia and mortality, which could be as a result of adult respiratory distress syndrome (2,6,7). In particular, PID often leads to infertility even with prompt treatment. Approximately 10% of women will develop tubal adhesions leading to infertility after one episode of PID, 30% after 2 episodes and more than 60% after three episodes (9). Patients whose PID is complicated by pelvic abscess formation may need surgical intervention which may be by laparoscopy, laparotomy or by posterior culpotomy. In centres with advanced medical technology, percutaneous drainage under sonographic or CT – scan guidance may be undertaken (6,7).

References

1. Pumima C. Tarun K.G.
Pelvic inflammatory
In: Principles and practice of Obstetrics and Gynaecology, 2nd edition, Jaypee brothers publications, 1997; page 252 – 260.
2. Dutta D.C.
Pelvic infections.
In: Textbook of Gynaecology, 3rd edition, New Central Publications, 2001; page 118–123.
3. Fomulu J.N.
Post – abortal sepsis and pelvic abscess at Kenyatta National Hospital
M. Med thesis, UON, 1981.
4. Ayoma O.Ojwang
Determination of HIV seroprevalence in patients with PID at KNH
M. Med thesis, UON, 1990.
5. Wanyonyi C.H.W
Determination of HIV seroprevalence in patients with PID/pelvic abscess at KNH
M. Med thesis, UON, 2002.
6. Jonathan S.B
Genitourinary, infections and sexually transmitted diseases.
In: Novak's Gynaecology, 13th edition, Lippincott Williams and Wilkins, 2002; page 460 – 463.
7. Martens M.G.
Pelvic inflammatory disease.
In: Te Linde's operative gynaecology, 8th edition, Lippincott- Raven publications, 1997; page 657 – 685.
8. Carney M.J, Nzioki J.M, Ver hagen A.R.
The role of gonococcus in acute PID in Nairobi.
East Afri. Med. J. 49; 376; 1972.
9. Spence M.
PID: Detection and treatment.
STD bulletin, John Hopkins University, vol 3 No.1, Feb, 1983;pg 78-91

Case No. 8

CARCINOMA OF THE OVARY STAGE III – SUBTOTAL

HYSTERECTOMY WITH BILATERAL SALPINGO-

OOPHORECTOMY AND INFRA-COLIC OMENTECTOMY AND

CHEMOTHERAPY.

Name:	Z.W.	Parity:	5+0
Age:	57 years	DOA:	09.06.04
IP NO:	0960097	DOD:	12.07.04

Presenting Complaints

The patient was admitted to ward 1B through the gynaecology outpatient clinic (GOPC) with complaints of progressive abdominal swelling and pains for about eight months.

History of presenting illness.

The patient had been well until about eight months prior to admission when she developed abdominal swelling that was progressive and associated with abdominal discomfort. She later noted that she was progressively becoming weak and poor appetite. She had no associated per vaginal bleeding. She had no urinary symptoms and had normal bowel habits. She had no chest pain or cough.

Two weeks prior to admission, she had developed lower abdominal pain that was dull in nature and continuous. She sought treatment at PCEA Kijabe hospital where she was admitted and subsequently referred to Kenyatta National Hospital.

Obstetric and gynaecologic history

She was a para 5+0 and her last delivery was in 1985. She had only two living children. Two died at the age of two years due to measles while one was a fresh stillbirth following a breech delivery. She was 10 years postmenopausal while her menarche was at 14 years. She had never been on any hormonal contraception.

Past Medical and Surgical History.

This was not significant.

Family Social History

She was married, a peasant farmer and lived at Mai-Mahiu. The husband was also a peasant farmer and neither smoked cigarettes nor consumed alcohol. She had no family history of cancers, diabetes mellitus or hypertension.

Physical Examination

General Examination

She was sick looking, wasted, mildly pale, not jaundiced, afebrile, had slight bilateral pitting pedal oedema but no lymphadenopathy.

Vital signs were; blood pressure-120/70mmHg, pulse rate-78/minute, regular and good volume, respiratory rate-19/minute and temperature-36.8°C

Abdominal examination

The abdomen was grossly distended and the franks were full. There were no areas of tenderness and no palpable mass. The abdomen was dull to percussion. There was fluid thrill and shifting dullness indicating the presence of ascites.

The liver and the spleen were not palpable and the bowel sounds were normal.

Pelvic Examination

She had vulval and vaginal atrophy but otherwise normal. The cervix was smooth, firm, posterior, short and closed. The uterine size was difficult to assess due to ascites but had bilateral tender adnexal masses. The pouch of Douglas was full but non-tender.

Other Systems

The breasts were atrophic but with no palpable nodules or masses. The central nervous, cardiovascular and respiratory systems were essentially normal.

Diagnosis

An impression of an ovarian tumour with ascites was made.

Investigations

1) Ultrasound – showed normal liver size and echopattern with no focal lesion seen. The gall bladder, spleen, pancreas and the kidneys were normal. There was generalized ascites with a few paracolic lymph nodes. The uterus was atrophic, had a left cyst adnexal mass measuring 4.53 x 5.08cm. The right adnexa was free.

Conclusion: Left adnexal mass; most probably carcinoma of the ovary.

2) Total blood count;

- WBC – $8.46 \times 10^9/L$
- Haematocrit- 31%
- Haemoglobin - 10.9 g/dL
- MCV – 74.9 fl
- MCH – 26.3 pg
- MCHC – 35.2 g/dL
- Platelets - $245 \times 10^9/L$

3) Pap smear – reported as normal.

4) Urea and electrolytes

- Sodium – 142 mmol/L
- Potassium – 3.5 mmol/L
- Chloride-102 mmol/L
- Urea – 2.5 mmol/L
- Creatinine – 78 $\mu\text{mol/L}$.

5) Liver function tests;

- Total protein - 64 g/L
- Albumin – 25 g/L
- AST - 22 i.u/L
- ALT -9 i.u/L
- ALP - 93 i.u/L
- Bilirubin- total 5.7 $\mu\text{mol/L}$ and direct 0.5 $\mu\text{mol/L}$.

6) Ca-125 - requested but not done due to financial constrains.

Management

The patient was explained the nature of the working diagnosis and the intended management. She gave an informed consent for laparotomy. A blood sample for grouping and cross matching was taken.

At 6.00 pm on the day before the operation, she had enema and was repeated at 6.00 am on the day of the operation.

She was starved from mid-night. She was pre-medicated with atropine sulphate 100mg and pethidine 100mg intramuscularly 30 minutes before being wheeled to theatre.

Operation

Once in theatre, the patient was anaesthetised, put in semi-lithotomy position, vulvovaginal toilet done and was aseptically catheterized. Examination under anaesthesia confirmed earlier findings in the ward. The vagina was painted with methylene blue and patient re-positioned to supine. The abdomen was cleaned and draped.

The abdomen was opened through an extended midline incision. About three litres of straw-coloured ascitic fluid was aspirated. On inspection of the abdominal cavity, the right ovary had irregular surface with necrotic and broken capsule and measured 4x3cm. The left ovary had a cyst measuring 5x5cm but appeared grossly normal.

There were tumour seedlings on the peritoneal surface of the anterior abdominal wall, transverse colon, omentum and the spleen. The liver had a large tumor mass measuring 5x5cm at the interlobular region and a few tumour seedlings on the posterior surface. The gall bladder was grossly distended.

The uterus was atrophic with visible tumour extension to the posterior aspect of the lower part and the cervix. There was visible involvement of the rectum or bladder. The tumour was therefore graded as stage III ovarian malignancy. Bilateral salpingo-oophorectomy and infracolic omentectomy was done. However, subtotal hysterectomy was done because it proved difficult to assess to the cervix due to the tumour extensions. The danger of damaging the ureters was a likely possibility if a total hysterectomy was attempted. Haemostasis was achieved. Peritoneal lavage was done and the abdomen was closed after a correct count of swabs, needles and instruments. Average blood loss was estimated at 500mls. The general anaesthesia was successfully reversed.

The specimens were taken for histology.

Post-operative care

The patient had continuous observation until she was fully awake in the recovery room. She was then transferred to the ward on 4 hourly observations. She had continuous intravenous fluids; normal saline alternating with 5% dextrose about 2.4 – 3 litres in 24 hours. She was also started on intravenous crystalline penicillin 2 mu 6 hourly, gentamycin 80mg 8 hourly and intramuscular pethidine 100mg 8 hourly for 48 hours. She

was then converted to oral ampiclox 500mg 6 hourly and mefenamic acid 500mg 8 hourly for 5 days. Once the bowel sounds were auscultated on the first postoperative day, the patient was started on graduated oral sips and light diet on the 2nd postoperative day. She did well postoperatively and the stitches were removed on the 6th and 7th postoperative days.

It was decided during the major ward round that since the intraoperative findings were highly suggestive of an ovarian malignancy, she be commenced on chemotherapy when the wound heals. She and her relatives were counseled on the intraoperative findings and the decision to start her on chemotherapy. She received the first course of chemotherapy (cisplatin, adriamycin and cyclophosphamide). She was discharged and booked for review in the GOPC after three weeks with histology results.

Follow-Up

After three weeks, she came for review in the GOPC as scheduled. She had no complaints and was in good general condition. She was not pale, not jaundiced and no lymphadenopathy. The incision site had healed well. The abdomen was scalphoid, with no palpable masses and no hepatosplenomegally.

The histology report showed a moderately well differentiated papillary serous cystadenocarcinoma with spread to the peritoneum, omentum and lymphoid tissue. The histology findings were discussed with the patient and her relatives. She was explained the need to continue with the second course of chemotherapy. She was admitted for chemotherapy.

Chemotherapy

Her course of chemotherapy comprised intravenous cisplatin 50mg and adriamycin 50mg stat and cyclophosphamide 500mg once daily for 5 days. After completion of every course, she was being discharged home on a 3 weeks rest period and then re-admitted for the next course.

Before each course of chemotherapy, the patient had repeated baseline investigations, which consisted of liver function test, urea and electrolyte, and total blood count. These baseline investigations remained within normal range throughout the course of treatment. She tolerated the chemotherapy well and had a total of six courses. The ultrasound done after the sixth course showed no abdominal masses and no hepatic deposits.

Discussion

The patient presented was a 57 years old para 5+0 and whose last delivery was in 1985. She had ovarian ovarian carcinoma stage III. She underwent subtotal hysterectomy, bilateral salpigo-oophorectomy and infra-colic omentectomy. She subsequently received chemotherapy, which comprised cyclophosphamide, cisplatin and adriamycin.

Ovarian malignancy constitutes about 15-20% of all female genital malignancy (1,2). It is more prevalent in United States and Scandinavian countries but much less in oriental or Latin American and Asian countries including Japan and India (2). In North America, ovarian malignancy claims the lives of more women per year than all other gynaecological malignancies combined (1,2,3). Appropriately 1 in every 70 newborn females in United States will live to develop ovarian cancer (2,3). At KNH, Njuki (1979) found that ovarian malignancy accounted for 8% of all female genital malignancies and ranked third as a cause of gynaecologic malignant disease after cancer of the cervix and choriocarcinoma (4).

In general, ovarian cancer is a disease of the postmenopausal women and the prepubescent girls, although it has been documented to occur in females of all ages (3). The incidence of ovarian cancer increases with age to a peak in the 50 – 70 years old age group (1,3,5). There is a relationship between the age and the type of ovarian malignancy. In children and young adults, the most common ovarian malignancy is germ cell tumours while in adults it is mainly epithelial. The sex chord stromal tumours occur in all age groups (2,3,5). Ojwang and colleagues (1980), at Kenyatta National Hospital, found majority of ovarian malignant cases occurred in the 40 – 60 years age group with a mean of 46.7 years (6).

The patient presented was 57 years old, postmenopausal and had an epithelial ovarian malignancy.

The cause of ovarian malignancy is unknown although a number of risk factors have been identified. There is significant reduction in the risk of ovarian cancer with increasing parity while nulliparity carry a higher risk (1,2,5). Other risk factors include an early menarche, a late age at menopause and a long estimated number of years of ovulation.

Exposure to industrial agents such as talc and asbestos has also been mentioned as a risk factor. The use of tobacco, coffee, alcohol and a high dietary fat has also been implicated. Genetic factors also appear to have a significant role in development of ovarian cancer (2,3). Between 5 and 10% of women with ovarian cancer have a positive family history of ovarian malignancy. A woman with one affected close relative has a lifetime risk of 2.5% - twice the risk in the general population. With two affected close relatives, the lifetime risk increases to 30 – 40% (5). Patients with Turner's syndrome are at risk of developing dysgerminoma and gonadoblastoma (2,3,5).

Multiparity, chronic anovulation and history of breastfeeding is protective. Pregnancy decreases the risk of ovarian cancer by 30 – 60%. The oral contraceptive use also decreases the risk by 30 – 60% depending on the duration of use (2,3). Women who use oral contraceptives for 5 or more years reduce the risk by at least 50%. In women with at least two children and oral contraception use for over 5 years, there is 70% reduction in likelihood of developing ovarian cancer (1).

The patient presented was a para 5+0, with no history of oral contraceptive use. She had menarche at 14 years and had menopause at 47 years. She had no family history of ovarian malignancy.

Based on the cell type of origin, ovarian neoplasms are classified histologically into (1,2,3,5); -

1. **Epithelial tumours:** They constitute 70 – 80% of all ovarian neoplasms. These include serous, mucinous, endometrial, clear cell tumour (mesonephroid) and transitional type.
2. **Sex cord stromal tumours:** These include granulose cell tumours, thecoma, androblastomas and sertoli-leyding cell tumours. They account for 5 – 10% of all ovarian neoplasms.
3. **Germ cell tumours:** These include dysgerminoma, teratomas, non-gestational choriocarcinoma, and endodermal sinus tumour (york sac tumour). They constitute 15 – 20% of all ovarian neoplasms.
4. **Mixed or unclassified tumours:** These comprise primary ovarian neoplasms that cannot fit in any of the above classifications.

5. **Secondary (metastatic) tumours:** - These are metastases from adjacent organs/ structures, for example, endometrial, gastric, gut and cervical malignancies.

Each of these groups is further classified into benign, borderline malignancy and malignant tumours.

The patient presented had serous cystadenocarcinoma, which is of epithelial origin.

Of all the gynaecological cancers, ovarian malignancies represent the greatest clinical challenge. Typically, ovarian cancer develops as an insidious disease, with a few warning signs or symptoms. Most neoplastic ovarian cancers, especially epithelial tumours produce few symptoms until the disease has widely disseminated throughout the abdominal cavity (1,3,5).

Symptoms are usually non-specific and include gastro-intestinal complaints such as nausea and vomiting, dyspepsia and a change in bowel habits in form of constipation are common. Abdominal distention and respiratory distress as a result of ascites is generally a feature of advanced disease. A large tumour may cause a sensation of pelvic weight or pressure. Rarely, an ovarian tumour may become incarcerated in the pouch of Douglas causing severe pain, urinary retention, rectal discomfort and bowel obstruction. Menstrual abnormalities may be noted especially in androgen or oestrogen producing ovarian neoplasms such as granulosa-theca cell tumours (1,2,3).

On examination, the patient may be cachexic with varying degree of pallor while jaundice may be evident in advanced disease.

The presence of palpable Virchows' (left supraclavicular) node with leg or vulval oedema is characteristic of ovarian malignancy (1,2,5). A mass may be palpable in the hypogastrium (sometimes bilateral) and may feel solid, mobile or restricted, slightly tender, irregular surface and dull to percussion. On pelvic examination, there may be an adnexal mass (sometimes bilateral) with palpable nodules in the posterior fornix. If the nodular size is greater than 1 cm, the diagnosis of ovarian malignancy is almost certain (1,2,3).

The patient presented had progressive abdominal swelling associated with abdominal discomfort. She was cachexic, mildly pale and had ascites.

Pre-operative evaluation of a patient with suspected ovarian neoplasm includes a total blood count, urea and electrolytes, liver function tests, coagulation profile cervical cytology and serum ca-125 levels. Intravenous urography may help to define the ureters and exclude a pelvic kidney. Barium enema is done to rule out colonic involvement or colonic cancer and a chest X-ray to detect pleural effusion or lung metastases. Ultrasonography is important to defining the mass and metastases to other organs such as the liver and spleen. Sonographic features of malignant ovarian tumours includes solid or solid and cystic, multiple septations (more than 3mm in size) and presence of ascites. CT-scan provides information about the retroperitoneal structures and abdomino-pelvic organs. However, the ultimate diagnosis depends on surgical exploration (1,3,7,8).

The patient presented had liver function tests, urea and electrolytes, and total blood count done. She also had cervical cytology (pap smear) abdominal/pelvic ultrasound scanning which revealed an adnexal mass and presence of ascites.

The importance of thorough surgical staging of ovarian cancer cannot be over-emphasized, because subsequent treatment is determined by the stage of disease. Histological and cytological findings are also considered in the staging. Ovarian cancer is staged according to the international federation of Gynaecologic and Obstetric (FIGO) classification of ovarian neoplasms (1,2,3).

Stage I – Growth limited to the ovaries.

I a – growth limited to one ovary; with no ascites containing malignant cells.

No tumour on the external surface and intact capsule.

I b – Growth limited to both ovaries; no ascites containing malignant cells.

No tumour on the external surface and intact capsule.

I c – Tumour either stage Ia or Ib but with tumour on the surface of one or both ovaries; or with capsule ruptured; or with ascites present containing malignant cells or with positive peritoneal washings.

Stage II – Growth involving one or both ovaries with pelvic extension.

II a – Extension and /or metastases to uterus and /or fallopian tubes.

II b – Extension to the pelvic tissues.

II c – Tumour either stage II a or II b but with tumour on the surface of one or both ovaries; or with capsule(s) ruptured; or with ascites present containing malignant cells or with positive peritoneal washings.

Stage III – Involving one or both ovaries with peritoneal implants outside the pelvis and /or positive retroperitoneal or inguinal nodes. Superficial liver metastases equals stage III. Also tumour limited to the true pelvis but with proven histological malignant extensions to small bowel or omentum.

III a – Tumour grossly limited to the true pelvis with negative nodes but with histologically confirmed seedlings of abdominal peritoneal surfaces.

III b – Tumour on one or both ovaries with histologically confirmed implants of abdominal peritoneal surfaces, none exceeding 2cm in diameter.

Nodes negative.

III c – Abdominal implants greater than 2cm in diameter or positive retroperitoneal or inguinal nodes or both.

Stage IV – Growth involving one or both ovaries with distant metastasis. If pleural effusion is present, there must be positive cytological test results to allot a case to stage IV. Parenchymal liver metastases equals stage IV.

The patient presented was placed in stage III at laparotomy but when the histological results were availed, she was placed in stage 3b.

Ovarian cancers spread by exfoliation of tumour cells into the peritoneal cavity (transcoelomic spread), by lymphatic dissemination and by haematological spread. Surgical staging therefore involves thorough exploration of the abdominal cavity including the sites where metastases are mostly likely. All peritoneal surfaces and the under surface of the diaphragm are inspected as well as the aortic and pelvic lymph nodes, liver, omentum and uterus. Peritoneal fluid should also be taken for cytological analysis (1,2,3).

There are two main modes of treatment for ovarian neoplasms; surgery and chemotherapy. Surgery is always the first line of treatment. It is undertaken to establish the stage, type and histological grading of the tumours (1,2,3). In early disease, surgery may be all that is required.

However, in some cases where the surgeon feels the cancer is inoperable, a biopsy is taken and the patient gets a few courses of chemotherapy first followed by surgery (adjuvant chemotherapy). The aim of surgery is to resect as much tumour as is safely possible (debulking). This includes total abdominal hysterectomy, bilateral salpingo-oophorectomy, infracolic omentectomy and removal of all visible tumour as is safely possible.

The patient presented had subtotal hysterectomy since it was not safely possible to do total hysterectomy due to tumour extension. She also had bilateral salpingo-oophorectomy and infracolic omentectomy. After surgery and confirmation of ovarian cancer by histology, the patient usually gets five days of chemotherapy every month for 6 - 8 cycles (courses). For epithelial ovarian malignancy, the standard therapy includes cisplatin based combination therapy with one or two of the following drugs; cyclophosphamide, adriamycin, and paclitaxel intravenously. Carboplatin and paclitaxel are less toxic, more effective and well tolerated but are relatively expensive. Cisplatin toxicity includes nephrotoxicity, neurotoxicity and ototoxicity. The patient requires adequate rehydration prior to administration of the cytotoxics in order to minimize renal toxicity. Paclitaxel, cyclophosphamide and adriamycin causes bone marrow suppression. The patient presented received a combination of cisplatin, cyclophosphamide and adriamycin.

Before a patient receives a course of chemotherapy, the liver function tests, total blood count, and urea and electrolytes must be done and be within the normal range. If they are abnormal, the therapy is deferred until the abnormal parameters are corrected appropriately. Chemotherapy may also be deferred if the develops stomatitis, vaginitis, cystitis or diarrhoea.

The patient presented had normal liver function tests, urea and electrolytes, and blood count before any of the scheduled therapy. She had no major side effects except alopecia.

Currently, radiation therapy plays a very limited role in the treatment of patients with epithelial ovarian malignancy. It is difficult to treat the entire abdominal cavity with therapeutic doses without causing life-threatening side effects especially the damage to the small bowel, liver and kidneys (1,2,3).

However, radiotherapy has been used successfully in the treatment of some germ cell neoplasms. Dysgerminoma is very sensitive to radiotherapy and may be curative, even for gross metastatic disease. However, radiotherapy causes loss of fertility and therefore should not be used as a first line treatment where preservation of fertility is desired (1).

The levels of ca-125, a surface glycoprotein associated with mullerian epithelial tissues is a useful tumour marker and is elevated in about 80% of patients with epithelial ovarian cancers. The serum ca-125 levels frequently become undetectable after the initial surgical resection and one or two cycles of chemotherapy. The change in serum ca-125 levels generally correlates with tumour response to chemotherapy. Therefore, patients with persistently elevated levels after 3 cycles of treatment may reflect tumour resistant clones (1,9). Rising levels of ca-125 are associated with disease progression while decreasing levels are associated with regression of the disease. The presence of high serum ca-125 levels in a patient who had previous undetectable levels upon completion of chemotherapy for epithelial ovarian cancer may imply recurrence of the disease (9,10).

The prognosis for patients with ovarian malignancy is related to the stage of disease and the histological type. The 5 year survival rate for patients with epithelial ovarian cancer stage I is 76 to 93%, stage II is 50 to 70%, stage III is 25 to 30%, and stage IV disease is less than 11% (1,2,3). Generally, germ cell tumours are associated with better 5 year survival rates than epithelial ovarian neoplasms (1,2).

References

1. Jonathan S.B.

Ovarian cancer.

In: Novak's Gynaecology, 13th Ed. Lippincott- Williams and Wilkins publications, 2002; page 1245 – 1307.

2. Dutta D.C.

Genital malignancy.

In: Textbooks of Gynaecology, 3rd Ed, New Central Publication, 2001; page 343 –

3. Vicky V.B.

Premalignant and malignant disorders of the ovaries and oviducts.

In: Current obstetric and gynaecologic diagnosis and treatment, 8th Ed, Appleton and Lange, 1994; page 954 – 966.

4. Njuki S.K.

Primary ovarian malignancy: The presentation at KNH.

M. Med Thesis, UON, 1979.

5. Stuart C, ASH M.

Malignant disease of the ovary.

In: Gynaecology by Ten Teachers, 17th Ed, Arnold Publications, 2000; page 155 – 166.

6. Ojwang S.B.O, Makokha A.R, Sinei S.K.A.

Ovarian cancer in Kenya.

East Africa medical journal 57: 13; 1980.

7. Tindal V.R.

Tumours of the ovary.

In: Jeff coats principles of Gynaecology, 5th Ed, Butterworth Publications, 1987; page 450 – 485.

8. Laurel W.R, Robert L.B

The ovary.

In: Kistner's Gynaecology principles and practice, 6th Ed, Mosby Publications, 1995; page 187 - 217.

9. Vergote I.B, Borner O.P, Abeler V.M.

Evaluation of serum ca-125 levels in the monitoring of ovarian cancer.

AM. J. Obstet. Gynaecol. 1987; 88: 157 – 158.

10. Ayalon D, Inbar M, Ron I.

Use of ca-125 response to predict survival parameters of patient with advanced ovarian carcinoma.

Acta Obstet. Gynaecol. 1994; 73: 658.

Case No. 9

**ENDOMETRIAL CARCINOMA STAGE I – TOTAL ABDOMINAL
HYSTERECTOMY AND BILATERAL SALPINGO-
OOPHORECTOMY**

Name:	E.N.	Parity:	7+0
Age:	61 years	DOA:	30.07.02
IP NO:	0798737	DOD:	13.08.02

Presenting Complaints

The patient was admitted with history of abnormal vaginal bleeding for duration of about six months.

History of presenting illness.

The patient had been well until January 2002 when she started having per vaginal bleeding. The bleeding was painless, non-cyclic, lasting between one to three weeks. She had no post-coital bleeding but had occasional foul smelling discharge. She had no urinary symptoms and had normal bowel habits.

She had been attended to at casualty and a pelvic scan had revealed a bulky uterus but no comment on the endometrial stripe. An endometrial biopsy taken in May 2002 was reported as atypical endometrial glands that were highly suggestive of endometrial carcinoma.

She had no cough or chest pain and gave no history of weight loss.

Obstetric and gynaecologic history

She was a para 7+0 and her last delivery was in 1976. The first delivery was in 1959 and all the deliveries were via spontaneous vertex delivery. Her menarche was at the age of 15 years. She had been postmenopausal for approximately 10 years. She gave a history of having been on combined oral contraceptive between most of the deliveries. She had been on depo provera injection for 2 years but could not recall the exact years.

She had an IUCD inserted in 1969 but reported to have been expelled during the menses after unknown duration. She underwent bilateral tubal ligation (BTL) after her last delivery in 1976.

Past Medical and Surgical History.

She was a known hypertensive and was being followed-up in the medical outpatient clinic (MOPC) at Kenyatta National Hospital since 1996. She had been on propranolol 40mg twice a day. She had never had surgery in the past.

Family Social History

She had been married for approximately 40 years and had been a tailor for many years until 1991 when she retired. Her husband was a retired engineer. They lived in Kikuyu where they did small-scale farming. Neither smoked cigarettes nor consumed alcohol. She had no family history of chronic illnesses.

Physical Examination

General Examination

She was in good general condition, had no pallor, no jaundice, clinically afebrile, no peripheral oedema, no lymphadenopathy and no oral thrush.

Her vital signs were: -

- Blood pressure – 130/80mmHg
- Pulse rate - 76/minute, regular and good volume
- Respiratory rate – 20/minute
- Temperature – 36.7°C

Abdominal examination

The abdomen was not distended and moved with respiration. She had a minilaparotomy scar above the umbilicus. She had no palpable masses and no areas of tenderness. Both the liver and the spleen were not palpable.

Pelvic Examination

She had atrophic vulva but normal. On speculum examination, the vaginal walls appeared normal and the cervix also looked healthy. On digital examination, the vaginal walls and cervix were smooth, the uterus was slightly bulky for a postmenopausal woman but mobile. The adnexae and pouch of Douglas were free. There was no blood or discharge on the gloved examining fingers.

Other Systems

The breasts were normal. The central nervous, cardiovascular and respiratory systems were essentially normal.

Diagnosis

An impression of endometrial carcinoma was made.

Investigations

- 1) Pelvic Ultrasound – Revealed a bulky uterus with normal echogenicity. The endometrium was reported as normal.
- 2) Pap Smear – Satisfactory smear with low-grade squamous intraepithelial lesion (LSIL).
- 3) Full blood count
 - WBC – $7.1 \times 10^9/L$
 - RBC - $4.2 \times 10^{12}/L$
 - Hb – 12.3 g/dL
 - Platelets – $308 \times 10^9/L$
- 4) Endometrial biopsy – Showed atypical endometrial glands suggestive of endometrial carcinoma.
- 5) Urea and electrolytes –
 - Sodium – 143 mmol/L
 - Potassium – 4.3 mmol/L
 - Urea – 4.6 mmol/L
 - Creatinine – 62 $\mu\text{mol}/L$
- 6) Random blood sugar 6.1 mmol/L

Management

The patient was explained the nature of her illness and the intended management. She gave an informed consent for the intended surgery. A blood sample was withdrawn for grouping and cross matching. She was starved from midnight and premedicated with atropine 0.6mg and pethidine 100mg intramuscularly 30 minutes before being wheeled to theatre.

In theatre, the patient was given general anaesthesia and placed in semi-lithotomy position. Vulvovaginal toilet was done and examination under anaesthesia confirmed the earlier findings. The patient was repositioned to supine position, abdomen cleaned and draped. The abdomen was opened through the Pfannenstiel incision.

The intra-operative findings were;

- ❖ Atrophic uterus but appeared grossly normal.
- ❖ Atrophic ovaries that were consistent with postmenopausal.
- ❖ No peritoneal metastasis.

Total abdominal hysterectomy was done as described in the introduction of this book. Bilateral salpingo-oophorectomy was also done. The specimens were taken for histological examination.

The patient did well post-operatively and was discharged on the 6th post-operative day and booked for review in the gynaecological outpatient clinic (GOPC) with histology results after 3 weeks.

Follow-up

The patient was reviewed in the GOPC as per the appointment. She was in good general condition, had no pallor, no jaundice, afebrile clinically and the incision site had healed well. She brought the histology report, which showed the following; -

- Uterus that weighed 85g, measured 7x4.5x1 cm and had one fibroid that measured 0.4cm.
- Sections of the endometrium exhibited features of a well-differentiated adenocarcinoma of the endometrium.
- The ovaries and tubes were unremarkable.

She was advised on the need for regular check-up every six months to monitor for recurrence.

Discussion

The patient presented was a 61 years old para 7+0 who had presented with postmenopausal bleeding. An endometrial biopsy taken was highly suggestive of endometrial carcinoma. She underwent a total abdominal hysterectomy and bilateral salpingo-oophorectomy.

Endometrial carcinoma constitutes 25-30% of all gynaecological malignancies and is the most common pelvic genital cancer in women in North America (1,2). About 75% of women with endometrial carcinoma are postmenopausal (2,3). The peak incident of onset is the sixth and the seventh decades with a median age of 60 years. Between 2 to 5% of cases occurs before the age of 40 years (1,3). In the United States, the incidence of endometrial carcinoma is higher amongst the white population compared to the black with a lifetime risk of the disease of 2.4% and 1.3% respectively (1).

The patient presented was 61 years old, black and postmenopausal.

The actual cause of endometrial carcinoma is still unknown. However persistence stimulation of endometrium with unopposed oestrogen is the single most important factor for the development of endometrial carcinoma (3,4). Unopposed oestrogen stimulation in conditions such as functioning ovarian tumours (granulosa cell) or polycystic ovarian syndrome is associated with increased risk of endometrial cancer. Unopposed oestrogen replacement therapy in postmenopausal women is associated with increased risk of the disease. Increased risk of endometrial cancer has also been noted in patients receiving exogenous oestrogen replacement therapy for Turner's syndrome or gonadal agenesis (2,3,4).

Tamoxifen, a drug widely used for treatment of breast cancer is anti-oestrogen as well as weakly oestrogenic. The drug has been associated with increased risk of endometrial cancer if used for a long time due to its weak oestrogenic effect (5,6). The use of cyclic progestin reduces the risk. Prior use of combined oral contraceptives reduces the risk significantly by about 50% (2,3,4). Other risk factors include obesity, nulliparity, late menopause, diabetes mellitus and hypertension.

Family history or personal history of colon, ovarian or breast cancer increases the risk of endometrial cancer. This may reflect a genetic factor in the development of endometrial carcinoma. About 25% of endometrial carcinoma cases are preceded by endometrial hyperplasia (3,4).

The patient presented had no known risk factors except hypertension.

The most common endometrial cancer cell type is adenocarcinoma comprising 70- 80% of cases and squamous metaplasia is not uncommon (7). Adenosquamous tumours contain malignant elements of both glandular and squamous epithelium. Clear cell and papillary serous carcinoma of the endometrium are histologically similar to those of the ovary and fallopian tube, and carries a worse prognosis. Mucinous, squamous and undifferentiated tumours of the endometrium are rarely encountered (1,3,7).

The frequencies of the endometrial carcinoma cell type are as follows (3,7);

- 1) Adenocarcinoma (Endometriod) – 80%.
 - a) Ciliated adenocarcinoma
 - b) Secretory adenocarcinoma
 - c) Papillary adenocarcinoma
 - d) Adenocarcinoma with squamous differentiation
 - i. Adenoacanthoma
 - ii. Adenosquamous.
- 2) Uterine papillary serous (<10%)
- 3) Mucinous (10%)
- 4) Clear cell (4%)
- 5) Mixed (10%)
- 6) Undifferentiated.

The patient presented had a well-differentiated adenocarcinoma.

Endometrial carcinoma is generally a slow growing tumour and may be confined to the stroma for a long time but finally it spreads directly by infiltrating the myometrium, parametrium or into the peritoneal cavity (2,8).

Downward spread to the cervix occurs in 15% of the cases. Lymphatic spread is usually late and involves the pelvic, Para-aortic and rarely inguinal or femoral lymph nodes.

The lymph nodes metastasis depends on the degree of tumour differentiation, myometrial invasion, tumour size and the surgical pathological stage of the disease. Lymph node metastasis is the most important prognostic factor (2,8).

Blood borne spread occurs late. The common sites of metastasis are lungs, liver, bones and brain. The fallopian tubes and the ovaries are involved in 3-5%, either by direct spread or by lymphatics (2,7).

The staging of endometrial carcinoma is based on abdominal exploration, pelvic washings, total abdominal hysterectomy with salpingo-oophorectomy, and selective pelvic and para-aortic lymph node biopsies. Approximately 75% of patients present with stage I disease (7). The International Federation of Gynaecologists and Obstetrics (FIGO-1989) have adopted the following surgical staging (7).

STAGE 0 – A typical hyperplasia suspicious of malignancy

STAGE I – Carcinoma confined to the corpus uteri.

la – Tumour limited to the endometrium

lb – Invasion to less than half of the myometrium

lc – Invasion to greater than half of the myometrium but not reaching the serosa

STAGE II – Carcinoma involving the corpus and cervix

Ila – Endocervical glandular involvement only

Ilb – Cervical stromal involvement

STAGE III – Carcinoma outside uterus but confined to the pelvis

IIla – Tumour invades serosa and/or adnexa and/or positive peritoneal cytology

IIlb – Vaginal metastasis

IIlc – Metastasis to pelvic and /or para-aortic

STAGE IV – Tumour invades bladder/bowel mucosa or has metastasised to distant sites

IVa – Tumour invasion of the bladder and/or bowel mucosa

IVb – Distant metastasis, including intra-abdominal and/or inguinal lymph nodes

The patient presented had endometrial carcinoma Stage I.

Abnormal per vaginal bleeding occurs in 75-80% of patients and is the most important warning sign of endometrial carcinoma. During the premenopausal years, the bleeding is described as heavy during menses, intermenstrual spotting, and premenstrual or postmenstrual bleeding. Postmenopausal bleeding, which is present in about 75% of the cases, may be described as slight, irregular or continuous (2,3,4).

Endometrial carcinoma as a cause of postmenopausal bleeding increases with age; after the ages of 80 years, the disease is responsible for 50-60% of cases (2,4). Watery and offensive discharge due to pyometra is usually present especially after menopause. Pain is not uncommon. About 10% of patients complain of lower abdominal pain. The pain may be colicky due to uterine contractions in an attempt to expel the polypoidal growth. About 5% of patients are usually asymptomatic.

The patient presented had postmenopausal bleeding.

Physical examination is usually unremarkable but may reveal medical problems associated with endometrial carcinoma and includes diabetes mellitus, hypertension and obesity. There may be varying degree of pallor. On speculum examination, there may be blood or purulent offensive discharge escaping out of the external cervical os. On bimanual examination, the uterus may be either atrophic, normal or may be enlarged due to tumour spread, associated fibroid or pyometra. The uterus may be mobile or fixed depending on the stage of the disease.

A case of postmenopausal bleeding is considered to be due to endometrial cancer unless proved otherwise. The finding of a benign condition such as a fibroid to account for postmenopausal bleeding does not negate thorough investigation to rule out carcinoma since the two lesions may co-exist (3,4).

Endometrial biopsy using a Sharman curette or a soft, flexible plastic suction cannula has been done with reliability.

The procedure may not require general anaesthesia and thus can be done as an outpatient procedure. Papanicolaou smear is not a very reliable diagnostic test for endometrial carcinoma and it is only positive in 50% of the cases (3,4).

Transvaginal ultrasonography has been used as an adjuvant to the diagnosis. Endometrial thickness of 4mm is considered as a cut-off value. Patients with endometrial thickness of over 4mm are recommended to have fractional curettage (9).

Fractional curettage is not only a definitive method of diagnosis but can also detect the extent of the growth. The procedure is done under general anaesthesia with utmost gentleness to prevent uterine perforation (3,4).

Hysteroscopy helps in direct visualization of endometrium and to take target biopsy.

Total blood count, urinalysis, chest X-ray, intravenous urography and sigmoidoscopy are useful ancillary diagnostic tests in patients with endometrial carcinoma. Liver function tests, blood urea and electrolytes, and blood glucose measurement are also useful. Serum ca-125, a well-established tumour maker for epithelial ovarian cancer is also useful in endometrial cancer. About 20% of pre-operative patients with endometrial carcinoma have elevated ca-125 levels (10).

The patient presented had a pelvic ultrasound and endometrial biopsy done. Routine blood counts, urea and electrolytes, papanicolaou smear and random blood sugar were also done.

The management of endometrial carcinoma depends on the stage of the disease. For stages I and II, total abdominal hysterectomy and bilateral salpingo-oophorectomy is the operation of choice. Surgical staging is done during the surgery and includes; aspiration of peritoneal fluid or washing, inspection and palpation of peritoneal structures, palpation with biopsy of pelvic and para-aortic lymph node. Nodal sampling identifies patients who may need radiotherapy (1,2,4).

The patient presented had endometrial carcinoma stage I and underwent total abdominal hysterectomy and bilateral salpingo-oophorectomy (TAH+BSO).

Radiotherapy is indicated in stage III and IV disease or in surgically risky patients. The irradiation may consist of brachytherapy or teletherapy or both. The total dose of irradiation is 40 to 45 Grays in fractions not greater than 1.8 Grays over 4 to 5 weeks (11).

Chemotherapy is usually reserved for advanced disease, recurrent cases or in metastatic lesions. Chemotherapy may be hormonal or cytotoxic drugs. Progestogens are widely used; the response is good in well-differentiated carcinoma with adequate oestrogen and progesterone receptors. These includes oral megestrol, parenteral (intramuscular) medroxyprogesterone acetate (Depo-Provera) or hydroxyprogesterone caproate. The minimum duration of treatment should be at least 3 months and if responsive, it may be continued for longer periods with reduced doses. Tamoxifen is a non-steroidal agent with anti-oestrogenic as well as weakly oestrogenic properties. It inhibits oestradiol binding to oestrogen receptor. It is effective in patients with hormone receptor positive tumours. It is used as 10mg twice daily alone or in combination with progestogen therapy (2,5,6).

Cytotoxic drugs are used either singly or in combination. The drugs commonly used are Adriamycin, cisplatin, carboplatin and cyclophosphamide. More often than not, the results of cytotoxic therapy are usually disappointing (2,3,4).

The poorly differentiated tumour, the greater the degree of myometrial penetration, lymph-vascular space invasion and the advanced disease stages are prognostically poor. Aneuploid tumours have the worst prognosis. Histologically, non-endometrioid tumours are aggressive and carry increased risk of recurrence (3,8).

Overall 5-year survival is 60%. A 5-year survival rate per disease stage is (8);

Stage I – 80-85%

Stage II – 55-60%

Stage III – 35-40%

Stage IV - <10%.

Primary prevention of endometrial carcinoma includes (12);

- a) Strict weight control
- b) To restrict the use of oestrogen hormonal replacement therapy after menopause in non-hysterectomised women. If needed, cyclic administration of progestogen preparation should be added and continued under supervision.
- c) Health education to women as regards the significance of irregular bleeding per vagina in perimenopausal period to detect and postmenopausal period.
- d) Screening of high-risk women, at least in menopausal period, to detect the premalignant or early carcinoma may be a positive step.

References

1. Annkathryn G
Premalignant and malignant disorders of the uterine corpus
In: Current Obstetric and Gynaecologic diagnosis and treatment, 8th edition, Appleton and Lange, 1994; page 937 – 946.
2. Soutter W P
Malignant diseases of the uterus
In: Dewhurst's textbook of Obstetricians and Gynaecology for postgraduates, 6th edition, Blackwell Science, 1999; PP 280 – 282.
3. Dutta D C
Genital malignancy
In: Textbook of Gynaecology, 3rd edition, New Central publishers, 2001; Page 329 – 334.
4. Thompson R J
Malignant tumours of the uterine corpus
In: Te Linde's Operative Gynaecology, 8th edition, Lippincott-Raven publishers, 1997; Page 1501 – 1519.
5. Leeuwen V, Bemraadt J, Coebergh J W
Risk of endometrial after tamoxifen treatment of breast cancer
Lancet 1994; 343: 448 – 452.
- 6). Fisher B, Costa Ntino J, Redmond C K
Endometrial cancer in tamoxifen-treated breast cancer patients
Journal of the National Cancer Institute, 1994; 87: 527 – 537.
7. Shepherd J H
Revised FIGO Staging for gynaecological cancer
British journal of Obstetrics and Gynaecology, 1989; 96(8): 889-892.

8. Sall S, Sonnenblick B, Stone M L
Factors affecting survival of patients with endometrial adenocarcinoma
An M J. Obstet. Gynaecol 1970; **107**: 16.

9. Smith B R, Kerlikowske K, Felstein V A
Endovaginal ultrasound to exclude endometrial cancer and other endometrial abnormalities
A M J. Obstet. Gynaecol 1998; **280(17)**: 1510 – 1517.

10. Gordon M S
Aids to Obstetrics and Gynaecology for MRCOG, 4th edition, 1998; Page 280 - 282

11. Nag S, Erickson B, Parikh et al
High dose rate brachytherapy for carcinoma of the endometrium
Int J. Radiat oncol phys, 2000; **48**: 779.

12. Pritchard K I
Screening for endometrial cancer: is it effective?
Annal of Internal Medicine, 1989; **110**: 177 – 179.

Case No 10

CARCINOMA OF THE CERVIX STAGE III B – RADIOTHERAPY

Name:	L.M.	Parity:	6+0
Age:	60 years	DOA:	30.06.04
IP NO:	0973821	DOD:	09.07.04

Presenting Complaints

The patient was admitted through the Gynaecology outpatient clinic (GOPC) with a five months history of vaginal bleeding.

History of presenting illness.

The patient had been referred from St.Mary's hospital, Lang'ata where she had presented with vaginal bleeding for five months. The bleeding was mainly postcoital and sometimes on exertion. Occasionally, she would notice a foul smelling vaginal discharge. She had no associated lower abdominal pain or backache. She had dizziness, easy fatigability and palpitation. She had no urinary symptoms and had normal bowel habits. She had no cough or chest pain. At St.Mary's hospital, she had been examined under anaesthesia and found to be in stage 3b. Subsequent histology of the punch biopsy revealed a moderately differentiated squamous cell carcinoma of the cervix.

Obstetric and gynaecologic history

She was a para 6+0 and her last delivery was in 1982. All the deliveries were by spontaneous vertex delivery. Her menarche was at the age of 17 years. She was 10 years postmenopausal. Her first intercourse was at the age of 20 years. She had never had any extramarital sex. She had no history of any contraception. She had never had a pap smear before the onset of this illness.

Past Medical and Surgical History.

She was a known hypertensive since 1978. She had been on aldomet 500mg thrice a day and lasix 40mg once a day.

Family Social History

She was married and was a peasant farmer. Her husband was a retired track driver. They stayed at Mai-Mahiu. Neither smoked cigarettes nor consumed alcohol. She had no family chronic illnesses.

Physical Examination

General Examination

She was in fair general condition and in good nutritional status. She was mildly pale, not jaundiced, clinically afebrile, no peripheral oedema and no lymphadenopathy.

Her vital signs were: -

- Blood pressure – 130/70mmHg
- Pulse rate - 88/minute, regular and good volume
- Respiratory rate – 18/minute
- Temperature – 36.6°C

Abdominal examination

The abdomen was not distended and moved with respiration. There were no areas of tenderness and had no palpable masses.

Pelvic Examination

She had a fungating, easily bleeding mass involving almost the entire vagina. The uterus was of normal size, anteverted but less mobile. The adnexae were slightly tender and fixed. There was a foul smelling pus-like discharge.

Other Systems

The central nervous, the cardiovascular and respiratory systems were essentially normal.

Diagnosis

A diagnosis of advanced cancer of the cervix was made.

Management

The patient was scheduled for examination under anaesthesia (EUA) for both staging and biopsy. The following investigations were done: -

1. Urea and electrolytes –

- Sodium – 140 mmol/L
- Potassium – 3.7 mmol/L
- Urea – 4.5 mmol/L
- Creatinine – 53 μ mol/L

2. Haemogram–

- PVC 25% (Hb 8.3 g/dL)
- WBC $6 \times 10^9/L$
- RBS $4.3 \times 10^{12}/L$

3. Chest X-ray – was normal.

The patient was transfused one unit of whole blood and a repeat PVC after 3 days was 33% (Hb 11g/dL).

Examination under anaesthesia (EUA).

The patient was informed of the diagnosis and the intended management. She gave an informed consent. She was starved from midnight and in the morning she was pre-medicated with atropine sulphate 0.6mg and pethidine 100mg intramuscularly 30 minutes before conveyance to theatre.

In theatre, she was placed supine on the table and anaesthetised. She was put in lithotomy position, vulvovaginal toilet done, draped and aseptically catheterized. About 50cc of clear urine was obtained.

A speculum examination revealed a friable, easily bleeding fungating mass arising from the cervix and involving almost the entire vagina.

The uterus was of normal size but slightly fixed (less mobile). The adnexae was tender, full and fixed to the uterus and the pelvic wall.. The pouch of Douglas was empty and non-tender.

Rectal examination revealed a normal mobile rectal mucosa. A wedge biopsy was taken for histology. The cancer was staged as stage III B. The general anaesthesia was successfully reversed and the patient transferred to the ward for recovery.

Cytoscopy and protoscopy were not done.

Histology

Histology result of the cervical biopsy revealed a well differentiated squamous cell carcinoma. Following the histology results and the staging, it was decided that the patient would benefit from radiotherapy. The patient was informed of the results and the intended radiotherapy. She concurred with the decision. Her husband was also counseled and agreed with the decision.

The following investigations had also been done.

1. Intravenous Urography (IVU) – The kidneys were normal, but had slight hydronephosis and hydro-ureter bilaterally.
2. Chest X-ray – was normal.
3. Ultrasound – Normal uterine size and echopattern. A mixed echomass in the cervix that measured 8.9 x 6.2cm. The adnexae were normal and the Pouch of Douglas was free.

4. Urea and electrolytes -

- Sodium – 137 mmol/L
- Potassium – 3.4 mmol/L
- Urea – 9.4 mmol/L
- Creatinine – 127 μ mol/L

5. Haemogram -

- Haemoglobin 10.9 g/dL
- WBC $6.2 \times 10^9/L$
- Platelets $298 \times 10^9/L$

6. Liver function tests were normal.

7. ELISA (HIV) – Negative.

Radiotherapy

The patient was taken to the radiotherapy department for marking and subsequently received radiotherapy five days in a week (i.e. except on weekends) for 5 consecutive weeks – a total of 25 sessions. She was transfused two units of whole blood while undergoing radiotherapy whenever the haemoglobin level would fall below 10g/dL.

She was booked for review at the GOPC after 4 weeks.

Follow-Up

The patient came for review as per the appointment. She was in fair general condition, was slightly pale, not jaundiced, afebrile and no peripheral oedema.

On speculum examination, the mass had remarkably reduced in size and was not bleeding on touch. She was to be seen again after two months.

Discussion

The patient presented was a 60 years old para 6+0 and who underwent radiotherapy for carcinoma of the cervix stage III B.

The cervix is the commonest site for genital malignancy. Cervical cancer is the most common cancer in women in most of the developing countries while its second commonest after cancer of the breast in developed countries (1,2,3). At present, there are nearly 1 million women getting cervical cancer each year globally and almost 75% of these are in the developing countries (1). The incidence of invasive cervical cancer has been declining in the developed world due to the availability and utilization of cervical cytology screening programs while the incidence in some of the developing countries is on the rise (2).

Although invasive cancer of the cervix may affect women of all ages, it usually affects women of middle age or older. In the United States, the mean age for cervical cancer is 52.2 years, and the distribution of cases is bimodal, with peaks at 35 to 39 years and at 60 to 64 years of age (1,4).

In Kenya, the incidence of cervical cancer is not known. However, the peak age of cervical cancer in Kenya is 35 to 45 years and a mean age of 42 years (5).

The patient presented was 60 years old.

The cause of cervical cancer is not known, but certain predisposing factors are recognized. Sexual activity seems to be positively correlated with the disease (1,3). Coitus at an early age (less than 16 years) especially within one year of menarche is recognized as a risk factor. The number of sexual partners is also a highly significant risk factor. Cancer of cervix is 4 times as frequent in prostitutes as in other women and is unusual in celibate women (3).

Infection with the human papillomavirus (HPV) has been strongly associated with malignant cervical transformation. HPV infection has been detected in up to 99% of women with squamous cervical carcinoma. There are 13 high-risk HPV subtypes; two of the high-risk subtypes, 16 and 18 are found in up to 62% of cervical carcinoma (1,2,3). The mechanism by which HPV affects cellular growth and differentiation is by interactions of viral E6 and E7 proteins with P53 and Rb, resulting in gene inactivation (6).

The role of immunodeficiency virus (HIV) in cervical cancer is thought to be mediated through immune suppression. Other risk factors include genital herpes simplex virus type 2 (HSV-2) infection, cigarette smoking, high parity, race and low socio-economic status. The role of oral contraceptive use in causing cervical cancer is controversial (1,2,3).

The patient presented was black, para 6+0, had menarche at 17 years, first coitus at 20 years and had no multiple sexual partners. She was HIV negative and a non-smoker.

Invasive cervical cancer begins as an intraepithelial lesion at the squamo-columnar junction of the transformation zone. Most cervical cancers probably begin as a dysplastic change with gradual progression over a period of several years to pre-invasive form (carcinoma in situ)(7).

Carcinoma in situ, if left untreated will progress to invasive carcinoma in a period of between 1 and 20 years (3,7). Squamous cell carcinoma accounts for 70 to 80% of cervical carcinomas. Adenocarcinoma accounts for approximately 10 to 15% and the remainder are composed of sarcomas and undifferentiated carcinomas (1,3).

The patient presented had a squamous cell carcinoma.

Carcinoma of the cervix is staged according to the international federation of Gynaecologist and Obstetricians (FIGO) staging. It is basically a clinical staging (1,2,3);

Stage 0: - Carcinoma in situ, intraepithelial carcinoma.

Stage I: - Carcinoma is confined to the cervix.

I A: - Microscopic carcinoma.

I B: - Macroscopic carcinoma.

Stage II: - The carcinoma extends beyond the cervix but has not extended to the pelvic wall. The vagina is involved but not the lower one third.

IIA: - Involves the upper one third of the vagina but no obvious parametrial involvement.

IIB: - Involves the upper one third of the vagina with obvious parametrial involvement.

Stage III: - The carcinoma has extended to the pelvic wall. There is no cancer-free space between the tumor and the pelvic wall. The tumour involves the lower one third of the vagina. All cases of hydronephrosis or non-functioning kidney.

III A: - No extension onto pelvic wall but involves the lower one third of vagina.

III B: - Extension onto the pelvic wall and/or hydronephrosis or non-functioning kidney due to the tumour.

Stage IV: - Carcinoma extends beyond the true pelvis or clinically involves the mucosa of bladder or rectum.

IV A: - Spread of growth to adjacent organs (i.e. rectum or bladder with positive biopsy from these organs).

IV B: - Spread of growth to distant organs.

In Kenya, majority of patients with cervical cancer present late. Ojwang in his series of patients less than 35 years of age with cervical cancer found that only 7.4% had presented in stage I and 19% in stage II (5). Rogo and colleagues (1991) in their study found that 55% of the study population had stage II disease (8).

The patient presented was found to be in stage III B.

Cervical cancer spreads principally by direct local invasion and via the lymphatics. The tumour spreads directly to the adjacent structures, vagina and to the body of the uterus. Lateral extensions include the paramerium, paracervical and paravaginal tissues. It may spread backwards along the uterosacral ligaments, to involve the rectum or forwards to involve the base of the bladder and may result in rectovaginal or vesicovaginal fistulae. In lymphatic spread, tumour cells are carried to the regional (primary) lymph nodes (obturator, hypogastric, sacral and external iliac) and to secondary nodes (common iliac group, inguinal nodes and para-aortic nodes)(2,3).

Haematological spreads leads to metastases to the liver mainly and less commonly to the brain, lungs, adrenal glands, spleen and pancreas (1,2,3).

The most common symptom of invasive cancer is abnormal vaginal bleeding which may be blood-stained discharge, spotting or frank bleeding. The bleeding may be provoked by coitus or exertion. In advanced disease, there may be lower abdominal pain or backache due to uterosacral ligament or parametrium involvement.

Bladder symptoms are in form of urinary frequency, dysuria, haematuria or true incontinence due to fistula formation. Rectal involvement is evidenced by diarrhoea, rectal pain or bleeding per rectum. Ultimately, the patient may become cachexic and anaemic with leg oedema.

The patient presented had a five-month history of vaginal bleeding and a vaginal discharge. She had no lower abdominal pain or backache. She had no urinary symptoms and had normal bowel habits.

On physical examination, patients with early disease may be sign-free. However in advanced disease, the patient may be of poor nutritional status (cachexic), varying degree of pallor, may have bilateral leg oedema and sometimes, inguinal lymphadenopathy.

The cervix may reveal gross erosions, ulcer or a mass, which may be infected and easy bleeding on touch. The lesion may extend to the vagina. Rectal examination may reveal an external mass or gross blood from tumour erosion of the rectum. Presence of leg oedema may suggest lymphatic or vascular obstruction by the tumour. Hepatomegally may be present in liver metastases (1,3).

Confirmation of cervical cancer is by histological examination of tissue biopsy. Differential diagnosis includes cervicitis, endometrial carcinoma, vaginitis, condyloma accumulata and genital tuberculosis (1,2,3).

The patient presented was slightly pale, had a fungating mass involving the cervix and almost the entire vagina. The diagnosis of cervical cancer was confirmed by histological examination of the biopsy.

Once the diagnosis of cervical cancer has been established, various investigations are undertaken to locate metastases and /or effects of metastases. These include a full blood count, urea and electrolytes and liver function tests.

Imaging studies include abdominal pelvic ultrasonography, chest X-ray, intravenous urography, CT-scan of the abdomen and pelvis, and barium enema. Others are protoscopy and cytoscopy to rule out colorectal and bladder involvement respectively. These imaging studies are also useful in staging of the disease.

The patient presented had cervical carcinoma stage III B.

The treatment options for cervical cancer largely depends on the stage of the disease, general condition of the patient, facilities available (surgery and radiotherapy) and the wish of the patient. The types of treatment employed for the invasive carcinoma include surgery, radiotherapy and rarely, chemotherapy (9).

For carcinoma in situ (stage 0), treatment includes local ablative measures such as cryosurgery, laser ablation and loop excision. Simple or extended hysterectomy is reserved for patients with completed family size or those whose follow-up may prove difficult (1,2,3)

For early invasive cancer, surgery is the treatment of choice (9). Cervical cancer stage 1A is managed by radical hysterectomy, sometimes also referred to as Wertheim's hysterectomy. Radical hysterectomy requires the removal of the uterus, cervix, parametrial tissues, upper vagina and pelvic lymphadenectomy from the bifurcation of the iliac vessels to approximately the level of the inguinal ligament. The ovaries may be preserved in young patients to avoid the need for replacement therapy (2,9). For patients with stage 1B or IIA disease, the treatment can be either radiotherapy or radical hysterectomy. Most studies have shown equivalent survival rates for both treatment options (2,9). The advantage of surgery includes the preservation of ovarian function, and retention of more functional and pliable vagina. Surgery is also preferred for patients with histological diagnosis of adenocarcinoma or adenosquamous carcinoma since these are less sensitive to radiotherapy (3,9).

Patients with stage IIB – IVA disease are traditionally treated with radiotherapy alone (1,2,3,9). The treatment begins with a course of external beam radiation to reduce tumour mass to enable subsequent intracavitary application. Brachy therapy is delivered using after loading applications that are placed in the uterine cavity and the vagina. (2,9). Palliative radiotherapy for advanced cervical cancer may be used to control bleeding and relief of pain (10). Complications of radiotherapy include diarrhoea, abdominal clamping, rectal discomfort and cysto-urethritis. Late sequelae include rectal or vaginal stenosis, vesicovaginal or rectovaginal fistulae, small bowel obstruction and malabsorption (1,2,9).

The patient presented had stage III B disease and therefore received radiotherapy. She developed occasional diarrhoea which was managed by anti-diarrhoeal agents.

The usefulness of chemotherapeutic agents in the treatment of cervical carcinoma has been disappointing (3,9,10).

However, Doxorubicin, bleomycin and cisplatin are the most active chemotherapeutic agents against squamous cell cancers of the cervix. Currently, the best results are achieved with the use of cisplatin alone in doses of 50 – 100mg/ m² every three weeks with response rates of 20%(2,3).

Cervical cancer is potentially preventable and it is imperative that health care providers who administer health care to women be familiar with the screening techniques, diagnostic procedures and risk factors for the disease especially its premalignant precursors. The pre-invasive lesions of the cervix can effectively be detected using a combination of cytology and colposcopy. It is recommended that women who have commenced sexual activity and those over 18 years of age, have a pap smear plus pelvic examination yearly. Women with risk factors such as HIV or HPV infection, cervical dysplasia and those with multiple sexual partners have at least one pap smear screening annually (3,9).

The clinical stage of the cervical cancer disease is the single most important prognostic factor (1,3,10). Generally, the 5 year survival rate for stage I disease is about 90%, stage II disease 60 – 80%, stage III disease approximately 50% and stage IV less than 30% (10).

References

1. Dutta D.C.
Genital malignancy
In: Textbooks of Gynaecology, 3rd ed, New Central Publication, 2001; pg 316-328.
2. Thomas C.K, John C.E.
Cervical and vaginal cancer
In: Novak's Gynaecology, 13th ed, Lippincott Williams and Wilkins, Philadelphia, 2002; page 1199 – 1232.
3. Annekathryn G, Edward C.H.
Premalignant and malignant diseases of the uterine cervix
In: Current obstetric and gynaecologic diagnosis and treatment, 8th ed, Appleton and Lange , 1994; page 926 – 935.
4. Jemal A, Thomas A, Murray T, et al.
Cancer statistics, 2002
CA Cancer J. Clin 2002; 52: 23 – 47.
5. Ojwang S.B.O, Mati J.KG.
Carcinoma of the cervix in Kenya
East Afri. Med. J. 1978; 55: 194.
6. Munger K, Sceffner M, Huibregtse J.M et al.
Interactions of HPV E6 and E7 oncoproteins with tumour suppressor gene products
Cancer Surv 1992; 12: 197 – 217.
7. McIndoe W.
The invasive potential of carcinoma in situ of the cervix
Obstet. Gynaecol. 1984; 64: 451 – 458.
8. Rogo K.O. Omany J, Onyango J.N. et al.
Cancer of the cervix in African setting
Int. J. Obstet. Gynaecol 1991; 36: 5 – 12.
9. Richard F.M, John D.T.
Invasive carcinoma of the cervix.
In: Te Linde's operative Gynaecology, 8th ed, Lippincott – Rave publications, Philadelphia, 1997; page 1385 – 1409.
10. Augustin A.G.
Cervical cancer
e. Medicine <http://www.emedicine.com/med/topic.324.htm>, April 17,2002.

Case No. 11

CHORIOCARCINOMA - REMISSION AFTER CHEMOTHERAPY

Name:	L.M	Parity:	3+0
Age:	28 years	DOA:	10.06.04
IP NO:	0949070	DOD:	18.06.04

Presenting Complaints

The patient was readmitted for the second course of chemotherapy for treatment of medium risk choriocarcinoma. She had no complaints.

History of presenting illness.

The patient had initially been admitted to ward ID on 2/4/2004 with two weeks history of per vaginal bleeding, intermittent lower abdominal pains, lower backache and amenorrhea for two and a half months. Initial impression of incomplete abortion was made but on attempted manual vacuum aspiration, she was noted to have grape-like tissue in the vagina and the procedure was abandoned.

A pelvic scan ordered showed an intrauterine mass with multicystic pattern with no gestational sac, no demonstrable cardiac activity and with no foetal pole. A diagnosis of molar pregnancy was made.

She had suction curettage done under general anaesthesia the next day and the evacuated material taken for histology. After one week, she was taken back to theatre for sharp curettage and again evacuated material taken for histology. The diagnosis of molar was confirmed by the histology. The B-HCG taken was 84 I μ /L.

She was discharged and instructed to come back after one week with serum B-HCG results. On review, the serum β -HCG level had risen to 431, 260 I.u./L. a diagnosis of gestational trophoblastic disease (choriocarcinoma) was made and scheduled to receive chemotherapy.

Obstetric and gynaecologic history

She was a 28 years old para 3+0 and one previous scar. Her last delivery was in 2000. the first delivery was through caesarean section due to transverse lie. The other two deliveries were through spontaneous vertex delivery. The second born died at 9 months of age due to pneumonia while the others are alive and well.

Her last menstrual period was on 23/1/2004. Her menses lasted 3 to 4 days, of normal flow, recurred after 28 days and were regular. She had no associated dysmenorrhoea.

She had no history of contraception.

Family Social History

She was married, a housewife and stayed at Waithaka. Her husband was an accountant in the city. Neither smoked cigarettes nor consumed alcohol.

There was no family history of chronic illnesses.

Physical Examination

General Examination

She was in fair general condition, had allocia, not pale, not jaundiced, afebrile, no peripheral oedema and lymphadenopathy. She had no stomatosis or oral mucositis.

Vital signs: -

- Blood pressure – 110/70mmHg
- Pulse rate - 82/min, regular and good volume
- Respiratory rate – 18/minute
- Temperature – 36.7°C

Abdominal examination

The abdomen was scaphorid and moved with respiration. There was no tenderness and no palpable masses. The liver and spleen were not palpable.

Pelvic Examination

The external genitalia was normal. On speculum examination, she had normal vaginal mucosa and cervix. On digital examination, the uterus was of normal size, anteverted and mobile. The adnexae and pouch of Douglas were free.

Other Systems

The cardiovascular, central nervous system and respiratory systems were essentially normal.

Diagnosis

The diagnosis of choriocarcinoma on chemotherapy was made.

Investigations

1) Total blood count –

- WBC – $6.4 \times 10^9/L$
- RBC – $4.04 \times 10^{12}/L$
- Haematocrit - 36%
- Haemoglobin - 12g/dL
- Platelets - $245 \times 10^9/L$

2) Urea and electrolytes

- Sodium – 141 mmol/L
- Potassium – 3.6 mmol/L
- Urea – 3.3 mmol/L
- Creatinine – 59 $\mu\text{mol}/L$

3) Liver function tests: -

- Total protein - 66g/L, Albumin – 33g/l
- ALT 10 iu/L
- AST – 13iu/L
- ALP - 136 iu/L
- Bilirubin: Total 5 $\mu\text{mol}/L$, Direct 0.4 $\mu\text{mol}/L$.

4) Chest X – ray –reported normal

5) Histology:

- After suction curettage: - Showed marked hydropic degeneration of nearly all chorionic villi.

Conclusion – Hydatiform mole.

- ii. After sharp curettage: - Showed decidualised endometrial stroma with secretory glands. No chorionic villi or trophoblastic cells seen.
6. Ultrasound (before curettage) – Showed an intrauterine mass with multicystic pattern, no foetal cardiac activity demonstrated and no foetal pole noted.
 7. Blood group – O Rhesus Positive.
 8. Serum β – HCG (before and during treatment):

Before treatment:	20/4/2004 - 84 i.u/l
	3/5/2004 - 434,330 i.u/l
During treatment:	22/5/2004 - 163 i.u/l
	10/6/2004 - 10.45 i.u/l
	21/6/2004 - 8.46 i.u/l
	11/7/2004 - 2.26 i.u/l
	30/7/2004 - <2 i.u/l
	16/7/2004 - 3.08 i.u/l
 9. ELISA (HIV) – Declined the test despite counseling.

Management

She had earlier been scored as medium risk. She received her second course of chemotherapy that comprised intravenous methotrexate 50mg on alternate days for 3 days, actriomycin – D 0.5mg once daily for 5 days and cydophosphamide 250mg once daily for 5 days.

Before administering the drugs, the patient had to be rehydrated using intravenous fluids and get antiemetics. She was then discharged on oral leucovolin 15mg once daily for 5 days and to come again for readmission with repeat serum β – HCG level test, liver function tests and urea and electrolytes after 7 days.

Follow-Up

On subsequent follow-ups, the serum β – HCG levels kept on dropping and after the fourth course of chemotherapy, the β – HCG had fallen to within normal range. She subsequently received 3 more courses of chemotherapy. She was counseled on contraception during the intended follow-up but opted for hysterectomy. Meanwhile, she is on follow-up in GOPC.

Discussion

The patient presented was a 28 years old para 3+0 who developed a choriocarcinoma following a molar pregnancy and was subsequently started on chemotherapy. Choriocarcinoma is a part of a spectrum of Neoplasms referred to as gestational trophoblastic disease and includes hydatiform and invasive moles. Gestational trophoblastic disease is derived from the trophoblastic tissue of the human pregnancy (chorionic epithelium). Hydatiform mole represents the benign form while choriocarcinoma represents the most malignant form of gestational trophoblastic disease. Invasive mole lies between these two extreme forms.

Hydatiform mole can either be a complete (classical) mole or partial (incomplete) mole. Both the complete and partial moles share common clinical features but they differ in morphology, histologically and karyotyping. Gestational trophoblastic disease is unique because its among the rare human tumors that can be completely cured even in the presence of wide-spread dissemination (1,2).

Hydatiform mole is the most common form of gestational trophoblastic disease. Its incidence varies greatly worldwide from 1 in 125 deliveries in Mexico and Taiwan to 1 in 1500 deliveries in the United States (2). Choriocarcinoma is rare, being reported in 2-5% of all cases of gestational trophoblastic disease. Its incidence in the United States is 1 in 40000 pregnancies, but it's noted to be higher in the orient. About 50% of all choriocarcinoma cases, the antecedent gestational event is hydatiform mole.

About 25% follow term pregnancy and the remainder follows abortion and ectopic pregnancy (1,2,3). At Kenyatta National Hospital, Fongoh (1984) found an incidence of 1 in 1118 deliveries (4). Makokha et al reported only 65 cases in 1975 and 1979 at KNH, and 50% of the cases had antecedent gestational event as hydatiform mole (5).

The patient presented had choriocarcinoma and the antecedent gestational event was hydatiform mole.

The risk factors associated with gestational trophoblastic disease includes nutritional deficiencies especially proteins, folates and carotene, low socio-economic status, maternal age over 40 years, nulliparity, previous history of molar pregnancy and geographical location.

Maternal age above 40 years is associated with five times risk compared to maternal age of 21 to 25 years, probably due to the fact that ova from older women may be more susceptible to abnormal fertilization (1,2,3). Another remarkable finding is that blood group A women impregnated by blood group O men have an almost 10 times increase of risk of developing choriocarcinoma than blood group A women impregnated by blood group A men. Women with blood group AB have been found to have a relatively poor prognosis (2,3,6).

The patient presented was a 28 years old para 3+0 with no previous history of molar pregnancy. Her blood group was O while her husband's blood group was B.

The diagnosis of choriocarcinoma requires a high index of suspicion. History of persistent or irregular per vaginal bleeding following an abortion, a molar pregnancy or even a normal delivery should always raise the suspicion of choriocarcinoma. The haemorrhage is characteristically intermittent and it may be profuse but sometimes only spotting.

The bleeding is arterial and can arise from a nodule in the vagina or form one in the uterus. As the condition advances, an offensive vaginal discharge develops and cachexia with pyrexia supervenes. The disease may also present by way of its metastases. Dyspnoea and haemoptysis are noticed with lung metastasis. Neurological symptoms, such as headache, visual disturbances, hemiplegia or convulsions, may occur with brain metastasis.

Convulsions may occur with brain metastasis. Vaginal metastasis appears as bluish red vascular tumor which bleeds easily on touch. The uterus may be disproportionately enlarged compared to the period of amenorrhoea and occurs in about 58% of cases.

Important investigations in the diagnosis and management of choriocarcinoma include serum or urinary human chorionic gonadotrophins (β -HCG) levels. The amount of beta-HCG found in the serum or excreted in urine correlates closely with number of variable tumor cells present. It's estimated that a single tumor cell produces about 5×10^5 to 5×10^4 iu of HCG in 24 hours (1,2,6).

Optimal management of choriocarcinoma requires a thorough assessment of the extent of the disease prior to the initiation of treatment. A careful pre-treatment evaluation includes the following (1): -

1. Complete history and physical examination.
2. Measurement of the serum HCG level.
3. Hepatic, thyroid, and renal function tests.
4. Determination of baseline total blood count.

Metastatic workgroup should include the following: -

1. Chest X-ray or computed tomography (CT) scan.
2. Ultrasonography or CT- scan of the abdomen and pelvis.
3. CT or magnetic resonance imaging (MRI) scan of the head.

Liver ultrasonography and CT scanning will reveal most hepatic metastases in patients with normal liver function tests. Ct or MRI scan of the head may facilitate the early diagnosis of asymptomatic cerebral lesions. Chest CT-scan may demonstrate micrometastasis not visible on a chest X-ray.

The patient presented had elevated β – HCG levels while the chest X-ray was normal. The renal and liver function tests were also normal.

Choriocarcinoma is anatomically staged according to the International Federation of Gynaecology and Obstetrics (FIGO). The staging is as follows: -

Stage I: Disease confined to the persistently and uterus elevated levels.

IA: Disease confined to the uterus with no risk factors.

IB: Disease confined to the uterus with two risk factors.

Stage II: Patient has metastases to the vagina and pelvis or both.

IIA: The disease involves genital structures without risk factors.

IIB: Disease extends beyond the uterus but limited to the genital structures with one risk factor.

IIC: Disease extends beyond the uterus but limited to the genital structures with two risk factors.

Stage III: Pulmonary metastasis with or without (genital tract) uterine, vaginal or pelvic involvement. The diagnosis is based on arising HCG levels in the presence of pulmonary lesions on chest radiograph.

IIIA: Disease extends to the lungs with or without genital tract involvement and with no risk factors.

IIIB: Disease extends to the lungs with or without genital tract involvement and with one risk factors.

IIIB: Disease extends to the lungs with or without genital tract involvement and with two risk factors.

Stage IV: All other metastatic sites.

IVA: All other metastatic sites with no risk factors.

IVA: All other metastatic sites with one risk factor.

IVA: All other metastatic sites with two risk factors.

The risk factors considered in the staging include the following: -

1. Beta – HCG levels greater than 100000 m lu/mL.
2. The detection of disease more than 6 months from termination of the antecedent pregnancy.

In addition to the anatomic staging, it is important to consider other variables to predict the likelihood of drug resistance and also to assist in selecting appropriate chemotherapy. A prognostic scoring system proposed by the World Health Organization (WHO) reliably predicts the potential for resistance to chemotherapy (1,2,3,7).

THE WHO PROGNOSTIC SCORING SYSTEM.

Score	0	1	2	4
Age(years	<=39	>=39		
Antecedent Pregnancy	Hydatiform mole	Abortion	Term	
Interval between end of antecedent pregnancy and start of chemotherapy (MONTHS)	<4	4 TO 6	7 TO 12	>12
B – HCG (m/u/ml)	<10 ³	10 ³ to 10 ⁴	10 ⁴ to 10 ⁵	> 10 ⁵
ABO Groups		A or O	B or AB	
Largest tumor, including uterine (cm)	<3	3 to 5	> 5	
Size of metastases		Spleen/ kidney	GIT/ liver	brain
Number of metastases		1 to 3	4 to 8	> 8
Prior chemotherapy			Single drug	Two or three drugs.

The individual scores for each prognostic factor are added together to obtain total score. A total score less than or equal to 4 is considered low risk; total score of 5 to 7 is considered medium risk and a total score of 8 or more is considered high risk.

The patient presented scored 5 and therefore placed under medium risk.

Choriocarcinoma is a highly curable disease even with widespread metastases. In fact, chemotherapy is the main stay of treatment of choriocarcinoma; low risk (score of <=4) or non-metastatic disease is treated with single agent drug therapy. Methotrexate with folinic acid rescue regime is used. Actinomycin D, or Bleomycin may also be used. Methotrexate may be given intramuscular or intravenous at a dose of 0.2 to 0.4mg/kg/day for 5 days or on alternate days.

Adverse effects of methotrexate includes, bone marrow suppression, liver and renal toxicity, stomatitis, vaginitis, gastroenteritis and ulceration of mucosal epithelial surface. Folinic acid given alternating with methotrexate as rescue regime reduces the frequency of toxicity and improves remission rate (6,7,8).

High risk and medium risk patients are treated with combination chemotherapy, often triple therapy. A protocol comprising methotrexate, Actinomycin-D and cyclophosphamide (MAC) is commonly used. Methotrexate is administered at a dose of 0.4mg/kg/day intravenously for 5 days, Actinomycin-D at a dose of 10 to 12mg/kg/day intravenously for 5 days and Cyclophosphamide at a dose of 3 – 5mg/kg/day intravenously for 5 days.

A combination drug therapy is EMACO regime which comprises Etoposide, methotrexate, Actinomycin-D Leucovorin calcium alternating with vincristine and cyclophosphamide. The EMACO regime results in response rate of about 90%. At Keyatta National Hospital, MAC is the commonly regime while EMACO regime is reserved for MAC therapy failure.

The patient presented was categorized as medium risk and received the methotrexate, Actinomycin-D and cyclophosphamide (MAC) regime.

Before every treatment course, β -HCG levels, total blood count, liver and renal function tests must be done. Treatment is withheld in case of toxicity or in situation where the above stated tests are abnormal.

Haemoglobin level must be at least 10g/dL, platelet count of at least 100000/mm³ and WBC count of at least 3 x 10⁹/L. Abnormal parameters must be corrected before resuming chemotherapy.

Treatment is repeated after a rest period of 7 days until remission is achieved. Remission is said to have occurred if 3 consecutive beta – HCG levels are negative. Further 3 courses of chemotherapy are given after the first negative (normal) beta – HCG result to prevent relapse.

The patient presented had total blood count, liver and renal functions tests done before resuming each course of chemotherapy. She received 3 courses of chemotherapy before the beta – HCG level dropped to normal levels after which she received 3 further courses of chemotherapy.

Following remission, the patients are followed-up with 2 weekly beta – HCG levels for 6 months, then monthly for the next 1 year. Pregnancy is avoided for at least one year after completion of the chemotherapy so as to allow wastage of the damaged ova, and allow monitoring of relapse. The patients are advised to use the combined oral contraceptive pill.

Surgery may have a place in management of choriocarcinoma, as either primary treatment or secondary after chemotherapy. Total abdominal hysterectomy (TAH) is undertaken in situation where there is intractable bleeding or accidental uterine perforation during uterine lesion unresponsive to chemotherapy or for those who have attained desired family size. Patients with brain metastases may require whole head irradiation with 3000 rads in 10 days (1,2,6,8).

The patient presented opted for hysterectomy since she had attained desired family size. The prognosis of non-metastatic disease is good with 100% remission rates and about 70-79% remission rates in high-risk metastatic disease. Cure is said to have been attained after a period of 5 years in remission (1,2,3,6,8).

References

1. Ross S.B, Donald P.G.
Gestational trophoblastic disease.
In: Novak's Gynaecology, 13th ed. Lippincott – Williams and Wilkins, Philadelphia, 2002; page 1353 – 1371.
2. April G.O, David E. B.
Gestational trophoblastic disease.
In: Current Obstetrics and Gynaecologic diagnosis and treatment, 8th ed, Appleton and Lange, 1994; page 967 – 976.
3. Dutta D.C.
Genital malignancy.
In: Textbooks of Gynaecology, 3rd ed, New Central Agency, 2001; pg 334 – 341.
4. Fongoh F.B.
Cinical and laboratory evaluation in the management of choriocarcinoma at KNH.
M. Med thesis UON 1984.
5. Makokha A.E, Mati J.K.G.
Choriocarcinoma at Kenyatta National Hospital.
Journal of Obstetrics Gynaecology for East and Central Africa 1:27: 1982.
6. Cunningham F.G, Gant F.G, Levono K.J.
Diseases and abnormalities of the placenta.
In: Williams Obstetrics, 21st ed, McGraw-Hill, 2001; page 827 – 849.
7. Goldstein D.P, Vzanten P.I.
Revised FIGO staging system for gestational trophoblastic tumors: recommendation regarding therapy.
J. reprod. Med. 1998; 43: 37 – 43.
8. Macdonald T.W, Ruaiilo E.N.
Modern management of gestational trophoblastic disease.
J. Obstet. Gynaecol. Survey 1992; 38: 67.
9. Plamsomboou S. Kudelka A.P.
Remission of refractory gestational trophoblastic disease in the brain with ifosfamide, carboplatin and Etoposide (ICE).
European journal of Gynaecologic oncology: 18(6); 453; 1997.

Case No. 12

IUCD WITH MISSING THREADS - RETRIEVAL

Name:	MW	Parity:	4+0
Age:	54 years	DOA:	4.10.02
IP No:	0839802	DOD:	8.10.02

Presenting History

The patient had presented with lower abdominal pain and backache for 3 months. She had an IUCD inserted in 1981 (21 years ago), had not felt the threads for unknown duration and had never seen it come out. Attempted removal at the family planning clinic was unsuccessful. Hence her admission to the acute gynaecological ward for retrieval under general anaesthesia.

Obstetric and Gynaecologic History

She was a 54 years old para 4+0 whose last delivery was in 1981. All her children were delivered by spontaneous vertex delivery and were alive and well. She could not recall her menarche. Her menses were irregular for the preceding eight months, lasting 4-5 days. She was no longer sexually active. The IUCD was inserted a few months after delivery and had never gone for check up ever since.

Past Medical/ Surgical History

These were not significant

Family and Social History

She had been widowed for the past one year and was a peasant farmer in Murang'a. She did not smoke cigarettes or drink alcohol. She had no family history of chronic illnesses.

Physical Examination

General Examination

She was in good general condition, not pale, afebrile, and no oedema. Her vital signs were; blood pressure was 120/80mmHg, respiratory rate of 18/minute, pulse rate of 80/minute, regular and of good volume. The temperature was 36.8 degrees centigrade.

Abdominal Examination

The abdomen was scaphoid and moved with respiration. There were no surgical scars, no organomegally, no masses and no areas of tenderness.

Other Systems

Central nervous, cardiovascular and respiratory systems were essentially normal.

Pelvic Examination

She had normal external genitalia. The vagina was showing some signs of atrophy – loss of rugae and was apparently shorter. The cervix looked normal but short, closed and no visible threads. On digital examination, the uterus was of normal size, the adnexae and POD were free and no tenderness. There was no blood or discharge on the gloved examining fingers.

Diagnosis

A diagnosis of misplaced IUCD was made.

Investigations

1. Full haemogram

Haemoglobin-12.3g/dl, WBC- $7.5 \times 10^9/L$, RBC - $4.64 \times 10^{12}/L$, Haematocrit- 37.9%, MCV -81.6fl and platelets- $423 \times 10^9/L$.

2. Urea and electrolytes

Urea- 3.5 mmol/l, creatinine- 98micromol/L, sodium -136 mmol/L and potassium -4.2 mmol/L.

3. Ultrasound

Showed a normal uterine size, anteverted and an IUCD in situ. No pelvic masses were seen.

Management

Though the patient had been explained what will be done while at the family welfare clinic, she was nevertheless explained again about her condition and the intended management. She gave an informed consent for the removal of the IUCD by dilation and the curetage under general anaesthesia.

She was starved from midnight and was premedicated with atrophine 0.6mg and pethidine 50mg intramuscularly half an hour before theatre.

In the theatre she was placed in supine position and general anaesthesia induced. She was repositioned to lithotomy position. Vulvovaginal toilet (VVT) was done, draped and about 80mls of clear urine obtained by aseptic catheterization.

Examination under anaesthesia confirmed earlier findings. Anvards speculum was used to expose the cervix, and its anterior lip grasped using a tenaculum forceps. The sounding of the uterus was done, and found to have 8cm long uterine cavity.

The cervix was dilated gradually by Hegars dilators, starting with dilator size 5 and graduating to size 8. A curved artery forceps was gently introduced into the uterine cavity attempting severally to grab the device. Finally the device was successfully grabbed and withdrawn. The device was preserved to be shown to the patient when fully awake. Minimal bleeding was noted. Reversal of the general anaesthesia was successful and the patient wheeled to the recovery room.

Post Operative

The patient did well postoperatively. Various contraception options were discussed with the patient. However, she declined any since she was widowed, no longer sexually active and was experiencing peri-menopausal symptoms.

Discussion

The patient had an IUCD as a method of family planning for 21 years. She developed a common complication of the threads disappearing into the uterine cavity. Through dilation and curettage under general anaesthesia, the IUCD was removed.

The intrauterine device is not a new method of contraception. During the last couple of decades, however, there has been a significant improvement in both its design and content. The idea being to obtain a device with maximum efficacy without increasing the adverse effects. The idea being to obtain a device with maximum efficacy without increasing the adverse effects. The device may be non-medicated such as Lippes Loop or medicated (Bioactive) by incorporating a metal copper in devices like Copper T-200, Copper T-380A, multiload –250 and Multiload – 375. Others are hormone-containing devices, such as progesterone or levonorgestrel, which have also been introduced into the market (1,2). The patient presented had a Copper-T intrauterine device.

The mechanism of anti-fertility effect of all types of IUCDs is not yet clear. However, they act predominantly in the uterine cavity and do not inhibit ovulation (1,2,3).

Probable mechanisms are (1);

- Non-specific inflammatory reaction and biochemical changes in the endometrium are thought to have gametotoxic and spermicidal effect. Lysosomal disintegration from the macrophages attached to the device liberates prostaglandins, which may have anti-fertility effect.
- Increased tubal motility may results in quick migration of the fertilized ovum to the uterine cavity before the endometrium is receptive.
- Copper devices- Ionized copper has got an additional local anti-fertility effect by preventing implantation through enzymatic interference. Copper initiates release of cytokines, which are cytotoxic.
- Levonorgestrel-containing device strongly induces suppression of endometrial proliferation and the cervical mucus becoming very scanty.

Intrauterine devices have nylon threads attached, which hang through the cervix into the upper vagina. By self-palpation of the threads, women confirm that the device is still in place and make the removal easy. Missing threads may indicate expulsion or translocation of the device although the strings may coil up to lie within the cervical os or the uterine cavity. A speculum examination is necessary to confirm the missing threads. *Never assume that the device has been expelled unless it was seen* (3). The life span of Copper- T is ten years: when it should be replaced.

The patient presented had the device for 21 years and whose missing threads from the vagina were confirmed by speculum examination.

Removal of IUCD before its lifespan is indicated if there is persistent excessive menses, down ward displacement of the device into the cervical canal or vagina, missing threads, persistent severe abdominal pain, suspected uterine perforation, pelvic infections and one year after menopause (5).

The patient presented had the threads missing and was no longer sexually active.

When the threads are missing from the cervical os, the device can be located by a two dimensional radiography with a marker-IUCD, hysterosalpingography, hysteroscopy or ultrasonography (1,2,3)

In majority of cases, ultrasonography is preferred because it is able to demonstrate whether the device is in the uterine cavity or not, will diagnose pregnancy with the device. It is also fast in making the diagnosis and hazard free (2,3).

The patient presented had a diagnosis of misplaced intrauterine device without pregnancy by the ultra-sound.

The incidence of uterine wall perforation is approximately 1 in 1000 to 2000 insertions and majority of perforations occur at the time of the insertion especially in the postpartum period. A displaced IUCD in the peritoneal cavity may cause peritonitis, adhesions or organ penetrations hence the urgency to remove it through laparoscopy or laparotomy when the diagnosis is confirmed. An intense local inflammation is encountered with copper-T device and may require laparotomy for its removal due to firm adherence (3,4).

Apart from uterine perforation, other numerous complications have been associated with various intrauterine devices.

Uterine cramping and bleeding usually develop soon after insertion and may persist for a variable period. Blood loss during menstruation may be doubled or just increased with the use of the IUCD and may cause iron-deficiency anaemia (1,3). Pelvic infection may also be observed with a variety of IUCDs. In suspected pelvic infections, the device should be removed. An increased prevalence of *actinomyces Israeli* isolation in patients with the IUCD has been observed in most studies (1,2,3). There is a 50% risk of abortion in pregnancy with an IUCD in situ compared to those with prompt removal. There are four times more chances of pre-term delivery with a device in situ. However, no increased foetal malformation has been reported in pregnancies complicated by the device (3,5).

Although IUCD prevents most intrauterine pregnancies, the device provides less protection against extra uterine nidation. With contraception failure, the risk of ectopic pregnancy increases significantly (2,3,5)

References

1. Dutta D.C
Contraception
In: Textbook of gynaecology, 5th Ed, New Central Publications, 2001; Pg 438 – 445

2. Ronald T.B
Contraception and Family Planning
In: Current obstetric and gynaecologic diagnosis and treatment, 8th Ed, Appleton and Lange, 1994; Pg 679-682

3. Cunningham F.G Norman FG
Family Planning
In: Williams Obstetrics, 21st Ed., McGraw and Hill, 2001; Pg 1518-1548

4. Johnson N Moodley J
Retrieval of IUCD with Missing Tail
Br. J Obstet. Gynaecol. 95: 97; 1988

5. A Cog Technical Bulletin no. 164 – Sept. 1992
The Intrauterine Device
Int. J. Obstet. Gynaecol. 41: 184-193; 1993

Case No. 13

DESIRED FAMILY SIZE - BILATERAL TUBAL LIGATION

Name:	TKM	Parity:	5+0
Age:	31 years	DOA:	8/11/02
IP No:	0845352	DOD:	8/11/02

History of Presenting Complaint

The patient had been referred from the post-natal clinic after having requested for a permanent surgical contraception because she had attained her desired family size.

The patient accompanied by her spouse were further counseled on bilateral tubal ligation and given information about the procedure. She did not have any difficulty in comprehending the procedure. They both gave an informed consent for the operation.

Obstetric and Gynaecologic History

She was a para 5+0 and her last delivery was on 14.9.02. All her deliveries were by spontaneous vertex delivery. All the children were alive and well. She had her menarche at 14 years of age. Her menses lasted 3 to 4 days, recurred every 28 days and had no associated dysmenorrhoea. She was about 7 weeks postpartum but had not resumed sexual activities. She had used oral contraceptives in between other pregnancies.

Past Medical and Surgical History

This was not contributory

Family and Social History

She was married, a business lady and lived at Kawangware. The husband was a waiter at a city hotel. Neither smoked cigarettes nor consumed alcohol. There was no family history of chronic illnesses.

Physical Examination

General Examination

She was in good general condition, not pale, not jaundiced, afebrile and no peripheral oedema. Her vital signs were: Blood pressure 110/60mmHg, pulse rate of 72 beats per minute, regular and of good volume. The respiratory rate was 18/minute and a temperature of 36.7 degrees centigrade. She weighed 61kg.

Abdominal Examination

The abdomen was scaphoid and soft. There were no surgical scars, no tenderness, no organomegaly and no palpable masses.

Pelvic Examination

She had normal female external genitalia. The cervix was firm, posterior, about 2.5cm long and os was closed. The uterus was of normal size, anteverted and freely mobile. The adnexae were not tender and were free of masses. The pouch of Douglas was empty. There was no vaginal discharge or blood on examining fingers.

Other Systems

The cardiovascular, central nervous and respiratory systems were essentially normal.

Diagnosis

She was a para 5+0 with completed desired family size, suitable for surgical sterilization via interval minilaparotomy.

Management

Although the counseling had been done before, it was revisited once again with great emphasis on the benefit of the procedure and the possible risks involved.

She was instructed to starve from midnight the day before and come to the clinic on the operation date (8/11/02) at 7am, accompanied by her spouse or someone else who would accompany her back home after the procedure. She presented herself at the clinic as per the appointment.

Operation

The vital signs were found to be within the normal range. She was given atropine 0.6mg intramuscular thirty minutes before the operation. In theatre she was placed in semi-lithotomy position, vulvovaginal toilet and aseptic catheterization done. About 20mls of clear urine was obtained.

Speculum examination was performed which reviewed a normal cervix and vaginal walls. The cervix was cleaned with antiseptic solution and uterine elevator introduced gently through the cervical canal. The speculum was removed and the patient repositioned to supine with her legs together.

The abdomen was cleaned, draped and 15mls of 1% Lignocaine was infiltrated at the abdominal wall at a point 2-3cm above the pubic tubercle in a diamond pattern until a field block was established. The area was gently massaged and the effectiveness of the local anaesthesia was tested with a needle prick. A transverse incision measuring about 3cm long was made on the midline and the abdomen opened in layers. The peritoneum was opened carefully to avoid bladder or gut injury. The table was then placed in Trendelburg's position and the patient asked to retract her lower abdomen as if she was putting on a tight skirt. By manipulating the uterine elevator, each tube was in turn brought into view through the incision. With the aid of the tubal hook, each tube was grasped with a Babcock forceps. Lignocaine was sprayed over the tube to aid analgesia. The fimbrial ends were visualized to confirm indeed it was the fallopian tube.

Pomeroy's technique was employed to occlude the middle portion of the tube, and using chromic catgut number 0, the base of the knuckle was tied and the loop above the ligated area excised. The tube was checked to ensure haemostasis was achieved. The same procedure was repeated on the opposite side.

The abdomen was closed in layers, wound dressed and the uterine elevator removed. The patient was then wheeled to the recovery room.

Post Operative Management

The patient's vital signs were monitored half hourly for one hour and hourly for the next three hours. The vital signs remained normal.

The patient was then discharged home on Ibuprofen 400mg thrice a day for three days and Amoxycillin 500mg 8 hourly for 5 days. She was instructed to keep the wound clean and dry, and how to recognize signs of complications. She was to be reviewed after one week.

Follow Up

She came to the clinic as per the appointment. She had no complaints, the wound had healed well and her vital signs were normal. She was discharged from the clinic but explained the need for yearly pap smear.

Discussion

The patient presented was 31 years old para 5+0 who had attained her desired family size and was done interval bilateral tubal ligation.

Bilateral tubal ligation is the mechanical blockage of the fallopian tubes to prevent spermatozoa from reaching the ovum (1). Tubal ligation can be done during the immediate postpartum period (within 48 hours of delivery), during the caesarean section or 6 weeks or more after delivery – also called interval sterilization (2).

The patient presented had interval sterilization.

Tubal sterilization was first performed in 1823 to prevent pregnancy in women who would need repeated caesarean section (3). Today, it has become the most popular and widely used permanent method of contraception for both the developing and developed countries (3,4). In the United States, the rate of tubal sterilization has increased by 164% for the period between 1970 and 1980. Currently, 700,000 women in the United States choose tubal sterilization yearly. However in most African countries, the rate of sterilization is still low. This could be as a result of high infant mortality rate and thus the fear of permanent sterilization. However, the continued economic and social pressures to limit the family size may increase the rate of tubal sterilization in the coming years (3,4,5).

Tubal sterilization is a good option for couples that have attained the desired family size and need a reliable contraception. This method is also indicated for women with medical disorders that are likely to worsen if repeated pregnancies occur. These include heart diseases, diabetes mellitus and chronic renal failure among others (3,4).

The patient presented opted for the tubal sterilization after attaining the desired family size.

Tubal sterilization can be done either abdominally or transvaginally. The abdominal approach is the commonest and can be done either through minilaparotomy or laparoscopic. Minilaparotomy involves tubal sterilization through a small incision on the abdominal wall. It can be done under local anaesthesia, sedation or general anaesthesia.

In the third world countries, minilaparotomy remains the mainstay in the national family planning programme as a method of permanent sterilization. It is safe, has a wider applicability, is less expensive and has a lower failure rate compared to the laparoscopic or transvaginal tubal sterilization (4).

Laparoscopic tubal sterilization is becoming popular especially in the developed countries. It is not done or recommended within six weeks following delivery (4). Transvaginal tubal sterilization via culdotomy or culdoscopy is technically more difficult than the transabdominal sterilization. The transvaginal approach is associated with a higher infection rate and often-higher failure rate (3,4,6).

The patient presented had tubal ligation through minilaparotomy under local anaesthesia.

There are various techniques of tubal occlusion. The most popular methods with the minilaparotomy procedure include (4,6);

1. **Modified Pomeroy's** procedure – a loop of the fallopian tube that consists the isthmus and part of the ampullary part is ligated and the knuckle above the ligature is excised
2. **Madlener** procedure – a knuckle of the fallopian tube is crushed and then ligated without resection
3. **Kroener** procedure – the tube is ligated across the ampulla and the distal portion of the ampulla including all of the fimbriae is resected.
4. **Irving** Procedure – the medial cut end of the fallopian tube is buried in the myometrium and the stall end is buried in the mesosalpinx
5. **Parkland** Procedure – A mid segment of the tube is separated from the mesosalpinx at an avascular area or site, and the separated tubal segment is ligated proximally and distally and then excised.

The modified **Pomeroy's** method is the procedure of choice for tubal sterilization at KNH.

The patient presented had tubal occlusion by Pomeroy's method.

Laparoscopic techniques of tubal occlusion include (2);

- a) Pomeroy's
- b) Fulguration – Electrocoagulation with or without excision or division
- c) Clips such as spring loads clips or tantalum clips
- d) Bands such as Falope rings

The main disadvantage of laparoscopic approach is that laparoscopes are expensive, difficult to repair and maintain, and require a lot of skill to operate. In our setting they are not commonly used.

Tubal sterilization is generally safe and complications usually occur in less than 1% of all sterilization cases (4). The use of general anaesthesia, previous pelvic or abdominal surgery, history of pelvic inflammatory disease, obesity and diabetes mellitus increase complications. Common complications reported include anaesthetic complications, uterine perforations with the uterine elevator, bladder and intestinal injury, sterilization failure and wound sepsis. Most of these complications can be minimized by the use of local anaesthesia, aseptic techniques and meticulous surgical techniques (3,5).

The overall failure rate in tubal occlusion is 0.7%; the Pomeroy's technique having the lowest (0.1-0.3%) and the Madlener's technique having the highest (1.5-3%). The failure rate is increased when it is done during hysterotomy or during caesarean section.

Major reasons that account for the failure of peripheral sterilization include (6);

- Surgical errors, which include transection of the round ligament instead of the oviduct or a partial transection of the oviduct.
- Formation of a fistula tract between the severed tubal stumps or spontaneous re-anastomosis.

Failure rate has also been noted to be highest in the transvaginal approach than through transabdominal tubal sterilization (4,6). However, many “failures” occur during the first month after sterilization and are as a result of a pregnancy already existing at the time of sterilization. It is therefore important that interval sterilization is carried out during the proliferative phase of the menstrual cycle when the patient is least likely to be pregnant (6,7).

Many sterilization failures carry a high risk of being an ectopic pregnancy. Infact, any symptoms of pregnancy in a woman after tubal sterilization must be investigated to exclude an ectopic pregnancy (4,6,7)

Post-natal ligation syndrome, which is variably characterized by pelvic discomfort, ovarian cyst formation and abnormal menstrual patterns have been described following tubal sterilization (4,6). However, specific and describable patterns of bleeding after sterilization have not been convincingly demonstrated (6).

Infact, majority of the studies find no change, unpredictable changes or changes that could be best explained on the basis of discontinuing the oral contraceptive pills or IUCD (4,6,7). Although complete the transection of the oviduct is mandatory, it is desirable at the same time to preserve the blood supply through the adjacent mesosalpinx. This can be achieved by avoiding techniques that may cause obstruction of the tubo-ovarian artery. This is likely to minimize the possibility of post-tubal ligation syndrome (4,6,7).

No woman should undergo tubal sterilization believing that her fertility can be restored. Couples must be properly counseled and understand the permanency of the procedure, its occasional failure rate and its alternatives. Unfortunately, regret and upsets are not uncommon. Procedures for restoring fertility are costly, difficulty and uncertain. Success rates vary greatly, depending upon the age of the woman and the technology utilized (4,5,6,7).

The patient presented and her partner had proper counseling regarding the complications that may arise from the tubal sterilization and the permanency of the procedure before giving an informed consent.

References

1. Hatcher R.A, Rinehart W, Geller J
Female Sterilization
The Essentials of Contraceptive Technology – A handbook for clinic staff,
John Hopkins Population Information, July 1997; 9-2
2. Hatcher R.A, Kowal D, Stewart G.K
Voluntary Surgical Sterilization
Contraception Technology International Edition, 1989; 209-234
3. Russell L.M, Carol A.W, Wheeler JM
Therapeutic Gynaecologic Procedures
In: Current Obstetric & Gynaecologic diagnosis and Treatment, 8th Ed, Appleton
and Lange, 1994; Pg 891-3
4. Dutta DC
Contraception
In: Textbook of Gynaecology, 3rd Ed, New Central Publications, 2001; Pg 455-
460
5. US Department of Health and Human Services
Centre for Disease and Control: Tubal Sterilization and Vasectomy
Family Planning methods and practice: Africa 2nd Ed, CDC, 1999; pg 507-543
6. Cunningham FG, Norman FG
Sterilization
In: Williams Obstetrics, 21st Ed, McGraw-Hill Publications, 2001; Pg 1555-1561
7. Stubblefield P G
Family Planning
In: Novak's Gynaecology, 13th Ed, William and Wilkins, Philadelphia, 2002; Pg
258-264

Case No 14

PRIMARY INFERTILITY-LAPAROSCOPIC TUBOPLASTY

Name:	M.A	Parity:	0+0
Age:	30 years	DOA:	30.03.04
IP NO:	0751963	DOD:	3.04.04

Presenting Complaints

The patient was admitted with history of inability to conceive for six years.

History of presenting complaints

The patient was admitted with a history of inability to conceive for 8 years despite having regular unprotected coitus at an average frequency of three to four times a week. She gave no history of deep dyspareunia. She had no history of sexually transmitted infections or abnormal vaginal discharge and had never used any contraception. She was treated for pelvic inflammatory disease in the year 2000 based on the hysterosalpingogram findings. Her husband was 33 years old and had five children with the first wife.

Obstetric and Gynaecologic History.

She was nulliparous and her menarche was at 16 years. Her last menstrual period was on 19.03.04. Her menses lasted 3 days, recurred after 30 days, regular and associated with mild dysmenorrhoea. She gave no history of contraception or prior surgery.

Past Medical and Surgical History

There was nothing remarkable about her past medical and surgical history.

Family and Social History

She was married as a second wife, unemployed and stayed with her husband at Kawangware. Her husband was a tailor at Kenyatta market. Her co-wife stayed at her rural home in Kisumu. Neither smoked cigarette nor consumed alcohol.

There was no family history of chronic illnesses.

Systemic enquiry

This was non-revealing

Physical Examination

General Examination

Physical examination revealed a relatively young woman in good general condition. She was not pale, not jaundiced, afebrile no peripheral oedema and no lymphadenopathy.

She had no neck swelling anteriorly, her breasts were well developed with no discharge and had a normal female body contours and hair distribution.

Pelvic Examination

She had a normal female external genitalia and a normal pubic hair distribution. The cervix was firm, posterior and the os closed. The uterus was of normal size, anteverted and mobile. The adnexae and pouch of Douglas were free. Cervical excitation test was negative.

Other Systems

The cardiovascular, respiratory and central nervous systems were essentially normal.

Investigations

1. Seminalysis – Volume 2.8mls, PH 8, count 48 million/mm³ mortality 70% with progressive motility, morphology 85%, colour cream-white, liquefaction 30 minutes and WBC count 0.5 x10⁶/ml.

Conclusion -Normospermia.

2. Hysterosalpingogram (HSG) – Showed a normal uterine size and cavity. Right tube had terminal (fimbrial) blockage. Left tube had terminal dilation due to hydrosalpinx with no spill demonstrated.
3. Ultrasound – Uterus was of normal size and echopattern, endometrial stripe was within the normal limit. There was an approximately 4.0x 2.9cm. Right adnexal cystic mass. Left adnexa, pouch of Douglas and urinary bladder were normal.

UNIVERSITY OF NAIROBI
MEDICAL LIBRARY

4. Papanicolaou (pap) smears – was reported as normal.
5. ELISA for HIV – Negative.
6. Urea and Electrolytes – Sodium 142mmol/l, potassium 4.4mmol/l, urea 5.1mmol/l and creatinine 76µmol/l.
7. Full Haemogram – WBC $6.5 \times 10^9/l$, haemoglobin 16.2g/dl and platelets $261 \times 10^9/l$.

Diagnosis

A diagnosis of primary infertility due to tubal factor was made.

Management

The patient was explained the nature of her condition and the intended management. She gave an informed consent for laparoscopic tuboplasty. On the evening before the operation day, she was given oral metronidazole 1-gram stat and two tablets of Dulcolax. She was starved from mid-night and enema given in the morning. Thirty minutes before theatre, she was injected 50g of pethidine and 0.6g of atropine sulphate both intramuscularly.

Operation

In theatre, general anaesthesia was induced. She was placed in semi-lithotomy position and vulvovaginal toilet done. The vagina and cervix were painted with iodine solution. The abdomen was cleaned and draped. She was then aseptically catheterized, 40mls of clear urine obtained and the catheter left in situ for continuous bladder drainage. Examination under anaesthesia confirmed earlier examination findings.

The anterior lip of the cervix was held by tenaculum and a cervical canular inserted gently and hooked to the tenaculum to remain secured in position. The patient was then placed in trendelenberg position.

A periumbilical stab was made and the Veress needle pushed into the abdominal cavity. Carbon dioxide gas was then introduced up to three litres to cause a pneumoperitonium. The trocar was then removed and the fibre optic camera fixed in place. The uterus was visualized and appeared normal.

A right ovarian cyst measuring 5x5cm was visualized. Both fallopian tubes had moderate peritubal adhesions and bilateral terminal blockage.

Two incisions were made in both franks for the introduction of surgical instruments. Right cystectomy was done which showed features of a haemorrhagic cyst. The right tube was freed by adhesiolysis with the fimbriac being visualized. The left tube was also freed and both tubes had dye spill demonstrated.

Both ovaries appeared grossly normal. Peritoneal lavage was done with warm saline then 5000 I U of heparin and 500mg of reconstituted hydrocortisone left in situ.

The stab wounds were closed, cervical cannular and catheter were removed, and general anaesthesia successfully reversed. The excised cyst was taken for histology.

Post – Operative care.

The patient was wheeled to the recovery room where quarter hourly observations of vital signs were taken until she was fully awake and then 4 hourly while in the ward. She was put on intravenous crystalline penicillin 2mu 6 hourly and gentamycin 80mg 8 hourly for 2 days and thereafter converted to oral Augmentin 625mg twice a day for 5 days. She also received pethidine 100mg intramuscularly every 8 hours for 24 hours and then converted to mefenamic acid 500mg 8 hourly or when necessary. On the first postoperative day, she was started on oral sips and a free diet on the second day.

She was discharged on the fourth postoperative day and booked for review in gynaecology out patient clinic after four weeks.

Follow-Up

The patient came for the appointment on 6.5.04 as scheduled. She had no complaints and was put on clomiphene for ovulation-induction. The histology report revealed a luteal cyst with haemorrhagic walls and lumen.

Discussion

The patient presented was a 30 years old lady with primary infertility due to tubal factor. She underwent laparoscopic surgery where adhesions were released and patency was achieved in both fallopian tubes as demonstrated by the bilateral dye spill. To enhance her chances of conceiving, she was put on ovulation induction medication (clomiphene).

Infertility is defined as failure to conceive within one or more years of regular unprotected coitus in a couple of reproductive age (1,2,3). Infertility can either be primary or secondary. Primary infertility denotes those patients who have never conceived before while secondary infertility indicates previous pregnancy with subsequent failure to conceive within one or more years of regular unprotected coitus. Eight percent of couples achieve conception within one year of regular unprotected coitus while additional 10% will achieve conception by the end of second year. As such, 10% will remain infertile by the end of second year (1,2,3).

The patient presented had never achieved conception despite regular unprotected coitus for six years and therefore had primary infertility.

The incidence of infertility worldwide varies between 10% and 20% of all married couples. In the United States, the incidence is reported as 13.9% among potentially married couples (2,3). The true incidence of infertility in Kenya is known. However, Mati (1986) observed that about 60% of patients attending the gynaecology out patient clinic (GOPC) at Kenyatta National Hospital complained of infertility (4). Conception depends on the fertility potential of both the male and female partner. The male is directly responsible in about 30 – 40%, the female in about 40 – 50% and both are responsible in about 10% of cases. The remaining 10% is unexplained inspite of thorough investigations with modern technical know-how (1,2,3).

The patient presented had infertility due to tubal factor and since the husband had children with the first wife (last born was six months old), and had a normal seminalysis, it is prudent to say that it was the female factor that had caused the infertility.

The aetiology of infertility is multifactorial. A world health organization (WHO) study in developing countries between 1979 and 1984 found that upto 64% of females in Africa and 28 – 35% in other continents had infertility that could be traced to prior pelvic

infection (6). This extrapolated to 49% bilateral tubal occlusion among African women and 11 – 15% among others (6).

At Kenyatta National Hospital, pelvic inflammatory disease (PID) has been blamed for tubal occlusion in over 70% of the cases with gonococcal infection accounting for 55% (6,7). Chlamydia trachomatis has also been found to be a major cause of tubal blockage accounting for even more cases than gonococcal infection especially in the developed world (8). Genital tract tuberculosis is less common occurring in about 2 – 6% of women in Kenya (9).

Although neisseria gonorrhoea and chlamydia trachomatis may be responsible for acute salpingitis, residual chronic salpingitis and subsequent tubal damage is mainly due to secondary invaders, both aerobic and anaerobic (10). The presence of an intrauterine contraceptive device (IUCD) in situ has been known to predispose to pelvic infections. Barrier methods protect against pelvic infections. Other aetiologic factors of infertility include disorders of ovulation, endometriosis and mullerian system defects (2,11).

The patient presented had infertility due to tubal blockage, which probably was caused by previous pelvic infection.

The aetiology of infertility can broadly be classified into male and female factors. The male causes of infertility are generally due to abnormalities in sperm count, motility or morphology as a result of (1,2); -

- Defective spermatogenesis
- Obstruction of the efferent duct system
- Failure to deposit sperm high in the vagina e.g. in the hypospadias
- Errors in the seminal fluid.

Female causes of infertility can be divided into (1,2); -

- Ovulatory disorders
- Tubal/peritoneal factors
- Cervical factors
- Uterine abnormalities.

Tubal and peritoneal factors accounts for 36-44% of causes of female infertility (1,2).

These factors include; -

- Damage or obstruction of the tubes usually associated with previous PID, pelvic or tubal surgery.
- Peritoneal and peri-ovarian adhesions, which may result from PID or pelvic surgery or endometriosis.

The patient presented had tubal blockage and peritubal adhesions probably due to previous pelvic infection.

Factors that affect the reproductive performance of a couple include their ages, frequency of coitus and duration of intercourse. Fertility potential is known to decline with advancing age especially in women above 35 years of age. Coital frequency of 3 times a week has been found appropriate to allow for sperm maturation and is spread over the fertile days. The spermatozoa can survive within the female reproductive tract for 48 to 72 hours while an ovum upon ovulation can survive and be fertilized for upto 36 hours (5,10).

The patient presented had regular coitus averaging a frequency of 3 to 4 times a week.

While evaluating a couple for fertility, it is important to note that either one or both of them may be the cause. Therefore a thorough history and physical examination should be conducted for both the male and female. Five primary tests have been adopted and are useful in the initial evaluation of an infertile couple (1,2,6,8). These are documentation of ovulation, semen analysis, post-coital test (PCT), hysterosalpingogram (HSG) and diagnostic laparoscopy. A pelvic ultrasound is also an important diagnostic tool. Investigations pertaining to the female partner are invasive, expensive and time consuming (11).

Therefore, the preferred initial tests should be cheap, simple and able to provide information on ovulation, tubal patency and surgical prognosis. Routine diagnostic tests include hysterosalpingogram (HSG) and dye laparoscopy. These two tests are complementary in that HSG will confirm tubal patency while laparoscopy will show evidence of pelvic adhesions, ovarian cysts, endometriosis and thus evaluate the possible success of further surgery (8,10,11).

The patient presented had a HSG done that showed bilateral tubal occlusion at the terminal ends while the spouse had a normal seminalysis. On laparoscopy, she was found to have peritubal adhesion and terminal tubal blockage on both sides.

Various methods of tubal surgery have been described including salpingolysis, salpingostomy or fimbrioplasty, end-to-end tubal anastomosis and tubal re-implantation, which have been perfected by microsurgery. Success rate generally depends on patients' selection and is inversely proportional to the severity of tubal damage, the extent and nature of the associated adhesions (8,9,10).

Mild filmy adhesions carry better prognosis than the thick broad and extensive adhesions. The presence of other infertility causing pathology, such as fibroids, endometriosis and pelvic infections, reduces significantly the success rate after surgery (10,12).

Other factors associated with poor outcome following tuboplasty include (12,13);

- Loss of fimbriae
- Bilateral hydrosalpinx especially if larger than 3cm in diameter.
- Length of the reconstructed tube especially if longer than 4cm.
- Cornual blockage

The role of repeat tubal surgery following a failed attempt remains controversial. However, it may be recommended in selected patients preferably those with limited tubal damage (2,13). Female fecundability decreases sharply after 35 years of age and therefore the success rate declines after this age (5,10).

The patient presented was 30 years old with no history of previous surgery and had moderate peritubal adhesions and distal tubal blockage. Peritubal adhesiolysis and fimbrioplasty was done.

Overall, the pregnancy rate ranges between 15 to 60% following tuboplasty with the chance of an ectopic pregnancy being about 10% (1,5,10).

The success rates of salpingo-ovariolysis are reported as 41 to 57% achieving pregnancy, with 5 to 8% being ectopic pregnancy.

In salpingostomy, pregnancy rates range between 20 to 37% with ectopic pregnancy rates of 5 to 18% (12,13). The results of tubo-tubal anastomosis are variable depending on the site of the tube, technique used, the cause of tubal blockage and the experience of the surgeon.

However, the ectopic pregnancy rates are higher in tubo-tubal anastomosis ranging between 13 to 22%. In tubo-cornual anastomosis, pregnancy rates ranges between 33 to 58% with ectopic pregnancy rates of 5 to 7% (5,10).

Prevention of sexually transmitted infections (STI), pelvic infections including puerperal and postabortal sepsis can decrease the incidence of infertility since 65 – 75% of infertility cases are a sequele of an infective process (2). Prompt and appropriate treatment of STIs and other pelvic infections can decrease the disease progression to adhesion formation and subsequent tubal damage (5,10).

References

1. Dutta D.C.
Infertility
In: Textbook of gynaecology, 3rd edition, New Central Publications, 2001; page 212 - 233
2. Hillard P, Berek S, Adashi K et al.
Infertility
In: Novak's gynaecology, 13th edition, Williams and Wilkins Publications, 2002;page 1223-1234
3. Rajan R.
Evolution of infertility management
In: Principles and practice of Obstetrics and Gynaecology for postgraduates, 2nd edition, JayRee brothers publishers 1997; page 266 - 273.
4. Mati J.K.G.
Infertility in Africa; magnitude, major causes and approaches to management.
J obstet. Gynaecol. East and Central Africa 1986; 5; 65
5. Martin M.C.
Infertility
In: Current obstetric and gynaecologic diagnosis and treatment, 8th ed, Appleton and Lange, 1994; page 996 – 1006.
6. Gates W, Farley T.M,
World partners of infertility
Lancet, 1985; 2: 596 – 598.
7. Mati J.K.G, Anderson G.E,
A second look into the problem of primary infertility in Kenya.
East Afr. Med, 1973; 50: 94

8. Tenore A.C, Levotti M et al.
Efficiency of external cephalic version performed at term.
European J. Obstet. Gynaecol. And reproductive biology: 76 (2): 161-163; 1998
9. Sciara J.
Infertility, selected topics of international interest; fertility, sterility and contraception.
12th world congress of Gynaecol. Obstet, 1999.
10. Gomel V.
Reconstruction tubal surgery.
In: Te linde's operative gynaecology, 8th Ed, Lippincott Raven Publications, 1997; page 549 – 584.
11. Speroff L, Glass R.H, Kase N.G.
Investigation of infertile couple.
In: clinical Gynaecologic Endocrinology and infertility; 5th Ed, Williams and Wilkins, 1996; page 513 – 540
12. Reiss H.
Management of tubal infertility in the 1990's
Br J. obstet. Gynaecol. 1991;98: 619 – 623.
13. Winston R.M.L, Magara R.A,
Microsurgical salpingostomy is not an obsolete procedure
Br J. obstet. Gynaecol. 1991;98: 637 – 642.

Case No 15

VESICOVAGINAL FISTULA – SUCCESSFUL REPAIR.

Name:	M.K.	Parity:	4+0
Age:	26 years	DOA:	19.7.04
IP NO:	0966999	DOD:	27.7.04

Presenting Complaints

The patient presented with a five months history of leakage of urine.

History of presenting illness.

The patient was been admitted as a referral from Kisii District Hospital. She had been well until January 2004 when she had a laparotomy for a ruptured uterus due to obstructed labour in a previous scar. She had been in labour at home for about 14 hours. She underwent a sub-total hysterectomy and had a fresh still- birth weighing 3000 grams. The patient noted dribbling of urine on the 7th postoperative day. She was examined and a diagnosis of a vesicovaginal fistula was made and subsequently referred to Kenyatta National Hospital.

Past Obstetric and Gynaecologic History

She was a para 4+0. Her last delivery was in January 2004 and the outcome was a fresh stillbirth, a ruptured uterus and a subtotal hysterectomy done. Her first delivery was in 1995 through an emergency caesarean section due to foetal distress. The outcome was a life male infant who weighed 2.5kg and was alive and well. The second and third deliveries were via spontaneous vertex delivery at home. Both weighed 3000 grams and were alive and well.

Her menarche was at 15 years. She gave no history of contraception.

Past Medical and Surgical History

This was not significant.

Family and Social History

She was a married lady. She and her husband were farmers in Kisii. Neither smoked

cigarettes nor consumed alcohol.

She had no family history of chronic illnesses.

Physical Examination

General Examination

She was a young woman in fair general condition and was in good nutritional status. She was not pale, not jaundiced, afebrile, no oral thrush and no peripheral oedema.

Vital signs were: -

- Blood pressure - 120/80 mmHg
- Pulse rate - 78/minute
- Respiratory rate – 18/minute
- Temperature – 36.9°C

Abdominal examination

The abdomen was not distended and moved with respiration. She had a sub-umbilical midline scar. There were no areas of tenderness and no palpable masses.

Pelvic Examination.

She had moderate excoriation of the vulva and the perineum. She had notable continuous dribbling of urine that was foul smelling. A dye test that was done in the gynaecology outpatient clinic (GOPC) was positive with a pin whole fistula on the anterior vaginal wall.

Other systems

The cardiovascular, respiratory and central nervous systems were essentially normal.

Diagnosis

A diagnosis of vesicovaginal fistula was made.

Management

The patient was informed the nature of her condition and the intended management. She gave an informed written consent for examination under anaesthesia and repair in the same sitting.

Pre-operative investigations done;-

8) Total blood count: -

- WBC – $9.45 \times 10^9/L$
- RBC – $4.47 \times 10^9/L$
- Haemoglobin 10.6g/dL
- Platelets - $300 \times 10^9/L$

9) Urea and electrolytes.

- a. Sodium – 137 mmol/ L
- b. Potassium – 3.6 mmol/ L
- c. Urea – 6.3 mmol/ L
- d. Creatinine – 42 $\mu\text{mol/ L}$

On the eve of the operation, she was starved from midnight and started on intravenous fluids. The pubic hair was shaved and had enema at 6 p.m. and 6 a.m. Half an hour before being wheeled to theatre, she was pre-medicated with atropine 0.6mg and Pethidine 100mg intramuscularly.

In theatre, the general anaesthesia was given and the patient was placed in exaggerated lithotomy position. Vulvovaginal toilet was done and draped. The labia were separated by suturing them onto the thighs bilaterally. The patient was catheterized and catheter retained. A left episiotomy was done and the edges sutured on the thighs. The area around the fistula was infiltrated with jungle juice. The margins of the fistula were freshened circumferentially and the vaginal wall dissected off the bladder wall 2cm. The intervening fascial plane was separated to mobilize a flap of bladder mucosa.

The bladder wall closure was done transversely using vicryl suture No. 2/0 with atraumatic needle. The vaginal mucosa was closed in an everted fashion using vicryl No. 2/0. A dye test done at the end of the procedure was negative.

A gauze soaked in iodine was placed over the repair site and to be removed after 24 hours. The episiotomy was repaired using vicryl No. 2/0 and the labial sutures were removed. A Foley's catheter was inflated with 5mls of normal saline and left in situ to ensure continuous bladder drainage. The anaesthesia was then reversed successfully and patient taken to recovery room.

Post-operative care

In the recovery room, the patient was observed continuously until she was fully awake and then taken to ward for 4 hourly observations. She received intravenous fluids, 5% dextrose alternating with normal saline, one litre every 6 hours. She was also instructed to take oral fluids freely. The gauze pack was removed after 24 hours and intravenous fluids stopped. She was instructed to drink 6 to 8 litres of fluids daily. She did well postoperatively, remained dry and the urine remained clear. She was discharged on the 7th postoperative day with the catheter in situ and instructed to continue taking plenty of oral fluids and to avoid coitus for at least 4 months.

She was booked for review and dye test on the 14th postoperative day.

Follow-up

She came to the clinic as per the appointment date. Dye test was done and there was no leakage of dye into the vagina. The catheter was removed. She was once again advised against having coitus for at least 4 months. She was allowed home and booked for another review in the GOPC after 4 weeks and she still had no leakage of urine.

Discussion

The patient presented was a 26 years old para 4+0 with a vesicovaginal fistula following an obstructed labour that subsequently resulted to a ruptured uterus. She later underwent a successful repair of the vesicovaginal fistula (VVF).

A fistula is a communication between two epithelial surfaces. A vesicovaginal fistula is a communication between the epithelia of the bladder and the vagina, and the urine escapes into the vagina causing true incontinence (1,2). A VVF is said to be one of the greatest misfortune that can happen to a woman (1). It is a socially embarrassing condition that makes her reclusive and depressed as a result of continuous dribbling of urine, wet clothes and the accompanying offensive ammonia smell.

The incidence of genitourinary fistula vary greatly from one part of the world to another, with the highest incidence being in developing countries compared to the developed world. The incidence in the developing world ranges between 0.5 and 3% of all gynaecologic admissions while in the developed countries the incidence is less than 0.03%. The peak incidence of VVF is found in patients who are in their late and early 20's, low parity and often in the first or second pregnancy (2,3).

The patient presented was 26 years old para 4+0 and whose VVF occurred during her fourth delivery.

The aetiology of VVF is classified into obstetrical or gynaecological causes. In the developing countries, the commonest cause is obstetrical and constitutes about 80 – 90% of the cases as opposed to only 5 – 15% in developed countries. The fistula may be due to ischaemia or trauma (2). Prolonged compression effect on the bladder base between the foetal head and symphysis pubis in obstructed labour leads to ischaemic necrosis, which is followed by infection with subsequent sloughing, and eventually a fistula develops (2,3). Thus it takes a few days, usually 7 to 14 days following delivery to produce such a type of fistula.

A fistula may also result from trauma during instrumental deliveries such as destructive operations or forceps especially with Kiellands. Abdominal operations such as for a ruptured uterus or caesarean section especially a repeat one may be complicated by a fistula as a result of direct trauma to the bladder or ischaemic necrosis following a part of the bladder wall being caught in the suture. This type of direct traumatic fistula usually follows soon after delivery (2,3).

Gynaecological causes of fistula include trauma during hysterectomy or anterior colporrhaphy. Others include malignancy of the cervix, bladder or vagina, irradiation and infections such as genital tract tuberculosis, schistosomiasis and actinomycosis. Although a rarity in the developing countries, gynaecological causes of fistula is the commonest type encountered in the developed countries and accounts for over 80% of fistulae (2,3).

Locally, Orweno (1984) found that 92.2% of VVF to be labour related and that 7.8% was related to the carcinoma of the cervix and other factors (4).

The patient presented developed VVF as a result of obstructed labour and first noticed on the 7th post-operative day.

Continuous escape of urine per vagina (true incontinence) is the classic symptom associated with VVF. The patient has no urge to pass urine. However, if the fistula is small, the escape of urine occurs in certain position(s) and the patient may pass urine normally. The patient often has an offensive odour of urea and majority have oligomenorrhoea or secondary amenorrhoea. Orwenyo (4) found oligomenorrhoea in 40% of the cases at Kenyatta National Hospital. Other features include redness of the vulva and perineum as a result of excoriation, ulceration, itchiness and urinary bladder calculi. Foot-drop due to prolonged compression of the sacral nerve roots by the foetal head during labour may be present as well as a complete perineal tear or rectovaginal fistula (2,3). Secondary amenorrhoea is thought to be hypothalamic in origin due to stress or psychogenic disturbances (2).

The patient presented had continuous leakage of urine, offensive smell of urea and excoriated skin. She had undergone subtotal hysterectomy and therefore she was not expected to have menstruation.

The diagnosis of VVF is usually confirmed by instillation of methylene blue dye into the bladder after which the escape of the coloured urine can be directly observed through a speculum. If the leakage is minimal, the staining of a vaginally placed pack will confirm the diagnosis. An intravenous urogram is essential to rule out a concurrent ureteric fistula or presence of calculi. Cystoscopy may also be used to identify the fistula in the bladder (2,3).

The patient presented had an obvious fistula and the escape of urine through it was visualized on speculum examination.

Fistulae may be located at any point along the anterior vaginal wall and may include any or all of the bladder base and the urethra. They may be single or multiple. Depending on the site of the fistula, it may be classified into (2,3,5); -

- 1) Juxta-cervical – the fistula is close to the cervix. The communication is between the supratrigonal region of the bladder and the vagina.
- 2) Mid-vaginal – the communication is between the bladder base (trigone) and the vagina.
- 3) Juxta-urethral – the communication is between the neck of the bladder and vagina. It may involve the upper urethra as well.

Depending on communication level, these fistulae may also be classified into uterovesical, vesicovaginal, ureterovaginal, urethrovaginal and vault fistulae (2,3,5).

The patient presented had a mid-vaginal fistula.

Another classification in common use is based on both anatomical and physiologic location of the fistula. It is classified into (6); -

- 1) I – Fistula not involving the closing mechanism.
- 2) II - Fistula involving the closing mechanism.
 - IIA – Without (sub) total involvement of the urethra.
 - IIAa – Without circumferential defect
 - IIAb – With circumferential defect
 - IIB - With (sub) total involvement of the urethra.
 - IIBa – Without circumferential defect

II Bb – With circumferential defect

3) III – Miscellaneous – for example, ureterovaginal fistula.

Fistulae may also be classified according to the size of the fistula into; small (<2cm), medium (2 – 3cm), large (4 – 5cm) and extensive (≥ 6 cm).

The patient presented had a small fistula measuring 0.5cm in diameter.

For many years, the VVF had the reputation of being difficult and almost impossible to repair (7). Infact, Dieffenbach in the 19th century commented, “ a VVF is the greatest misfortune that can happen to a woman, more so because she is condemned to live with it, and cannot hope to die from it” (1). However, for a couple of decades now, the fistulae have been successfully repaired.

Urinary fistulae have a natural tendency to close spontaneously by granulation, fibrosis and contraction. However, this process may be interfered with by sepsis and continued flow of urine. If the urine is diverted by the use of a catheter to ensure bladder drainage and prompt treatment of sepsis with antibiotics, the size of the fistula may decrease in 20% of the fistulae. Smaller fistulae (less than 1cm) may close spontaneously in 2 to 3 months. However, fistulae that fail to close spontaneously in 3 to 6 months should be closed surgically. This period of wait also allows for inflammation to subside, oedema to settle, infection to clear and tissue necrosis to deslough. This allows complete re-epithelization of the fistula tract, thus reducing the fistula size (2,3,7).

However, the 3 to 6 months period of wait has currently been revised and lowered to 6 – 8 weeks so as to minimize the social agony and psychological trauma the patient undergoes while waiting for repair.

Before surgery is undertaken, sepsis and anaemia should be treated first. Vaginal irrigations and antibiotics can clear local sepsis. The nutritional status of the patient should be improved before surgery (7,8). Sit baths and barrier ointments, such as zinc oxide preparations can provide relief from local dermatitis.

Acidification of the urine to diminish the risks of cystitis, mucus production and formation of bladder calculi may be necessary before surgery.

The patient presented had no local sepsis and her haemoglobin level was 10.6 g/dL.

The route of repair of VVF can be either abdominal or vaginal. The route of repair depends on the surgeon's experience and type of fistula. The approach route of choice for types I and II fistula is the vagina. For type III fistula the abdominal route may be necessary. Absolute indications for abdominal approach include the need for concomitant abdominal surgery such as the augmentation cystoplasty and ureteral re-implantation, the inability to adequately expose the fistula vaginally, a complex presentation of VVF involving the ureters, bowel or other intra-abdominal structures, and involvement of the ureteric orifices (3,6).

The vaginal route can be approached through the knee-chest or exaggerated lithotomy position and it is characterized by minimal blood loss, low post-operative morbidity, shorter operative time and shorter operative recovery time (3,6,7,8).

The patient presented had the VVF repair undertaken through the vaginal route and an episiotomy done to aid the exposure.

For both vaginal and abdominal approaches, excellent success rates are achieved if the following surgical principles are adhered to (3,6,7);

- Complete pre-operative diagnosis
- Adequate exposure
- Good haemostasis
- Adequate mobilization of tissues
- Tissue closure under no tension
- Water tight closure of bladder
- Repair timing to avoid inflammation of tissues or infection.
- Adequate blood supply at area of repair
- Continuous catheter drainage post-operatively.

Continuous bladder drainage postoperatively is essential for the success of the repair. A large caliber catheter minimizes the potential for catheter blockage. A high intake of fluids, approximately 6 to 8 litres in 24 hours, in order to maintain a high output of dilute urine of upto 75 to 100mls per hour.

This aids flushing out the debris, blood clots, washout bacteria and dilute urine would be less irritant to raw tissues. The indwelling catheter is maintained for at least 14 days post-operatively (5,6).

Incase of doubt about the healing of the repair or presence of leakage, the catheter can be left for further 1 to 2 weeks (3,6,7). Once the catheter is removed, the patient is instructed to refrain from sexual intercourse for at least 6 months following the operation. A pregnancy following a successful repair mandates an elective caesarean section.

The patient presented had an indwelling catheter for 14 days and a daily fluid intake of 6 to 8 litres was maintained.

The role of antibiotics postoperatively is controversial. Many physicians recommend the use of prophylactic oral antibiotics until the indwelling catheter is removed while others check closely for development of urinary tract infection and initiate antibiotic therapy when urine cultures are positive for bacterial growth (3,6).

The patient presented was not given any prophylactic antibiotics but was closely monitored to detect development of urinary tract infection.

The cure rate of VVF repair depends upon (3,6);

- The location and size of the fistula
- The amount of tissue loss
- The amount of scar tissue
- The age of the patient
- The accessibility of the site
- The pre-operative preparation
- The surgical technique and experience of the surgeon
- The quality of postoperative care.

Lawson observed that an experienced surgeon supported by a competent nursing staff could achieve an overall success rate of 75% on first attempt and a further 15% on the second attempt. But since each successive repair produces more scar tissue, a successful first attempt repair is the goal (9).

The overall cure rate at KNH is 60%, the midvaginal fistula has the highest cure rate of 85.7% (10). Orwenyo (1983) found a cure rate of 80.6% for juxta-cervical fistula at KNH (4).

Complications of fistula repair include repair failure, stress incontinence and vaginal stenosis. In case of repeated repair failures, it is preferable to have a second opinion or to consult an urologist before declaring the case as irreparable. In irreparable cases, urinary diversion may be done by implanting the ureters into the pelvic colon or ileal bladder (2,3,6).

The patient presented had a midvaginal fistula that was successfully repaired and did not develop any complications.

The best treatment of VVF is prevention. This involves adequate antenatal care to identify "at risk" mothers who are likely to develop obstructed labour. These include contracted pelvis, malpresentation and those with history of previous prolonged labour. Good obstetric care during labour, which include anticipation, early detection and ideal approach in the method of delivery in relieving the obstruction. Continuous bladder drainage for variable period of 7 to 10 days following delivery of obstructed labour with cephalic presentation should be mandatory. During pelvic surgery, whether obstetric or gynaecological, care should be taken to avoid bladder injury. In case of bladder injury during such operation, it should be detected and repaired immediately in two layers (3,6).

References

1. Mann C.V, Russell R.C.G.
The urinary bladder.
In: Bailey and Love's short practice of surgery, 21st edition, Chapman and Hall, Publications 1994; page 1395 – 1397.

2. Dutta D.C.
Genital Fistulae.
In: Textbook of Gynaecology, 3rd edition, New Central Publications, 2001;
Page 385 – 395.

3. John D.T.
Vesicovaginal fistulae
In: Te Linde's operative Gynaecology, 8th edition, Lippincott-Raven, Publications, 1997; Page 477 – 497.

4. Orwenyo E.A.
A retrospective study of 166 cases of acquired urinary genital and rectovaginal fistula treated at KNH 1979 – 1982.
M. Med Thesis, UON, 1983.

5. Wall L.L.
Incontinence, prolapse and disorders of the pelvic floor.
In: Novak's Gynaecology, 13th edition, Lippincott-Williams and Wilkins, 2002;
page 638 – 639.

6. Waaldjik K.
Step by step surgery for vesicovaginal fistulas.
Campion press Limited, Edinburgh, 1994.

7. King M, Bowes P, Cairns J et al.

The surgery of labour.

In: Primary Surgery: non-trauma, volume one, oxford medical publications, 1993;
Page 288 – 292.

8. Padubidri V.G, Shirish N.D.

Diseases of the urinary system.

In: Shaw's Textbook of gynaecology, 12th Ed, Churchill Livingstone
publications, 1999; page 133 – 151.

9. Lawson J.B.

Injuries of the urinary tract.

In: Obstetrics and Gynaecology in the tropics and developing countries, 3rd Ed,
Edward-Anold publications, 1976; page 481.

10. Mati J.K.G, Gunaratne M.

**Acquired fistula of the female lower genital tract: A comprehensive 5-year
review.**

J. Obstet. Gynaecol. East and Central Africa, 1982; 1: 11.

GYNAECOLOGY LONG COMMENTARY

TITLE: PELVIC ABSCESS AT KENYATTA NATIONAL HOSPITAL - 5 YEAR RETROSPECTIVE STUDY(1998-2002)

ABSTRACT

Background

The magnitude of pelvic abscess locally is undermined despite the fact that it is an important cause of morbidity and mortality especially among women of reproductive age. Pelvic abscess is often associated with long-term complications, which are mainly attributable to adhesion formation and tubal damage. These complications includes; infertility, chronic low abdominal pains, bowel obstruction and dyspareunia.

Objective

The objective of this study was to determine how frequent pelvic abscess is encountered at KNH, possible risk factors, treatment challenges and complications.

Study Design

This was a retrospective descriptive study.

Study Period

The study covered the period between 1st January 1998 and 31st December 2002.

Results

Pelvic abscess accounted for 3.8% of all acute gynaccological admissions.

Patients in the age group 20 – 29 years and those between 30 – 39 years accounted for 55.4% and 29.3% of cases respectively. Three cases (1.4%) of post-menopausal women was encountered, one was diabetic and the other two had acute appendicitis. Majority of the pelvic abscess cases were nulliparus (27.9%) and only 8.8% had a parity of above 4.

Single women comprise the majority (68.9%) of the cases while married women accounted for 22.5%. Post-abortal sepsis was the commonest cause of pelvic abscess accounting for 33.3% of the cases. STI/PID and puerperal sepsis were identified as the cause of pelvic abscess in 16.7% and 11.7% respectively. Only 67 out of the 222 cases of pelvic abscess had been tested for HIV infection – 59.7% tested positive while 40.3% tested HIV negative. Only 59 cases had pus swab specimen taken for culture and sensitivity.

Positive cultures were identified in 34 (57.6%) of cases while sterile growths (no growths) was observed in 43.4% of the cases – probably due to prior administration of antibiotics. *Escherichia coli* was identified in the majority (20.5%) of isolates while *staphylococcus aureus* and enterococci comprised 11.9% and 10.1% respectively. Augmentin (Clavulanic acid/ amoxycillin) was found to be the most potent anti-biotic against most of the isolates. 86% of the isolates were sensitive to Augmentin (Clavulanic acid/ amoxycillin) while 14% and 2% of the isolates were sensitive to Tetracycline and co-trimoxazole respectively.

The majority (83.9%) of cases had never been on any contraception. IUCD was the most widely used method comprising 5.7% while barrier methods accounted for only 0.95%. Twenty-one patients with pelvic abscess in this study died, giving a mortality rate of 9.5%. Pelvic abscess secondary to post-abortal sepsis and HIV/AIDS were responsible for 52.3% (11 cases) and 33.3% (7 cases) of the deaths respectively. Anaemia and septicaemia were the immediate cause of death in the majority of cases, accounting for 57.1% (12 cases) and 28.6% (12 cases) respectively. Within the study period (1998-2002) a total of 42 patients who had pelvic abscess were reattended to, with morbid conditions that were probably attributable to its complications. Fifteen cases (35.7%) had infertility, 11 cases (26.2%) had deep dyspareunia while 9 cases (21.4%) had chronic lower abdominal pain.

Conclusion

Pelvic abscess accounted for 3.8% of all acute gynaecological admissions. Pelvic abscess was commonest in the young, unmarried and sexually active women of low parity. Post-abortal sepsis was identified as the commonest cause of pelvic abscess among women of reproductive age. Pelvic abscess was associated with high mortality and morbidity.

Like in previous local studies, the offending organisms have remained fairly the same. *Escherichia coli* accounted for the majority (20.3%) of the positive cultures, *staphylococcus aureus* 11.9% and enterococci 10.1%. However the antibiotic sensitivity patterns has changed over the years due to emerging resistance to various antibiotics. Augmentin (Clavulanic acid/ amoxycillin), Gentamycin and Ceflazidime had reasonable

sensitivity patterns while high resistance to Tetracycline and Co-trimoxazole was observed.

INTRODUCTION AND LITERATURE REVIEW

Pelvic abscess is defined as a localized collection of pus in the pelvic peritoneum and it is the commonest type of intra-peritoneal abscess (1). Pelvic abscess is a major cause of morbidity and mortality amongst women in the reproductive age group. The incidence varies from country to country due to differences in management of gynecological admissions (2). Patients who develop pelvic abscess are usually in their 20s and 30s with a large percentage (20%-59%) of these women being nulliparous. It is rare in those above the parity of four (1,2,3). In post-menopausal women, a pelvic abscess is usually secondary to pathology in the intestinal tract such as appendicitis and ruptured gallbladder or immunosuppressive conditions such as diabetes mellitus (2,3,4).

The Aetiology of Pelvic Abscess

The aetiology of pelvic abscess can be classified into either pelvic causes (the commonest) or extra - pelvic causes (less common) (2).

The pelvic causes include post-abortal sepsis, puerperal sepsis, acute pelvic inflammatory disease (PID), perforation of uterus such as during curettage and irritant peritonitis following contamination by meconium spilled during the caesarean section. The extra-pelvic causes include appendicitis, diverticularitis, ruptured gallbladder or perforated peptic ulcer, - all of which may cause generalized peritonitis and the resultant peritoneal exudate (pus) ultimately settles in the dependent, pouch of Douglas which may subsequently develop into a pelvic abscess (2,3,4).

The commonest cause of pelvic abscess is acute pelvic inflammatory disease (PID) which refers to the inflammation of the pelvic structures including the uterus (endometrium), fallopian tubes, the ovaries and the parametrium (3,4,5). PID usually follows infections which reach the pelvic structures as a result of sexually transmitted diseases via the vagina and cervix, introduction of foreign bodies such as intra-uterine contraceptive device (IUCD)-the highest risk being the first four months of insertion, infected retained

products of conception following either delivery or abortion and rarely as a result of blood-borne bacterial transmission e.g. pelvic tuberculosis (3,6).

Acute PID is usually a consequence of infection with *Neisseria gonorrhoea* and *Chlamydia trachomatis*. Others include *Escherichia coli*, *Mycoplasma hominis*, *Ureaplasma*, *Streptococcus pyogenes* and *Staphylococcus aureus* (5,7).

In gonococcal infection of the lower genital tract, the initial site of infection is usually the cervix although there may also be infection of the urethra or Bartholin's glands (1,7). By direct spread across mucosal surfaces (those not lined by stratified squamous epithelium), infection ascends quickly from the cervix to the endometrium and hence to the endosalpinx. The fallopian tubes quickly become oedematous and hyperaemic with exudation of pus. This may escape into the peritoneal cavity or may be retained within the tube depending on whether the fimbrial end (abdominal ostium) becomes closed or not. Thus, pus collection in the tube results in pyosalpinx, in the ovary to form an ovarian abscess, in both to form a tubo-ovarian abscess or in the pouch of Douglas to cause a pelvic abscess (3,6,7).

Puerperal sepsis is a general term used to describe any bacterial infection of the genital tract after delivery (8). Pelvic infections are the most common serious complications of puerperium, and along with the pre-eclampsia and obstetrical hemorrhage, forms the lethal triad of causes of maternal deaths (5). Puerperal sepsis primarily involves the placental implantation site, decidua, adjacent myometrium and parametrial tissues. Bacterial infections responsible for pelvic infections are mainly those that reside in the bowel and those that colonise the perineum, vagina and the cervix (8,9).

The uterine cavity is usually sterile before rupture of the amniotic sac. However, following labour and delivery plus associated manipulations, the amniotic fluid and the uterine lining become contaminated both anaerobic and aerobic bacteria (8).

Giltrap and colleagues (10) did a study on bacterial pathogenesis of infections following caesarean section. They obtained amniotic fluid from women who were in labour with membranes having ruptured longer than 6 hours. The outcome was that 63% of them had anaerobic and aerobic bacteria isolated, anaerobes alone was 30% and aerobes alone 7%.

The pre-dominant anaerobes were peptococcus (45%), bacterioides 9% and clostridium 3%. For aerobes, Escherichia coli accounted for 14% and enterococcus 22%.

Occasionally, despite prompt and appropriate anti-microbial treatment for puerperal sepsis (endometritis), a parametrial phlegmon will suppurate forming a pelvic abscess. Should the pelvic abscess rupture into the peritoneal cavity, a life threatening peritonitis may develop and an emergency laparotomy is mandatory to avert an imminent death (3,5,8).

Locally, Fomulu (1981) in his study, observed that abortion accounted for 51% of all acute gynaecological admissions at Kenyatta National Hospital (11). Majority (62.5%) of the abortions were induced and while 37.5% had occurred spontaneously. He also found that 8.75% of the pelvic abscess cases were secondary to post-abortal sepsis. Escherichia coli accounted for the majority (38.5%) of the isolates from the pus swab specimens collected from the pelvic abscess intra-operatively. Staphylococcus aureus and Neisseria gonorrhoea accounted for 15.4% and 7.7% of the isolates respectively (11).

Chebrot (1985) in his study on pelvic abscess in the female genital tract observed that 13% of the pelvic abscess cases had a prior induced abortion - a figure that could be low due to fear to disclose criminal abortion (12). Pus swabs obtained from the pelvic abscess during surgery were subjected to culture and sensitivity. Escherichia coli accounted for 23%, peptococcus 13% and 60% were sterile (no growth) - a fact that could be attributed to the administration of antibiotics prior to surgery. Nearly 86% of both anaerobes and aerobes were sensitive to Tetracycline while only 2% were sensitive to co-trimoxazole. Approximately 96% of the patients in his study were young, unmarried, sexually active group - probably related to high incidence of PID and increased rate of induced abortions in the same group (12).

Clinical Findings

Pelvic abscess usually occurs in young sexually active women who present with lower abdominal pain, fever, dysuria, frequency of micturation, vomiting, mucoid diarrhoea and a foul smelling vaginal discharge. Generally, the severity of symptoms are often proportionate to the size of the abscess although some cases may be totally asymptomatic (3,4). On examination, the patient is usually sick looking, in pain, febrile and may be

anaemic. Jaundice and anaemia is usually present especially in those patients who have had a pelvic abscess for several weeks (13).

The abdomen is usually distended, tender, guarding and rebound tenderness may be present, and decreased or absent bowel sounds. Pelvic examination elicits severe pain even on slight cervical excitation and the uterus may not be appreciated due to tenderness. The pouch of Douglas may be full and fluctuant, there may or may not be an adnexal mass. There is usually a purulent foul smelling vaginal discharge (1,4,6).

An abdominal ultrasound may be useful in aiding the diagnosis of pelvic abscess. A transvaginal ultrasound is more superior due to better resolution (14).

Laboratory findings include Leucocytosis (polymorphonucleocytes), raised erythrocyte sedimentation rate (ESR), C-reactive proteins, interferons and Ca-125 levels may be elevated. Urea and electrolytes may be deranged especially in patients with peritonitis or septicaemia (1,3,9). The haemoglobin level may be normal or low. A blood culture specimen may yield the offending micro-organism(s). A pus swab for culture and sensitivity is more useful in identifying both the causative organism(s) and anti-microbial sensitivity pattern (4).

Treatment

The initial management of a patient with pelvic abscess consists of supportive measures such as intravenous fluids, nasogastric tube suction, blood transfusion, analgesics and parenteral antibiotics. Those with an intrauterine contraceptive device should have it removed after initiation of treatment (4,5).

Good response is judged by absence or declining of fever, decrease in white blood cell count by at least 3000 per mm³ and improved symptomatology (3,15).

In cases where the diagnosis is in doubt or when a ruptured abscess is suspected then surgical intervention is needed (3,4). Posterior colpotomy is restricted to cases where diagnosis is certain, the abscess is in the midline and dissecting the rectovaginal septum. However, posterior colpotomy is not very popular in our set-up. Laparotomy is usually preferred where the diagnosis is uncertain or where extensive abscesses are suspected. Laparotomy also offers easier identification of structures involved and breaking up of pus locurations (3,15). In cases where the abscess preceded an induced abortion, the

possibility of undiagnosed uterine perforation should be considered, looked for and repaired appropriately.

In patients with recurrent pelvic abscess and are past the reproductive age or have the desired family size or whose pelvic organs' damage is too expensive for future fertility consideration, a total abdominal hysterectomy may be recommended (15,16).

The differential diagnosis for pelvic abscess include tubo-ovarian abscess, peri-appendicular abscess, ectopic pregnancy, ovarian neoplasm, infected uterine fibroids, pelvic endometriosis and diverticulitis with perforation (2,16).

Complications

These include long-term complications of pelvic abscess related to tubal damage and pelvic adhesions. Persistent or recurrent pelvic pains, dyspareunia with subsequent matrimonial disharmony, bowel obstruction, ectopic pregnancy, infertility, dysmenorrhoea and chronic pelvic Inflammatory disease (PID) are common complications of pelvic abscess (15,17). More immediate complications include anaemia, wound sepsis, burst abdomen, peritonitis, septicaemia and even death. Acute renal failure and septic thromboembolism are also early complications which have a high incidence of morbidity and mortality (1,2,3).

Pelvic inflammatory diseases (PID) is difficult to manage and often leads to infertility. Even with prompt treatment, approximately 10% of patients will develop tubal adhesions leading to infertility after one episode of acute PID, 30% after two episodes, and more than 60% after three episodes (13,17,18).

All these complications can be prevented by health education to improve health seeking behaviour for early treatment, adequate health programmes and facilities, prevention of sexually transmitted diseases and provision of family planning services.

RATIONALE OF THE STUDY

Pelvic abscess is a major cause of mortality and morbidity among women especially the young and sexually active (1,2,3).

In his study, Fomulu (1981) found that abortion accounted for the majority (51%) of all acute gynaecological admissions at Kenyatta National Hospital (11). He also observed that 8.75% of the patients with post-abortal sepsis developed pelvic abscess.

Escherichia coli accounted for the majority (38.5%) of the isolates from the pus swab specimen collected intra-operatively (11).

Similarly, Chebrot's study (1985) revealed that *Escherichia coli* was the most frequent offending organism among the pelvic abscess cases and Tetracycline had the highest sensitivity pattern to the isolates (12). These two local studies mainly focused on socio-demographic characteristics and the pattern of infective organisms in patients with pelvic abscess.

This study is aimed at re-evaluating the pattern of infective organisms and the current anti-microbial sensitivity against the backdrop of possible emerging resistance. The study will also focus on identifying possible causes or risk factors associated with pelvic abscess especially with the advent of HIV/AIDS pandemic, treatment challenges and complications.

OBJECTIVES

Broad Objective

To determine the pattern of occurrence and complications of pelvic abscess at Kenyatta National Hospital.

Specific Objectives

1. To determine the frequency of occurrence of pelvic abscess at the Kenyatta National Hospital.
2. To determine the sociodemographic characteristics of patients with pelvic abscess at Kenyatta National Hospital.
3. To determine the risk factors associated with pelvic abscess.
4. To evaluate the challenges encountered in the treatment of pelvic abscess.
5. To determine the complications arising in patients with pelvic abscess.

DESIGN AND METHODOLOGY

Study Design

This was a retrospective descriptive study.

Study Area

This study was carried out at Kenyatta National Hospital which is located about 3 kms west of Nairobi city centre and it offers health services to the residents of Nairobi and neighbouring districts. It is also the main referral hospital for the rest of the country.

All new patients are clerked by the houseman and reviewed by the registrar who undertakes the management in consultation with senior members of the department. Patients with acute gynaecological conditions are admitted to ward ID. The majority of those admitted have incomplete abortions, Pelvic Inflammatory Disease (PID), Ectopic Pregnancy and pelvic abscess among others. A theatre is reserved in Main Theatre for emergency gynaecological operations at all times. Laparotomy for pelvic abscess, ectopic pregnancies, ovarian cysts and other tubo-ovarian masses are done in this reserved theatre.

Inclusion Criteria

1. Patients whose records confirmed diagnosis of pelvic abscess at surgery.
2. Patients whose records were available.
3. Patients whose files/records were complete.
4. Patients who were examined and operated at Kenyatta National Hospital.

Exclusion Criteria

1. Patients whose record/ files were incomplete.
2. Patients whose files/records were unavailable.

Study Procedure

The records of the patients seen at the casualty (Ward ID) on Outpatient and In-patient basis and those at Main Theatre during the period between 1st January 1998 and 31st December 2002 were reviewed. Where a diagnosis of pelvic abscess had been made at the surgery, the file numbers were used to trace the case records from the hospital records department. Relevant data was transferred from the file to the questionnaire where clinical notes were deemed adequate.

SAMPLE SIZE

In his study, Fomulu (1981) found a 8.75% prevalence of pelvic abscess among patients with post-abortal sepsis at Kenyatta National Hospital (11). To determine the sample size to 95% confidence limits, the following Woolson's formula was used:

$$n = \frac{z^2 \times P(1-P)}{d^2}$$

where n = sample size
z = standard error from mean
p = prevalence in percentage
d = level of precision.

$$n = \frac{1.96^2 \times 0.0875 \times 0.9125}{(0.05)^2}$$

$$n = 122$$

The minimum sample size was therefore 122

On average 2 to 3 cases of pelvic abscess are diaganised and operated at Kenyatta National Hospital per month. Therefore, a period of 5 years was deemed adequate to realize the minimum sample size.

DATA COLLECTION, PROCESSING AND ANALYSIS

A total of 222 case files of patients who had a surgical diagnosis of pelvic abscess in the period specified, were retrieved and included in the study. The data obtained from the case files was recorded in the data collection sheets and analyzed using appropriate standard statistical methods. The significance of difference between the variables was assessed using chi square (χ^2) test. A P-value of 0.05 or less signified significant difference between the variables of interest.

STUDY PERIOD COVERED

Between 1st January 1998 and 31st December 2002

Ethical Considerations

1. The study commenced after permission was granted by Kenyatta National Hospital – Ethics and Research Committee (KNH – ERC).
2. The information obtained was treated confidentially and used strictly for the purpose intended and not to incriminate or harm anyone.
3. The results were purely for health improvement and academic purposes.

RESULTS

A total of 222 case files of patients who had an intraoperative diagnosis of pelvic abscess at Kenyatta National Hospital between 1st January 1998 and 31st December 2002 were reviewed and analyzed.

Table 1: Age distribution

Age in years	Frequency	%
≤ 19	18	8
20 – 24	65	29.3
25 – 29	58	26.1
30 – 34	37	16.7
35 – 39	28	12.6
40 - 44	11	5
45 - 49	2	0.9
≥ 50	3	1.4
Total	222	100

Women in the age group 20 – 29 years accounted for the majority (55.4%) of the patient with pelvic abscess in this study. It is notable that only 3 (1.4%) cases of pelvic abscess were of past the reproductive age (over 49 years).

Table 2: Education background

Education level	Frequency	%
None	14	6.3
Primary	141	63.5
Secondary	23	10.4
Tertiary	44	19.8
Total	222	100

Results from table 2 above, shows that 93.7% of cases had at least attained some level of education while only 6.3% of the cases had no education at all. The majority (63.5%) had attained primary level of education.

Table 3: Marital status

Marital status	Frequency	%
Single	153	68.9
Married	50	22.5
Divorced/separated	15	6.8
Widowed	4	1.8
Total	222	100

The majority (68.9%) of the patients with pelvic abscess were single, 8.6% were either divorced/separated or widowed while 22.5% of the cases were married.

Table 4: Nature of employment

Nature of employment	Frequency	%
Employed	18	8.1
Self employed	30	13.5
Unemployed	125	56.3
Housewife	25	11.3
Student	21	9.5
Others	3	1.3
Total	222	100

The majority (56.3%) of the patients were unemployed while students accounted for 9.5% of the cases. Employed and self employed accounted for 21.6% of the patients. One of the patients was a prisoner.

Table 5: Parity

Parity	Frequency	%
0	62	27.9
1	52	23.4
2	50	22.5
3	24	10.8
4	15	6.8
5	7	5.4
6	12	3.4
Total	222	100

The result from table 5 above shows that majority of patients with pelvic abscess were of low parity compared to those of high parity. Parity of less or equal to two accounted for 73.8% of the cases while 26.2% had parity of three and above.

Table 6: Where patient was referred from

Origin of referral	Frequency	%
Home/ self referral	166	74.8
Private clinic	24	10.8
Health centre and dispensary	10	4.5
Hospital	22	9.9
Total	222	100

Self-referral accounted for 74.8% of the patients compared to 25.2% that had been referred from health facilities.

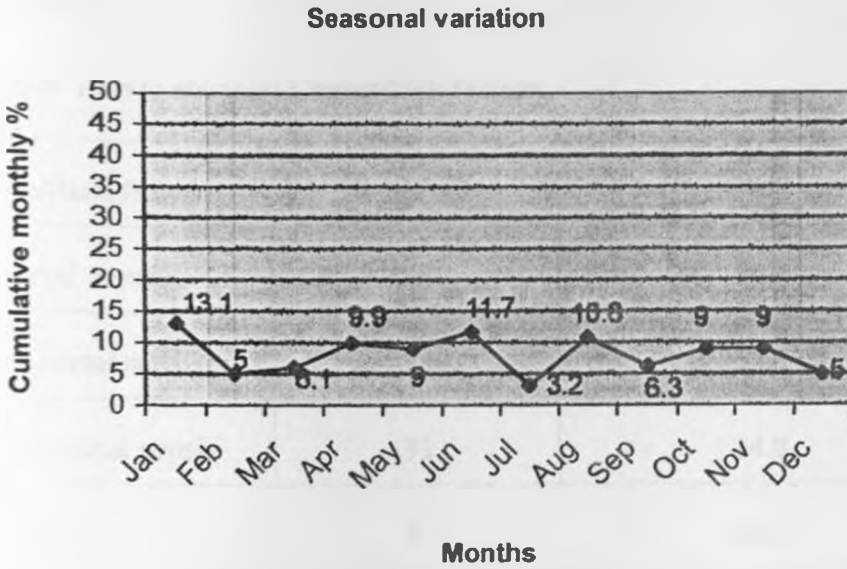
Table 7: Acute gynaecological admissions (1998-2002)

Acute gynaecological conditions	Cumulative frequency	%
Abortions	3727	63.7
Puerperal sepsis	405	6.9
Pelvic abscess	222	3.8
STI/PID	344	5.9
Bartholin Abscess	142	2.4
Hydatiform mole	128	2.2
Ectopic pregnancy	693	11.9
Others	190	3.2
Total	5851	100

Abortion accounted for the majority (63.7%) of the acute gynaecological admissions. Pelvic abscess accounted for 3.8% of the admissions while puerperal sepsis and STI/PID accounted for 6.9% and 5.9% respectively.

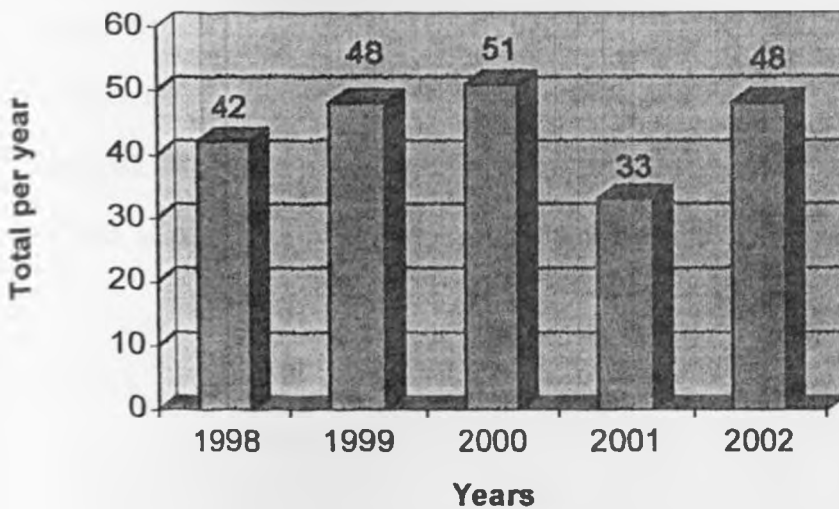
UNIVERSITY OF NAIROBI
MEDICAL LIBRARY

Figure 1: Seasonal variation



Although there appears to be no seasonal variable in the occurrence of pelvic abscess (fig 1), January and June recorded the highest cumulative monthly percentage of 13.1% and 11.7% respectively. July had the lowest cumulative monthly percentage of 3.2%. There was no clear cut seasonal variation observed.

Figure 2: Pelvic abscess yearly distribution



On average, 44 cases of pelvic abscess were admitted at Kenyatta National Hospital every year as demonstrated on figure 2 above. The highest number of pelvic abscess cases (23%) were admitted during the year 2000 while 2001 had the least (14.5%) admissions.

Table 8: Pelvic abscess: Causes/risk factors

Cause/Risk factor	Frequency	%
Puerperal sepsis	26	11.7
Post-abortal sepsis	74	33.3
Post-surgical sepsis	33	14.9
STI/PID	37	16.7
HIV/AIDS	13	5.9
Others	3	1.4
Unknown	36	16.1
Total	222	100


Post-abortal sepsis was the cause of pelvic abscess in the majority (33.3%) of the cases compared to 16.7% of cases that were due to STI/PID. HIV/AIDS without a known additional risk factor accounted for 5.9% of the cases. Among the “others” (1.4%) two patients had acute appendicitis and one had diabetes mellitus as the cause of pelvic abscess.

Table 9: Puerperal sepsis: Place of delivery

Place of delivery	Frequency	%
Home	20	76.9
Private clinic	2	7.7
Health centre and dispensary	2	7.7
Hospital	2	7.7
Total	26	100

From the results on table 9 above, it is notable that 76.9% of patients who had pelvic abscess secondary to puerperal sepsis had delivered at home compared to 23.1% who had delivered in a health facility.

Figure 3: Type of Abortion



Seventy-four (33.3%) cases of pelvic abscess preceded post-abortal sepsis. Figure 3 above shows that 66 (89.2%) of post-abortal sepsis resulted from induced abortion compared to only 8 (10.8%) that occurred spontaneously. The majority (82.4%) of the abortions had no prior uterine evacuation done.

Table 10: Pelvic abscess: HIV status

HIV status	Frequency	%
Positive	40	18
Negative	27	12.2
Unknown	155	69.8
Total	222	100

Sixty seven patients with pelvic abscess had been tested for HIV infection and their status known. One hundred and fifty five pelvic abscess cases had not been tested, and therefore their HIV status was unknown. Of those tested for HIV infection, 40 (59.7%) cases were positive while 27 (40.3%) cases were negative.

Table 11: Pelvic abscess: Known HIV status against other risk factors/causes

Risk Factors/ Causes	HIV Positive		HIV Negative	
	Frequency	%	Frequency	%
Puerperal sepsis	6	15	5	18.5
Post – abortal sepsis	9	22.5	11	40.7
Post – abdominal surgery	3	7.5	3	11.1
STI/PID	9	22.5	1	3.7
Unknown	13	32.5	5	18.5
Total	40	100	27	100

Table 11 above, shows the HIV status of the 67 patients who had been tested for HIV infection against the probable risk factor/cause that preceded pelvic abscess. Of the 40 cases that tested HIV positive, 22.5% had STI/PID compared to only 3.7% of STI/PID among those who tested HIV negative.

Table 12: Contraceptive use

Contraception	Frequency	%
IUCD	12	5.7
Oral pills	11	5.2
Injectables	7	3.3
Barrier methods	2	0.95
BTL	2	0.95
None	176	83.9
Total	210	100

Table 12 above, shows that the majority (83.9%) had never been on any contraception. The most common contraception used was IUCD accounting for 5.7% while the barrier methods were the least common, accounting for only 0.95%. The two cases of barrier method used were male condoms while 12 cases had no history of contraception indicated in the file notes.

Table 13: Pelvic abscess: Bacterial growth isolation

Bacteria	Frequency	%
Diphtheria	1	1.7
Escherichia coli	12	20.3
Enterococci	6	10.1
Klebsiella	2	3.4
Proteus	2	3.4
Staphylococcus aureus	7	11.9
Streptococcus pyogens	2	3.4
Neisseria . gonorrhoea	1	1.7
Mixed	1	1.7
No growth (sterile)	25	42.4
Total	59	100

Fifty nine cases of pelvic abscess had a pus swab for cultures and sensitivity taken intra-operatively. No growth (sterile) was observed in 42.4% of the cases and this probably reflected prior antibiotic use.

The majority of the isolates were E coli (20.3%), staphylococcus aureus (11.9%) and enterococci (10.1%). Both mixed growth and neisseria gonorrhoea were observed in 1.7% of the isolates each.

Table 14: Pelvic abscess: Antibiotic sensitivity to isolates

Antibiotic	% of sensitivity isolates
Ampicillin	41
Augmentin(Clavulanic acid/ amoxicillin)	86
Chloramphenical	32
Ceftazidime	65
Cefuroxime	63
Doxycycline	12
Tetracycline	14
Erythromycin	62
Gentamycin	68
Co-trimoxazole	2
Amoxycillin	11
Kanamycin	66
Crystalline penicillin	28

Majority of the isolates (86%) were sensitive to Augmentin (Clavulanic acid/ amoxicillin), Ceftazidime 65%, Cefuroxime 65% and Gentamycin 66%. Only 14% and 2% of the isolates were seensitive to Tetracycline 14% and Co-trimoxazole 2% respectively.

Table 15: Pelvic abscess: Post-operative complications n = 127

Complications	Frequency	%
Anaemia	56	44.1
Wound sepsis	38	29.9
Wound dehiscence	2	1.6
Peritonitis	8	6.3
Septicaemia	13	10.2
Faecal fistula	2	1.6
Bladder injury	2	1.6
Acute Renal Failure	4	3.1
Others	2	1.6
Total	127	100

The results in table 15 above shows that 57.2% (127) of the patients with pelvic abscess developed postoperative complications. Anaemia and wound sepsis accounted for 44.1% and 29.9% of the complications respectively. Of the 56 patients who had anaemia, 25.2% (14 cases) were transfused blood either intra or post-operatively. One unit of blood was transfused in 6 cases (42.9%), 2 units in 4 cases (32.1%) and 3 units in 3 cases (21.4%).

Table 16: Pelvic abscess: Mortality n = 21

Cause of death	Frequency	%
Septicaemia	6	28.6
Anaemia	12	57.1
ARF	3	14.3
Total	21	100

Twenty-one patients with pelvic abscess in this study died, giving a mortality rate of 9.5%.

Table 17: Mortality: Preceding risk factor/cause for pelvic abscess

Risk factor/cause	Frequency	%
Post-abortion sepsis	11	52.3
Puerperal sepsis	1	4.8
Post-surgical sepsis	0	0
STI/PID	1	4.8
HIV/AIDS	7	33.3
Others	0	0
Unknown	1	4.8
Total	21	100

Pelvic abscess secondary to post-abortion sepsis and HIV/AIDS were responsible for the majority of the deaths accounting for 52.3% and 33.3% respectively.

Table 18: Pelvic abscess: complications encountered within the study period (1998-2002) n=42

Complication	Frequency	%
Infertility	15	35.7
Ectopic pregnancy	2	4.8
Chronic abdominal pain	9	21.4
Bowel obstruction	3	7.1
Deep dyspareunia	11	26.2
Others	2	4.8
Total	42	100

Within the study period (1998-2002), 42 patients were re-admitted or reattended to, with complications that were most probably a sequelae of pelvic abscess. As such, table 18 above, shows that infertility accounted for the majority (37.5%) while chronic abdominal pain and ectopic pregnancy accounted for 21.4% (9 cases) and 4.8% (2 cases) respectively.

Table 19: Post-pelvic abscess complications: Preceding risk factors (n = 42)

Complications	Preceding Risk Factors/ Causes					Total
	Post-abortal sepsis	Puerperal sepsis	STI/TID	HIV/AIDS	Others	
Infertility	6 (40%)	2 (13.3%)	5 (33.3%)	1 (6.7%)	1 (6.7%)	15 (100%)
Ectopic pregnancy	1 (50%)	0 (0%)	1 (50%)	0 (0%)	0 (0%)	2 (100%)
Chronic abdominal pains	3 (33.4%)	2 (22.2%)	2 (22.2%)	1 (11.1%)	1 (11.1%)	9 (100%)
Bowel obstruction	2 (66.7%)	1 (33.3%)	0 (0%)	0 (0%)	0 (0%)	3 (100%)
Deep dyspareunia	4 (36.3%)	1 (9%)	5 (45.7%)	0 (0%)	1 (9%)	11 (100%)
Others	1 (50%)	0 (0%)	0 (0%)	1 (50%)	0 (50%)	2 (100%)

Table 19 above tabulates the possible relationship between the preceding risk factors and post-pelvic abscess related complications that were encountered within the study period. The majority of the infertility cases were associated with pelvic abscess secondary to post-abortal sepsis and STI/PID accounting for 40% and 33.3% respectively.

Discussion

A total of 5,851 acute gynaecological cases were admitted within the specified study period. A total of 222 cases of pelvic abscess were managed, thus accounting for 3.8% of all acute gynaecological admissions. Abortion accounted for the majority (63.7%) of the cases while ectopic pregnancy and puerperal sepsis accounted for 11.9% and 6.9% respectively. These findings compares well with those of Fomulu (1981) who found that abortion was the commonest (51%) cause of acute gynaecological admissions at Kenyatta National Hospital (11). Similarly, Mati and colleagues (1980) observed that abortion constituted 40% - 60% of the total gynaecological admissions at KNH (19). On average 44 cases of pelvic abscess were seen per year. January and June recorded the highest cumulative monthly percentages while July had the least. However, there was no clear cut seasonal variation.

In this study, patients in the age group between 20 – 29 years comprised the majority (55.4%) while those between 30 – 39 years accounted for 29.3%. These results compares well with those of Fomulu (1981) who observed that majority of patients with pelvic abscess were in their 20's and 30's (11). He also observed that pelvic abscess was rare in postmenopausal women and was usually secondary to gut pathology or immunosuppressive conditions such as diabetes mellitus (11). In this study, three (1.4%) cases of postmenopausal patients were encountered; two had acute appendicitis while the other one had diabetes mellitus.

Majority (27.9%) of patients with pelvic abscess were nulliparus while 8.8% had a parity of above four. Single women comprised the majority (68.9%) of the cases while 22.5% were married. These results agrees with those observed by both Fomulu (1981) and Chebrot (1985) (11,12). They had observed that majority of patients with pelvic abscess were nulliparus comprising between 20-59%, and that its incidence declined with increasing parity; being rare above the parity of four (1,16). This study, as well as other studies, shows that pelvic abscess is commonest among the young, unmarried and sexually active women.

Most studies, have identified sexual transmitted infections (STI) including acute pelvic inflammatory disease (PID) as the major cause of pelvic abscess, followed by post-abortion and puerperal sepsis among women in their reproductive years (3,11,12).

In his study, Fomulu (11) found that 8.75% of pelvic abscess at Kenyatta National Hospital were preceded by post-abortion sepsis. In contrast, this study found that post-abortion sepsis preceded pelvic abscess in majority (33.3%) of the cases while STI/PID and puerperal sepsis preceded pelvic abscess in 16.7% and 11.7% respectively. However, this was not surprising given that abortion cases accounted for 63.7% of all acute gynaecological cases managed at KNH during the period of this study. This study also revealed that 89.2% of the abortion cases were induced and only 10.8% were spontaneous while 82.4% of the post-abortion sepsis cases had no uterine evacuation done prior to admission. However, Fomulu (11) found that 62% of abortions were induced while 37.5% occurred spontaneously. This study found that abortion, like pelvic abscess, was more prevalent among the young, unmarried and unemployed sexually active women. It's possible that modern civilization and socio-economic pressures may encourage these women to seek abortion services not only from skilled medical workers but also from unskilled abortionists (20).

Puerperal sepsis preceded pelvic abscess in 11.7% of the cases. It is also instructive that 76.9% of the deliveries occurred at home with the assistance of traditional birth attendants (TBA) or self assisted. Only 23.1% of deliveries occurred at health facilities. These figures compares well with Kenya national estimates of 80% home deliveries and 20% of health facility deliveries (21,22). These worrying figures of puerperal sepsis preceding pelvic abscess would probably decline if easy accessibility and affordable health care whereby clean and safe delivery under skilled attendants was provided for.

Sixty-seven cases of pelvic abscess were tested for HIV infection. Forty cases (59.7%) were HIV positive while 40.3% were HIV negative. Of those who tested HIV positive, 22.5% had STI/PID compared to only 3.7% of STI/PID among those who tested HIV negative. These figures may not reflect the true picture given that only 67 out of 222 cases were tested for the HIV infection.

This may partly explain why the association between HIV and pelvic abscess secondary to STI/PID was not statistically significant (P-value = 0.13). However, Wanyonyi (2002) found a HIV seroprevalence rate of 40% among PID/pelvic abscess patients while Ayoma (1990) reported a HIV prevalence rate of 21% among patients presenting with PID - both studies were done at KNH (23,24).

The national HIV seroprevalence among women of reproductive age is estimated as 13% (NASCOP 1999). So far no local studies have been done to determine the HIV seroprevalence rate among patients with pelvic abscess per se. A large prospective study requires to be undertaken in order to give a clear picture of what is happening currently.

In Kenya studies have revealed a wide gap between knowledge of contraceptive methods (> 90% of married women) and use (33% of currently married women) (21). This study found that 83.9% of the patients had not used any contraception giving only 16.1% contraceptive use. Twelve cases had no contraception history indicated in their case files. These figures are worrying given that both puerperal and post abortion sepsis reflects lack of contraception or failure and that they preceded 45% of the pelvic abscess cases. If properly used, condoms are known to offer protection against STI and pregnancy. However, it's worrying that only 0.95% had used barrier methods (condoms) yet STI/PID preceded 16.7% of the pelvic abscess cases while 59.7% of those tested for HIV infection were positive.

Pus swabs for culture and sensitivity were taken intra-operatively in 59 cases of pelvic abscess. Positive cultures were identified in 34 cases (57.6%) while sterile growth (no growth) was observed in 25 (42.4%) cases. The sterile growth could be attributed to prior antibiotic use. *Escherichia coli* accounted for the majority (20.3%) of the positive cultures, *Staphylococcus aureus* 11.9% and *Enterococcus* species 10.1%. One case of *Neisseria gonorrhoea* was isolated. These results compares fairly well with those of Chebrot's (1985) study (12). He had positive culture rate of 53.8%, *Escherichia coli* accounted for the majority (23.1%) of isolates, *Staphylococcus aureus* 15.4%, while both *Chlamydia* and *Ureaplasma* species accounted for 6.7% (12). However, both *Chlamydia* or *Ureaplasma* species were not isolated from specimens in this study.

Pelvic abscess secondary to post abortal sepsis accounted for the majority (52.3%) of the deaths and closely followed by HIV/AIDS (33.3%). The association between mortality and pelvic abscess secondary to post-abortal sepsis, and HIV/AIDS was statistically significant (P-value < 0.001). This study revealed that post-abortal sepsis is the leading cause of pelvic abscess as well as mortality associated with it. This probably reflects the skills of the abortionist and the unhygienic conditions under which these abortions are carried out.

Forty-two patients who were part of the study were later attended to with various complications within the study period (1998-2002) that were highly attributable to pelvic abscess.

The commonest complication was infertility (35.7%), chronic lower abdominal pain (21.4%) and deep dyspareunia (26.2%). The majority of infertility cases were associated with pelvic abscess secondary to post-abortal sepsis and STI/PID, comprising 33.3% and 26.7% respectively. However, the association was not statistically significant (P-value = 0.66). Pelvic abscess causes damage of the pelvic structures (or organs) and subsequent adhesions which may give rise to a frozen pelvis. Infertility due to a frozen pelvis has a poor prognosis even in this era of advanced medical technology (17). Adhesions may also cause deep dyspareunia due to a retroverted uterus.

CONCLUSIONS

1. Pelvic abscess accounted for 3.8% of all acute gynaecological admissions.
2. Majority of pelvic abscess cases occurred in the young, unmarried and unemployed sexually active women of low parity.
3. Majority of the patients with pelvic abscess had no prior use of contraception.
4. Post-abortal sepsis was identified as the major cause of pelvic abscess among women of reproductive age.
5. Anaemia, wound sepsis, peritonitis and septicacimia were found to be the major complications of pelvic abscess. Pelvic abscess was associated with a mortality rate of 9.5%.
6. While the offending organisms in pelvic abscess have remained fairly the same, the antibiotic sensitivity pattern has drastically changed over the years. Augmentin (Clavulanic acid/ amoxicillin) should be the drug of choice in pelvic abscess management while Gentamycin and Kanamycin are still useful. However, Tetracycline and Co-trimoxazole are of limited use.

RECOMMENDATIONS

1. Taking pus swabs for both culture and sensitivity intra-operatively for both anaerobic and aerobic organisms should be encouraged. This will enhance prompt and effective management of pelvic abscess cases thereby reducing the morbidity and mortality associated with it.
2. Doubling our efforts, in raising the contraceptive usage rate in Kenya so as to reduce unwanted pregnancies, HIV/AIDS and other STI.
3. Improved accessibility and affordable health care system whereby clean and safe delivery under skilled attendants is provided for.
4. Uterine evacuation for cases of incomplete abortion and use of appropriate and effective anti-biotics regimes as documented by sensitivity tests to prevent post-abortal sepsis and its complications. The current debate on whether to legalize abortion or not in Kenya should be encouraged in order to chart the way forward in reducing the morbidity and mortality associated with abortion.
5. A large prospective study to find out how abortion, PID, post-gynaecological surgery and puerperal sepsis patients' are managed; including specific anti-biotics and sensitivity patterns.

References

1. Maclean A B
Pelvic infections
In: Dewhurst's textbook of Obstetrics and Gynaecology for postgraduates, 6th edition, Blackwell Science publications, 1999; Pg 3940 – 3949.
2. Dutta D.C.
Infections of the individual pelvic organs
In: Textbook of gynaecology, New Central, publications, 2001;
Pg 165-167
3. Martens M G.
Pelvic Inflammatory Diseases
In: Te Linde's Operative Gynaecology, 8th edition, Lippincott - Raven.
Philadelphia, 1997; Pg. 657-685.
4. Thomas M.D. Joseph A.H.
Pelvic infections
In: Novak's Gynaecology, 13th edition Lippincott Williams and Wilkins,
Philadelphia, 2002; page 431 – 459.
5. Allan H D, Martin L.P.
Sexually Transmitted Diseases and pelvic infections
In: Current Obstetric and Gynaecologic diagnosis and treatment, 8th edition .
Appleton and Lange. 1994; Pg 773 – 782.
6. Landers D V, Sweet RL
Current trends of diagnosis and treatment of Tubo-ovarian abscesses
AM J Obstet. Gynaecol 151:1098; 1989
7. Cartey MJ, Nzioki JM, Verhangen AB
The role of gonococcus in acute pelvic inflammatory disease in Nairobi
East Afr. Med. J. 49: 376, 1972

8. Tindall V R.
Infections as they affect individual organs
In: Jeff Coate's principles of gynaecology. 5th edition. Butterworth Heinmann Publishers, Pg 328-334; 1987.
9. Cunningham F G, Gant E N
Pueperal sepsis
In: Williams Obstetrics, 21st edition, McGraw-Hill publications, 2001;
Pg 672-674
10. Gilstrap L.C, Cunningham F. G.
The Bacterial pathogenics of infections following caesarean section
A M J Obstet. Gynaecology 1997; **89**: 409
11. Fomulu J N
Bacterial and sensitivity patterns in post-abortal sepsis and associated pelvic abscess
M Med Thesis, University of Nairobi, 1981
12. Chebrot CS
Pelvic abscess in the female genital tract
M. Med thesis, University of Nairobi, 1985.
13. Precis S
Pelvic infections
An update in Obstetrics and Gynaecology Vol 4, 17: 171 – 179; 1986.
14. Corsi P J, Johnson S C, Gonic B
Transvaginal guided aspiration of pelvic abscess
J Obstet. Gynecol, 1999; 7: 216 – 221.
15. Walker C K, Daniel V L
Pelvic abscess: New trends in management
Obstet. Gynecol Surv 1991; **46**: 615 – 619.\

16. Maurice K, Bewes P, Cairns J et al
The surgery of sepsis
In: Primary surgery: non-trauma, Vol 1, Oxford medical publications, 1990;
Pg 161 – 178.
17. Frederick R J
Severe pelvic infection and infertility
Emedicine journal, April 5th 2000, vol 3 No. 4 at <http://www.emedicine.com>
18. Spence M
PID: Detection and treatment
STD Bulletin, John Hopkins University, Vol 3, No.1, 1993; Pg 16 – 22.
19. Mati JKG, Aggarwal NP
Review of Abortion at KNH, Nairobi
East Afr Med. J 57:111, 1980
20. Savage W D, Khehar B S
Septic abortion
East Afr Med. J 46:634, 1969.
21. Implementation plan for national reproductive health strategy, 1999 – 2003
Ministry of health, Kenya, 1998; 3:24
22. National reproductive health strategy; 1997 – 2010
Ministry of health, Kenya, 2000; 4:63-81
23. Wanyonyi C H W
Determination of HIV seroprevalence in patients with PID/pelvic abscess at KNH
M.Med Thesis , University of Nairobi, 2002
24. Ayoma O. Ojwang
Determination of HIV seroprevalence in patients with PID at KNH
M.Med Thesis, University of Nairobi, 1990

Appendix 1

Study questionnaire

TITLE: PELVIC ABSCESS AS SEEN AT KHN – A 5-YEAR RETROSPECTIVE
STUDY

Data Collection sheet

Date _____

A. Socio Demographic Data

1. Patient's identification date

--	--	--	--

2. Age in completed years

--	--

3. Residence

--

4. Educational Background

(Tick appropriate)

None	
Primary level	
Secondary level	
College	

5. Marital status

Single	
Married	
Divorced/separated	
Widowed	

6. Nature of Employment

Employed	
Self employed	
Not employed	
Others (specify)	

B. Obstetric And Gynaecological Data

1. Patient admitted/Referred from:

Home	
Private clinic	
Health center/dispensary	
Not indicated	

2. Parity

(i) Number of Births

(ii) Number of abortions/ectopic pregnancies

(iii) Total number of pregnancies (i +ii)

3. Recent history of delivery? _____ yes/no

If yes _____ (tick appropriately)

Home delivery	
Private clinic	
Health center/disp	
Hospital delivery	

4. Recent History of Abortion? _____yes/no

(a) If yes _____ (tick appropriately)

Spontaneous abortion	
Induced abortion	

(b) Gestation by dates

(c) Was Dilatation and Curretege (D & C) done _____yes/No

5. Patient had recent abdominal surgery _____yes/no

If yes _____ (tick appropriately)

Caesarean section	
Ectopic pregnancy	
Appendectomy	
Others (specify)	

6. Patient had a recent sexually transmitted disease(s) _____yes/No

If Yes _____ (tick appropriately)

Gonococcal / chlamydia	
Pelvic inflammatory disease	
Others (specify)	

7. Patient's HIV status

(Tick appropriately)

Positive	
Negative	
Not indicated	

8. Type (s) of contraceptive method(s) used

IUCD	
Oral pills	
Injectables	
Norplant	
Barrier methods	
Natural	
None	
Not indicated	

C. SEASONAL VARIATION

1. Month of occurrence

D. TREATMENT AND COMPLICATIONS

1. Was a pus swab taken intra- operative for culture and sensitivity? _____ Yes/ No

If yes; -

(i) What bacteria(s)/ organism(s) was isolated?

(ii) To which drug(s) were the organisms :

(a) Sensitive to _____

(b) Resistant to _____

(iii) Which drug(s) were prescribed and given to the patient?

2. Was the patient transfused any blood? _____ Yes / No

If Yes, indicate the number of units _____

3. Was there any post-operative complications (s) _____ Yes / No

If Yes – (tick appropriately)

Haemorrhage	
Wound sepsis	
Burst abdomen	
Peritonitis	
Death	
Others (specify)	

5. Duration of hospitalization _____ days

6. Was the patient ever re-admitted/ re-attended later (within study period: 1998-2002):

Infertility	
Ectopic pregnancy	
Chronic abdominal pains	
Dyspareunia	
Others (specify)	

Appendix 2

TOPIC: The prevalence of foetal distress due to cord entanglement among the patients undergoing emergency caesarean delivery at Kenyatta national Hospital.

CONSENT FORM

Foetal distress is among the commonest indications of emergency caesarean section at Kenyatta National Hospital.

I Dr John M. Murima, a postgraduate student at the University of Nairobi; I am carrying out a study to determine the prevalence of cord entanglement and outcome among patients with foetal distress undergoing emergency caesarean section.

The findings from this study may shed some light on the significance of cord entanglement as a cause of foetal distress, subsequent neonatal morbidity and mortality.

All findings shall be treated as confidential and if for any reason you decline to take part in this study then your treatment and management will not be interfered with whatsoever.

I have read and understood the meaning of this study and what it entails. I have been given a chance to ask questions and I also have the choice to withdraw from this study at any time if I so wish.

I hereby on my own free will and without coercion give consent to take part in this study.

Name and signature of the subject _____

Date _____

Name and Signature of investigator _____

Date _____

QUESTIONNAIRE

Date ___/___/2003

A. SOCIO- DEMOGRAPHIC CHARACTERISTICS

Patient's identification date _____
Age in completed years _____
Educational Background None/Primary/Secondary/Tertiary
Marital Status Single/Married/Divorced or Separated/Widowed
Nature of Employment Employed/Self Employed/Not employed/Others

B. OBSTETRIC HISTORY.

a. PARITY.

- a. Number of births _____
- b. Number of abortions/Ectopics _____
- c. Total number of pregnancies _____

b. CURRENT PREGNANCY.

- 1. Date of last menstrual period (LMP) _____
- 2. Expected date of delivery (EDD) _____
(Calculated from LMP)
- 3. Maturity by dates (MBD) _____

C. EXAMINATION FINDINGS

- 1. Fundal height _____
- 2. Foetal heart rate (FHR) _____ beats / min.
 - a) Normal /Bradycardia /Tachycardia
 - b) Regular/ Irregular.
- 3. Colour of amniotic fluid - Clear /MSL-1/MSL-2/MSL-3.
- 4. Cervical dilatation (when foetal distress diagnosis is made) _____ cm.

D. FINDINGS AT CAESAREAN SECTION.

1. Cord entanglement present ___ yes /No.
2. Single/double/triple cord wrappage around the foetal neck. _____
3. Site of cord entanglement _____ neck, upper limb(s), lower limb(s), abdomen/thorax.
4. Colour of liquid _____ clear /MSL1/ MSL2/ MSL3.
5. Cord length _____ cm.
6. APGAR scores at _____ 1 min, _____ 5 min.
7. Sex of Newborn _____ M/F
8. Birth Weight _____ grams

E. 48 HOURS - FOLLOW UP IN NEW BORN UNIT (NBU)

1. Baby joins mother _____ Yes/ No
2. Baby admitted to new born unit (NBU) _____ Yes/ No
3. Baby's condition in NBU within 48 Hours _____ Still Sick/ Discharged/ Dead.
4. Diagnosis/ cause of death _____.



KENYATTA NATIONAL HOSPITAL

Hospital Rd. along, Ngong Rd.
P.O. Box 20723, Nairobi.

Tel: 726300-9

Fax: 725272

Telegrams: "MEDSUP", Nairobi.

Email: KNHplan@Ken.Healthnet.org

Ref: KNH-ERC/01/2149

Date: 11 February 2004

Dr John M Murima
Dept of Obs/Gynae
Faculty of Medicine
University of Nairobi

Dear Dr. Murima,

RESEARCH PROPOSAL "THE PREVALENCE OF FOETAL DISTRESS DUE TO CORD
ENTANGLEMENT AMONG PATIENTS UNDERGOING EMERGENCY CAESERIAN DELIVERY
AT KENYATTA NATIONAL HOSPITAL" (P71/7/2003)

This is to inform you that the Kenyatta National Hospital Ethics and Research Committee has reviewed and approved the revised version of your above cited research proposal for the period 11 February 2004 – 10 February 2005. You will be required to request for a renewal of the approval if you intend to continue with the study beyond the deadline given.

On behalf of the Committee, I wish you fruitful research and look forward to receiving a summary of the research findings upon completion of the study.

This information will form part of database that will be consulted in future when processing related research study so as to minimize chances of study duplication

Yours sincerely,

PROF. A. N. GUANTAI
SECRETARY, KNH-ERC

Cc Prof. K M Bhatt, Chairperson, KNH-ERC
The Deputy Director (C/S), KNH
The Dean, Faculty of Medicine, UON
The Chairman, Dept of Obs/Gynae, UON
CMRO

Supervisors: Dr. J B Oyieke, Dept of Obs/Gynae, UON
Dr. Kamau Gichuru, Dept. of Obs/Gynae, UON



KENYATTA NATIONAL HOSPITAL

Hospital Rd. along, Ngong Rd.

P.O. Box 20723, Nairobi.

Tel: 726300-9

Fax: 725272

Telegrams: "MEDSUP", Nairobi

Email: KNHplan@Ken.Healthnet.org

Ref: KNH-ERC/01/2078

Date: 17 December 2003

Dr. John M. Murima
Dept of Obs/Gynae
Faculty of Medicine
University of Nairobi

Dear Dr. Murima

RESEARCH PROPOSAL, "PELVIC ABSCESS AS SEEN AT KENYATTA NATIONAL HOSPITAL
A5-YEAR RETROSPECTIVE STUDY" (P104/9/2003)

This is to inform you that the Kenyatta National Hospital Ethics and Research Committee has reviewed and approved the revised version of your above cited research proposal for the period 17 December 2003 – 16 December 2004. You will be required to request for a renewal of the approval if you intend to continue with the study beyond the deadline given.

On behalf of the Committee, I wish you fruitful research and look forward to receiving a summary of the research findings upon completion of the study.

This information will form part of database that will be consulted in future when processing related research study so as to minimize chances of study duplication.

Yours sincerely,

PROF. A. N. GUANTAI
SECRETARY, KNH-ERC

Cc Prof. K. M. Bhatt, Chairperson, KNH-ERC
The Deputy Director (C/S), KNH
The Dean, Faculty of Medicine, UON
The Chairman, Dept. of Obs/Gynae, UON
CMRO
Supervisors: Dr. J. B. Oyieke, Dept. of Obs/Gynae, UON
Dr. Kamau Gichuru, Dept. of Obs/Gynae, UON