

DISSERTATION

A 5 YEAR'S RETROSPECTIVE CASE SERIES ON THE CLINICAL PROFILE AND MANAGEMENT OF RETINOBLASTOMA AT MAPUTO CENTRAL HOSPITAL, MOZAMBIQUE

Dr. LÁCEA STELA ALFREDO DIMANDE

H58/81632/12

**A RESEARCH DISSERTATION SUBMITTED IN PARTIAL
FULFILMENT FOR THE AWARD OF DEGREE OF MASTER OF
MEDICINE (OPHTHALMOLOGY), UNIVERSITY OF NAIROBI,
KENYA**

©2016

DECLARATION

I declare that this research dissertation is my original work.

PRINCIPAL INVESTIGATOR:

Dr. LÁCEA S. AFREDO DIMANDE

MB. ChB (Camaguey, Cuba), Postgraduate student (Nairobi)

Signed

Date

APPROVAL

This dissertation has been submitted in part fulfilment of the degree of master of medicine (ophthalmology) with our approval as university supervisors:

Prof. Dunera Rahel Ilako

MB.ChB, (NBI) MMed Ophthalmology (NBI); MBA – Health (Durban); F.E.A.C.O
Ass. Prof. Department of Ophthalmology,
University of Nairobi, Kenya

Signed _____ Date _____

Dr. Emmanuel. M. Nyenze


MB.ChB, MMED Ophthalmology (NBI); F.E.A.C.O
Sub-Specialist; Oculoplastic /Orbit/Ocular Oncology
(LV Prasad Eye Institute and Aravind Eye Hospitals- India)
Lecturer, Department of Ophthalmology
University of Nairobi, Kenya


Signed _____ Date _____

Dr. Yolanda Zambujo

MB.ChB, MMED Ophthalmology
Consultant Ophthalmologist, Department of Ophthalmology
Maputo Central Hospital, Mozambique

Signed:





Date: 23 Maio 2016

ACKNOWLEDGEMENT

To God for guiding and helping me in all steps of this appreciated course.

To my supervisors (Prof. Ilako, Dr Nyenze, Dr. Yolanda as well as Dr. Faizana) for your constructive knowledge, dedication and hard work helping with many ideas to build this research work.

To all the lecturers of the department of Ophthalmology University of Nairobi especially the retinoblastoma team (Dr. Kimani and Dr. Njambi) for guiding and giving the necessary contributions for a better understanding of this study.

To the Ministry of health of Mozambique and my sponsors Light for the World for sponsoring my study, guiding and helping me to believe that I can be an Ophthalmologist.

To the staff members of Maputo Central Hospital /Department of ophthalmology for the assistance during the data collection period.

To my colleagues and special friends who motivated and help me.

To my lovely family who encouraged me and believed that I can transform my dream to reality.

DEDICATION

This book is dedicated to the Ministry of Health of Mozambique and Maputo Central Hospital for allowing us to do the study and by facilitating access to the retinoblastoma patient records. I hope this study will help in understanding the reality of care of retinoblastoma patients in Mozambique in view of their improved management.

To my Parents: Alfredo Laisse Dimande and Celeste Geremias Muiambo Dimande for the lovely and strong support.

To the retinoblastoma patients who inspired me to know more about the disease and help them to have an opportunity of a quality life as any other person.

CONTENTS

DECLARATION	i
APPROVAL	ii
ACKNOWLEDGEMENT	iii
DEDICATION	iv
CONTENTS	v
LIST OF TABLES	vii
LIST OF FIGURES	viii
LIST OF ABBREVIATIONS	ix
ABSTRACT	x
1.0 INTRODUCTION	1
1.1 LITERATURE REVIEW	2
1.1.1 Epidemiology Of Retinoblastoma.....	2
1.1.2 Risk Factors and Prognosis	3
1.1.3 Age at Presentation	4
1.1.4 Sex Distribution	5
1.1.5 Genetics of Retinoblastoma	6
1.1.6 Laterality of Retinoblastoma.....	7
1.1.7 Secondary Tumors in Retinoblastoma	7
1.1.8 Clinical Features Of Retinoblastoma	8
1.1.9 Diagnosis of Retinoblastoma	9
1.1.9.1 Clinical.....	9
1.1.9.2 Histopathologic Studies	10
1.1.9.3 Imaging Studies	11
1.1.10 Management of retinoblastoma.....	12
2.0 STUDY RATIONALE	18
3.0 OBJECTIVES	18
3.1 Broad Objective	18
3.2 Specific Objectives	18
4.0 METHODOLOGY	19
4.1 Study design.....	19
4.2 Study area.....	19
4.3 Study Setting.....	20
4.4 Ethical considerations	21

4.5 Study Population: Source Population	21
4.6 Inclusion Criteria	21
4.7 Data collection Procedure	22
4.8 Required tools	22
4.9 Data Management	22
4.10 Data Storage.....	23
4.11 Data Analysis	23
4.12 Study duration.....	24
5.0 RESULTS	25
6.0 DISCUSSION	43
6.1 Overview and demographic characteristics	43
6.2 Age at presentation, risk factors and prognosis	43
6.3 Laterality	45
6.4 Sex distribution and family history	45
6.5 Delay	46
6.6 Clinical features of retinoblastoma	47
6.7 Diagnosis of retinoblastoma	48
6.7.1 Imaging studies	48
6.7.2 Histopathology findings and Prognosis	49
6.8 Management.....	51
6.8.1 Treatment Modalities, Indications and Regime	51
6.9 CONCLUSIONS.....	54
6.10 RECOMMENDATIONS	55
6.11 STUDY LIMITATION.....	56
REFERENCES.....	57
APPENDICES	65
APPENDIX I: Reese-Ellsworth Classification of Retinoblastoma for Eye Preservation	65
APPENDIX II: International Classification of Retinoblastoma.....	66
APPENDIX III: International Retinoblastoma Staging System	67
APPENDIX IV: Questionnaire.....	68
APPENDIX V: Gantt Chart Showing Timeframe	75
APPENDIX VI: Budget.....	76
APPENDIX VII: Letter of Approval from Maputo Central Hospital	78
APPENDIX VIII: KNH/UON-ERC Approval Letter.....	80

LIST OF TABLES

Table 1 : Age at presentation of retinoblastoma patients from studies done in African countries:.....	5
Table 2: Distribution of retinoblastoma patients by Province of residence (n = 57).....	26
Table 3: Distribution based on Initial Diagnosis (n=57)	27
Table 4: Distribution by age at presentation vs. laterality (n= 57)	29
Table 5: Family history (n=34).....	30
Table 6: Duration from symptoms to diagnosis at MCH (n= 34).....	31
Table 7 : Duration from diagnosis to primary management (n =34)	32
Table 8: Duration from symptoms to initial management (n=34)	32
Table 9: Presenting Complaint.....	33
Table 10: Clinical signs of Retinoblastoma	33
Table 11: Patients who had EUA and Ocular Ultrasound (n = 34)	34
Table 11.1: Ocular Ultrasound Findings (n=5).....	34
Table 12: Other investigation (CTscan /MRI) n=34.....	35
Table 12.1 MRI findings (n=5).....	35
Table 13: Patients who had surgery (n = 57)	36
Table 13.1: Interventions (n= 49)	36
Table 14: Histology report.....	37
Table 14.1: Histology report based on the invasion and extension of ocular and periocular structures	38
Table 15: Number of patients who received chemotherapy (n=34)	39
Table 15.1: Eligible patients for chemotherapy (n= 34)	39
Table 15.2: Reasons of no chemotherapy in the 22 patients with available file.....	40
Table 15.4: Chemotherapy regimen (n=12).....	41
Table 15.5: Number of courses of chemotherapy given (n=12)	41
Table 16: Number of patient on follow up (n=57).....	42

LIST OF FIGURES

Figure 1: Map of Mozambique, showing location of Maputo City	19
Figure 2 Map of an area of Maputo City, showing Maputo central hospital.....	20
Figure 3: Flowchart.....	25
Figure 4: Distribution of retinoblastoma patients found by Province of residence	26
Figure 5: Distribution of cases by age of presentation (n= 57)	28
Figure 6 : Laterality (n= 57).....	29
Figure 7: Sex Distribution of Cases (n=57)	30

LIST OF ABBREVIATIONS

CNS	Central Nervous System
CT scan	Computerized Tomographic Scan
EBRT	External Beam Radiotherapy
ERC	Ethics and Research Committee
EUA	Examination Under Anesthesia
ICCC	International classification of Childhood Cancer
IICR	International Intraocular Retinoblastoma Classification
KNH	Kenyatta National Hospital
MCH	Maputo Central Hospital
MRI	Magnetic Resonance Imaging
NACT	Neoadjuvant Chemotherapy
ON	Optic Nerve
RB1	Retinoblastoma gene (Tumour suppressor gene)
RBL	Retinoblastoma
SPSS	Statistical Package for Social Scientists
SQL	Structured Query Language
TRb	Trilateral Retinoblastoma
UK	United Kingdom
UoN	University of Nairobi
USA	United States of America
VEC	Vincristine, Etoposide, Carboplatine

ABSTRACT

Background: Retinoblastoma is the commonest intraocular malignancy in childhood. The national epidemiological characteristics of retinoblastoma in Mozambique are not clearly known. Early diagnosis and appropriate treatment leads to a favourable outcome while a delayed diagnosis and inappropriate treatment can be fatal.

Objective: To determine the pattern of presentation and management of retinoblastoma patients at Maputo Central Hospital during a 5 year period (1/01/ 2010 to 31/12/ 2014)

Methodology: The study was a descriptive retrospective case series carried out at the ophthalmology Services, Paediatric Oncology ward and theatres of Maputo Central Hospital. Records of all retinoblastoma patients within the identified timeframe were retrieved with the help of the specific file number. Demographic characteristics, clinical presentation, investigations and management modalities of retinoblastoma patients as well as discharge/death records were retrieved. Data was extracted and entered into a structured questionnaire and analysed.

Results: A total of 57 patients from 7 different provinces of Mozambique had clinical, histological or both clinical and histological diagnosis of retinoblastoma. The overall mean age at presentation was 30.5 months (CI 24.65 - 36.05) (SD 21.5); 82.4 % of cases had unilateral retinoblastoma while 12.3 % of cases had bilateral (mean age at presentation was 30.2 months and 26.4 months respectively).The sex was almost equally represented among the patients with an F: M ratio of 1.2:1. The main presenting complaint was white reflex(62.5 %) followed by eye swelling (50 %) , eye redness (40 %) and poor vision (32.5%) while the main clinical sign were leukocoria (55%) followed by proptosis (50%) and eye redness (27.5%). Out of the 51 eyes who had surgery: 96 % did not have documentation of the choroid and 98 % of the scleral, but 54.9 % of the eyes had optic nerve involvement, 33.3 % had resection margin involvement and 31.4% had periocular tissue involvement. The main modalities of management were enucleation (93.9%), chemotherapy (24.5%) and exenteration (18%). The eligible patients for chemotherapy were 67.7% but only 35.3% of the patients received chemotherapy.

Conclusion: Many patients presented at older ages and late with advanced orbital disease. Majority of the patients had unilateral retinoblastoma. Significant number of patients had optic nerve, resection margin and periocular tissue involvement noted on histology. The main modalities of management were enucleation, exenteration and chemotherapy, although there were no clear eligibility criteria for chemotherapy in retinoblastoma patients who needed.

1.0 INTRODUCTION

Retinoblastoma accounts for about 3% of all childhood cancers and is the commonest primary intraocular malignancy in childhood affecting children less than 5 years with over 90% being diagnosed before 3 years, while Uveal Melanoma is the commonest intraocular malignant tumour in adults and overall. There is no racial or gender predisposition in the incidence of retinoblastoma¹.

Untreated retinoblastoma is almost uniformly fatal, therefore, early diagnosis and treatment is critical in saving lives and preserving the visual function. With availability of resources for early detection and improvements of treatment modalities, the management of retinoblastoma has been changing over the years and the prognosis for vision and life in patients with retinoblastoma has improved significantly in the last 20 years especially in developed countries².

Many studies have been done in African countries looking at the pattern of Retinoblastoma including in South Africa, Kenya, Nigeria, Tanzania, Ghana, Malawi, and Congo. However a similar study has never been done in Mozambique. In studies in Africa, the survival rate has been found to be poor due to multiple factors including the age at presentation, late presentation, proptosis, recurrent disease, metastatic disease and extraocular disease on histology^{3, 4}.

Mozambique is also a developing country in the Southeast of Africa with a total population of approximately 21,397,000 and has 11 administrative provinces. Each province has a Provincial Hospital that provides eye care and receives cases of retinoblastoma referred from the District hospitals. Maputo Central Hospital is one of the biggest hospitals of the country located in the capital of Mozambique (Maputo) and receives patients referred from different parts of the country.

1.1 LITERATURE REVIEW

1.1.1 Epidemiology Of Retinoblastoma

Currently retinoblastoma is the most common solid tumor in children after nervous system tumors and lymphomas among UK and American children reported by Foucher et al ⁵. Most studies done in African countries for example, Nigeria, found retinoblastoma as the second commonest childhood solid tumor (21%) only after Burkitt's lymphoma (36%)⁶, also in Ghana, Welbeck et al found that retinoblastoma (8.6%) is the second commonest tumor after Burkitt's lymphoma (67%)⁷. In Kenya, Mostert et al in a study of epidemiology of diagnosed childhood cancer in Western-Kenya, found Non-Hodgkin's lymphoma as the commonest type of cancer (34%), followed by acute lymphoblastic leukemia(15%), Hodgkin's lymphoma((8%), nephroblastoma (8%), rhabdomyosarcoma (7%), retinoblastoma (5%) and brain tumor (1%)⁸.

The frequency of retinoblastoma has been increasing over the past 60 years. In USA there are approximately 250 to 300 newly diagnosed cases of retinoblastoma yearly, and worldwide the estimate is approximately 7000 to 9000 cases yearly^{1,9}.

There is a Geographic variation in the incidence and prevalence of retinoblastoma. In Mexico, 6.8 cases per million population have been reported compared to 4 cases per million in the United States. In Central America, there has been an increased incidence in recent years and the highest incidence of the disease has been noted in Africa and India¹. The worldwide incidence of retinoblastoma ranges from 1:14,000 to 1:20,000 live births and varies according to the country¹. Approximately 1: 15,000 to 1:16,600 live births was reported in United States¹⁰ and approximately 1: 20,000 children in Northern Europe¹¹.

While the incidence of retinoblastoma in developing countries of Africa and Asia has been noted to range from 1:10,000 to 1:18,000 live births¹². Freedman reported an incidence of 1:10,000 live births amongst the Bantus of the Republic of South Africa in a 20 year retrospective study¹³ while in Kenya a 2 year retrospective study done by Nyamori et al showed an incidence of retinoblastoma of 1: 17,030 live births¹⁴.

In Nigeria a 6 years retrospective study by Abiose et al found difficulty in determining the true incidence due to lack of accurate demographic and population data, and a weak coordination of the report¹⁵ and the highest retinoblastoma incidence in the world was

1:3,300 reported by Albert et al in Haiti¹⁶. In Malawi, BenEzra et al found annual incidence of 2:100,000 children less than 5years¹⁷.

1.1.2 Risk Factors and Prognosis

The clinical factors for poor prognosis may include late presentation, old age at presentation and advanced disease (proptosis) at the time of diagnosis having a higher risk of disease spread. Tumour recurrence, metastatic disease are other very poor prognostic factors³. It has been reported that a delay of more than 6 months from the first clinical symptoms to diagnosis is associated with 40-70% mortality recorded in developing countries (like in Africa and Asia)¹⁸. Other risk factors associated is the delay of treatment with an interval between onset of symptoms to treatment of more than 5 months and a lag time before treatment of more than 2.5 months²⁰. Nyawira et al found a mean delay between onsets of symptoms to management of 12 months³.

Lack of disease awareness among the population and healthcare professionals, high birth rates, patients seeking for alternative means of healing before coming to hospital, difficult in accessing the health care, fear of enucleation as well as lack of resources in the health facilities (lack of well-established tertiary care centers) and high costs of hospital care are correlated factors^{3, 9, 18- 22}.

The most important histopathologic high-risk and prognostic factors identified following enucleation are massive choroidal infiltration, invasion of the optic nerve lamina cribrosa, retro-laminar optic nerve invasion including the resection margin, scleral infiltration and extrascleral extension. This factor can predict metastasis, being vital for patient selection for adjuvant therapy. Other histopathologic high- risk factors include anterior chamber seeding, Iris and Ciliary body infiltration^{4, 18, 20, 23, 24}.

The survival rate has improved from approximately 30% in the 1930s to over 90% in the 1990s. MacCarthy et al showed an improvement of 5 year survival rate from 89% to 95% during the study period (1978-1997)²⁵ and currently studies are showing a very good survival rate of more than 95% in developed countries². However, in developing countries, the survival is still poor where the majority of patients with retinoblastoma present with advanced disease with the resultant 5 year survival of less than 50%^{3, 14, 18, 21}.

1.1.3 Age at Presentation

Generally Retinoblastoma has an age predilection; affecting children under the age of 5 years with over 90% being diagnosed before 3 years of age¹. The tumour is seldom seen after 3 years of age because the primitive retinal cells generally disappear within the first years of life²⁶ although in India, Singh et al, reported 24 cases in adults aged between 20 years and 74 years²⁷.

In developed countries retinoblastoma patients present at a very young age and for many years the overall median age at diagnosis has been reported as 18 months. The mean age at diagnosis in bilateral cases is 12 months, occurring in 30%-40% of cases and 24 months in unilateral cases occurring in 60%-70% of cases. In approximately 5% of patients with positive family history of retinoblastoma the mean age of presentation is less than 4 months¹.

A large study done in USA covering a 30-year period (1975 – 2004) found that with increasing age at diagnosis the bilateral tumours decreased significantly (no new cases are seen after 3 years) and the percentage of unilateral tumours increased. The peak age of presentation for both bilateral and unilateral retinoblastoma was by 1 year of age, decreasing the incidence steeply with age. Only 4.3% new cases of retinoblastoma were seen between the ages of 5-9 years in this study¹⁰.

In a study done in UK, the peak incidence was in children below 1 year, reducing steadily after 1 year of age (similar to the findings of the USA study) and children older than 4 years made up less than 5% of new cases. The peak age for unilateral cases were in the 2 year age group while in bilateral cases was before 1 year¹¹.

In studies done in developing countries, the age at presentation for retinoblastoma patients has been found to be higher (Table 1).

Table 1 : Age at presentation of retinoblastoma patients from studies done in African countries:

Country	Mean age at presentation month / (yrs)	Bilateral cases month / (yrs)	Unilateral cases month / (yrs)
South-Africa, Freedman et al. ¹³	-	36m (3yrs)	42m (3.5yrs)
Kenya, Kimani et al. ²²	-	26m (2.2yrs)	36m (3yrs)
Kenya, Nyawira et al. ³	37.5m (3.1yrs)	24.4m (2yrs)	39.9m (3.3yrs)
Kenya, Nyamori et al. ¹⁴	33.5m (2.7yrs)	26m (2.2yrs)	35.9 m (3yrs)
Kenya, Makite et al. ³⁶	-	23.6m (1.9yrs)	43.2m (3.6yrs)
Nigeria, Owoeye J et al. ¹²	29m (2.4yrs)	15m (1.3yrs)	31m (2.6yrs)
Tanzania, Bowman et al. ²¹	-	24m (2yrs)	36m (3yrs)
Malawi, Nyaka et al. ²⁸	34.5m (2.9yrs)	19.9m (1.7yrs)	37.2m (3.1yrs)
Congo, Kaimbo et al. ²⁹	35.3m (2.9yrs)	13m (1.1yrs)	38.8m (3.2yrs)

1.1.4 Sex Distribution

Most studies from different parts of the world suggest no sex or race predilection in the incidence of retinoblastoma^{1, 10}.

In Great Britain, MacCarthy et al, showed no difference between males and females in the distribution of retinoblastoma for all ages with an M: F ratio of 1.3: 1.0².

In Southern Africa studies there was a marked male predominance over females 3:1 in bilateral cases and in unilateral cases an M: F ratio of 1.2: 1.0 and overall the M: F ratio is 4:3¹³. In Kenya, Nyamori et al found an M: F ratio of 1.5:1 for confirmed cases,¹⁴ and Nyawira et al, at KNH found an M: F ratio of 1.16:1³.

In Ilorin-Nigeria, Owoeye et al, found a mild female predominance of 1.2:1 overall¹². However, in Ibadan-Nigeria Akang et al, reported a female predominance of 3:2³⁰.

In Tanzania, Bowman et al reported no significant difference between sexes although incidence was slightly higher in males (52%). They also reported an increased incidence of bilateral disease in females (23%) compared to males (10%)²¹.

In Malawi, Nyaka et al reported a presenting male to female ratio of 1.3:1²⁸ while in Congo, Kaimbo et al, showed an M: F ratio of 2:1 predominance for all cases of retinoblastoma seen over a 6 year period to be 2:1²⁹.

1.1.5 Genetics of Retinoblastoma

Retinoblastoma was the first cancer gene identified and cloned in 1986 and is one of the well-studied tumors³¹. It is caused by a mutation in the *RB1* tumour suppressor gene located at the long arm of chromosome 13q14, and has autosomal dominant inheritance with 80 -90% penetrance¹.

The pathogenesis to form a tumor is triggered by a mutation in both alleles of the retinoblastoma gene *RB1*^{18, 32} and the modes of presentation of Retinoblastoma could be Germline or Somatic mutations.

The type of presentation and the family history as well as examination of the parents, can act as a guide to the possibility of heritability, then counselling should be done to all parents with children affected by retinoblastoma keeping in mind that a bilateral retinoblastoma survivor has a 45% chance of having an affected offspring and the siblings, while unilateral survivor has 7-15% of having an affected child with also 45% of chance of sibling being affected and if the parents are normal the chances of the offspring being affected is less than 1 %¹.

Studies done have been showed that approximately 5-8% of all retinoblastoma patients have a family history of retinoblastoma^{1, 33}. Nyawira et al, found positive family history in 8.5% and negative family history in 34.3% (it was found not to significantly affect the survival)³ Makite et al, found a positive family history of retinoblastoma in 6.3 % of cases³⁴ while Nyamori et al, found a family history to be present in only 4.5% of patients¹⁴ and Nyaka et al found only one patient with positive family history²⁸.

1.1.6 Laterality of Retinoblastoma

Studies in different parts of the world also found no eye discrepancy in the incidence of retinoblastoma, affecting equally the right or left eye. Approximately 30-40% of cases are bilateral and 60% of retinoblastoma cases are unilateral^{1,26}.

The study by Broaddus et al in USA, found a proportion of 26.7% bilateral cases and 71.9% unilateral cases, remaining stable over the 30-year study period and in 1% of cases the laterality was unknown¹⁰.

British studies by McCarthy et al found 36% bilateral cases. They also showed that laterality does not rule out heredity although almost 11% of the unilateral retinoblastomas were heritable cases and generally all the bilateral cases were heritable².

In South Africa, in a 20 year period, Freedman et al found 18% bilateral cases and 82% unilateral cases¹³.

In Kenya, Nyamori et al found a proportion of 25.8% bilateral cases and 74.2% unilateral cases¹⁴, almost similar to other study done in KNH by Nyawira et al which found 28% cases had bilateral disease while 72% had unilateral disease, no patient had trilateral disease and the laterality was not found to be significantly associated with survival³.

In Malawi, Nyaka et al study showed 17.6% had bilateral and 82% were unilateral²⁸ while in Nigeria, Owoeye et al found 13% of cases were bilateral¹². In Congo, Kaimbo et al found 21% bilateral cases²⁹.

1.1.7 Secondary Tumors in Retinoblastoma

The most common second cancers among retinoblastoma survivors include: Osteosarcoma, soft tissue sarcoma, pinealomas, melanoma, brain and Central nervous tumours. Leukaemia, lymphoma, breast cancer, bladder cancer and uterine cancers can also develop; therefore the entire body must be carefully examined to avoid missing the second cancers^{1,35}.

Bilateral retinoblastoma survivor has a higher risk for developing second cancer throughout life, with a mean latency after 9 years from the management of primary retinoblastoma. It is associated with 25% incidence of second tumour development within 50 years in patients treated without exposure to the radiation therapy; with an increase incidence in the first 30 years of life in patients using EBRT¹. Therefore it is important to follow up the retinoblastoma survivors and advise in avoiding radiation.

MacCarthy et al reported a 48.3% cumulative risk of developing non ocular malignancy at 50 years after retinoblastoma diagnosis amongst heritable retinoblastoma compared to 4.9% risk for the non-hereditary retinoblastoma³⁶. While Kleinerman et al, found a 36% cumulative incidence for developing a new ocular cancer at 50 years after diagnosis of retinoblastoma in hereditary patients and 5.7% for nonhereditary patients. They concluded that carriers of the retinoblastoma gene have an increased incidence of second tumours over time and the incidence rate increases in patients who receive radiation therapy³⁷.

1.1.8 Clinical Features Of Retinoblastoma

Presenting symptoms and signs of retinoblastoma depend on the tumour size, location, growth pattern (endophytic, exophytic or infiltrative) and its effect on visual functions. A patient with retinoblastoma may present with any one or a combination of symptoms and signs. Generally leukocoria is the commonest presentation (60%) and may first be noticed in family photographs, followed by strabismus (20%) and ocular inflammation (5%) in developed countries. Strabismus usually suggests foveal involvement therefore fundoscopy is mandatory in all cases of childhood strabismus^{1,26}.

In USA, Abramson et al, reported Leukocoria as the most common presenting complaint (56.2%), followed by strabismus (23.6%), poor vision (7.7%) and family history (6.8%). They did not find any correlation between any of the presenting signs and laterality, sex, race, or survival. They also noted that vitreous haemorrhage (0.1%), microphthalmos (0.3%), and orbital cellulites (0.2%) were rare findings on presentation³⁸.

In the developing world the scenario differs, In Kenya, Kimani et al noted that leukocoria was the first symptom (77%) noted by the guardian of retinoblastoma patients at KNH, but proptosis was the most common reason for presenting to the hospital (42.3%) followed by leukocoria (26.9%) and ocular pain/redness (23%); phthisis bulbi and poor vision (3.9%) were the least common presenting complaints²². Nyamori et al found leukocoria in 91.7% of retinoblastoma patients, followed by ocular pain/redness (28.8%) and proptosis (18.2%) nystagmus (1.5%) and phthisis (0.8%) were rare¹⁴.

Nyawira et al, at KNH, found white reflex (71% cases) as the most common presenting complaints followed by eye swelling (37%), poor vision (9.5%), redness (7.6%) and squint (5%). On clinical examination leukocoria was found in 46% of patients, ocular inflammation in 30%, recurrent mass in the socket in 27% of patients and proptosis in 20% of cases. The

results demonstrate that patients who presented with leukocoria only were 4 times more likely to be alive at 3-year follow up and a significant number of patients presented with advanced disease (48% of cases with proptosis /recurrence socket mass). 65% of the patients who died within the 3 year follow up had either proptosis or recurrent masses, associated with very poor outcome³.

In Tanzania, Bowman found that the most common presenting symptoms were leukocoria (56%), proptosis (30%), lid swelling (28%), and strabismus (11%)²². In Malawi, Nyaka et al found white reflex (66.2%) as the most common presenting complaint followed by proptosis (44.1%) and poor vision (36.8%). In correlation with clinical findings, leukocoria was 66.2%, proptosis (30.9%), orbital cellulites and anterior staphyloma (13.2%)²⁸.

In Congo, Kaimbo et al noted that most of the patients presented with leukocoria (49%) and proptosis (28%). Strabismus, red eye, anterior scleral staphyloma, hyphaema and buphthalmos were rare presentations²⁹.

1.1.9 Diagnosis of Retinoblastoma

1.1.9.1 Clinical

Diagnosis of retinoblastoma is mainly clinical; usually made after symptoms and signs of the disease are noted by the parents or pediatricians. Patients with a positive family history of retinoblastoma must be examined in early infancy and have a regular follow up examination. Generally a complete physical examination should be done, where vision helps to determine whether there is macula involvement and abnormal extraocular motility may point towards trilateral disease. Fundoscopy should be performed ideally during examination under anaesthesia (EUA) using an indirect ophthalmoscopy and scleral indentation in both eyes after full mydriasis looking at the far periphery to rule out pre-equatorial tumours that may be missed considering that one eye may harbour multiple tumours. All findings should be documented with colour drawings or photography²⁶.

Diffuse retinoblastoma invading the anterior segment tends to present in older children. It may cause a red eye due to tumour-induced uveitis and iris nodules or may be associated with iris neovascularisation, hyphaema and pseudohypopyon having a relative increased risk for metastatic disease¹.

The results demonstrate that a significant number of patients in developing countries of Africa have advanced (orbital) disease at the time of diagnosis with high risk of metastatic disease (involvement of regional lymph nodes and brain)^{3, 21, 28} unlike developed countries that diagnose very early^{2, 10, 11}.

In Tanzania, Bowman et al found 8 patients had metastatic disease at presentation (4 scalp and 4 skeletal) and 11 patients developed metastases during follow-up (5 scalp, 2 skeletal, 4 CNS). None had lymph node involvement at presentation but 2 of those with metastatic disease developed lymph node involvement during follow-up²¹.

1.1.9.2 Histopathologic Studies

Confirmation of retinoblastoma is by histological report. Several features can be found on histology: Small basophilic cells (retinoblasts), large hyperchromatic nuclei and scanty cytoplasm. Also retinoblastoma may be associated with cellular necrosis and prominent calcifications. Many retinoblastomas are undifferentiated and the well differentiated tumors are characterized by the formation of rosettes including: *Flexner–Wintersteiner*, *Homer–Wright* ('pseudorosettes') and *Fleurettes* resembling a bouquet of flowers²⁶. Shuangostsi et al found that *Homer Wright rosettes* were observed in all tumors, *Flexner–Wintersteiner rosettes* in 33.3% and *fleurettes* in 2.6%³⁹.

The growth patterns observed in retinoblastoma could be endophytic (into the vitreous), with seeding of tumor cells throughout the eye or exophytic (into the subretinal space), causing retinal detachment. Palazzi et al, found endophytic retinoblastoma (60.9%) being more common than exophytic retinoblastoma (39%) in enucleated globes with unilateral retinoblastoma, although they noted that choroidal invasion occurred significantly more often in patients who had exophytic retinoblastoma⁴⁰.

Retinoblastoma may arise from primitive bipotential or multipotential cells capable of neuronal and glial differentiation⁴¹. Primarily it affects the retina and later it may advance to involve the optic nerve or beyond, choroid and sclera. On histology optic nerve involvement beyond the lamina cribrosa with or without resection margin involvement, choroidal involvement (massive), scleral or extrascleral involvement, anterior chamber or uveal structures infiltration may be found as the most important histopathologic high-risk factors for metastasis, presence of tumour at the optic nerve surgical margin is considered the major prognostic factor for the disease dissemination with a mortality rate of 50-81%^{4, 18, 23, 24, 42, 43}.

Therefore proper histological diagnosis is very important in predicting the prognosis and deciding the management of retinoblastoma.

Studies done by Uusitalo et al (n=129) found optic nerve involvement in 63.5% of cases (11.6 % of whom had tumor extension beyond the lamina cribrosa and 3.1 % had involvement of optic nerve resection margin). Choroid involvement was in 33.3 % of patients (where 9.3% had massive choroidal involvement). Also 2.3 % of cases had tumor invading the sclera, 7.8% had anterior segment involvement. One patient with tumor extending to the surgical margin of the optic nerve died of metastatic disease²⁴.

Magrann et al observed the following mortality rate for different stages in optic nerve involvement: superficial optic nerve head invasion (10%), lamina cribrosa (29%), optic nerve involvement posterior to the lamina cribrosa but anterior to the resection margin (42%) and involvement at the surgical resection line (78%)⁴³.

Nyawira et al, found that out of a total of 105 patients, most had extraocular involvement (62.1%, 39) where 34 patients (44.2%) died. Six patients had choroid invasion without sclera or ciliary body involvement, out of this 6 patients, 5 died and 1 was alive after 3 years. Missing histology record was found in 20 % of patients and was not indicated the extent of the tumour on histology in 13.3% of patients³.

1.1.9.3 Imaging Studies

The imaging modalities used in assessment of retinoblastoma include ocular ultrasound, MRI or CTscan. Ultrasonography is a useful and cost effective adjunct to indirect ophthalmoscopy in establishing the diagnosis of retinoblastoma and is used to determine tumour extension, growth pattern and associated calcifications^{44, 45}.

In USA, Miami, Roth et al found that the ocular ultrasound detects calcifications in 92–95% of cases^{44, 45} and in Kenya; Kimani et al found that ocular ultrasound has 76% sensitivity in detecting intraocular calcifications of retinoblastoma²².

MRI helps to evaluate an intraocular mass and determine disease extension. MRI has proved to be the most sensitive to delineate the extension of retinoblastoma tumours, especially regarding tumor infiltration of the optic nerve, extraocular extension and CNS involvement (intracranial disease), and can detect if there is an associated haemorrhagic or exudative retinal detachment. At the same time it does not expose the child to radiation and may be

useful in tumour staging. Also it is recommended to help to rule out trilateral retinoblastoma principally in patients with bilateral retinoblastoma and positive family history^{1, 45}.

In USA, Chawla et al noted that MRI has an accuracy of detecting choroidal invasion of 68%, pre-laminar invasion of 84%, post-laminar invasion of 76% and an accuracy of detecting scleral invasion of 98.7 %, with a higher specificity of 80-100% between them⁴⁶.

CT scan is sensitive in revealing intraocular calcifications with sensitivity of 81–96% and an even higher specificity but has a lower sensitivity in detection of optic nerve invasion. It is no longer recommended because it poses a risk of secondary tumours from radiation exposures^{1, 45}. Nyawira et al study found 4 patients who had evidence of intracranial extension on the CT scan³.

1.1.10 Management of retinoblastoma

The success in managing retinoblastoma is attributable to general developments in medicine and the multidisciplinary management approach between the ophthalmologist, pediatric oncologist and pediatric radiation oncologist.

In the management of intraocular as well as extraocular retinoblastoma different classifications have been used to help to decide on the initial method of treatment, assessment of prognosis and outcome of retinoblastoma^{1, 18}:

Reese-Ellsworth classification was the first classification of intraocular retinoblastoma developed by Algernon Reese and Robert Ellsworth, in USA, in the 1960s. It is used to determine the outcome and predicts the ocular prognosis of EBRT by looking at the number, size, location of the original tumours and presence or absence of vitreous seeding. This classification is thought to be a poor predictor of tumour reduction after chemotherapy and does not provide prognosis information for the survival or vision. This modality was shifted to systemic chemotherapy due to the increased risk of secondary tumors following radiation in patients with retinoblastoma and also shifted to emphasize that the failure of lateral portal radiation was due to larger-sized tumours, more anterior located tumours and vitreous seeds tumours^{4, 48}. (Appendix I)

International Intraocular Retinoblastoma Classification (IIRC) replaced later the above classification, because it can predict better an intraocular retinoblastoma response to chemotherapy and focal laser treatment helping to decide who are likely to be cured without

the need for enucleation or EBRT. It analyses the extent of the intraocular disease at the time of diagnosis where the eyes are grouped from group A to E, based on the size of the tumour, presence of subretinal fluid as well as extension of vitreous and subretinal seeding⁴⁹. (Appendix II)

TNM classification is a worldwide recommended standard classification that assesses the whole patient by extent of extraocular disease. It has been developed to standardize clinical findings (cTNM) and pathological assessment (pTNM). Therefore it helps to establish an appropriate plan for patients with retinoblastoma^{4, 18, 50, 51}.

There is also a recently (2006) introduced **International Retinoblastoma Staging System (IRSS)** based on clinical and histopathologic evaluation. This classification encompasses the entire spectrum of the disease with consideration of disease spread, including extraocular retinoblastoma, regional extension and metastatic disease^{4, 52}. (Appendix III)

Considering that treatment modalities of retinoblastoma depend on visual prognosis, laterality, extension of the tumour and the disease stage there are 3 possible modalities of treatment:

1) Focal targeted treatment (local treatment modalities): Enucleation and External beam radiation therapy (EBRT)

Enucleation: Remains the most frequent and definitive treatment for intraocular retinoblastoma, resulting in a cure rate of more than 95% in patients with unilateral disease. It is the choice of treatment for unilateral retinoblastoma (IIRC group B - E), also indicated in children with bilateral disease in the eye with most advance disease that does not respond to chemotherapy and conservative treatment, and in most cases of extraocular orbital disease (stage III) responding to 2-3 cycles of chemotherapy (NACT). The procedure should be done carefully to avoid globe perforation and tumour spread: and a long segment of the optic nerve should be obtained to minimise the chances of leaving tumor at the resection margin^{18,48, 53- 55}.

External Beam Radiotherapy (EBRT): Because retinoblastoma tumours are responsive to radiation, it is used in the treatment of intraocular tumors (very large tumours with vitreous or subretinal seeding that fail to respond to chemotherapy or multiple tumours not amenable for laser or cryotherapy). It is also used in microscopic residual disease stage II (scleral or resection margin involvement), stage III (extraocular disease) or stage IV disease at the site

of metastasis (Appendix III). Current techniques use focused megavoltage radiation treatments with lens-sparing techniques to deliver, the dose is between 42 to 46 Gy (4000 - 4500 cGy in fractionated doses during 4-6 weeks) ^{1, 48, 54}.

Studies done initially by Algernon Reese and radiologists, developed techniques for radiation and identified patterns of regression after using EBRT, having many cures with higher ocular salvage rates. Currently it has been discovered that when using EBRT the preservation of the globe and control of the disease is 58 to 88%. Although adverse effects were noted such as secondary cancers, midface hypoplasia, cataract, vitreous haemorrhage, retinopathy and optic neuropathy making it unsuitable for infants. Currently it has been suggested that combination of the EBRT and chemotherapy allows for increased globe conservation with decreased radiation morbidity ^{1, 48, 56, 58}.

2) Globe saving treatment (Focal treatment modalities) were discovered as conservative strategies. The use depends on the tumour size, tumour retinal location and established treatment goals. Generally they are used primarily in the treatment of intraocular tumors (ICRB group A–D) or used following chemoreduction (2-3 cycles) ⁵⁴ and includes:

Laser photocoagulation: Xenon arc and argon laser (532nm) has been used to treat retinoblastoma mass less than 4.5 mm in basal dimensions and smaller than 2.5 mm in apical height, to achieve an effective therapy 2–3 sessions are required at monthly intervals and it is recommended to do 2 to 3 rows of encircling retinal photocoagulation destroying the tumour's blood supply with ensuing regression. Studies done by Shield et al, found 70% control and 30% recurrence ^{48, 57, 58, 59}.

Hyperthermia: Is a method using a diode laser (810nm) to provide hyperthermia. The direct application to the surface increases the tumour's temperature to the 45° - 60° Celsius range which is below the coagulative threshold. It is used for tumors not larger than 3 mm in basal dimensions located at the posterior pole or mid-periphery without any vitreous seeding. It has a synergistic effect with chemotherapy and may be used in conjunction with chemotherapy for large tumors. Has a direct cytotoxic effect which can be augmented by chemotherapy and radiation ^{1, 48, 54}.

Cryotherapy: Is effective in small equatorial or peripheral tumours with less than 3.5 mm in basal dimension and less than 2 mm in apical thickness, without vitreous seeding or focal vitreous seeding (Group A- C) It is applied under direct visualization with a triple freeze-thaw technique and it is recommended as repetitive treatment if there is continued tumour

growth. It was recommended by Shields et al who found tumors eradication in 79% of cases using only cryotherapy, with additional intervention of episcleral plaque radiotherapy, external beam radiotherapy or enucleation in 21% of the tumors^{4, 60}.

Plaque radiotherapy (Brachytherapy) with Iodine (125) or ruthenium (106): may be used as salvage therapy for eyes in which globe conserving therapies have failed to destroy all viable tumours and in the treatment of some children with small to medium sized tumours (with focal vitreous seeds⁵⁵ but no recurrent vitreous or subretinal seeding⁶¹). A custom designed Iodine 125 plaque radiotherapy is applied transclerally to the apex of the tumor and generally 4000- 4500 cGy fractioned dose is given over a period of 2 to 4 days in tumour less than 16mm base and 8mm thick. Shield et al found a 95% tumour control when Iodine (125) was used as salvage treatment, for selected retinoblastomas that fail on chemoreduction; but the child can develop radiation retinopathy (proliferative retinopathy, non-proliferative maculopathy), optic neuropathy, vitreous hemorrhage, cataract and glaucoma. Using the plaque radiotherapy may lower the incidence of radiation induced second malignancies^{55, 61}.

3) Chemotherapy:

Significant advances have been seen in the last two decades using systemic chemotherapy in the management of retinoblastoma. It may be used in different situations:

- a) As **chemoreduction** specifically in intraocular bilateral retinoblastoma having satisfactory results with a subsequent application of consolidative focal therapy (laser photocoagulation, cryotherapy, laser thermotherapy and plaque radiotherapy). The objective is to reduce the tumor volume in patients with large intraocular tumors (ICRB Group B to D), thereby allowing use of less eye damaging and more-focused therapeutic measures in order to preserve vision and avoid procedures like enucleation or EBRT^{18, 53, 55, 62-67}.

Shield et al showed that chemoreduction alone generally is not adequate to achieve complete tumor seed control, but chemoreduction and focal therapy provides good vitreous seeds and retinal tumor control of intraocular retinoblastoma. In those eyes with seeds before treatment, the addition of focal treatment to the 6 cycles of VEC had decreased the vitreous seed recurrence from 75% to 0% and decreased the subretinal seed recurrence from 67% to 0%⁶⁵.

Also Shields et al, in 7 years follow-up study reported a tumor recurrence in 45% of cases treated with chemotherapy alone compared with only 22% recurrence in combination with focal therapy⁶¹. Wilson et al also found around 92% tumor recurrence rate in those who completed six cycles of chemotherapy without undergoing adjuvant laser treatment or cryotherapy⁶⁷. They recommended a careful follow-up of affected patients because the risk for recurrent vitreous and subretinal seeds is substantial. Gallie et al have noted that retinoblastoma is curable by combining chemotherapy with cyclosporine therapy, laser therapy, and cryotherapy, without requiring external beam⁶⁸.

- b) It also has a role for "pre-enucleation chemotherapeutic induction" to treat largest intraocular retinoblastoma reducing the volume of the tumour for later enucleation. In this case it is used in children with high-risk features such as orbital disease or suspected optic nerve disease⁴. It is also indicated after enucleation if there is optic nerve invasion, choroidal or scleral involvement and in distant metastasis as a palliative treatment^{4, 24}.

Use of chemotherapy may delay the need for EBRT and decreases the incidence of secondary tumours especially for children aged less than 12 months who are at increased risk for developing secondary non-ocular cancers and other complications like orbital and midfacial hypoplasia after EBRT. The visual outcomes after chemoreduction have been shown to be good and comparable to EBRT for patients with bilateral disease with visual potential in one or both eyes⁶². Abramson et al and Kingston et al have shown that almost all tumours respond initially to chemotherapy^{69, 70}.

Chemotherapy protocols include vincristine, carboplatine and etoposide (VEC) for intraocular/ extraocular retinoblastoma, usually given in 6 courses^{4, 65, 66, 71}. Hanovar et al, has a protocol for management of retinoblastoma patient where patients with high histopathology risk factors should do: a baseline systemic evaluation for metastasis, a standard 6 cycle of adjuvant chemotherapy. In patients with scleral infiltration, extraocular extension, and optic nerve extension to transection high dose adjuvant chemotherapy and orbital external beam radiotherapy⁴. Shield et al was evaluating the retinoblastoma tumor control following chemoreduction using 6 courses of VEC and focal therapy for intraocular disease^{65, 66, 71}. On the other hand Cyclosporine has been shown to have a good and long-term response of retinoblastoma to chemotherapy and increased chemosensitivity in patients resistant to a number of cycles of VEC with an overall relapse-free rate of 76%⁷².

Periocular carboplatine has been noticed to have a therapeutic benefit in the treatment of retinoblastoma (ICRB groups C-D), with vitreous seeding and retinal tumors response. But it is associated with serious adverse effects such as orbital myositis, orbital fat necrosis, periocular fibrosis, severe pseudopreseptal cellulitis and ischemic necrosis with atrophy of the optic nerve resulting in blindness. Topotecan in fibrin sealant has also been used subconjunctival to treat retinoblastoma⁵⁴.

The follow up of the retinoblastoma patients should be active follow-up for 5 years after treatment, then a long-term follow-up where the frequency of follow up decreases. Children on salvage therapy should be on closer follow up (3-4 weeks) to treat and monitor the presence of new masses until there are no signs of cancer for 8- 12 month without receiving focal treatment, then if over 3 years age there should be follow up every 3-6 month. Children with non-hereditary retinoblastoma have lower risk of developing retinoblastoma in the other eye, for them the EUA schedule is: 3monthly in <3 years age, 6 monthly between 3-5 years and annually in > 5 year. In enucleated eyes any changes in the socket suggestive of regrowth should be observed^{26, 73, 74}.

Therapy of retinoblastoma is complex and interesting, however; the primary objective in treatment is to save life, the second is to make efforts to save the globe and third to save vision if possible. It is also an opportunity for genetic counselling of the parents, principally the parents with positive family history on the possibility of tumour development in future offspring and the need for their early and regular ophthalmic examinations. Patient counselling usually takes place much later in life as this is a childhood disease.

2.0 STUDY RATIONALE

In Mozambique, no study has been done to document the demographic characteristic, clinical presentation and management of children with retinoblastoma. There is need to create and document a retinoblastoma data and eye care delivery system.

The results from the study will be useful in informing policy makers the status of retinoblastoma care in the country and thus lead to the formation of Management Guidelines for retinoblastoma.

3.0 OBJECTIVES

3.1 Broad Objective

To determine the pattern of presentation, clinical profile and management of retinoblastoma patients at "Maputo Central Hospital" during a period of five years

3.2 Specific Objectives

To identify the demographic characteristic of retinoblastoma patients seen at "Maputo Central Hospital" in Mozambique during a period of five years

To identify the clinical presentation of the retinoblastoma patients

To describe the method of diagnosis of retinoblastoma patients

To describe the modalities of management of retinoblastoma patients

4.0 METHODOLOGY

4.1 STUDY DESIGN

A descriptive retrospective case series of retinoblastoma patients, who presented at MCH, Mozambique, during a 5 years period (1st January 2010 to 31st December 2014)

4.2 STUDY AREA

The study was done at Maputo Central Hospital at Maputo City, in Mozambique.

Mozambique is a country in Southeast Africa bordered by: Indian Ocean (East), Tanzania (North), Malawi and Zambia (Northwest), Zimbabwe (West), Swaziland and South Africa (Southwest). The total population is 21,397,000 and an area of 801,590 km². The Capital is Maputo with a population of 1,766,184 and an area of 346 km² and the primary official language is Portuguese.

Administratively Mozambique is divided into 3 regions (Northern, Central, Southern) with 11 administrative provinces. In each region there is a referral hospital, Maputo Central Hospital (Southern), Beira Central Hospital (Central) Nampula Central Hospital (Northern).

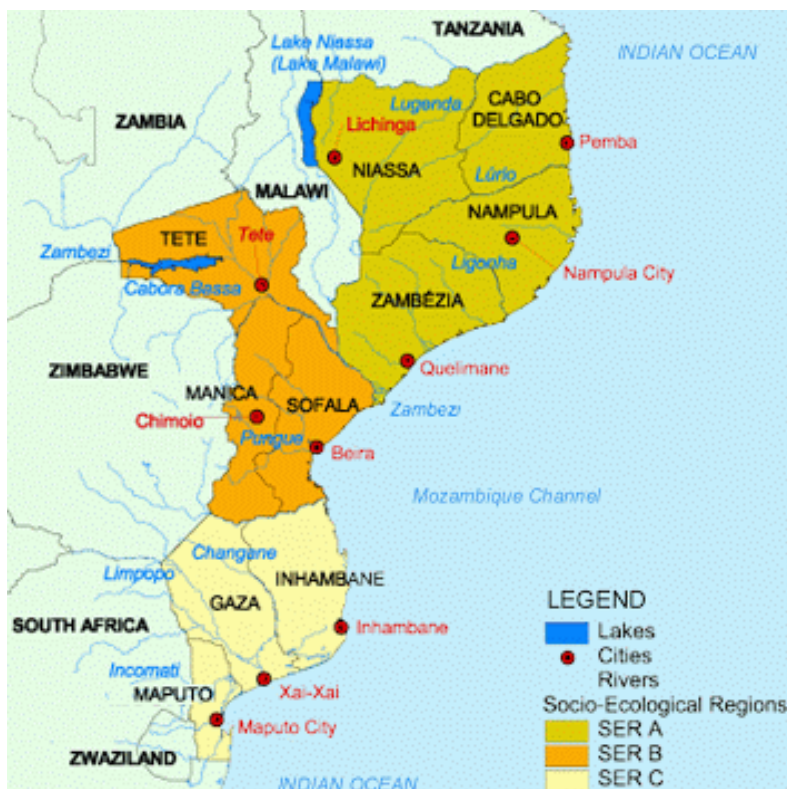

Figure 1: Map of Mozambique, showing location of Maputo City

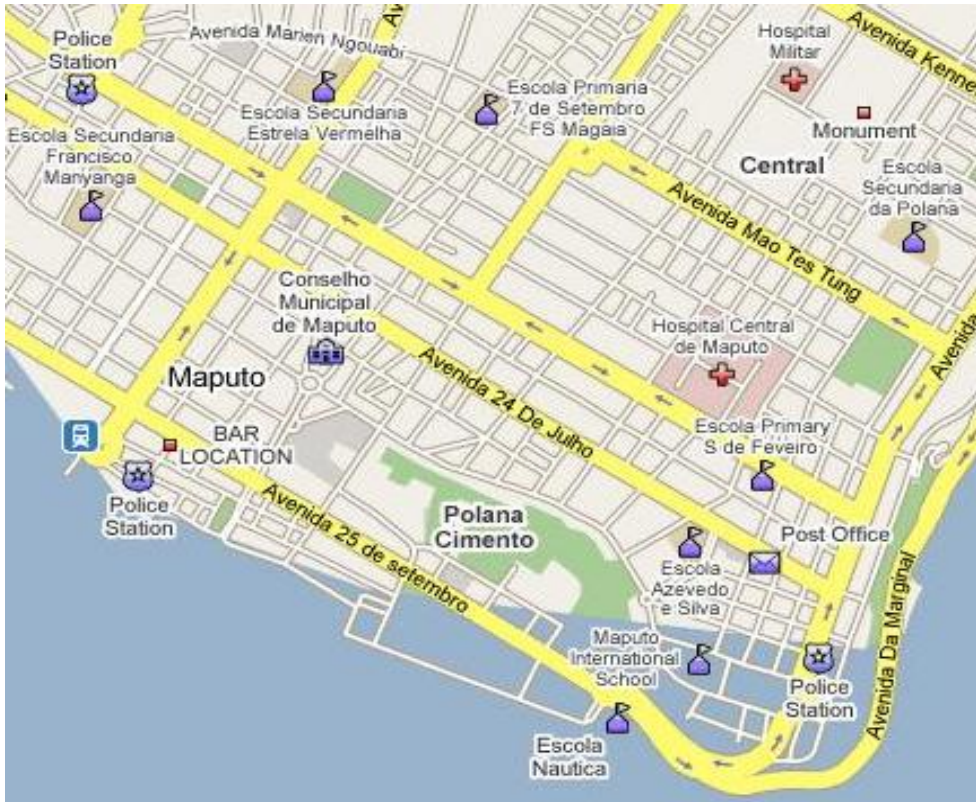

Figure 2 Map of an area of Maputo City, showing Maputo central hospital.

4.3 STUDY SETTING

The health care system in Mozambique comprises of District Health Centres offering primary health care, a Provincial Hospitals for secondary health care and Central Hospitals for tertiary services. Maputo Central Hospital (MCH) is the biggest government referral hospital which is also a teaching hospital in Mozambique with approximately 8 Mozambican ophthalmologists and 1 foreign ophthalmologist. Health services in Mozambique are offered free in government health facilities.

4.4 ETHICAL CONSIDERATIONS

Ethical approval was given by Kenyatta National Hospital/University of Nairobi Ethics and Research Committee. Approval was also given by the director of Ophthalmology department and the Maputo Central Hospital Scientific /Ethics and Research Committee before the commencement of the study (Annex)

A code and patients IP number was used for purposes of confidentiality and to match their histopathology results as obtained from the Pathology department.

Data collected in the structured questionnaire was stored safely and confidentially in the database on a laptop computer and was only available to the principal researcher and the statistician. Confidentiality of the medical records was maintained throughout the study.

Steps were taken to secure all electronic data collected through the use of strong passwords and firewalls to prevent unauthorised access.

The benefit of this study is directed at improving the diagnosis and management of patients with retinoblastoma and to improve the screening and follow ups of those genetically predisposed to the condition. Therefore the results of the study will be shared with the health management teams in the referring District/Provincial/ Central Hospitals and the directorate of clinical services at the ministry of health

4.5 STUDY POPULATION: SOURCE POPULATION

The study included all patients with the clinical, histological or both clinical and histological diagnosis of Retinoblastoma in Maputo Central Hospital between: 1st January 2010 to 31st December 2014.

4.6 INCLUSION CRITERIA

All recorded presumptive clinical diagnosis of retinoblastoma with or without confirmed histological diagnosis of retinoblastoma seen at MCH during the study period.

Patients with histological diagnosis of retinoblastoma were included, even if the initial clinical diagnosis was different.

Patients with incomplete records on the file were analyzed up to the level reached. The rest of information needed was recorded as missing/undocumented.

4.7 DATA COLLECTION PROCEDURE

This study was carried out primarily by identifying relevant records of patients with the help of the patient IP number from Ophthalmology Services, Paediatric Oncology ward, theatres and histology department (Using the attendance, admission, discharge /death and surgery registration books).

The diagnoses of interest were: Retinoblastoma, Globe tumour and orbital tumour and other clinical presentation of the disease like endophthalmitis, orbital cellulites and globe phthisis.

The identification details (IP numbers) were used to retrieve the relevant files from the records department with the help of a records clerk.

Once the files were retrieved and accessed chronologically (from the oldest to the most recent) the necessary information was extracted and filled in a designed structured questionnaire printed previously (Appendix IV). Each identified patient file had its own copy of the questionnaire.

Information sought was demographic characteristics, clinical presentation, investigations (done), patient management, discharge and death records.

In cases where the histopathology reports of the retinoblastoma patients were not available in the files help was sought from the Histopathology department at MCH to reconcile histology specimens on record with the identified patients.

4.8 REQUIRED TOOLS

Questionnaire, Hard Copy Patient Records (including admission notes, surgical/theatre notes, discharge and death registers), Laptop Computer and Flash Disc were used during the study period.

4.9 DATA MANAGEMENT

Data collected via the questionnaire was transferred into a computer based SQL database (MySQL version 5.5) then managed via its form interface. This was achieved through manual data entry and validation of each questionnaire.

4.10 DATA STORAGE

Data was stored on the database on a laptop computer with a compressed and encrypted backup stored separately on a removable flash disc.

4.11 DATA ANALYSIS

Data collected was analysed using the Statistical Package for Social Scientists (SPSS) version 21.0.

Analysis for all variables was conducted in the comprehensive analysis functionality of SPSS with frequency tables being populated for all variables to gain better insight into the results of data collection.

Correlation matrices were created for all variables against each other in order to determine any significant *p* values. Descriptive statistics such as mean and median, standard deviation was calculated for each variable and any relationships that emerged were assessed. Tables, charts and graphs of significant findings were constructed and used to present the results.

The variables assessed and assigned as unique identifier were:

Age at time of first presentation

Age at diagnosis

Sex

Area of Origin (rural or urban)

Length of time (months) between first presentation and referral to MCH

Family history of Retinoblastoma

Symptoms

Signs (Physical Examination)

Fundoscopy done

Examination under anesthesia done

Frequency of EUA

Number of investigations/tests done

Management done

Chemotherapy received

Number of doses of chemotherapy

Number of drugs in regimen

Delay of treatment

Outcome details (Dead, disease free, regrowth)

Age at death

Cause of death

Follow up visits conducted

Frequency of Follow up Visits

4.12 STUDY DURATION

The study was carried from November 2013 to April 2016 (Appendix IV).

5.0 RESULTS

We searched hospital records for patients with a diagnosis of retinoblastoma, globe tumour and orbital tumour.

Figure 3: Flowchart

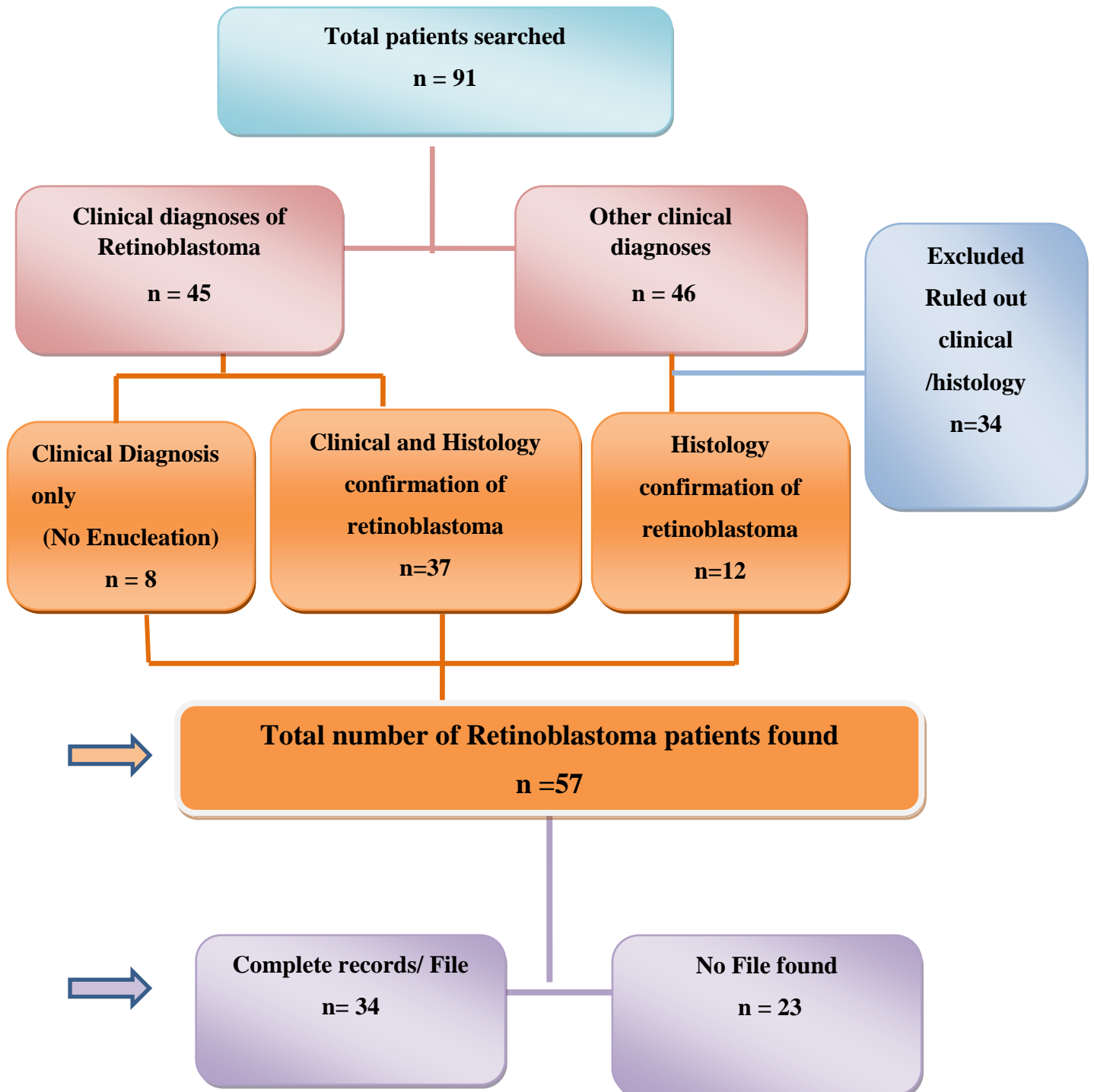


Table 2: Distribution of retinoblastoma patients by Province of residence (n = 57)

Province	Cases	Percent %
Maputo	26	45.6
Gaza	13	22.8
Inhambane	8	14.0
Tete	4	7.0
Zambézia	3	5.3
Niassa	2	3.5
Cabo Delgado	1	1.8
Total	57	100.0

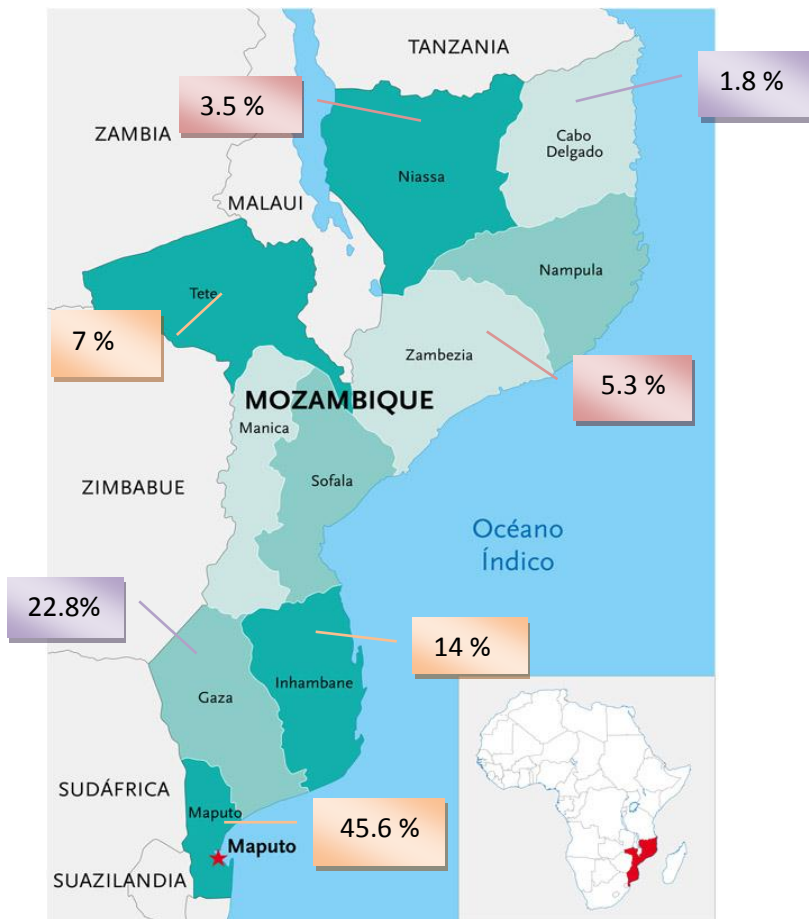


Figure 4: Distribution of retinoblastoma patients found by Province of residence

The cases found reside in 7 different provinces of Mozambique (Out of 11 provinces), 45.6% of the cases were from Maputo.

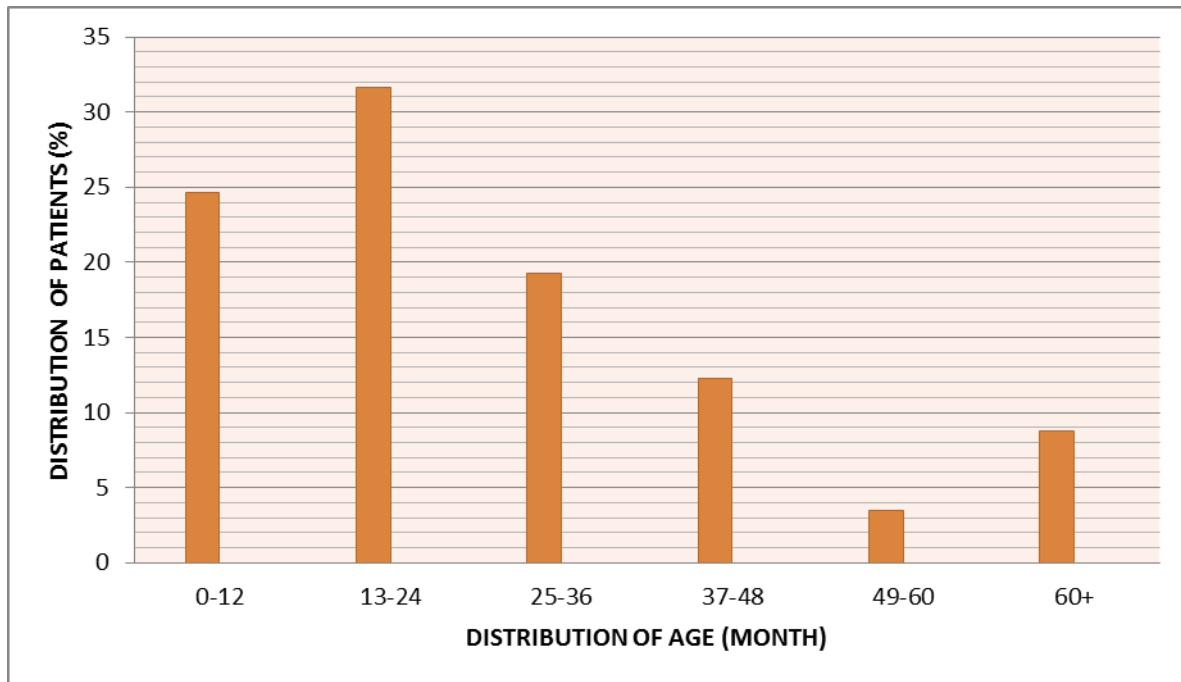
Table 3: Distribution based on Initial Diagnosis (n=57)

Diagnosis	Frequency n=57 (%)	Histology confirmation	No histology confirmation (No surgery)
Retinoblastoma	42 (73.7)	35	7
Globe Tumor	12 (21.1)	11	1
Orbit Tumor	1 (1.8)	1	
Panophthalmitis	2 (3.5)	2	
Total	57 (100.0)	49 (86%)	8 (14%)

In this study 42 patients (73.7 %) had initial clinical diagnosis of retinoblastoma and out of them 35 patients had histological confirmation of retinoblastoma.

Some of the patients had associated differential diagnoses of Endophthalmitis (3), rhabdomyosarcoma (2), lymphoma (1). Some patients had other co-morbidities like severe Anemia (3), HIV (3), Kaposi's sarcoma (1), Malaria (1), and Chickenpox (1)

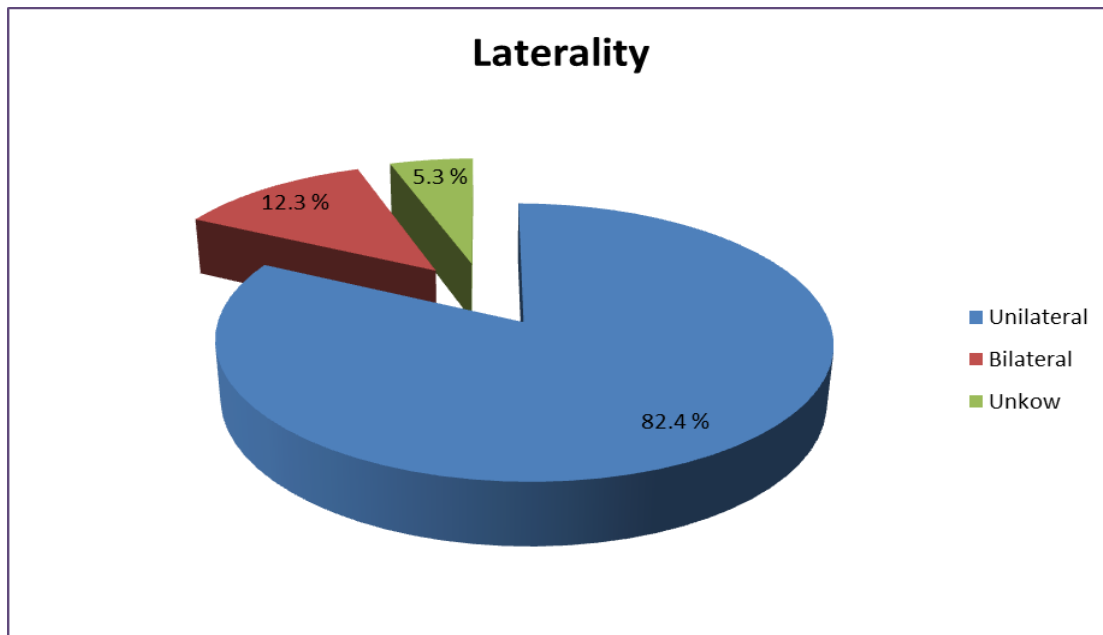
Figure 5: Distribution of cases by age of presentation (n= 57)



Most of the patients presented between the ages of 13 to 24 months (31.6%)

The mean age of presentation was: **30.5 months (CI 24.65 - 36.05), (SD 21.5), median 24.00, range 1-96 months.**

Figure 6 : Laterality (n= 57)



Majority of patients (82.4%) had unilateral retinoblastoma

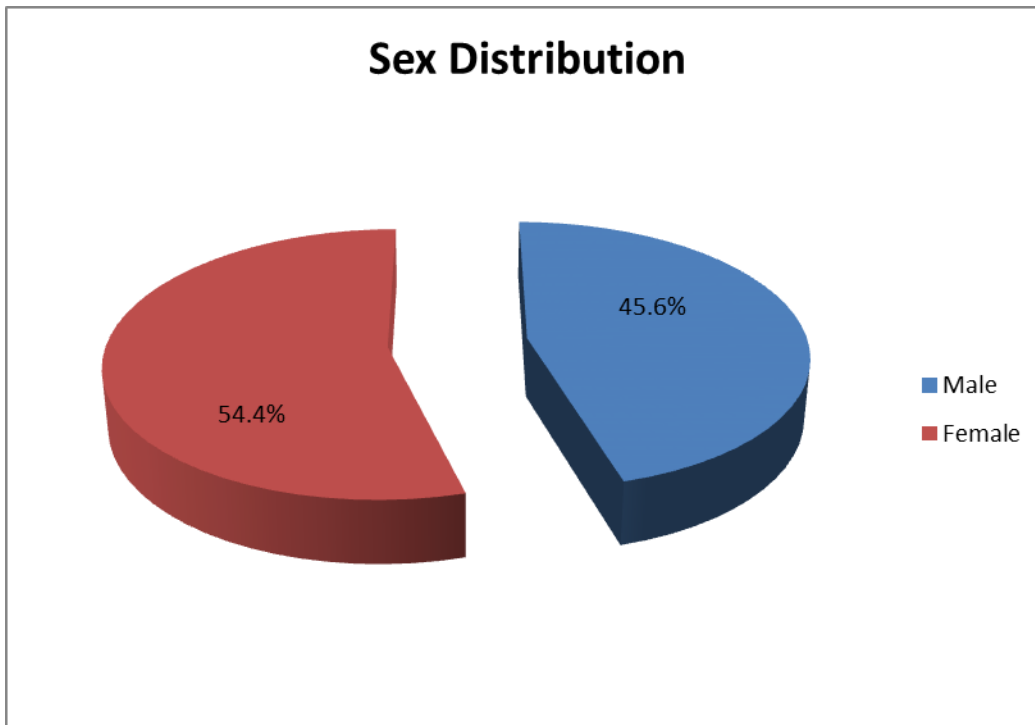
Table 4: Distribution by age at presentation vs. laterality (n= 57)

Age (Month)	Bilateral	Unilateral	Unknown laterality
0-12	3	11	0
13-24	2	15	1
25-36	0	11	0
37-48	1	5	1
49-60	0	2	0
>60	1	3	1
Total	7 (12.3%)	47 (82.4%)	3 (5.3%)

The mean age at presentation in bilateral cases was 26.4 month (SD 24.8), **median: 18.0** while for unilateral cases it was 30.2 months (SD 20.9), **median: 24.0**

There was no statistical significant difference between them (p -value of 0.599)

Figure 7: Sex Distribution of Cases (n=57)



The female: male ratio was 1.2:1

There was no statistical significant difference between the females and males with a p –value of 0.570

Table 5: Family history (n=34)

Family History	Frequency n= 34	Percent %
Undocumented	32	94.1
Yes	1	2.9
No	1	2.9
Total	34	100.0

Table 6: Duration from symptoms to diagnosis at MCH (n= 34)

Duration(Month)	Maputo	Other provinces	Frequency (Percent %)
< 1	2	4	6 (17.6)
1-2	2	0	2 (5.9)
3-4	8 (23.5)	5 (14.7)	13 (38.2)
5-6	3	1	4 (11.8)
7-8	0	1	1 (2.9)
9-12	0	2	2 (5.9)
>12	1	5	6 (17.6)
Total (Percent)	16 (47.0)	18 (52.9)	34 (100.0)

Most of the patients (38.2 %) presented at 3 to 4 months from the initial symptoms to the diagnosis at MCH. The mean delay time was 6.9 months.

There was no statistically significant difference in the presentation between patients coming from different provinces and those from Maputo (P- value: 0.127)

Table 7 : Duration from diagnosis to primary management (n =34)

Out of the 34 files analyzed, 6 patients (17.6 %) did not undergo any treatment because the parents declined treatment.

Duration (Days)	Frequency n= 28	Percent %
< 7 Days	4	14.3
7-14 Days	11	39.3
15- 23 Days	6	21.4
24- 31 Days	3	10.7
>31 Days	4	14.3
Total	28	100.0

Many of the patients admitted (11, 39.3%) started treatment on the second week from initial diagnosis. The mean time delay was 19 days.

Table 8: Duration from symptoms to initial management (n=34)

Duration (Month)	Frequency n= 28	Percent %
< 3 month	4	14.3
3-6 month	14	50.0
7 -10 month	2	7.1
11 -14 month	2	7.1
15 - 18 month	1	3.6
19-24 month	5	17.9
Total	28	100.0

Most of the patients (50%) started treatment between 3 to 6 month from the initial symptoms. Total mean time of delay from symptoms to treatment was 8 months and 7 days

Table 9: Presenting complaint:

Out of 34 patients with complete records, a total of 40 eyes were affected (28 unilateral + 6 bilateral)

Symptoms	Eyes affected n=40	Percent %
White Reflex	25	62.5
Eye Swelling	19	47.5
Eye Redness	16	40.0
Poor Vision	13	32.5
Tearing	5	12.5

Table 10: Clinical signs of retinoblastoma:

Out of 34 patients with complete records, a total of 40 eyes were affected (28 unilateral + 6 bilateral)

Signs	Affected eyes n=40	Percent %
Leukocoria	22	55.0
Proptosis	20	50.0
Eye Redness	11	27.5
Orbital Cellulites	2	5.0
Strabismus	1	2.5
Pseudohypopyon	1	2.5
Buphthalmos	1	2.5

Other signs documented: Corneal opacity, mydriasis, shallow anterior chamber, fungating mass , phthysical eye

Three patients (8.8%) had recurrences of the disease

Table 11: Patients who had EUA and ocular ultrasound (n = 34)

Findings	EUA Other eye Frequency n= 34 (%)	Ocular ultrasound Frequency (%)
Undocumented	33 (97.1)	29 (85.3)
Yes	1 (2.9)	5 (14.7)
Total	34 (100.0)	34 (100.0)

Only 1 patient had EUA records of the fellow eye, having normal findings.

Only 5 patients (14.7%) had ocular ultrasound done, the rest (85.3%) did not have documentation of the ocular ultrasound findings.

Table 11.1: Ocular ultrasound findings (n=5)

Ocular ultrasound findings	Frequency n= 5 patients	
	Bilateral	Unilateral
Intraocular mass	2	3

Out of the 3 patients who had unilateral retinoblastoma, findings of the other eye were not recorded.

Table 12: Other investigation (CTscan /MRI) n=34

Investigation	Frequency n= 34	
	CT-scan (%)	MRI (%)
No	31 (91.2)	20 (58.8)
Requested (Awaiting to be done)	3 (8.8)	9 (26.5)
Yes	0	5 (14.7)
Total	34 (100.0)	34 (100.0)

Table 12.1 MRI findings (n=5)

MRI findings	Frequency n = 5	Histology
Intraocular Mass	5	
Extraocular Mass	4	ON involvement (3) No Surgery- Parents declined (1)
Intracranial Extension	1	RM involvement (1)
Pineal Gland Involvement	0	

Only 5 patients had MRI done where 4 patients had extraocular mass extension (3 had optic nerve invasion by histology and 1 did not have surgery done because parents declined)

Intracranial extension was found in 1 patient (This was a 4 year old child that underwent enucleation and tumor was found at the resection margin)

Table 13: Patients who had surgery (n = 57)

Surgery	Frequency n=57 (Percent %)	Eyes
Yes	49 (86)	51
No*	8 (14)	0
Total	57 (100)	51

Out of the 49 patients, 47 patients had one enucleated and 2 patients had bilateral enucleation. Therefore a total of 51 eyes had surgical intervention.

* The reasons for no surgery in the 8 patients were:

- Parents declined surgery and requested to be discharged (5)
- Not available files (but from the registration book noted patients had advance disease) (2)
- Sick with Anemia (1)

Table 13.1: Interventions (n= 49)

Procedures	Frequency n= 49	Percent %
Enucleation	45	93.9
Exenteration	9	18.0
Chemotherapy	12	24.5
Laser Photocoagulation	0	0
Cryotherapy	0	0
Radiotherapy	0	0

Three patients who had enucleation also underwent exenteration due to tumor recurrence.

Out of the 12 patients who received chemotherapy: 7 patients had enucleation and 4 had exenteration done.

Table 14: Histology report

From a total of 49 patients who had surgery, 47 patients had one eye enucleated and 2 patients had bilateral enucleation (n=51 eyes)

HISTOLOGY	Frequency n= 51 Eyes	Percent %
a) Differentiation		
Differentiated	31	60.8
Undifferentiated	19	37.2
Histology not available	1	2.0
b) Growth		
Diffuse	32	62.7
Endophytic	17	33.3
Exophytic	1	2.0
Histology not available	1	2.0
c) Length of Globe Reported		
Yes	44	86.3
Difficult to measure	6	11.7
Histology not available	1	2.0
d) Length of optic nerve (mm)		
Unreported	46	90.2
Reported	4	7.8
Histology not available	1	2.0

Table 14.1: Histology report based on the invasion and extension of ocular and periocular structures

HISTOLOGY: SPREAD	Frequency n=51 eyes	Percent %
a) Choroidal Involvement		
Undocumented	49	96.0
Yes	1	2.0
Histology not available	1	2.0
b) Scleral Involvement		
Undocumented	50	98.0
Histology not available	1	2.0
c) Periocular Tissues Infiltration		
Undocumented	26	51.0
Yes	17	33.3
No	7	13.7
Histology not available	1	2.0
d) Optic Nerve Involvement		
Involved	28	54.9
Not Involved	11	21.6
Undocumented	6	11.7
Difficult to recognize ON (Not identifiable)	5	9.8
Histology not available	1	2.0
e) Resection Margin Involvement		
Undocumented	20	39.2
Involved	17	33.3
Not Involved	13	25.5
Histology not available	1	2.0

Optic nerve involvement was documented in 28 eyes (54.9%) of which 17 eyes (33.3%) show involvement of the resection margin.

In 5 eyes (9.8%) it was difficult to recognize the optic nerve with no documentation of the resection margin. In 11 eyes (21.6%) the optic nerve was not involved.

Table 15: Number of patients who received chemotherapy (n=34)

Chemotherapy given?	Frequency n=34	Percent %
Yes	12	35.3
No	22	64.7
Total	34	100.0

Out the total of 57 patients found only 34 patients had the file to analyze the proportion of patients who received chemotherapy, among them only 35.3% of patients received.

Table 15.1: Eligible patients for chemotherapy (n= 34)

Eligible	Clinical / Histological criteria for Chemotherapy *	Received Chemotherapy		
		Frequency n=34		
		Yes (%) n=12	NO (%) n=22	Total (%)
Yes	Clinical criteria (Proptosis)	1	3	4
	Histological Criteria(ON involvement, periocular tissues)	3	2	5
	Clinical and Histological criteria	8	6	14
	Total Patients Eligible (%)	12 (35.3)	11(32.4)	23 (67.7)
Unknown**				8 (23.5)
No Eligible				3 (8.8)

*Eligibility criteria for chemotherapy: Treatment of intraocular bilateral retinoblastoma (for globe salvage)^{55,60-67} extraocular extension (orbital disease -Proptosis) and the histopathologic high-risk factors (Massive choroidal involvement, scleral or extrascleral involvement and optic nerve involvement beyond the lamina cribrosa with or without involvement of the resection margin)^{4, 23, 24}

Out of the 34 patients with available file noted that 23(67.7%) were eligible for chemotherapy based on clinical and histological criteria. No patient was in globe salvage therapy.

** Unknown eligibility for chemotherapy in 8 patients (23.5%)

- Six patients did not have any surgery done because: In 5 patients the parents declined surgery and 1 patient was sick
- The optic nerve was no documented in 2 patients

Table 15.2: Reasons of no chemotherapy in the 22 patients with available file

Reasons of no chemotherapy	Frequency n = 22	Eligibility for Chemotherapy
Unknown reasons	6	Eligible (11)
Died	2	
Awaiting results	2	
Was to start	1	
No surgery	6	Unknown ** (8)
ON undocumented	2	
Optic nerve no involvement	3	No Eligible (3)
Total	22	

Table 15.4: Chemotherapy regimen (n=12)

Regimen (Drugs)	Frequency n=12
Vincristine, Etoposide, Carboplatine (VEC)	8
Vincristine, Etoposide, Carboplatine (VEC), Cisplatin (added)	2
Vincristine, Adriamycin, Cyclophosphamide (VAC)	1
Vincristine, Adriamycin, Cyclophosphamide (VAC) Actinomycin(added)	1
Total	12

The patients that had cisplatin (2) added in the previous regimen underwent exenteration and histology showed resection margin involvement.

Table 15.5: Number of courses of chemotherapy given (n=12)

Courses of chemotherapy	Frequency n=12	Percent %
< 4 courses	5	41.7
4-6 courses	3	25.0
>6 courses	4	33.3
Total	12	100.0

From the 12 patients who started chemotherapy, 5 patients (41.6%) did not complete 4 courses.

Table 16: Number of patient on follow up (n=57)

Follow up	Frequency n=57	Percent %
Unknown	41	71.9
Yes	14	24.6
No	2 (Died)	3.5
Total	57	100.0

Only 24.6% of patients were on follow up, were all the patients who started chemotherapy were initially on follow up but many of them did not complete 4 courses because they were lost to follow up.

We identified 2 patients who died: One had resection margin involvement (associated with abdominal mass, severe anemia with blood dyscrasia), while in the other patient the optic nerve was difficult to identify on histology but an MRI confirmed involvement of the optic nerve.

6.0 DISCUSSION

6.1 OVERVIEW AND DEMOGRAPHIC CHARACTERISTICS

After searching for all the patient records with an initial diagnosis of retinoblastoma, globe tumor, orbit tumor, endophthalmitis or orbital cellulitis over the study period, a total of 91 patient records were identified. Out of these, a total of 45 patients had an initial clinical diagnosis of retinoblastoma while 46 patients had any of the other diagnoses. Out of the 46 patients with other diagnosis, 12 were confirmed to be retinoblastoma patients by histology. This made a total of 57 patients with a diagnosis of retinoblastoma either clinically or by histology or by both histological and clinical diagnosis. Out of the 57 patients, 8 patients did not have a histology report and the diagnosis of retinoblastoma was therefore only clinical.

Out of the total of the 57 retinoblastoma patients, it was only possible to retrieve 34 files from the hospital records. These were the only records that received a complete analysis in the study. The remaining 24 patients received a partial analysis mainly on the information that could be extracted from the registration book and the histopathology records.

The cases found resided in 7 different provinces of Mozambique (Out of a total of 11 provinces). No cases were found in Beira and Nampula most likely because there are referrals Central Hospitals with ophthalmologists in the regions. Majority of the patients (54.4 %) were referred from other provinces (Gaza, Inhambane, Zambezia, Tete, Niassa and Cabo Delgado) to MCH, probably due to unavailability of tertiary care like chemotherapy in these regions.

6.2 AGE AT PRESENTATION, RISK FACTORS AND PROGNOSIS

In developed countries most studies have showed that retinoblastoma patients present at a very young age with an overall median age at diagnosis of 18 months, the mean age at diagnosis in bilateral cases is usually less than 12 months while in unilateral cases the average is less than 24 months¹. Broaddus et al, In USA, similar to Seregard et al in UK found a peak age at presentation for both bilateral and unilateral retinoblastoma of less than 1 year of age with incidence decreasing steeply after 1 year^{10, 11}.

In developing countries studies have shown a different scenario where patients presented at older ages than in developed countries. In Kenya, Nyawira et al, found an overall mean age at presentation of retinoblastoma patients of 35 months (SD 25); the mean age for bilateral

retinoblastoma was 24.4 months and for unilateral retinoblastoma 39.9 months ($p < 0.001$)³ Nyamori et al found a mean age at presentation of 33.46 months (SD 20.8) with a mean age at presentation of 26 months for bilateral cases and 35.9 months for unilateral cases ($p = 0.017$)¹⁴. In Malawi, Nyaka et al found a mean age at presentation of 34.5 month with a mean age of 19.9 month for bilateral cases and 37.2 month for unilateral cases ($p = 0.008$, being statistically significant)²⁸.

In Mozambique, this study has showed an overall mean age at presentation of 30.5 months (CI 24.6 - 36.0) with a standard deviation of 21.5 months and a median of 24 months. The mean age at presentation in bilateral cases was 26.4 months (SD 24.8), median: 18.0 while in unilateral cases it was 30.2 months (SD 20.9), median: 24.0. The difference on the mean age at presentation at MCH between bilateral and unilateral retinoblastoma was however not that obvious in our study (with a p-value of 0.599, no statistical significant difference) probably due to the delayed presentation with an average delay from onset of symptoms to presentation of 6.9 months.

We noted that bilateral cases presented younger than unilateral cases, although both groups presented at older ages compare with developed countries. The older age at presentation found in this study is in keeping with other African studies which had also showed an older age at presentation (for bilateral and unilateral cases)^{3, 14, 21} and this relatively older age at presentation in African series has been attributed to very late presentation and the African patients may seek alternative means of healing before coming to hospital^{3, 34}.

In Kenya, KNH, Nyawira et al, found that the main reasons for poor prognosis and low survival in retinoblastoma patients were: older age at presentation, late presentation with advanced disease and delay from diagnosis to management³. Other factors for poor prognosis found included proptosis, tumor recurrences, extraocular disease on histology and metastatic disease; lack of disease awareness among the population and healthcare professionals, difficulty accessing healthcare, fear of enucleation, lack of resources in the health facilities (lack of well-established tertiary care centers) and high costs of hospital care are correlated factors^{3, 18-21}.

It is known that the tumour is seldom seen after 3 years of age because the primitive retinal cells generally disappear within the first years of life,²⁶ therefore the incidence of retinoblastoma decreases with age after around 5 years of life. In this study we found that 8.8

% of patients were above 5 years. This was higher than what was found in Kenya by Nyamori et al (8.3 %) ¹⁴ and very high than what was found in developed countries where only 4.3% new cases of retinoblastoma were seen between the ages of 5-9 years in USA ¹⁰ and 5% new cases above the age of 4 years in UK¹¹.

6.3 LATERALITY

Based on the laterality, in this study most of the patients had unilateral retinoblastoma (47, 82.4%) while only 7 patients (12.3%) had bilateral retinoblastoma. We did not find any patient with trilateral retinoblastoma. Few patients were found to have bilateral retinoblastoma probably due to poor screening of fellow eyes and this may have missed some bilateral retinoblastoma, only 1 patient was noted to have the EUA done on the fellow eye as part of the patients work-up.

The findings for bilateral retinoblastoma is less than what is generally found in different studies over the world where bilateral cases usually occur in 30-40% and unilateral cases in 60% -70% of cases¹. Another study that also found less proportion of patients with bilateral retinoblastoma was by Nyaka et al done in Malawi. In this study bilateral retinoblastoma was found in 17.6% of patients and unilateral retinoblastoma in 82.4 % ²⁸. In Kenya the studies done had figures almost closer to what is generally found in developed countries, where Nyamori et al found that most cases had unilateral retinoblastoma (74.2 %) and bilateral retinoblastoma was found in 25.8 % ¹⁴, also Nyawira et al found unilateral retinoblastoma in 72% of cases and bilateral retinoblastoma in 28% of cases³.

6.4 SEX DISTRIBUTION AND FAMILY HISTORY

The sex was almost equally represented among the patients with an F: M ratio of 1.2:1 with no statistical significant difference between females and males (p- value of 0.570). Overall, many studies in developed and developing countries show that there is no difference in the distribution between males and females^{2, 10}.

In Nigeria, Owoeye et al, found a mild female predominance of 1.2:1¹² and Akang et al, reported a female predominance of 3:2³⁰ while in Kenya, Nyawira et al, found an M: F ratio of 1.16:1 ³ and Nyamori et al found an M: F ratio of 1.5:1 for confirmed cases ¹⁴. In Malawi, Nyaka et al reported a presenting M: F ratio of 1.3:1 ²⁸.

Generally family history is present in only 5% of retinoblastoma patients¹. In our study the family history was not recorded in majority of the patients (94.1 %) attributed to a poor recording of family history data. We only noted a positive family history in 1 patient (2.9 %). Nyaka et al also found only 1 patient with positive family history²⁸. Nyamori et al, found a family history to be present in only 4.5% of cases¹⁴ while Nyawira et al and Makite et al found in slightly more cases (8.5%) and (6.3%) respectively^{3, 34}.

6.5 DELAY

Most of the patients (38.2 %) presented at 3 to 4 months from the initial symptoms to the diagnosis at MCH. The overall mean delay in presentation was 6.9 months; however this was less than what Nyawira et al found in Kenya with a mean delay time of 10.5 month.

Comparing the delay from onset of symptoms to diagnosis at MCH between patients from Maputo and those from other provinces (Gaza, Inhambane, Zambezia, Tete, Niassa and Cabo delgado) there was no statistically significant difference on the time of presentation between patients coming from different provinces and the ones coming from Maputo (P- value: 0.127)

In this study, it was not possible to determine the time from onset of symptoms to diagnosis at 1st facility in patients who came from different provinces due to lack of this information on the files. Makite et al had a mean interval between onset of symptoms and 1st visit to a health facility of 4.7 month with more than 50% of patients presenting late from the onset of symptoms to the presentation at the first facility. She also found that most health care providers took a short time to refer to the facility of definitive management³⁴.

Analyzing the delay from diagnosis to treatment at MCH, it was noted that many of the patients admitted at MCH started treatment on the second week (11 patients, 39.3 %) with mean time delay of 19 days. Makite et al also found that majority of patients started treatment on the first and second weeks after admission: 1st week (40.6 %) and 2nd week (48.4 %) with a mean time of 3.4 weeks (Median 1 week)³⁴ and Nyawira et al had a mean time of 1 month (median 7 days)³ On the analysis of the delay from the onset of symptoms to management at MCH, we noted that 50% of the patients initiated treatment within the period of 3-6 month, but the mean delay time was 8 month and 7 days. The reasons for the delay in treatment at the hospital could be due to the time taken to stabilize the patients with co-morbidities like anemia, respiratory infection and also the long time taken to book for MRI / CT-scan. The mean delay time between onset of symptoms and management in our study was lower than

what was found by Nyawira et al (Total delay of 12 months with a median of 8 month, this was found to influence the 3 years outcome) ³.

6.6 CLINICAL FEATURES OF RETINOBLASTOMA

There was an overlap of symptoms because patients presented with more than one complaint and the main presenting complaint was white reflex (62.5%) followed by eye swelling (50 %), eye redness (40 %) and poor vision (32.5%)

Almost similar common symptoms were found by Nyawira et al where white reflex was the most common complaint in 71% of cases, followed by eye swelling (37%), poor vision (9.5%) redness (7.6%) and squint (5%) ³ while Nyamori et al also found white reflex as the commonest symptom (91.7%) followed by redness/ eye pain (28.8%), proptosis (18.2%), poor vision (10.6%) and squint (9.8%) ¹⁴. Nyaka et al also found white reflex as the most common presenting complaint (66.2 %) followed by proptosis (44.1%) and poor vision (36.8%) ²⁸.

The main clinical signs found were leukocoria (55 %) followed by proptosis(50 %) and eye redness (27.5%). Three patients (8.8%) were found to have recurrent orbital disease documented.

In Kenya, Nyawira et al found leukocoria in 46% of patients followed by ocular inflammation in 30%, recurrent mass in the socket in 27% of patients and proptosis in 20% of cases³.Nyamori et al found leukocoria in 71.1% followed by squint (25.9%), proptosis (21.1%), redness (17.5%) and hyphaema (12.7%) ¹⁴ In Malawi, Nyaka et al, found leukocoria (66.2%) followed by proptosis (30.9%) and orbital cellulitis (13.2%)²⁸.

In this study, patients presenting with proptosis (50%) were more than what was reported in other studies in the region, example: Nyaka et al (30.9%) ²⁸, Nyamori et al (21.1%) ¹⁴ and Nyawira et al (20%) ³. The main factors found to be associated with proptosis at presentation in the study were: Old age at presentation, patients been coming from other provinces, time delay from initial symptoms to diagnosis.

6.7 DIAGNOSIS OF RETINOBLASTOMA

We found only one recorded EUA for the second eye with the rest missing (97.1%). This could suggest that EUAs for second eye was not routinely done and could have missed some bilateral retinoblastoma, explaining the small percentage of bilateral retinoblastoma we found. There was no patient on salvage therapy for the other eye, could be because they were never picked early by routine EUAs.

The EUA should be done for early diagnosis of retinoblastoma (usually in patients with positive family history of retinoblastoma, in globe salvage or in the second eye of all patients undergoing enucleation for retinoblastoma. The follow up of the retinoblastoma patients should be active follow-up for 5 years after treatment, then a long-term follow-up where the frequency of follow up decreases. Children on salvage therapy should be on closer follow up (3-4 weeks) to treat and monitor the presence of new masses until there are no signs of cancer for 8- 12 month without receiving focal treatment, then if over 3 years age should be follow up every 3-6 month. Children with non-hereditary retinoblastoma have lower risk of developing retinoblastoma in the other eye, for them the EUA schedule is: 3monthly in <3years age, 6 monthly between 3-5years and annually in > 5 year. In enucleated eyes any changes in the socket suggestive of regrowth should be observed^{23, 73, 74}.

6.7.1 Imaging studies

Ultrasonography is a cost effective diagnostic modality in retinoblastoma and is used to determine the growth pattern, ocular calcifications and tumour extension^{44, 45}. In the study many patients (85.3%) did not have documentation of whether ocular ultrasound was done or not, only few patients (14.7%) had ocular ultrasound done with findings suggestive of retinoblastoma. Studies done by Roth et al, in USA, found that ocular ultrasound has 92- 95% of sensitivity in detecting intraocular calcifications of retinoblastomas⁴⁴, also noted by Kimani et al, in Kenya with a sensitivity of 76%²².

The main role of either MRI or CTscan in retinoblastoma is to detect orbital or intracranial extension. MRI and CT scan also can help in staging of the disease and also diagnosis of trilateral retinoblastoma. In bilateral cases, it is better to do MRI to decrease the risk of secondary tumors by decreasing the exposure to radiations and is most sensitive to detect CNS involvement and rule out trilateral retinoblastoma^{45, 46}. CT scan is sensitive in revealing intraocular calcifications (sensitivity 81–96%) but is no longer recommended because poses a

risk of secondary tumours from radiation exposures and has a lower sensitivity in detecting optic nerve invasion in retinoblastoma patients due to its low soft-tissue contrast^{1,45}.

In the study only 5 patients (14.7%) had MRI done where 4 patients had extraocular mass extension (3 had optic nerve invasion by histology and 1 did not have surgery done because parents declined) and intracranial extension was found in 1 patient (This was a 4 year old child that underwent enucleation and tumor was noted at the resection margin)

Nyaka et al found 4 patients with extraocular mass and 1 patient with intracranial extension on the CT scan²⁸ and Nyawira et al found around 4 patients had evidence of intracranial extension on the CT scan³.

6.7.2 Histopathology findings and Prognosis

The most common histopathologic high risk factors reported in this study were optic nerve involvement (54.9%) and resection margin involvement (33.3%), although we noted that were not documented in a significant number of eyes (Optic nerve not documented in 11.7% and resection margin in 39.2 %). In 9.8% of the eyes the optic nerve was recorded as "Optic nerve difficult to recognize or not identifiable " possibly pointing to poor specimen handling, preservation (not put in formalin immediately such that it undergoes decomposition before it reaches pathologist) as well as poor processing and identification of the eye structures during histopathologic analysis. We also found periocular tissues involvement in 33.3 % of the eyes, guiding to a high possibility of extraocular involvement. On the other hand, majority of the patients did not have documentation of choroid and sclera (96 % and 98% respectively). Also none of the patients had documentation of the Cerebrospinal Fluid (CSF) and Bone Marrow Aspirate (BMA) cytology.

In Kenya, Nyawira et al, also found a significant but less proportion of patients with optic nerve involvement (24 %) and resection margin involvement (21%). They also found retrolaminar with resection margin free in 3%, choroid extension in 10.4% and extraocular disease in 37% of patients. Missing histology records was found in 20% and the extension of the tumor was not indicated on the histology of 13.3% patients³.

In a study done in USA, University of California and Miami, Uusitalo et al, found a higher number of cases (63.5%) with optic nerve involvement, 13.4% had tumor extension beyond the lamina cribrosa, but fewer patients (4.8 %) had involvement of the resection margin. They

also found choroid involvement in 33.3 % of patients and 2.3 % of cases had tumor invading the sclera. One patient with tumor extending to the surgical margin of the optic nerve died of metastatic disease²⁴.

Histology results have an important role in the management of retinoblastoma patients and in predicting the prognosis. The major histopathologic prognostic factors to take in consideration for the disease dissemination are usually patients with massive choroidal involvement, scleral or extrascleral involvement and optic nerve involvement beyond the lamina cribrosa (retrolaminar). Involvement of the resection margin is the major prognostic factor with a mortality rate of 50-81%. Anterior chamber or uveal structures infiltration are also important histopathologic high-risk factors for metastasis^{4, 18, 24, 42, 43}.

Magrann et al observed the following mortality rate for different stages in optic nerve involvement: superficial optic nerve head invasion (10%), lamina cribrosa (29%), optic nerve involvement posterior to the lamina cribrosa but anterior to the resection margin (42%) and involvement at the surgical resection line (78%)⁴³.

During the study period we identified 2 patients who died: One had resection margin involvement (associated with abdominal mass, severe anemia with blood dyscrasia) and in the other patient the optic nerve was difficult to identify on histology, with an MRI confirming involvement of optic nerve. Nyawira et al found that Out of 77 patients who died, 34 patients (44.2%) had extraocular disease. Six patients had choroid invasion without sclera or ciliary body involvement, out of this 6 patients 5 died after 3 years. Therefore they found a very low survival rate (26.6%) in the 3 years study period³.

6.8 MANAGEMENT

6.8.1 Treatment Modalities, Indications and Regime

In this study, out of a total of 57 patients, 49 (86%) patients had surgery of which 45 (93.9%) patients had enucleation and 9 (18%) patients had exenteration. Three of the patients who had enucleation also underwent exenteration due to tumor recurrence.

A total of 8 patients (14 %) did not have any intervention because the parents of five patients declined surgery and requested to be discharged probably to consult family members, two patients had advanced disease(No file available) and one patient was not ready because had severe anemia and respiratory infection. The number of patients who declined surgery was high showing the need of more parents counseling to understand the consequence, complications and prognosis of the disease.

We also noted that out of the total of 57 patients found during the study, only 34 patients had the file to analyze the proportion of patients who received chemotherapy. Out of the 34 patients a total of 23 patients (67.7%) were eligible for chemotherapy, but out those only 12 patients (35.3%) received chemotherapy. There were other eligible patients for chemotherapy based on the clinical and histological criteria (32.4%, 11), but did not received chemotherapy (due to unknown reasons, died, awaiting histology at that time).

The other 11 patients with available file did not receive chemotherapy because 5 patients had no intervention (declined), 2 had no documentation of the optic nerve spread, 1 was sick and 3 did not have clinical and histological criteria for chemotherapy.

The criteria used in those patients who received chemotherapy were: Big orbital tumors with difficult surgical intervention, histological confirmation of optic nerve or resection margin involvement. But we noted that some other retinoblastoma patients with "proptosis" were awaiting surgery for histological confirmation of the disease before chemoreduction Therefore there were no clear eligibility criteria for chemotherapy.

Also with the inadequate histology reporting in some of the patients (11.7%) and lack of EUAs in the other eye, it was difficult to determine who should have received chemotherapy or no, and is also possible that some deserving patients missed chemotherapy with fatal consequences. Lack of EUAs meant that many of the patients (97.1%) did not have EUA done to identify early tumors in patients that could be having bilateral retinoblastoma for salvage therapy.

We did not find any modalities of treatment of intraocular retinoblastoma for globe salvage like laser therapy, cryotherapy, laser hypothermia or brachytherapy. These modalities are important in the salvage therapy of intraocular disease in cases of early presentation or in case of salvage of the fellow eye after enucleation of the first eye.

According to various studies done all over the world, different indications for chemotherapy in retinoblastoma patients should include: Treatment of intraocular bilateral retinoblastoma (for globe salvage)^{1, 18, 55, 62-67} extraocular extension (Orbital disease -Proptosis) and the histopathology high-risk factors (Massive choroidal involvement, scleral or extrascleral involvement and optic nerve involvement beyond the lamina cribrosa with or without involvement of the resection margin)^{4, 23, 24}.

In the study out of the 12 patients who were on chemotherapy, 8 patients received Vincristine, Etoposide and Carboplatine (VEC). Two patients had cisplatin added to the regime of VEC; these were patients who underwent exenteration and histology had shown resection margin involvement. The others two patients received adriamycin, cyclophosphamide, Actinomycin; therefore there was no clear standard chemotherapy protocol.

Out of the 12 patients on chemotherapy, 5 patients received less than 4 courses and were lost to follow up without finishing the regimen, 3 patients received between 4 to 6 courses, and 4 patients received more than 6 courses. Most of the patients received chemotherapy after enucleation and one was given for chemoreduction previous to exenteration.

There are no randomized clinical trials on the proper regimes in the management of retinoblastoma. However most centers (like in USA, Canada and India) use the VEC regime with a good success, having a high success: On enucleated eyes with high risk features on histopathology^{4, 23, 24} and adjuvant chemotherapy treatment for intraocular retinoblastoma^{4, 65, 67, 72}. Hanovar et al, for example has a protocol in the management of retinoblastoma where patients with high histopathology risk factors should do a baseline systemic evaluation for metastasis and standard 6 cycle of adjuvant chemotherapy. In patients with extraocular extension, scleral infiltration, and optic nerve extension to transection should be given a high dose adjuvant chemotherapy and orbital external beam radiotherapy⁴.

In Malawi, Nyaka et al found 75% (36) patients who had enucleation and 22.9% (11) patients who had exenteration. They also found slightly fewer patients (8.8%, 6) who declined surgery. In the same study there was no well-established Chemotherapy protocol, having only

5 patients on cyclophosphamide and 1 patient on a single dose of etoposide and there was no patient found on intraocular focal therapy or radiotherapy in the study due to non-availability of these therapeutic choices during the study period (2005-2009), they noted that chemotherapy was given for palliation in recurrent disease and they were concerned on the need to improve therapeutic options in the management of retinoblastoma in Malawi²⁸.

Nyamori et al found 48.5% of patients were enucleated at the first centers and 58.8% were finally treated at KNH. Of 53% who received chemotherapy, few (14.3%) were treated at church based and provincial hospital but most (85.7%) were treated at referral hospitals. They also found few cases (4.5%) that declined enucleation. Kenyatta National Hospital (KNH) is a referral hospital that has ophthalmologists well trained and an organized setting for globe salvage and radiotherapy management, therefore Nyamori et al, in his study period (2006-2007) found 6 cases (4.5%) on focal therapy and 16 cases (12.1%) on radiotherapy¹⁴.

6.9 CONCLUSIONS

1. The average age at presentation was high 30.5 months, almost similar to other developed countries. Most patients presented late with mean delay of 6.9 months from initial presentation. There was no significant sex predilection
2. Majority of the patients had unilateral retinoblastoma (82.4%).
3. Most patients presented with leukocoria (62.5%). There was however a high percentage of patients with late presentation feature like proptosis (50%). There was tumor recurrence in 8.8% of patients
4. The main method of diagnosis was clinical. Routine EUA/Fundoscopy of the other eye where not documented in most of the patients (97.1%). Few patients had ocular ultrasound and orbit MRI done
5. The definitive method of diagnosis was histology, although it was not well done because some histopathologic high risk factors were not documented, especially choroidal and scleral involvement (96% and 98% respectively). Lack of visualization of optic nerve was found in some cases (9.8%) pointed to poor processing of eye balls
6. High proportion of patients had optic nerve (54.9%) and resection margin involvement (33.3%) as well as periocular tissues (31.4%)
7. The main modalities of management were enucleation (93.9%), exenteration (18%) as well as chemotherapy (24.5%). Although between the eligible patients for chemotherapy (64.6%), only 35.6% of the patients received chemotherapy
8. There were no patients on globe salvage therapy using laser, cryotherapy or radiotherapy

6.10 RECOMMENDATIONS

1. There is a need to create awareness of the disease to the health care workers and the community for an early approach to the health facilities to ensure early diagnosis in young ages
2. There is a need to improve on the histopathology by:
 - a) A proper processing of eyeballs from the time of the enucleation to mounting on the slides for a better histopathologic report
 - b) Create a histology form specifying the different parts of the eye that could be involved (Choroid, sclera, optic nerve and resection margin) since they are the main indicators for the management and prognosis and the same adhered to by pathologists
3. There is a need to create an appropriate protocol for treatments of the different clinical and histopathologic stages of the disease considering the different treatment modalities of retinoblastoma
4. There is a need for equipment (laser machine, cryotherapy equipment) as well as a radiotherapy unit for the cases that require these services
5. There is a need to perform routine EUAs/ fundoscopy on the other eye and patient relatives according to recommended protocols, as well as documentation of the important findings (EUA/ Fundoscopy, ocular ultrasound) for a better management and follow up of the patients
6. There is a need for more studies showing the prevalence and the survival rate of retinoblastoma patients in Mozambique.
7. There is a need to work in coordination with the record service to ensure an adequate storage and retrieval of patient files

6.11 STUDY LIMITATION

The challenges of this study were:

1. There was poor patient records keeping and incomplete medical records documentation:
 - a) Some of the patients included did not have the IP number and a code had to be used for every patient
 - b) Missing files: Some patients files were missing and some had 2 IP numbers (One from registration books and another different IP number from histology records) making it difficult to retrieve the file
 - c) Majority of the patients submitted to a procedure did not have EUA finding documented (Measurement of optic nerve, sclera appearance and fundoscopy of the other eye)

REFERENCES

1. Ophthalmologists, American Academy of. Ophthalmic Pathology and Intraocular Tumours: Section 4 – BCSC: AAO, 2012 – 2013
2. MacCarthy A, Birch JM, Draper GL, et al. “Retinoblastoma: treatment and survival in Great Britain 1963 to 2002,” *British Journal of Ophthalmology*.2009; 93(1): 38–39
3. Nyawira G, Kahaki K, Kariuki M. Survival among Retinoblastoma patients at KNH, Kenya. *Journal of Ophthalmology of Eastern Central and Southern Africa* August 2013; 17(1): 15-19
4. Honavar S.G, Retinoblastoma: They Live and See! AIOS ... MD, FACS Head, Ocular Oncology Service, LV Prasad Eye InstituteLV Prasad Marg, Banjara Hills, Hyderabad 500034, India
5. Foucher ES, Stiller CA. International classification of Childhood Cancer, third edition. *Cancer* 2005 apr 1; 103(7):1457- 67
6. Agboola AO, Adekanmi FA, Musa AA, et al. Pattern of childhood malignant tumours in a teaching hospital in south-western Nigeria. *Med J Aust*. 2009 Jan; 190 (1):12-4
7. Welbeck JE, Hesse AA. Pattern of childhood malignancy in Korle Bu Teaching Hospital, Ghana. *West Afr. Med. J* .1998; 17(2) 81-4
8. Mostert S, Njuguna F, Kemps L, et al. Epidemiology of diagnosed childhood cancer in western Kenya *Arch Dis Child* 2012;97:508-512
9. Kivela T. The epidemiological challenge of the most frequent eye cancer: retinoblastoma, an issue of birth and death. *Br J Ophthalmol* 2009; 93: 1129–31
10. Broaddus E, Topham A, Singh AD. Incidence of retinoblastoma in the USA: 1975-2004. *Br J Ophthalmol* 2009; 93:21-23

11. Seregard S, Lundell G, Svedberg H, Kivelä T. Incidence of retinoblastoma from 1958 to 1998 in Northern Europe: advantages of birth cohort analysis. *Ophthalmology* 2004; 111:1228
12. Owøeye JFA, Afolayan EAO, Ademola-Popoola DS. Retinoblastoma – a clinicopathologic study in Ilorin Nigeria. *Afr J Health Sci* 2005; 12(3-4): 94-100
13. Freedman J, Goldberg L: Incidence of retinoblastoma in the Bantu of South Africa. *Br J Ophthalmol* 1976; 60:655–656
14. Nyamori JM, Kimani K, Njuguna MW, Dimaras H. The incidence and distribution of retinoblastoma in Kenya. no. 1; pp. 141–3, s.l.: The British Journal of Ophthalmology, Jan 2012, Vols. vol. 96
15. Abiose A, Adido J, Agarwal SC. Childhood malignancies of the eye and orbit in Northern Nigeria: Cancer. 1985; 55; 2889-2893
16. Albert DM, Lahav M, Lesser, et al. Recent observations regarding retinoblastoma: ultra-structure, tissue culture growth, incidence and animal models. *Trans Ophthalmol Soc UK* 1974; 94:909-928
17. BenEzra D, Chirambo MC. Incidence of Retinoblastoma in Malawi. *J Pediatr Ophthalmol.*1976 Nov-Dec, 13 (6): 340-343
18. Dimaras H, Kimani K, Dimba EAO, et al. Retinoblastoma. *The Lancet.* April 2012, 379 (9824): 1436–1446
19. Dimaras H, Dimba E, Gallie BL. Challenging the global retinoblastoma survival disparity through a collaborative research effort. *Br J Ophthalmol* 2010; 94:1415–1416
20. Chang CY, Chiou TJ, Hwang B, et al. Retinoblastoma in Taiwan: survival rate and prognostic factors. *Jpn J Ophthalmol.* 2006 May–Jun; 50(3):242–249

21. Bowman RJC, Mafwiri M, Luthert P, et al. Outcome of Retinoblastoma in East Africa *Pediatr Blood Cancer* 2008;50:160–162
22. Kimani K, Ilako D, Kollmann M, A review of retinoblastoma, presentation, diagnosis and management at Kenyatta National Hospital. University of Nairobi, 2000. Unpublished
23. ElZomor H, Taha H, Aleieldin A, et al. High Risk Retinoblastoma: Prevalence and Success of Treatment in Developing Countries, *Ophthalmic Genetics*, 2015, 36(3): 287-289
24. Uusitalo MS, Van Quill KR, Scott IU, et al. Evaluation of Chemoprophylaxis in Patients with Unilateral Retinoblastoma with High-Risk Features on Histopathologic Examination. *Arch Ophthalmol*. 2001 Jan; 119 (1) 41-48
25. MacCarthy A, Draper GJ, Steliarova-Foucher E, Kingston JE. Retinoblastoma incidence and survival in European children (1978–1997). Report from the Automated Childhood Cancer Information System project. *Eur J Cancer*. 2006 Sep; 42(13):2092–2102
26. Kanski JJ. Bowling B. *Clinical Ophthalmology, a Systematic Approach*. : Elsevier Saunders, 7th ed. 2011. ISBN-13: 978070204095-5
27. Singh SK, Das D, Bhattacharjee H, et al. A rare case of adult onset retinoblastoma. *Oman J Ophthalmol* 2011; 4(1): 25-27
28. Nyaka AS, Kimani K, Kollmann MK, The pattern of Retinoblastoma at Queen Elizabeth Central Hospital, Malawi. University of Nairobi. M. Med Ophthalmology Thesis, 2010
29. Kaimbo WA, Kaimbo D, Mvitu MN, Missotten L. Presenting signs of retinoblastoma in Congolese Patients. *Bull Soc Belge Ophthalmol* 2002; 283: 37-41

30. Akang EE, Ajaiyeba IA, Campbell OB, et al. Retinoblastomas in Ibadan Nigeria-II: Clinicopathologic features. *West Afr J Med* 2000; 19(1): 6-11
31. Friend SH, Bernards R, Rogelj S, et al. A Human DNA segment with properties of the gene that predisposes to retinoblastoma and osteosarcoma. *Nature*. 1986; 323:543–646
32. Murphree AL, Benedict WF: Retinoblastoma: Clues to human oncogenesis. *Science* 1984; 223:1028–1033
33. What are the risk factors for retinoblastoma? www.cancer.org. 05/12/ 13
34. Makite I, Kimani K, Njuguna MW, Delay in presentation and management of retinoblastoma patients at Kenyatta National Hospital. September-2014
35. Second cancers after retinoblastoma –American Cancer Society www.cancer.org. 05/12/13
36. MacCarthy A, Bayne AM, Draper GJ, et al. Non-ocular tumours following retinoblastoma in Great Britain 1951 to 2004. *Br J Ophthalmol*. 2009 Sep; 93(9):1159-62
37. Kleinerman RA, Tucker MA, Tarone RE et al. Risk of New Cancers After Radiotherapy in Long-Term Survivors of Retinoblastoma: An Extended Follow-Up, *American Society of Clinical Oncology* April 1, 2005 Apr 1; 23(10) 2272-79
38. Abramson DH, Frank CM, Susman M, Whalen MP, Dunkel IJ, Boyd NW 3rd. Presenting signs of retinoblastoma *J Pediatr*. 1998 Mar; 132(3 Pt 1):505-8
39. Shuanggoti SJ, Chuiwum B, Kasantikul V: A study of 39 retinoblastomas with reference to morphology, cellular differentiation and tumour origin. *Histopathology* 198(1):255-8

40. Palazzi M, Abramson DH, Ellsworth RM: Endophytic vs. exophytic unilateral retinoblastoma: Is there any real difference? *J Pediatr Ophthalmol Strabismus* 1990; 27: 255–258
41. Xu KP, Lu SL, Ni C. Immunohistochemical evidence of neuronal and glial differentiation in retinoblastoma. *Br J Ophthalmol* 1995;79:771-776
42. Khelifaoui F, Validire P, Auperin A, et al. Histopathologic risk factors in retinoblastoma: a retrospective study of 172 patients treated in a single institution. *Cancer* 1996; 77:1206–13
43. Magrann I, Abramson DH, Ellsworth RM. Optic nerve involvement in retinoblastoma. *Ophthalmology* 1989; 96:217–22
44. Roth DB, Scott IU, Murray TG, et al. Echography of retinoblastoma: histopathologic correlation and serial evaluation after globe-conserving radiotherapy or chemotherapy. *J Pediatr Ophthalmol Strabismus*. 2001; 38:136–143
45. Graaf P, Görlicke S, Rodjan F, et al. Guidelines for imaging retinoblastoma: imaging principles and MRI standardization *Pediatr Radiol* (2012) 42:2–14
46. Chawla B, Sharma S, Sen S, et al. Correlation between Clinical Features, Magnetic Resonance Imaging, and Histopathologic Findings in Retinoblastoma: A Prospective Study. *Ophthalmology* 2012; 119(4): 850–856
47. AB Reese, RM Ellsworth. The evaluation and current concept of retinoblastoma therapy. *Trans Am Acad Ophthalmol Otolaryngol*, 67 (1963):164–172
48. Chintagumpala M, Barrios PC, Paysse EA, Retinoblastoma: Review of current management *The Oncologist* 2007 Oct; 12: 10 1237- 46
49. Murphree LA. Intraocular retinoblastoma: The case for a new group classification *Ophthalmol Clin North Am*. 2005;18: 41–53

50. Finger P, Harbour J, Murphree A, *et al.* **Retinoblastoma**. AJCC Cancer Staging Manual, 7th edn. Springer Science and Business Media, Berlin (2010), 52:561–568
51. Purposes and Principles of Cancer staging –Sutter Medical
www.suttermedicalfoundation.org /(<http://www.cancerstaging.org/cstage/index.html>)
52. Chantada G, Doz F, Antoneli CBG, *et al.* A proposal for an International Retinoblastoma Staging System, *Pediatr Blood Cancer* 2006 Nov; 47(6): 801 – 805
53. Retinoblastoma. Best practice guideline 2014. Kenya National Retinoblastoma Strategy, Ministry of Health. Daily’s Eye Cancer Fund, Life and sight for every child.
www.daisyfund.org
54. Meel R, Radhakrishnan V, Bakhshi S. Current therapy and recent advances in the management of retinoblastoma *Indian J Med Paediatr Oncol.* 2012 Apr-Jun; 33(2): 80–88
55. Shields CA, Shields JA. Recent development in the management of retinoblastoma: *J Pediatric Ophthalmol. Strabismus* 1999; 36:8-18
56. Abramson DH, Retinoblastoma in the 20th Century: Past Success and Future Challenges The Weisenfeld Lecture *Invest. Ophthalmol. Vis. Sci* 2005 Aug; 46(8):2684-91
57. Shields JA, Shields CL, Parsons H, *et al.* The role of photocoagulation in the management of retinoblastoma. *Arch Ophthalmol* 1990 feb; 108(2):205-208
58. Shields CL, Shields JA, Kiratli H, *et al.* Treatment of retinoblastoma with indirect ophthalmoscope laser photocoagulation. *J Pediatr Ophthalmol Strabismus* 1995; 2:317-322
59. Shields JA. The expanding role of laser photocoagulation for intraocular tumors. The 1993 H. Christian Zweng Memorial Lecture. *Retina* 1994; 14:310-322

60. Shields JA, Parsons H, Shields CL, et al The role of cryotherapy in the management of retinoblastoma. *Am J Ophthalmol* 1989; 108:260- 264
61. Shields CL, Mashayekhi A, Sun H: Iodine 125plaque radiotherapy as salvage treatment for retinoblastoma recurrence after chemoreduction in 84 tumors, *Ophthalmology* 2006Nov; 113(11): 2087-92
62. Demirci H, Shields CL, Meadows AT, et al. Long-term visual outcome following chemoreduction for retinoblastoma. *Arch Ophthalmol* 2005; 123 (11): 1525-30.
63. Antoneli CB, Ribeiro KC, Steinhorst F, et al. Treatment of retinoblastoma patients with chemoreduction plus local therapy: Experience of the AC Camargo Hospital, Brazil. *J Pediatr Hematol Oncol* 2006; 28 (6): 342-5
64. Chan HS, Gallie BL, Munier FL, Popovic B M. Chemotherapy for retinoblastoma. *Ophthalmol Clin North Am.*Mar 2005; 18 (1):55-63
65. Shields CL, Shields JA, Needle M, et al. Combined chemoreduction and adjuvant treatment for intraocular retinoblastoma. *Ophthalmology* 1997; 104 (12): 2101-11
66. Friedman DL, Himelstein B, Shields CL, et al. Chemoreduction and local ophthalmic therapy for intraocular retinoblastoma. *J Clin Oncol* 2000; 18 (1): 12-7
67. Wilson MW, Rodriguez-Galindo C, Haik BG, et al. Multiagent chemotherapy as neoadjuvant treatment for multifocal intraocular retinoblastoma. *Ophthalmology* 2001; 108 (11): 2106-14
68. Gallie BL, Budning A, DeBoer G, et al. Chemotherapy with focal therapy can cure intraocular retinoblastoma without radiotherapy. *Arch Ophthalmol* 1996; 114(11): 1321-8
69. Abramson DH, Lawrence SD, Beaverson KL, et al. Systemic carboplatin for retinoblastoma: change in tumour size over time. *Br J Ophthalmol* 2005; 89 (12): 1616-9

70. Kingston JE, Hungerford JL, Madreperla SA, et al. Results of combined chemotherapy and radiotherapy for advanced intraocular retinoblastoma. *Arch Ophthalmol* 1996; 114 (11): 1339-43
71. Shields CL, Mashayekhi A, Cater J, et al. Chemoreduction for retinoblastoma: Analysis of tumor control and risks for recurrence in 457 tumors. *Trans Am Ophthalmol Soc.* 2004; 102:35–44
72. Chan HS, DeBoer G, Thiessen JJ, et al. Combining Cyclosporin with chemotherapy controls intraocular retinoblastoma without requiring radiation. *Clin Cancer Res* 1996; 2 (9): 1499-508
73. National retinoblastoma strategy Canadian guidelines for care
https://www.orpha.net/.../retinoblastoma_canadian_guidelines_EN2009
74. Follow-up after treatment for retinoblastoma - Canadian...
www.cancer.ca/.../retinoblastoma/.../follow-up/? Canadian Cancer Society

APPENDICES

APPENDIX I: REESE-ELLSWORTH CLASSIFICATION OF RETINOBLASTOMA FOR EYE PRESERVATION

Group 1: Very Favourable	A. Solitary tumor < 4 disc diameter (DD) in size, at or behind equator
	B. Multiple tumors < 4 DD in size, all at or behind equator
Group 2: Favourable	A. Solitary tumor 4 to 10 DD in size, at or behind equator
	B. Multiple tumors, 4 to 10 DD in size, behind equator
Group 3: Doubtful	A. Any tumor anterior to equator
	B. Solitary tumor >10 DD, behind equator
Group 4: Unfavourable	A. Multiple tumors, some larger than 10 DD
	B. Any lesion extending anteriorly to the ora serrata
Group 5: Very Unfavourable	A. Massive tumor occupying half or more of retina
	B. Vitreous seeding

APPENDIX II: INTERNATIONAL CLASSIFICATION OF RETINOBLASTOMA

Group A	<ul style="list-style-type: none"> - Small intraretinal tumors ≤ 3mm confined to the retina (>3mm away from the fovea and >1.5mm away from the disc)
Group B	<ul style="list-style-type: none"> - Large Tumors >3 mm, macular or juxtapapillary location (≤ 3mm to the fovea and ≤ 1.5mm to the disc) - Subretinal fluid ≤ 3mm from the tumour margin
Group C	<ul style="list-style-type: none"> - Localized vitreous and/or subretinal seeding (≤ 3 mm in total from the tumour margin)
Group D	<ul style="list-style-type: none"> - Diffuse vitreous and/or subretinal seeding (>3 mm in total from the tumour margin)
Group E	<ul style="list-style-type: none"> - No visual Potential, tumor occupying > 50 % of the globe - Presence of 1 or more of the following: Tumor touching lens, Neovascular glaucoma, hyphaema, vitreous haemorrhage, extension of tumor to optic nerve or anterior segment, orbital cellulitis or phthisis bulbi. Suspected extraocular disease on imaging

APPENDIX III: INTERNATIONAL RETINOBLASTOMA STAGING SYSTEM

Stage 0	Patients treated conservatively
Stage I	Eye enucleated, tumor completely resected on histopathology examination
Stage II	Eye enucleated, microscopic residual tumor present in the form of: <ul style="list-style-type: none">- Tumor invasion into extrascleral tissue- Tumor invasion in to cut end of optic nerve
Stage III	Regional extension: <ul style="list-style-type: none">- Overt orbital disease- Pre-auricular or cervical lymph node extension
Stage IV	Metastatic disease: <ol style="list-style-type: none">1. Hematogenous metastasis (without CNS extension):<ul style="list-style-type: none">- Single lesion- Multiple lesion2. Central nervous system extension (with or without any other site of regional or metastatic disease):<ul style="list-style-type: none">- Prechiasmatic lesion- CNS mass- Leptomeningeal and cerebrospinal fluid disease

APPENDIX IV: QUESTIONNAIRE

Title: A 5 years retrospective case series on the clinical profile and management of retinoblastoma at Maputo Central Hospital, Mozambique (1st January 2010 to 31st December 2014)

1. FORM SERIAL NUMBER _____

2. DEMOGRAPHIC DATA:

2.1 Date of Birth: ____/____/____

2.3 Sex: Male ____ Female ____

2.4 Laterality: RE____ LE _____

3. HEALTH FACILITY PRESENTED TO:

	1 st Health Facility presented
Province	
Type of facility	
Date of presentation	

4. DELAYS IN DIAGNOSIS:

Delay	Age(Month)				
4.1) When did the parents first note the symptoms?					
4.2) When did the parents visit the 1 st facility?					
4.3) Were the nurses, technicians or doctors referred the patient to the 2 nd facility? <table border="1" style="margin-left: auto; margin-right: auto;"> <tr> <td>Yes</td> <td></td> </tr> <tr> <td>No</td> <td></td> </tr> </table> 4.3.1) If Yes, When did the parents visit the 2 nd facility?	Yes		No		
Yes					
No					
4.4) Were the parents referred to MCH? <table border="1" style="margin-left: auto; margin-right: auto;"> <tr> <td>Yes</td> <td></td> </tr> <tr> <td>No</td> <td></td> </tr> </table> 4.4.1) If yes, When did they visit MCH?	Yes		No		
Yes					
No					

5. PRESENTATION TO MCH:

Date of first presentation to MCH	
Age at diagnosis in MCH (month)	

6. RELATIONSHIP OF GUARDIAN:_____

7. FAMILY HISTORY OF RETINOBLASTOMA:

Yes___ No___ Undocumented ___ if yes, specify relationship _____

8. PRESENTING COMPLAINTS:

Symptoms	RE	LE	Duration RE	Duration LE
White reflex				
Squint				
Poor vision				
Tearing				
Eye Swelling				
Eye redness				
Others				

9. CLINICAL FINDINGS:

Physical Examination	RE	LE
Leukocoria		
Strabismus		
Eye redness		
Orbital cellulitis		
Proptosis		
Pseudohypopyon		
Vitreous mass		
Fungating mass		
Buphthalmos		
Others		

10. FUNDOSCOPY DONE?

Yes____ No ____ Undocumented _____ If yes, how many times? _____

RE _____ Findings _____

LE _____ Findings _____

Frequency	
Monthly	
Every 3 month	
Every 6 month	
Every 1 year	

11. EUA DONE?

Yes____ No____ Undocumented _____ If yes, how many times? _____

RE _____ Findings _____

LE _____ Findings _____

Frequency	
Monthly	
Every 3 month	
Every 6 month	
Every 1 year	

12. INVESTIGATIONS DONE:

12.1 HISTOLOGY REPORT? Yes____ No ____ Undocumented _____

Stage		RE	LE
Differentiation	Undifferentiated		
	Differentiated		
Growth	Exophytic		
	Endophytic		

Spread	RE		LE	
	Yes	No	Yes	No
Choroidal invasion				
Scleral invasion				
Lamina cribrosa invasion				
Length of Optic nerve(mm)				
ON invasion				
Resection margin involved				
CSF Involvement				
Bone marrow involvement				

12.2) OCULAR ULTRASOUND DONE? Yes____ No____ Undocumented ____

Ocular U/S	RE	LE
Intraocular mass		
Evidence of Calcifications		

12.3) CT - SCAN DONE? Yes____ No____ Undocumented ____

CT Scan	RE	LE
Intraocular mass		
Extra ocular mass		
Intracranial extension		
Pineal gland involvement		

12.4) MRI DONE? Yes _____ No _____ Undocumented _____

MRI	RE	LE
Intraocular mass		
Extraocular mass		
Intracranial extension		
Pineal gland involvement		

13. CLASSIFICATION OF RETINOBLASTOMA:

Clinical _____ Pathological _____

14. MANAGEMENT DONE: Yes _____ No _____

Procedure done?	RE	LE
Enucleation		
Exenteration		
Laser photocoagulation		
Cryotherapy		
Radiotherapy		

14.1 CHEMOTHERAPY RECEIVED?

Yes _____ No _____ Undocumented _____

14.1.1 Number of courses _____

14.1.2 Regimen (Drugs):

Carboplatine _____ Etoposide _____ Others _____

Vincristine _____ Cisplatin _____

15. DELAY OF TREATMENT:

Delay (Duration)	Days	Month
Period since admission at MCH until 1 st intervention(Management done)		

16. FOLLOW UP: Yes _____ No _____ Undocumented _____

Number of follow up visits _____ Date of last visit ____/____/____

Frequency	
Monthly	
Once every 3 months	
Once in 6 months	
Once a year	

17. OUTCOME:

17.1 PATIENT ALIVE? Yes _____ No _____ Unknown _____

a) Age (Month) _____

b) If alive, disease free: Yes _____ No _____ Unknown _____

c) Tumour regrowth: Yes _____ No _____ Unknown _____

17.2 PATIENT DEATH? Yes _____ No _____ Unknown _____

a) Age (months) _____

b) Cause of Death: - Metastasis _____

- Others _____ specify _____

- Unknown _____

APPENDIX V: GANTT CHART SHOWING TIMEFRAME

Activity	2013	2014				2015		2016			
	Nov- Dic	Jan- May	Jun	Jul- Nov	Dic	Jan- Nov	Dic	Jan	Feb	Mar	Apr- May
Proposal development											
Proposal presentation											
Ethical approval KNH											
Ethical approval MCH											
Data collection											
Data analysis											
Report writing											
Results presentation/ approval											
Dissemination /Final book preparation											

APPENDIX VI: BUDGET

ITEM	Quantity	Unit Cost (Ksh)	Total cost (Ksh)
Printing of proposal 1 st drafts	54 pages	20	1,080
Photocopy of proposal 1 st drafts	108 pages	3	324
Printing of proposal 2nd drafts	54 pages	20	1,080
Photocopy of proposal 2nd drafts	108 pages	3	324
Photocopy of proposal to be analyzed by Ministry of Health Mozambique	108 pages	3	324
Binding Proposal	8 copies	100	800
Ethics submission fee	1	2,000	2,000
Approval letter from Ministry of Health Mozambique & Hospital (MCH)	4 pages	3	12
Sub-total			5,944
DATA TOOLS AND COLLECTION			
Printing Tools-questionnaire (Appendix III)	9 pages	10	90
Photocopy Tools- questionnaire(Appendix III)	9 pages x 170	3	4,590
Flash Disc (tools)	1	1,500	1,500
Email		3,000	3,000
Sub-total			9,180
CONTRACTED SERVICES			
Research Assistants (clerks)	31 days	400	12,400
Data entry clerks	10 days	1,000	10,000
Data analyst		32,000	32,000
Sub-total			54,400
TRANSPORT COSTS/STUDY LOCATION			
Nairobi -Maputo	Return Ticket	80,000	80,000

Accommodation	31 days	1,800	55,800
Meals	31 days	1,000	31,000
Sub- total			166,800
RESULTS AND TEMPORARY BOOK			
Printing of results ((black & white)	65 pages	20	1,300
Photocopy of results (black & white)	65 pages x 2	3	390
Printing of results (colored)	15 pages x 3	30	1,350
Binding of books temporary	3 copies	100	300
Sub-total			3,340
PRINTING AND BINDING FINAL BOOK			
Printing final book (black & white)	65 pages	10	650
Photocopy of final book (black & white)	65 x 8 copies	3	1,560
Printing final book (colored)	15pages x9	30	4,050
Binding of books	9 copies	200	1,800
Sub -total			8,060
TOTAL			247,724

APPENDIX VII: LETTER OF APPROVAL FROM MAPUTO CENTRAL HOSPITAL



MAPUTO CENTRAL HOSPITAL

Cirurgia Departament

Oftalmologia Service

In consideration to the research Work that shall take place between November and December, 2015 entitled:

A 5 YEAR'S RETROSPECTIVE CASE SERIES ON THE CLINICAL PROFILE AND MANAGEMENT OF RETINOBLASTOMA AT MAPUTO CENTRAL HOSPITAL, MOZAMBIQUE

Supervised by DR YOLANDA ZAMBUJO and DR FAISANA AMAD,

We hereby accept that the researcher **LÁCEA STELA ALFREDO DIMANDE**, a resident medical specialist, in the area of ophthalmology, carry out data collection, in the Ophthalmology Service of the Maputo Central Hospital, bearing in mind that the study will contribute for statistical date and improvement of retinoblastoma patient management, in the Maputo Central Hospital.

Maputo, On this 20th day of November 2015

Tha Head of Ophthalmology service of the Maputo Central Hospital


.....
Dr. Yolanda Zambujo
Oftalmologista

Dr. Yolanda Zambujo

Ophthalmologist and Hospital Consultant



2/

OFFICIAL TRANSLATION

BIOETHICS INSTITUTIONAL COMMITTEE IN HEALTH OF FACULTY OF MEDICINE/ MAPUTO CENTRAL HOSPITAL (CIBS FM&HCM)

Dr. **Jahit Sarcarlal**, president of the Bioethics Institutional Committee in Health of the Faculty of Medicine/ Maputo Central Hospital (CIBS FM&HCM) hereby **CERTIFIES** that the Committee has assessed the proposal of the researcher:

Name: LÁCEA STELA A. DIMANDE
Research Protocol: Version of May 2, 2015
Consent Informed: N/A
Inquiry: Version of May 2, 2015

RESEARCH TITLE:

TITLE: *“A 5 Year’s retrospective case series on the clinical profile and management of retinoblastoma at Maputo Central Hospital, Mozambique”*

We further certify that:

1. After review, by Committee Members, of the recommendations made on April 6, 2015, by the Committee, and included in the Minutes 03/2015, the CIBS FM&HCM, hereby informs To Whom It May Concern that there are no ethical inconveniences that may impede the commencement of this Study.
2. The review was carried out in conformity with the Regulation of the Institutional Committee of FM&HCM- amendment 2, of 28 July, 2014.
3. The protocol was registered under number CIBS FM&HCM/16/2015.
4. The current CIBS FM&HCM composition is available in the Committee’s Main Office.
5. No conflict of interest was registered by CIBS FM&HCM Committee Members.
6. CIBS FM&HCM ethical approval does not replace scientific approval or administrative authorization.
7. This approval is valid for 1 year and expires on January 19, 2017. One month prior to the expiration date, the researcher must apply for approval extension, if necessary.
8. The researcher should keep CIBS informed about the course of study, at least once a year.
9. The researcher is asked to send the report at the end of the study

RESULT: APPROVED

Issued in Maputo, on this 20th day of January, 2016

APPENDIX VIII: KNH/UON-ERC APPROVAL LETTER



UNIVERSITY OF NAIROBI
COLLEGE OF HEALTH SCIENCES
P O BOX 19676 Code 00202
Telegrams: varsity
(254-020) 2726300 Ext 44355

KNH/UON-ERC
Email: uonknh_erc@uonbi.ac.ke
Website: www.uonbi.ac.ke

KENYATTA NATIONAL HOSPITAL
P O BOX 20723 Code 00202
Tel: 726300-9
Fax: 725272
Telegrams: MEDSUP, Nairobi

Ref: KNH-ERC/A/373

Link: www.uonbi.ac.ke/activities/KNHUoN

13th November 2014

Dr. Lacea Stela A. Dimande
Dept. of Ophthalmology
School of Medicine
University of Nairobi



Dear Dr. Dimande

Research proposal – A 5 year's retrospective case series on the clinical profile and management of retinoblastoma at Maputo Central Hospital, Mozambique (P551/09/2014)

This is to inform you that the KNH/UoN-Ethics & Research Committee (KNH/UoN-ERC) has reviewed and **approved** your above proposal. The approval periods are 13th November 2014 to 12th November 2015.


This approval is subject to compliance with the following requirements:

- Only approved documents (informed consents, study instruments, advertising materials etc) will be used.
- All changes (amendments, deviations, violations etc) are submitted for review and approval by KNH/UoN ERC before implementation.
- Death and life threatening problems and severe adverse events (SAEs) or unexpected adverse events whether related or unrelated to the study must be reported to the KNH/UoN ERC within 72 hours of notification.
- Any changes, anticipated or otherwise that may increase the risks or affect safety or welfare of study participants and others or affect the integrity of the research must be reported to KNH/UoN ERC within 72 hours.
- Submission of a request for renewal of approval at least 60 days prior to expiry of the approval period. (*Attach a comprehensive progress report to support the renewal.*)
- Clearance for export of biological specimens must be obtained from KNH/UoN-Ethics & Research Committee for each batch of shipment.
- Submission of an *executive summary* report within 90 days upon completion of the study
This information will form part of the data base that will be consulted in future when processing related research studies so as to minimize chances of study duplication and/or plagiarism.

For more details consult the KNH/UoN ERC website www.uonbi.ac.ke/activities/KNHUoN.

Protect to discover

Yours sincerely



PROF. W. L. CHINDIA
SECRETARY, KNH/UON-ERC

c.c. The Principal, College of Health Sciences, UoN
The Deputy Director CS, KNH
The Assistant Director, Health Information, KNH
The Chairperson, KNH/UON-ERC
The Dean, School of Medicine, UoN
The Chairman, Dept. of Ophthalmology, UoN
Supervisors: Prof. Dunera Rahel Ilako, Dr.E.M. Nyenze, Dr. Yolanda Zambujo

Protect to discover